EA DV CONGRESS
VIENNA
30 SEP - 3 OCT 2026

Abstract N°: 4

Clinical Evidence of Improved Post Inflammatory Skin Changes and Skin Oiliness with Continuous Use of aFacial Sunscreen Containing 2% Trehalose and 2% Niacinamide in a Multiethnic Brazilian Population

Isabelle Rennó*[1], Debora Felix[1], Cinthia Satake[1], Maria Carolina Semprini[1], Ana Cláudia Cavalcante Espósito Lemos[2], Marco Rocha[3]

[1] Kenvue Brands LLC, São José dos Campos, Brazil
[2] University of Western São Paulo, São Paulo, Brazil
[3] Federal University of São Paulo, São Paulo, Brazil

Introduction
Oily skin is highly prevalent among Brazilians and holds clinical relevance due to its association with acne development, related sequelae and psychosocial burden, underscoring the need for a comprehensive understanding to ensure effective and individualized management. Multifunctional sunscreens that combine broad-spectrum protection with sebum control, anti-inflammatory action, and skin hydration may serve as a therapeutic tool in the management of this condition alone or associated. The objectives of this study were: 1) to evaluate the efficacy of a broad-spectrum chemical sunscreen SPF 70 formulated with 2% Trehalose and 2% Niacinamide in reducing post inflammatory hyperpigmentation (PIH) and erythema (PIE) induced by acne, specifically acne-induced erythema (AIE) and acne-induced hyperpigmentation (AIH), in a diverse Brazilian population with mild acne after 28 days of continuous use; 2) to investigate the effectiveness of a broad-spectrum chemical sunscreen SPF 70 in reducing skin oiliness and shine, increasing skin hydration over continuous use for 28 days.

Materials and Methods
The efficacy of a broad-spectrum SPF 70 facial sunscreen containing 2% Trehalose and 2% Niacinamide was evaluated in two clinical studies in Brazil: one in individuals with mild acne, assessing AIE and AIH via expert grader before and after 28 days of use; and another in individuals with oily skin, confirmed by instrumental measurements, evaluating oiliness (Sebumeter), shine (Visia), hydration (Corneometer), and self-assessments over the same period.

Results
In the acne multiethnic group (n=32; 54% brown, 40% white, 6% Black), AIE and AIH were significantly reduced by 56% and 46%, respectively ($p < 0.001$) after 28 days. In the oily skin multiethnic group (n=32; 51% white, 46% brown, 3% Black), oiliness decreased by 7% on day 7 and 12% on day 28, with a 10% reduction in shine, according to Sebumeter and Visia assessments. Oiliness reduction was achieved while maintaining skin balance, with a significant 13% increase in hydration after 28 days. Perceived efficacy was high: 90% reported less oiliness and 78% noted reduced acne marks.

Conclusions
These findings confirm the multifunctional sunscreen's efficacy for oily and acne-prone skin without compromising hydration, recognized as an important condition for sebum control. Its combined benefits contribute to improved adherence to daily skincare routines.

Disclosures: This work was sponsored by Kenvue Brands LLC

Author Disclosures: 1. Authors are employees of Kenvue Brands LLC, except 2. M.Rocha and 3. A. Espósito who are consultants (MD)

EADV Congress 2026, VIENNA
30 SEPTEMBER - 03 OCTOBER 2026
POWERED BY M-ANAGE.COM

EA DV CONGRESS
VIENNA
30 SEP - 3 OCT 2026

Abstract N°: 102

Cutaneous Polyarteritis Nodosa Revealing Hairy Cell Leukemia

Filipe Monteiro*[1], Inês Tribolet de Abreu[1], Gustavo Silva[1], Inês Pereira Amaral[1], Ivânia Soares[1], Pedro de Vasconcelos[1], Paulo Filipe[1], Sonia Fernandes[1], Joana Antunes[1]

[1] Unidade Local de Saúde Santa Maria, Lisboa, Portugal

Introduction

Panniculitides comprise a diverse group of inflammatory disorders primarily affecting the subcutaneous tissue, with a broad spectrum of underlying etiologies, including infections, autoimmune conditions, medications, and, less commonly, hematologic malignancies. These disorders may present with erythematous nodules, plaques, or ulcerations, often posing a diagnostic challenge due to overlapping clinical and histopathologic features. Hairy cell leukemia (HCL) is an uncommon B-cell lymphoproliferative neoplasm, classically characterized by splenomegaly, cytopenias, and bone marrow infiltration. Cutaneous involvement in HCL is exceptionally rare and typically manifests later in the disease course, often as nonspecific lesions, making early recognition challenging. Reports of panniculitis, particularly polyarteritis nodosa-like presentations, as the initial sign of HCL are exceedingly uncommon, highlighting the need for awareness of atypical dermatologic presentations as potential harbingers of underlying hematologic malignancy.

Case Presentation

We report a 45-year-old previously healthy man who presented with a four-day history of painful erythematous nodules on the lower limbs, accompanied by fever (38.2 °C), fatigue, myalgias, and an unintentional weight loss of 5 kg over the preceding four months. Physical examination revealed hepatosplenomegaly.Laboratory evaluation showed macrocytosis, thrombocytopenia (50 × 10^9/L), neutropenia (0.99 × 10^9/L), and elevated C-reactive protein (8.11 mg/dL). Peripheral blood smear revealed dysmorphic lymphoid cells with loose chromatin and cytoplasmic projections suggestive of hairy cells. Computed tomography demonstrated homogeneous splenomegaly (20 cm) and small mesenteric lymphadenopathy.Skin biopsy revealed an acanthotic epidermis with orthokeratotic hyperkeratosis. In the deep dermis, a medium-caliber arteriole exhibited luminal occlusion with fibrin deposition, surrounded by dense neutrophilic infiltrate with leukocytoclasia and prominent erythrocyte extravasation. Adjacent mixed neutrophil-rich panniculitis was also observed. No atypical hematolymphoid cells were detected. Gram, PAS, and Ziehl–Neelsen stains were negative for microorganisms, supporting a diagnosis of cutaneous polyarteritis nodosa. Septic vasculitis was excluded based on negative microbiologic studies and absence of organisms on histochemical stains.Bone marrow biopsy revealed extensive infiltration by monoclonal B lymphocytes (CD19$^+$, CD20$^+$, CD103$^+$, CD200$^+$) harboring the BRAF V600E mutation, confirming hairy cell leukemia. Treatment with cladribine and prednisolone led to progressive resolution of both cutaneous lesions and hematologic abnormalities.

Conclusion

Although polyarteritis nodosa has been reported in association with hairy cell leukemia, it remains an uncommon manifestation, typically appearing after the hematologic diagnosis, often following splenectomy or infection. In our patient, however, vasculitic panniculitis was the inaugural presentation, preceding any established diagnosis of leukemia. The presence of systemic “red flags,” including persistent fever, significant unintentional weight loss, and splenomegaly, in combination with painful cutaneous nodules, provided critical clues suggesting an underlying systemic disorder. Histopathologic confirmation via skin biopsy, coupled with comprehensive hematologic evaluation, allowed timely identification of hairy cell leukemia. This case underscores the importance

of recognizing unusual dermatologic presentations as potential harbingers of occult hematologic malignancies, emphasizing the role of the skin as a window into systemic disease and the need for a multidisciplinary approach to patients with unexplained panniculitis or vasculitis.

EA DV CONGRESS
VIENNA
30 SEP - 3 OCT 2026

Abstract N°: 130

Acquired acrodermatitis enteropathica: complications from bariatric medical tourism

Eimear Duff*[1, 2], Aoife Courtney[3], Tudor Munteanu[2], Cliona Feighery[2]

[1] Saint James's Hospital, Dublin, Ireland
[2] Our Lady of Lourdes Hospital, Drogheda, Ireland
[3] St Columcilles Hospital, Dublin, Ireland

Introduction

The global prevalence of obesity, together with healthcare resource constraints and increasing globalisation, has led to more patients seeking obesity treatment outside their home countries. Bariatric and metabolic surgery medical tourism (BMT), a term used to describe people travelling abroad to access bariatric and metabolic surgery, has grown in recent years. However, this industry remains largely unregulated, posing risks for patients and healthcare systems in both home and destination countries. Reliable data on the scale of BMT are limited, however the broader medical tourism market is estimated to exceed $400 billion annually and is projected to grow by approximately 25% each year, and most patients (71%) self-refer for bariatric surgery.

Case Presentation

A 37-year-old woman was admitted with a six-week history of a painful, pruritic, scaly cutaneous eruption. A dermatology consult was requested with a clinical query of severe psoriasis. The eruption consisted of scaly, erythematous discrete and confluent macules and plaques affecting the acral and sub-mammary regions, in addition to the vulva and buttocks. The scalp and face were spared, and nails were normal.

Her medical history was significant for emotionally unstable personality disorder. She underwent an elective sleeve gastrectomy abroad ten months prior to referral, with no structured postoperative follow-up and experienced 57.3% total weight loss. She was not taking recommended postoperative vitamin supplementation and reported difficulty maintaining adequate nutritional intake due to restrictive gastrointestinal symptoms.

Seven months postoperatively, she presented with progressive unsteady gait, lower limb weakness and paraesthesia to T10 sensory level. Nerve conduction studies demonstrated a symmetric sensory-predominant axonal sensorimotor peripheral neuropathy. Serum copper was reduced at 8 µmol/L (reference range [RR] 11.0-25.0). Her symptoms improved markedly following intravenous copper replacement.

On review by dermatology, her cutaneous eruption was clinically consistent with acrodermatitis enteropathica. A skin biopsy was consistent, and serum zinc was reduced at 8.0 µmol (RR 10.7-24.5).

The patient was managed with topical corticosteroids and referred to obesity management services for management of symptomatic zinc and copper deficiencies. Supplementation was optimised with oral zinc (30mg daily) and copper (2mg daily), targeting a zinc-to-copper ratio of 8-15:1. Repeat testing at three months demonstrated normalisation of serum zinc (18.2µmol/L) and copper (13.6µmol/L), with significant improvement in cutaneous and neurological symptoms.

Conclusion

Transnational collaboration is necessary to regulate the BMT industry and protect patient safety. Dermatologists need to be aware of related complications, which may have atypical presentations, and their management. This

case underscores the risk of severe micronutrient deficiencies as a complication from bariatric medical tourism without structured follow up, and the value of multidisciplinary care in these patients.

EA DV CONGRESS
VIENNA
30 SEP - 3 OCT 2026

Abstract N°: 208

Linear and Round Naevoid Acanthosis Nigricans: A case series of 12 patients

Divya Divya*[1], Saurabh Singh[1], Anupama Bains[1], Deepak Vedant[1]

[1] AiiMs Institute, Jodhpur, India

Introduction

Naevoid acanthosis nigricans is a less common variant of acanthosis nigricans characterized by a benign course and absence of usual systemic associations. It typically presents at an early age with an asymmetric distribution and is considered to have an autosomal dominant inheritance.

Case Presentation

We evaluated 12 patients diagnosed clinically with light to dark brown hyperpigmented plaques having a thickened velvety surface. All patients were assessed for body mass index, fasting blood glucose, and lipid profile to identify metabolic associations. There was a slight female predominance (7 females, 5 males), with a mean age of onset of 17.7 years and a mean disease duration of 2.03 years. Two morphological patterns were observed: linear lesions along the lines of Blaschko in 5 patients and discrete round to oval lesions in 7 patients. Linear lesions resembled linear epidermal nevus in distribution, while round lesions presented as localized plaques. The abdomen was the most common site for linear lesions, while the extremities were commonly involved in round lesions. Umbilical involvement was noted in 3 patients. All cases presented before the second decade, and none had onset after 20 years. Only one patient had associated type 1 diabetes mellitus and celiac disease, while the remaining had no systemic associations. Histopathology revealed hyperkeratosis, papillomatosis, acanthosis, and elongated rete ridges in all cases, with increased basal pigmentation in two patients. Dermoscopy showed a cerebriform pattern with sulci and cristae cutis along with brown pigment dots, correlating histologically with papillomatosis, rete ridge patterns, and melanin at the dermo-epidermal junction. As most patients were asymptomatic and lacked systemic abnormalities, they were counselled regarding the benign nature of the disease and kept under follow-up. Three patients treated with topical tretinoin showed mild improvement after two months.

Conclusion

Acanthosis nigricans typically presents as symmetric velvety plaques over intertriginous areas and is often associated with insulin resistance or, rarely, internal malignancy. However, naevoid acanthosis nigricans differs by its early onset, benign nature, and lack of systemic associations. It has also been described as RAVEN or unilateral naevoid acanthosis nigricans. It may present as solitary or linear lesions with morphological similarity to classical acanthosis nigricans. In our cohort, lesions were either solitary or linear, with some involving the umbilicus. Unlike classical forms, naevoid variants lack associations with endocrinopathies or malignancy. All patients in our series had early onset and non-progressive disease. Although considered autosomal dominant, no family history was noted. The condition may stabilize or regress over time. Differential diagnoses include linear epidermal nevus, seborrheic keratosis, and confluent and reticulated papillomatosis. Differentiation from epidermal nevus may be difficult, though histopathology may show more compact orthokeratosis and pronounced acanthosis in epidermal nevus. Early onset, linear distribution, and absence of horn cysts favor naevoid acanthosis nigricans over seborrheic keratosis. This condition is benign and does not require extensive systemic evaluation. Various treatments, including topical retinoids and other modalities, have shown variable responses. Overall, naevoid acanthosis nigricans represents a benign entity with distinct clinical patterns and minimal systemic relevance.

EADV CONGRESS
VIENNA
30 SEP - 3 OCT 2026

Abstract N°: 210

Eruptive Collagenoma in a 32-Year-Old Woman with Type 2 Diabetes Mellitus and Polycystic Ovary Syndrome: A Rare Dermatologic Presentation.

Jutamas Tankunakorn*[1], Ratchanee Vipanurat[1]

[1] Division of Dermatology, Department of Medicine, Rajavithi hospital, College of Medicine, Rangsit University, Bangkok, Thailand

Introduction

Eruptive collagenoma is a rare benign connective tissue nevus characterized by the sudden appearance of multiple collagen-rich papules. Its association with endocrine and metabolic disorders remains poorly defined. Familial and isolated variants exist, but associations with endocrine disorders like diabetes mellitus and polycystic ovary syndrome (PCOS) remain sparsely reported, warranting further exploration of potential metabolic links.

Case Presentation

We report the case of a 32-year-old woman with a 4-year history of poorly controlled type 2 diabetes mellitus (HbA1c 8.7%) and polycystic ovary syndrome (PCOS), who presented with a 3-year history of progressively increasing, asymptomatic cutaneous lesions. Dermatologic examination revealed more than 50 firm, dome-shaped, skin-colored papules measuring 2–5 mm, distributed over the trunk and proximal extremities. There was no family history of similar lesions, and the patient denied preceding trauma or dermatologic interventions. Laboratory findings confirmed hyperandrogenism and features of metabolic dysregulation. Histopathological analysis demonstrated dense, hypocellular collagen bundles in the reticular dermis with preserved elastic fibers, consistent with eruptive collagenoma. This case underscores eruptive collagenoma as a possible cutaneous indicator of metabolic disturbances in polycystic ovary syndrome (PCOS) and diabetes, potentially associated with fibrosis stemming from chronic hyperglycemia or hormonal effects on the dermal extracellular matrix. Differential diagnoses considered encompassed eruptive xanthomas (excluded via lipid panel analysis), lipoid proteinosis, and familial cutaneous collagenoma; however, histopathological examination provided definitive diagnostic confirmation.

Conclusion

Although uncommon, this presentation raises the possibility of a link between metabolic or hormonal abnormalities and altered dermal collagen deposition. This case highlighted the potential role of eruptive collagenoma as a cutaneous marker of underlying metabolic dysfunction.

Keywords: Eruptive collagenoma, diabetes mellitus, polycystic ovary syndrome, connective tissue nevus.

EADV CONGRESS
VIENNA
30 SEP - 3 OCT 2026

Abstract N°: 413

Generalized pustular eruption secondary to severe hypocalcemia: a metabolic cause not to miss

Assia El Bouhmadi*[1], Fatimazahra Benhayoun[1], Bouchra Baghad[1], Hanane Rachadi[1], Soumiya Chiheb[1]

[1] CHU Ibn Rochd, CASABLANCA, Morocco

Introduction

Hypocalcemia-related pustulosis is a rare dermatologic condition characterized by the development of sterile pustules on an erythematous background, often associated with metabolic disorders, particularly hypocalcemia. Correction of this electrolyte imbalance typically leads to resolution of the cutaneous lesions. This clinical case highlights the importance of recognizing hypocalcemia as a potential cause of pustular dermatosis.

Case Presentation

We report the case of a 34-year-old woman with a history of total thyroidectomy performed 10 years ago, complicated by permanent postoperative hypoparathyroidism and chronic hypocalcemia requiring lifelong supplementation. She presented with an acute-onset, generalized pustular eruption. Clinical examination revealed diffuse pustules on an erythematous base involving the trunk and limbs. Concurrently, the patient reported symptoms such as muscle cramps, fatigue, and paresthesia. Laboratory investigations confirmed severe hypocalcemia, with a serum calcium level of 1.45 mmol/L.The diagnosis of hypocalcemia-related pustulosis was established after excluding other inflammatory or drug-induced causes. Treatment consisted of calcium and vitamin D supplementation. Following correction of serum calcium levels, the patient exhibited a rapid and significant improvement in her cutaneous symptoms, with pustules resolving within a few days. No recurrence was observed after long-term stabilization of calcium levels.



Clinical aspect at admission showing generalized pustular eruption with diffuse pustules on the erythematous base primarily affecting the trunk and extremities

Conclusion

This case underscores the importance of investigating electrolyte imbalances, particularly hypocalcemia, in patients presenting with unexplained pustular eruptions. The prompt resolution of lesions following calcium correction confirms the direct association between hypocalcemia and pustulosis. Early and appropriate management of hypocalcemia ensures complete clinical recovery.

EADV CONGRESS
VIENNA
30 SEP - 3 OCT 2026

Abstract N°: 415

Cutaneous extramedullary hematopoiesis: a rare diagnostic challenge in advanced myelofibrosis

Assia El Bouhmadi*[1], Bouchra Baghad[1], Fatimazahra Benhayoun[1], Hanane Rachadi[1], Soumiya Chiheb[1]

[1] CHU Ibn Rochd, CASABLANCA, Morocco

Introduction

Extramedullary hematopoiesis (EMH) refers to the production of hematopoietic cell lineages outside the bone marrow as a compensatory response to medullary failure. It most commonly involves the liver and spleen. Cutaneous EMH (CEMH) is exceptionally rare and is mainly described in chronic myeloproliferative neoplasms, particularly primary myelofibrosis (PMF), where it appears to be associated with poor prognosis. We report a case of CEMH occurring in a patient with JAK2-positive PMF and rapidly fatal outcome.

Case Presentation

A 54-year-old woman with JAK2-positive PMF, regularly transfused for two years because of severe anemia (hemoglobin 6.5 g/dL) and thrombocytopenia (38 × 10^9/L), presented with cutaneous lesions evolving over one month. Clinical examination revealed multiple firm, infiltrated, erythematous-violaceous nodules and papulonodules on the trunk, without ulceration, pruritus, or mucosal involvement. Massive splenomegaly was known. Her general condition was severely impaired, with marked weight loss, profound asthenia, and transfusion dependency.Histological examination of a 6 × 4 mm skin biopsy showed a dense dermal infiltrate composed of polymorphous hematopoietic cells at various stages of maturation. Immunohistochemistry demonstrated diffuse myeloperoxidase expression, supporting the diagnosis of cutaneous extramedullary hematopoiesis. Concomitant bone marrow biopsy confirmed advanced-stage myelofibrosis without acute leukemic transformation. Despite supportive care, anemia remained severe and the patient died two weeks after presentation.



General clinical view of the patient's trunk demonstrating the widespread distribution of multiple papulonodular lesions predominantly involving the anterior trunk, with relative sparing of the face and extremities. Marked cachexia and severe weight loss are evident, reflecting advanced systemic disease.

Conclusion

CEMH is an exceptionally uncommon manifestation, first described in 1937, and may clinically mimic cutaneous metastases. It typically presents as firm erythematous to violaceous papulonodules on the trunk. Histologically, lesions usually contain precursors from myeloid, erythroid, and megakaryocytic lineages, although incomplete

lineage representation is frequently reported. Immunohistochemistry is essential to differentiate EMH from leukemic or metastatic infiltrates. From a prognostic perspective, cutaneous involvement generally reflects advanced marrow exhaustion and is associated with markedly reduced survival. In our case, transfusion-dependent cytopenia and CEMH likely indicated terminal hematopoietic failure, as illustrated by the rapidly fatal course.

EADV CONGRESS
VIENNA
30 SEP - 3 OCT 2026

Abstract N°: 476

Cutaneous metastasis as the initial presentation of pancreatic adenocarcinoma

Jorge Varandas Lindo*[1], João Fernandes[1], Teresa Lemos[1], José Cardoso[1], Maria Xavier[1]

[1] Dermatology Department, Unidade Local de Saúde de Coimbra, Coimbra, Portugal

Introduction
Cutaneous metastases may represent the first manifestation of an internal malignancy and display diverse clinical morphologies. Metastatic spread from pancreatic adenocarcinoma to the skin is rare.

Case Presentation
A 71-year-old male was evaluated for a progressively enlarging violaceous, indurated plaque on the left buttock, first noted six months earlier and associated with unintentional weight loss. On physical examination, a solitary, indurated, infiltrative violaceous cutaneous plaque measuring 5 × 6 cm was observed on the left buttock. Dermoscopic evaluation revealed an erythematous background with a reticular network of white lines, scattered yellowish areas, shiny crystalline structures, and focal surface scaling. No peripheral lymphadenopathy was palpable.Histopathological examination of an incisional biopsy demonstrated metastatic adenocarcinoma with an immunohistochemical profile consistent with pancreatobiliary origin (CK7 positive, CK20 negative). Laboratory tests showed markedly elevated tumor markers (CA 19-9 and CA 125). Subsequent imaging studies identified a pancreatic tail mass with hepatic, pulmonary, and bone metastases, establishing the diagnosis of metastatic pancreatic adenocarcinoma.The patient initiated palliative chemotherapy with gemcitabine and nab-paclitaxel but experienced rapid disease progression and died shortly thereafter, reflecting the poor prognosis associated with cutaneous dissemination of pancreatic cancer.

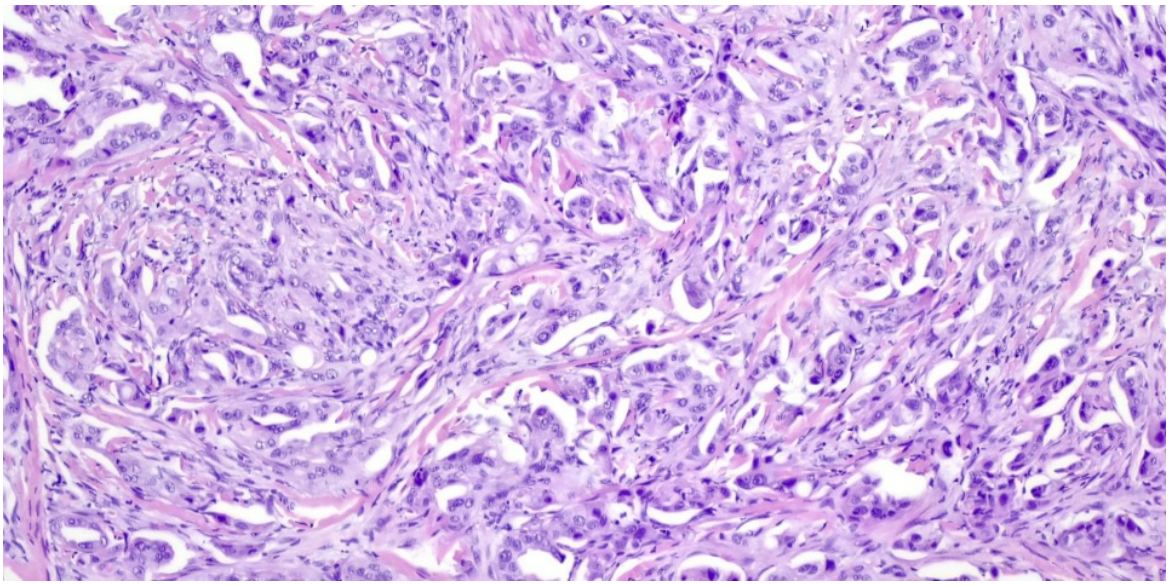

Histopathological examination showing diffuse infiltration of the dermis by a malignant epithelial neoplasm with infiltrative growth pattern, ductal and glandular differentiation, atypical epithelioid cells with abundant amphophilic cytoplasm, and vesicular pleomorphic nuclei, as well as a markedly sclerotic stroma, with no significant necrosis. (H&E stain).

Conclusion

Cutaneous metastases from pancreatic cancer are uncommon and usually indicate advanced disease. While some studies suggest a tendency for umbilical involvement, others describe a preference for non-umbilical sites, such as the head, neck, and thoracic regions. The typical presentation of these lesions is a nodule or a mass-like lesion, often associated with primary tumors located in the pancreatic head or uncinate process. Thus, a non-nodular gluteal cutaneous metastasis from an adenocarcinoma of the pancreatic tail, as seen in this case, presents a significant diagnostic challenge. A broad differential diagnosis was initially considered, including cutaneous lymphoma, adnexal tumors, subcutaneous infectious processes or metastatic disease. The immunohistochemical profile helped exclude other primary sites and pinpoint a pancreatobiliary origin. The markedly elevated CA 19.9 and CA 125 levels further supported the diagnosis and reflected advanced disease burden, consistent with previous reports. Published data indicate that median survival after diagnosis of cutaneous metastasis from pancreatic adenocarcinoma is typically less than six months, as observed in this case.This case emphasizes that atypical, rapidly progressive cutaneous lesions - particularly in elderly patients with systemic symptoms - should prompt consideration of an underlying visceral malignancy. Early skin biopsy, appropriate immunohistochemical evaluation, comprehensive staging, and multidisciplinary collaboration are essential for establishing the diagnosis, guiding management, and initiating timely palliative care in patients with advanced pancreatic adenocarcinoma.

EADV CONGRESS
VIENNA
30 SEP - 3 OCT 2026

Abstract N°: 487

Clinical and Dermoscopic Evaluation to study the effectiveness of Metformin versus Pioglitazone in Acanthosis nigricans - A randomized controlled trial.

Jinisha Jain*[1]

[1] Jawaharlal Nehru Medical College, Belgaum, Dr. DY patil Medical College, Pune, Eye and Skin Advance Hospital, Belgaum, India

Introduction
Acanthosis Nigricans (AN) features thickened, hyperpigmented skin in flexural areas, often indicating insulin resistance. Its prevalence in India is rising, reaching 6.5%. Dermoscopy aids diagnosis by revealing sulci cutis and crista cutis. This study evaluates clinical and dermoscopic changes in AN patients treated with metformin and pioglitazone, as comparative efficacy studies are lacking.

Materials and Methods
A randomized open-label trial was conductedto include consenting AN patients aged over 18 years. Patients were randomized to receive either metformin 500mg BD or pioglitazone 7.5mg BD for 3 months. Clinical grading, anthropometric measurements, and dermoscopic features were compared at baseline and follow-up after 12 weeks using IBM SPSS v26.

Results
Sixty-six patients, evenly distributed between the two groups with a mean age of 35 years and a female predominance, participated. Both drugs significantly improved clinical grading from baseline to 12 weeks. Metformin notably reduced BMI and weight compared to pioglitazone. However, no significant difference was observed between the drugs for other parameters. Both drugs significantly altered dermoscopic parameters—sulci cutis and hyperpigmented dots and globules—from baseline, with no differences noted between metformin and pioglitazone. Morphology of papillary projections and sulci cutis correlated significantly with clinical grading.

Conclusions
Metformin and pioglitazone both significantly improved AN clinically and dermoscopically, with no significant differences between them. Metformin is more effective in reducing weight and BMI, suitable for overweight patients. Pioglitazone is an alternative for those intolerant or unresponsive to metformin but can lead to weight gain. Dermoscopic parameters can indicate early treatment response before visible clinical improvement. Further research with larger samples is warranted to validate these findings.

EA DV CONGRESS
VIENNA
30 SEP - 3 OCT 2026

Abstract N°: 503

Menopause as a trigger for common skin conditions. Results from the IMPACT study on the effects of the menopause transition on skin health.

Claudia DeGiovanni*[1, 2], Christina Koulouglioti[1], Maha Mustafa[3], Kirsty Perry[3], Louise Newson[4], Carrie Llewellyn[5]

[1] University Hospitals Sussex NHS Foundation Trust, Brighton, United Kingdom

[2] Brighton and Sussex Medical School, University of Brighton and University of Sussex,, Brighton, United Kingdom

[3] Patient and public member of co-production team. Woman with lived experience., BRIGHTON, United Kingdom

[4] Newson Global, Stratford upon Avon, United Kingdom

[5] Department of Primary Care & Public Health, Brighton and Sussex Medical School, University of Brighton and University of Sussex, Brighton, United Kingdom

Introduction

Menopause is characterised by a hormonal shift in oestrogen, progesterone and testosterone levels affecting women in midlife. During menopause, the oestrogen deficient state causes reduction in collagen levels and thinning of the skin. There is paucity of evidence related to the experience of skin problems by women during menopause and their impact on quality of life.

Materials and Methods

To explore the impact of the menopause on the skin we conducted a national survey of 1457 women experiencing perimenopause or post-menopause, investigating their skin symptoms, their experiences with accessing care and how dermatology conditions have changed through the menopause. Survey findings were further supported by semi-structured interviews of 17 women experiencing skin issues through the menopause.

Results

The majority of women noted general skin symptoms such as dry skin 70%, itch 64%, decreased elasticity 55% and acne /spots 45%. Hair symptoms including hair thinning, scalp symptoms and excess hair affected 84% of women. Vulval symptoms such as pain, itch, burning and change in appearance affected 74% of women and oral symptoms such as dryness, gum disease, tooth loss and pain affected 58% of them. We asked women about medically diagnosed skin conditions, whether these were diagnosed in perimenopause or post-menopause and if diagnosed pre-menopause, how these skin conditions transitioned through the menopause journey. Many common skin conditions including atopic eczema, psoriasis, contact dermatitis, acne, rosacea, melasma vitiligo and urticaria were diagnosed in perimenopause or post-menopause and deteriorated through the menopause when diagnosed pre-menopause (Table 1). Current medical practice rarely considers the impact of menopause on such conditions. Other skin conditions such as androgenic alopecia, frontal fibrosing alopecia, lichen sclerosus, lichen planus and genitourinary syndrome of menopause were predominantly diagnosed in perimenopause or post-menopause. Three-quarters (76%) of our cohort were taking hormone replacement therapy (HRT) and over half (56%) felt their skin improved or resolved on HRT. Most of the women (72%) would value more information and support for managing skin issues through the menopause. Qualitative themes on managing skin symptoms through the menopause will also be discussed including impact on life, difficulty accessing care, lack of information and self-management behaviours.

Diagnosis	Total number of patients	Percentage diagnosed in perimenopause or post menopause	Percentage that deteriorated through peri menopause or post-menopause
Atopic Eczema	254	33%	35%
Contact Dermatitis	184	44%	38%
Acne	170	46%	33%
Rosacea	240	67%	37%
Psoriasis	133	43%	36%
Hidradenitis Suppurativa	45	49%	21%
Melasma/chloasma	92	59%	43%
Urticaria	114	60%	32%
Vitiligo	32	38%	33%
Other Autoimmune condition	46	59%	53%
Female Pattern Hair Loss	99	86%	50%
Frontal Fibrosing Alopecia	32	88%	**75%**
Alopecia Areata	31	65%	**25%**
Lichen Sclerosis	69	77%	40%
Lichen Planus	24	79%	**20%**
Genitourinary syndrome of menopause	208	94%	58%

Table 1 – The impact of menopause on common dermatology conditions

Conclusions

In summary, common skin conditions are negatively impacted through the menopause journey and menopause should be considered as a trigger for flares and midlife diagnoses of such conditions. Skin symptoms in general affect most women through the menopause and taking opportunities to raise the link between menopause and skin will enable women to seek support and treatment early. The impact of HRT on common skin conditions and symptoms needs to be fully evaluated, as our data suggests that it could be a helpful management strategy for many patients.

EADV CONGRESS
VIENNA
30 SEP - 3 OCT 2026

Abstract N°: 508

Same Look, Different Story: Differential Diagnosis in Mimicking Disorders

Anil Bhokare*[1]

[1] Apex Skin & Laser Clinic, Malegaon, Maharashtra, India, MALEGAON, India

Introduction

In clinical practice, disparate pathologies often converge into identical physical presentations, leading to potential diagnostic pitfalls. Relying on "spot diagnosis" can result in mismanagement when rare or atypical conditions mimic common diseases.

Case Presentation

Objectives: This presentation aims to illustrate the "Same Look, Different Story" phenomenon through a curated series of clinical cases, emphasizing the necessity of a structured approach to differential diagnosis.
Case Series/Methods: We present a collection of diagnostic dilemmas, including:·
Nodular lesions of the hand: Contrasting inflammatory vs. infectious etiologies.·
Cord-like neck swellings: Distinguishing vascular thrombosis from neuritic hansen’s, a clinical mimic.·
Papulocrusted facial lesions: Differentiating between common viral infections and acne from rarer autoimmune triggers.
Results/Discussion: Each case highlights specific "red flags" and subtle clinical clues—such as history of progression, palpation characteristics, and bedside diagnostics—that led to the correct diagnosis. The series demonstrates how similar morphology often hides vastly different systemic implications.

Conclusion

Conclusion: Masterful diagnosis requires looking beyond initial appearances. By recognizing these mimicking disorders, clinicians can refine their diagnostic algorithms, reduce medical errors, and significantly improve patient outcomes

EADV CONGRESS
VIENNA
30 SEP - 3 OCT 2026

Abstract N°: 571

To Biopsy or Not ? Development of Saraburi IVLBCL Screening Score (SISS): A Practical Tool Based on a 10-year experience in Resource-limited Settings.

Natnicha Girdwichai*[1]

[1] Dermatology unit, Department of Internal Medicine, Saraburi Hospital, Saraburi, Thailand

Introduction
Intravascular large B-cell lymphoma (IVLBCL) is a rare, aggressive extranodal lymphoma frequently presenting as fever of unknown origin without skin lesions, resulting in significant diagnostic delays. Random skin biopsy (RSB) is an accessible diagnostic strategy; however, its utility is limited by procedural risks, false-negative results, and the absence of validated patient selection criteria. Existing scoring systems require sIL-2R, a biomarker unavailable in many resource-limited settings

Materials and Methods
A retrospective case-control study was conducted at Saraburi Hospital, Thailand (January 1, 2016- December 31, 2025). Six histologically confirmed IVLBCL cases were compared with 20 non-IVLBCL controls who underwent RSB for clinically suspected disease. The SISS was developed using variables with statistical significance and clinical relevance. Screening performance was assessed by sensitivity, specificity, PPV, NPV, and ROC analysis.

Results
Twenty-six patients were included (IVLBCL: n=6, 23.1% diagnostic yield). Thrombocytopenia (platelet <100,000/μL) and elevated LDH (≥institutional UNL, 247 U/L) were the strongest discriminators (p=0.030 and p=0.002, respectively). The SISS comprises six parameters: unexplained fever (+1), unintentional weight loss (+1), hepatomegaly/splenomegaly (+1), anemia/Hb<10 g/dL (+1), thrombocytopenia (+2), and elevated LDH (+1); maximum score 7. At cut-off ≥4, the SISS achieved: sensitivity 100% (95% CI 54.1–100.0), specificity 55% (95% CI 31.5–76.9), PPV 40.0% (95% CI 16.3–67.7), NPV 100% (95% CI 71.5–100.0), AUC 0.875 (95% CI 0.70–0.99).

Conclusions
The SISS is a simple, practical screening tool for suspected IVLBCL without cutaneous manifestations. At a cut-off of ≥4, it achieves 100% sensitivity and 100% NPV, reliably identifying candidates for RSB while safely deferring the procedure in low-risk patients. Comprising only six routinely available parameters and requiring no sIL-2R measurement, the SISS offers an accessible approach to RSB decision-making across diverse clinical settings.

EADV CONGRESS
VIENNA
30 SEP - 3 OCT 2026

Abstract N°: 628

Cocaine-induced vascular purpura

Meriem Mhiri*[1], Maha Lahouel[1], Jacem Rouatbi[1], Nadia Ghariani[1], Amina Aounallah[1], Ghariani Nejet[1]

[1] Dermatology Department, Farhat Hached University Hospital, Sousse, Tunisia, sousse, Tunisia

Introduction
Vascular purpura represents a heterogeneous group of cutaneous manifestations with diverse etiologies, among which toxic causes remain underrecognized. Cocaine, frequently adulterated with levamisole, is an established trigger of vasculitis and may lead to potentially severe systemic complications.

Case Presentation
A 50-year-old man with no significant past medical history, a 35 pack-year smoking history, daily alcohol consumption (four beers/day), and weekly intranasal cocaine use, presented with extensive, infiltrated, dependent purpuric plaques involving both lower limbs, the subumbilical region, and inner forearms. There was no necrosis, mucosal involvement, or systemic symptoms. Platelet count was within normal limits (209,000/mm^3). Detailed history revealed cocaine use two hours prior to the onset of lesions, with no recent medication intake. Liver and renal function tests were normal. Immunological investigations and viral serologies were negative. Skin biopsy demonstrated nonspecific leukocytoclastic vasculitis. The patient was hospitalized for strict bed rest and close monitoring. The clinical course was rapidly favorable, with near-complete resolution of lesions within 48 hours. A toxic etiology was considered most likely. No recurrence was observed during follow-up after cessation of all psychoactive substances.

Conclusion
Cocaine-associated vascular purpura is an uncommon but increasingly reported condition, often related to levamisole adulteration. Levamisole, an antihelminthic agent withdrawn from human use due to toxicity, exerts immunomodulatory effects that may induce leukocytoclastic vasculitis through neutrophil activation and autoantibody production, particularly p-ANCA with anti-MPO specificity. Clinically, lesions typically involve dependent or acral areas, may become necrotic, and can be associated with systemic complications, including renal and hematological involvement. The differential diagnosis includes infectious, medication-induced, and autoimmune vasculitis, which were excluded in this case through comprehensive evaluation. The temporal relationship with cocaine exposure, absence of systemic involvement, compatible histopathological findings, and complete resolution following drug cessation strongly support a toxic etiology. This case is notable for the absence of necrosis or systemic features and for its rapidly favorable outcome. It underscores the importance of systematically investigating substance use in cases of acute cutaneous vasculitis, particularly in patients without prior vascular or autoimmune disease. Early recognition of this entity is essential to prevent unnecessary investigations and avoid inappropriate therapeutic interventions.

EA DV CONGRESS
VIENNA
30 SEP - 3 OCT 2026

Abstract N°: 633

Type 3c Diabetes Mellitus Presenting as Acquired Reactive Perforating Collagenosis

Mun Leng Lee*[1], Andrew Affleck[1]

[1] NHS Tayside, Dundee, United Kingdom

Introduction

Acquired reactive perforating collagenosis is a perforating dermatosis characterised by transepidermal elimination of altered dermal collagen. It exists in two forms: an inherited childhood form and an acquired adult form, the latter most commonly associated with diabetes mellitus and chronic renal disease.



Case Presentation

A 42-year-old woman presented to the psychodermatology clinic with a 3-month history of pruritic, punched-out lesions predominantly affecting the chest, shoulders, and upper back, with the scalp, nails, and genitalia unaffected. The eruption developed spontaneously without identifiable triggers, including infection, new medications, vaccinations, or dental procedures.

Her medical background included chronic pancreatitis, alcohol-related liver disease, alcohol excess, fibromyalgia, and a history of self-harm and overdose; previous treatments comprised of topical permethrin, topical corticosteroids, and emollients.

Laboratory investigations demonstrated iron deficiency anaemia, hyponatraemia, and deranged liver function consistent with known cirrhosis, alongside elevated IgA (6.36 g/L), IgM (2.30 g/L), and hyperglycaemia (glucose

33.6 mmol/L).

Punch biopsy revealed a full-thickness epidermal ulcer with fibrinous exudate, adjacent epidermal hyperplasia, underlying chronic inflammation, and focal fat necrosis. PAS stain showed no fungal organisms, while Elastin van Gieson's stain highlighted vertically oriented collagen within the ulcer base.

Clinically, hyperkeratotic papules typically arise on the extensor surfaces of the limbs and hands. Management focuses on addressing underlying systemic disease, which often triggers or exacerbates the condition. Additional therapeutic options include topical retinoids, keratolytics, topical or systemic corticosteroids, tetracyclines, rifampicin, narrowband UVB phototherapy, PUVA phototherapy, oral acitretin, and allopurinol.



Conclusion

The patient was referred to endocrinology and diagnosed with type 3c diabetes secondary to longstanding chronic pancreatitis. Optimisation of glycaemic control, combined withdermatological management including topical clobetasol propionate, oral chlorphenamine,and narrowband UVB phototherapy, led to some clinical improvement. She continues to develop occasional new lesions on the arms while glycaemic control is being optimisedand is currently receiving ongoing UVA1 phototherapy.

This case highlights the importance of thorough evaluation, including random blood glucose testing, in patients with atypical pruritic dermatoses. While perforating collagenosis is usually reported in individuals with established diabetes, it can also present as an initial cutaneous manifestation, revealing previously undiagnosed diabetes.

EA DV CONGRESS
VIENNA
30 SEP - 3 OCT 2026

Abstract N°: 637

Clinical Characteristics and Mortality Outcomes in Cancer-Associated Dermatomyositis: A Systematic Review and Meta-Analysis

Shireen Dumont*[1], Megan Park[2], Samiha T. Mohsen[3], Jenna Mistry[2], Esther Provost[2], Haleh Zabihi[4], Eric McMullen[4], Edgar Akuffo-Addo[4], Aaron M. Drucker[5], Vincent Piguet[6]

[1] Division of Dermatology and Venereology, Geneva University Hospitals, Geneva, Switzerland
[2] Temerty Faculty of Medicine, University of Toronto, Toronto, Canada
[3] Division of Dermatology, Cumming School of Medicine, University of Calgary, Calgary, Canada
[4] Division of Dermatology, Department of Medicine, University of Toronto, Toronto, Canada
[5] Division of Dermatology and Research and Innovation Institute, Women's College Hospital, Toronto, Canada
[6] Division of Dermatology, Department of Medicine, Women's College Hospital, Toronto, Canada

Introduction
Cancer is a well-recognized complication of dermatomyositis and a major contributor to increased morbidity and mortality. However, evidence regarding clinical characteristics, survival and mortality in cancer-associated dermatomyositis remains limited. Our objective is to comprehensively synthesize the available evidence on clinical characteristics and mortality outcomes in cancer-associated dermatomyositis.

Materials and Methods
MEDLINE, Embase, and PubMed were searched from inception to August 5, 2025 (PROSPERO CRD420251269785). Observational studies including at least 10 cases and reporting mortality outcomes among adults with cancer-associated dermatomyositis were eligible. Risk of bias and certainty of evidence were assessed using the Joanna Briggs Institute tools, the Newcastle–Ottawa Scale, and the GRADE. Random-effects meta-analysis was used to estimate pooled survival outcomes. When pooling was not feasible, findings were synthesized narratively following SWiM guidance.

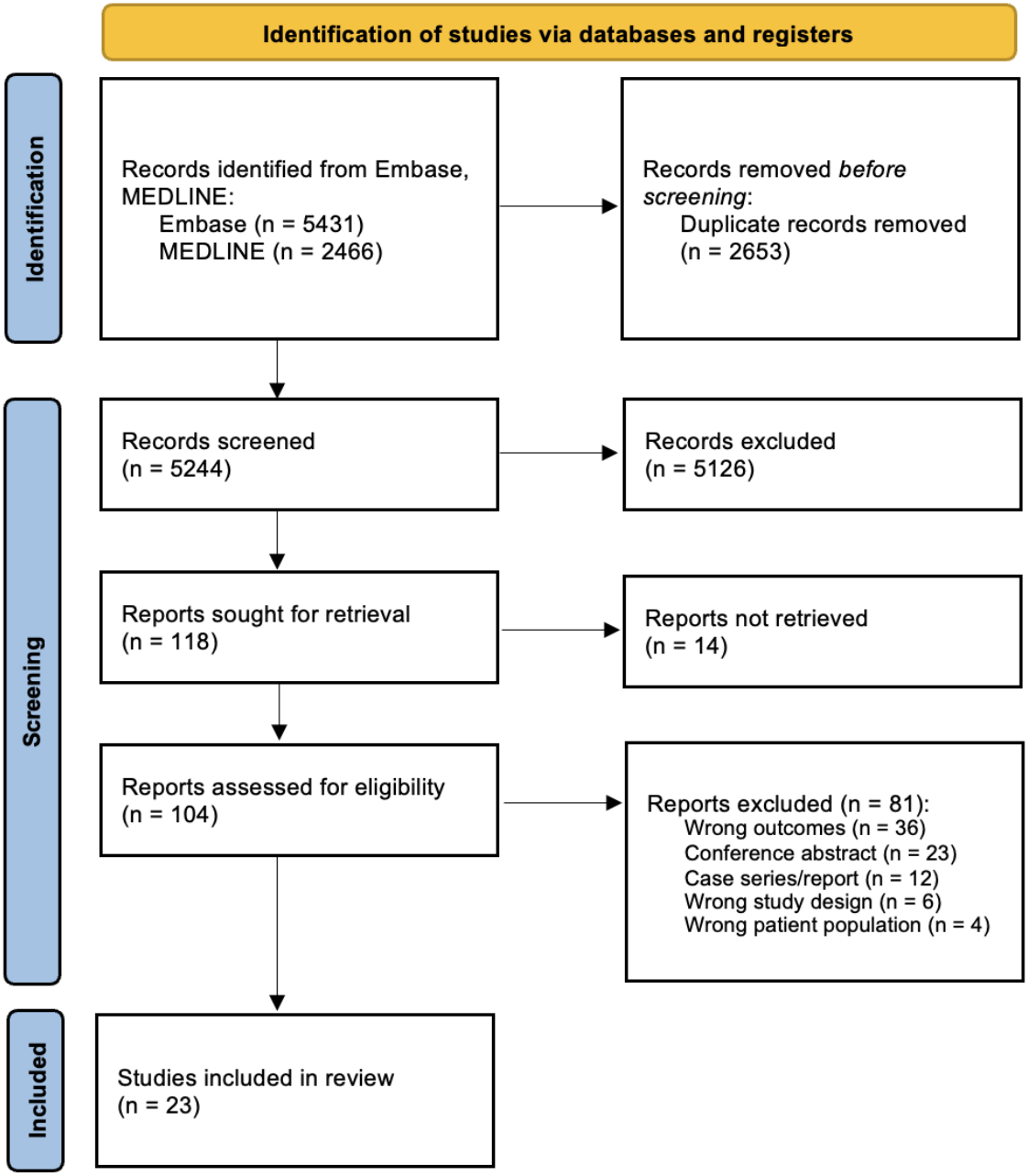

Figure 1: Flow diagram of literature screening according to the Preferred Reporting Items for Systematic reviews and Meta-Analyses (PRISMA) guidelines

Results

Twenty-three studies including 974 patients were analyzed with a mean age of 58 years and a female predominance. Head and neck cancers were the most frequently reported malignancies, reflecting population patterns. Muscle weakness, heliotrope rash, and dysphagia were common. Across 16 studies including 605 patients, malignancy was diagnosed within 2 years of dermatomyositis onset in 82% of cases. Patients with cancer-associated dermatomyositis had higher mortality rates than those without malignancy (in 20 studies, low certainty of evidence) with worse 1- and 5-year survival (low certainty of evidence). Only two studies assessed mean survival time, with a pooled estimate of 4.57 years from dermatomyositis diagnosis (95% CI, 2.08–7.05; I^2 = 0%).

Study, year	Country	Duration of the study / Average duration of follow-up (years)	Sample Size Dermatomyositis patients with malignancy (n)	Age (at diagnosis) median [IQR] or mean ± (SD)	Cancer type	Muscular weakness (n, %)	Dysphagia (n, %)	Mortality rate (%)	Survival rate at 1 year (%, 95% CI)	Survival rate at 5 years (%, 95% CI)
Teboul, 2025	France	1 / 3.9	73	63.2 [55.9–73.1]	Breast cancer (14), Lung cancer (11), GI cancer (5), Ovarian (13), Head and neck (5), Other (25)	67 (91.8)	34 (46.6)	43.8	75.3 (65.8–86.3)	NR
Nossent, 2024	Australia	35 / NR	47	67 [46–71]	Specific cancer types associated with dermatomyositis not detailed	NR	NR	NR	NR	NR
Zhou, 2023	China	7 / NR	24	65.5 [65–69]	Lung cancer (24)	14 (58.3)	10 (41.7)	29.2	NR	NR
Ly, 2021	Japan	3 / NR	15	65.3 ± 3.8	Lung cancer (3), GI cancer (2), Ovarian cancer (2), Other (8)	12 (80)	8 (53.3)	53	NR	NR
Lauinger, 2021	Germany	15 / NR	19	68.8 ± 11.6	Breast cancer (6), Lung cancer (3), GI cancer (2), Ovarian cancer (4), Head and neck (1), Other cancers (3)	14 (73.7)	13 (68.4)	10.5	NR	NR
Lau, 2021	Singapore	10 / 2.8	24	NR	Breast cancer (4), Lung cancer (2), GI cancer (2), Ovarian cancer (1), Head and neck (10), Other cancers (5)	NR	NR	NR	NR	NR
Bowerman, 2020	United States	10 / NR	16	55 [50–64]	Breast cancer (4), Lung cancer (2), Ovarian cancer (2), Other cancers (6)	14 (87.5)	NR	18.8	NR	NR
Galadari, 2020	United States	NR / 1.3	63	NR	Breast cancer (22), Lung cancer (6), GI cancer (20), Ovarian cancer (3), Head and neck (3), Other cancers (9)	NR	NR	25	NR	NR
Andras, 2020	Hungary	30 / NR	30	55.9 ± 13.7	Specific cancer types associated with dermatomyositis not detailed	43	17 (56.7)	83.3	49.4	27.5
Shao, 2020	China	6 / 2.3	37	54.8 ± 9.8	Breast cancer (7), Lung cancer (2), GI cancer (6), Ovarian cancer (11), Other cancers (11)	NR	NR	29.7	NR	NR
Liu, 2018	China	20 / 3.2	43	59 [54.5–73]	Breast cancer (5), Lung cancer (6), GI cancer (10), Ovarian cancer (4), Head and neck (4), Other cancers (14)	23 (53.5)	16 (37.2)	41.9	81.4	58.1
Fang, 2016	Taiwan	13 / 5.8	26	NR	Breast cancer (3), Lung cancer (3), GI cancer (2), Ovarian cancer (1), Head and neck (9), Other cancers (8)	NR	NR	38.5	NR	NR
Galindo-Feria, 2016	Mexico	27 / 2.9	30	NR	Specific cancer types associated with dermatomyositis not detailed	NR	NR	NR	NR	NR
Huang, 2014	China	43 / NR	86	46 [19–68]	Specific cancer types associated with dermatomyositis not detailed	NR	NR	48.8	86.9	58.1
Neri, 2014	Italy	35 / 3.8	18	NR	Specific cancer types associated with dermatomyositis not detailed	NR	8 (44.4)	63.7	NR	44
Kuo, 2011	Taiwan	4 / 3	111	NR	Breast cancer (17), Lung cancer (13), GI cancer (6), Head and neck (29), Other cancers (46)	NR	NR	45	NR	NR
Mebazaa, 2003	Tunisia	18 / NR	20	NR	Breast cancer (7), Head and neck (5), Other cancers (8)	20 (100)	3 (15)	45	NR	38
Peng, 1995	Taiwan	23 / 8.3	12	42.8 [23–56]	NR	10 (83.3)	NR	41.7	83.8	69.4
Koh, 1993	Singapore	5 / 1.6	15	NR	Breast cancer (1), Lung cancer (4), GI cancer (3), Head and neck (2), Other cancers (5)	NR	NR	43	NR	NR
Hidano, 1992	Japan	4 / NR	47	NR	Breast cancer (6), Lung cancer (10), GI cancer (19), Ovarian cancer (1), Head and neck (1), Other cancers (10)	42 (89.36)	NR	57.4	NR	NR
Basset-Seguin, 1990	France	16 / 3.5	13	NR	Breast cancer (5), GI cancer (3), Ovarian cancer (1), Head and neck (1), Other cancers (3)	NR	NR	69	NR	NR
Bonnetblanc, 1990	France	5 / NR	34	NR	Breast cancer (11), Lung cancer (5), GI cancer (2), Ovarian cancer (3), Other cancers (13)	NR	NR	61.8	NR	NR
Hidano, 1986	Japan	10 / NR	171	NR	Breast cancer (21), Lung cancer (26), GI cancer (77), Ovarian cancer (5), Head and neck (2), Other cancers (40)	72 (42.1)	NR	69	NR	NR

Table 2. Characteristics, mortality, and survival outcomes of patients with cancer-associated dermatomyositis in the included studies

Conclusions

In conclusion, this work highlights the clinical features and poor prognosis of cancer-associated dermatomyositis. However, it underscores a major gap in the literature regarding this specific population. Larger studies are needed to better define clinical characteristics, prognostic factors, and enable risk stratification of adverse outcomes.

EADV CONGRESS
VIENNA
30 SEP - 3 OCT 2026

Abstract N°: 720

Dermato-Neuro Syndrome in Scleromyxedema triggered by Influenza A Infection: A Case Report Highlighting the Efficacy of Urgent Intravenous Immunoglobulin Therapy

Kah Wai Cheong*[1], Chong Han Peh[1]

[1] National Skin Centre, Singapore, Singapore

Introduction

Scleromyxedema (generalised lichen myxedematosus) is a rare mucinosis characterized by widespread papules and sclerosis, and is strongly associated with monoclonal gammopathy. Its prognosis is guarded primarily due to its extra-cutaneous manifestations, most notably Dermato-Neuro Syndrome (DNS), a life-threatening encephalopathy.

Case Presentation

We present the case of a 53-year-old male with a long-standing diagnosis of scleromyxedema and underlying IgG-lambda monoclonal gammopathy. Previously, the patient did not respond to conventional immunosuppressants, dupilumab, bortezomib, phototherapy and isotretinoin. He had finally maintained clinical stability via regular intravenous immunoglobulin (IVIg) therapy every 8 - 12 weeks. The patient presented in October 2025 with fever for five days and generalised tonic-clonic seizures later progressing to status epilepticus. Physical examination revealed induration of the face, ears, and waxy papules on the extensor limbs consistent with scleromyxedema. Extensive clinical workup excluded structural intracranial pathology, malignancies, infective encephalitis and other occult causes. Significant positives included a respiratory PCR for Influenza A, and IgG-lambda monoclonal gammopathy. This is the first occurrence of neurological decompensation in this patient. The last dose of IVIg he received was 13 weeks ago due to the patient's wishes to reduce the frequency of infusions.

Empiric antibiotics for meningo-encephalitis were initiated immediately, along with aciclovir. Anti-epileptic therapy with benzodiazepines, levetiracetam and phenytoin were not successful in aborting the seizures nor in reversing his altered mental status and low Glasgow Coma Score (GCS). The patient was intubated on day 2 of admission, and received empirical IVIg therapy (2g/kg) over five days and IV methylprednisolone (1g/day) for 3 days.

Following IVIg therapy and methylprednisolone, seizures ceased by day 4, and encephalopathy resolved over a two-week period. The patient was discharged on day 13 with levetiracetam and phenytoin after achieving stable neurologic function. No adverse events were noted after re-initiation of IVIg therapy 8 weeks later.

Conclusion

This case contributes to the scarce existing literature regarding a potential association between acute respiratory viral infections and DNS onset in scleromyxedema patients. We advocate for a high index of suspicion regarding DNS when scleromyxedema patients present with fever, seizures, or coma. Additionally, the risks of DNS may be elevated in patients who prolong their IVIg infusion intervals. Early empirical initiation of IVIg therapy may be critical to improving neurological outcomes, and any undue delay may result in inadvertent patient mortality.

EADV CONGRESS
VIENNA
30 SEP - 3 OCT 2026

Abstract N°: 772

Petrified Ear: Clinical, Imaging, and Pathophysiological Aspects of a Rare Condition

Gabriel Pires[1], Eduardo Perin[1], Juliano Peruzzo*[1, 2]

[1] Hospital de Clínicas de Porto Alegre, Porto Alegre, Brazil
[2] Universidade Federal do Rio Grande do Sul, Porto Alegre, Brazil

Introduction

Petrified ear (PE), also known as petrified pinna, is a rare condition characterized by abnormal mineralization of the auricular cartilage, resulting in progressive rigidity of the external ear. This process may involve calcification or true ossification, the latter defined by replacement of cartilage with mature lamellar bone. While calcification of the auricle is relatively common and often asymptomatic, true ossification is exceedingly rare and may be associated with local factors such as trauma, frostbite, or chronic pressure, as well as systemic conditions including endocrine and metabolic disorders. Recognition of this entity is important, as it may mimic other causes of auricular pain and deformity.

Case Presentation

An 85-year-old male with a history of systemic arterial hypertension, type 2 diabetes mellitus, and chronic obstructive pulmonary disease was admitted for pulmonary exacerbation. During hospitalization, he reported bilateral ear pain, particularly when lying down, with progressive hardening of both ears over approximately 10 years. He denied prior trauma or local injury. Physical examination revealed markedly rigid auricles, painful on palpation, with normal overlying skin. Biopsy was not feasible due to tissue hardness. Computed tomography demonstrated radiopaque auricular cartilages with cortical and medullary bone formation, confirming ossification. Laboratory evaluation, including calcium, phosphorus, parathormone, thyroid function, and vitamin D levels, was within normal limits. Histopathology showed normal skin without inflammation or neoplasia.

Conclusion

PE results from abnormal mineral deposition in auricular cartilage, leading to calcification and/or ossification. Dystrophic calcification occurs in damaged tissue with normal mineral metabolism, whereas metastatic calcification is associated with systemic disturbances. True ossification is distinguished by the presence of trabecular and cortical bone, best identified on CT imaging. The condition has been associated with endocrine disorders such as adrenal insufficiency, hypothyroidism, diabetes mellitus, and abnormalities in calcium–phosphate metabolism, although idiopathic cases occur. Clinically, most patients are asymptomatic, but some may present with stiffness, reduced flexibility, or pain due to pressure. Differential diagnoses include relapsing polychondritis, calcinosis cutis, and chondrodermatitis nodularis helicis. There are no specific laboratory tests, but evaluation of metabolic and endocrine function is recommended. Treatment is usually unnecessary; however, surgical intervention may be considered in symptomatic cases.

EADV CONGRESS
VIENNA
30 SEP - 3 OCT 2026

Abstract N°: 773

Acute Bullous Iododerma with Cryptococcoid Neutrophilic Dermatosis

Helen-Yiwen Li*[1], Emily Chen[1], Justin Cheeley[1]

[1] Emory School of Medicine, Atlanta, United States

Introduction

Iododerma is a rare halogenoderma resulting from exposure to iodine-containing compounds such as iodinated contrast media, povidone-iodine, and certain medications. While classically presenting with acneiform or pustular eruptions, bullous variants are uncommon and can pose significant diagnostic challenges. Both clinical and histopathologic features may mimic Sweet syndrome, ANCA-associated vasculitis, or autoimmune blistering diseases. Cryptococcoid neutrophilic dermatosis (CND), a rare histopathologic pattern characterized by yeast-like structures resembling Cryptococcus, has only infrequently been described in association with iododerma. We present a case series of acute bullous iododerma with CND following iodinated radiocontrast exposure, highlighting diagnostic pitfalls and clinical implications.

Case Presentation

We describe four female patients (ages 50s–70s) with underlying chronic kidney disease or end-stage renal disease who developed acute cutaneous eruptions within 2–10 days of iodinated contrast exposure . All patients presented with painful, hemorrhagic vesiculobullous eruptions involving the face, trunk, and upper extremities, with occasional mucosal involvement. Laboratory evaluation revealed markedly elevated p-ANCA titers (>1:1280) with anti-myeloperoxidase positivity in all cases. Serum iodine levels, obtained in three patients, were profoundly elevated (ranging from 1,199.6 to 47,964.2 µg/L), supporting iodine toxicity.Histopathologic examination demonstrated neutrophilic dermatosis with subepidermal blistering and features of CND, including variable numbers of cryptococcoid bodies (Figure 1). The burden of these structures ranged from scant to extensive across cases, suggesting a spectrum of histopathologic findings that did not correlate with clinical severity (Figure 1). Direct immunofluorescence studies were negative, and extensive infectious workup, including cryptococcal testing, was unrevealing.The differential diagnosis included Sweet syndrome, ANCA-associated vasculitis, and autoimmune blistering disease. However, the absence of systemic vasculitis, lack of fever, negative immunofluorescence, elevated iodine levels, and temporal association with contrast exposure supported a diagnosis of iododerma. Notably, one patient experienced clinical worsening following repeat contrast administration and ultimately died from complications of critical illness, whereas the remaining three patients improved with systemic corticosteroids, topical therapy, and strict avoidance of further iodine exposure.

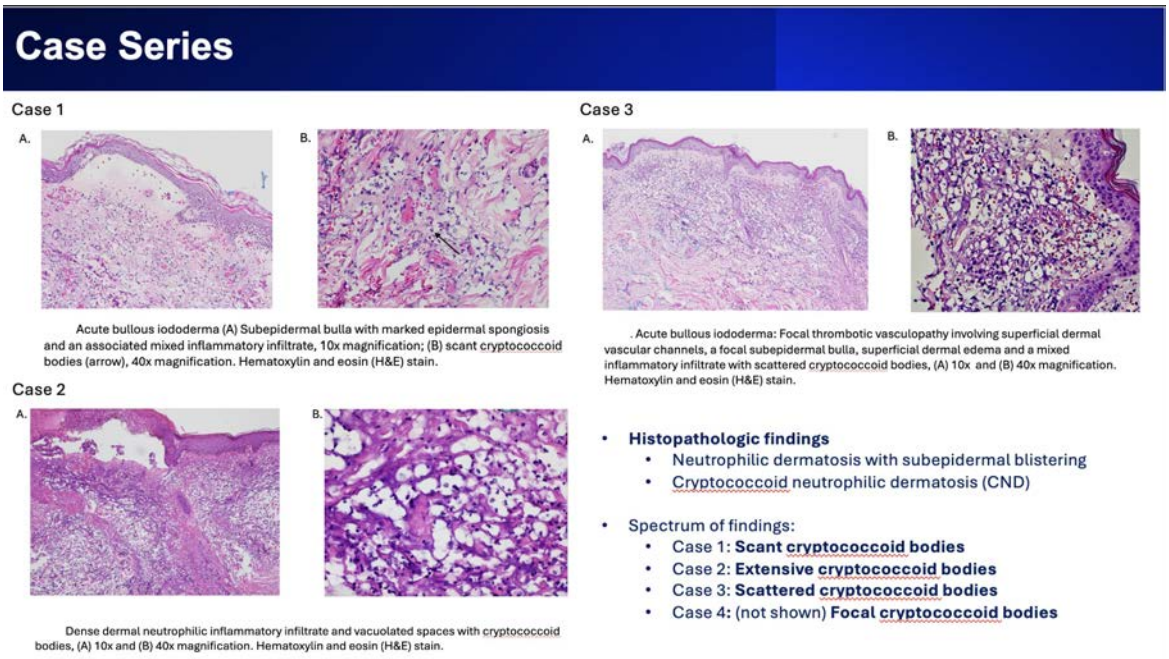

Figure. Histopathologic features of acute bullous iododerma with cryptococcoid neutrophilic dermatosis (CND). Case 1 (A–B): Low-power view (A, 10×) demonstrates a subepidermal bulla with marked epidermal spongiosis and an underlying mixed inflammatory infiltrate. Higher magnification (B, 40×) reveals scattered cryptococcoid bodies (arrow) within a neutrophil-rich dermal infiltrate. Case 2 (A–B): Low-power view (A, 10×) shows a dense dermal neutrophilic infiltrate with subepidermal blister formation. High-power examination (B, 40×) highlights numerous vacuolated spaces containing abundant cryptococcoid bodies, consistent with extensive involvement. Case 3 (A–B): Low-power view (A, 10×) demonstrates focal subepidermal blistering with superficial dermal edema and features of thrombotic vasculopathy involving superficial vessels. High-power view (B, 40×) shows a mixed inflammatory infiltrate with scattered cryptococcoid bodies. Overall, findings across cases illustrate a spectrum of neutrophilic dermatosis with subepidermal blistering and variable burden of cryptococcoid bodies, ranging from scant to extensive, consistent with cryptococcoid neutrophilic dermatosis. Hematoxylin and eosin (H&E) stain.

Conclusion

This case series highlights a rare and severe bullous variant of iododerma associated with cryptococcoid neutrophilic dermatosis. Renal dysfunction likely contributes to impaired iodine clearance, resulting in accumulation and prolonged toxicity. Additionally, concurrent factors such as hydralazine exposure may potentiate neutrophilic dysregulation and autoantibody formation, contributing to the observed clinicopathologic features. Importantly, p-ANCA and anti-MPO positivity may mislead clinicians toward a diagnosis of systemic vasculitis, prompting repeat contrast imaging and exacerbating disease.Recognition of acute bullous iododerma is critical to avoid diagnostic delay and prevent harmful re-exposure to iodine. Identification of CND on histopathology and measurement of serum iodine levels can aid in establishing the diagnosis. Early intervention with corticosteroids and elimination of iodine exposure are key to improving outcomes. These cases underscore the importance of clinicopathologic correlation in neutrophilic dermatoses and expand the spectrum of iododerma presentations.

EADV CONGRESS
VIENNA
30 SEP - 3 OCT 2026

Abstract N°: 778

Dermoscopic Clues Facilitating the Diagnosis of Multicentric Reticulohistiocytosis in a Pediatric Patient With Destructive Arthritis

Simay Yasbay*[1], Cemile ALTUNEL[1]

[1] BASKENT UNIVERSITY HOSPITAL, DERMATOLOGY, ANKARA, Türkiye

Introduction

Multicentric reticulohistiocytosis (MRH) is an extremely rare multisystemic disease, withapproximately 300 cases reported in the literature to date. It is classified as a non–Langerhans cell reticulohistiocytosis. Clinically, MRH most commonly presents with erythematous to reddish-brown papulonodular lesions, predominantly affecting the hands, accompanied by a characteristic mutilating arthritis involving the distal interphalangeal (DIP), proximalinterphalangeal (PIP), and metacarpophalangeal (MCP) joints. Although the disease may resolve spontaneously, it can also result in severe and permanent joint deformities.Herein, we report a 14-year-old female patient presenting with erythematous papulonodular lesions on the dorsum of the hands and mutilating arthritis involving the DIP, PIP, and MCP joints.

Case Presentation

The patient was referred to our dermatology clinic from the Pediatric Rheumatology Department. On physical examination, she had dull-red erythematous papulonodular lesionson the dorsum of the hands, along with swelling and deformities of the DIP and PIP joints. She had previously been diagnosed with juvenile idiopathic arthritis. Her laboratory investigations revealed no elevation in rheumatoid factor (RF), anti–cycliccitrullinated peptide (anti-CCP), or complement (C3–C4) levels. Antinuclear antibody (ANA)and anti–double-stranded DNA antibodies were also negative. She had been treated with methotrexate, etanercept, and intermittent systemic corticosteroids. While systemic corticosteroids led to temporary clinical improvement, disease flares recurred upon discontinuation. Given the absence of supportive laboratory findings and the atypical appearance of the skinlesions, which were not characteristic of rheumatoid nodules, the initial diagnosis was reconsidered. The erythematous papulonodular lesions were examined in detail using bothhandheld and digital dermoscopy. Dermoscopic examination of the nodules demonstrated clustered, coral bead–like structures on a homogeneous erythematous background, accompanied by yellowish to pink globular elements. These findings raised clinical suspicion for Multicentric Reticulohistiocytosis have been rarely described in the literature.
An excisional biopsy from a lesion revealed dermal infiltration by multinucleated histiocytic cells with eosinophilic ground-glass cytoplasm. Immunohistochemical staining showed positivity for CD68 and negativity for CD1a and S100, confirming the diagnosis of Multicentric Reticulohistiocytosis.

Conclusion

This case highlights the diagnostic value of careful dermatologic examination and dermoscopy in patients with destructive arthritis and atypical papulonodular lesions.
Recognition of characteristic dermoscopic features may facilitate earlier diagnosis of Multicentric Reticulohistiocytosis and help prevent irreversible joint damage.

EADV CONGRESS
VIENNA
30 SEP - 3 OCT 2026

Abstract N°: 813

When the Skin Reveals the Gut: Metastatic Crohn's Disease: 2 pediatric case reports

Eya Bouzaien*[1], Anissa Zaouak[1], Haifa Ouarda[2], Raoueh Hedhli[3], Houda Hammami[1]

[1] Dermatology Department, Habib Thameur Teaching Hospital, Tunis, Tunisia
[2] Department of Pediatrics, Mongi Slim Hospital, La Marsa, Tunis, Tunisia
[3] Anatomopathology Department, Habib Thameur Teaching Hospital., Tunis, Tunisia

Introduction

Metastatic Crohn's disease (MCD) is a rare dermatologic manifestation of Crohn's disease (CD) that is defined by the presence of skin lesions non-contiguous from the gastrointestinal tract. Reaching a diagnosis of MCD can be challenging given its nonspecific presentation. We report two pediatric cases of MCD preceding intestinal manifestations.

Case Presentation

The first case involved a 14-year-old girl with a history of congenital heart disease, hypothyroidism, and celiac disease who presented with a 3-month history of rapid-onset swelling of the labia majora. She denied any associated pain, difficulty passing urine, recent trauma, constitutional symptoms, or gastrointestinal symptoms. On clinical examination, swelling of the labia majora without overlying erythema or warmth was observed, associated with perianal skin tags. No genital ulcers, fistulous tracts, or mucosal lesions were present. Abdominal examination was unremarkable. Laboratory investigations revealed no abnormalities. Histopathological findings demonstrated the presence of dermal granulomatous inflammatory infiltrate with no signs of necrosis. She subsequently underwent an esophagogastroduodenoscopy and colonoscopy, which revealed granulomatous ileopan-colitis, highly suspicious of CD. Treatment with continuous enteral nutrition combined with azathioprine led to marked improvement of cutaneous lesions. The second case concerned an 11-year-old boy referred for painless infiltrated macrocheilitis of the upper lip evolving for three months, associated with transient episodes of diarrhea. A labial biopsy revealed a dermal granulomatous inflammatory infiltrate with no signs of necrosis. A complete gastrointestinal evaluation confirmed CD. Prednisone 30 mg daily was added to the patient's treatment regimen, which resulted in progressive improvement of the lesions. MCD is a rare dermatologic manifestation, particularly in children, in whom cutaneous lesions may precede gastrointestinal symptoms. Genital or orofacial involvement is the most frequent pediatric presentation, as illustrated by our cases. The differential diagnosis is broad, including infectious and noninfectious granulomatous diseases such as sarcoidosis, tuberculosis, and hidradenitis suppurativa, making detailed history, thorough physical examination, and skin biopsy essential for diagnosis. Early recognition of MCD allows prompt gastrointestinal evaluation and initiation of therapy. Unfortunately, there is no consensus on standard treatment for MCD, as no clinical trials have been done to guide treatment.

Conclusion

MCD is a rare pediatric manifestation that may precede gastrointestinal symptoms, posing both diagnostic and therapeutic challenges. Early recognition through skin examination and biopsy allows multidisciplinary management.

EADV CONGRESS
VIENNA
30 SEP - 3 OCT 2026

Abstract N°: 851

Reactive Perforating Collagenosis Successfully Treated with Low-Dose Colchicine: A Case Report

Giacomo Minuzzi*[1], Antonia Nuñez[2], Alonso Arroyo[2]

[1] Hospital Guillermo Grant Benavente, Concepcion, Chile
[2] Universidad San Sebastian, Concepcion, Chile

Introduction

Reactive perforating collagenosis (RPC) is a rare perforating dermatosis characterized by transepidermal elimination of altered collagen. It is frequently associated with systemic conditions such as diabetes mellitus and chronic kidney disease, and management remains challenging due to variable therapeutic responses.

Case Presentation

A 42-year-old woman with type 2 diabetes mellitus (non–insulin requiring) presented with reactive perforating collagenosis affecting the dorsal aspect of both hands. Diagnosis was confirmed by incisional biopsy. Previous treatments included 35 sessions of localized narrowband UVB phototherapy, allopurinol 100 mg/day for 6 months, adjunctive local therapies were performed, including topical and intralesional corticosteroid injection and cryotherapy, all without clinical improvement. Then treatment with colchicine (0.5 mg twice daily) was initiated, resulting in marked and sustained clinical improvement, with reduction in lesion number and symptoms. The patient reported no adverse effects.

Conclusion

RPC is often refractory to conventional therapies, including phototherapy and systemic agents such as allopurinol. Colchicine, through its anti-inflammatory effects and inhibition of neutrophil chemotaxis, may represent an effective therapeutic alternative.This case highlights a favorable response to low-dose colchicine, supporting its use as a safe and accessible option, particularly in patients with metabolic comorbidities.

EA DV CONGRESS
VIENNA
30 SEP - 3 OCT 2026

Abstract N°: 859

When IgA Vasculitis Isn't Self-Limiting: A Chronic Adult Case

Umar Al-Haddad*[1], Mark Finn[2], Nabihah Hussaini[3], Ameenah Hussaini[3], Naayema Syeda Hussaini[2], Priyanka Misra[2], Dushmanta Talukdar[2], Nader Ghaderi[2, 2]

[1] Leeds Teaching Hospitals NHS Trust, Leeds, United Kingdom
[2] Bradford Teaching Hospitals NHS Foundation Trust, Bradford, United Kingdom
[3] University of Manchester, Manchester, United Kingdom

Introduction

IgA vasculitis (IgAV), formerly known as Henoch-Schonlein purpura, is a small vessel vasculitis affecting the skin, gastrointestinal tract, joints and kidneys. Cutaneous manifestations typically present as palpable purpura on the lower limbs. Management strategies in adults are not well defined due to limited randomised controlled trial data. Although IgAV is usually self-limiting, adults with severe disease may require treatment. Options include corticosteroids and immunosuppressants such as azathioprine and rituximab. Evidence for methotrexate remains conflicting. We report a rare case of chronic, relapsing, steroid-refractory adult IgAV successfully managed with methotrexate and hydroxychloroquine.

Case Presentation

A 46-year-old female with an almost 20-year history of IgA vasculitis presented with a chronic, relapsing course characterised by recurrent painful purpuric eruptions predominantly affecting the lower limbs. Identified triggers included wearing high heels, prolonged standing and alcohol consumption.

Renal involvement remained stable throughout. A native renal biopsy in 2015 showed IgA deposition consistent with IgA nephropathy, without significant chronic damage.

A skin biopsy in 2018 confirmed leukocytoclastic vasculitis, supporting the diagnosis of IgA vasculitis. Despite the typically self-limiting nature of the disease, this patient exhibited an atypical adult course with recurrent flares over two decades which severely impacted her quality of life.

Hydroxychloroquine (200 mg daily) was initiated in 2019 with good symptomatic improvement and disease control between 2020 to 2022. However, in late 2023, the patient developed a significant flare following COVID-19 infection. Initial management with oral steroids resulted in only partial improvement.

Given ongoing relapses and steroid-refractory disease, immunosuppressive therapy was considered in 2024. The patient commenced methotrexate at 7.5 mg weekly, subsequently titrated to 15 mg weekly. Following dose escalation, disease control improved, with only occasional mild flares reported in 2025.

By early 2026, the patient demonstrated good disease control on methotrexate (15 mg weekly) and hydroxychloroquine (400 mg daily), with no flares. This was also associated with a significant improvement in quality of life, with the patient now able to tolerate previous triggers.

Conclusion

This case highlights an atypical presentation of IgAV with a relapsing course over two decades, which is rarely described in the literature. Most cases of IgAV are self-limiting, resolving within weeks to months; however, persistent disease in adults represents a poorly understood subset with limited evidence to guide management.

A key feature of this case is steroid-refractory disease. Although systemic corticosteroids are frequently used for moderate to severe IgAV, their efficacy in altering long-term disease course remains uncertain. In this patient, corticosteroids provided only partial benefit. This reflects the growing recognition that a subset of adult IgAV may be inadequately controlled with corticosteroids alone.

Evidence supporting the use of immunosuppressive/ immunomodulatory agents in IgAV is limited, with most data derived from small case series and extrapolation from other vasculitides. The sustained disease control observed in this patient following methotrexate escalation suggests a potential therapeutic role for this combination in steroid-refractory IgAV.

Additionally, this case demonstrates identifiable mechanical and environmental triggers, including prolonged standing and alcohol, as well as COVID-19 infection. The role of these factors in IgAV pathogenesis remains incompletely understood.

Overall, this case underscores the need for recognition of chronic, adult-onset, or persistent IgAV as a distinct phenotype, and highlights the limitations of corticosteroids in this population. It also supports consideration of alternative immunomodulatory strategies in refractory disease.

EADV CONGRESS
VIENNA
30 SEP - 3 OCT 2026

Abstract N°: 875

Localized Insulin-Derived Amyloidosis: A Clinical Mimicker of Lipohypertrophy in Refractory Diabetes

Yu-Ching Wang*[1], Yu-Hsiang Lin[1], Cheng-Yuan Li[1]

[1] Taipei Veterans General Hospital Department of Dermatology, Taipei, Taiwan

Introduction

Localized insulin-derived amyloidosis (LIDA), often referred to as "insulin balls," is an under-recognized complication of long-term subcutaneous insulin therapy. It occurs when exogenous insulin aggregates into amyloid fibrils at injection sites, creating a barrier that impairs insulin absorption. This could lead to persistent, refractory hyperglycemia despite complex medical regimens. We present a case confirmed by specific immunohistochemical (IHC) staining, highlighting the necessity of differentiating this condition from common lipohypertrophy to restore effective metabolic control.

Case Presentation

A 74-year-old female patient with poorly controlled type 2 diabetes and several years of insulin use presented with large, indurated plaques on the lower abdomen at her primary injection sites. An incisional biopsy (1.9 x 0.9 x 0.5 cm) was performed, and histopathological evaluation revealed extensive deposition of amorphous, eosinophilic material within the dermis. Congo red staining was positive, confirming the presence of amyloid. Importantly, IHC for CK34βE12 was negative, ruling out keratin-derived cutaneous amyloidosis. Anti-insulin antibody staining was positive within the eosinophilic deposits; notably, this staining was specific to the patient's specimen, as separate amyloidosis control samples showed no immunoreactivity. Based on these findings, a diagnosis of localized insulin-derived amyloidosis was made. The patient was subsequently instructed to rotate injection sites away from the indurated plaques. This intervention resulted in a marked improvement in glycemic control, allowing for a significant reduction in concurrent oral anti-diabetic agents as insulin absorption kinetics were optimized.

Conclusion

This case illustrates that persistent indurated plaques at insulin injection sites should not be reflexively dismissed as lipohypertrophy. While they may appear similar on physical examination, the use of anti-insulin antibody IHC is a critical diagnostic tool to confirm LIDA even when staining is not intense, provided there is specific immunoreactivity compared to controls. Accurate diagnosis is essential because simple clinical intervention by avoiding the amyloidogenic sites can resolve treatment-resistant hyperglycemia and reduce the overall pharmacological burden on the patient.

EADV CONGRESS
VIENNA
30 SEP - 3 OCT 2026

Abstract N°: 875

Rheumatoid Vasculitis: A Diagnosis to Consider in Chronic Leg Ulcers

Seddiki Meriem*[1], Taibi Lynda[1], Imene Mahiou[1], Samira Zobiri[1]

[1] Mustapha University Hospital Center, Algiers, Algeria

Introduction
Chronic lower-limb ulcers are most commonly vascular or infectious in origin. However, in patients with established rheumatoid arthritis (RA), refractory ulcers may indicate rheumatoid vasculitis, a rare but severe extra-articular complication.

Materials and Methods
We report the case of a 75-year-old man with long-standing rheumatoid arthritis treated with methotrexate, admitted for approximately 30 bilateral leg ulcers evolving over three months.The lesions were deep, painful, with a fibrino-necrotic base, purulent exudate, and associated inflammatory edema of both legs. Laboratory findings showed elevated C-reactive protein (146 mg/L), increased erythrocyte sedimentation rate, hypoalbuminemia, and normocytic anemia (hemoglobin 10 g/dL).Arteriovenous Doppler ultrasound was normal, excluding significant vascular insufficiency. Local culture isolated Pseudomonas aeruginosa resistant to multiple antibiotics.Skin biopsy revealed a polymorphous perivascular inflammatory infiltrate with hemorrhagic suffusions, consistent with non-leukocytoclastic vasculitis involving small- and medium-sized vessels.

Results
Cutaneous ulcers in patients with rheumatoid arthritis pose a diagnostic challenge. Differential diagnoses include vascular insufficiency, secondary infection, drug-induced toxicity, and rheumatoid vasculitis.Rheumatoid vasculitis is a rare but severe extra-articular manifestation of long-standing, usually seropositive RA. It affects small- and medium-sized vessels, leading to ischemia, tissue necrosis, and painful ulcers that are often bilateral and resistant to conventional wound care.In our case, normal Doppler findings excluded a primary vascular cause. Although secondary infection was documented, histopathological examination confirmed an underlying vasculitic process. Methotrexate-induced ulceration was considered; however, the vasculitic pattern on biopsy and marked systemic inflammation supported the diagnosis of rheumatoid vasculitis.Early recognition is essential, as management requires systemic immunosuppressive therapy rather than local treatment alone.

Conclusions
In patients with long-standing rheumatoid arthritis, multiple refractory leg ulcers should prompt suspicion of rheumatoid vasculitis. Early skin biopsy is crucial to establish the diagnosis and initiate appropriate systemic therapy, thereby improving outcomes.

EA DV CONGRESS
VIENNA
30 SEP - 3 OCT 2026

Abstract N°: 909

Fatal Papular Neutrophilic Xanthoma: Beyond a Benign Cutaneous Entity

Xinyu Yao*[1]

[1] Department of Dermatology, Peking University First Hospital, Beijing, China

Introduction

Papular neutrophilic xanthoma (PNX) is a rare non-Langerhans cell histiocytosis typically presenting as limited cutaneous lesions. However, its systemic potential is poorly understood. We report a fatal case of PNX that manifested as a treatment-refractory **"Sweet-like" syndrome**, characterized by sterile deep-tissue involvement and **multi-organ failure (MOF)**. This case challenges the perception of PNX as a purely benign cutaneous entity and highlights its potential for life-threatening systemic progression.

Case Presentation

A 60-year-old male presented with a 5-year history of yellow papules and plaques. Initially diagnosed as Sweet's syndrome via skin biopsy, he was treated with systemic glucocorticoids and acitretin with transient efficacy. The clinical course escalated to recurrent hyperpyrexia (>39°C) and septic-like shock.

Extensive imaging (CT/MRI) revealed extensive lesions in the bilateral psoas muscles and iliopsoas, which radiologists initially misinterpreted as extracutaneous manifestations of Sweet's syndrome. Despite aggressive broad-spectrum anti-infective therapy, the patient developed MOF (SOFA score: 13). Notably, multiple cultures and pathogen DNA testing from psoas abscess drainage were consistently negative, suggesting a sterile, neutrophilic inflammatory process.

A definitive diagnosis of PNX was established through repeat multi-site skin biopsies, which demonstrated the hallmark juxtaposition of dense neutrophilic infiltrates, nuclear dust, and diffuse xanthomatized foam cells. Despite intensive care interventions, including CRRT and mechanical ventilation, the patient succumbed to progressive inflammatory shock and cardiac arrest.

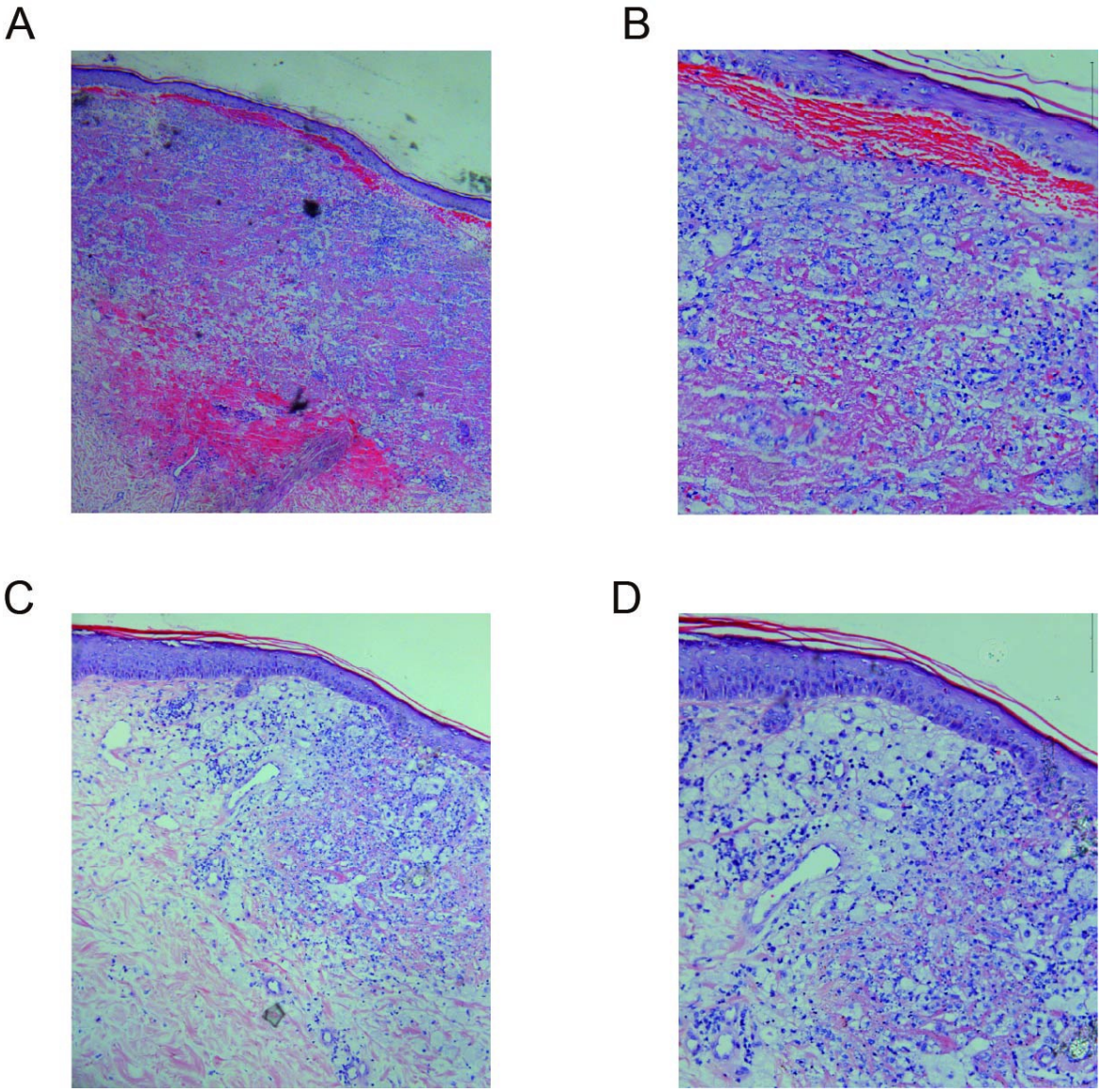

Figure 1. Histopathological findings of the chest and abdominal lesions. (A) Low-magnification (4X) view of the chest biopsy showing distinctive subepidermal fissures and dense inflammatory cell infiltration in the superficial to mid-dermis. (B) High-magnification (20X) view of the chest lesion revealing diffuse xanthomatized foam cells accompanied by prominent nuclear dust (leukocytoclasis). (C) Histopathology of the abdominal lesion (10X) demonstrating diffuse, monotonous single-cell infiltration in the superficial dermis. (D) Higher magnification (20X) of the abdominal biopsy showing cells with enlarged, irregular nuclei and associated nuclear dust.

Conclusion

This case identifies PNX as a potentially fatal systemic disorder rather than a localized dermatosis. The occurrence of "**sterile psoas abscess**" mirrors the extracutaneous neutrophilic infiltration seen in Sweet's syndrome, further complicating the differential diagnosis. For the EADV community, this case serves as a critical reminder: PNX can mimic Sweet's syndrome not only clinically and histologically but also in its systemic aggressive behavior. Early recognition of the "xanthomatized" component is vital to distinguish this entity and monitor for catastrophic systemic outcomes.

Clinical Phase	Cutaneous Morphology	Key Laboratory & Imaging	Pathological Feature	Clinical Insight (Enlightenment)
Early Stage (Years 1-3)	Recurrent red patches and plaques; Initial response to steroids.	Intermittent low-grade fever; Anemia.	Neutrophilic infiltration (Initially misdiagnosed as Sweet's Syndrome).	PNX can perfectly mimic Sweet's Syndrome in early inflammatory stages.
Progressive Stage (Years 4-5)	Yellow papules/nodules; Worsening skin infiltration.	Refractory high fever (>39.5°C); Shock; Normolipemic.	Xanthomatized foam cells mixed with massive nuclear dust (Leukocytoclasis).	"Xanthomatization" is a progressive process; repeated multi-site biopsies are mandatory.
Terminal Stage (Final Month)	Widespread papules/plaques; Multi-site skin involvement.	SOFA score: 13; Sterile psoas abscess; Multi-organ failure (MOF).	Systemic neutrophilic inflammatory storm; Biopsy confirmed PNX.	PNX is not always benign; it can trigger a fatal systemic inflammatory response.

Table 1. Longitudinal clinicopathological evolution and systemic progression of a fatal Papular Neutrophilic Xanthoma case.

EADV CONGRESS
VIENNA
30 SEP - 3 OCT 2026

Abstract N°: 943

Treatment Strategies for Lipedema: A Scoping Review on liposuction, compression therapy, bariatric surgery and pharmacological treatment

Sarah Østergaard Holm*[1]

[1] Department of Dermatology and Venereology, Aarhus University Hospital, Aarhus N, Denmark

Introduction
Lipedema is a chronic condition associated with pain, reduced quality of life, and increased prevalence of depression and fibromyalgia. This study aims to conduct a scoping review of treatment options for lipedema, focusing on liposuction, compression therapy, bariatric surgery, and pharmacological treatment.

Materials and Methods
A scoping review was conducted in accordance with the PRISMA statement. Three online databases were used to identify papers published from 2020 to March 2025 by a systematic search strategy.

Results
A total of 27 studies were included. 16 studies on liposuction, 9 studies on compression therapy and 2 studies on bariatric surgery. No studies on pharmacological treatment of lipedema were identified.

Conclusions
The majority of the studies focused on liposuction or compression therapy, both of which are reported to have beneficial effects in the management of lipedema. In contrast, there is a significant lack of research regarding bariatric surgery and pharmacological treatments, highlighting a clear need for further studies in these areas.

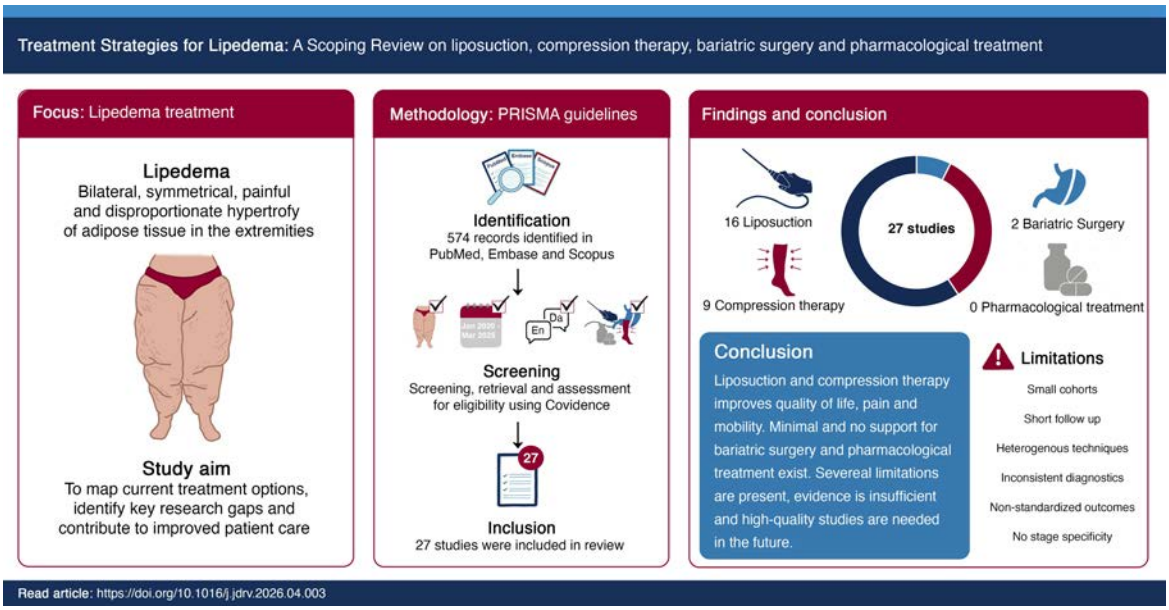

Graphical abstract

EADV Congress 2026, VIENNA
30 SEPTEMBER - 03 OCTOBER 2026
POWERED BY M-ANAGE.COM

EA DV CONGRESS
VIENNA
30 SEP - 3 OCT 2026

Abstract N°: 955

Skin as a diagnostic clue to underlying systemic amyloidosis: A Case Associated with Multiple Myeloma

Pooja kotian*[1]

[1] Department of Dermatology, Venereology and Leprosy, Kasturba Medical College Mangalore, Manipal Academy of Higher Education, Manipal, India, Mangalore, India

Introduction
Amyloidosis involves the deposition of misfolded protein fibrils, leading to significant disruption of normal tissue function. Primary systemic amyloidosis is a rare disease that occurs in isolation or in conjunction with plasma cell dyscrasias. We present a case of primary systemic amyloidosis associated with multiple myeloma, marked by distinctive skin findings that highlight dermatology's role in detecting systemic disease.

Case Presentation
An elderly male patient was admitted with altered sensorium, severe anaemia and extensive asymptomatic skin lesions, which had progressed over a one-year period, initially localizing over the periocular region before disseminating to other areas of the body. Cutaneous examination revealed well-defined yellowish waxy papules, plaques, purpura, and ecchymosis, predominantly affecting the peri-orbital region, forehead, trunk, and flexural areas of the limbs.

The laboratory tests revealed severe anaemia, increased erythrocyte sedimentation rate, and significant proteinuria with Bence Jones protein. Histopathology revealed dermal amyloid deposits, confirmed with Congo-red staining. Electrophoresis showed an M spike and increased levels of lambda light chain confirming the presence of paraproteinemia. Additionally, bone marrow biopsy indicated hypercellularity with plasma cell proliferation, consistent with multiple myeloma. Based on the above findings, a diagnosis of primary systemic amyloidosis secondary to multiple myeloma was made. Patient was referred to Haematology department for further management.

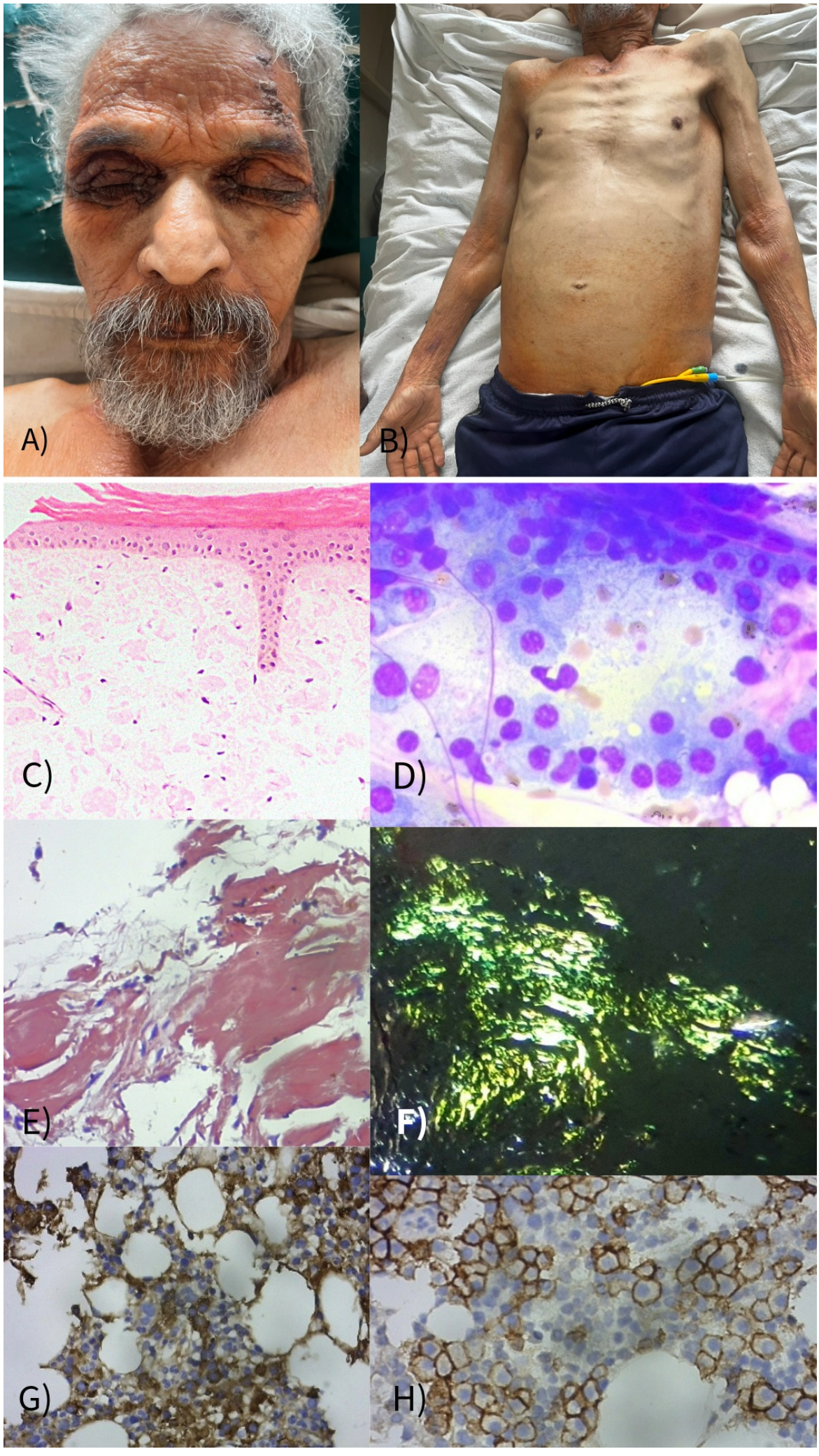
A)
B)
C)
D)
E)
F)
G)
H)

Figure A : Diffuse yellowish waxy papules coalescing to form plaques along with ecchymosis noted over the forehead and periorbital region; Fig B : Diffuse yellowish- orange waxy plaques noted over the flexural aspect of upper limbs, neck and waist line; Fig C : HPE showing the presence of amyloid deposits over the dermis and subcutaneous layer; Fig D : Bone marrow biopsy showing atypical plasma cells in clusters (400X MGG Stain); Fig E : Congo red positive staining seen among the amyloid deposits in the bone marrow; Fig F : Apple green birefringence noted with polarising microscopy; Fig G, H : Immunohistochemistry suggestive of strong positive CD-38,56 and Lambda confirming the presence of clonal plasma cells.

Conclusion

This case highlights how dermatology can offer valuable clues to underlying systemic disease through characteristic skin findings, allowing for timely diagnosis and management. These observations can play a key role in directing further evaluation and clinical decision-making.

EADV CONGRESS
VIENNA
30 SEP - 3 OCT 2026

Abstract N°: 958

Type I cryoglobulinemic vaso-occlusion mimicking calciphylaxis: an important differential diagnosis in end-stage renal disease

Krista Yordanova*[1], Alica Gravius[1], Roman Saternus[1], Thomas Vogt[1]

[1] Department of Dermatology, Saarland University, Homburg/Saar, Germany, Saarland, Germany

Introduction

Introduction & Objectives: Cryoglobulinemia (CG) can cause multisystem involvement, frequently affecting the kidneys and skin. Type I CG, usually monoclonal IgG (less commonly IgM or IgA), is often associated with hematologic malignancies, while types II and III involve immune complexes. Cryoglobulins precipitate at temperatures below 37°C, causing cyanosis, Raynaud phenomenon, palpable purpura, livedo reticularis, and ischemic necrotic ulcers. In dialysis-dependent patients, painful necrotic lesions often raise suspicion of calciphylaxis (CP), a high-morbidity arteriolopathy. Differentiating CG from CP is challenging for both clinicians and pathologists. In this report, we outline major hallmarks of the conditions considered and highlight that vascular damage and hypoxia can simultaneously create a setting for concomitant reactive angioendotheliomatosis (RAE), adding further complexity to histopathologic interpretation and diagnosis.

Case Presentation

Case report: A 69-year-old female patient with of monoclonal gammopathy of undetermined significance (MGUS) and CG-associated glomerulonephritis presented with rapidly progressive, painful necrotic skin ulcers. At presentation, the patient was already dialysis-dependent due to advanced renal failure. Her history included prior rituximab therapy and liver cirrhosis with mild acquired deficiencies of protein C, S, and antithrombin III. CP was initially suspected, but biopsy revealed a triad of monoclonal IgG-dominant vaso-occlusive angiopathy, microthromboses, and secondary reactive angioendotheliomatosis, without vascular calcification. The diagnosis of recurrent type I CG-associated vascular disease was established. Treatment included methylprednisolone (1 mg/kg/day), aspirin (100mg/day), local warmth therapy, plasmapheresis for five days, and re-initiation of rituximab. The course was complicated by influenza B infection and hyponatremia, but gradual improvement and initial wound healing were observed, allowing discharge in stable condition.

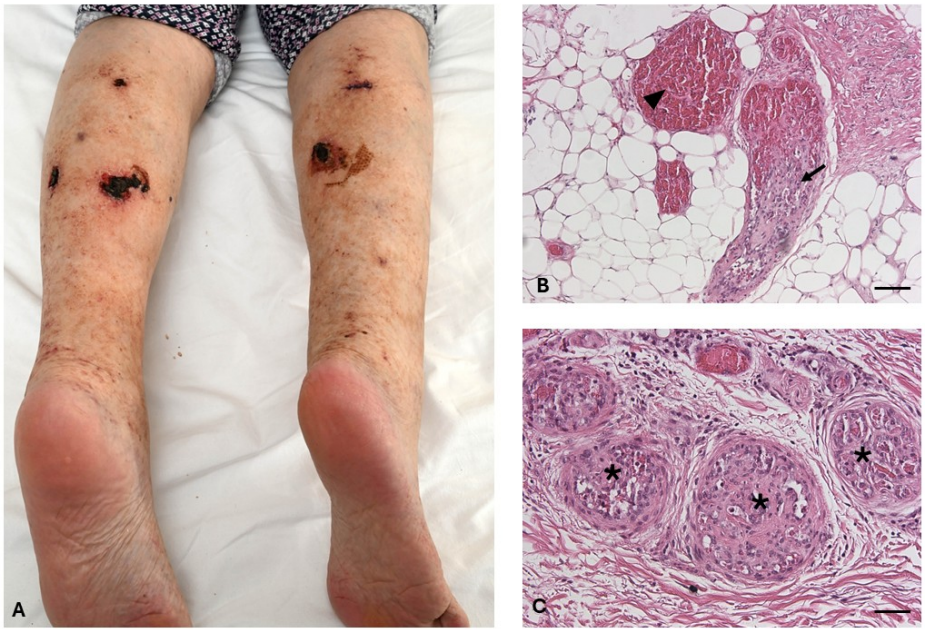

Figure 1: (A) Clinical photographs of the patient showing necrotic ulcerations on the dorsal aspects of the legs. (B, C) Hematoxylin and eosin (H&E) staining of a skin biopsy from the lesions demonstrating a triad of vaso-occlusive angiopathy with bright pink amorphous protein deposits (arrow), true microthrombi (arrowhead), and prominent glomeruloid angioendotheliomatosis (asterisk). Scale bars: (B) 100 µm; (C) 50 µm.

Conclusion

Discussion: This case illustrates the diagnostic challenge of purpura-like, vasculopathic, and necrotic skin lesions in dialysis-dependent patients. Meticulous dermatopathologic work-up is essential, as not all lesions are due to calciphylaxis. Therapeutic strategies differ: CG-associated vaso-occlusion requires immunosuppression and plasmapheresis, whereas calciphylaxis focuses on correcting mineral metabolism. In our patient, the vaso-occlusion caused by monoclonal cryoglobulins was treated with rituximab to suppress pathogenic B cells, alongside glucocorticoids and plasmapheresis to reduce circulating cryoglobulins and address any vasculitic component. Histopathology was decisive in excluding calciphylaxis and identifying secondary RAE, reflecting severe endothelial response to vascular injury. The triad of cryoglobulin deposition, microthrombosis, and RAE led to a phenotype that closely mimicked calciphylaxis, emphasizing the importance of precise histologic assessment to guide therapy.

Conclusion: Accurate diagnosis of cutaneous vasculopathy in dialysis-dependent patients requires integration of histopathology, systemic disease history, and prior therapy. Recognition of reactive angioendotheliomatosis as a marker of severe endothelial injury facilitates appropriate treatment, which may substantially affect prognosis.

EA DV CONGRESS
VIENNA
30 SEP - 3 OCT 2026

Abstract N°: 973

IgG4-related disease with cutaneous and parotid gland involvement: a case report

Natalia Valero Montalvo*[1], María Asunción Arregui Murua[1], Deborah Ximena Ugas Burranca[1], Nerea Infante Gonzalo[1], Paula Arratibel Goenaga[1], Sandro de Urban Chamorro San Juan[1], Miren Marquina Iñarrairaegui[1], Aitor Xabier De Vicente Aguirre[1], María Aránzazu López Pestaña[1], Hirune Cembrero Saralegui[1], Nerea Ormaechea Pérez[1]

[1] Hospital Universitario Donostia, Donostia-San Sebastián, Spain

Introduction
IgG4-related disease (IgG4-RD) is a rare multisystem fibroinflammatory disorder characterized by IgG4-positive plasma cell infiltration and tissue fibrosis, often involving multiple organs. Cutaneous manifestations are uncommon (4-6% of cases) and lack well-defined diagnostic criteria, which may delay diagnosis.

Case Presentation
A 68-year-old woman with a history of stage II sarcoidosis presented with a chronic pruritic eruption in the left submandibular region. Initial ultrasound revealed bilateral hypoechoic submandibular nodules, and biopsy showed reactive lymphoid tissue.

Over time, the patient developed progressive infiltrated subcutaneous lesions involving the left parotid and submandibular regions (Figure 1a). Imaging studies demonstrated persistent glandular enlargement and regional lymphadenopathy. Repeat biopsy revealed a lymphohistiocytic infiltrate with eosinophils and numerous plasma cells (Figure 1b). Immunohistochemistry showed CD38-positive plasma cells (Figure 1c) with an IgG4/IgG ratio >40% (Figure 1d, 1e), and serum IgG4 levels were markedly elevated. A diagnosis of IgG4-RD with cutaneous and parotid gland involvement was established.

Treatment with oral prednisone was initiated with gradual tapering, achieving significant clinical, serological, and radiological improvement. Due to partial biochemical persistence and mild radiological progression, azathioprine was added. The patient is currently on glucocorticoids and azathioprine, and dupilumab will be considered if response is inadequate.

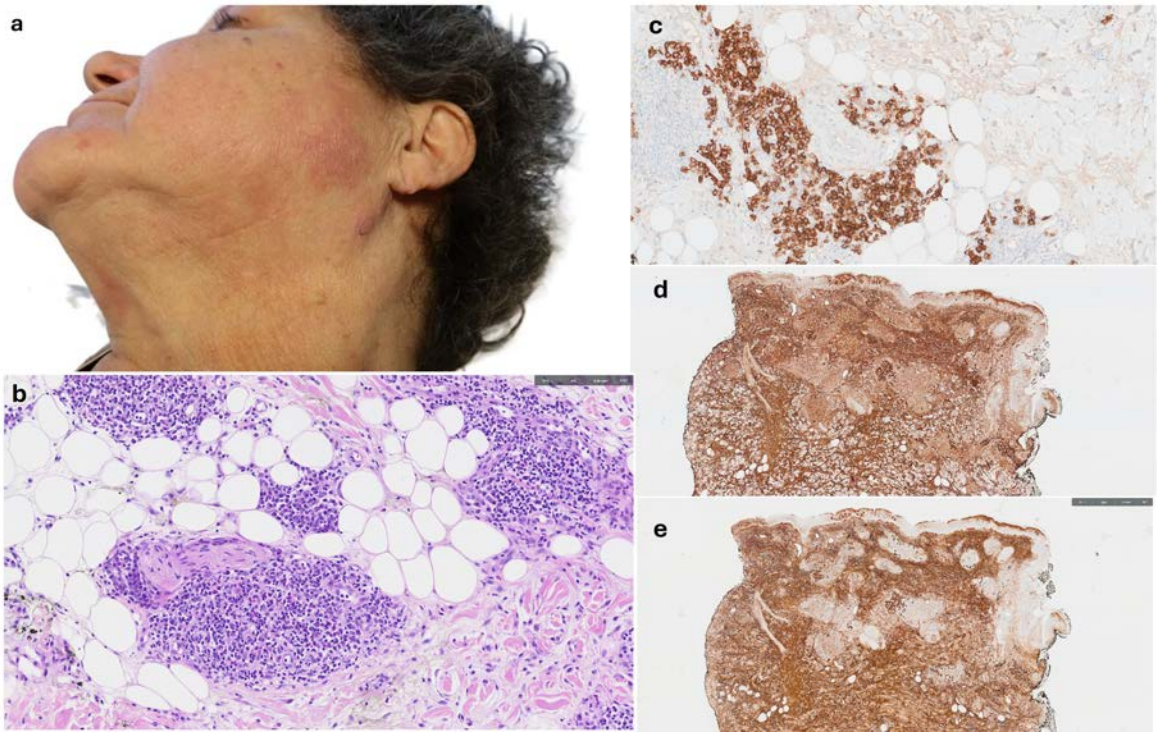

• Figure 1a: infiltrated subcutaneous lesions involving the left parotid and submandibular regions. • Figure 1b: lymphohistiocytic infiltrate with eosinophils and numerous plasma cells (Hematoxylin and eosin staining) • Figure 1c: CD38-positive plasma cells (Immunohistochemistry). • Figure 1d: immunohistochemistry positive for IgG4.

Conclusion

Cutaneous IgG4-related disease is an uncommon and under-recognized manifestation that requires a high index of suspicion. This case highlights the importance of integrating clinical, histological, and serological findings for accurate diagnosis and appropriate management, as well as the potential need for immunosuppressive or targeted therapies in relapsing disease.

EADV CONGRESS
VIENNA
30 SEP - 3 OCT 2026

Abstract N°: 991

red ear , what is the diagnostic ?

salah eddin awawde*[1], Issam TABLIT[1], Lemya Mezdour[1], Saliha Takheroubt[1], Asma Haciane[1], Samira Zobiri[1]

[1] Mustapha University Hospital Center, Dermatology and venereology, Sidi M'Hamed - alger, Algeria

Introduction
Relapsing polychondritis (RP) is a rare, chronic, and potentially life-threatening systemic autoimmune disease characterized by recurrent inflammation and progressive destruction of cartilaginous structures. Due to its uncommon occurrence and non-specific early clinical features, the diagnosis is frequently delayed—often by several years—as initial presentations commonly mimic localized bacterial infections like erysipelas or perichondritis. While auricular involvement is the most frequent inaugural symptom, the long-term prognosis is primarily dictated by the involvement of the respiratory tract and other major systemic complications. This case highlights the critical role of the dermatologist as a "sentinel" clinician, whose ability to identify specific cutaneous and mucosal signs can lead to the early detection of a potentially fatal multisystemic condition.

Case Presentation

2. Observation

A 70-year-old female with a medical history of heart disease and hypothyroidism presented to the dermatology department with a painful, erythematous swelling of the left pinna persisting since August 2025. Prior to admission, the condition was managed unsuccessfully as recurrent bacterial perichondritis with multiple courses of broad-spectrum antibiotics. Specialized dermatological examination revealed a bright red, edematous auricle characterized by the strict sparing of the non-cartilaginous ear lobule. This pathognomonic finding shifted the clinical focus toward a systemic process. The patient reported a catastrophic constitutional decline, including an 18 kg weight loss over five months, anorexia, and ageusia. Further examination revealed a "saddle nose" deformity with scaling at the osteocartilaginous junction, persistent dysphonia, and a dry cough refractory to bronchodilators. Laboratory investigations showed a normocytic anemia (Hb **[insert value]** g/dL) with a normal C-reactive protein (CRP). Pulmonary function tests confirmed a non-reversible obstructive syndrome of the upper airways, though the chest CT scan remained normal.

The diagnosis of relapsing polychondritis was established according to Damiani’s criteria, based on the presence of auricular and nasal chondritis combined with respiratory symptoms. Treatment was promptly initiated with systemic prednisolone at a dose of **[insert value]** mg/kg/day. The clinical response was immediate and favorable, with the patient reporting a rapid resolution of pain, cough, and ageusia within the first week. Over the following month, she experienced steady weight gain and stabilization of her general health. The previously inflamed auricle evolved into a brownish, atrophic state, characteristic of the cicatricial phase of the disease. While the systemic inflammation was successfully controlled and the obstructive symptoms improved, the saddle nose deformity remained as a permanent structural sequela, underscoring the necessity of initiating treatment before irreversible cartilage destruction occurs.

Conclusion
The "red ear" is a significant diagnostic decoy in clinical practice, frequently leading to ineffective antibiotic

treatments. This case underscores that the key to differentiation lies in the fine semiological analysis of the ear: whereas infectious cellulitis involves the entire ear, relapsing polychondritis strictly spares the lobule. The massive weight loss and dysphonia in this patient served as "red flags" for high systemic activity and imminent airway risk, even in the absence of elevated inflammatory markers like CRP. Respiratory involvement remains the primary cause of mortality in RP, making early detection and multidisciplinary management (Dermatology, ENT, Rheumatology) essential. Early aggressive treatment with corticosteroids, and potentially steroid-sparing agents, is mandatory to prevent fatal respiratory collapse and the permanent structural damage observed in this patient's nasal architecture.

EADV CONGRESS
VIENNA
30 SEP - 3 OCT 2026

Abstract N°: 998

Differentiating Psychogenic Cheilitis from Crohn's Disease: The Importance of Clinical Examination in Diagnosis

salah eddin awawde*[1], Saliha Takheroubt[1], Issam TABLIT[1], Lemya Mezdour[1], Asma Haciane[1], Samira Zobiri[1]

[1] Mustapha University Hospital Center, Dermatology and venereology, Sidi M'Hamed - alger, Algeria

Introduction

Psychogenic cheilitis, also known as factitial labial dermatosis, is a rare condition characterized by self-induced lesions. It often occurs in adolescents with underlying psychiatric disorders, such as anorexia nervosa. While the diagnosis is typically suspected based on the patient's psychological profile and the clinical morphology of the lesions, the presence of extra-cutaneous signs can introduce diagnostic uncertainty. The objective of this report is to demonstrate that when suspecting labial pathomimia, the presence of massive weight loss and digestive symptoms necessitates a rigorous diagnostic approach to rule out metastatic Crohn's disease before confirming a factitial origin.

Case Presentation

We report the case of a 14-year-old female adolescent, currently followed for anorexia nervosa, who presented with chronic erosive and crusted cheilitis evolving over three months. From the outset, the clinical appearance strongly suggested pathomimia: the erosions were superficial, the fissures were sharply defined, and the lips notably lacked granulomatous infiltration or permanent edema.

However, the patient's history revealed a rapid weight loss of 10 kg, paroxysmal abdominal pain, and rectal bleeding. This cluster of symptoms, despite occurring within a known psychiatric context, compelled the clinician to investigate for Crohn's disease, as cheilitis can occasionally be the sole initial cutaneous manifestation of the disease.

Examination upon admission confirmed severe emaciation with a BMI of 15.61 kg/m^2. The labial lesions were painful but not infiltrated. To rule out the organic inflammatory pathology suggested by the digestive symptoms, a comprehensive workup was performed. CRP, fecal calprotectin, and fecal occult blood tests were all within normal limits, excluding active intestinal inflammation. Autoimmune serologies and an upper gastrointestinal (GI) endoscopy revealed no abnormalities, confirming that the digestive symptoms and weight loss were strictly related to anorexia nervosa. Consequently, the final diagnosis of psychogenic cheilitis was retained by exclusion.

Conclusion

In this case, pathomimia was the primary hypothesis from the initial examination due to the non-granulomatous nature of the lesions and the patient's history. Nevertheless, the **"golden rule"** in factitial dermatology is to never establish a diagnosis of pathomimia without first definitively ruling out an underlying organic pathology—especially when the patient reports red-flag symptoms such as rectal bleeding.

Crohn's disease can closely mimic cheilitis, but it is generally characterized by**firm macrocheilitis** and histological granulomas. In this instance, the normal results of biological markers and fecal tests allowed for the exclusion of Crohn's. This enabled the medical team to focus entirely on psychiatric and nutritional management, thereby

avoiding inappropriate and heavy immunosuppressive therapies.

EADV CONGRESS
VIENNA
30 SEP - 3 OCT 2026

Abstract N°: 1002

Amicrobial Pustulosis of the Folds Associated with Metastatic Crohn’s Disease: A Diagnostic and Therapeutic Challenge

salah eddin awawde*[1], Tasnime Bouaziz[1], Issam TABLIT[1], Saliha Takheroubt[1], Lemya Mezdour[1], Asma Haciane[1], Samira Zobiri[1]

[1] Mustapha University Hospital Center, Dermatology and venereology, Sidi M'Hamed - alger, Algeria

Introduction

Amicrobial Pustulosis of the Folds (APF) is a rare neutrophilic dermatosis characterized by sterile pustules predominantly affecting major skin folds. Metastatic Crohn’s Disease (MCD) is an uncommon extraintestinal manifestation defined by skin lesions histologically characterized by non-caseating granulomas, separated from the gastrointestinal (GI) tract by normal skin. Cutaneous signs, such as deep genital ulcerations, can precede GI symptoms by years, making early diagnosis exceptionally challenging. We report a complex case of a patient initially treated for APF who progressively developed severe mucocutaneous lesions, ultimately revealing underlying metastatic Crohn’s disease.

Case Presentation

A 38-year-old female presented in 2019 with intense genital pruritus and oozing papules extending to the trunk. In 2022, she was diagnosed with APF based on axillary and inguinal sterile pustules and compatible histology. The condition was refractory to multiple lines of therapy, including corticosteroids, colchicine, and cyclosporine. Despite a partial response to dapsone, severe relapses led to the initiation of infliximab in March 2025.

By late 2025, the patient was admitted with severe cachexia (BMI 16.4 kg/m^2) and a significant clinical flare. Dermatological examination revealed widespread ichthyosiform scaling, persistent sterile axillary pustules, and a purulent 3-cm scalp tumor. Crucially, the ano-genital examination showed profound infiltration, pseudo-mariscas (skin tags), and bilateral "knife-cut" linear ulcers. Mucosal involvement included fetid otitis externa, severe sicca syndrome, macrocheilia, and macroglossia.

Extensive investigations were conducted to assess for luminal Crohn's disease. Colonoscopy (December 2025) and upper endoscopy (February 2026) were strictly normal. Perineal MRI showed no fistulae or anomalies; however, fecal calprotectin was mildly elevated at 164 µg/g.

Histopathology of the genital "knife-cut" ulcers and the scalp tumor revealed non-specific inflammation without visualized non-caseating granulomas. Despite the normal endoscopies and non-specific biopsies, the pathognomonic clinical triad (linear genital ulcers, macrocheilia, and pseudo-mariscas) led the multidisciplinary team to a diagnosis of severe metastatic Crohn’s disease. In February 2026, the patient was started on IV methylprednisolone (1 mg/kg/day) and metronidazole, followed by induction with adalimumab combined with azathioprine. This regimen led to the rapid resolution of auricular lesions and a marked reduction in genital infiltration.

Conclusion

This case highlights a deceptive clinical overlap. While the initial presentation aligned with APF, the subsequent development of deep linear ulcers and macrocheilia strongly indicated MCD. Cutaneous Crohn's can be the inaugural manifestation of the disease, preceding digestive involvement by months or years.

A critical teaching point here is that the absence of granulomas on biopsy does not exclude the diagnosis when clinical signs are pathognomonic. The striking mucocutaneous severity justified an aggressive "top-down" therapeutic approach with anti-TNF α and immunosuppressant combotherapy, despite the absence of active luminal disease. Close clinical surveillance is imperative, as the patient remains at high risk for future gastrointestinal manifestations.

EA DV CONGRESS
VIENNA
30 SEP - 3 OCT 2026

Abstract N°: 1022

A rare case of adult-onset Langerhans cell histiocytosis: erythroderma, eosinophilia, and lymphadenopathy

Emily Matejin*[1], Nick Manuelpillai[1], Holly Sexton[1], Alexander Nirenberg[2], Laura Scardamaglia[1, 3, 4, 5]

[1] Department of Dermatology, Western Health, Melbourne, Australia
[2] Dorevitch Pathology, Melbourne, Australia
[3] Department of Dermatology, The Royal Melbourne Hospital, Melbourne, Australia
[4] Department of Dermatology, The Royal Children's Hospital, Melbourne, Australia
[5] Faculty of Medicine, Dentistry and Health Sciences, The University of Melbourne, Melbourne, Australia

Introduction

Langerhans cell histiocytosis (LCH) is a rare disease characterised by circulating Langerhans cells that express CD1a, CD207 (langerin), and S100. The disease varies in its manifestations from singular eosinophilic granulomatous lesions to multisystem disease involving bone, skin, lungs, and the pituitary gland. There is limited literature exploring cutaneous manifestations of LCH. We describe a case of adult-onset Langerhans cell histiocytosis presenting with erythroderma, eosinophilia, and lymphadenopathy.

Case Presentation

An 80-year-old woman presented to hospital with widespread blanching erythema, pruritus, and lymphadenopathy. The patient was afebrile and haemodynamically stable with no constitutional symptoms. She had a history of chronic kidney disease, superior mesenteric artery thrombosis, chronic obstructive pulmonary disease, and latent tuberculosis. She had no known dermatological history, malignancy, or recent infection. A medication timeline did not reveal any potential drug triggers, and there was no suspicion for a contact allergen.

Differential diagnoses for the presentation were broad, including atopic dermatitis, cutaneous lymphoma, hypereosinophilic syndrome, drug hypersensitivity syndrome, and infection. Extensive investigations including autoimmune, connective tissue disease, infection, and malignancy screens were all negative. Eosinophils were markedly elevated up to 9.0×10^9/L (reference range $<0.5 \times 10^9$/L). Radiographic imaging demonstrated extensive lymphadenopathy without hepatosplenomegaly. Initial skin biopsy was unrevealing and left axilla core lymph node biopsy demonstrated acute lymphadenitis with increased number of larger CD30+ B cells. Further differential diagnoses in this context included primary cutaneous anaplastic large cell lymphoma and Mycosis fungoides with large cell transformation.

The patient remained a diagnostic dilemma, with persistent eosinophilia and erythroderma; repeat skin biopsy was performed. Immunostaining on this second skin biopsy demonstrated CD1a and Langerin positive Langerhans cells, with immunostaining on an excisional lymph node biopsy highlighting a cortical infiltrate of histiocyte-like cells that were CD1a and S100 positive (BRAF V600E negative) immunophenotype, supportive of the diagnosis of multi-focal LCH. The patient was commenced on oral prednisolone 50mg daily with subsequent reduction in eosinophil count (5.1×10^9/L to 0.6×10^9/L) and improvement in cutaneous symptoms. Hydroxyurea was utilised as adjunctive therapy. Additional systemic therapies were deemed inappropriate in this patient after multidisciplinary discussion for reasons including comorbidities and morbidity of treatments. Her disease remains well-managed with hydroxyurea, low-dose prednisolone, potent topical corticosteroids, and topical emollients.

Conclusion

Our patient's primary cutaneous presentation was erythroderma. Erythroderma is an inflammatory disorder hallmarked by generalised erythema and scaling that involves more than 90% of the body surface area, and can be life-threatening due to the metabolic demands it places on the body and subsequent complications. LCH rarely presents as erythroderma, with published literature noting papules and scale/crusting as the most common presentation. Uniquely, our case appears to represent the first female patient with LCH presenting with erythroderma, and fifth case overall. Our patient also demonstrated a marked eosinophilia ($9.0x10^9$/L, 43.06% of leukocyte count) compared to other documented cases. Clinicians should consider LCH as a diagnosis in patients with erythroderma, eosinophilia, and lymphadenopathy that are not otherwise explained. Dermatologists can play an important role in the early diagnosis and multidisciplinary management of this rare and impactful disease. Through documentation of this case, we aim to increase knowledge surrounding this rare disease to improve the time to diagnosis and subsequent care in adults with new onset LCH.

EA DV CONGRESS
VIENNA
30 SEP - 3 OCT 2026

Abstract N°: 1047

Cutaneous Clues to Pacemaker Lead Endocarditis: Septic Purpura and Acral Necrosis in the Setting of Disseminated Intravascular Coagulation

Felicia Thianich*[1], Martin Gruebler[1, 2, 3], Christian Posch[1, 4, 5, 6]

[1] Sigmund Freud University, Vienna, Austria
[2] Danube Private University, Krems an der Donau, Austria
[3] Universitätsklinikum Wiener Neustadt, Wiener Neustadt, Austria
[4] Clinic Hietzing, Vienna, Austria
[5] Clinic Landstrasse, Vienna, Austria
[6] Klinik und Poliklinik für Dermatologie und Allergologie am Biederstein TU München, München, Germany

Introduction

Acral purpura as a sign of microthrombotic occlusions of cutaneous small vessels may be an important hint to underlying endocarditis, expediting diagnosis prior to confirmation by cardiac imaging. This report details a case of pacemaker lead endocarditis where evolving purpura and nascent acral necrosis lead to the diagnosis of bacterial endocarditis.

Case Presentation

A 57-year-old male, with a complex medical history including biological aortic valve replacement, ascending aortic surgery, dual-chamber pacemaker implantation with a prior right ventricular lead revision, and alcohol use disorder, presented with generalized seizures, fever, hypotension, and delirium.

Progressive livid discoloration of both feet and the left index finger prompted dermatological consultation. Examination revealed reduced temperature of both lower extremities with confluent non-blanchable purpura over the feet and toes, alongside early necrotic changes at the left index fingertip. Peripheral pulses were impalpable below the popliteal level, yet ankle-brachial indices were preserved, indicating microvascular occlusion rather than macrovascular disease.

Blood cultures confirmed methicillin-sensitive Staphylococcus aureus. Laboratory findings revealed marked inflammation, thrombocytopenia, elevated D-dimer, but normal fibrinogen compatible with disseminated intravascular coagulation. Transoesophageal echocardiography identified a 10 × 15 mm floating vegetation on the right ventricular pacemaker lead within the right atrium, no left-sided manifestation of endocarditis could be identified.

The cutaneous findings reflect septic purpura with acral ischemia, secondary to endocarditis-associated coagulopathy. Despite targeted antimicrobial therapy and attempted lead extraction the patient died after a prolonged hospital stay due to multi-organ failure.

Conclusion

This case underscores the critical role of dermatologic findings in diagnosing bacterial endocarditis. It is important to note that right-sided bacterial endocarditis may also present with cutaneous *stigmata* in addition to pulmonary

manifestations. The rapid recognition of purpura and acral hypoxia can dramatically shorten the diagnostic interval to echocardiography and thereby enabling earlier, potentially lifesaving intervention.

EADV CONGRESS
VIENNA
30 SEP - 3 OCT 2026

Abstract N°: 1063

MIGRAINE -ASSOCIATED PURPURIC RASH: A RARE CUTANEOUS CLUE

Bikash Ranjan Kar[1], Liza Mohapatra[1], Riddhi Sable*[1]

[1] Department of Dermatology, Institute of Medical Sciences and SUM hospitals,, Bhubaneshwar, India

Introduction

Migraine is a neurological disorder characterized by recurrent unilateral throbbing headaches with photophobia, aura, or autonomic symptoms. Although primarily neurological, cutaneous manifestations are rare and poorly understood. We report an unusual case of migraine associated with a localized purpuric rash over the right breast.

Case Presentation

A 26-year-old female presented with a three-month history of recurrent erythematous lesions over the right breast, temporally associated with severe right-sided throbbing headaches radiating to the right arm. There were no focal neurological deficits. Examination revealed multiple tender, non-blanchable purpuric macules over the right breast with discrete right axillary lymphadenopathy.

The lesions appeared during headache episodes, evolved from bright red to dusky purple, and resolved spontaneously within a few days. Dermoscopy demonstrated red clods on a light erythematous background. Ultrasonography showed reactive intramammary (10 × 5 mm) and subcentimetric axillary lymph nodes. Coagulation parameters were normal. A diagnosis of migraine was confirmed neurologically.

The patient was treated with propranolol 40 mg once daily and advised trigger avoidance. At two-week follow-up, there was complete resolution of both the cutaneous lesions and lymphadenopathy, with no recurrence.

Conclusion

Cutaneous manifestations of migraine are uncommon and typically confined to cephalic regions, such as red forehead dot syndrome. The underlying mechanism may involve aberrant activation of the trigeminovascular system or trigemino-cervical autonomic reflex, leading to extracerebral vasodilation and neurogenic inflammation mediated by vasoactive peptides.

This case highlights an extracephalic purpuric eruption temporally associated with migraine, expanding the clinical spectrum of migraine-related skin manifestations and underscoring the need for awareness of atypical dermatological presentations.

EADV CONGRESS
VIENNA
30 SEP - 3 OCT 2026

Abstract N°: 1069

Seborrheic Keratosis: A Mirror of Neoplasia

Dorra Medhaffar*[1, 1], Gara Soumaya[1], Litaiem Noureddine[1, 1], Jones Mariem[1], Zeglaoui Faten[1]

[1] Charles Nicolle Hospital, Tunis, Tunisia

Introduction

The Leser–Trélat syndrome is characterized by the sudden and eruptive onset of multiple seborrheic keratoses associated with an underlying malignancy. Only a few cases have been reported, mainly in association with gastrointestinal adenocarcinomas, particularly gastric cancer, but also with breast and renal carcinomas. We report a case of Leser–Trélat syndrome revealing an urothelial carcinoma.

Case Presentation

A 68-year-old man, with a history of treated tuberculosis 15 years earlier, presented with the rapid appearance over one month of multiple hyperpigmented oval lesions associated with general deterioration of health status. Clinical examination revealed numerous seborrheic keratoses on the trunk. The diagnosis of eruptive seborrheic keratoses was suspected, prompting investigations for an associated internal malignancy. Thoraco-abdomino-pelvic computed tomography showed irregular left-sided bladder wall thickening. Cystoscopy with biopsy and histopathological examination confirmed a high-grade papillary urothelial carcinoma with deep chorion invasion. The diagnosis of Leser–Trélat syndrome was retained. The patient subsequently underwent surgical management.

Conclusion

Leser–Trélat syndrome is a rare cutaneous paraneoplastic syndrome, first described by Edmund Leser and Ulysse Trélat. Its pathophysiology is thought to involve increased epidermal growth factor (EGF) receptor stimulation in the skin. Although its authenticity remains debated because of the lack of consistent parallel evolution between the skin lesions and the underlying tumor, the absence of specificity regarding tumor histology, and the discrepancy between the frequent occurrence of eruptive seborrheic keratoses and the rarity of associated malignancies, its recognition remains clinically important. Indeed, cutaneous paraneoplastic syndromes such as Leser–Trélat syndrome may represent the first manifestation of an underlying cancer. Clinicians should therefore remain vigilant when faced with the abrupt onset of multiple seborrheic keratoses, particularly in elderly patients or in the presence of constitutional symptoms, and should promptly initiate investigations for an occult malignancy.

EA DV CONGRESS
VIENNA
30 SEP - 3 OCT 2026

Abstract N°: 1088

Chronic Nodular Deposits in the Skin: A Diagnostic Dilemma

Amina Asfiya M Iqbal*[1]

[1] Yenepoya Medical College, Mangaluru Taluka, India

Introduction

Gout is a metabolic disorder characterised by deposition of monosodium urate (MSU) crystals secondary to chronic hyperuricemia. It can develop into tophaceous gout, a severe type of the disease characterised by MSU crystal accumulation that causes joint deformity, functional disability, and a lower quality of life if untreated. Although classically presenting with arthritis, cutaneous involvement in the form of tophi may occasionally be the initial manifestation, posing a diagnostic challenge for dermatologists.

We describe a 38 -year-old man who had poorly controlled hyperuricemia and severe polyarticular tophaceous gout. This case contributes to our understanding of the course of chronic gout and its complications by highlighting the negative effects of delayed therapy and the significance of early and consistent management.

Case Presentation

We report a case of a 38-year-old male presenting with a 4-year history of multiple nodular lesions over elbows and ankles. Some lesions were associated with chalky white discharge, while others remained asymptomatic. There was a prior history of joint pains in the form of morning stiffness. He had a history of alcohol dependence for which he was on treatment.

On examination, multiple large, firm, irregularly shaped, skin-coloured and a few yellowish-white nodules were seen distributed over the bilateral elbows, extensor aspect of proximal forearms, medial malleoli and Achilles tendons, along with deformity of the left feet. A few of the nodules discharged a chalky, white material.

Clinical differentials included calcinosis cutis, rheumatoid nodules, xanthomas and tophaceous gout. Laboratory investigations revealed elevated serum uric acid (15.7 mg/dL). Wet mount preparation of the discharge showed the presence of needle-shaped crystals. Histopathological examination showed chronic inflammatory cell infiltrate composed of lymphocytes, plasma cells and histiocytes in the papillary dermis. Focal areas show nodular aggregates of acellular amorphous, pale eosinophilic material and a feathery appearance (monosodium urate crystals). However, it is recognised that urate crystals may dissolve during routine tissue processing, potentially limiting histological identification

Polarised microscopy demonstrated negatively birefringent needle-shaped crystals, confirming the diagnosis of cutaneous tophaceous gout.
The patient was started on urate-lowering therapy with colchicine 0.5 mg BD and febuxostat 40 mg OD along with anti-inflammatory measures and lifestyle modification. Follow-up over 1 month showed significant reduction in lesion size and symptomatic improvement.



Negatively birefringent needle-shaped crystals seen on Polarized microscopy

Conclusion

Multiple nodular cutaneous lesions may be an uncommon initial presentation of gout. Awareness of such atypical presentations is essential to avoid misdiagnosis and ensure timely management. Dermatologists play a pivotal role in early identification through clinicopathological correlation.

EADV CONGRESS
VIENNA
30 SEP - 3 OCT 2026

Abstract N°: 1103

Previously undiagnosed alpha-1 antitrypsin deficiency presenting as panniculitis with rapid response to augmentation therapy

Maria Hedman*[1], Paola Lara-Valencia[2], Patrik Ivert[1], Karin Popovic Silwerfeldt[1]

[1] Department of Dermatology and Venereology, Karolinska University Hospital, Stockholm, Sweden
[2] Department of Clinical Pathology and Cancer Diagnostics, Karolinska University Hospital, Stockholm, Sweden

Introduction

Alpha-1 antitrypsin (AAT) is a protease inhibitor, and an acute phase reactant that rises during inflammation, similarly to C-reactive protein (CRP). Alpha-1 antitrypsin deficiency (AATD)–associated panniculitis is a rare manifestation of AATD, often triggered by trauma or infection. Diagnosis can be challenging, particularly in previously undiagnosed individuals, and therapeutic evidence remains limited to case reports.

Case Presentation

A 48-year-old woman presented with painful erythematous nodules on her thighs, hips, buttocks, breast, and axilla, accompanied by fever, fatigue, and dyspnea. Laboratory investigations showed elevated inflammatory markers, and antibiotics for presumed erysipelas were ineffective. Initial investigations included serum AAT measurement as part of the inflammatory workup; levels were noted as slightly reduced and disregarded. Following skin biopsy, corticosteroid therapy for suspected inflammatory panniculitis was initiated. The subsequent month, serological inflammation gradually subsided, whilst large ulcerations appeared in affected skin areas and general symptoms worsened. Clinical deterioration and repeat blood tests demonstrating severe AAT deficiency prompted inpatient management. Treatment with oral tetracycline was ineffective, whereas administration of intravenous AAT augmentation (a concentrate of plasma-derived human AAT, given 60 mg/kg bodyweight weekly) resulted in rapid systemic and cutaneous improvement, reported by the patient on the day following the first infusion, and visibly within days. Repeat skin biopsies were supportive of AATD-associated panniculitis. Infusions thereafter continued on an outpatient basis, with regular clinical and laboratory monitoring. Inflammatory markers had normalized after 3 weeks of treatment, and complete clinical remission was achieved after 11 weeks (a total of 12 infusions). Three weeks after treatment cessation, repetitive trauma during karate training induced a relapse, with transient lesions appearing first at trauma sites and later at unrelated locations, this state resolved spontaneously within one month without further therapy. The patient returned to her daily activities including regular physical exercise, and has been followed for 7 months without further relapse.

Conclusion

This case illustrates the diagnostic challenge of AATD-associated panniculitis, which can mimic infectious disease as well as other inflammatory panniculitides, especially as AATD can remain unrecognized when AAT is measured during active inflammation. In this patient, corticosteroid therapy may have contributed to an exacerbation of the panniculitis, whist intravenous AAT augmentation was associated with prompt systemic and cutaneous response to treatment. These findings support consideration of AATD in panniculitis of unclear etiology and suggest that AAT augmentation may provide rapid clinical improvement in affected patients.



A.



B.

Figure A.
Shows early skin changes in the left axilla, with warm, tender, erythematous yellow-red, fluctuant abscess-like nodules.

Figure B.
Seven weeks after Figure A, two weeks into corticosteroid therapy, demonstrating progression with inflammation of the left breast skin and subcutis, hemorrhagic features, yellowish liquefied subcutaneous material and ulceration.

Figures C-H.
Show serial left breast images during IV AAT therapy and after cessation.



C. Before 1st dose weekly IV AAT (after skin biopsy with suturation).



D. 3 days after 1st dose IV AAT.



E. 3 weeks into treatment.

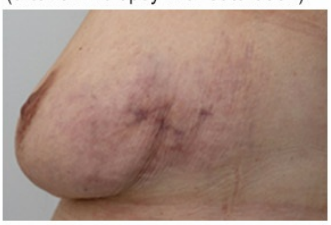

F. 8 weeks into treatment.



G. 11 weeks into treatment.



H. 6 weeks after finished treatment.

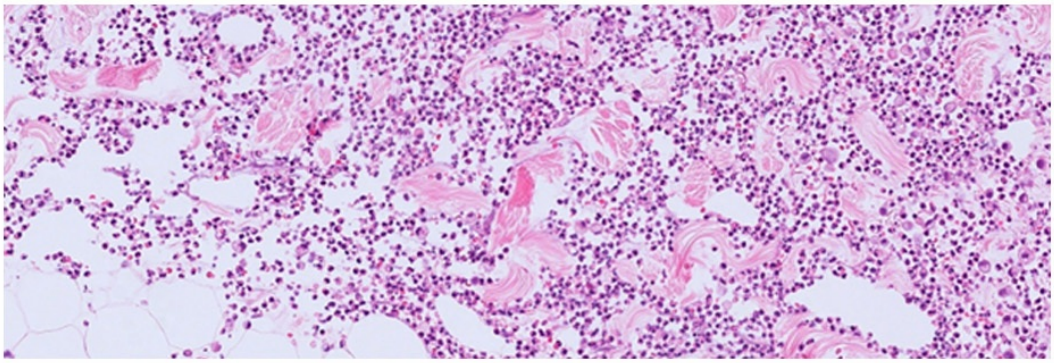

I. Histologic section of a left breast skin biopsy including subcutaneous fat, obtained before 1st dose IV AAT (Figure C). The subcutis demonstrates a predominantly lobular panniculitis, with extensive involvement of the adipose lobules by a dense inflammatory infiltrate composed predominantly of neutrophils, accompanied by marked leukocytoclasia. Associated with this infiltrate are foamy histiocytes and eosinophils, as well as focal hemophagocytosis. Small-caliber vessels exhibit reactive inflammatory changes, without evidence of primary vasculitis, and erythrocyte extravasation is noted in the surrounding adipose tissue.

EADV CONGRESS
VIENNA
30 SEP - 3 OCT 2026

Abstract N°: 1109

Liver transplant recipients receive less dermatological surveillance than kidney transplant recipients independent of skin cancer status: a single-centre cross-sectional study.

Georgia Gilbert*[1], Girish Gupta[1], Ruth Jones[1]

[1] NHS Lothian, Edinburgh, United Kingdom

Introduction
Post-transplant skin cancer research is predominantly focused on kidney transplant recipients. Whether liver transplant recipients receive equivalent dermatological surveillance is unclear.

Materials and Methods
A cross-sectional study of 620 solid organ transplant recipients (428 kidney, 192 liver) was conducted within a single regional health board. Multivariable logistic regression examined the association between transplant type and skin cancer prevalence, adjusting for age, sex, time since transplant, and immunosuppressive regimen. Separate models examined regular dermatology follow-up and documented sun protection advice as outcomes, additionally adjusting for skin cancer status.

Results
Skin cancer was present in 69 (16.1%) kidney and 25 (13.0%) liver recipients (p=0.382). After adjustment for demographics, time since transplant, and immunosuppressive regime, liver recipients had significantly lower odds of skin cancer (OR 0.50, 95% CI 0.26 to 0.95, p=0.037). After adjustment for age, sex, time since transplant, and skin cancer status, liver recipients were less likely to receive regular dermatology follow-up (OR 0.53, 95% CI 0.28 to 0.97, p=0.043) and documented sun protection advice (OR 0.52, 95% CI 0.33 to 0.81, p=0.004).

Conclusions
Liver transplant recipients had lower adjusted skin cancer prevalence than kidney recipients. This may reflect a lower burden of immunosuppression, as liver transplantation is associated with reduced rates and severity of acute and chronic rejection, relative immunological privilege, and a greater potential for tolerance during immunosuppression tapering compared with kidney transplantation (1). However, liver transplant recipients were also less likely to receive regular dermatology follow-up and sun protection advice, and this difference persisted after adjustment for skin cancer status, suggesting a surveillance gap beyond what would be expected from their lower disease burden. Whether this lower observed prevalence itself partly reflects under-detection due to less intensive surveillance, rather than a true difference in disease burden, remains an important unanswered question.

Reference
1. Kim A, Waldron O, Daoud D, Huang Y, Patel J, Hong J, Butler T, Jain A. Comparative review of standardized incidence ratio of nonlymphoid, de novo malignancies after liver transplant versus after kidney transplant. Exp Clin Transplant. 2024;22(8):600–606. doi:10.6002/ect.2024.0136.

EA DV CONGRESS
VIENNA
30 SEP - 3 OCT 2026

Abstract N°: 1117

Dermatologic Signs Unmasking Insulin Resistance: Prevalence and Patterns

Melany Nahomi de la O Rendon*[1], Jorge Ocampo Candiani[1], Jose Gerardo González González[1], Adriana Sánchez García[1], Cristina Naomi Alvarez López[1], Iván Dimitry Ruiz Esparza Ramírez[1]

[1] Hospital Universitario Dr. José Eleuterio Gonzalez, Monterrey, Mexico

Introduction

The skin serves as a mirror of overall health, offering a window into internal alterations, such as Insulin Resistance. Due to the complexity and high costs associated with demonstrating Insulin Resistance, there is an unmet need for a reliable, accessible, and minimally invasive approach to detect this condition, allowing for timely intervention. One such pathway lies in the recognition of its cutaneous manifestations, including Acanthosis Nigricans, Keratosis Pilaris, Skin tags, and Androgenetic Alopecia.

Materials and Methods

We conducted an analytical cross-sectional study including 150 patients aged 18 to 45 years, of both sexes, who presented with the previously described manifestations. Medical histories were obtained, and anthropometric measurements were recorded. Blood glucose and insulin levels were measured to assess Insulin Resistance using the HOMA-IR method. A comprehensive physical examination was performed to evaluate the presence of Keratosis Pilaris, Acanthosis Nigricans, Skin Tags, and Androgenetic Alopecia. The study population was stratified by sex, age, and Fitzpatrick skin phototype, and these variables were analyzed to determine their association with the presence or absence of Insulin Resistance.

Results

A total of 150 participants were included in the analysis, comprising 46 males and 104 females, with a median age of 23 years [21–29]. Overweight or obesity was identified in 123 subjects (82%), with a mean Body Mass Index (BMI) of 31.53 ± 6.87. Regarding Fitzpatrick skin phototypes, the majority of participants exhibited type III (44.7%) and type IV (42%). Assessment of cutaneous manifestations revealed that Acanthosis Nigricans was the most prevalent finding (94.7%), followed by Keratosis Pilaris (64.7%), Skin Tags (31.3%), and Androgenetic Alopecia (7.3%). Using a HOMA-IR cutoff value of 2.5, the median HOMA-IR was 3.35 [2.26–5.51], and 108 participants met the criteria for Insulin Resistance.

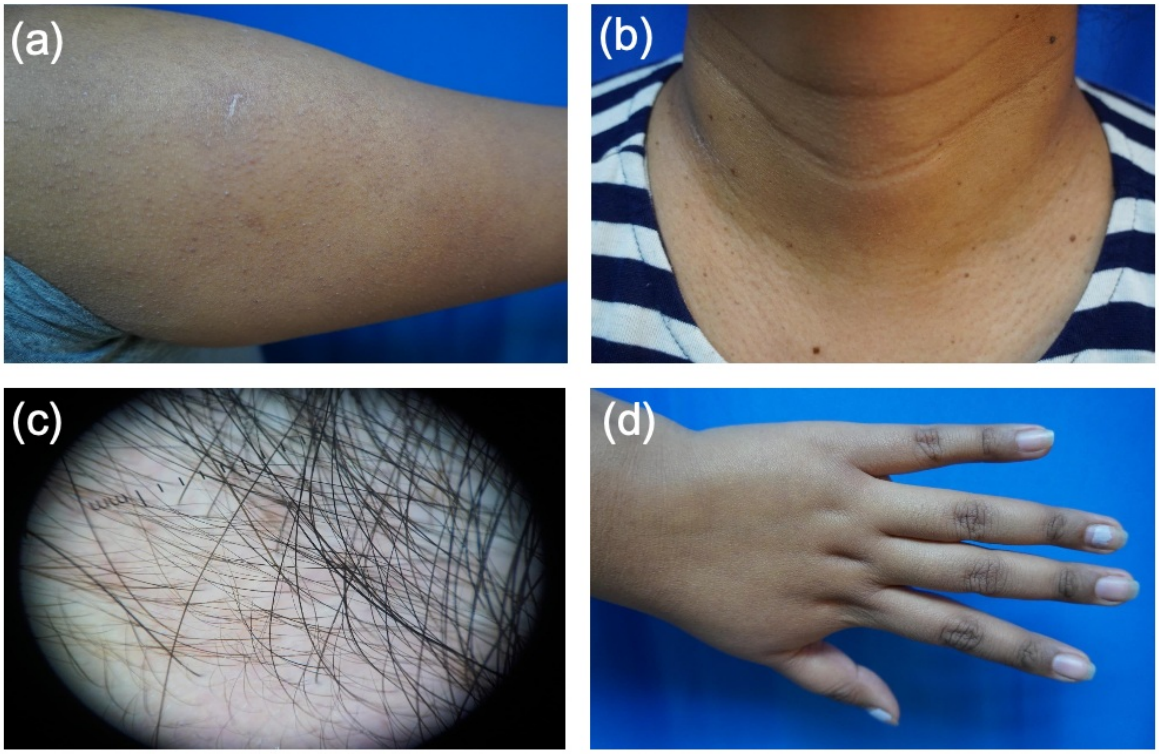

Figure 1. Dermatologic manifestations of Insulin Resistance. (a) Keratosis Pilaris in the extensor surface of the upper arm. (b) Skin Tags on the neck. (c) Anisotrichosis, hallmark trichoscopic sign in Androgenetic Alopecia. (d) Acanthosis Nigricans on the knuckles.

Conclusions

In our study population with dermatologic manifestations associated with Insulin Resistance, 72% met HOMA-IR criteria. Acanthosis Nigricans was the most prevalent finding, followed by Keratosis Pilaris. No statistically significant association was identified between IR and the evaluated cutaneous manifestations, possibly due to limited sample size and statistical power. Nevertheless, the high prevalence of HOMA-IR positivity supports the role of dermatologic signs as a practical, cost-effective, and non-invasive tool for early metabolic risk detection.

We identified a high prevalence of Insulin Resistance in a relatively young cohort, consistent with global trends showing IR is increasingly common in young adults. Cutaneous markers represent early visible indicators of metabolic vulnerability. Their identification should prompt metabolic evaluation, particularly in individuals with additional risk factors.

EADV CONGRESS
VIENNA
30 SEP - 3 OCT 2026

Abstract N°: 1156

Delayed fulminant purpura without disseminated intravascular coagulation following successful treatment of staphylococcal endocarditis in a young patient with end-stage renal disease

Ludivine Marie Rose Compain*[1], Genaro Suarez[1]

[1] Hospital Regional de Alta Especialidad de La Península de Yucatán, Mérida, Mexico

Introduction

Purpura fulminans (PF) is a rare thrombotic dermatologic emergency classically associated with severe infection, disseminated intravascular coagulation (DIC), or inherited anticoagulant deficiencies. Post-infectious PF is uncommon and may pose major diagnostic challenges, particularly in patients with end-stage kidney disease, in whom calciphylaxis and other thrombotic dermatoses must also be considered. We report a fatal case of post-infectious PF developing after microbiologic control of Staphylococcus aureus infective endocarditis and in the absence of overt DIC at presentation.

Case Presentation

A 29-year-old anephric woman on chronic hemodialysis, with prior bilateral nephrectomy for complicated urolithiasis and recurrent sepsis, developed rapidly progressive painful purpuric lesions several weeks after successful treatment of S. aureus Mahurkar catheter-related infective endocarditis. The eruption began in the right gluteal region during hemodialysis and extended over 48 hours to the lumbar, pelvic, intergluteal, pubic, thigh, and flank regions. Examination showed large asymmetric violaceous plaques with central necrosis and multiple hemorrhagic bullae, several of which rapidly ulcerated. At presentation, there was no overt sepsis or DIC: leukocytes were 10.9 $\times 10^3/\mu L$, platelets 262 $\times 10^3/\mu L$, PT was not prolonged, and ISTH DIC score was 1, although D-dimer was markedly elevated (21,272 ng/mL). Blood and wound cultures remained negative. Skin biopsy demonstrated thrombotic vasculopathy, while negative Von Kossa staining argued against calciphylaxis. A markedly decreased protein C level further supported the diagnosis of post-infectious PF. Despite multidisciplinary management including broad-spectrum antibiotics, repeated surgical debridement, and critical care support, the patient died from progressive disease.

Conclusion

This case highlights that PF may occur as a delayed post-infectious complication after apparent microbiologic and echographic resolution of *S. aureus* endocarditis and may initially present without DIC. In patients with end-stage kidney disease, this entity can closely mimic calciphylaxis, making early clinicopathologic correlation essential. Recognition of this atypical presentation is critical given its rapid progression and high mortality.

EADV CONGRESS
VIENNA
30 SEP - 3 OCT 2026

Abstract N°: 1162

When facial cellulitis doesn't respond: Fulminant odontogenic Mucormycosis in a Diabetic patient

Ludivine Marie Rose Compain*[1]

[1] Hospital Regional de Alta Especialidad de La Península de Yucatán, Mérida, Mexico

Introduction

Mucormycosis is an opportunistic, angioinvasive fungal infection with high mortality that presents diagnostic and therapeutic challenges. Early intervention is critical due to its rapid and progressive course. Odontogenic mucormycosis accounts for approximately 8% of facial mucormycosis cases and is a frequently underdiagnosed clinical entity. In patients with poorly controlled diabetes mellitus (DM), rhino-orbito-cerebral mucormycosis is the most common presentation. Mortality rates can reach 50% in cases without cerebral invasion and >80% with intracranial invasion. Early diagnosis and initiation of antifungal therapy reduce mortality from approximately 80% to 40% in high-risk patients. Early detection and aggressive combined management with antifungals and surgery are crucial for improving outcomes. Our objective is to present a case of fulminant mucormycosis post-dental extraction in a patient with uncontrolled DM2, emphasizing missed warning signs, diagnostic errors that delayed definitive treatment, and lessons for early recognition.

Case Presentation

A 52-year-old male with poorly controlled type 2 diabetes presented with right facial edema, hyperemia, and oppressive palatal pain following recent upper molar extraction treated with outpatient levofloxacin. Due to worsening symptoms, he sought re-evaluation. Examination revealed right facial erythema and edema, suggesting facial cellulitis and possible maxillary abscess. Empirical vancomycin and clindamycin were initiated. CT showed increased soft tissue volume in the right zygomatic region with subcutaneous fat stranding, platysma thickening extending to masticator, buccal, parotid, and maxillary spaces, plus air density images near right maxillary molars. Maxillofacial surgery initially deferred intervention after negative exploratory aspiration. Within hours to days, rapid progression occurred with dermatosis involving the eyelid, nasal dorsum and ala, nasolabial fold, and right cheek—characterized by erythematous-violaceous macules and papules with central necrosis evolving to crusted necrotic plaques. This was accompanied by fever, periorbital edema, decreased visual acuity, and ophthalmoplegia. Despite tigecycline and acyclovir, the patient developed septic shock. With progressive facial and palatal necrosis plus neurological deterioration, liposomal amphotericin B was started for suspected mucormycosis. Urgent surgical debridement and right hemifacial resection revealed hard palate and periorbital tissue necrosis. Histopathology confirmed mucormycosis with fungal thrombosis. The patient deteriorated and died.

Conclusion

Odontogenic mucormycosis presents atypically and requires a high index of suspicion. Notably, mortality in odontogenic mucormycosis without cerebral extension is significantly lower (9.5%) compared to rhino-orbito-cerebral mucormycosis with intracranial invasion (>80%). This case illustrates that post-dental extraction mucormycosis is an underdiagnosed condition whose prognosis depends critically on early recognition. The differential diagnosis of facial cellulitis in poorly controlled diabetic patients should include mucormycosis when alarm signs are present: palatal necrosis, rapid progression despite antibiotics, periorbital edema, or ophthalmoplegia. Successful management requires immediate multidisciplinary coordination (internal medicine, dermatology, infectious diseases, maxillofacial surgery, otolaryngology, ophthalmology) with urgent initiation of

liposomal amphotericin B, early biopsy for histopathological confirmation, aggressive surgical debridement, and correction of hyperglycemia and acidosis. In diabetic patients with blood glucose >360 mg/dL, fever, and ophthalmological findings after dental procedures, mucormycosis should be considered until proven otherwise.

EADV CONGRESS
VIENNA
30 SEP - 3 OCT 2026

Abstract N°: 1176

Managing Menopausal Skin: Evidence-Based Strategies for Clinical Practice

Claudia DeGiovanni*[1]

[1] University Hospitals Sussex NHS Foundation Trust, Brighton, United Kingdom

Introduction

Menopause-related oestrogen decline leads to impaired skin barrier function, reduced collagen and altered hair biology, yet its impact on dermatological disease remains under-recognised in clinical practice and dermatology guidance for management is limited. This presentation integrates skin biology, current evidence on the effects of hormone replacement therapy on the skin and dermatological conditions, and real world data of women with lived experience of skin conditions through the menopause, to provide practical management strategies for common menopausal skin conditions.

Materials and Methods

This is a narrative review of the literature on skin biology and clinical evidence on skin changes and conditions through the menopause, integrated with findings from the IMPACT mixed -methods study of 1457 peri/postmenopausal women and 17 qualitative interviews.

Results

Menopause-related oestrogen deficiency is associated with significant structural and functional changes in the skin. Collagen content declines by approximately 2% per year following menopause, contributing to reduced dermal thickness, elasticity and increased wrinkling. Oestrogen depletion also impairs epidermal barrier function through alterations in stratum corneum lipid composition, including reduced ceramide levels, resulting in increased transepidermal water loss and xerosis. Reduced oestrogen levels are also associated with diminished antioxidant capacity and increased oxidative stress, further contributing to skin ageing and impaired wound healing. In addition, in hair follicles, declining oestrogen levels in menopause combined with a relative increase in androgen activity leads to shortening of the anagen phase and increased transition to telogen, contributing to hair thinning and shedding. Emerging evidence suggests that hormone replacement therapy may partially reverse some of these changes, with improvements in skin hydration, collagen content and preservation of stratum corneum lipid composition reported in treated women.

These biological changes are experienced by peri-menopausal and post-menopausal women in many ways, including dry skin, itch, reduced elasticity, spots, wrinkling, flushing and hair changes. Menopause is associated with both new diagnoses and notable deterioration of common dermatological diseases. HRT is associated with improvement in skin symptoms in many women, although evidence for its role in treating specific dermatological conditions remains limited and is predominantly based on outdated hormone formulations.

Table 1 demonstrates how common skin conditions are affected through the menopause, the current evidence on HRT and practical management tips that will be discussed.

Diagnosis	Menopause effect (IMPACT study + pathophysiology + literature)	HRT evidence	Practical management in menopause
Eczema	Oestrogen deficiency leads to impaired skin barrier function and reduced hydration causing increased xerosis driving flares.	Indirect (improves barrier/hydration)	Barrier optimisation (ceramide-rich emollients), avoid irritants. Standard treatments.
Contact dermatitis	Barrier impairment increases susceptibility to irritants/allergens in menopausal skin	Indirect (barrier support)	Trigger avoidance, patch testing, barrier repair.
Psoriasis	Studies suggest increased prevalence/severity post-menopause, likely due to altered immune regulation and oestrogen decline	Limited	Cardiovascular risk with both menopause and psoriasis. Assess triggers, sleep, adherence, genital involvement. Standard psoriasis treatments.
Acne	Recognised in perimenopause with decline post menopause Relative androgen excess and sebaceous changes.	Limited	Skin barrier optimisation. Gentle regimens, retinoids, azelaic acid.
Rosacea	Can be triggered in perimenopause, some data suggests incidence decreases post menopause. Vascular instability and overlap with vasomotor flushing. Impaired skin barrier function.	Limited	Skin barrier optimisation. Consider HRT for vasomotor symptoms.
Urticaria	Recognised in menopause. Hormonal fluctuations, heat and stress may exacerbate symptoms.	None	Antihistamines (up-dosing), address triggers (heat, stress).
FPHL	Strong evidence of postmenopausal association; oestrogen decline shifts hair cycle and androgen balance	Emerging	Minoxidil first-line, early diagnosis, exclude other causes
FFA	Strong association with peri/postmenopausal status suggests hormonal/immune contribution.	None	Early recognition, potent TCS, intralesional steroids, 5α-reductase inhibitors
Lichen sclerosus	Strongly associated with low-estrogen states; vulval fragility and immune dysregulation. Can co-exist with genitourinary syndrome of menopause (GSM)	Not primary treatment	Ultrapotent TCS, long-term maintenance, treat GSM topical oestrogen or alternative.

Table 1 Current evidence and management tips for common skin conditions affected by menopause

Conclusions

Menopausal skin disease is common, clinically significant and frequently under-recognised. Dermatologists should proactively consider menopausal status in midlife women presenting with new-onset or deteriorating skin disease. This presentation outlines practical, evidence-informed approaches to optimise recognition and management of menopausal skin changes in clinical care.

EA DV CONGRESS
VIENNA
30 SEP - 3 OCT 2026

Abstract N°: 1191

Keloidal Scleroderma as a Diagnostic Challenge: Report of Two Cases

Maneeha Naveed*[1], Philip M. Laws[1]

[1] Leeds Teaching Hospital Trusts, Leeds, United Kingdom

Introduction

Keloidal or nodular scleroderma (KS) is a rare variant of scleroderma characterised by keloid like plaques or nodules. Diagnosis and treatment of this entity is often challenging due to heterogenous presentations and overlapping morphology with hypertrophic scars, keloids and other fibrosing dermatoses. We report two cases highlighting variable clinical morphology, histology and an inconsistent treatment response.

Case Presentation

Case 1

A 62-year-old white male with a background of Scl-70 positive systemic sclerosis presented with a 12-month history of indurated, firm, linear plaques over the anterior chest wall. Punch biopsy demonstrated features in keeping with a dermal scar and a diagnosis of KS. Topical clobetasol propionate was used, achieving limited success in flattening the lesions, with no further escalation in treatment as per patient preference.

Case 2

A 53-year-old black female with a 2-year history of systemic scleroderma (ANA and NOR 90 positive), presented with thickening of the upper chest associated with pain and increased sensitivity. Biopsy demonstrated increased fibroblast count, prominent collagen deposition in the reticular dermis; features compatible with a diagnosis of KS. Treatment trials included tacrolimus ointment, mometasone furoate, intralesional triamcinolone, hydrocortisone and extensive UVA1 phototherapy, with partial improvement. She remains under rheumatology for follow-up with a reported Rodnan Skin Score 0.

Conclusion

We present two cases of KS from a tertiary connective tissue disease service. Recent literature describes KS as keloid-like nodules or plaques, typically on the trunk, with a predominance in black middle-aged women. Both denied history of previous trauma at sites of lesions. Histology is frequently variable, often showing overlapping features of scar/keloidal fibrosis and sclerodermatous change rather than classical diagnostic findings. Our series is consistent with the reported truncal distribution, but highlights a broader morphological spectrum including indurated plaques, painful cutaneous thickening and papular lesions. In the two biopsied cases, histology was in keeping with features of KS, however wider literature suggests this is largely variable and reliance on biopsy alone may delay diagnosis and treatment. Furthermore, recent reports have also increasingly described skin-limited disease termed keloidal morphea, contrasting with older literature linking this entity more strongly to systemic sclerosis albeit our cases favour earlier findings. Therapeutic response in the literature is similarly inconsistent, with only partial or variable improvement with topical corticosteroids, topical immunomodulation, intralesional corticosteroid and UVA1 phototherapy. This case series highlights the diagnostic and therapeutic challenges of suspected KS. Greater awareness of its variable morphology, and appreciation of difficulty in differentiating between keloids histologically may support earlier recognition and more appropriate assessment and treatment.

EADV Congress 2026, VIENNA
30 SEPTEMBER - 03 OCTOBER 2026
POWERED BY M-ANAGE.COM

EA DV CONGRESS
VIENNA
30 SEP - 3 OCT 2026

Abstract N°: 1194

Breast Sarcoidosis as a Rare Case: Clinical Course and the Role of Dermatological Differential Diagnosis

İrem Aşkın Özçelik*[1], Ece Uğurer[1], Burçe Can Kuru[1]

[1] Sultan II Abdülhamid Han Training and Research Hospital, Dermatology Clinic, istanbul, Türkiye

Introduction

Sarcoidosis is a multisystem inflammatory disease characterized by non-caseating granulomas of unclear etiology. It is commonly associated with systemic symptoms such as fatigue, weight loss, and fever, as well as pulmonary symptoms including cough and dyspnea. Hilar and mediastinal lymph node involvement is observed in approximately 90% of cases. Rarely, asymptomatic cases with breast involvement have also been described. This group accounts for less than 1% of all sarcoidosis patients.

Granulomatous mastitis (GM) is a rare inflammatory disease of the breast. It may pose diagnostic challenges as it can clinically and radiologically mimic malignant breast lesions. GM can develop in association with infectious agents, autoimmune mechanisms, or systemic granulomatous diseases.

Here we present a 42-year-old female patient who was initially diagnosed with infectious granulomatous mastitis and was later directed to a diagnosis of sarcoidosis following a resistant clinical course and dermatological evaluation.

Case Presentation

A 42-year-old female nurse with no history of smoking, alcohol use, or comorbidities presented in September 2024 with pain, tenderness, and serous discharge in the right breast. Symptoms partially improved after amoxicillin-clavulanic acid therapy; however, a subcutaneous nodule persisted.
In November 2024, breast ultrasonography revealed a retroareolar, heterogeneously hypoechoic lesion measuring 16×18 mm at the 5–6 o'clock position. MRI demonstrated heterogeneous contrast enhancement. Although findings suggested granulomatous or inflammatory pathology, malignancy could not be excluded (BI-RADS 4), and histopathological evaluation was recommended. Histopathology showed fibrolipomatous tissue with chronic nonspecific inflammation and granulomatous structures.

Due to recurrence in May 2025 and lack of response to antibiotics, the patient was referred to dermatology. Examination revealed an erythematous, slightly livedoid plaque with fine scaling on the medial aspect of the right areola. The lesion was tender on palpation, and dermoscopy showed increased vascularization. A 4 mm punch biopsy was performed with differential diagnoses including GM, Paget's disease, and cutaneous metastasis.

Histopathological examination revealed suppurative granulomatous inflammation (Figure 1). Laboratory findings were: PPD negative, Hb 10.7 g/dL, MCV 72.1 fL, CRP 25.53 mg/L, ACE 72.8 U/L. Chest X-ray showed minimal fullness in the right hilar region. The patient was referred to pulmonology with a diagnosis of sarcoidosis.

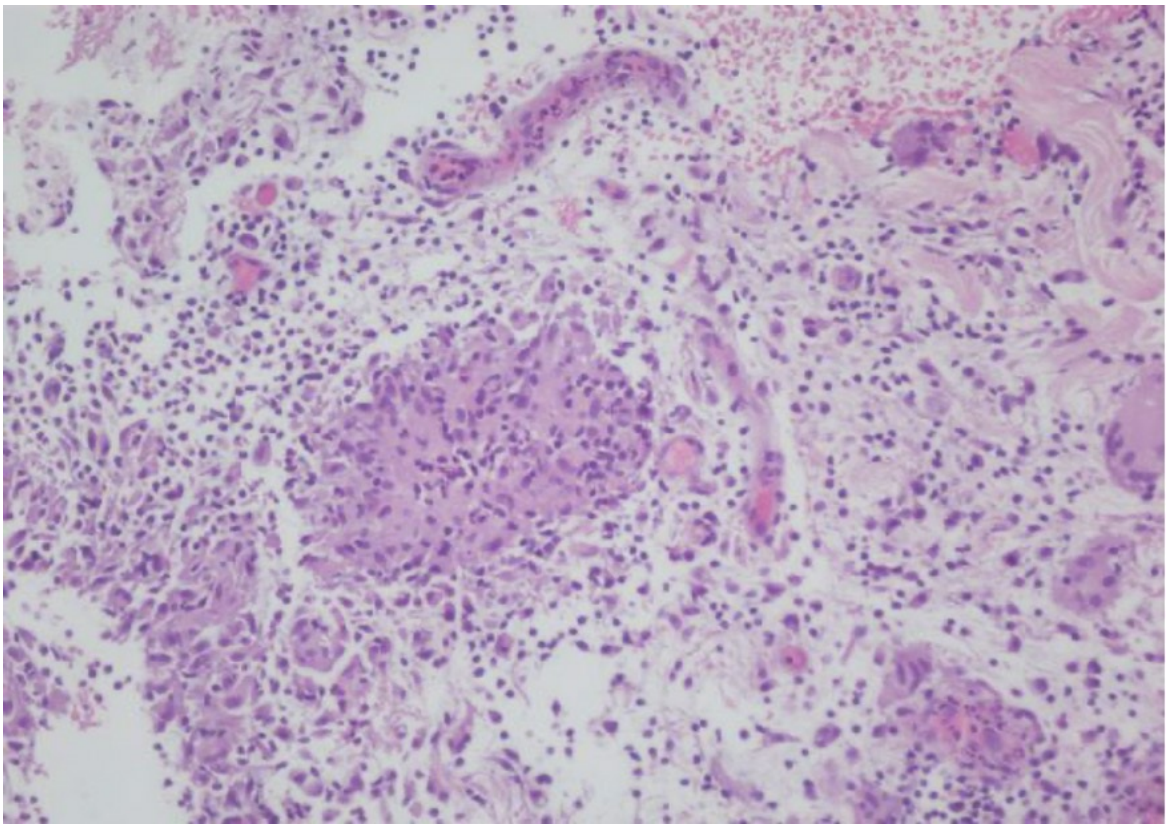

Suppurative granulomatous inflammation in the mid-dermis

Conclusion

This case represents a rare presentation of breast sarcoidosis manifesting as granulomatous mastitis, leading to symptoms such as breast swelling, pain, and a mass.

The diagnosis was established based on histopathological findings of non-caseating granulomatous inflammation and elevated serum ACE levels.

Sarcoidosis is often detected incidentally through hilar lymphadenopathy on chest radiography. Extrapulmonary involvement affects approximately 30% of patients, most commonly involving the skin, eyes, liver, and lymph nodes. Rarely, it may present with isolated breast involvement, which is clinically significant as it can mimic malignant breast diseases.

In this case, diagnosis was achieved through dermatological and histopathological evaluation of a treatment-resistant lesion, followed by systemic investigations. A negative PPD test helped exclude tuberculosis. Elevated serum ACE levels supported the diagnosis.

Although rare, sarcoidosis may present with breast involvement. Therefore, in cases where granulomatous inflammation is identified, sarcoidosis and other systemic granulomatous diseases should always be considered in the differential diagnosis.

EA DV CONGRESS
VIENNA
30 SEP - 3 OCT 2026

Abstract N°: 1206

GVHD post DRESS in Autologous Stem Cell Transplant

Yoo-Jeong Shin*[1], Renee Chan[2], Vera Miao[3], Janice Yeon[3], Linda Chan[3]

[1] Concord Repatriation General Hospital, Royal Prince Alfred Hospital, Sydney, Australia
[2] Concord Repatriation General Hospital, Sydney University Medical School, Sydney, Australia
[3] Concord Repatriation General Hospital, Sydney, Australia

Introduction

Drug rash with eosinophilia and systemic symptoms (DRESS) is a severe cutaneous adverse reaction (SCAR) with polymorphous cutaneous changes, facial oedema associated with fever, eosinophilia, lymphadenopathy and multiorgan involvement. Graft-versus-host-disease (GVHD) is a well-recognised complication of allogenic stem cell transplantation, involving the skin, driven by donor T cell recognition of recipients' allo-antigens. Autologous GVHD is a rarer, albeit clinically and histologically similar autoimmune syndrome observed in autologous Haematopoietic Stem Cell Transplant (HSCT). We report a novel case of DRESS and acute GVHD occurring consecutively in an autologous HSCT recipient.

Case Presentation

A 56-year-old female was hospitalised two months post autologous HSCT for multiple myeloma, with fever, generalised polymorphous skin eruption, facial oedema, liver enzyme derangement, thrombocytopaenia, eosinophilia (2.8 x 10^9/L). Skin biopsies from two body sites showed subtle interface dermatitis with superficial perivascular lymphocytic infiltrate and isolated eosinophils. Whilst not specific, the changes were compatible with DRESS. This was initially managed with oral prednisone 50mg daily and the most likely drug culprit-sulfamethoxazole/trimethoprim was ceased. Rash progression following prednisone taper prompted ciclosporin therapy, however, we were unable to wean her off prednisone without recurrence.

Ten months post-HSCT, she re-presented with perifollicular keratosis pilaris-like eruption, scarring scalp alopecia, LFT derangement and marked thrombocytopaenia in the 20s. She was trialled on higher-dose oral prednisone (50mg), intravenous immunoglobulin infusion, oral tacrolimus, pulsed methylprednisolone, and benralizumab, all without sustained clinical response. A repeat skin biopsy showed persistent interface dermatitis with apoptotic keratinocytes at all levels of the epidermis. Bone marrow biopsy showed no obvious cause for the thrombocytopaenia.

Given the prolonged and brittle disease course post ceasing the initial culprit drug, scarring alopecia and the skin biopsy results, patient was seen and confirmed to have autologous GVHD in a dedicated GVHD clinic. After commencing Janus Kinase Inhibitor (JAKi) ruxolitinib 5mg BD, while remaining on prednisone 50mg OD, she displayed brisk clinical and biochemical response. Ruxolitinib was uptitrated to 10mg BD and prednisone was slowly tapered to 7.5mg OD over three months. Topical betamethasone dipropionate 0.05% ointment and narrowband UVB phototherapy 3x weekly helped with ongoing pruritus.

Conclusion

We report a case of autologous GVHD following the clinical resolution of DRESS in an autologous HSCT recipient,

and discuss the possibility that immunopathogenic mechanisms of DRESS may predispose to the development of GVHD. We speculate that DRESS, and the associated functional depletion of regulatory T cells may predispose susceptible individuals to auto-GVHD. Recognition of this potential association is clinically important, and clinicians should consider the diagnosis when faced with similar presentations.

EADV CONGRESS
VIENNA
30 SEP - 3 OCT 2026

Abstract N°: 1222

Necrolytic Migratory Erythema as a Diagnostic Clue to Glucagonoma

Iker Narváez Gonzalo*[1], Iñigo Sánchez Benítez[1], Irene Arévalo Ortega[1], Mikel Meruelo Ruano[1], Ana Sánchez Díez[1], Rosa Izu Belloso[1]

[1] Dermatology Department. University Hospital Basurto, Bilbao, Spain

Introduction

Paraneoplastic dermatoses may precede the diagnosis of an underlying malignancy by months or even years, representing a valuable opportunity for early detection. Necrolytic migratory erythema (NME) is a well-recognized but rare entity within this group. Its low prevalence, heterogeneous clinical presentation, and lack of specificity for glucagonoma often make diagnosis challenging.

Case Presentation

A 34-year-old male with a history of childhood atopic dermatitis was referred from a private dermatology clinic for evaluation of chronic skin lesions with a six-year history. Physical examination revealed erythematous, erosive plaques with lamellar scaling, predominantly involving the acral areas of the lower extremities, with mild perineal and genital involvement. The patient denied systemic symptoms and reported stable body weight. He had previously been treated with topical and systemic corticosteroids, as well as cyclosporine, without clinical improvement. A prior skin biopsy was non-diagnostic, and laboratory evaluation revealed only a mild elevation in liver transaminase levels.

Based on the morphology, distribution, and treatment-refractory nature of the lesions, NME was suspected. Serum glucagon levels were markedly elevated (>1000 pg/mL), and imaging studies confirmed the presence of a glucagonoma without evidence of metastatic disease. The patient was initially treated with somatostatin analogues, followed by surgical resection, resulting in complete resolution of the cutaneous lesions. He remains disease-free at follow-up.

Conclusion

This case highlights the pivotal role of dermatologists in the recognition of cutaneous signs as potential markers of underlying systemic disease. Persistent or atypical dermatoses that are refractory to standard therapies should prompt a thorough reassessment and consideration of paraneoplastic syndromes. Early identification of these manifestations may lead to timely diagnosis of systemic conditions, including malignancies, with a significant impact on prognosis and the possibility of curative treatment.

EA DV CONGRESS
VIENNA
30 SEP - 3 OCT 2026

Abstract N°: 1232

Acquired pachydermatoglyphia (tripe palms) associated with bullous pemphigoid and mixed-type intraductal papillary mucinous neoplasm with high-risk stigmata: An inflammatory or paraneoplastic phenomenon?

Wei Sheng Chong*[1], Yong Jian Cheng[1], Shang-Ian Tee[1]

[1] National Skin Centre, Singapore, Singapore

Introduction

Tripe palms, also termed acquired pachydermatoglyphia, is a rare cutaneous paraneoplastic dermatosis characterised by diffuse velvety palmar hyperkeratosis with exaggerated dermatoglyphic ridges resembling bovine tripe. It is strongly associated with internal malignancy, although rare cases occurring in association with benign pruritic dermatoses have been reported. Here, we present a case of tripe palms arising in the context of bullous pemphigoid, with complete resolution following achievement of disease remission.

Case Presentation

An 80-year-old man with a history of recalcitrant bullous pemphigoid was electively admitted for intravenous rituximab. He initially presented with a blistering eruption 10 years prior and was diagnosed with bullous pemphigoid based on the clinical presentation, skin biopsy demonstrating a subepidermal blister, with positive BP180 serology and indirect immunofluorescence study. Despite multiple therapies, including doxycycline, azathioprine, mycophenolate mofetil, and dupilumab, he continued to have active disease requiring high-dose prednisolone.

Physical examination revealed scattered tense blisters, fresh and re-epithelialising erosions, and post-inflammatory hyperpigmentation over the trunk and limbs. The palms and soles had diffuse hyperkeratosis with velvety thickening and exaggerated dermatoglyphic patterns, producing a characteristic tripe-like appearance. The changes involved the entire palmar and plantar surfaces, with partial extension onto the distal dorsal surfaces.

Histopathological examination of the palmar skin showed marked compact hyperkeratosis, hypergranulosis, and psoriasiform hyperplasia, with a superficial perivascular infiltrate of lymphocytes and prominent eosinophils. Cross-sectional imaging with CT and MRI demonstrated a 5.9 cm tubulocystic lesion spanning the pancreatic head to body, consistent with a mixed-type intraductal papillary mucinous neoplasm with high-risk stigmata. The patient declined further invasive investigations or surgical intervention for the pancreatic lesion.

A clinical decision was made to proceed with intravenous rituximab, with gradual tapering of prednisolone dose. He subsequently achieved clinical remission of his bullous pemphigoid. At three-month follow-up, disease activity remained quiescent and, notably, his tripe palms had completely resolved with full restoration of normal palmar (and plantar) texture.

Conclusion

We report a rare case of tripe palms occurring in the context of bullous pemphigoid. Although an incidental pancreatic lesion was identified on imaging, the patient declined further evaluation, making definitive exclusion of malignancy challenging. Nevertheless, the temporal correlation between bullous pemphigoid remission and

complete resolution of tripe palms strongly implicates the inflammatory dermatosis as the underlying driver, supporting a causal relationship with the underlying inflammatory dermatosis rather than occult malignancy.

In conclusion, tripe palms should prompt thorough evaluation to exclude underlying malignancy. However, this case adds to the growing body of evidence that it is not exclusively a paraneoplastic phenomenon. In patients with bullous pemphigoid, tripe palms may represent a reversible phenomenon, resolving with disease control.

EA DV CONGRESS
VIENNA
30 SEP - 3 OCT 2026

Abstract N°: 1233

How Seborrheic Keratosis is Interrelated with Insulin Resistance, Metabolic Syndrome, and the IGF-1/IGFBP-3 axis: A Case-Control Study

Leyla Elmas*[1], Ozay Gököz[2], Okan Bulent Yildiz[3], Sibel Ersoy Evans[1]

[1] Hacettepe University, School of Medicine, Department of Dermatology and Venereology, Ankara, Türkiye

[2] Hacettepe University, School of Medicine, Department of Pathology, Ankara, Türkiye

[3] Hacettepe University, School of Medicine, Department of Internal Medicine, Division of Endocrinology and Metabolism, Ankara, Türkiye

Introduction

Seborrheic keratosis (SK) is the most common benign skin tumor; however, its pathogenesis remains unclear. Recent studies have suggested possible links between SK, metabolic factors, and growth factor signaling. We aimed to investigate insulin resistance, metabolic syndrome, and serum/tissue IGF-1 and IGFBP-3 levels and their correlation to the dermoscopic features in patients with SK.

Materials and Methods

This exploratory case–control study included 100 SK patients and 100 healthy controls. Patients aged ≥18 years with clinically, dermoscopically, and histopathologically confirmed SK were consecutively enrolled. Controls were age- and sex-matched individuals without any dermatologic complaint who voluntarily presented for full skin examination. All participants underwent physical and dermatological examination, anthropometric measurement, fasting glucose and insulin testing, and assessment of IGF-1 and IGFBP-3. HOMA-IR was calculated, and metabolic syndrome was defined according to NCEP ATP III and IDF criteria.

Results

SK patients showed significantly higher BMI, waist circumference, fasting insulin, and HOMA-IR values than controls ($P < 0.05$). Metabolic syndrome was more prevalent in the SK group (NCEP ATP III: 40% vs. 17%; IDF: 36% vs. 15%; $P < 0.001$). Serum IGFBP-3 levels were higher in SK patients, while IGF-1 levels did not differ significantly. IGF-1 staining was localized to the granular layer of lesional epidermis, whereas IGFBP-3 staining showed no difference between lesional and normal skin. In dermoscopic findings, negative correlations between hairpin vessels and fasting insulin level ($p=0.038$) and between fat fingers and fasting insulin level, FBS and HOMA-IR ($p<0.01$), between milium-like cysts and serum IGF-1 and IGFBP-3 levels ($p=0,033$ and $p=0,002$), and finally between the sharply demarcated borders and tissue IGF-1 expression ($p<0.01$) were found. A positive correlation was found between the total number of lesions and the serum IGF-1 level ($r=0.250$, $p=0.012$).

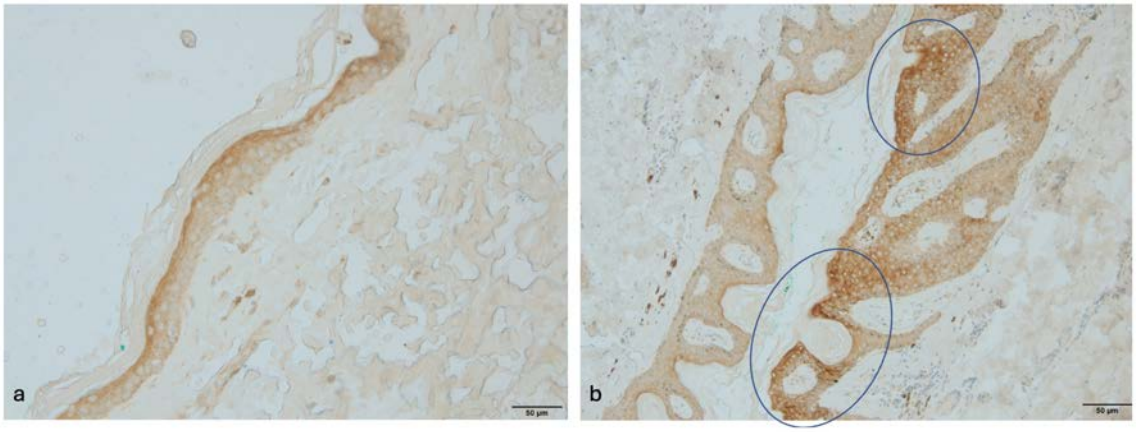

Staining for IGF-1 in the granular layer of adjacent normal skin without focal positivity (IGF-1, ×200). (b) Lesional area of seborrheic keratosis demonstrating focal IGF-1 positivity in two distinct regions (IGF-1, ×200).

Conclusions

Patients with SK are more likely to have insulin resistance and metabolic syndrome. Certain dermoscopic features may correlate with these metabolic abnormalities. IGF-1 and IGFBP-3 may play a role in SK pathogenesis, but larger, population-based studies are warranted.

EADV CONGRESS
VIENNA
30 SEP - 3 OCT 2026

Abstract N°: 1236

Primary Anetoderma as an Early Manifestation of Autoimmunity: Case Report and Literature Review

Eva Castillo-Castillo*[1], Elisa Ríos-Viñuela[1], Diego Meléndez-Sanz[1], Javier Torres-Marcos[1], Isabel Zapata-Martínez[1], Paloma Arribas-Granado[2], Adriana Martín-Fuentes[1], Esther de Eusebio-Murillo[1]

[1] Department of Dermatology, Hospital Universitario de Guadalajara, Guadalajara, Spain
[2] Department of Pathology, Hospital Universitario de Guadalajara, Guadalajara, Spain

Introduction

Primary anetoderma is a rare elastolytic disorder characterized by sac-like, skin-colored or bluish-white papules that herniate on palpation, reflecting a focal loss of dermal elastic fibers. These lesions typically arises on previously healthy skin in young women. While its etiopathogenesis remains poorly understood, it is frequently associated with autoimmune phenomena, particularly antiphospholipid antibodies and lupus erythematosus.

Case Presentation

We report a 26-year-old woman presenting with asymptomatic, well-circumscribed, atrophic papules on the trunk that arose on previously healthy skin. Histopathological analysis revealed significant rarefaction and fragmentation of elastic fibers in the mid-dermis, confirmed by selective elastic fiber staining, consistent with a diagnosis of primary anetoderma. Comprehensive laboratory investigations demonstrated significantly high antinuclear antibody (ANA) titers, anti-Ro (SSA)/anti-La (SSB) positivity, and elevated rheumatoid factor. At diagnosis, episodic parotitis was the sole concomitant extracutaneous manifestation. While the literature typically links anetoderma to antiphospholipid syndrome (either primary or secondary to lupus), our patient's anti-Ro/La profile is unusual. Rare precedents associate these antibodies with clinical manifestations meeting Sjögren's syndrome diagnostic criteria during follow-up, further reinforcing the role of primary anetoderma as a cutaneous marker within the broad spectrum of systemic autoimmune diseases.

Conclusion

This case underscores the clinical importance of a multidisciplinary approach and a comprehensive autoimmune panel at baseline. Given the potential for anetoderma to precede systemic disease, regular longitudinal follow-up is essential for the early detection of prothrombotic complications and evolving connective tissue diseases, such as Sjögren's syndrome or lupus erythematosus.

EADV CONGRESS
VIENNA
30 SEP - 3 OCT 2026

Abstract N°: 1239

Necrobiotic xanthogranuloma – a case report with non-invasive imaging findings and literature review on intravenous immunoglobulin (IVIG) therapy

Zuzanna Pawlus[1], Irena Wojtowicz[1], Adam Reich[1], Magdalena Zychowska*[1]

[1] Department of Dermatology; University of Rzeszow, Rzeszow, Poland

Introduction
Necrobiotic xanthogranuloma (NXG) is a rare, chronic non-Langerhans cell histiocytosis strongly associated with paraproteinemia and hematologic disorders. We present a clinical case of NXG, with particular emphasis on the dermoscopic and reflectance confocal microscopic (RCM) findings, and review the literature on the efficacy of intravenous immunoglobulin (IVIG) therapy in this condition.

Case Presentation
A 58-year-old woman presented with progressive yellow-orange plaques, showing irregular vessels and hemorrhagic dots on dermoscopy. RCM displayed multiple large refractive cells and smaller cells with horseshoe-like structures, corresponding to xanthomatous histiocytes and Touton multinucleated giant cells, respectively. Diagnostic evaluation revealed monoclonal IgG gammopathy and an indolent B-cell lymphoma. Long-term treatment with IVIG combined with systemic glucocorticosteroids resulted in partial improvement. A review of 16 published cases indicates that IVIG is one of the most effective therapeutic options for NXG, often leading to rapid and significant improvement or complete remission. However, treatment responses vary, and interruption of therapy may result in disease relapse, suggesting the importance of sustained treatment.

Conclusion
In conclusion, NXG is a multisystem disease showing several characteristics in non-invasive imaging methods. Although IVIG appears highly effective, variability in treatment response highlights the need for individualized management and for further research to better understand disease pathogenesis.

EADV CONGRESS
VIENNA
30 SEP - 3 OCT 2026

Abstract N°: 1259

Beyond the Surface: Occult Staphylococcus aureus Empyema presenting as Cutaneous Small-vessel Vasculitis

Sirag Elaribi*[1], Sara Ibzea[1], Aleef Al-Amin[1], Aebel Joseph[1], Nazia Farah[1], Farlin Asharaff[1], Charles Cathcart[1], Ying Teo[1], Caroline Murray[1], Moutasim Karwan[1], Michael Ardern-Jones[1, 2], Keith Godfrey[1]

[1] University Hospital Southampton NHS Foundation Trust, Southampton, United Kingdom
[2] Clinical Experimental Sciences, Faculty of Medicine, University of Southampton, Southampton, United Kingdom

Introduction

Cutaneous small-vessel vasculitis (CSVV) is the most common form of vasculitis affecting the skin, characterised by inflammation of postcapillary venules. It may arise from direct endothelial injury caused by infectious agents or, more commonly, through immune-mediated mechanisms such as circulating immune complex deposition and complement activation. While many cases are idiopathic, identifying an underlying trigger—particularly infection—is crucial, as management and prognosis depend largely on treating the precipitating cause. Occult infections can pose a diagnostic challenge, especially in patients with multiple comorbidities, and may lead to delayed or inappropriate treatment if not recognised early.

Case Presentation

A 75-year-old man with significant comorbidities, including type 2 diabetes mellitus and end-stage renal disease, presented with a few-day history of fever and malaise. Initial assessment suggested sepsis of unknown origin, supported by elevated inflammatory markers. His recent history was notable for a persistent right-sided pleural effusion following community-acquired pneumonia. Three days into admission, he developed a widespread cutaneous eruption characterised by tender, palpable, non-blanching purpura affecting all four limbs, with areas of necrotic ulceration. These clinical features were consistent with small-vessel vasculitis. A vasculitic screen was unremarkable, and repeated blood cultures remained negative. Histopathological examination of a skin biopsy demonstrated a superficial perivascular neutrophilic infiltrate with endothelial swelling, in keeping with small-vessel vasculitis. Microbiological stains did not identify any organisms. Despite empirical treatment with broad-spectrum intravenous antibiotics, including piperacillin–tazobactam and vancomycin, the patient's condition deteriorated. Transthoracic echocardiography excluded infective endocarditis. Given the absence of a clear source of infection, further evaluation with positron emission tomography–computed tomography (PET-CT) was undertaken. This revealed intense metabolic activity within the right pleural space, raising suspicion of an underlying empyema. Subsequent pleural aspiration yielded frank pus, and cultures grew *Staphylococcus aureus*. Antibiotic therapy was tailored to flucloxacillin based on sensitivities, and a pleural drain was inserted. Following source control and targeted antimicrobial therapy, there was marked clinical improvement, with resolution of both systemic symptoms and the cutaneous vasculitis.

Conclusion

This case underscores the importance of maintaining a high index of suspicion for occult infection in patients presenting with small-vessel vasculitis of unclear aetiology, particularly in those with predisposing factors. Negative initial investigations, including blood cultures and vasculitic screens, do not exclude an infectious trigger. Advanced imaging modalities such as PET-CT can play a pivotal role in identifying hidden sources of infection

when conventional investigations are inconclusive. Prompt recognition and treatment of the underlying cause, alongside appropriate source control, are essential for achieving clinical resolution and improving patient outcomes.

EADV CONGRESS
VIENNA
30 SEP - 3 OCT 2026

Abstract N°: 1288

Follicular hyperkeratotic spicules as a cutaneous clue to multiple myeloma: a diagnostic challenge

Yunus Emre Ulusoy*[1], Kadir Kaya[1], Yavuz Selim Pilis[1], Vildan Manav[1], Cem Leblebici[2], Ayşe Esra Koku Aksu[1]

[1] Department of Dermatology, Istanbul Training and Research Hospital, University of Health Sciences, ISTANBUL, Türkiye
[2] Department of Pathology, Istanbul Training and Research Hospital, University of Health Sciences, ISTANBUL, Türkiye

Introduction

Follicular hyperkeratotic spicules (FHS) are a rare and distinctive dermatosis most commonly reported in association with monoclonal gammopathies, particularly multiple myeloma (MM). Because of their unusual appearance and resemblance to more common facial dermatoses, diagnosis may be delayed.

Case Presentation

A 61-year-old man presented with a 1.5-year history of asymptomatic, stiff, spiny facial projections. Dermatological examination revealed widespread follicular, yellowish, hyperkeratotic, filiform, firm papules on the face, scalp, and periauricular areas, with marked accentuation on the nose and ears; some lesions were covered by hemorrhagic crusts. He had previously received multiple topical and systemic therapies, including antiparasitic, anti-inflammatory, and retinoid agents, for presumed demodicosis, rosacea, and contact dermatitis, with only partial and transient improvement. Dermoscopy revealed fine telangiectatic vessels on a pink-yellow background and perifollicular homogeneous yellowish structureless areas partially obliterating the follicular openings. Standardized skin surface biopsy revealed aDemodex density below the diagnostic threshold. Laboratory investigations showed anemia, thrombocytosis, hyperproteinemia, elevated IgG, and reduced IgM levels. Histopathological examination of a punch biopsy demonstrated a keratinization disorder involving the follicular infundibulum with dyskeratotic changes and intracytoplasmic eosinophilic inclusions, consistent with FHS. Serum immunofixation electrophoresis detected an IgG-kappa monoclonal band, and bone marrow biopsy demonstrated 60–70% neoplastic plasma cells; the diagnosis of MM was subsequently established by the hematology department. Following initiation of MM treatment, both the skin lesions and migratory bone pain began to regress within one week and had completely resolved after one month.

Conclusion

This case highlights that FHS may be an important cutaneous clue to an underlying monoclonal gammopathy, including MM. In patients presenting with treatment-resistant or atypical spiny follicular facial lesions, particularly with nasal predominance, clinicopathological correlation and hematological evaluation should be considered.

EADV CONGRESS
VIENNA
30 SEP - 3 OCT 2026

Abstract N°: 1290

Microblading-associated eyebrow sarcoidosis with asymptomatic pulmonary involvement: a case report

Esra Genç*[1], Bilge Coşkun[1], Mehtap Toprak[2], Burçe Can Kuru[1]

[1] Department of Dermatology, Sultan 2nd Abdulhamid Han Training and Research Hospital, University of Health Sciences, İstanbul, Türkiye

[2] Department of Pathology, Sultan 2nd Abdulhamid Han Training and Research Hospital, University of Health Sciences, İstanbul, Türkiye

Introduction

Sarcoidosis is a non-caseating granulomatous disease that can involve multiple organs, including the lungs, heart, eyes, and skin. Cutaneous manifestations occur in approximately 25% of patients. Granulomatous reactions may develop in association with permanent tattoos, microblading, and local skin injury. We present a case of scar sarcoidosis developing on the eyebrows after microblading, accompanied by pulmonary involvement.

Case Presentation

A 37-year-old woman presented with a 4-month history of raised lesions on both eyebrows at the sites of microblading performed 1 year earlier. She had no known medical conditions and was not taking any medication. Physical examination revealed pink-orange erythematous plaques with a papillomatous surface on the medial and lateral aspects of both eyebrows. A punch biopsy was performed with a differential diagnosis of trauma-induced xanthogranuloma and sarcoidosis. Histopathological examination revealed non-caseating granulomatous inflammation with multinucleated giant cells together with pigment-laden macrophages in the dermis. The epidermis was unremarkable. Routine blood and urine tests, serum calcium, liver function tests, renal function tests, and ECG were normal. The serum angiotensin-converting enzyme level was 75 U/L. Chest X-ray and computed tomography demonstrated bilateral hilar lymphadenopathy, faint ground-glass opacities in both lower lobes, and interlobular septal thickening. The patient had no pulmonary symptoms. She was referred to a pulmonologist for further evaluation, and endobronchial ultrasonography was planned. Topical clobetasol propionate was applied to both eyebrows for 1 month. Partial regression of the erythematous plaques was observed after treatment.

Conclusion

This case highlights the importance of dermatologists in recognizing cutaneous findings that may lead to the diagnosis of systemic sarcoidosis. Granulomatous lesions developing after tattooing or microblading are clinically significant because they may represent not only a localized foreign body reaction but also the first visible sign of systemic sarcoidosis and require further systemic evaluation.

EA DV CONGRESS
VIENNA
30 SEP - 3 OCT 2026

Abstract N°: 1314

Neutrophilic Alarm: Cutaneous Pyoderma Gangrenosum and Occult Neoplasia

Majd Abu Taleb*[1], Nesrine Ben Salah[1], Youssef Monia[1], Lobna Saad[2], Samiha Mabrouk[3], Seif Ben Hammouda[3], Hichem Belhadjali[1], Chawki Loussaief[2], Jameleddine Zili[1]

[1] Dermatology Department, Fattouma Bourguiba University Hospital, Monastir, Tunisia
[2] Infectious Diseases Department, Fattouma Bourguiba University Hospital, Monastir, Tunisia
[3] Anatomopathology Department, Fattouma Bourguiba University Hospital, Monastir, Tunisia

Introduction
Pyoderma gangrenosum (PG) is a rare neutrophilic dermatosis characterized by rapidly progressive ulcerative lesions and frequent associations with systemic diseases. Although it is classically linked to inflammatory bowel disease and inflammatory rheumatologic disorders, PG may also occur in association with hematologic malignancies and, less commonly, solid tumors. Atypical localizations represent a diagnostic challenge and may delay appropriate management. The aim of this study was to describe the clinico-epidemiological characteristics of PG in our department and to analyze its associations with systemic and neoplastic diseases.

Materials and Methods
We conducted a retrospective descriptive study over an 11-year period (2016–2026), including all patients with clinically and histologically confirmed PG.

Results
Fifteen patients were included, with a mean age of 38.6 years and a male-to-female ratio of 1.14 (8 men, 7 women). Ten patients (66.7%) had an associated systemic disease: inflammatory bowel disease in 3 cases (20%), inflammatory rheumatologic disorders in 2 cases (13.3%), and breast cancer in 2 patients (13.3%). In the latter cases, PG occurred in an evolving oncologic context, raising the possibility of a paraneoplastic mechanism. Typical lesions were observed in 11 patients (73.3%), characterized by rapidly progressive, painful ulcerations predominantly affecting the lower limbs; a central necrotic appearance was noted in one case. Four patients (26.7%) presented with atypical localizations (face, breast, perianal region, upper eyelid), initially misdiagnosed as infectious processes-particularly ecthyma gangrenosum-and unsuccessfully treated with intravenous antibiotics. Histopathological examination ultimately confirmed the diagnosis. A moderate biological inflammatory syndrome accompanied these atypical presentations. Treatment primarily consisted of systemic corticosteroid therapy (33.3%) combined with local wound care, with overall favorable outcomes.

Conclusions
Pyoderma gangrenosum (PG) exhibits profound clinical heterogeneity and serves as a critical cutaneous marker of underlying systemic disease, identified in two-thirds of our cohort. While inflammatory bowel disease and rheumatologic conditions represent classical associations, the occurrence of breast cancer in two patients highlights an underrecognized link with solid tumors potentially reflecting paraneoplastic phenomena or tumor-driven immune dysregulation. This observation expands the oncologic spectrum associated with PG beyond the more frequently

reported hematologic malignancies. Compounding diagnostic complexity, 26.7% of cases presented with atypical localizations, significantly increasing the risk of misdiagnosis and inappropriate therapeutic interventions. These findings mandate heightened clinical vigilance: dermatologists must systematically evaluate for occult systemic disease-including solid tumors-in patients with PG, particularly when presentations deviate from classic morphologies or distributions. Early integration of multidisciplinary assessment not only prevents diagnostic delay but also enables targeted management of both cutaneous and systemic components. Ultimately, recognizing PG as a potential paraneoplastic indicator positions dermatology at the forefront of early cancer detection and immune-mediated disease coordination, with direct implications for improving diagnostic algorithms and therapeutic precision in complex inflammatory dermatoses.

EA DV CONGRESS
VIENNA
30 SEP - 3 OCT 2026

Abstract N°: 1329

A Systematic Review and Meta-Analysis of Common Skin Manifestations Associated with COVID-19 Infection

Iqra Khawaja*[1], Nauman Khan[1], Sarvjit Sahedra[2]

[1] Northampton General Hospital NHS Trust, Northampton, United Kingdom
[2] University Hospitals of Leicester NHS Trust, Leicester, United Kingdom

Introduction

Coronavirus disease 2019 (COVID-19) is a multisystem disorder caused by Severe Acute Respiratory Syndrome Coronavirus 2 (SARS-CoV-2), which primarily causes respiratory symptoms. However, there have been reports of various cutaneous manifestations that may serve as early or isolated indicators of infection. Their prevalence, clinical significance, duration, and associated mortality rates from disease remain incompletely understood.

Objectives

To evaluate the prevalence of common skin manifestations in COVID-19 infection, assess their temporal relationship to the disease, and explore associations with disease severity and mortality.

Materials and Methods

A literature search was conducted in PubMed using the keywords “COVID-19,” “SARS-CoV-2,” “cutaneous manifestations,” and “rash.” The inclusion criteria were studies published within the last five years that involved adult populations. Publications focusing on paediatric cohorts or vaccine-related dermatological findings were excluded. Eligible studies included case reports, observational studies, cohort studies, and systematic reviews that reported the prevalence, patterns, duration, and outcomes of cutaneous manifestations. Subsequently, data were extracted and synthesised qualitatively and quantitatively.

Results

Twelve studies were included, encompassing over 350,000 patients. Cutaneous manifestations were reported in approximately 3.9% to 20% of COVID-19 patients, and a prevalence of around 8.8–9% in large population-based data. Maculopapular or morbilliform eruptions were the most common (16–47%), followed by urticarial lesions (4–19%), acral chilblain-like lesions (up to 39%), vesicular or varicella-like eruptions (11–18%), and livedoid or necrotic lesions (0.6–6%).

A significant association was demonstrated between cutaneous manifestations and COVID-19 infection, with an odds ratio of 1.67. Interestingly, we found that cutaneous signs preceded other symptoms in up to 17% of cases and were the sole manifestation in approximately 21%. This highlights their diagnostic value in detecting COVID-19 early.

The duration of each rash varied by morphology. Urticarial lesions were short-lived (mean 4–7 days), maculopapular eruptions lasted approximately 7–14 days, and acral lesions persisted for 10–30 days. Most lesions were self-limiting, with over 50% resolving within one month.

Notably, livedoid and necrotic lesions were associated with more severe disease and complications, whereas

chilblain-like lesions were present in milder disease or in cases with negative PCR testing. Overall, mortality was not significantly increased in patients with cutaneous manifestations, although some studies showed that livedoid lesions and severe varicella-like eruptions were linked to adverse outcomes.

Conclusions

Dermatological manifestations are clinically relevant features of COVID-19 and exhibit significant heterogeneity in presentation and timing. Certain lesions, especially maculopapular and urticarial rashes, are most prevalent, while vascular lesions indicate more severe disease. It is important to note that skin manifestations can precede or occur independently of classical COVID-19 symptoms, highlighting their potential as early diagnostic markers to help prevent complications. Recognition of these patterns can provide insight into disease severity and identify the need for further treatment. Further large-scale studies are required to understand the underlying pathophysiology and to investigate the implications of vascular lesions and varicella-like eruptions in COVID-19, as these manifestations have been associated with more severe disease and adverse clinical outcomes.

EA DV CONGRESS
VIENNA
30 SEP - 3 OCT 2026

Abstract N°: 1345

Efficacy of Baricitinib in Adolescent Patients with Severe Alopecia Areata and Comorbid Atopic Dermatitis or Broader Atopic Background at 52 Weeks

Bianca Maria Piraccini*[1], OHSANG KWON[2], Benjamin Lockshin[3], Lara Wine Lee[4], Matthew Zirwas[5], Marni Wiseman[6], Yves Dutronc[7], Angelina Sontag[7], Tuhina Das[8], Yutaka Shimomura[9]

[1] Private Dermatology Practice, Bologna, Italy
[2] Seoul National University College of Medicine, Seoul, Korea, Rep. of South
[3] DermAssociates, Rockville, Maryland, United States
[4] Medical University of South Carolina, Charleston, South Carolina, USA, Charleston, South Carolina, United States
[5] Bexley Dermatology Research Clinic, Bexley, Ohio, United States
[6] SKiNWISE Dermatology, University of Manitoba, Manitoba, Canada
[7] Eli Lilly and Company, Indianapolis, Indiana, United States
[8] Eli Lilly and Company, Indianapolis, United States
[9] Yamaguchi University, Yamaguchi, Japan

Introduction

Baricitinib (BARI), an oral, selective, Janus kinase inhibitor, is approved in many countries to treat severe alopecia areata (AA) in adults and moderate-to-severe atopic dermatitis (AD) in patients aged ≥2 years. Outcomes through week 52 in the phase 3 BRAVE-AA-PEDS trial (NCT05723198) showed that once-daily BARI 2mg or 4mg is also effective in adolescents (aged 12–17 years) with severe or very severe AA (hereafter referred to as severe AA).

Materials and Methods

Post hoc analyses were conducted to assess the efficacy of BARI for severe AA in adolescents with comorbid AD or a broader atopic background (AB), as these patients tend to have more severe AA and more systematic inflammation.

The analysis included two BRAVE-AA-PEDS cohorts of adolescents with severe AA for ≥1 year, current AA episode duration ≥6 months, Severity of Alopecia Tool (SALT) score ≥50, and failure of ≥1 prior treatment. Cohort 1 patients (N=257) were randomised 1:1:1 to BARI 2mg, BARI 4mg, or placebo; cohort 2 patients (N=166) were randomised 1:1 to BARI 2mg or 4mg. Patients randomised to BARI continued their assigned treatment through week 52. Data from patients randomised to BARI were pooled by dose level. Patients randomised to placebo were omitted from analyses because placebo nonresponders had been re-randomised to BARI 2mg or 4mg at week 36.

Week 52 efficacy was assessed in adolescents with comorbid AD, those with broader AB (historic or comorbid AD, allergic rhinitis, allergic asthma, or allergic conjunctivitis), and the overall sample of adolescents. Endpoints included achievement of SALT score thresholds (≤20, ≤10, =0), and clinician-reported outcome (ClinRO) eyebrow (EB) or eyelash (EL) hair loss scores of 0 or 1 with ≥2-point improvement from baseline.

Results

Analyses included 335 adolescents (120 with AB and a subset of 73 with AD; Table 1). Baseline demographics in atopic subgroups were comparable to those in the overall sample, except that AD and AB subgroups had higher proportions of Asian or Black/African American adolescents than the overall treatment groups. At baseline, slightly

higher proportions of patients in atopic subgroups than in overall groups had very severe AA (SALT score 95–100) and ClinRO EB or EL scores 2 or 3, confirming a trend for higher AA disease severity in atopic subgroups. Baseline Skindex-16 AA domain scores also indicated greater impacts on quality of life in atopic subgroups. About 65% of patients in atopic subgroups had immunoglobulin E levels ≥200, whereas such levels were observed in <50% of patients in the overall groups.

At week 52, SALT ≤20 was achieved in 51% of patients with AB on BARI 4mg and in 38% on BARI 2mg, similar to the response rates and dose-response pattern in the overall groups. In patients with AD, SALT ≤20 response rates were 45% with BARI 4mg and 49% with BARI 2mg, indicating similar efficacy across dose levels. These response patterns for SALT ≤20 were generally consistent for SALT ≤10, SALT=0, ClinRO EB, and ClinRO EL, except that EL responses with BARI 2mg were substantially higher in both atopic subgroups than in overall groups.

These findings show that BARI provides robust hair regrowth in adolescents with severe AA and comorbid AD or broader AB. Patients with AB had similar scalp and EB response rates to those in the overall adolescent sample, with BARI 4mg associated with substantially better rates than 2mg. Interestingly, response patterns in patients with AD were slightly different: efficacy was comparable across 2mg and 4mg doses for scalp, EB, and EL regrowth. Because of the small sample size of the AD subgroup, these results should be interpreted with caution. The trend of comparable efficacy across doses had not been observed in adult AA patients with comorbid AD.

Table 1. Baseline Characteristics and Week 52 Efficacy Outcomes in Adolescents with Severe AA

	With Atopic Background [a]		With Atopic Dermatitis [b]		Overall	
	BARI 2mg (N=55)	BARI 4mg (N=65)	BARI 2mg (N=35)	BARI 4mg (N=38)	BARI 2mg (N=167)	BARI 4mg (N=168)
Baseline characteristics						
Age in years, Mean (SD)	14.3 (1.8)	14.6 (1.7)	13.9 (1.6)	14.5 (1.6)	14.6 (1.7)	14.5 (1.7)
Female, %	45.5	47.7	54.3	50.0	50.9	50.0
Race, %						
Asian	32.7	35.4	40.0	39.5	23.4	25.6
Black/African American	7.3	12.3	11.4	10.5	6.6	6.5
White	52.7	50.8	37.1	47.4	64.1	66.7
AA duration in years, Mean (SD)	6.0 (4.0)	6.0 (3.7)	5.9 (4.0)	6.2 (3.7)	6.6 (4.0)	6.1 (3.8)
Current episode duration in years, Mean (SD)	2.8 (1.7)	3.1 (2.1)	3.0 (1.8)	3.3 (2.1)	3.1 (2.0)	3.2 (2.1)
Prior systemic therapy, %	50.9	60.0	42.9	73.7	45.5	48.2
Immunoglobulin E ≥200, %	61.8	63.1	65.7	65.8	46.1	44.6
Skindex-16 AA domain score, Mean (SD)						
Symptoms	13.0 (16.1)	16.1 (15.8)	15.1 (14.9)	18.1 (16.0)	11.6 (14.1)	13.4 (13.8)
Emotions	44.7 (31.3)	53.5 (31.1)	40.5 (26.5)	57.9 (30.3)	46.3 (29.8)	41.2 (30.5)
Functioning	22.9 (28.7)	27.5 (27.5)	21.5 (26.7)	26.9 (28.6)	25.9 (26.3)	20.7 (25.5)
SALT score						
Mean (SD)	86.7 (18.4)	88.6 (17.3)	88.1 (18.0)	87.5 (17.6)	86.8 (17.7)	85.9 (18.0)
Very severe (95–100), %	60.0	67.7	62.9	63.2	57.5	56.5
ClinRO EB 2–3, % [c]	67.3	66.2	71.4	57.9	58.1	59.5
ClinRO EL 2–3, % [c]	63.6	60.0	65.7	57.9	52.7	50.0
Week 52 efficacy [d]						
SALT score <20, %	38.2	50.8	48.6	44.7	36.5	57.1
SALT score <10, %	30.9	38.5	37.1	34.2	28.7	45.2
SALT score =0, %	16.4	18.5	17.1	15.8	10.8	25.6
ClinRO EB response, % [e]	37.8 (N=37)	58.1 (N=43)	44.0 (N=25)	45.5 (N=22)	33.0 (N=97)	63.0 (N=100)
ClinRO EL response, % [e]	51.4 (N=35)	61.5 (N=39)	56.5 (N=23)	59.1 (N=22)	39.8 (N=88)	63.1 (N=84)

Abbreviations: AA, alopecia areata; BARI, baricitinib; ClinRO EB, clinician-reported outcome eyebrow hair loss; ClinRO EL, clinician-reported outcome eyelash hair loss; SALT, Severity of Alopecia Tool; SD, standard deviation.

[a] Patients with atopic background included patients in the comorbid atopic dermatitis subset, as well as patients with historic atopic dermatitis or historic or comorbid allergic rhinitis, allergic asthma, or allergic conjunctivitis.

[b] Patients with comorbid atopic dermatitis. These patients were also included in the atopic background subgroup.

[c] ClinRO EB (EL) Scores range from 0–3, with 0 reflecting no eyebrow (eyelash) hair loss, 1 reflecting minimal gaps and even distribution (spacing) of eyebrow hair (eyelashes), 2 reflecting significant gaps or uneven distribution (spacing) of eyebrow hair (eyelashes), and 3 reflecting no notable eyebrow hair (eyelashes).

[d] Calculated using non-responder imputation.

[e] Response was defined as week 52 score of 0–1 with ≥2-point improvement from baseline. N reflects the number of patients in the analysis population among patients with a score of ≥2 at baseline. Proportions with response are calculated using N as the denominator.

Conclusions

Overall, efficacy of BARI in subgroups of adolescents with severe AA and comorbid AD or broader AB was comparable to that observed in the overall adolescent sample, despite the slightly higher baseline AA severity in atopic subgroups.

EADV CONGRESS
VIENNA
30 SEP - 3 OCT 2026

Abstract N°: 1353

Identification of clinical phenotypes with distinct disease course and therapeutic response within the eosinophilic fasciitis–deep morphoea spectrum

Nuria Gonzalvo-Bassets*[1], Sara Clota-Albana[1], Guillermo Pérez-Limousin[1], Ivette Casafont-Solé[1], Isabel Bielsa[1]

[1] Germans Trias i Pujol University Hospital, Badalona, Spain

Introduction

Eosinophilic fasciitis (EF) and deep morphoea (DM) are rare inflammatory and sclerosing disorders involving the skin and soft tissues. Whether they represent two distinct diseases or different phenotypes within a single clinical spectrum remains a matter of debate, given their clinical, histological and laboratory overlap. Nevertheless, certain patterns of clinical presentation may be associated with a poorer disease course and therapeutic response, such as trunk involvement or the presence of more superficial lesions indicating dermal involvement in the fibrotic process, irrespective of the anatomic location.

Materials and Methods

A retrospective descriptive study was conducted including cases diagnosed with EF or DM from the Dermatology and Rheumatology databases. The cases were classified into two groups according to baseline clinical presentation:

- E–D group: exclusive involvement of the extremities and deep tissues (hypodermis and/or fascia and/or superficial muscle).

- T–S group: trunk involvement and/or skin involvement presenting as ivory-coloured plaques or hyperpigmentation, regardless of the presence or absence of involvement of extremities and deeper tissues.

A comparative analysis of the demographic, clinical, therapeutic and outcome data from the resulting groups was performed. P-value <0.05 was considered statistically significant and results were interpreted in an exploratory manner.

Results

Twenty-five cases were included: 13 initially diagnosed with EF and 12 with DM. Based on the new classification, the E–D group consisted of 11 cases and the T–S of 14. All E–D cases had been previously diagnosed with EF. No differences were observed regarding age and sex distribution, nor the presence of potential triggering factors such as infections, malignancies or trauma (Table 1).

Oedema was more frequently observed in E–D compared with T–S (100% vs 42.9% respectively; p = 0.006). The E-D group also showed higher rates of fatigue (60% vs 21.4% in T-S) and myalgia (40% vs 35.7% in T-S), although these differences did not reach statistical significance (Table 2).

Regarding disease course, T–S showed higher rates for immunosuppressive treatment change or escalation compared with E–D (35.7% vs 0%; p = 0.046), as well as higher relapse rates (42.9% vs 9.1%), although the latter did not reach statistical significance. Complete remission was achieved in all E-D cases, compared with the 57.1% in T–S (p = 0.020).

Table 1. Demographic data and baseline characteristics of the cohorts

	E-D (n = 11)	T-S (n = 14)	p value
Age at diagnosis, median (IQR), years	51.5 [44.2–61.5]	61 [43.5–67]	0.703
Female sex, n (%)	5 (45.5)	9 (64.3)	0.435
Diagnosis			
Eosinophilic fasciitis, n (%)	**11 (100)**	2 (14.3)	***<0.001***
Deep morphoea, n (%)	0 (0)	**12 (85.7)**	
Same diagnosis at disease onset, n (%)	**11 (100)**	9 (64.3)	**0.046**
Follow-up exclusively by Dermatology, n (%)	0 (0)	3 (21.4)	
Follow-up exclusively by Rheumatology, n (%)	**5 (45.5)**	0 (0)	**0.010**
Joint follow-up, n (%)	6 (54.5)	11 (78.6)	

Table 2. Differential clinical features, disease course and treatment outcomes

	E-D (n = 11)	T-S (n = 14)	p value
Baseline involvement			
Trunk involvement, n (%)	0 (0)	8 (57.1)	0.006
Upper extremity involvement, n (%)	8 (80)	9 (64.3)	0.653
Lower extremity involvement, n (%)	9 (90)	12 (85.7)	1
Distribution of involvement and other disease features			
Residual pigmentation, n (%)	0 (0)	**9 (64.3)**	**0.001**
Ivory-coloured skin, n (%)	0 (0)	**9 (69.2)**	**0.002**
Muscle contracture, n (%)	0 (0)	4 (28.6)	0.105
Oedema, n (%)	**10 (100)**	6 (42.9)	**0.006**
Arthritis, n (%)	2 (18.2)	1 (7.1)	0.564
Fatigue, n (%)	6 (60)	3 (21.4)	0.092
Myalgia, n (%)	4 (40)	5 (35.7)	1
Disease course and treatment response			
Relapses, n (%)	1 (9.1)	6 (42.9)	0.09
Need for immunosuppressive treatment change or escalation, n (%)	0 (0)	**5 (35.7)**	**0.046**
Remission at last follow-up, n (%)	**11 (100)**	8 (57.1)	**0.020**

Table 1. Demographic data and baseline characteristics of the cohorts; Table 2. Differential clinical features, disease course and treatment outcomes

Conclusions

Classification of EF and DM cases according to baseline patterns of involvement identifies groups with distinct clinical characteristics and disease course. Trunk involvement and the presence of ivory-coloured skin areas and/or hyperpigmentation were associated with a more refractory disease course and a greater need for therapeutic modifications, whereas exclusive involvement of the extremities and deep tissues was associated with a higher frequency of remission. These findings should be interpreted with caution and be validated in prospective studies with larger sample sizes.

EADV CONGRESS
VIENNA
30 SEP - 3 OCT 2026

Abstract N°: 1371

Facial Discoid Dermatosis – Clinical Symptoms and Therapeutic Challenges Associated with a Rare Disease Entity

Paulina Rutecka-Wolak*[1], Grzegorz Dyduch[2], Alina Jankowska-Konsur[1]

[1] University Centre of General Dermatology and Oncodermatology, Wroclaw Medical University, Borowska 213, 50-556, Wrocław, Poland

[2] Department of Pathomorphology, Collegium Medicum, Jagiellonian University,, Kraków, Poland

Introduction

Facial discoid dermatosis (FDD) is a rare and likely underdiagnosed disorder characterized by sharply demarcated pink-orange facial plaques with a chronic, treatment-resistant course. Since its first description in 2010, only 43 cases have been reported. Clinically, FDD may mimic seborrhoeic dermatitis, rosacea, tinea faciei, or cutaneous lupus erythematosus. Histopathology is nonspecific and may resemble pityriasis rubra pilaris (PRP). Based on clinical and histological overlap and a reported case of progression to PRP, FDD has been proposed as a localized PRP variant. The aim of this report is to highlight diagnostic and therapeutic challenges associated with FDD.

Case Presentation

A 42-year-old woman presented with a four-year history of persistent, asymptomatic facial plaques. Examination showed sharply demarcated pink-orange lesions on the forehead, nose, and cheek, without extracutaneous involvement. Extensive differential diagnosis was performed. Seborrhoeic dermatitis and rosacea were excluded due to lack of response to topical corticosteroids, antifungals, calcineurin
inhibitors, antibiotics, and ivermectin. Cutaneous lupus erythematosus was ruled out based on clinical, immunological, and histopathological findings, and contact dermatitis by negative patch tests. Histopathology revealed a slightly atrophic epidermis with orthokeratosis, minimal spongiosis, dermal edema, and superficial lymphocytic infiltrate. FDD was diagnosed. Treatment with acitretin 20 mg daily was initiated, resulting in partial remission after three months. Acitretin appears to be the most effective reported therapy, possibly through modulation of keratinocyte differentiation and Th17-mediated inflammation. Successful use of biologics (ustekinumab, secukinumab) further supports a potential link to IL-23/Th17-driven dermatoses.

Conclusion

FDD is an underrecognized condition that should be considered in chronic, sharply demarcated, treatment-resistant facial plaques. Its nonspecific presentation frequently leads to misdiagnosis and ineffective treatment. Lack of response to standard therapies should prompt reconsideration of the diagnosis. A possible association with PRP and IL-23/Th17 pathways suggests relevant therapeutic implications.
Acitretin remains the most consistently effective treatment, while biologics may be an option in refractory cases. Increased awareness is crucial for early diagnosis and appropriate management.

EADV CONGRESS
VIENNA
30 SEP - 3 OCT 2026

Abstract N°: 1380

Cutaneous Lesions as the First Manifestation of Urothelial Carcinoma

Anita Ptak*[1], Agnieszka Hałoń[2], Joanna Maj[1], Alina Jankowska-Konsur[1]

[1] University Centre of General Dermatology and Oncodermatology, Wroclaw Medical University, Borowska 213, 50-556, Wroclaw, Poland

[2] Department of Clinical and Experimental Pathology, Wrocław Medical University, 50-556, Wroclaw, Poland

Introduction

Cutaneous metastases from genitourinary malignancies are rare, occurring in approximately 1–1.3% of patients with advanced disease. They most commonly originate from renal tumors and less frequently from malignancies of the bladder, prostate, or testes. Cutaneous involvement in urothelial carcinoma is exceptionally uncommon and typically reflects advanced disease. Its clinical presentation is often nonspecific and may closely mimic benign dermatological conditions, leading to diagnostic delays.The aim of this report is to present a case in which cutaneous lesions constituted the first manifestation of urothelial carcinoma and to highlight the associated diagnostic challenges. Definitive diagnosis relies on histopathological examination to confirm the malignant nature of the lesion, followed by imaging studies to identify the primary tumor site.

Case Presentation

A 91-year-old patient with no prior oncological history presented with an enlarging erythematous, infiltrative, and desquamative lesion involving the groin, lower abdomen, perineum, and thigh. The lesion developed over four months, initially appearing as a localized erythematous patch on the lower abdomen and progressively expanding. The course was initially asymptomatic; however, over time, the lesions progressed with the development of erosions and ulcerations. Due to the lesion's location and clinical appearance, a fungal etiology was initially suspected, but this was excluded based on negative mycological examination. Given the suspicion of a malignant neoplastic process, a punch biopsy was performed for histopathological evaluation. Further diagnostic work-up included computed tomography of the chest, abdomen, and pelvis, as well as Doppler ultrasound of the lower limbs; these did not reveal unequivocal abnormalities. Histopathological examination demonstrated diffuse infiltration of the dermis and subcutaneous tissue by malignant cells. Immunohistochemical analysis showed positivity for CK7, CK20, GATA3, and p63, along with a high Ki-67 proliferation index. These findings were consistent with cutaneous metastasis of urothelial carcinoma, most likely originating from the urinary bladder. Imaging studies revealed extensive edema and fluid accumulation within the soft tissues of the lower abdomen, perineum, penis, and scrotum, without identification of a clearly defined primary tumor.

Conclusion

This case illustrates that persistent, progressive, and treatment-resistant skin lesions may represent the initial manifestation of an underlying malignancy, including metastatic disease. The nonspecific clinical presentation may mimic common dermatoses, contributing to delayed diagnosis and inappropriate initial management. Skin biopsy with histopathological and immunohistochemical evaluation remains essential for establishing the diagnosis. Importantly, unremarkable imaging findings do not exclude metastatic disease. Early consideration of a neoplastic process in atypical, non-responsive cutaneous lesions is crucial for timely diagnosis and appropriate patient management.

EADV CONGRESS
VIENNA
30 SEP - 3 OCT 2026

Abstract N°: 1416

Florid Cutaneous And Mucosal Papillomatosis Associated with Colon Cancer: A Novel Association with Distinctive Syringometaplasia

My Kristoffersson*[1], Paula Kulinski[1], Jan Lapins[1, 2], Ismini Vassilaki[3]

[1] Karolinska University Hospital, Department of Dermatology and Venerology, Stockholm, Sweden
[2] Dermatology and Venerology Unit, Department of Medicine, Solna, Karolinska Institutet, Stockholm, Sweden
[3] Department of Clinical Pathology and Cancer Diagnostics, Karolinska University Hospital, Stockholm, Sweden

Introduction

Paraneoplastic dermatological manifestations can precede, coincide with, or follow the diagnosis of internal malignancies. These manifestations may include changes in the skin, hair, nails and mucosa and may develop due to tumour-produced growth factors, mainly EGF and TGF-a. Florid cutaneous and mucosal papillomatosis is a rare sign of internal malignancy and is associated with adenocarcinomas, the majority of which are gastric, followed by lung and gynecological cancers, however, it has not yet been described in colon cancer.

Case Presentation

A 90-year-old man with chronic renal failure and a history of urothelial carcinoma in situ presented with 8 months of weight loss and progressive eruption of the skin and mucosal membranes. Clinical findings included distinct pachydermatous cerebriform skinfoldings, rugose papillomatosis of the tongue and oral mucosa and extensive papillomas of the eyelid margins. Additional findings included diffuse alopecia, onychodystrophy, nipple hyperkeratosis and perianal verrucous changes.

Skin biopsies showed a variable acanthotic and verrucous epidermal hyperplasia and previously undescribed consistent syringometaplasia pattern with multifocal lobular clusters centered on the acrosyringeal ducts, and diffuse transition into the surrounding epidermis. Eyelid biopsies showed conjunctival papillomatosis.

CT scan did not show any signs of malignancy, but due to a strong clinical suspicion of a paraneoplastic process, further investigation was undertaken and confirmed elevated tumour markers for colorectal cancer. Colonoscopy revealed a tumour in the proximal ascending colon. After hemicolectomy the cutaneous and mucosal changes resolved gradually over the subsequent months.

Conclusion

A thorough dermatologic examination and appropriate systemic investigation lead to the diagnosis of ascending colon adenocarcinoma. This case illustrates how recognition of paramalignant signs is essential for early cancer detection. To our knowledge, this is the first reported case of florid cutaneous and mucosal papillomatosis associated with colon cancer. As far as we know, the acrosyringeal histopathological pattern has not previously been reported and warrants further investigation.

EADV CONGRESS
VIENNA
30 SEP - 3 OCT 2026

Abstract N°: 1426

Scleredema of Buschke in Diabetes: Recognizing Subtle Skin Changes Beyond Dermatology

Bruna Marques Bilia*[1], Hudson Rezende[1], João Henrique Aurich[1], Letícia Ferreira de Hybi Cerqueira[2], Nara Cristina Tasso Almeida Carvalho[3]

[1] Centro Universitário Lusíada (UNILUS), Santos, Brazil

[2] Centro Universitário CESMAC, Maceió, Brazil

[3] Centro Universitário de Araraquara (UNIARA), Araraquara, Brazil

Introduction

Scleredema of Buschke is an uncommon disorder characterized by progressive, non-pitting induration of the skin, most often affecting the upper trunk and neck. Although rare, its association with long-standing diabetes mellitus is well established. In practice, however, the condition is frequently overlooked, particularly when cutaneous findings are insidious and overshadowed by systemic complaints.

Case Presentation

Persistent pruritus of the trunk, initially interpreted as a nonspecific symptom, led to dermatologic evaluation in a 63-year-old man with a nine-year history of insulin-treated type 2 diabetes. What emerged on examination was not simply xerosis or diabetic pruritus, but a diffuse and firm induration involving the upper back, neck, and shoulders, with noticeable restriction of upper limb mobility. Facial involvement was also present, although subtle enough to have gone unrecognized by the patient. He was obese, with otherwise stable clinical status and no additional complaints. A skin biopsy obtained from the upper back confirmed the diagnosis of scleredema. While the degree of skin thickening remained relatively unchanged over time, optimization of glycemic control, along with supportive measures such as skin hydration, resulted in meaningful improvement of pruritus.

Conclusion

This case highlights how scleredema may remain undiagnosed when its cutaneous features are gradual and clinically underestimated. In patients with diabetes. Particularly those with long-standing disease skin induration should not be overlooked or attributed solely to metabolic factors. Given that these patients are often followed more closely by endocrinologists than dermatologists, early recognition depends on a broader clinical perspective. Awareness of this entity across specialties may facilitate earlier diagnosis and more comprehensive care

EA DV CONGRESS
VIENNA
30 SEP - 3 OCT 2026

Abstract N°: 1436

Fatal Papular Neutrophilic Xanthoma: Beyond a Benign Cutaneous Entity

Xinyu Yao*[1]

[1] Peking University First Hospital & Peking University First Hospital Taiyuan, Taiyuan, China

Introduction

Papular neutrophilic xanthoma(PNX) is a rare non-Langerhans cell histiocytosis typically presenting as limited cutaneous lesions. However, its systemic potential is poorly understood.We report a fatal case of PNX that manifested as a treatment-refractory**"Swveet-like" syndrome**, characterized by sterile deep-tissue involvement and **multi-organ failure (MOF)**. This case challenges the perception of PNX as a purely benign cutaneous entity and highlights its potential for life-threatening systemic progression.

Case Presentation

A 60-year-old male presented with a 5-year historyof yellow papules and plaques. Initially diagnosed as Sweet's syndrome via skin biopsy, he was treatedwith systemic glucocorticoids and acitretin with transient efficacy. The clinical course escalated to reecurrent hyperpyrexia(>39C)and septic-like shock.

Extensive imaging(CT/MRI) revealed extensive lesiors in the bilateral psoas muscles and iliopsoas, which radiologists initially misinterpreted as extracutaneous manifestations of Sweet's syndrome. Despite aggressive broad-spectrum anti-infective therapy, the patient developed MOF(SOFA score:13).Notably, multiple cultures and pathogen DNA testing from soas abscess drainage were consistently negative, suggesting a sterile,neutrophilic inflammatory process.

A definitive diagnosis of PNX was establishedthrough repeat multi-site skin biopsies, which demonstrated the hallmark juxtaposition of dense neutrophilic infiltrates, nuclear dust, and diffuse xanthomatized foam cells. Despite intensive care interventions, including CRRT and mechanical ventilation, the patient succumbed to progressive inflammatory shock and cardiac arrest.

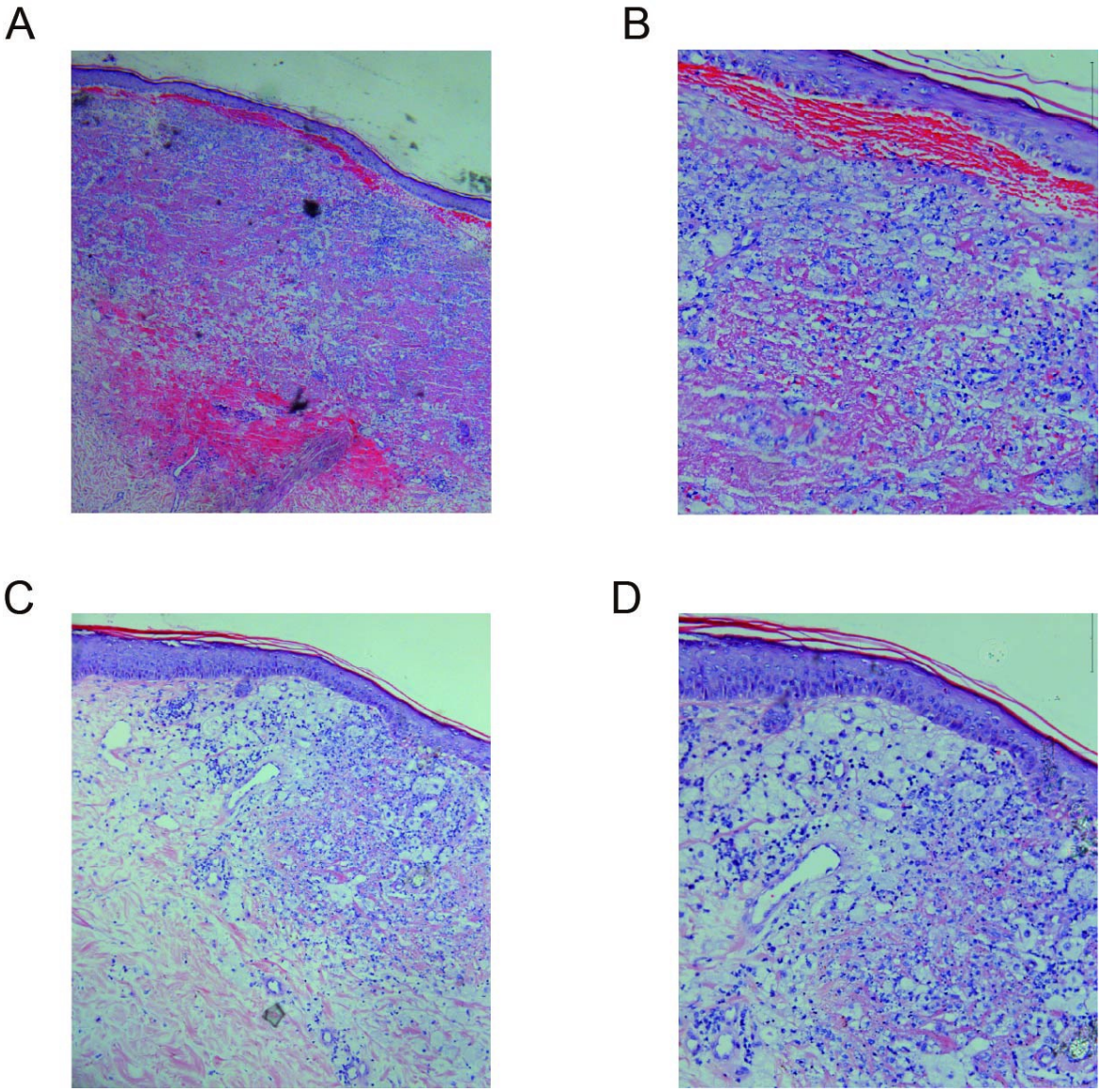

Figure1. Histopathological findings of the chest and abdominal lesions. (A) Low-magnification(4X) view of the chest biopsy showing distinctive subepidermal fissures and dense inflammatory cell infiltration in the superficial to mid-dermis.(B)High-magnification(20X)view of the chest lesion revealing diffuse xanthomatized foam cells accompanied by prominent nuclear dust(leukocytoclasis). (C) Histopathology of the abdominal lesion(10X)demonstrating diffuse, monotonous single-cell infiltration in the superficial dermis.(D)Higher magnification(20X) of the abdominal biopsy showing cells vwith enlarged,irregular nuclei and associated nuclear dust.

Conclusion

This case identifies PNX as a potentially fatal systenic disorder rather than a localized dermatosis.The occurrence of **"sterile psoas abscess"** mirrors the exttracutaneous neutrophilic infiltration seen in Sweet's syndrome, further complicating the differential diagnosis.For the EADV community, this case serves as a critical reminder:PNX can mimic Sweet's syndrome not only clinically and histologically but also in its systemic aggressive behavior.Early recognition of the"xanthomatized" component is vital to distinguish this entity and monitor for catastrophic systemic outcomes.

Clinical Phase	Cutaneous Morphology	Key Laboratory & Imaging	Pathological Feature	Clinical Insight (Enlightenment)
Early Stage (Years 1-3)	Recurrent red patches and plaques; Initial response to steroids.	Intermittent low-grade fever; Anemia.	Neutrophilic infiltration (Initially misdiagnosed as Sweet's Syndrome).	PNX can perfectly mimic Sweet's Syndrome in early inflammatory stages.
Progressive Stage (Years 4-5)	Yellow papules/nodules; Worsening skin infiltration.	Refractory high fever (>39.5°C); Shock; Normolipemic.	Xanthomatized foam cells mixed with massive nuclear dust (Leukocytoclasis).	"Xanthomatization" is a progressive process; repeated multi-site biopsies are mandatory.
Terminal Stage (Final Month)	Widespread papules/plaques; Multi-site skin involvement.	SOFA score: 13; Sterile psoas abscess; Multi-organ failure (MOF).	Systemic neutrophilic inflammatory storm; Biopsy confirmed PNX.	PNX is not always benign; it can trigger a fatal systemic inflammatory response.

Table 1. Longitudinal clinicopathological evolution and systemic progression of a fatal Papular Neutrophilic Xanthoma case.

EADV CONGRESS
VIENNA
30 SEP - 3 OCT 2026

Abstract N°: 1464

Dermatomyositis in 50 year old sine myositis

Sweta Rambhia*[1]

[1] JUST CARE DENTAL AND SKIN CLINIC, Mumbai, India

Introduction
Dermatomyositis (DM) is an idiopathic inflammatory myopathy characterized by distinctive cutaneous manifestations and varying degrees of muscle involvement. A subset of patients, classified as **amyopathic dermatomyositis (ADM)**, present with hallmark cutaneous features in the absence of clinical or laboratory evidence of myositis. ADM accounts for approximately 10–20% of dermatomyositis cases and often poses a diagnostic challenge, particularly in individuals with darker skin phototypes where classical erythematous or violaceous lesions may appear as hyperpigmented patches.

Autoantibody profiling has enhanced diagnostic precision in dermatomyositis. Among these,**anti–Mi-2 antibodies** are highly specific for DM and are typically associated with prominent cutaneous involvement, favorable prognosis, and lower risk of interstitial lung disease and malignancy. However, reports of **Mi-2β–positive amyopathic dermatomyositis** remain relatively uncommon.

We present a clinically and serologically characteristic yet rare case of ADM with Mi-2β positivity, emphasizing the importance of early recognition of cutaneous signs and appropriate immunological evaluation.

Case Presentation

CASE PRESENTATION

A 50-year-old female presented with a history of **photosensitivity** and gradual onset pigmentation over the face and upper extremities. There was no history of proximal muscle weakness, dysphagia, dyspnea, or systemic complaints.

Cutaneous examination revealed:

- **Bilateral periorbital hyperpigmentation** with a heliotrope-like appearance
- **Erythematous to hyperpigmented patches** over photo-exposed areas of the face, particularly the preauricular and malar regions FORHEAD AND CHEEK
- mechanic’s hands,
- NO GOTTRON PAPULES or periungual telangiectasia were evident. Systemic examination was unremarkable.

Laboratory investigations showed:

- **Normal muscle enzymes** (CPK within reference range)
- **Normal ESR and CRP**
- **Normal complement levels (C3)**
- **Mildly elevated LDH (clinically nonspecific)**

Autoimmune profile revealed:

- **Positive ANA blot with Mi-2β antibody positivity (++)**
- Negative dsDNA, Sm, SSA, SSB, and other extractable nuclear antigens

Based on the **characteristic cutaneous features**, **absence of muscle involvement**, and **specific autoantibody positivity**, a diagnosis of **amyopathic dermatomyositis** was established.

The patient was initiated on **photoprotection, ORAL METHOTREXATE, and topical immunomodulators**, with plans for periodic monitoring of muscle enzymes and malignancy screening.

Conclusion

This case underscores a rare presentation of **Mi-2β–positive amyopathic dermatomyositis**, highlighting the diagnostic value of integrating clinical morphology with autoantibody profiling. In patients with skin of colour, dermatomyositis may present predominantly as hyperpigmentation rather than classical violaceous erythema, leading to potential underdiagnosis or misdiagnosis.

Recognition of such subtle and atypical manifestations is essential for early diagnosis, timely treatment, and appropriate systemic surveillance. This case further reinforces the role of **Mi-2 antibodies as a key diagnostic marker** and a predictor of favorable prognosis in dermatomyositis.

EA DV CONGRESS
VIENNA
30 SEP - 3 OCT 2026

Abstract N°: 1475

An unusual presentation of VEXAS syndrome

Hiba Al-Bayati*[1], Justine Gallo[1], Sophie Grabczynska[1], Amal Eissa[1], Keiko Miyazaki[1]

[1] Amersham Hospital, Amersham, United Kingdom

Introduction

VEXAS (Vacuoles, E1 enzyme, X-linked, autoinflammatory, somatic) syndrome is a recently described autoinflammatory condition caused by acquired somatic mutations in the *UBA1* gene. Cutaneous manifestations are common, with Sweet syndrome—particularly the histiocytoid variant—being one of the most frequently reported dermatological presentations. Early recognition is important, as cutaneous disease may precede other systemic signs and symptoms.

Case Presentation

A 69-year-old man with no significant past medical history presented with pruritic, erythematous plaques on the trunk and upper limbs. He was systemically well, with no fevers, chondritis, or other inflammatory symptoms. Initial treatment in primary care for presumed eczema with potent topical corticosteroids and antibiotics led to only transient improvement. Over the subsequent year, the lesions persisted and spread to the face, neck and upper limbs.

Laboratory investigations demonstrated persistently elevated inflammatory markers with a normal full blood count and negative autoimmune screen. Imaging was unremarkable. Skin incisional biopsy revealed dermal oedema with a mixed inflammatory infiltrate composed of neutrophils, histiocytes, and lymphocytes, consistent with histiocytoid Sweet syndrome. Oral prednisolone resulted in rapid clinical improvement; however, symptoms recurred aggressively following steroid withdrawal, with periocular and truncal involvement.

Given recurrent disease, haematological referral and assessment was undertaken. Bone marrow aspirate included trephine and genetics demonstrated dysplastic changes. Genetic analysis identified a somatic *UBA1* mutation with a normal karyotype leading to the diagnosis of VEXAS syndrome.

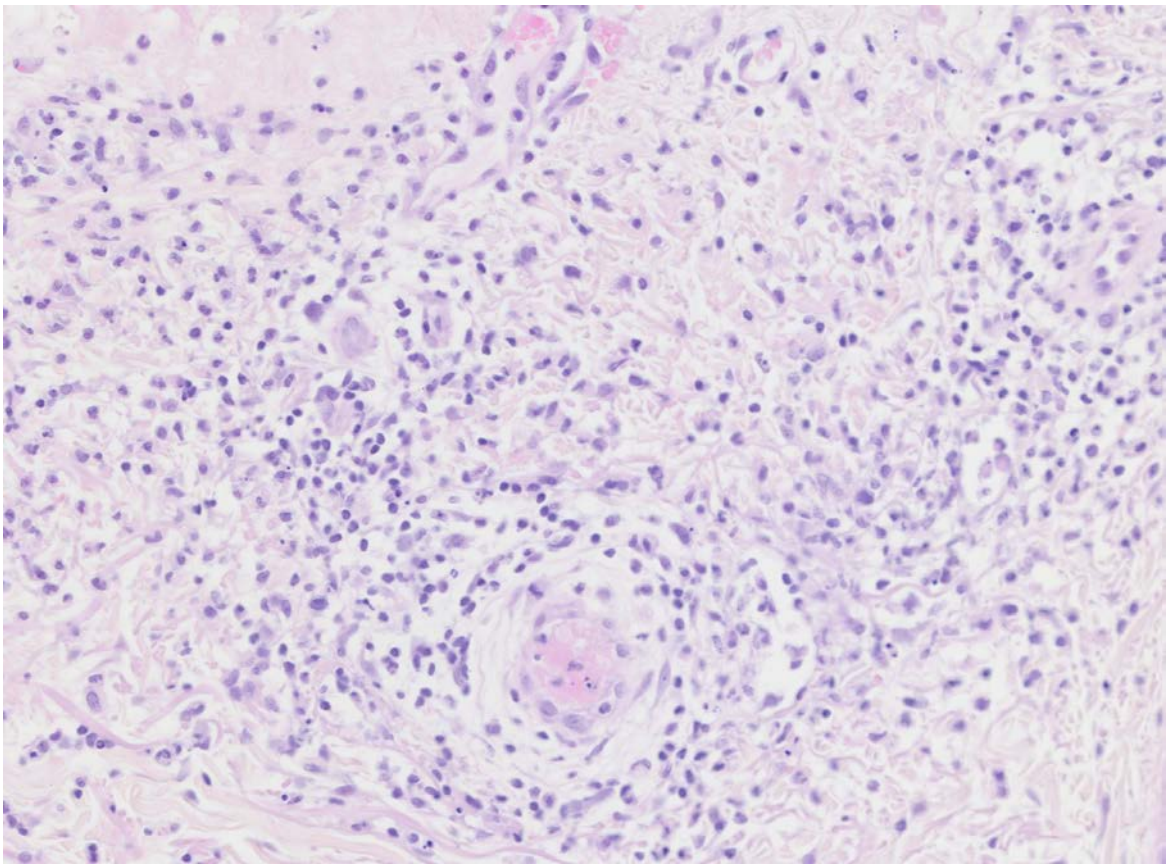

skin incisional biopsy from right arm (high magnification) showed Mild to moderate mainly perivascular infiltrate of inflammatory cells in both superficial and deep dermis, mainly small lymphocytes and histiocytes with a few polymorphs and mast cells. A little nuclear dust is also seen

Conclusion

VEXAS syndrome typically presents with systemic inflammation, cytopenias, and cutaneous disease; however, skin-limited presentations may occur early. This case highlights that recurrent histiocytoid Sweet syndrome in an older male, even in the absence of systemic features, should prompt consideration of VEXAS syndrome. Early recognition is essential due to its association with myelodysplastic syndromes and implications for long-term management.

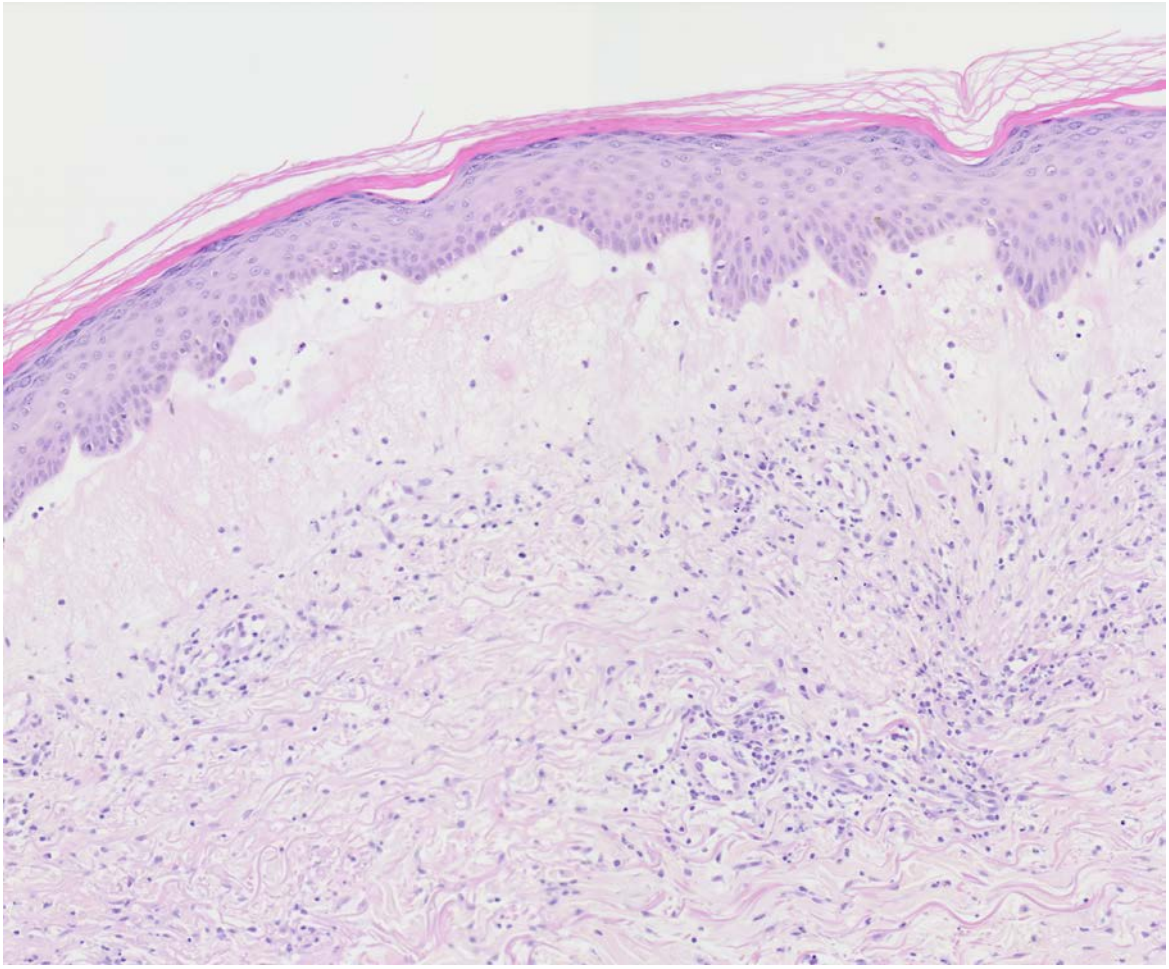

skin incisional biopsy from right arm (low magnification) showed Mild hyperkeratosis, slight acanthosis of the epidermis and prominent sub-epidermal oedema

EADV CONGRESS
VIENNA
30 SEP - 3 OCT 2026

Abstract N°: 1484

Retinal Vein Occlusion and Psoriasis in the All of Us Research Program

Andrew Mihalache[1], Brendan Tao[1], Dea Metko*[1], Ryan Huang[1], Tasha Miller[1], Milica Milakovic[1], Jensen Yeung[1], Rajeev Muni[1], Marko Popovic[1], Radha Kohly[1]

[1] University of Toronto, Toronto, Canada

Introduction
Emerging observational evidence from Asian populations suggests that psoriasis may be associated with retinal vein occlusion (RVO), potentially mediated by a cytokine-driven proinflammatory milieu. This study represents the first to evaluate the association between psoriasis and RVO in a large, demographically diverse U.S. cohort.

Materials and Methods
A retrospective study was conducted among adults enrolled in the National Institutes of Health All of Us Research Program. Psoriasis cases were identified using standardized diagnostic codes, with the index date defined as the first recorded psoriasis diagnosis. Controls without psoriasis were propensity score-matched (1:2) based on age, sex, self-reported race/ethnicity, smoking history, and key cardiometabolic and ocular comorbidities[1] . The primary analysis estimated the conditional odds ratio (OR) for ever having RVO among individuals with psoriasis compared with matched controls. Secondary analyses estimated hazard ratios (HRs) for incident RVO, assessed annually after the index date for five years and through each participant's final follow-up, using stratified Cox proportional hazards models that accounted for the matching covariates.

Results
A total of 9,951 participants with psoriasis and 19,902 matched controls were included in the primary analysis (mean age, 51.79 ± 14.83 years; n=18,516 [62.0%] female). Retinal vein occlusion was diagnosed in 61 (0.61%) participants with psoriasis and 76 (0.38%) matched controls. Psoriasis was associated with significantly higher odds of ever having RVO than matched controls (OR=1.62, 95% CI=[1.15, 2.20], p<0.01). In secondary analyses, the risk of incident RVO was significantly elevated in the psoriasis cohort within two years (HR=4.50, 95% CI=[1.39, 14.61], p=0.01), three years (HR=2.67, 95% CI=[1.12, 6.33], p=0.03), four years (HR=2.91, 95% CI=[1.35, 6.27], p<0.01), and five years (HR=3.00, 95% CI=[1.53, 5.90], p<0.01) of follow-up, but not within one year (p=0.10) or over a mean follow-up duration of 8 ± 6 years (p=0.32).

Conclusions
Individuals in the All of Us Research Program with psoriasis exhibited higher odds of an RVO diagnosis than matched controls; however, the risk of incident RVO following psoriasis diagnosis was not consistently increased over the long term. Further studies should clarify potential shared mechanisms linking psoriasis and RVO, and to validate these findings in additional diverse cohorts worldwide.

EADV CONGRESS
VIENNA
30 SEP - 3 OCT 2026

Abstract N°: 1492

Cryptococcal Panniculitis as an Initial Manifestation of Disseminated Cryptococcosis: A Case Report and Literature Review

Dan Cao*[1], Xiao Yan Lyu[1]

[1] West China Hospital, Sichuan University, Chengdu, China

Introduction
Cryptococcal panniculitis is a rare and underrecognized manifestation of cryptococcal infection that is prone to clinical misdiagnosis. This study aims to analyze the clinical characteristics of cryptococcal panniculitis and its association with disseminated infection through a case report combined with a literature review.

Materials and Methods
Materials and Methods: This study reports a case of a renal transplant recipient who initially presented with cryptococcal panniculitis and subsequently developed disseminated cryptococcosis involving the central nervous system, lungs, and heart. In addition, a structured review of published cases (n = 20) was performed to summarize clinical features, systemic involvement, and outcomes.

Results
The patient initially presented with painful indurated skin lesions in the absence of systemic symptoms, but later developed disseminated cryptococcosis. In the literature review, most patients (18/20) were immunocompromised, with solid organ transplantation as the most common underlying condition (11/20). Skin lesions predominantly involved the lower extremities (16/20) and typically presented as nodules or sclerotic plaques. Notably, although only a subset of patients exhibited systemic symptoms (9/20), most showed evidence of systemic dissemination upon further evaluation. The overall prognosis was poor, with a mortality rate of 45% (9/20), mostly attributed to disseminated infection.

Conclusions
Cryptococcal panniculitis may represent an early or skin-first manifestation of disseminated cryptococcosis, particularly in immunocompromised patients. Recognizing this presentation should prompt timely systemic evaluation, even in the absence of overt systemic symptoms, to facilitate early diagnosis and improve outcomes.

EADV CONGRESS
VIENNA
30 SEP - 3 OCT 2026

Abstract N°: 1520

Dyskeratosis Congenita: An Unusual Case of Lace-like Hyperpigmentation

Fanniyah Anis*[1], Lynette Wee[2], Mark Koh[2], Pei Ming Yeo[1]

[1] Sengkang General Hospital, Singapore, Singapore
[2] KK Women's and Children's Hospital, Singapore, Singapore

Introduction

Dyskeratosis congenita (DC) is a rare telomere biology disorder characterised by the classic triad of oral leukoplakia, nail dystrophy, and reticular hyperpigmentation. Cutaneous manifestations typically present in the first decade of life, and approximately half of all patients develop bone marrow failure by age 40. Over 18 genes have been implicated, with *ZCCHC8* representing an exceedingly rare cause. Herein, we describe a patient who was newly diagnosed later in adulthood, harbouring a *ZCCHC8* variant.

Case Presentation

A 34-year-old Chinese male presented with fever, haematuria, and left flank pain. He had a past medical history of lichen simplex chronicus, treated with betamethasone dipropionate 0.05% and salicylic acid 3% ointment. Investigations revealed pyuria, and computed tomography intravenous pyelography (CT IVP) showed a non-obstructing 2-millimetre left renal calculus, consistent with a urinary tract infection.

Incidentally, pancytopenia was detected: white blood cell count 2.90 × 10^9/L (normal 4.00–10.00 × 10^9/L), absolute lymphocyte count 0.80 × 10^9/L, absolute neutrophil count 1.68 × 10^9/L, haemoglobin 11.8 g/dL (normal 14.0–18.0 g/dL), and platelets 79 × 10^9/L (normal 140–440 × 10^9/L). Thyroid function was normal, with no nutritional deficiency or haemolytic anaemia identified. He was referred to haematology with a working diagnosis of aplastic anaemia versus myelodysplasia, and subsequently to dermatology for evaluation of his mucocutaneous features.

On examination, he had extensive fine reticulate hyperpigmentation on his trunk and limbs (present since early childhood), premature greying of hair, trachyonychia, dorsal pterygium, longitudinal splitting, and anonychia of the fingernails and toenails, as well as oral leukoplakia of the right buccal mucosa and palmoplantar hyperkeratosis.

His father and paternal aunt had similar premature greying, and his paternal great-grandfather and great-uncle had liver and colon cancer, respectively.

CT IVP incidentally revealed upper abdominal and gastro-oesophageal collateral vessels suggestive of portal hypertension. CT thorax showed bilateral lower lobe–predominant subpleural reticulation, raising concern for early interstitial lung disease. Genetic testing identified a variant in *ZCCHC8*, a gene encoding a component of the nuclear exosome targeting complex required for telomerase RNA maturation.

Bone marrow aspirate and trephine examination are planned.

Conclusion

ZCCHC8 is among the rarest genetic causes of DC. It follows autosomal dominant inheritance and is essential for TERC processing; its disruption leads to telomere shortening. In our patient, despite childhood-onset reticulate hyperpigmentation, the diagnosis was not made until age 34, when pancytopenia was incidentally discovered. This delayed recognition is consistent with the variable expressivity of telomere biology disorders, where haematologic manifestations may not emerge until adulthood.

Patients with DC carry an 11-fold increased risk of malignancy, particularly head and neck squamous cell carcinomas, followed by skin and anorectal cancers. The family history of malignancies, along with findings suggestive of portal hypertension and early interstitial lung disease, emphasises the multisystem nature of this disorder.

This case highlights the importance of recognising subtle mucocutaneous features that may precede life-threatening complications by decades, enabling earlier surveillance and intervention.

EADV CONGRESS
VIENNA
30 SEP - 3 OCT 2026

Abstract N°: 1573

Beyond Hepatic Pruritus: Scleromyxedema and Monoclonal Gammopathy of Cutaneous Significance Associated with Advanced Hepatocellular Carcinoma

Gohar Aftab*[1], Saadia Tabassum[1], Sadia Masood[1], Saira Fatima[1]

[1] Aga Khan University Hospital, Karachi, Karachi, Pakistan

Introduction

Scleromyxedema is a generalized variant of lichen myxedematosus characterized by sclerodermoid skin changes, monoclonal gammopathy, and a histological triad of dermal mucin deposition, fibroblast proliferation, and fibrosis. While it is a recognized dermatosis associated with Monoclonal Gammopathy of Cutaneous Significance (MGCS), its link to solid organ malignancies remains poorly documented. We present a case of scleromyxedema-spectrum mucinosis occurring in the setting of advanced hepatocellular carcinoma (HCC).

Case Presentation

A woman in her mid-80s presented with a four-month history of progressive pruritus and generalized skin tightening. Physical examination revealed diffuse leathery induration involving the trunk, thighs, and hands, accompanied by coalescing waxy papules. She had recently been diagnosed with advanced hepatocellular carcinoma with vascular invasion, occurring on a background of Child–Pugh A cirrhosis.

Skin biopsy showed spindle-shaped fibroblasts and abundant interstitial mucin deposition separating thickened collagen bundles. These findings confirmed a diagnosis of scleromyxedema. Further evaluation revealed concurrent polyclonal hypergammaglobulinemia, likely secondary to underlying chronic liver disease and malignancy-related immune dysregulation. Serum immunofixation additionally identified an IgG-κ monoclonal gammopathy, consistent with MGCS.

Conclusion

This case is noteworthy for the coexistence of MGCS and advanced HCC. Although scleromyxedema is classically associated with plasma cell dyscrasias, its occurrence alongside HCC raises the possibility that paraneoplastic mechanisms or cirrhosis-associated immune dysregulation may have contributed to disease pathogenesis. Persistent pruritus with progressive skin induration should prompt early dermatologic assessment. This case expands the recognized clinical spectrum of scleromyxedema-associated disorders and highlights the importance of multidisciplinary evaluation in patients with systemic disease and internal malignancy.

EA DV CONGRESS
VIENNA
30 SEP - 3 OCT 2026

Abstract N°: 1603

The Forgotten Diagnosis: Pellagra Mimicking Photocontact Dermatitis in a Middle-Aged Woman

Selen Taner Akbay*[1]

[1] Hatay Mustafa Kemal University Tayfur Ata Sökmen Medical Faculty, Dermatology Department, Hatay, Türkiye

Introduction
Pellagra is a potentially life-threatening nutritional deficiency disorder caused by niacin deficiency or impaired tryptophan metabolism. Although historically associated with poverty and malnutrition, it may still occur in modern clinical settings, particularly in patients with gastrointestinal dysfunction, inadequate nutritional intake, or unexplained weight loss. Because its classical triad of dermatitis, diarrhoea, and dementia is often incomplete, pellagra may be misdiagnosed as allergic contact dermatitis, photocontact dermatitis, autoimmune bullous disease, or infectious dermatoses. Recognition of its characteristic photodistributed eruption remains crucial for timely diagnosis and treatment.

Case Presentation
A 50-year-old woman presented with a two-month history of acneiform and erosive lesions initially affecting the arms, followed by progressive involvement of the neck and face. She reported marked exacerbation after sun exposure. Dermatological examination revealed widespread erythematous plaques with pustules, erosions, crusting, and desquamation on the bilateral arms, neck, and face, with prominent cervical involvement. She had previously received potent topical corticosteroids and systemic corticosteroids for presumed allergic contact dermatitis or photocontact dermatitis, without sustained improvement.

Bacterial culture from exudative lesions revealed *Klebsiella pneumoniae* and *Staphylococcus aureus*. Although she had no known chronic systemic disease or regular medication use, she described profound fatigue, epigastric burning, an unintentional weight loss of approximately 10 kg within one month, and episodes of mental confusion, inattentiveness, and forgetfulness. Given the combination of photosensitive dermatitis, constitutional symptoms, gastrointestinal complaints, and neurocognitive manifestations, pellagra was suspected.

Extensive evaluation for underlying malignancy, including gynaecological, surgical, gastroenterological, internal medicine, and haematological assessments, showed no evidence of malignancy. Endoscopic examination demonstrated erosive pangastritis, grade A oesophagitis, enterogastric reflux, and chronic gastritis with reactive atypical changes and intestinal metaplasia; *Helicobacter pylori* was negative. Laboratory investigations revealed hypoalbuminaemia and iron deficiency, supporting an underlying nutritional impairment.

Nutritional replacement therapy, including niacin, tryptophan, thiamine, pyridoxine, folate, vitamin B12, biotin, and zinc, was initiated together with supportive dermatological care. At the 40-day follow-up, the lesions on the face, neck, and upper extremities had improved by approximately 70–80%, leaving mainly residual desquamation on the arms.

Conclusion
This case emphasizes pellagra as a forgotten but clinically relevant diagnosis in patients presenting with photodistributed erosive dermatitis, unexplained weight loss, gastrointestinal symptoms, and neurocognitive

complaints. The absence of the complete classical triad should not exclude the diagnosis. In contemporary dermatology practice, pellagra may masquerade as allergic, phototoxic, infectious, or autoimmune dermatoses, leading to diagnostic delay and unnecessary investigations. Early recognition and prompt vitamin replacement can result in dramatic clinical improvement and prevent potentially severe systemic complications. This case serves as a reminder that pellagra, although uncommon in modern dermatology, should remain in the differential diagnosis of treatment-resistant photodistributed dermatitis, particularly when accompanied by weight loss, gastrointestinal symptoms, and subtle neurocognitive changes.

EA DV CONGRESS
VIENNA
30 SEP - 3 OCT 2026

Abstract N°: 1645

Early androgenetic alopecia as a possible indicator of diabetes mellitus and its link to cardiovascular risks: a cross-sectional study

Jiayu He*[1], Min He[1], Dehua Zhang[1], Ning Ning[1], Lin Chen[1], Shiyu He[1], Yunxia Ling[1], Jinfen Zheng[1], Xiangzi Li[1], Yang Guan[1], Yanyan Li[1]

[1] Department of dermatology, Shenzhen Center for Chronic Disease Control | Shenzhen Dermatology Hospital, Shenzhen, China

Introduction

Previous studies have reported inconsistent associations between androgenetic alopecia (AGA) and diabetes mellitus (DM). Thus, we aim to assess AGA prevalence in Southern China and explore its link to cardiovascular risks.

Materials and Methods

A population-based cross-sectional study in Shenzhen was conducted. AGA was diagnosed by dermatologists. Logistic regression analyzed associations between AGA and obesity, DM, hypertension, dyslipidemia, and cerebrovascular diseases.

Results

Out of 11,968 participants, the AGA prevalence was 18.94%, higher in males (32.42%) than females (7.12%). AGA patients exhibited high rates of obesity, abdominal obesity, dyslipidemia, DM, and hypertension (All $P<0.05$). Stratified analyses revealed a significantly higher DM prevalence in AGA patients aged 18~49 years, but not in patients aged over 50 years. A further comparison of average FBG and HbA1c values across age groups in AGA and non-AGA individuals showed similar patterns. A significant negative age-DM interaction on AGA was observed ($P_{interact}<0.001$). After rigorous adjustment, multivariable analyses in adults <45 years showed that AGA was associated with DM (OR=1.66, 95%CI: 1.21~2.27, $P=0.002$), impaired fasting glucose (OR=1.45, 95%CI: 1.11~1.89, $P=0.006$), fasting glucose ≥ 7.0mmol/L (OR=1.86, 95%CI: 1.27~2.74, $P=0.002$), HbA1c≥ 6.5% (OR=1.65, 95%CI: 1.16~2.34, $P=0.006$). No associations were found in adults over 45 years.

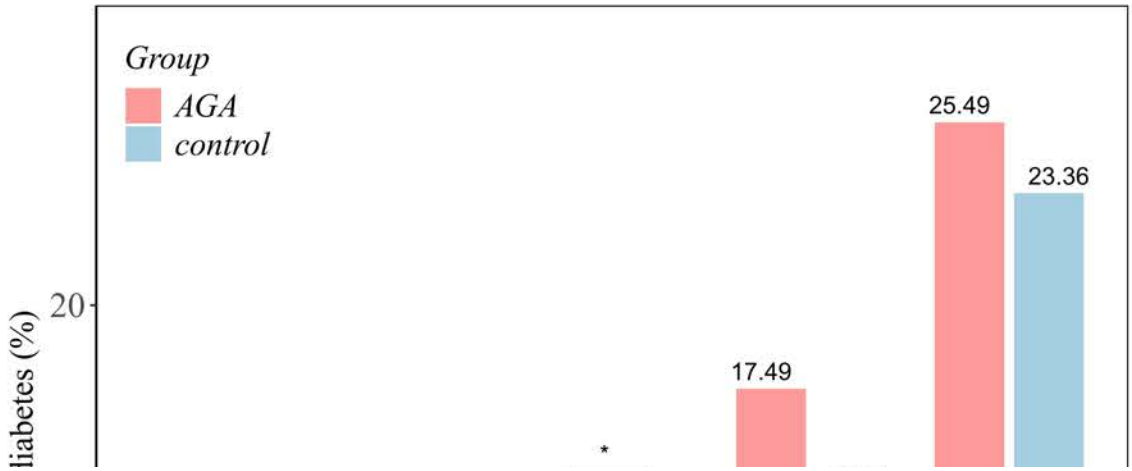

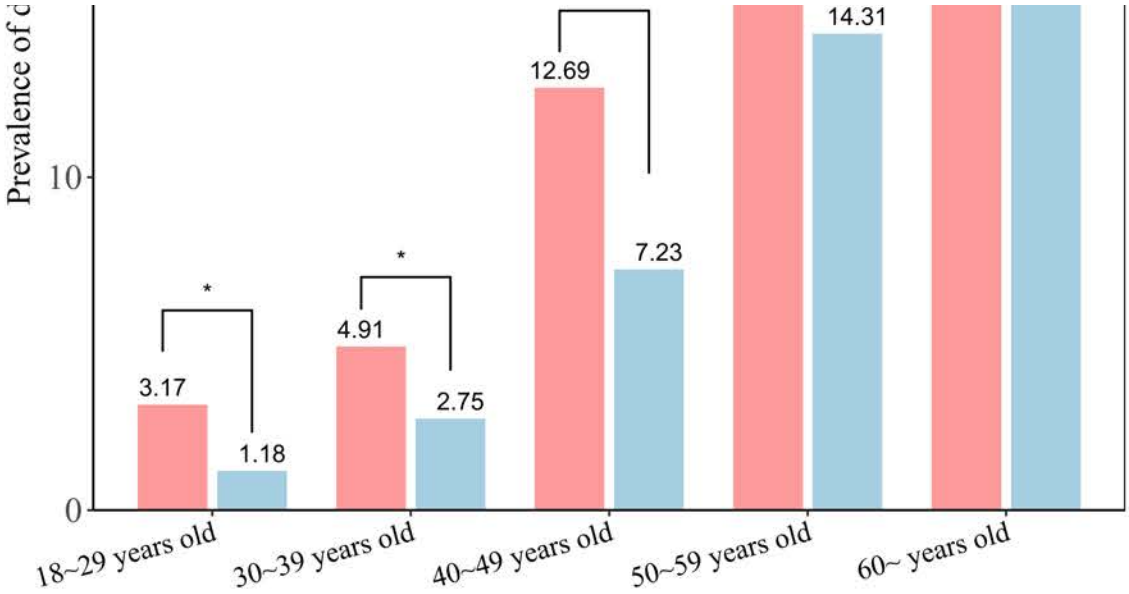

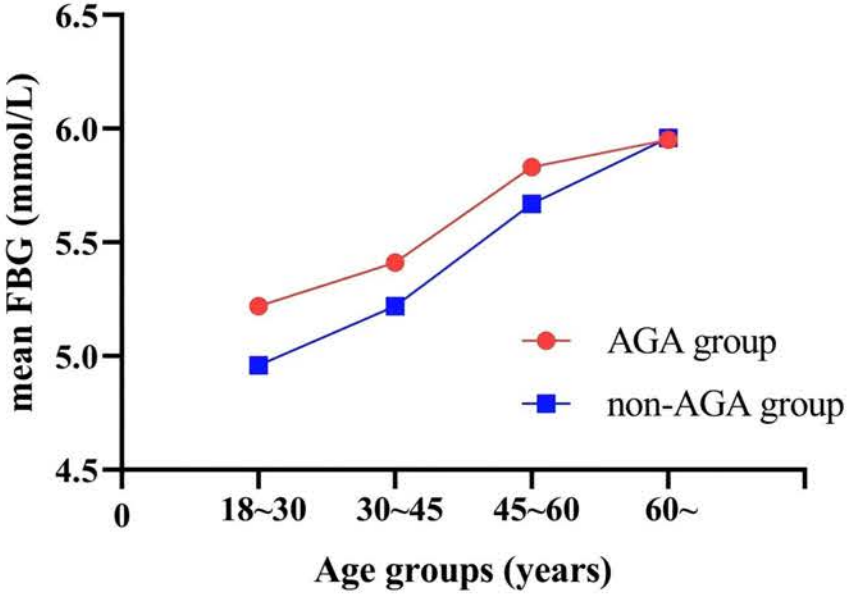

mean FBG (mmol/L)	18~29 years	30~44 years	45~59 years	60~ years
AGA group	5.22±1.50	5.41±1.36	5.84±1.80	5.95±1.38
non-AGA group	4.97±0.64	5.22±1.09	5.67±1.44	5.96±1.48
P value	0.043	<0.001	0.014	0.841

6.2

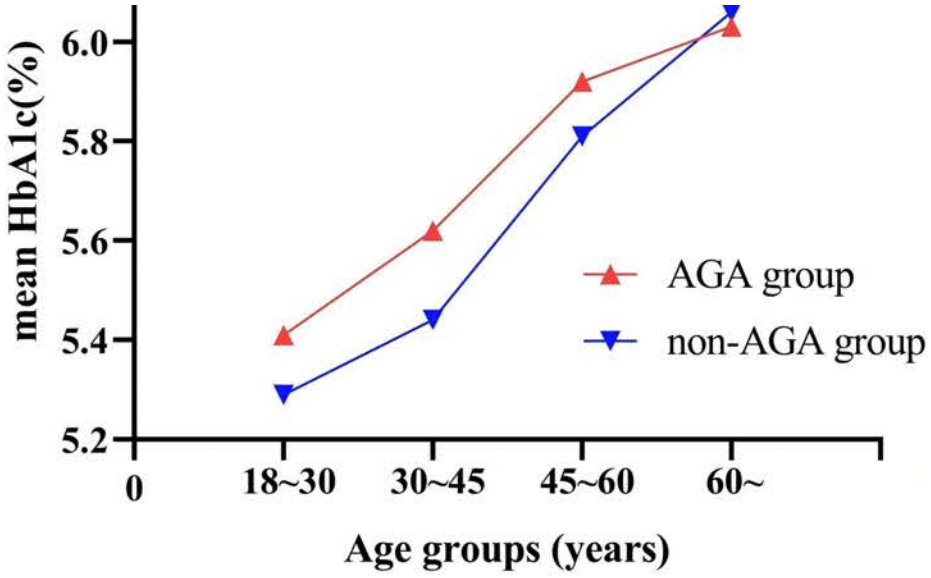

mean HbA1c (%)	18~29 years	30~44 years	45~59 years	60~ years
AGA group	5.41±0.84	5.62±0.86	5.92±1.15	6.02±0.91
non-AGA group	5.29±0.53	5.44±0.68	5.81±0.95	6.06±0.96
P value	0.029	<0.001	0.006	0.548

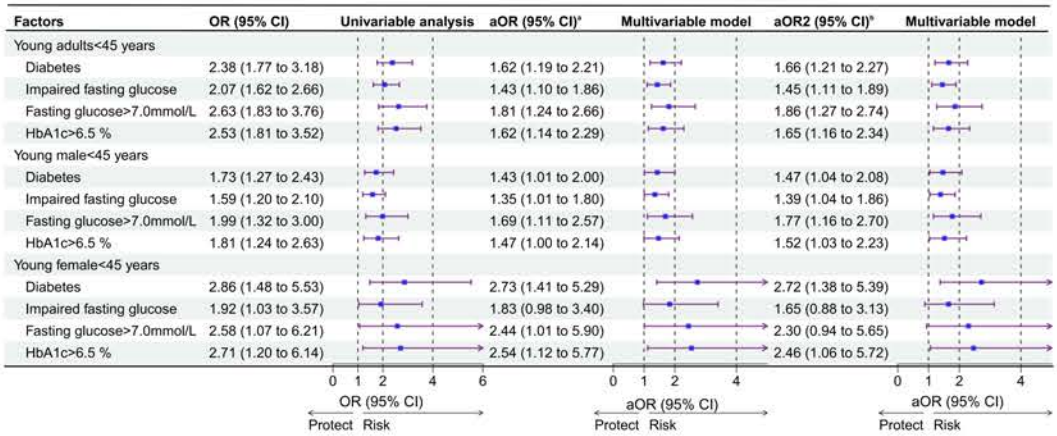

Figure 1. Prevalence of diabetes mellitus in different age groups among AGA and non-AGA participants. *P<0.05. Figure 2. Mean fasting blood glucose across four age groups (18-29 years, 30-44 years, 45-59 years, and 60- years) among AGA and non-AGA participants. Figure 3. Mean HbA1c across four age groups (18-29 years, 30-44 years, 45-59 years, and 60- years) among AGA and non-AGA participants. Figure 4. Forest plot of the association between AGA and blood glucose metabolism among participants under 45 years old. a. adjusted for age and gender; b. adjusted for age, gender,

marital status, education, smoking status, alcohol consumption, BMI category, exercise, insomnia.

Conclusions

Early-onset AGA may indicate DM risk in young and middle-aged adults, highlighting the need for early identification aimed at preventive strategies.

EA DV CONGRESS
VIENNA
30 SEP - 3 OCT 2026

Abstract N°: 1661

When the skin speaks: Eruptive disseminated porokeratosis as a paraneoplastic sign

Teresa Lemos*[1], Mariana Pedroso[1], João Luís Fernandes[1], Jorge Varandas Lindo[1], João Teixeira[1], Joana Calvão[1]

[1] Dermatology Department, Coimbra Local Health Unit, Coimbra, Portugal

Introduction

Eruptive disseminated porokeratosis (EDP) is a rare variant of porokeratosis characterized by the abrupt onset of disseminated, often pruritic lesions. As the other subtypes, the skin lesions have a well demarcated, threaded rim, corresponding histologically to a cornoid lamella. Three major associations have been described: underlying malignancy, immunosuppression, and inflammation of pre-existing lesions.

Case Presentation

A 76-year-old man presented to our dermatology clinic with a 1-month history of widespread pruritic lesions sparing the face. His medical history was significant for squamous cell carcinoma of the oral cavity, treated 4 months prior with surgery and radiotherapy. Physical examination revealed multiple erythematous-brown maculopapules, 2-6mm in diameter, with a well-demarcated, elevated, threaded keratotic border. Dermoscopy revealed multiple linear-irregular as well as branched vessels within an annular keratin rim. An incisional biopsy of one of the lesions showed cornoid lamellae, narrow columns of parakeratotic corneocytes. The recent history of malignancy, together with the abrupt onset of pruritic, disseminated skin lesions that were histologically consistent with porokeratosis, supported the diagnosis of EDP. The patient was initially treated with clobetasol propionate ointment and oral loratadine; due to a lack of significant response, oral acitretin (10 mg) was initiated, with modest improvement of lesions and pruritus. Given the possible association of EDP with tumour relapse, additional work-up with computed tomography and PET imaging was undertaken and revealed extensive locoregional disease with contralateral nodal metastasis. Chemotherapy with carboplatin was then initiated and, after three cycles, there was significant improvement of pruritus and skin lesions, alongside partial regression of cervical lymphadenopathy.

Conclusion

EDP is associated with an underlying malignancy in 30% of cases. The most frequently associated neoplasias are hepatobiliary (e.g., hepatocellular carcinoma) and hematologic (e.g., lymphoma). Although several cutaneous paraneoplastic syndromes have been well described in patients with head and neck cancers, particularly oral malignancies, to our knowledge, this represents the first reported case of EDP in this context.

When the malignancy is successfully treated, the lesions tend to regress, revealing its paraneoplastic behaviour. Since cutaneous manifestations may precede diagnosis of the malignancy, this association should prompt thorough investigation when a malignancy has not been diagnosed yet. Therapeutic options are diverse and include destructive modalities such as cryotherapy or photodynamic therapy, as well as topical agents including 5-fluorouracil, retinoids, or imiquimod. In refractory cases, oral acitretin may be considered, although relapse after discontinuation is common. Long-term control is ultimately dependent on effective treatment of the underlying tumour.

EADV Congress 2026, VIENNA
30 SEPTEMBER - 03 OCTOBER 2026
POWERED BY M-ANAGE.COM

EADV CONGRESS
VIENNA
30 SEP - 3 OCT 2026

Abstract N°: 1746

When “Rosacea” Reveals Systemic Sarcoidosis: A Case of Lupus Pernio

oumaima sabour*[1], hanane baybay[1], ikram bejja[1], saadia boughaleb[1], zakia douhi[1], meriem soughi[1], sara elloudi[1], fatimazahrae mernissi[1]

[1] Department of Dermatology, Hassan II University Hospital, fes, Morocco

Introduction

Sarcoidosis is a systemic granulomatous disease, histologically characterized by the presence of non-caseating epithelioid cell granulomas. Cutaneous involvement occurs in approximately 20–35% of patients and may occasionally represent the initial manifestation of the disease. Among the specific cutaneous forms, lupus pernio is a rare but highly suggestive presentation of systemic sarcoidosis and is frequently associated with pulmonary and upper respiratory tract involvement. Because of its erythematous and telangiectatic appearance, lupus pernio may clinically mimic rosacea, potentially leading to diagnostic delay.

Case Presentation

We report the case of a 51-year-old woman followed by ophthalmology for chronic bilateral dacryocystitis and by the otorhinolaryngology department for rhinitis initially considered allergic. She was referred to the dermatology department for suspected rosacea after the progressive development of erythematous plaques on the nose. Dermatological examination revealed infiltrated erythematous-violaceous plaques with prominent telangiectasias located on the nasal root and tip. Dermoscopic examination showed an erythematous background with telangiectasias and brownish-orange globules visible under pressure, suggestive of granulomatous infiltration. Based on these findings, a skin biopsy was performed with lupus pernio, corticosteroid-induced granulomatous dermatitis, and foreign body granuloma considered as differential diagnoses. Histopathological examination revealed a specific granulomatous dermatitis composed of non-caseating epithelioid and multinucleated giant cell granulomas, consistent with cutaneous sarcoidosis. Further systemic evaluation revealed bilateral hilar lymphadenopathy suggestive of pulmonary sarcoidosis. A nasal biopsy performed in the context of the patient's ENT symptoms also demonstrated granulomatous involvement of the upper respiratory tract compatible with sarcoidosis, leading to a revision of the initial diagnosis of allergic rhinitis.

Lupus pernio represents one of the most characteristic forms of cutaneous sarcoidosis. It typically presents as infiltrated erythematous-violaceous plaques affecting the nose, cheeks, and ears. This form is frequently associated with chronic systemic involvement, particularly affecting the lungs and upper respiratory tract. Clinically, these lesions may resemble rosacea because of the presence of facial erythema and telangiectasias. However, the infiltrated aspect of the lesions, their violaceous coloration, and the presence of orange-brown globules on dermoscopy, corresponding to dermal granulomas, are suggestive of a granulomatous dermatosis. The diagnosis relies on histopathological examination demonstrating non-caseating epithelioid granulomas after exclusion of infectious causes and other granulomatous diseases. The identification of lupus pernio should prompt a systematic evaluation for extracutaneous involvement, particularly pulmonary and ENT manifestations. Treatment generally relies on systemic corticosteroids combined with immunomodulatory agents such as antimalarials, with possible adjunctive use of topical immunosuppressive therapy. In our patient, treatment with prednisone at a dose of 1 mg/kg/day combined with hydroxychloroquine 400 mg/day and topical tacrolimus resulted in significant clinical improvement.

Conclusion

This case highlights the importance of considering sarcoidosis in the differential diagnosis of facial dermatoses mimicking rosacea. Lupus pernio represents a highly suggestive cutaneous manifestation that is frequently associated with systemic involvement. Early recognition of this dermatological presentation allows timely systemic evaluation and appropriate therapeutic management.

EA DV CONGRESS
VIENNA
30 SEP - 3 OCT 2026

Abstract N°: 1815

Destructive Orofacial Granulomatosis: A Rare Presentation of Systemic Sarcoidosis

Sonda Yaich*[1], Soumaya Gara[1], Sarra Agoubi[1], Noureddine Litaiem[1], Meriem Jones[1], Soumaya Rammeh[2], Feten zeglaoui[1]

[1] Dermatology, Hopital Charles Nicolle, Tunis, Tunisia
[2] Anatomopathology, Hopital Charles Nicolle, Tunis, Tunisia

Introduction
Sarcoidosis is a systemic granulomatous disease of unknown etiology, characterized by polymorphic clinical manifestations that may involve multiple organs, including the skin. We report a rare case of sarcoidosis with a particularly mutilating and destructive cutaneo-mucosal presentation.

Case Presentation
A 52-year-old woman, followed for chronic crusting rhinitis for four years, presented with a deforming centrofacial plaque evolving for one year. Dermatological examination revealed a 7-cm infiltrated, atrophic, erythematous-squamous plaque involving the upper cutaneous lip, nasolabial folds, nostrils, and nasal tip, associated with two atrophic telangiectatic plaques on the cheeks. Dermoscopy showed arborizing telangiectasias on an orange-yellow background. There were no palpable lymph nodes, no alteration of general condition, no history of raw milk consumption, and no tuberculosis exposure.

Initial laboratory investigations were unremarkable (normal renal, liver function and calcium-phosphate balance, 24-hour proteinuria, ANCA, HIV, HBV, HCV, and syphilis serologies were negative). The first skin biopsy revealed poorly circumscribed granulomas without necrosis, with a dense inflammatory infiltrate rich in plasma cells and neutrophils. PCR for *Mycobacterium tuberculosis* on biopsy was negative, as was the tuberculin skin test.

Facial and thoracoabdominal scan showed chronic pansinusitis with lysis of the middle and inferior turbinates, axillary and supra- and infradiaphragmatic lymphadenopathy—some necrotic—along with bilateral pulmonary and hepatic nodules. Lymph node biopsy demonstrated granulomatous adenitis with fibrinoid necrosis; PCR for tuberculosis was negative. Lepra testing was also negative. Empirical antituberculous therapy was administered for three months.

Clinical progression was marked by extension of the centrofacial plaque, disappearance of the nasal orifices, formation of a synechia between the inner lip and upper gingiva, palatal perforation with nasal regurgitation, new infraorbital, interbrow, and thoracic plaques, and a 10-kg weight loss. Angiotensin-converting enzyme levels turned out elevated. A second skin biopsy revealed typical sarcoid granulomas. The diagnosis of systemic sarcoidosis with mutilating centrofacial cutaneo-mucosal involvement was established. The patient was treated with systemic corticosteroids (1 mg/kg/day) combined with methotrexate, with favorable outcome. Surgical repair of the palatal perforation was planned after resolution of inflammation.



infiltrated, atrophic, plaque of the upper cutaneous lip, nasolabial folds, nostrils, and nasal tip, associated with two atrophic telangiectatic plaques on the cheeks.

Conclusion

This case illustrates a rare and severe form of systemic sarcoidosis revealed by mutilating centrofacial cutaneo-mucosal involvement. Cutaneous tuberculosis was initially suspected due to the atrophic and destructive aspect, the poorly defined granulomas with polymorphous inflammatory infiltrate suggesting infection, and the presence of fibrinoid necrosis in lymph nodes. However, absence of microbiological confirmation, lack of response to antituberculous therapy, repeated skin biopsies, and elevated angiotensin-converting enzyme levels supported the diagnosis of sarcoidosis. Granulomatosis with polyangiitis was unlikely given negative ANCA and absence of renal involvement.

Orofacial sarcoidosis is rare and particularly misleading. Deep mucosal infiltration of the nasal cavities, sinuses, palate, or pharynx may produce a destructive pattern. Chronic rhinosinusitis is an uncommon but reported manifestation that may delay diagnosis. Bone involvement occurs in about one quarter of cases, usually affecting peripheral bones in patients with known systemic disease. Nasosinus bone involvement remains exceptional; turbinate lysis in our patient reinforced the suspicion of infectious or vasculitic disease. Moreover, necrosis within lymph node granulomas, although rare, may occur in sarcoidosis and represents a major diagnostic pitfall, leading to a false diagnosis of tuberculosis.

EADV CONGRESS
VIENNA
30 SEP - 3 OCT 2026

Abstract N°: 1822

Hydroa vacciniforme-like lymphoproliferative disorder in a young adult: Diagnostic challenges of a rare progressive disease with uncertain prognosis

Daniela Zumárraga*[1], Fernando Montalvo[1], Nicole Edmonds[2], Stephanie Snyder[2], Cristina Altamirano[3], Cristhian Suárez-Noboa[4], Janyna Jaramillo[1], Richard Flowers[2], Corina Rusu[2], Santiago Palacios[1]

[1] Centro de la Piel, Universidad San Francisco de Quito, Quito, Ecuador

[2] University of Virginia, Charlottesville, United States

[3] Hospital de la Policia Nº 1, Quito, Ecuador

[4] Universidad San Francisco de Quito, Quito, Ecuador

Introduction

Hydroa vacciniforme–like lymphoproliferative disorder (HVLLD) is a rare Epstein–Barr virus (EBV)-associated condition characterized by heterogeneous clinical phenotypes and an unpredictable prognosis. Given its rarity and potential for systemic progression, diagnosis often requires high clinical suspicion and meticulous clinicopathologic correlation. This report aims to detail the diagnostic pitfalls encountered in a young adult and discuss the efficacy of systemic immunosuppressive therapy in arresting disease progression.

Case Presentation

A 28-year-old male was evaluated for a 6-month history of facial lesions progressing to the trunk and extremities (60% body surface area), sparing the palms and soles. Systemic symptoms included fever, fatigue, anorexia, and weight loss. Clinical examination, laboratory investigations (C-reactive protein, HIV and syphilis serology, EBV-VCA IgG/IgM), and histopathological analysis of two punch biopsies were performed. Laboratory findings showed elevated CRP (17.91 mg/L) and EBV VCA IgG positivity; HIV and syphilis serology were negative. Histopathology revealed subepidermal vesicles with neutrophilic and lymphocytic involvement, alongside dense perivascular and periadnexal lymphohistiocytic infiltrates. Diagnostic confirmation was achieved using an immunohistochemistry (IHC) panel (CD3, CD4, CD5, CD8, CD30, Ki-67) and EBER in situ hybridization. IHC demonstrated a T-cell immunophenotype (CD3+, CD4+, CD5+, CD8+) with rare CD30+ cells and EBER positivity. The Ki-67 index was 9%, confirming HVLLD. Treatment was initiated with weekly subcutaneous methotrexate (10 mg) and topical corticosteroids, resulting in complete resolution of systemic symptoms and stabilization of cutaneous lesions. Written informed consent was obtained from the patient before diagnostic procedures.

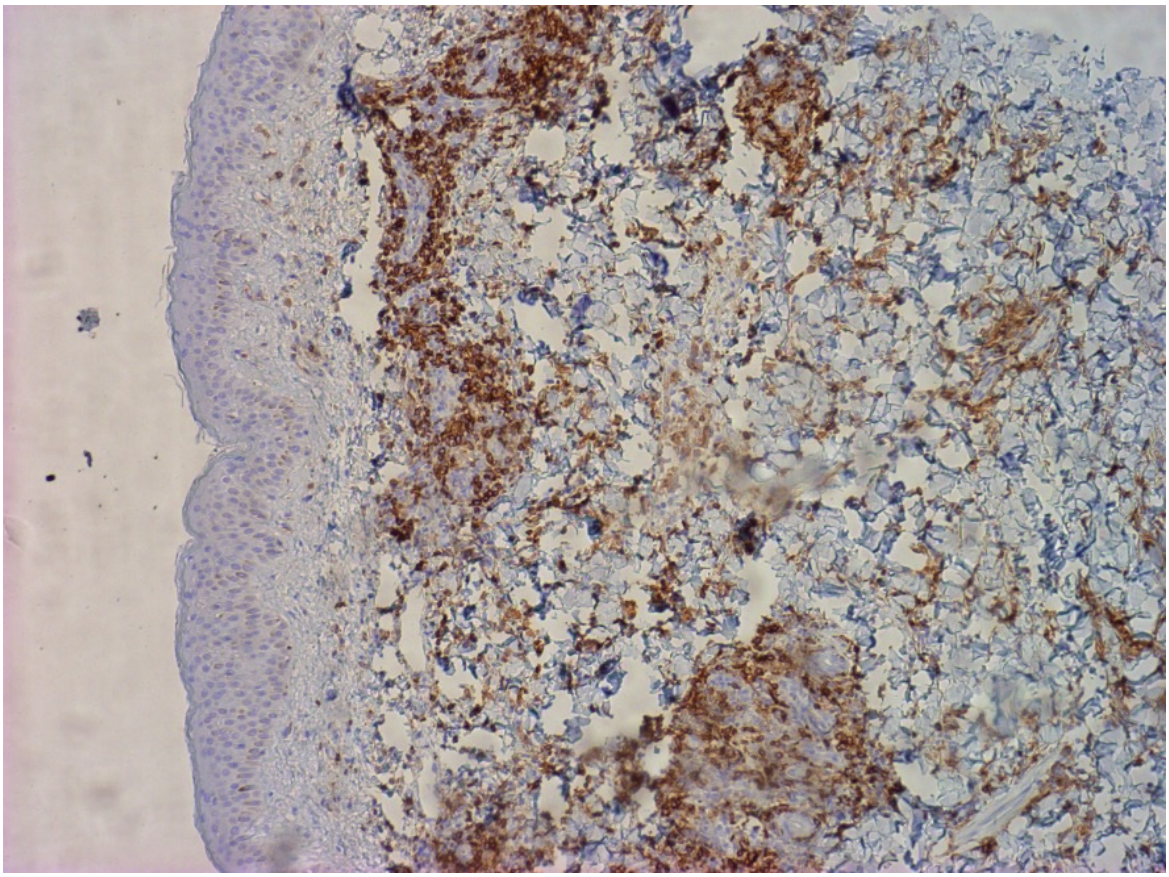

Immunohistochemical reaction (immunoperoxidase method) showing T-cell marker positivity (CD3/CD8); the inflammatory infiltrate demonstrates a cytotoxic T-cell immunophenotype with dense dermal involvement (10x).

Conclusion

This case highlights HVLLD as a critical differential diagnosis for progressive vesiculopustular eruptions in young adults. Early recognition through IHC and EBER testing is essential to initiate systemic therapy, such as methotrexate, which proved effective in preventing further clinical deterioration in this patient. Long-term follow-up remains essential given the potential for progression to systemic lymphoma.

EADV CONGRESS
VIENNA
30 SEP - 3 OCT 2026

Abstract N°: 1827

Scar sarcoidosis associated with retained surgical staples

Noor Almaani[1], Deema Rayyan*[1], Mariana Nusair[1], Deena Nafea[2], Nesreen Alhamwi[3], Malek Absieh[3]

[1] Department of Dermatology, School of Medicine, The University of Jordan, Amman, Jordan

[2] Department of Pathology, School of Medicine, The University of Jordan, Amman, Jordan

[3] School of Medicine, The University of Jordan, Amman, Jordan

Introduction

Sarcoidosis is a multisystem granulomatous disease of unknown etiology characterized by non-caseating epithelioid granulomas. Cutaneous involvement occurs in approximately 20–35% of patients and may be specific, demonstrating sarcoidal granulomas, or nonspecific, such as erythema nodosum. It may occasionally represent the first or only manifestation of disease. Scar sarcoidosis is a recognized variant in which granulomatous inflammation develops within pre-existing scars or sites of prior trauma. Triggers include surgical scars, tattoos, injection sites, and healed herpes zoster lesions. Lesions typically present as erythematous or violaceous plaques or nodules, with latency ranging from years to decades. The pathogenesis is thought to involve an exaggerated immune response to persistent antigenic stimuli within previously injured skin. Scar tissue may represent an immunologically altered microenvironment predisposing to granuloma formation.

Case Presentation

A 23-year-old woman presented with progressive erythema and induration affecting longstanding burn scars on the chest and upper limbs. The scars resulted from a scald injury sustained at age 3 years that required reconstructive surgery. Over several months, she noted increasing redness and thickening within the scarred areas, without systemic symptoms.

Examination revealed extensive burn scars with superimposed erythematous, infiltrated plaques. Skin biopsy demonstrated non-caseating granulomatous inflammation composed of epithelioid histiocytes and multinucleated giant cells. Polarizable foreign material was identified within the granulomas (Figure 1). Initial laboratory investigations and chest imaging were unremarkable. During follow-up, the patient developed bilateral ocular pain and redness. Ophthalmological evaluation confirmed intermediate uveitis. Subsequent imaging revealed retained metallic surgical staples within the affected areas from her childhood reconstructive procedure. Most staples were surgically removed. The patient was treated with systemic corticosteroids followed by methotrexate, with the addition of mycophenolate mofetil for ocular involvement. Following removal of retained foreign material and escalation of immunosuppressive therapy, she showed significant improvement in both cutaneous and ocular disease.

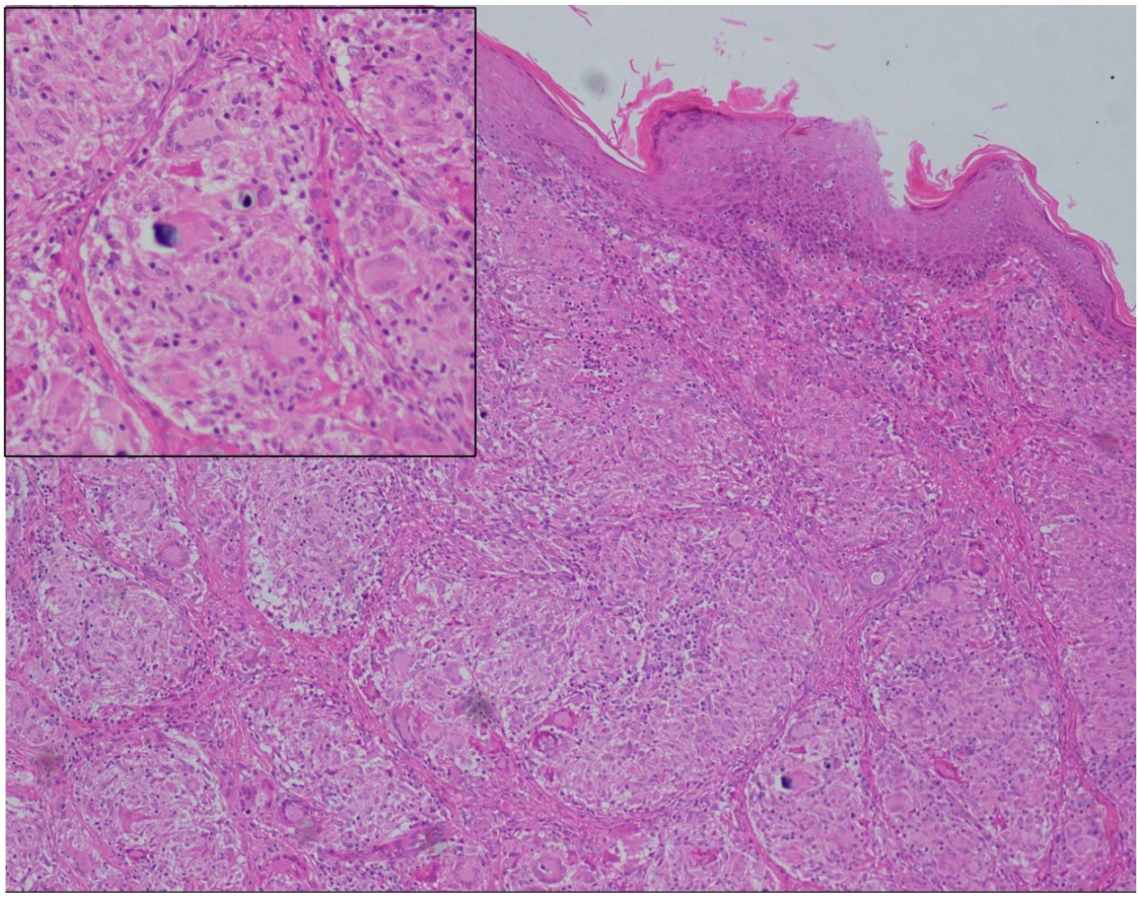

Figure 1: Granulomatous dermatitis with non-caseating epithelioid granulomas in the dermis. Polarizable foreign material is identified within the granulomas on polarized light microscopy (H&E, ×100 and ×400).

Conclusion

Distinguishing scar sarcoidosis from foreign body granulomatous reactions can be challenging due to overlapping clinical and histopathologic features. This case highlights the potential role of retained foreign material as a trigger for sarcoidal granuloma formation and underscores the importance of clinicopathologic correlation and evaluation for systemic involvement in patients presenting with granulomatous lesions arising within scars.

EADV CONGRESS
VIENNA
30 SEP - 3 OCT 2026

Abstract N°: 1974

Effectiveness of Cyclophosphamide in the Treatment of Cutaneous Sarcoidosis: A Case Report

Vicente Márquez Garrido*[1], Jose Fuentes Ros[1], Pablo Díaz-Calvillo[1], Cecilia Iborra García-Trevijano[1], Marta Cortés Pérez[1]

[1] Hospital Universitario de Puerto Real, Puerto Real, Spain

Introduction
Sarcoidosis is a systemic non-caseating granulomatous disease of unknown etiology that may affect the skin. We present a case of ulcerative cutaneous sarcoidosis refractory to multiple treatments.

Case Presentation
A 57-year-old woman presented with a 2-month history of painful infiltrated violaceous plaques on the right forearm and hand, together with periorificial nasal papules. She was afebrile and had no other systemic symptoms.

Biopsy revealed a non-necrotizing sarcoid-type granulomatous dermatitis, with nodular epithelioid aggregates of histiocytes and Langhans-type multinucleated giant cells. Polymerase chain reaction for *Leishmania*, acid-fast bacilli smear, and mycobacterial culture from the skin biopsy were negative. Laboratory and imaging studies showed no relevant findings. Based on these results, a diagnosis of cutaneous sarcoidosis was established. Interferon-γ testing was positive, and therefore chemoprophylaxis was required.

She underwent multiple lines of treatment over 3 years, including topical, oral, and intralesional corticosteroids, topical tacrolimus, methotrexate, hydroxychloroquine, mycophenolate mofetil, and adalimumab, with poor response. The lesions progressed to ulceration and impaired the patient's functionality, with a visual analog pain scale score of 10/10. Again a skin biopsy was performed to rule out mycobacterial infection, cutaneous leishmania or tuberculosis. Mycobacterial culture and PCR for Leishmania were negative, likewise pathological techniques for microorganism detection were also negative.

Treatment with intravenous cyclophosphamide 750 mg monthly for 6 months and then every 3 months for a further 6 months was initiated, followed by intravenous infliximab 500 mg at weeks 0, 2, and 6, and subsequently every 6 weeks. After 3 months of treatment, the lesions resolved, pain ceased, and functionality was restored. The response has been maintained after 7 months of follow-up, with good treatment tolerance.

Conclusion
Cutaneous sarcoidosis represents a therapeutic challenge due to the lack of standardized treatments in this setting.

The remission of the lesions reflected successful use of cyclophosphamide in our case, highlighting the potential role of this drug in ulcerative cutaneous sarcoidosis refractory to other treatments.

The safety profile of cyclophosphamide requires limiting its use and encourages investigation of other potentially useful therapeutic targets in refractory cases, such as IL-6, IL-17, and the JAK-STAT pathway.

EADV Congress 2026, VIENNA
30 SEPTEMBER - 03 OCTOBER 2026
POWERED BY M-ANAGE.COM

EA DV CONGRESS
VIENNA
30 SEP - 3 OCT 2026

Abstract N°: 2001

Acral Psoriasiform Lesions Following Breast Cancer: Revisiting Bazex Syndrome

Ingrid Palloma Vieira de Melo*[1], Hudson Rezende[1], João Henrique Aurich[1], Antonio Moraes Madeira Quindos[2], Juliana Santos Rodrigues[1]

[1] Centro Universitário Lusíada, Santos, Brazil

[2] Universidade de Taubaté (UNITAU), Taubaté, Brazil

Introduction

Bazex syndrome, or paraneoplastic acrokeratosis, is a rare dermatosis characterized by symmetric psoriasiform lesions affecting acral sites, often accompanied by nail dystrophy and palmoplantar keratoderma. It is classically associated with squamous cell carcinomas of the upper aerodigestive tract. Associations with other malignancies are uncommon, and its recognition in these settings remains challenging.

Case Presentation

Six months after the diagnosis of a poorly differentiated, triple-negative infiltrating ductal carcinoma of the breast (cT4bcN2), a 52-year-old woman began to develop erythematous, scaly plaques affecting the palms, soles, and elbows, accompanied by nail dystrophy. Skin biopsy (4-mm punch) demonstrated psoriasiform dermatitis without specific features. In the context of acral involvement, nail changes, and close temporal association with the underlying malignancy, a paraneoplastic process was suspected, and Bazex syndrome was considered the most likely diagnosis. Neoadjuvant chemotherapy with doxorubicin and cyclophosphamide, followed by weekly paclitaxel combined with carboplatin, was initiated. This led to a significant oncologic response, paralleled by marked improvement of the cutaneous lesions within 12 weeks. Surgical management was subsequently planned, including mastectomy, axillary lymph node dissection, and thoracic wall reconstruction.

Conclusion

This case highlights an uncommon presentation of Bazex syndrome associated with breast cancer, expanding the spectrum of malignancies linked to this condition. Although histopathological findings are often nonspecific, clinical suspicion is essential, particularly in patients with treatment-resistant acral psoriasiform eruptions. The parallel improvement of skin lesions with oncologic therapy supports their paraneoplastic nature. Early recognition of this entity may facilitate timely diagnosis, guide management, and avoid misclassification as primary inflammatory dermatoses.

EADV CONGRESS
VIENNA
30 SEP - 3 OCT 2026

Abstract N°: 2041

Erythema gyratum repens associated with adenomyosis and endometriosis: a case report

Emanuele Scala[1], Donatella Sordi[1], Arlind Kalaja[2], Francesca Passarelli[1], Lidia Francesconi[1], Filomena Russo*[1]

[1] Istituto Dermopatico dell'Immacolata, IDI-IRCCS, Rome, Italy
[2] Ospedale Guglielmo da Saliceto, Piacenza, Italy

Introduction
Erythema gyratum repens (EGR) is a rare figurate erythema traditionally considered a paraneoplastic dermatosis, most often linked to internal malignancies. Nevertheless, sporadic non-paraneoplastic cases have been reported, suggesting that alternative inflammatory or immune-mediated mechanisms may also play a role in its pathogenesis.

Case Presentation
A 37-year-old non-Caucasian woman presented with a 2-year history of pruritic, erythematous concentric plaques refractory to topical and systemic therapies. Clinical findings were consistent with EGR. Laboratory investigations showed normal blood parameters and negative autoantibody panels, with the exception of elevated CA-125 levels. Further gynecological evaluation revealed severe adenomyosis associated with endometriosis. The patient underwent hysterectomy for management of the underlying condition. Following surgery, the cutaneous eruption completely resolved without the need for additional dermatologic treatment.

Conclusion
This case highlights a rare non-paraneoplastic presentation of EGR associated with benign gynecologic disease. The complete resolution after surgical treatment supports a possible link between chronic inflammatory processes and EGR. Clinicians should consider both neoplastic and non-neoplastic causes when evaluating patients with EGR to ensure appropriate diagnostic workup and management.

EADV CONGRESS
VIENNA
30 SEP - 3 OCT 2026

Abstract N°: 2061

The dermatologic spectrum of monoclonal gammopathies in a real-world cohort

Eirini Solia[1], Ioannis-Alexios Koumprentziotis[2], Maria Gavriatopoulou[1], Evangelos Terpos[1], Antonis Tsimpidakis[2], Evdoxia Panou[2], Meletios A Dimopoulos[1], Alexander Stratigos[2], Efstathios Kastritis[1], Vasiliki Nikolaou*[2]

[1] Department of Clinical Therapeutics, Plasma Cell Dyscrasia Unit, National and Kapodistrian University of Athens, Athens, Greece

[2] 1st Department of Dermatology and Venereology, Andreas Sygros Hospital, National and Kapodistrian University of Athens, Medical School of Athens, Athens, Greece

Introduction

Monoclonal gammopathies (MGs) are characterized by the presence of plasma or B-cell clones producing monoclonal immunoglobulins causing a variety clinical complications including a broad spectrum of dermatologic manifestations. Recently, the term monoclonal gammopathy of skin significance (MGSS) has been introduced to describe MG-related skin manifestations and syndromes. However, systematically collected data on the prevalence, clinical patterns, and determinants of skin disease in this population remain limited. We aimed to characterize dermatologic comorbidities and treatment-related skin manifestations in patients with plasma cell disorders, and to explore potential associations with disease characteristics and immunoglobulin profiles.

Materials and Methods

Consecutive patients followed for MG were invited to complete a structured questionnaire capturing personal and family dermatologic history. In cases of self-reported or clinically suspected skin disease, patients were referred for dermatologic evaluation and confirmation of diagnosis. Demographic and hematologic data were collected for all participants. Descriptive statistics were used to summarize patient characteristics and the prevalence of dermatologic conditions. Categorical variables were expressed as counts and percentages. Associations between dermatologic manifestations and clinical variables were assessed using logistic regression models, with results reported as odds ratios (ORs) and corresponding p-values. Statistical significance was set at $p<0.05$.

Results

A total of 393 patients with MGs were included (173 monoclonal gammopathy of undetermined significance (MGUS), 111 smoldering multiple myeloma (SMM), 46 MM, 28 asymptomatic Waldenström macroglobulinemia, 8 Waldenström macroglobulinemia, and 18 AL amyloidosis). A personal history of dermatologic disease was identified in 146 patients (37.1%), while 34 (8.7%) had a family history of skin conditions while 53 patients (13.5%) were referred for dermatologic evaluation due to suspected skin disease. Among reported dermatologic symptoms pruritus was the most frequent (n=88, 22.4%), followed by dermatitis (35 cases based on patient history and 11 confirmed after dermatologic evaluation), psoriasis (17 based on history and 11 confirmed), and skin cancer (16 based on history and 7 confirmed following evaluation). Among patients with skin cancer, 4 had a personal history of melanoma and 2 reported a family history of melanoma. Additionally, 4 patients had a history of lupus erythematosus (3 previously diagnosed and 1 newly identified during dermatologic assessment). No significant associations were observed between pruritus, dermatitis, or skin cancer and the underlying plasma cell disorder, age, or sex. In exploratory analyses, psoriasis was significantly associated with asymptomatic Waldenström macroglobulinemia (odds ratio [OR] 3.6, p=0.032), whereas whereas this association was not retained when asymptomatic and symptomatic Waldenström cases were analyzed together. No significant associations were found for MGUS or MM No correlations were identified between immunoglobulin subtype or light chain restriction and dermatologic comorbidities.

Conclusions

Patients with MGs exhibit a significant burden of dermatologic disease, encompassing a wide spectrum of conditions. Inflammatory dermatoses, particularly psoriasis, appear relatively frequent, supporting a potential role for underlying immune dysregulation. These findings suggest that further clinical research is needed to improve MGSS definitions and avoid overdiagnosis or missing significant associations. Importantly, a notable prevalence of skin cancers, including melanoma, was also observed, underscoring a clinically relevant oncologic-dermatologic burden in this population. These findings highlight the need for increased awareness, preventive strategies, and systematic dermatologic assessment. Routine dermatologic follow-up should be considered in the comprehensive management of these patients.

EADV CONGRESS
VIENNA
30 SEP - 3 OCT 2026

Abstract N°: 2083

SEBORRHEIC DERMATITIS AS A MARKER OF IMMUNOSUPPRESSION IN PATIENTS WITH PULMONARY TUBERCULOSIS

Ksenia Stavriyani[1], Darya Nalobina[1], Anastasiia Kolerova[1, 1], Nataliya Stavitskaya[2], Irina Sergeeva*[1]

[1] Novosibirsk State University, Novosibirsk, Russian Federation

[2] Tuberculosis Research Institute, Novosibirsk, Russian Federation

Introduction

Seborrheic dermatitis is widely recognized as one of the earliest cutaneous markers of HIV-associated immunosuppression, with a prevalence of 40–80% in HIV-positive individuals compared to only 1–3% in the general population. However, its role as an indicator of immune status in other conditions associated with impaired cellular immunity has not been sufficiently explored. Pulmonary tuberculosis leads to sequestration of CD4+ lymphocytes in pulmonary granulomas, resulting in peripheral lymphopenia, yet the relationship between this process and cutaneous manifestations has not been previously described. **Objective.** To assess the prevalence of seborrheic dermatitis in patients with pulmonary tuberculosis and to determine its association with laboratory markers of immune status.

Materials and Methods

A single-centre cross-sectional study was conducted involving 106 patients receiving treatment for pulmonary tuberculosis. The cohort comprised 78 males (73.6%) and 28 females (26.4%), with a mean age of 46.2 ± 11.8 years. All patients underwent a dermatological examination including trichoscopy of the scalp. The diagnosis of seborrheic dermatitis was based on trichoscopic findings. Clinical and laboratory data were obtained from medical records. Statistical analysis was performed using the Mann–Whitney U test for continuous variables and Fisher's exact test for categorical variables; multivariate analysis was carried out using logistic regression.

Results

Seborrheic dermatitis was identified in 41 patients (38.7%). Males accounted for 40 out of 41 cases (97.6%; OR=28.4; p<0.001), which is consistent with the known androgen-dependent nature of the condition. No association with HIV infection was found (OR=0.30; p=0.40): only 1 out of 41 patients with seborrheic dermatitis was HIV-positive. There was no significant association with sputum smear positivity (OR=1.37; p=0.55) or age (p=0.53). Fibrocavitary tuberculosis was more common among patients with seborrheic dermatitis, approaching statistical significance (OR=2.14; p=0.069).

Patients with seborrheic dermatitis demonstrated a distinct laboratory profile: relative lymphopenia (24.9% vs 30.0%; p=0.007) accompanied by leukocytosis (8.96 vs 7.03 $\times 10^9$/L; p=0.0008) and neutrophilia (59.5% vs 54.8%; p=0.021), an elevated neutrophil-to-lymphocyte ratio (2.86 vs 2.26; p=0.011), thrombocytosis (353 vs 303 $\times 10^9$/L; p=0.028), elevated total protein (74.6 vs 69.6 g/L; p=0.001), hyperuricaemia (425.6 vs 304.3 µmol/L; p=0.0001) and raised creatinine (88.9 vs 78.2 µmol/L; p=0.015). This pattern suggests a shift in the immune response towards the innate arm with a weakening of the adaptive cellular component.

Conclusions

The prevalence of seborrheic dermatitis in patients with tuberculosis (38.7%) substantially exceeds the population level and is comparable to that seen in HIV-positive cohorts, while no association with HIV was confirmed in our study. The association of seborrheic dermatitis with lymphopenia, neutrophilia, elevated neutrophil-to-lymphocyte ratio and hyperproteinaemia suggests that it may serve as a readily available clinical marker of tuberculosis-induced cellular immunosuppression, requiring no additional laboratory investigations.

EA DV CONGRESS
VIENNA
30 SEP - 3 OCT 2026

Abstract N°: 2117

Skin as the First Clue: Leukemia Cutis Revealing Chronic Myeloid Leukemia

Fathima Buhari*[1]

[1] INSTITUTE OF DERMATOLOGY VENEREOLOGY &LEPROSY, MADRAS MEDICAL COLLEGE, CHENNAI, India

Introduction

Leukemia cutis refers to infiltration of the skin by neoplastic leukocytes resulting in clinically identifiable cutaneous lesions. It is an uncommon manifestation in chronic myeloid leukemia (CML) and may rarely precede or reveal the underlying hematological malignancy. Early recognition of suspicious cutaneous lesions is important as it may facilitate prompt diagnosis and management of systemic disease.



Multiple erythematous to violaceous infiltrated papules and nodules over the trunk and extremities in leukemia cutis associated with chronic myeloid leukemia.

Case Presentation

A 63 year old male presented with multiple asymptomatic erythematous to violaceous papules and nodules over the face , forehead, temple, periorbital region, and trunk over an indurated background. Examination revealed firm infiltrated lesions with progressive increase in number and size. Dermoscopic evaluation showed pinkish-brown structureless areas , linear vessels, red globules, focal hemorrhagic areas,surrounded by white structureless zones, and central crusting in few lesions, enhanced by UV exposure.Skin biopsy obtained from a papular lesion over the temple demonstrated diffuse dermal infiltration by atypical mononuclear cells consistent with leukemic infiltrate, confirming leukemia cutis. Immunohistochemistry and hematological investigations confirmed the diagnosis of leukemia cutis associated with chronic myeloid leukemia. Peripheral smear and bone marrow evaluation revealed

features consistent with CML. The patient was referred medical oncology and started on chemotherapy (LDAC Regimen)

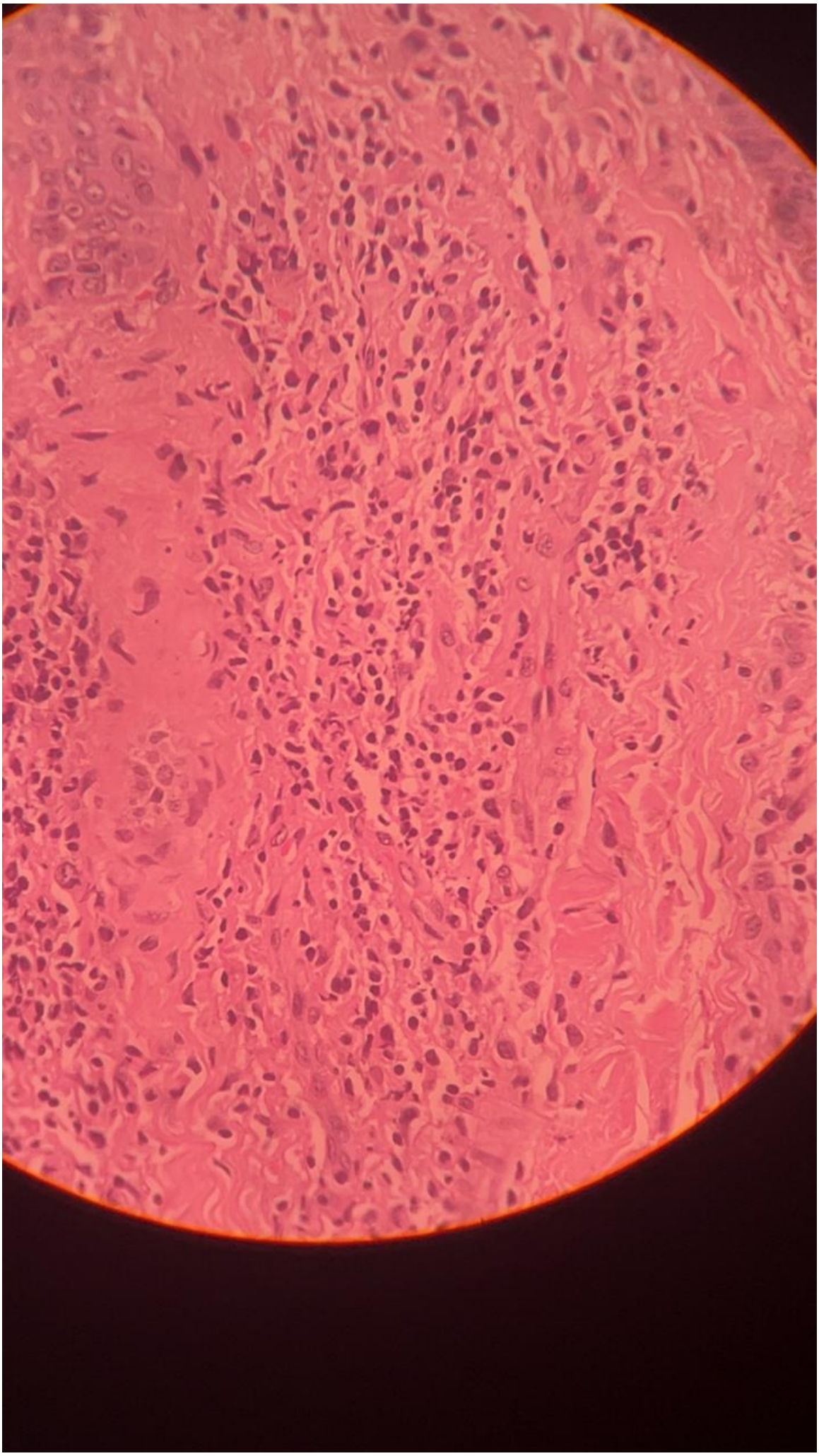

Histopathology showing dense dermal infiltrate of atypical leukocytic cells consistent with leukemia cutis (H& E Stain)

Conclusion

Leukemia cutis in CML is rare and may occasionally represent the first manifestation of systemic leukemia. Cutaneous lesions may mimic inflammatory or neoplastic dermatoses, creating diagnostic difficulty. Recognition of atypical infiltrative skin lesions by dermatologists is essential for early diagnosis and timely multidisciplinary management. This case highlights the role of dermoscopy and histopathology and importance in clinicopathological correlation in identifying underlying hematological malignancy.



Dermoscopic examination showed pinkish-brown structureless areas , linear vessels.

EA DV CONGRESS
VIENNA
30 SEP - 3 OCT 2026

Abstract N°: 2135

Cutaneous Sarcoidosis Arising in an Area of Notalgia Paresthetica Revealing Systemic Disease

Chourouq Mustapha Eid*[1], Fatima Zahra Sassine[1], hajar ammari[2], Tarik Hanafi[2], Rachid FRIKH[2], Hjira Naoufal[2]

[1] Centre Hospitalier Ibn Sina, Dermatology Department, Rabat, Morocco
[2] Dermatology Department, Mohammed V Military Hospital, Rabat, Morocco

Introduction

Sarcoidosis is a multisystem granulomatous disorder that can affect virtually any organ, and diagnosis relies on a compatible clinical and radiologic presentation, histologic evidence of non-caseating granulomas, and exclusion of alternative causes. Cutaneous manifestations are among the most frequent extrapulmonary features of sarcoidosis and may represent the initial manifestation of systemic disease.

Notalgia paresthetica is a chronic cutaneous neuropathy characterized by localized pruritus and dysesthesias of the upper back, often accompanied by burning, numbness, tingling, tenderness, or hyperpigmentation. To our knowledge, the occurrence of cutaneous sarcoidosis arising in an area of notalgia paresthetica has not previously been described in the literature.

Case Presentation

A 48-year-old male patient with a history of notalgia paresthetica evolving for more than 10 years presented with the progressive appearance of multiple small papules arising over the hyperpigmented area affected by notalgia paresthetica. The lesions were asymptomatic, with no associated pruritus or pain. Similar papules were also noted on the trunk and within the axillary folds. The patient did not report any pulmonary, gastrointestinal, ocular, articular, or neurologic symptoms.

Physical examination revealed numerous small, well-demarcated, rounded hemispherical papules in a Fitzpatrick skin phototype IV patient. The lesions measured 2 to 5 mm in diameter and were orange to salmon-colored, with a smooth surface and soft consistency. They were distributed over the neck, upper trunk, bilateral axillary folds, and within the area affected by notalgia paresthetica. No mucosal or adnexal involvement was observed. The remainder of the physical examination was unremarkable.

Dermoscopy of the papules demonstrated orange-yellow structureless areas consistent with granulomatous infiltrates, associated with a few linear and arborizing vessels, as well as whitish scar-like areas suggestive of fibrosis.

Laboratory investigations showed no anemia or lymphopenia. The erythrocyte sedimentation rate was within normal limits. Renal, hepatic, electrolyte, and phosphocalcic profiles were unremarkable. Serum protein electrophoresis and angiotensin-converting enzyme levels were also normal.

A skin biopsy was performed and revealed epithelioid cell granulomas with multinucleated giant cells, without caseous necrosis. Periodic acid-Schiff and Ziehl-Neelsen stains were negative. These findings were consistent with cutaneous sarcoidosis.

Because of these findings, a systemic evaluation was performed. Chest imaging revealed interstitial pulmonary

involvement associated with mediastinal lymphadenopathy, the largest lymph node being located in the right lower paratracheal region and measuring 15 mm in short-axis diameter.

Further investigations did not reveal any ophthalmologic, cardiac, or osseous involvement. A diagnosis of systemic sarcoidosis with pulmonary involvement was therefore established. The patient was treated with high-potency topical corticosteroids. After six months of follow-up, clinical improvement was noted, with flattening of the papular lesions.

Conclusion

Areas affected by notalgia paresthetica may conceal cutaneous sarcoidosis, and any new or progressive lesion in this setting should prompt biopsy and systemic evaluation.

This case expands the range of sarcoidosis presentations and reinforces the need to look beyond neuropathic itch when the morphology changes.

EADV CONGRESS
VIENNA
30 SEP - 3 OCT 2026

Abstract N°: 2142

Atypical Pityriasis Rosea in Patients With Autoimmune and Rheumatologic Disease: A Possible Link to Immune Dysregulation

Ekin Altinbas*[1], Mehmet Yeral[1], Ceyda Tetik Aydoğdu[1], Emine Tugba Alatas[1], suzan demir pektas[1], Yunus özcan[1], Miray Kendir[1]

[1] Muğla Eğitim ve Araştırma Hastanesi, Muğla, Türkiye

Introduction

Pityriasis rosea (PR) is an acute papulosquamous eruption classically associated with human herpesvirus 6/7 reactivation. Although atypical variants have increasingly been reported, factors contributing to unusual morphology, localization, recurrence, and treatment resistance remain poorly understood. Growing evidence following the COVID-19 era has renewed interest in the role of immune dysregulation in PR pathogenesis. We aimed to describe the clinical and histopathological features of atypical PR occurring in patients with autoimmune and/or rheumatologic disease.

Case Presentation

We retrospectively evaluated five patients presenting with papulosquamous eruptions clinically inconsistent with classical PR but histopathologically compatible with PR. Atypical PR was defined as the absence of one or more classical diagnostic criteria and/or the presence of atypical morphology, localization, course, or herald patch pattern. Differential diagnoses, including psoriasis, pityriasis lichenoides chronica, dermatophytosis, and syphilis, were excluded by histopathology, potassium hydroxide examination, and serological tests. Antinuclear antibody (ANA), rheumatoid factor (RF), and anti-thyroid peroxidase (anti-TPO) antibody levels were evaluated in all patients.

Five patients (4 females, 1 male; mean age 52 years) were included (Figure 1). All patients had underlying autoimmune or rheumatologic disease, including autoimmune thyroid disease, vitiligo, scleroderma, Sjögren syndrome, and systemic lupus erythematosus. The disease course was recurrent in three patients and persistent in two, with durations ranging from 1 month to 2 years. Lesions showed atypical and localized involvement, including palmoplantar regions, inguinal folds, unilateral antecubital area, dorsal feet, and isolated lower extremities. Only one patient demonstrated herald patches, presenting with two distinct lesions. Dermatoscopy revealed pityriasiform collarette scaling, while histopathology consistently demonstrated spongiosis, superficial perivascular lymphocytic infiltrates, and erythrocyte extravasation without fungal elements, eosinophils, or neutrophilic infiltration. All patients were unresponsive or only partially responsive to topical corticosteroids, oral antihistamines, valacyclovir, and clarithromycin.



Figure 1. (a) lesions localized to the distal upper extremities of patient 1, (b) lesions localized to palmar region of patient 2, (c) lesions localized to the leg of patient 3, (d) solitary recurrent lesions localized to the antecubital region of patient 4, (e) multiple giant plaques on lower extremities of patient 5.

Conclusion

Previous studies have demonstrated altered cellular immunity in PR and increased incidence in immunologically altered states such as pregnancy, systemic corticosteroid use, and post-transplantation settings. The clustering of persistent or recurrent atypical PR in patients with autoimmune/rheumatologic disease in our series further supports a possible role for immune dysregulation in atypical disease behavior. Immune imbalance may facilitate viral reactivation or alter cutaneous immune responses, potentially contributing to unusual morphology, localization, chronicity, and therapeutic resistance. To our knowledge, this is the first case series specifically focusing on atypical PR in the setting of autoimmune and rheumatologic disease.

Atypical PR in patients with autoimmune or rheumatologic disorders may demonstrate an unusually persistent, recurrent, and treatment-resistant course. Recognition of this association may help broaden the clinical spectrum of PR and support the emerging hypothesis that immune dysregulation contributes to atypical disease phenotypes. Larger studies are needed to clarify the underlying mechanisms and therapeutic implications.

Patient	Gender	Age (years)	Comorbidity	ANA	RF	Anti-TPO	Herald patch	Localization	Disease duration
1	Female	37	Autoimmune thyroid disease	+3 positive	Negative	Positive	Absent	Bilateral forearms and dorsal feet	5 months (Recurrent)
2	Female	68	Scleroderma, vitiligo	+2 positive	Negative	Negative	Absent	Hands and feet including palmoplantar area	6 months (Recurrent)
3	Male	74	Vitiligo	Negative	Negative	Negative	Absent	Legs	2 years (Persistent)
4	Female	38	Autoimmune thyroid disease	Negative	Negative	Positive	Absent	Antecubital, unilateral	1 month (Recurrent)
5	Female	40	Scleroderma, Sjögren	+2 positive	Negative	Negative	Absent	Inguinal fold, anterior thigh	10 months (Persistent)

Demographic, clinical, and laboratory features of the patients. (ANA, anti-nuclear antibody; RF, Rheumatoid factor; anti-TPO, anti-thyroid peroxidase)

EA DV CONGRESS
VIENNA
30 SEP - 3 OCT 2026

Abstract N°: 2189

Papulonodular Mucinosis with Discoid Lupus Erythematosus and Generalized Lymphadenopathy

Michelle Sze Yiu Leung*[1], Mairepati Dilixiati[2], Chaocheng Liu[3], Liuyi Liu[2], Yexiao Wang[2], Xuhua Tang[2], Jiande Han[2], Hui Zhou[2]

[1] University of Alberta, Edmonton, Canada
[2] The First Affiliated Hospital of Sun Yat-sen University, Guangzhou, China
[3] University of British Columbia, Vancouver, Canada

Introduction

Papulonodular mucinosis (PNM) is a rare cutaneous mucinosis characterised by skin-coloured to erythematous papules and nodules with diffuse dermal mucin deposition. Approximately 75% of reported PNM cases are associated with systemic lupus erythematosus (SLE), 20% with discoid lupus erythematosus (DLE), and 5% with subacute cutaneous LE. Generalised lymphadenopathy has been described almost exclusively in SLE-associated PNM. We report a case of PNM with concurrent DLE and generalised lymphadenopathy in a patient with no clinical or serological evidence of SLE over more than a decade of follow-up.

Table 1. Comparison of the present case with previously reported DLE-associated PNM cases.

Case / Source	ANA Status	Lymphadenopathy	Serum Immunoglobulin / Complement	Progression to SLE During Follow-up
Present case (China)	Negative. ANA, anti-dsDNA, anti-Sm, anti-U1-RNP, anti-Ro/SSA, anti-La/SSB, anti-Scl-70, anti-Jo-1, anti-ribosomal-P, and antiphospholipid antibodies all negative on repeated testing.	Yes. Generalised lymphadenopathy: bilateral submandibular, posterior cervical, supraclavicular, axillary, and inguinal nodes (smooth, mobile, non-tender). ^{18}F-FDG PET-CT: diffuse uptake (SUVmax 3.9; largest node 1.2 × 0.8 cm). Inguinal node biopsy: reactive follicular hyperplasia.	Hypogammaglobulinaemia: IgG 5.21, IgA 0.63, IgM 0.57 g/L at presentation; IgG 4.64, IgA 0.58, IgM 0.67 g/L at relapse. γ-globulin fraction 7.2%. C4 persistently low (0.16 g/L); C3 subsequently decreased (0.73 g/L).	No. No clinical or serological evidence of SLE on >10-year follow-up.
Lowe et al., 1992 (case 1)[1] (USA)	Positive. ANA 1:80 (speckled); anti-Ro (SS-A) positive. Anti-La (SS-B), anti-dsDNA, anti-RNP, and anti-Sm negative.	NR	CH50 78 U/ml (low; normal 100–250 U/ml). Serum and urine protein electrophoresis normal. Specific immunoglobulin levels NR.	No. Did not meet SLE criteria. Follow-up ~5 months.
Lowe et al., 1992 (case 2)[1] (USA)	Negative. ANA, anti-Sm, anti-dsDNA, anti-RNP, anti-Ro (SS-A), anti-La (SS-B), and rheumatoid factor all negative.	NR	Total hemolytic complement normal. Serum protein electrophoresis normal. Specific immunoglobulin levels NR.	No. Did not meet SLE criteria. Follow-up ~3 months (30-year CCLE history).
Yoneda et al., 2012[a] (Japan)	Positive. ANA positive (40-fold dilution). Anti-dsDNA within normal range; anti-cardiolipin negative.	NR	C3 and C4 normal. Specific immunoglobulin levels NR.	No. No SLE criteria met; no progression to SLE observed over ~12-year disease course.
Hansen et al., 2024[a] (USA)	Positive. ANA >1:160; anti-Ro-60 (SS-A) positive. Anti-dsDNA, anti-Sm, anti-RNP, anti-Ro-52, and anti-La (SS-B) negative.	NR	Serum immunofixation normal. Specific immunoglobulin levels and complement levels NR.[a]	No. No SLE. Associated rheumatoid arthritis and Sjögren syndrome.

Shaded row denotes the present (index) case. Superscripts in the Case/Source column refer to the reference list of the accompanying manuscript.
[a] Hansen et al. reported that serum immunofixation, urinalysis, and CBC were normal but did not report specific immunoglobulin levels or complement component levels.

Abbreviations: *ANA, antinuclear antibody; anti-CCP, anti-cyclic citrullinated peptide; anti-dsDNA, anti-double-stranded DNA; anti-RNP, anti-ribonucleoprotein; anti-Sm, anti-Smith; CBC, complete blood count; CCLE, chronic cutaneous lupus erythematosus; CH50, total hemolytic complement; C3/C4, complement components 3 and 4; DLE, discoid lupus erythematosus; ^{18}F-FDG PET-CT, 18-fluoro-deoxyglucose positron emission tomography–computed tomography; IgA, immunoglobulin A; IgG, immunoglobulin G; IgM, immunoglobulin M; NR, not reported; PNM, papulonodular mucinosis; SLE, systemic lupus erythematosus; SS-A/Ro, Sjögren-syndrome-related antigen A/Ro; SS-B/La, Sjögren-syndrome-related antigen B/La; SUVmax, maximum standardised uptake value.*

Table 1. Comparison of the present case with previously reported DLE-associated PNM cases.

Case Presentation

A 45-year-old Chinese man presented with a 10-year history of asymptomatic, progressive, skin-coloured papules over the neck, chest, back, and upper limbs. Two years earlier he developed a scalp lesion with alopecia; one year prior, generalised superficial lymphadenopathy. Constitutional and lupus-related symptoms were absent.

Examination revealed numerous 0.5–1.0 cm firm, dome-shaped papules and nodules on the trunk and proximal upper limbs, and a coin-sized, centrally atrophic erythematous scalp plaque. Smooth, non-tender, mobile lymph nodes were palpable bilaterally in submandibular, posterior cervical, supraclavicular, axillary, and inguinal regions.

Histopathology of a trunk nodule showed diffuse dermal mucin deposition between collagen bundles, confirmed by Alcian blue staining. Scalp biopsy showed interface dermatitis with basal vacuolar degeneration, pigment incontinence, and perivascular/periadnexal lymphocytic infiltrates consistent with DLE; direct immunofluorescence showed granular IgG, IgA, and C3 at the dermal–epidermal junction. PET-CT confirmed generalised lymphadenopathy (cervical, axillary, hilar, retroperitoneal, inguinal; largest 1.2 × 0.8 cm); inguinal node biopsy showed reactive follicular hyperplasia, excluding lymphoma and necrotising lymphadenitis.

ANA, anti-dsDNA, anti-Sm, anti-U1-RNP, anti-Ro/SSA, anti-La/SSB, anti-Scl-70, anti-Jo-1, anti-ribosomal-P, and antiphospholipid antibodies, rheumatoid factor, and anti-CCP were repeatedly negative. C4 was persistently low (0.16 g/L); C3 subsequently decreased (0.73 g/L). Immunoglobulins were globally reduced at presentation (IgG 5.21, IgA 0.63, IgM 0.57 g/L) and at relapse (IgG 4.64, IgA 0.58, IgM 0.67 g/L), with diminished γ-globulin fraction (7.2%). No SLE features emerged over >10 years of follow-up.

Oral methylprednisolone (24 mg/day) plus hydroxychloroquine (200 mg twice daily), tapered over ~15 months, produced complete resolution of cutaneous lesions and lymphadenopathy. Approximately 10 months after discontinuation, the patient relapsed and was successfully retreated with methylprednisolone (16 mg/day) and the same dose of hydroxychloroquine.

Fewer than 40 cases of LE-associated PNM have been reported in the English-language literature, and PNM with DLE alone is exceptionally rare; a search of PubMed, Embase, MEDLINE, and Scopus from inception to January 2025 identified only four additional cases. Persistently negative ANA — in contrast to the typically positive ANA in published LE-associated PNM — combined with hypogammaglobulinaemia and low complement suggests an immune-dysregulatory mechanism distinct from classical lupus autoimmunity.

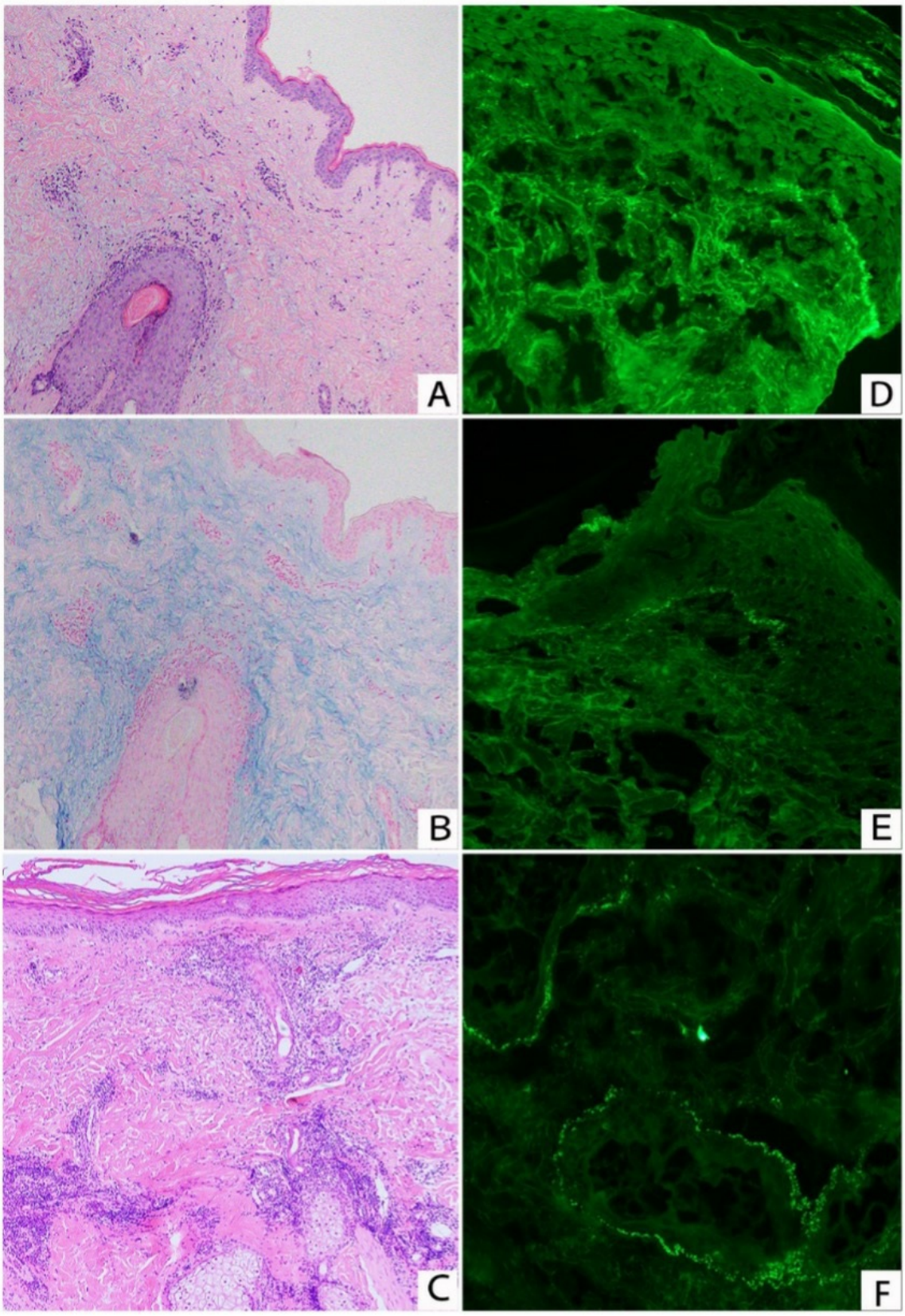

Figure 2. (A) Trunk nodule: increased spacing between dermal collagens from mucin deposition (hematoxylin and eosin, magnification x 100). (B) Trunk nodule: prominent mucin deposition throughout the dermis confirmed by Alcian blue stain (magnification x 100). (C) Scalp plaque: prominent vacuolar interface dermatitis with necrotic keratinocytes, epidermal atrophy, pigment incontinence, and focal perivascular lymphocytic infiltrate (hematoxylin and eosin, magnification x 100). (D-F) Scalp plaque: granular deposition of Complement component 3 [C3] (Panel D), Immunoglobulin G [IgG] (Panel E), and IgA (Panel F) at the dermal-epidermal junction on direct immunofluorescence (magnification x 100).

Conclusion

The co-occurrence of PNM, DLE, and generalised lymphadenopathy without SLE appears unreported; the only previously described PNM case with polyadenopathy rapidly evolved into multisystem SLE, whereas our patient has shown no systemic progression over >10 years. Kikuchi–Fujimoto disease was excluded histologically. Relapse after corticosteroid withdrawal underscores the chronic relapsing course of PNM and the need for sustained immunomodulation. This case expands the spectrum of PNM-associated cutaneous lupus and highlights the value of thorough immunological work-up, nodal biopsy to exclude malignancy, and prolonged surveillance in ANA-negative patients with PNM, DLE, and lymphadenopathy without SLE.

EADV CONGRESS
VIENNA
30 SEP - 3 OCT 2026

Abstract N°: 2203

Early Cutaneous Clues of CEAP C4a Chronic Venous Disease in Dermatology Practice

Halime Kaya*[1]

[1] "Sf. Cuvioasa Parascheva" Clinical Hospital of Infectious Diseases, Galati, Romania

Introduction

Chronic venous disease (CVD) is a progressive vascular disorder associated with substantial morbidity and impaired quality of life. Early cutaneous manifestations such as hyperpigmentation and stasis dermatitis correspond to CEAP C4a-stage disease and may precede venous ulceration. Because these findings are commonly encountered in dermatology practice, dermatologists may play an important role in early recognition before progression to chronic ulcerative disease.

Case Presentation

A 34-year-old male with morbid obesity and hypertension presented with a two-year history of progressive bilateral brownish discoloration and eczematous changes involving the distal lower extremities. Clinical examination revealed symmetrical perimalleolar hyperpigmentation, induration, mild ankle edema, and fine scaling consistent with stasis dermatitis. A sharply demarcated distribution pattern at Wallace's line was observed bilaterally. Dermoscopic evaluation revealed subtle pigmentary and scaling changes consistent with chronic venous skin alterations. Duplex ultrasonography did not demonstrate significant venous abnormalities; however, the characteristic cutaneous findings, sharply demarcated distribution pattern, and longitudinal clinical evolution supported the diagnosis of early chronic venous disease with CEAP C4a-type skin manifestations. Despite the absence of ulceration, the cutaneous findings reflected clinically significant venous hypertension and microcirculatory dysfunction. Early vascular evaluation and conservative management were initiated to reduce the risk of progression to chronic ulcerative disease.

Conclusion

Early cutaneous findings such as hyperpigmentation and stasis dermatitis should not be regarded solely as cosmetic or purely inflammatory changes. Recognition of characteristic clinical distribution patterns, including Wallace's line, together with supportive dermoscopic findings, may facilitate earlier identification of chronic venous disease in dermatology practice. Early recognition of CEAP C4a disease may help prevent progression to chronic venous ulceration, a stage associated with impaired healing, frequent recurrence, and substantial healthcare burden.

EA DV CONGRESS
VIENNA
30 SEP - 3 OCT 2026

Abstract N°: 2203

Prevalence, Clinical Features And Treatment Pattern Of Patients With Coexistence Lupus Erythematosus And Psoriasis: A Retrospective Study In A Single-Center in Taiwan

Ting-Ting Cheng*[1], Yang Lo[1]

[1] Department of Dermatology, Cathay General Hospital, Taipei, Taiwan

Introduction

Patients with systemic lupus erythematosus (SLE) are at increased risk of developing multiple comorbidities. From a dermatological perspective, the coexistence of SLE and psoriasis (PSO) is rare, with a prevalence of 3.4% reported in Caucasian populations.However, such an overlap presents unique diagnostic and therapeutic challenges. Management of patients with coexisting SLE and PSO is particularly complex due to the potential for treatment-induced disease exacerbation. For example, ultraviolet phototherapy, a mainstay in PSO treatment, can provoke or worsen SLE activity. Tumor necrosis factor-alpha inhibitors have been associated with drug-induced lupus-like syndromes in post-marketing studies. Conversely, antimalarial agents and systemic corticosteroids, commonly used in the management of SLE, have been reported to trigger or exacerbate psoriatic lesions.

Historically, PSO has been linked to Th1-mediated immune responses, whereas lupus erythematosus has been considered a Th2-driven condition. However, recent evidence highlights a shared pathogenic mechanism involving the Th17 axis and interleukin (IL)-23/IL-17 pathway in both diseases.This immunologic overlap may explain the observed coexistence and opens the door for targeted therapeutic strategies. Case series have reported favorable outcomes using IL-12/23 inhibitors such as ustekinumab in patients with overlapping SLE and PSO.

The objectives of this study were to determine the prevalence of PSO among patients diagnosed with SLE, to characterize the clinical features, laboratory profiles, and treatment patterns in patients with coexisting SLE and psoriasis, and to compare comorbidities between patients with and without PSO in the context of lupus.

Materials and Methods

We conducted a retrospective, single-center study from 2007 to 2023 at Cathay General Hospital, a tertiary medical center in Taiwan, identifying patients diagnosed with both SLE and PSO. Clinical features, laboratory profiles, treatment patterns, and comorbidities were analyzed.

Results

A total of 12 patients with coexisting SLE and PSO were identified, yielding a prevalence of 1.5% among patients with SLE. Plaque psoriasis was the predominant subtype, and the disease was mild in most cases. Compared to the SLE-only group, the coexistence group had a higher proportion of males. No significant differences were observed in typical lupus manifestations or most laboratory parameters, except for a lower frequency of reduced complement levels in the coexistence group. No additional cardiovascular risk was identified.

Table 1. Clinical Characteristics of SLE patients with concomitant PSO

Patient demographics	
Females/males	8/4
Mean age (years)	55.5 ±18.4 ; 60.5
Mean age at diagnosis of SLE (years)	39.82±19.12 ; 42
Mean age at diagnosis of psoriasis (years)	44.25±18.49 ; 41
Patients diagnosed with SLE first	N=9
Latency period between diagnoses (years)	7.33±4.52 ; 5
Patients diagnosed with psoriasis first	N=2
Latency period between diagnoses (years)	5±0 ; 5
Psoriasis types	
Plaque psoriasis	11(91.67%)
Intertriginous psoriasis	1(8.33%)
Psoriasis arthritis	1(8.33%)
Cutaneous lupus erythematosus types	
ACLE	6(50%)
SCLE	1(8.33%)
DLE	2(16.67%)

Values are n (%) or mean ± SD ; median. One patient unknown onset age of SLE

Table 2. Treatment of SLE patients with concomitant PSO

SLE treatment at psoriasis diagnosis	
Without treatment	5(41.67%)
Antimalarials alone	2(16.67%)
Antimalarials + Corticosteroids	2(16.67%)
Sulfasalazine + Methotrexate	2(16.67%)
Antimalarials + Corticosteroids +Mycophenolate	1(8.33%)
Treatment for psoriasis	
Topical treatment ever	12(100%)
Methotrexate ever	3(25%)
Acitretin ever	1(8.33%)
Etanercept ever	2(16.67%)
Ixekizumab ever	1(8.33%)
Phototherapy ever	1(8.33%)

Values are n (%).

Table 3. Comparison between SLE patients with concomitant psoriasis and without psoriasis regarding clinical and laboratory features

Variable	Psoriasis (n=12)	Without psoriasis(n=796)	*p*
Gender			0.010
Female	8	737	
Male	4	59	
Oral ulcer ever	5(41.7%)	173(21.7%)	0.150
Photosensitivity ever	5(41.7%)	176(22.1%)	0.153
Malar rash ever	4(33.3%)	127(20%)	0.114
Alopecia ever	6(50%)	381(47.9%)	1.000
Arthritis ever	8(66.7%)	560(70.4%)	0.757
Serositis ever	0(0%)	85(10.7%)	0.626
Renal involvement ever	2(16.7%)	232(30%)	0.525
Neurologic involvement ever	1(8.3%)	44(5.5%)	0.500
Leukopenia ever	4(33%)	492(61.8%)	0.069
Anemia ever	6(50%)	578(72.6%)	0.228
Thrombocytopenia ever	2(16.7%)	296(37.2%)	0.103
Low C3/C4 ever	5/11(45.5%)	731(92.3%)	0.000
Anti-dsDNA (+) ever	7/12(58.3%)	548(70.1%)	0.362
Anti-SSA/Ro (+)	3/10(30.0%)	407(59.0%)	0.102
Anti-SSB/La (+)	0/10(0%)	165(23.9%)	0.128
Anti-Sm (+)	1/9(11.1%)	153(27.2%)	0.456
Anti-RNP (+)	1/9(11.1%)	208(37.0%)	0.165
Anti-cardiolipin (+)	1/7(14.3%)	241(37.9%)	0.264

Values are n (%).

Table 4. Comparison between SLE patients with concomitant psoriasis and without psoriasis regarding comorbidities

Variable	Psoriasis (n=12)	Without psoriasis (n=796)	*p*
Thyroid disorder*	1(8.33%)	120(16.2%)	1.000
Sjögren syndrome	2(16.7%)	129 (15.1%)	1.000
Vitiligo	0(0%)	7(0.9%)	1.000
Rheumatic arthritis	2(16.7%)	38(4.8%)	0.115
Urticaria	1(8.33%)	44(5.5%)	0.500
Pulmonary hypertension	0(0%)	21(2.6%)	1.000
Interstitial lung disease	0(0%)	15(1.9%)	1.000
Dyslipidemia	5(41.7%)	227(28.5%)	0.341
Hypertension	4(33.3%)	261(32.8%)	1.000
Diabetes mellitus	2(16.7%)	47(5.9%)	0.161
Malignancy	2(16.7%)	75(9.4%)	0.319
Cardiovascular event**	1(8.33%)	90(11.3%)	1.000
Osteoporosis	1(8.33%)	113(14.2%)	1.000

*Thyroid disorder was defined as any condition resulting in either hyperthyroidism or hypothyroidism, including diagnoses such as Graves' disease, goiter, and Hashimoto's thyroiditis. **Cardiovascular events

Conclusions

In conclusion, this retrospective study conducted in Taiwan demonstrated that the coexistence of PSO and SLE is a rare clinical entity, with a prevalence of approximately 1.5% among patients with SLE. A higher proportion of male patients was observed in the coexistence group. Overall, the clinical and most laboratory characteristics of patients with both conditions were comparable to those with SLE alone. PSO in this cohort was generally mild to moderate in severity and could be managed with topical therapies. For more severe or refractory cases, newer agents such as deucravacitinib may offer therapeutic potential. Importantly, no additional cardiovascular risk was identified in patients with both diseases. These findings highlight the need for increased awareness and individualized management strategies in this unique subgroup of autoimmune patients.

EA DV CONGRESS
VIENNA
30 SEP - 3 OCT 2026

Abstract N°: 2234

Clinical–endocrine dissociation in hirsutism: Relationship between androgens, body mass index, and clinical severity

Divya Madonna Dsouza*[1], Martis Jacintha[1]

[1] Father Muller Medical College Hospital, Mangalore, India

Introduction
Hirsutism reflects androgen excess or increased peripheral sensitivity, yet the relationship between circulating androgens and clinical severity remains inconsistent. Data from South Asian populations are limited. This study evaluated androgen profiles in women with hirsutism and assessed their association with body mass index (BMI), waist–hip ratio (WHR), and severity using the modified Ferriman–Gallwey (mFG) score.

Materials and Methods
A prospective cross-sectional study was conducted over 18 months in 72 women aged 15–45 years presenting with hirsutism. Clinical evaluation included mFG scoring, BMI, waist circumference, and WHR. Serum total testosterone (TT), dehydroepiandrosterone sulfate (DHEAS), sex hormone-binding globulin (SHBG), and 17-hydroxyprogesterone (17-OHP) were measured using ELISA. Free androgen index (FAI), calculated free testosterone (cFT), and calculated bioavailable testosterone (cBT) were derived. Statistical analyses included the Kolmogorov–Smirnov test, Mann–Whitney U test, Chi-square/Fisher's exact test, and Spearman's correlation.

Results
The mean age was 26.6 ± 6.4 years, with 74.9% aged 18–30 years. Mild hirsutism predominated (63.9%) using global mFG cut-offs; all participants were classified as hirsute using ethnicity-specific thresholds. Overweight and obesity were present in 72.2% of participants; however, BMI was not associated with hirsutism severity ($p=0.176$). Cutaneous hyperandrogenic manifestations included female pattern hair loss (41.7%), acne (27.8%), seborrhoea (30.6%), and acanthosis nigricans (34.7%). Menstrual irregularities were observed in 37.5%, and 51.4% reported a sedentary lifestyle. Biochemically, elevated TT was observed in 80.6%, DHEAS in 15.3%, and 17-OHP in 47.2% of participants. No significant correlation was found between mFG scores and TT ($p=0.075$), DHEAS ($p=0.744$), SHBG ($p=0.772$), or 17-OHP ($p=0.305$). Similarly, FAI, cFT, and cBT did not correlate with clinical severity. BMI demonstrated a significant inverse correlation with SHBG ($\rho = -0.270$, $p=0.025$) and weak but significant positive correlations with cFT ($p=0.014$) and cBT ($p=0.006$). TT showed a strong positive correlation with FAI ($\rho=0.678$, $p<0.001$), but not with cFT or cBT. Waist–hip ratio was elevated across both lean and obese PCOS groups, with no significant difference between them, and showed no association with hirsutism severity. Mild hirsutism predominated across BMI categories, while severe hirsutism was relatively more frequent in obese individuals (9.1%). The upper lip and chin were the most commonly affected sites. Polycystic ovary syndrome (36%) and idiopathic hirsutism (40.3%) were the most common etiologies. Other causes included non-classic congenital adrenal hyperplasia and SAHA syndrome (9.7% each), HAIR-AN syndrome (5.5%), suspected androgen-secreting tumors (2.7%), and one case of Cushing's disease.

Table 1: Comparison of SHBG, Free Androgen Index, calculated Free Testosterone, and calculated Bioavailable Testosterone across BMI categories

Parameter	BMI <25kg/m^2 (n=33)	BMI ≥25kg/m^2 (n=36)
Sex Hormone Binding Globulin (nmol/L)	417.90 (± 601.90)	300.14 (± 490.56)
Free Androgen Index (FAI)	117.09 (± 142.75)	108.87 (± 132.02)
Calculated free testosterone (cFT)	0.49 (± 0.28)	0.55 (± 0.27)
Calculated Bioavailable testosterone (cBT)	0.68 (± 0.25)	0.78 (± 0.27)

Table 1. Comparison of SHBG, free androgen index, calculated free testosterone, and calculated bioavailable testosterone across body mass index categories. Values are presented as mean ± standard deviation. SHBG: sex hormone–binding globulin; FAI: free androgen index; cFT: calculated free testosterone; cBT: calculated bioavailable testosterone.

Conclusions

Hirsutism is a multifactorial disorder requiring an integrated dermatologic–endocrine approach. Clinical severity showed poor correlation with androgen levels, supporting a role for peripheral androgen sensitivity. Body mass index and waist–hip ratio were not reliable predictors of androgen excess or disease severity, although reduced sex hormone–binding globulin may influence androgen bioavailability independent of obesity. Lifestyle modification remains an essential component of management across all body mass index categories.

EA DV CONGRESS
VIENNA
30 SEP - 3 OCT 2026

Abstract N°: 2248

IgG4-related disease: A diagnostic dilemma for 20 years

Alexandra Murray*[1], Jillian Wells[1]

[1] Westmead Hospital, Westmead, Australia

Introduction

Immunoglobulin G4-related disease (IgG4-RD) is a rare fibroinflammatory disorder, characterised by infiltrates of IgG4-positive plasma cells in affected tissues. Originally thought to be a pancreas-limited disease, broader multi-organ involvement was first described in 2001. IgG4-RD was only formally recognised as a disease entity in 2011. Given the systemic nature of the disease, clinical features are diverse. Diagnosis should be suspected when there is clinical or radiological evidence of characteristic organs showing mass lesions or wall thickening. Additional supporting evidence includes elevated serum IgG4 and histopathology demonstrating dense lymphoblastic infiltrate with high IgG4/IgG ratio. Management is aimed at reducing disease activity and preventing irreversible fibrotic damage, with use of oral corticosteroids and biologic therapies. Response to treatment varies depending on the organs involved, duration of disease and degree of fibrosis present.

Case Presentation

A 65-year-old man had a 20-year history of painless bilateral periorbital and right cheek swelling. In the years following, he developed cervical lymphadenopathy and a pruritic papular eruption across his arms and back, the severity of which had been fluctuating over time. His past medical history was significant for IgA nephropathy, resolved hepatitis B infection, hyperlipidaemia and hypertension and his only regular medication was atorvastatin. Biopsies of the facial swelling and cutaneous manifestations at the time showed dense lymphoplasmacytic infiltrate of the dermis and subcutaneous fat. IgG4 immunostaining was not performed, as IgG4-RD was not yet recognised as a systemic disease. He was reviewed by ophthalmology, immunology and dermatology clinicians with no definitive diagnosis or long-term management instigated.

In 2025, he developed right sided paraesthesia and was found to have a left thalamic stroke, attributed to atherosclerosis. An MRI head was performed, with coincidental findings of bilateral lateral recti muscle and left infraorbital nerve enlargement, diffuse periorbital swelling and nodular wall thickening of the right pre-malar soft tissues. The radiologist proposed the possibility of a concurrent IgG4-RD diagnosis.

Following this admission, he was reviewed in the outpatient immunology and dermatology clinics. On examination, he had significant bilateral periorbital oedema, right cheek oedema, cervical lymphadenopathy and a widespread, lichenified pink papular eruption across his arms, upper back and knees. Blood results demonstrated mildly deranged kidney function (eGFR 68, Creatinine 100), elevated total IgG (22g/L) and significantly elevated IgG4 levels (14.7g/L). A CT pan scan showed intraparotid, cervical and axillary lymphadenopathy, with no other evidence of internal disease. Periapical lucency of tooth 4-8 and atherosclerotic disease in coronary artery and aortic arch was also noted.

Repeat biopsies were taken from the back and right cheek, which showed mild-moderate dermal lymphoplasmacyticinfiltrate and papillary dermal fibrosis. IgG staining revealed an IgG4/IgG ratio >40% in both samples. The clinical, serological, radiological and pathological findings were supportive of a diagnosis of systemic IgG4-RD. He is planned to be treated with prednisolone and rituximab, following clearance from hepatology clinicians, regarding hepatitis B reactivation risk, and from dental clinicians, to address the 4-8 tooth findings.

Conclusion

This case represents the variety of clinical presentations and diagnostic complexity of IgG4-RD, contributing to a 20-year delay in diagnosis. Cutaneous manifestations can aid in early diagnosis by providing accessible histopathological evidence of disease. Given the trajectory of chronic inflammation and irreversible fibrosis demonstrated in this condition, greater awareness is warranted to reduce diagnostic delay and initiate early treatment.

EA DV CONGRESS
VIENNA
30 SEP - 3 OCT 2026

Abstract N°: 2334

Improvement in CLA-IGA(-R) outcomes with enpatoran in participants with active cutaneous manifestations of lupus with or without systemic disease: post-hoc analysis of the phase II WILLOW study

Joseph F. Merola*[1], Eric Morand[2], Richard Furie[3], David R Pearson[4], Sanjeev Roy[5], Ruth Fernandez-Ruiz[6], Summer Goodson[6], Genevieve Jehl[7], Victoria Werth[8]

[1] Department of Dermatology and Department of Medicine, Division of Rheumatology, UT Southwestern Medical Center and O'Donnell School of Public Health, Dallas, TX, United States

[2] Centre for Inflammatory Diseases, Monash University, Melbourne, Vic, Australia

[3] Division of Rheumatology, Northwell Health, Great Neck, NY, United States

[4] Department of Dermatology, University of Minnesota, Minneapolis, MN, United States

[5] Global Clinical Development, Ares Trading SA, an affiliate of Merck KGaA, Eysins, Switzerland

[6] Global Clinical Development, EMD Serono Research & Development Institute, Inc., an affiliate of Merck KGaA, Billerica, MA, United States

[7] Merck Sant S.A.S, an affiliate of Merck KGaA, Lyon, France

[8] Department of Dermatology, Perelman School of Medicine, University of Pennsylvania, and Corporal Michael J Crecenz VAMC, Philadelphia, PA, United States

Introduction

There are no approved systemic therapies with a primary indication for cutaneous lupus. Enpatoran is an oral, selective, potent and reversible dual inhibitor of toll-like receptors 7/8 (TLR7/8), which are upstream drivers of the interferon pathway and neutrophil, myeloid and B-cell activation, and have roles in innate and adaptive immune responses that lead to inflammation in lupus. In the phase II WILLOW trial (NCT05162586), enpatoran improved Cutaneous Lupus Erythematosus Disease Area and Severity Index-Activity (CLASI-A) total score and CLASI-50/70 response rates at Week 24 vs placebo (pbo) in participants (pts) with active cutaneous manifestations of lupus, with or without systemic disease activity. Remission from cutaneous disease activity, defined in the absence of a standard definition, as CLASI-A ≤3 or Cutaneous Lupus Activity Investigator's Global Assessment (CLA-IGA) 0 or 1 (clear or almost clear) also improved with enpatoran vs pbo at Week 24. The CLA-IGA-Revised(R) tool allows separate assessment of three domains: Erythema, Other Morphologic Characteristics (OMC), and Follicular Activity.

Materials and Methods

Pts were randomised to twice-daily enpatoran (25 mg, 50 mg or 100 mg) or pbo for 24 weeks, plus standard of care. This was a post-hoc, exploratory analysis of pts with active cutaneous manifestations (CLASI-A ≥8 at screening and baseline [BL]) of lupus with or without systemic disease. CLA-IGA score 0/1 at Week 24 was a secondary endpoint in WILLOW; pts with events affecting the outcome were counted as non-responders. CLA-IGA-R Erythema score 0/1 at Week 24 was an exploratory endpoint and all available data were analysed regardless of such events. Here, we also present CLA-IGA-R OMC score 0/1 (clear or almost clear), and CLA-IGA-R Follicular Activity 'Absent', at Week 24. CLA-IGA was assessed in all pts with active cutaneous manifestations of lupus. After a protocol amendment, CLA-IGA-R data were collected where possible at BL and post-BL, irrespective of a BL assessment.

Results

Overall, 262 pts enrolled in WILLOW had active cutaneous manifestations at BL and screening and CLA-IGA data at

BL and Week 24. Of these, 81 had CLA-IGA-R data at BL and 131 had CLA-IGA-R data at Week 24. Only one pt (in the pbo group) had CLA-IGA 0/1 at BL. Rates of CLA-IGA 0 /1 with enpatoran 25 mg, 50 mg and 100 mg began differentiating from pbo from Week 4 (8/52 [15.4%], 8/59 [13.6%] and 13/62 [21.0%] vs 6/55 [10.9%] respectively) and were higher with enpatoran vs pbo as early as Week 12 (17/52 [32.7%], 19/62 [30.6%] and 31/69 [44.9%] vs 11/65 [16.9%]); rates continued to improve with enpatoran through Week 24 (24/52 [46.2%], 31/63 [49.2%] and 48/76 [63.2%] vs 21/67 [31.3%]). In pts with CLA-IGA-R data at BL, 2/19 (10.5%) pts in the pbo group and 0 pts across all enpatoran groups had Erythema 0 or 1; and 8/19 (42.1%) pts receiving pbo and 6/19 (31.6%), 11/26 (42.3%), 6/17 (35.3%) pts in the enpatoran 25 mg, 50 mg and 100 mg groups, respectively, had OMC 0 or 1. Rates of CLA-IGA-R Erythema and OMC 0/1 with enpatoran and pbo at Week 24 are shown in Figures A and B. At BL, 14/19 (73.7%), 23/26 (88.5%) and 12/17 (70.6%) pts in the enpatoran 25 mg, 50 mg and 100 mg groups, respectively, had CLA-IGA-R Follicular Activity 'Absent' vs 16/19 (84.2%) pts receiving pbo. At Week 24, 30/32 (93.8%), 34/36 (94.4%) and 30/32 (93.8%) pts in the 25 mg, 50 mg and 100 mg groups had CLA-IGA-R Follicular Activity 'Absent', respectively, vs 26/31 (83.9%) pts receiving pbo.

Figure. (A) CLA-IGA-R Erythema[a] 0 or 1 or (B) CLA-IGA-R OMC 0 or 1 at Week 24 with enpatoran vs placebo in pts with active cutaneous manifestations of lupus, with or without systemic disease activity[b]

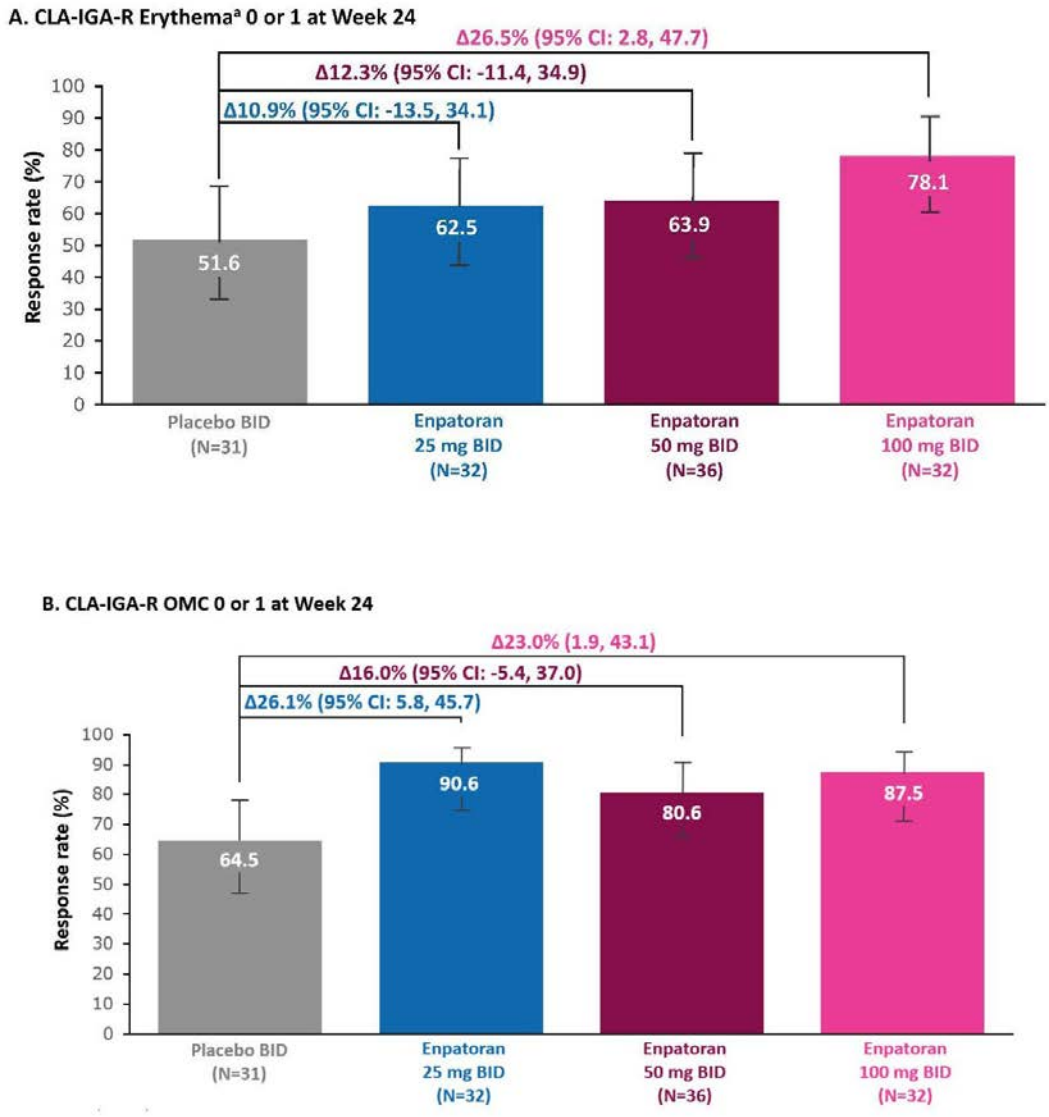

[a]WILLOW exploratory endpoint.
[b]Post-hoc exploratory analysis (pts from WILLOW Cohorts A and B with CLASI-A ≥8 at baseline and CLA-IGA-R data, N=131).
95% CI of Erythema response rate is computed using Clopper–Pearson method.
95% CI of OMC response rates are computed using Newcombe–Wilson Score Method.
95% CI of difference in response rates are computed using non–stratified Miettinen–Nurminen method.
BID, twice daily; CI, confidence interval; CLA-IGA-R, Cutaneous Lupus Activity investigator's Global Assessment-Revised; CLASI-A, Cutaneous Lupus Disease Area and Severity Index-Activity; OMC, Other Morphologic Characteristics; pts, participants.

Conclusions

In pts with active cutaneous manifestations of lupus, with or without systemic disease activity, enpatoran tended to increase remission rates vs pbo based on CLA-IGA 0/1, and overall CLA-IGA-R data (Erythema, OMC 0/1 and Follicular Activity ‘Absent’); onset of effect may be as early as Week 4. These data support ongoing evaluation of enpatoran in the phase III ELOWEN-1 (NCT07332481) and ELOWEN-2 (NCT07355218) trials.

EA DV CONGRESS
VIENNA
30 SEP - 3 OCT 2026

Abstract N°: 2396

The Women's Health Initiative Revisited: How Misinterpretation of a Landmark Trial Created Unwarranted Fear and Disadvantaged a Generation of Women

Mary Alice Mina*[1]

[1] Baucom & Mina Derm Surgery, LLC, The Skin Real, LLC, Emory University, Department of Dermatology, Atlanta, United States

Introduction

The 2002 publication of the Women's Health Initiative (WHI) hormone therapy trial results triggered one of the most dramatic reversals in prescribing history, with a 70–80% reduction in hormone therapy (HT) prescriptions worldwide. The trial, which enrolled 27,347 postmenopausal women aged 50–79 (mean age 63), was stopped early after finding increased risks of breast cancer, stroke, and venous thromboembolism with conjugated equine estrogens (CEE) plus medroxyprogesterone acetate (MPA). However, the initial presentation of these findings created widespread fear that led to a generation of women who were withheld effective treatment. Over two decades of reanalysis have revealed critical design limitations and interpretive errors that demand a paradigm shift in clinical practice. As the skin is the largest hormonal receptive organ, understanding the role of estrogen systemically and locally is important for dermatologists to understand.

Materials and Methods

A narrative literature review was conducted using PubMed, EMBASE, and Cochrane databases through May 2026. Sources included the original WHI publications, subsequent WHI reanalyses and age-stratified secondary analyses, the 2025 Cochrane systematic review, society guidelines (AHA, ACOG, NAMS, Endocrine Society), and observational studies comparing modern HT formulations. Search terms included "Women's Health Initiative limitations," "timing hypothesis hormone therapy," "menopausal hormone therapy safety," and "bioidentical estradiol versus conjugated equine estrogens."

Results

The WHI was designed to test chronic disease prevention in older postmenopausal women (mean age 63.3) — not symptom management in recently menopausal women. Only 33% were aged 50–59, and only one formulation was tested (oral CEE ± MPA), which does not reflect modern prescribing. Absolute excess risks in women aged 50–59 were remarkably small: fewer than 12 additional adverse events per 10,000 women per year for CEE+MPA, and 19 fewer events per 10,000 for CEE alone. When adjusted confidence intervals were applied, the only significant increase was for DVT.

Age-stratified reanalyses vindicated the timing hypothesis: early-initiation HT reduced CHD risk by ~50% (RR 0.52, 95% CI 0.29–0.96) and all-cause mortality by 30% (RR 0.70, 95% CI 0.52–0.95). A 2025 WHI secondary analysis confirmed HT relieved vasomotor symptoms without raising atherosclerotic CVD risk in women aged 50–59. The CEE-alone arm showed no breast cancer increase — a significant reduction emerged at 20-year follow-up (HR 0.78, 95% CI 0.65–0.93) with reduced breast cancer mortality (HR 0.38). Observational data suggest transdermal estradiol

carries lower VTE/stroke risk than oral CEE, and micronized progesterone may have a more favorable breast safety profile than MPA — neither was tested in the WHI. Post-WHI, MHT initiation rates dropped from 8.6% to 2.8%, with the largest declines in younger symptomatic women — the population for whom HT carries the lowest risk and greatest benefit.

Conclusions

The WHI remains a landmark contribution to women's health research, but its legacy has been marred by flawed initial interpretation and overgeneralization. Two decades of reanalysis, including by the WHI's own principal investigators, have established that: (1) timing of initiation is the critical determinant of cardiovascular risk; (2) estrogen-only therapy does not increasem and may decrease, breast cancer risk; (3) modern formulations (transdermal estradiol, micronized progesterone) likely carry lower risks than the regimens studied; and (4) the absolute risks in younger symptomatic women are exceedingly small. The persistent undertreatment of menopausal symptoms represents a failure of evidence translation. Clinical practice must evolve to reflect the nuanced, individualized approach that the totality of WHI data, not just the 2002 headlines, supports.

EADV CONGRESS
VIENNA
30 SEP - 3 OCT 2026

Abstract N°: 2399

Rowell Syndrome : a distinct entity or a mere association between lupus erythematosus and erythema multiforme ?

Chaima Ezzaki*[1], sokaina chhiti[1], mhaimer soukaina[1], safae el msayryb[1], chaouche mohammed[1], Radia Chakiri[1]

[1] Department of Dermatology, Faculty of Medicine and Pharmacy, Ibn Zohr University, Agadir, Morocco, agadir, Morocco

Introduction

Rowell syndrome (RS) is a rare condition defined by the coexistence of lupus erythematosus (LE) and erythema multiforme (EM) like lesions, associated with distinctive immunological pattern.

The diagnosis can be challenging and is based on multiple criteria.

Case Presentation

We report the case of a 13-year-old girl with a history of recurrent undocumented gingivostomatitis and photosensitivity, who presented with respiratory symptoms followed by painful oral erosions, conjunctival hyperemia, genital erythema, and polymorphic cutaneous lesions including annular erythematous patches, papules, bullae, and targetoid lesions on the extremities, associated with fever. Laboratory investigations revealed positive ANA (1:160), positive anti-Ro52 antibodies, hypocomplementemia (C3 :0,55g/L), and proteinuria, while infectious workup (*Mycoplasma*, HIV, hepatitis B, and hepatitis C) was negative.. A skin biopsy was performed, histopathological examination showed liquefactive keratinocyte necrosis in the epidermis, mild spongiosis, and a moderate perivascular lymphohistiocytic inflammatory infiltrate in the dermis, consistent with erythema multiforme. Based on the clinico-biological findings, the patient was treated with prednisone (1 mg/kg/day) and hydroxychloroquine (200 mg/day), with complete resolution of lesions after two months.

Conclusion

Rowell syndrome is a distinct and rare condition, who was initially described in 1963 by Rowell et al.. It is characterized by an unusual presentation of LE with EM-like lesions associated with distinctive serological findings. The disease predominantly affects young adults, with a reported median age of 32 years, however pediatric and elderly cases have also been reported. RS shows a marked female predominance (female to male ratio is 8:1). RS is frequently preceded by history of LE, but it has been reported to be its first sign.

The diagnosis of RS is based on precise diagnostic criteria, although these remain debated across different studies. In 2000, Zeitouni proposed three major criteria ; LE (acute, subacute, or systemic), EM-like lesions, and speckled ANA pattern, and three minor criteria ; including anti-SSA or anti-SSB antibodies, RF positivity, and chilblains. All major criteria and at least one minor criterion are necessary for RS diagnosis [4]. Before considering a diagnosis of RS, common triggering factors such as bacterial an viral infections, drugs, and malignancies, should be carefully excluded. The histological findings of RS reveal EM and/or LE-like manifestations, the presence of necrotic keratinocytes is not specific for EM, since it might also be found in cutaneous LE. Although diagnostic criteria for RS have been proposed, its existence as a distinct entity remains controversial. Some authors suggest that LE with EM-like lesions may represent a subset of subacute cutaneous LE, while others consider it to be only a coincidental association. In our case, the patient presented with features of EM without any identifiable triggerings factors.

Further investigations revealed an underlying systemic LE. None of the minor diagnostic criteria for RS were present. This raises the question of wether this represents a simple association between LE and EM-like lesions, or wether it should be considered as Rowell syndrome.

There is no standardized treatment for RS, the therapeutic approach and prognosis are generally similar to those of isolated systemic LE or discoid LE. Most reported cases have shown good responses to systemic corticosteroids combined with agents such as azathioprine, antimalarials (chloroquine or hydroxychloroquine), dapsone, or cyclosporine.
Our case illustrate the importance of considering Rowell syndrome and performing thorough investigations for underlying systemic autoimmune disease, in patients presenting initially as EM-like lesions without identifiable triggering factors, in order to faciliate early management and improve prognosis.

EADV Congress 2026, VIENNA
30 SEPTEMBER - 03 OCTOBER 2026
POWERED BY M-ANAGE.COM

EADV CONGRESS
VIENNA
30 SEP - 3 OCT 2026

Abstract N°: 2402

Perianal Crohn Disease or Hidradenitis Suppurativa? A Diagnostic Pitfall

Gülay Keyik*[1], Doğuhan Inalöz[1], Yusuf Can Edek[1], İrem Özdemir[1], Esra Adışen[1]

[1] Gazi University Faculty of Medicine, Department of Dermatology and Venereology, Ankara, Türkiye

Introduction

Perianal fistulizing Crohn disease (CD) and hidradenitis suppurativa (HS) are distinct inflammatory conditions that can coexist and present with nearly identical clinical and radiologic features, making accurate diagnosis challenging. Both disorders affect the perianal and intertriginous regions, manifest with abscesses, sinus tracts, and scarring, and share overlapping immunopathologic mechanisms driven by dysregulated innate immunity and TNF-alpha.

The association between HS and inflammatory bowel disease is well established, with CD patients carrying a substantially higher risk of HS compared to the general population. Despite this known comorbidity, concomitant HS and perianal CD is frequently underrecognized in clinical practice. The two conditions require different treatment strategies and surgical approaches. Magnetic resonance imaging (MRI) has emerged as a valuable tool for differentiating the two entities.

Here we report a case of a patient with known fistulizing CD who developed progressive perianal and gluteal lesions refractory to infliximab, in whom clinicopathologic and radiologic evaluation revealed coexisting perianal HS. This case highlights the importance of maintaining a broad differential diagnosis in patients with perianal disease and illustrates how systematic use of imaging and histopathology can guide management when two conditions simultaneously contribute to the clinical picture.

Case Presentation

A 33 year old man with a five year history of fistulizing CD presented with progressive perianal and gluteal lesions despite receiving infliximab (5 mg/kg monthly), in the absence of active gastrointestinal symptoms. Physical examination revealed multiple erythematous nodules, abscesses, superficial ulcerations, and interconnected sinus tracts involving the perianal, gluteal, and scrotal regions (Figure 1). Pelvic MRI demonstrated complex transsphincteric perianal fistulizing disease along with diffuse inflammatory thickening of the perineal and gluteal skin and subcutaneous tissue. The associated superficial sinus tracts and intertriginous distribution raised suspicion for concomitant HS. Histopathologic examination revealed psoriasiform epidermal hyperplasia with neutrophilic microabscesses, without evidence of noncaseating granulomas.The patient underwent surgical drainage, and the infliximab dose was increased to 10 mg/kg monthly. During follow up, drainage decreased, and the lesions partially regressed. Overall, the clinicopathologic and radiologic findings supported the coexistence of perianal HS and fistulizing CD.

Conclusion

HS is more common in patients with inflammatory bowel disease, especially those with CD [1]. On MRI, CD usually

shows transsphincteric or intersphincteric fistulas, while HS more frequently involves subcutaneous tunnels and inflammation of the subcutaneous tissue and skin [2]. In our patient, MRI findings suggestive of both CD and HS, along with the absence of active gastrointestinal symptoms, supported the diagnosis of coexisting conditions. The absence of noncaseating granulomas made metastatic cutaneous CD less likely. Recognizing this coexistence is clinically important because treatment approaches and surgical indications differ between the two conditions [2].

EA DV CONGRESS
VIENNA
30 SEP - 3 OCT 2026

Abstract N°: 2435

Acquired Pili Torti in Scurvy: A Novel Dermoscopic Finding Suggestive of Early Disease

Alessandro Gradassi*[1], Arunima Batra[2]

[1] London North West Healthcare, London, United Kingdom
[2] Chelsea and Westminster Hospital, London, United Kingdom

Introduction

Scurvy, caused by vitamin C deficiency, is an increasingly recognised but still underdiagnosed nutritional disorder in developed countries, particularly among individuals with alcohol dependence, malnutrition, or restrictive diets. Cutaneous manifestations include perifollicular purpura, hyperkeratosis, and corkscrew hairs, reflecting impaired collagen synthesis and vascular fragility. Dermoscopy may aid early diagnosis by identifying characteristic follicular changes. We present a novel dermoscopic finding of acquired pili torti associated with scurvy, which may represent an early manifestation of disease.

Case Presentation

A 56-year-old gentleman with a history of alcohol dependence was referred for dermatological review of a widespread rash affecting the lower limbs. Clinical examination demonstrated purpuric follicular papules distributed symmetrically over both legs. Contactless dermoscopy revealed whitish to orangish perifollicular papules centred by corkscrew hairs and twisted hair shafts consistent with pili torti, surrounded by a purpuric halo.

Given the clinical and dermoscopic findings, nutritional deficiency was suspected. Laboratory investigations confirmed severe vitamin C deficiency, with plasma levels <0.1 mg/dL (reference range 0.3–0.5 mg/dL), while zinc and copper levels were normal. Oral ascorbic acid supplementation (500 mg twice daily) resulted in complete resolution of the cutaneous lesions within 10 days.

The dermoscopic features of scurvy are classically characterised by corkscrew hairs surrounded by pale whitish or yellowish perifollicular changes and a purpuric halo due to perifollicular haemorrhage. In this case, acquired pili torti was additionally observed, potentially resulting from rotational distortion and traction of the hair shaft secondary to perifollicular fibrosis.

Conclusion

To our knowledge, this is the first reported case describing acquired pili torti in association with scurvy. The coexistence of pili torti and corkscrew hairs may represent an early dermoscopic marker of vitamin C deficiency, particularly in patients without advanced systemic manifestations. Recognition of these subtle features may facilitate earlier diagnosis and prompt treatment, preventing potentially serious complications of scurvy.

EADV CONGRESS
VIENNA
30 SEP - 3 OCT 2026

Abstract N°: 2440

Beyond the Skin: Exploring the Rosacea Skin-Gut Axis and Novel Therapeutic Avenues

Kamilla Irgasheva*[1], Nilufar Malikova[1]

[1] Central Asian University, Tashkent, Uzbekistan

Introduction

Rosacea was believed to be confined to the skin, mostly influenced by external triggers such as UV light, demodex mites and bacteria on the skin. Current evolving research suggests that pathophysiology of rosacea is strongly associated with the state of gut microbiome and gastrointestinal comorbidities.

Materials and Methods

Multiple articles publsihed between January 2010 and March 2026 on electronic databases (PubMed, EMBASE, Cochrane Library, and Google Scholar) were studied and reviewed.

Results

Clinically, it promotes and necessitates a close interconnection of dermatologists and gastroenterologists in the diagnosis and treatment of rosacea patients. Therapeutically, it emphasizes the need for novel treatment approaches. Topical postbiotics, microencapsulated delivery, PDE4 inhibitors have shown positive results in the recent trials.

The reviewed articles have shown that rosacea patients are much more likely to exhibit GI comorbidities than control group patients. Most common were: Small Intestinal Bacterial Overgrowth (SIBO), H.pylori infection and Inflammatory Bowel Diseases (IBD). Eradication of SIBO with Rifaximin showed a complete clearance of rosacea lesions in 72% of patients. This highlights the need to reevaluate the treatment approach to rosacea which currently concentrates on topical therapy.

Conclusions

Addressing the issue systemically, by normalizing the gut microbiome and treating the underlying GI issues might prove more cost-effective and yield better long-term outcomes than providing topical symptomatic relief. More randomized control trials are needed in order to give this theory more basis and standardize treatment protocols that address underlying GI pathologies.

EADV CONGRESS
VIENNA
30 SEP - 3 OCT 2026

Abstract N°: 2452

A rare case of scalp sarcoidosis in a woman with dark phototype

oumaima berradi*[1], siham alaoui[1], narjess ERRACHDY[1], NAJWA AMMAR[1], SYRINE HAMADA[1], meriame meziane[1], nadia ismaili[1], laila benzekri[1, 1]

[1] chu avicenne rabat, rabat, Morocco

Introduction
Scalp involvement in cutaneous sarcoidosis is rare and may be diagnostically challenging, particularly in patients with dark phototype. It can mimic several inflammatory or infectious dermatoses and may lead to irreversible cicatricial alopecia if diagnosis and treatment are delayed. Dermoscopy and trichoscopy may provide useful clues and help select the biopsy site.



Scalp involvement in cutaneous sarcoidosis. Multiple erythematous infiltrated alopecic plaques of the scalp, illustrating the risk of follicular destruction and permanent cicatricial alopecia.

Case Presentation
A 26-year-old woman with dark phototype and no significant medical history presented with a 5-month history of

pruritic umbilicated papules progressively coalescing into infiltrated plaques on the neck and back, associated with inflammatory alopecic plaques of the scalp. There was no fever, weight loss, mucosal or nail involvement, palpable lymphadenopathy or other systemic symptoms.

Clinical examination revealed bilateral and symmetrical brown-red infiltrated cervicodorsal plaques with satellite umbilicated papules, associated with erythematous infiltrated alopecic plaques of the scalp. Dermoscopy of the cutaneous plaques showed structureless brown-orange areas with arborising vessels of variable calibre. The papular lesions displayed brown-orange areas with a lighter yellowish centre, an erythematous halo and linear vessels. Trichoscopy showed a yellow to brown-orange background, perifollicular hyperkeratosis, diffuse white scaling and arborising vessels.

Histopathological examination of two skin biopsies, taken from the trunk and scalp, revealed a non-necrotising granulomatous dermatitis composed of well-formed epithelioid and giant-cell granulomas, without caseous necrosis. Ziehl-Neelsen staining was negative. These findings supported the diagnosis of cutaneous sarcoidosis with scalp involvement. The main differential diagnoses were cutaneous tuberculosis, discoid lupus erythematosus, lichen planopilaris and folliculitis decalvans. A systemic assessment including chest imaging, pulmonary function tests, electrocardiography, ophthalmological examination and laboratory investigations was initiated. Systemic corticosteroid therapy was started because of the extent of the lesions and the risk of permanent scarring alopecia.



Clinical presentation of cutaneous sarcoidosis. Multiple brown-red infiltrated papules and plaques involving the posterior neck and upper back, with bilateral and symmetrical distribution. Some lesions show annular or umbilicated morphology.

Conclusion

This case highlights a rare presentation of cutaneous sarcoidosis involving the scalp in a woman with dark phototype. The brown-orange dermoscopic and trichoscopic background, associated with arborising and linear

vessels, was an important clue toward a granulomatous disorder, but histopathological confirmation remained essential. Scalp sarcoidosis should be recognised early because follicular destruction may result in irreversible cicatricial alopecia. A complete systemic work-up is mandatory after diagnosis.

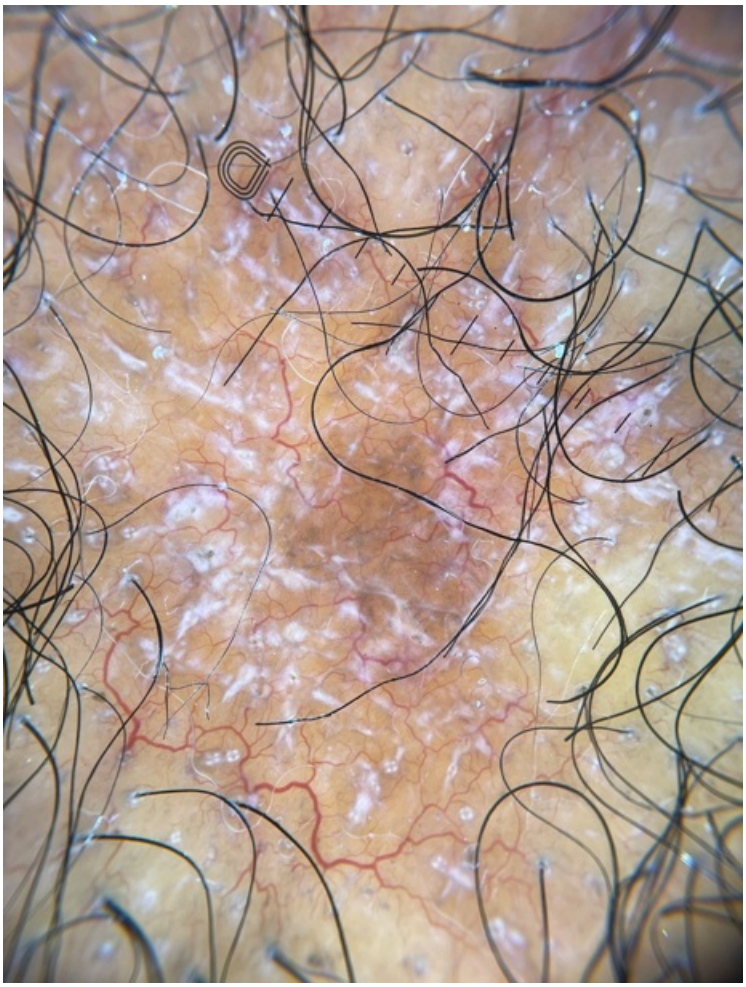

Trichoscopic findings of scalp sarcoidosis. Yellow-orange to brown-orange background with arborising vessels, whitish structureless areas and fine scaling, suggesting a granulomatous inflammatory process involving the scalp.

EA DV CONGRESS
VIENNA
30 SEP - 3 OCT 2026

Abstract N°: 2469

Widespread Violaceous Nodules in a Child: The Dermatologist's Role in an Unsuspected Systemic Diagnosis

Gülay Keyik*[1], Burcu Beksac[1], Pelin Bayık[2], Feriha Pınar Uyar Göçün[2], Zühre Kaya[3], Serap Kırkız[3], Emine Yılmaz Orulluğlu[3], Ülker Koçak[3]

[1] Gazi University Faculty of Medicine, Department of Dermatology and Venereology, Ankara, Türkiye
[2] Gazi University Faculty of Medicine, Department of Pathology, Ankara, Türkiye
[3] Gazi University Faculty of Medicine, Department of Pediatric Hematology, Ankara, Türkiye

Introduction

Blastic Plasmacytoid Dendritic Cell Neoplasm (BPDCN) is a rare and aggressive hematologic malignancy with a predilection for the skin. The median age at diagnosis is 67, and it is extremely rare in children. 80 to 90% of patients present with cutaneous lesions as their first and, initially, only manifestation. Despite this defining cutaneous tropism, the diagnosis is rarely made by the first clinician to examine the skin. Peripheral blood counts are characteristically normal in the early phase, constitutional symptoms are absent, and the lesions themselves — firm, indurated, violaceous nodules — are morphologically indistinguishable from a range of more common conditions. Here, we present a case of BPDCN in a child patient.

Case Presentation

An 8 year old girl was referred with a firm, indurated, nontender, violaceous nodule on the posterior left thigh that had slowly enlarged over 10 months. In the 3 months preceding presentation, multiple similar lesions had appeared across the trunk, extremities, and scalp (Fig. 1). The child was systemically well, with no constitutional symptoms or pruritus. Complete blood count was within normal limits.

The clinical differential included Kaposi sarcoma, tumoral mycosis fungoides, kaposiform hemangioendothelioma, rhabdomyosarcoma, Blue Rubber Bleb Nevus Syndrome, and aleukemic leukemia cutis. Several features argued against a primary vascular process: the lesions were noncompressible, uniformly nodular, and disseminating at a pace inconsistent with benign vascular tumors.

Ultrasonography of the index lesion demonstrated a hypervascular, heterogeneous subcutaneous mass measuring 6.5×3 cm. Skin biopsy revealed a monotonous infiltrate of medium-sized blastic cells with open chromatin and scant cytoplasm, extending from the superficial dermis to the deep reticular dermis and dissecting between elastic fibers. Immunohistochemistry demonstrated CD43, CD4, CD56 and CD123 positivity with absence of TdT — a phenotypic profile incompatible with mycosis fungoides, Kaposi sarcoma, or rhabdomyosarcoma, and consistent with a plasmacytoid dendritic cell lineage.

This immunophenotype, identified on the skin biopsy alone, prompted bone marrow evaluation in a child whose hematological parameters had given no indication of marrow disease. Aspiration revealed 80–90% blastoid infiltration. PET-CT demonstrated SUVmax values ranging from 1.5 in subcutaneous scalp deposits to 5.8 in the primary femoral mass. The full burden of marrow and soft-tissue involvement became apparent only after the skin biopsy guided the workup.

Following multidisciplinary evaluation, induction chemotherapy was administered according to a high-risk acute lymphoblastic leukemia protocol. This was followed by tagraxofusp, and subsequently by allogeneic hematopoietic stem cell transplantation from a matched sibling donor as consolidation. The patient achieved

remission and remains disease-free at follow-up.

Conclusion

This case illustrates a diagnostic pattern that recurs consistently in the published literature on BPDCN: a child with progressive cutaneous nodules, a normal blood count, and no systemic symptoms, in whom the diagnosis is made not by the clinical presentation but by the histology and immunophenotype obtained from the skin. The dermatologist who performs the biopsy, who extends the immunopanel to include CD4, CD56, and CD123 when the morphology does not conform to a recognisable diagnosis, and who does not accept a normal blood count as sufficient grounds for reassurance, is the clinician who makes this diagnosis at a stage when curative treatment remains achievable.

A progressive, indurated, violaceous nodule in a child — regardless of the child's clinical wellbeing and regardless of hematological parameters — warrants tissue biopsy, a full immunopanel, and, if the phenotype is anomalous, urgent hematological referral.

EA DV CONGRESS
VIENNA
30 SEP - 3 OCT 2026

Abstract N°: 2503

Acquired Perforating Dermatosis Beyond Classic Associations: Systemic Lupus Erythematosus as an Unusual Setting

Karine Domingues Tavares*[1], Lais dos Santos[1], Ana Clara Boareto Costa[1], Danielle Santana Melo[1], Gabriela Higino de Souza[1], Maria de Fátima Guimarães Scotellaro Alves[1], Alexandre Gripp[1]

[1] Universidade Estadual do Rio de Janeiro - Hospital Pedro Ernesto, Rio de Janeiro, Brazil

Introduction

Acquired perforating dermatosis (APD) is a rare disorder characterized by transepidermal elimination of dermal components, mainly collagen and elastic fibers. It is typically associated with systemic conditions such as diabetes mellitus and chronic renal failure. Its occurrence in systemic lupus erythematosus (SLE) is exceedingly rare, with only a few cases reported to date. We report a case of acquired perforating dermatosis in a patient with systemic lupus erythematosus, without diabetes, presenting with rapid clinical progression and favorable response to tetracycline treatment.

Case Presentation

A 37-year-old woman presented with painful disseminated erythematous nodules progressing to central necrosis and purulent discharge. She had a history of systemic lupus erythematosus with previous lupus nephritis, pleural effusion, and pericardial effusion, although the disease was clinically stable at presentation, with normal renal function and no evidence of active nephropathy. Initial differential diagnoses included pyoderma, cutaneous vasculitis, and cutaneous mucinosis. Dermatological examination revealed multiple tender nodules, some displaying a central keratotic plug. Dermoscopy demonstrated a crateriform central opening with keratotic extrusion. Histopathological examination showed vertically oriented collagen bundles undergoing transepidermal elimination. Masson's trichrome staining confirmed the collagenous nature of the eliminated material, establishing the diagnosis of acquired perforating dermatosis.

Clinicopathological correlation allowed classification as acquired reactive perforating collagenosis according to the classification proposed by Kawakami et al. Treatment consisted of optimization of lupus control combined with doxycycline, initially at 100 mg/day and later increased to 200 mg/day, considering its anti-inflammatory and collagenase-modulating properties. Complete remission of the lesions was achieved after four months of treatment.

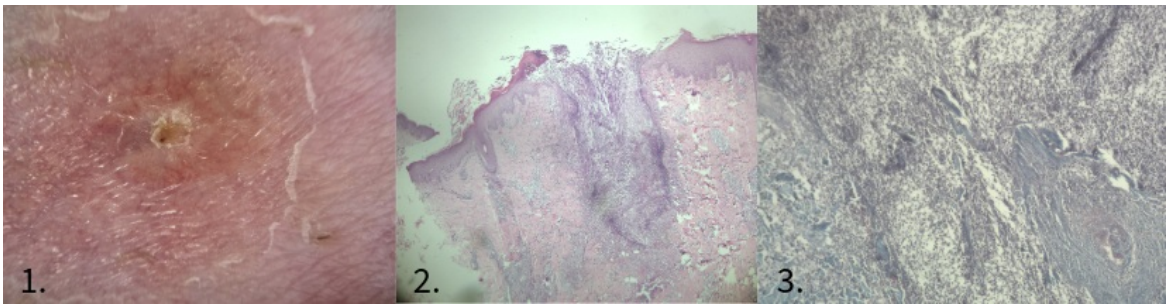

Figure 1. Dermoscopy revealing a crateriform central ulceration with prominent keratotic extrusion. Figure 2. H&E, Crateriform epidermal invagination containing vertically oriented keratinous material, consistent with transepidermal elimination. Figure 3. Masson's trichrome stain, blue-stained

intraepidermal collagen fibers arranged in a vertical orientation.

Conclusion

This case expands the clinicopathological spectrum of acquired reactive perforating collagenosis associated with SLE and suggests that previous immune-mediated renal injury, even in the absence of active nephropathy, may contribute to disease pathogenesis. In previously reported cases, APD either preceded or followed the diagnosis of SLE, suggesting a potential immunological link between the two conditions. In addition, doxycycline may represent a valuable anti-inflammatory therapeutic alternative in selected cases.

EA DV CONGRESS
VIENNA
30 SEP - 3 OCT 2026

Abstract N°: 2556

T-Cell Prolymphocytic Leukemia mimicking Cutaneous Lupus Erythematosus: a diagnostic challenge

Renata Rodrigues*[1], Paulo Ricardo Criado[1], José de Almeida[1], Renata Costa[1], Lisandra Porta Nova[1], Ana Lígia Scotti Alérico[1], Ingrid Melo[1], Sandra e Dinato[1]

[1] Centro Universitário Lusíada (UNILUS) – Santos, SP, Santos, Brazil

Introduction
Cutaneous lupus erythematosus may present with a broad spectrum of clinical and histopathological manifestations, frequently mimicking other inflammatory dermatoses. However, atypical presentations or unfavorable clinical evolution should raise suspicion for alternative diagnoses, including lymphoproliferative disorders.

T-cell prolymphocytic leukemia (T-PLL) is a rare and highly aggressive neoplasm that may present with nonspecific cutaneous manifestations, often delaying diagnosis by simulating inflammatory, infectious, and infiltrative dermatoses.

Case Presentation
A 36-year-old woman presented in June 2025 with an erythematous lesion on the nasal dorsum, initially diagnosed as rosacea. She progressively developed infiltrated erythematous plaques involving the face and anterior chest.

The first skin biopsy revealed lichenoid interface dermatitis with superficial and deep perivascular and periadnexal inflammatory infiltrate, hydropic degeneration of the basal layer, follicular ectasia, and keratotic plugs, favoring chronic cutaneous lupus erythematosus. Treatment with hydroxychloroquine 400 mg/day and topical clobetasol was initiated.

During follow-up, the patient developed progressive cervical, axillary, and supraclavicular lymphadenopathy, splenomegaly, intermittent fever, night sweats, and marked weight loss (20 kg in 3 months).

Six months after disease onset, she was hospitalized due to worsening facial edema and progression of the skin lesions, which evolved into confluent infiltrated papular plaques involving the lips, nasolabial folds, nasal dorsum, malar regions, and ears. She also developed dysphonia and dyspnea. Laboratory tests demonstrated marked leukocytosis (123,950/mm^3), atypical lymphocytosis, and Gumprecht shadows.

Due to clinical deterioration, a second facial skin biopsy revealed atypical lymphoid proliferation. Concurrently, peripheral blood immunophenotyping demonstrated a T-cell lymphoproliferative disorder consistent with T-cell prolymphocytic leukemia. The patient was referred for chemotherapy; however, she rapidly progressed to respiratory failure and died approximately 30 days later.

Conclusion
This case illustrates an initially nonspecific cutaneous presentation whose differential diagnosis included cutaneous lupus erythematosus, rosacea, Morbihan disease, lepromatous leprosy, and hematologic malignancies. Persistent erythema and edema associated with progressive facial infiltration may mimic inflammatory, infectious,

and lymphoproliferative dermatoses, making diagnosis particularly challenging.

Although the initial histopathological findings suggested cutaneous lupus, the unfavorable clinical evolution and emergence of systemic manifestations, including lymphadenopathy and hematologic abnormalities, were crucial for diagnostic reassessment. In atypical or treatment-refractory cases, cutaneous infiltration by a lymphoproliferative disorder should be considered.

T-PLL is a rare and aggressive neoplasm with heterogeneous and nonspecific cutaneous manifestations. Cutaneous involvement occurs in approximately 25% of patients and may precede or obscure the hematologic diagnosis.

This case highlights the importance of maintaining a broad differential diagnosis in infiltrative facial dermatoses and reinforces the need for continuous reassessment in cases with unexpected evolution and associated systemic manifestations.

EA DV CONGRESS
VIENNA
30 SEP - 3 OCT 2026

Abstract N°: 2608

Systemic Mastocytosis Mimicking Lichen Planus and Lichen Planopilaris: A Diagnostic Pitfall

Irem Ozcan*[1], Hande Ermis Akkus[1], Sinem Civriz Bozdag[2], Nesimi Buyukbabani[3], Asude Kara Polat[1], Savaş Yaylı[1]

[1] Koç University School of Medicine, Dermatology and Venereology Department, Istanbul, Türkiye
[2] Koc University Hospital, Hematology Department, Istanbul, Türkiye
[3] Koc University Hospital, Pathology Department, Istanbul, Türkiye

Introduction

Mastocytosis is a clonal disorder characterized by the accumulation of neoplastic mast cells in the skin and/or extracutaneous organs, driven by activating KIT mutations, particularly D816V. Maculopapular cutaneous mastocytosis (MPCM) or urticaria pigmentosa (UP) is the most common cutaneous mastocytosis subtype in adults and typically involves the trunk and proximal extremities. The appearance of cutaneous lesions in adult life frequently raises concern for underlying systemic mastocytosis. In MPCM, systemic involvement tends to be less frequent or relatively indolent, whereas rare variants such as telangiectasia macularis eruptiva perstans are more often associated with significant systemic disease. Although Darier's sign is a useful clinical clue, its sensitivity decreases in older patients and in long-standing lesions. Here, we report a case of systemic mastocytosis mimicking the lichenoid dermatosis spectrum including lichen planus (LP), lichen planus pigmentosus (LPPig) and lichen planopilaris (LPP), highlighting this rare but important diagnostic pitfall.

Case Presentation

A 70-year-old female patient presented with a 15-year history of pruritic eruptions initially localized to the right thigh, with progression over the past 2 years to intertriginous areas. Examination revealed a pruritic red-brown rash predominantly involving the bilateral axillae, medial upper arms, groins and inframammary regions. Violaceous, partially coalescing patches were observed on the right thigh, while discrete brownish macules were present on the volar wrist and dorsum of the feet. Darier's sign was negative across all lesions. Dermatoscopic evaluation disclosed white linear structures compatible with Wickham striae, raising suspicion for LP spectrum disorders. Frontal hairline recession with perifollicular scaling and lateral eyebrow loss further supported a preliminary diagnosis within the LP, LPP and LPPig spectrum.

Biopsy from the right axilla showed epidermal acanthosis with increased basal layer pigmentation and a band-like infiltrate in the papillary dermis composed predominantly of mast cells with abundant granular cytoplasm, admixed with eosinophils. Toluidine blue staining confirmed metachromatic granules, consistent with mastocytosis. Clinical and histopathological findings established a diagnosis of MPCM. Systemic symptoms such as flushing, anaphylactoid reactions and gastrointestinal complaints were absent. Serum tryptase was elevated at 63 ng/mL. Hematologic workup prompted bone marrow biopsy, revealing multifocal dense mast cell aggregates, CD117, CD25, and tryptase positivity, and a KIT D816V mutation. The patient fulfilled the major criterion and three of four minor WHO 2022 diagnostic criteria, establishing the diagnosis of systemic mastocytosis. Midostaurin 25 mg/day was subsequently initiated, resulting in notable regression of cutaneous lesions within one month. The patient remains on active treatment.

Conclusion

This case highlights mastocytosis as an important diagnostic pitfall that may closely mimic LP and its variants both clinically and dermatoscopically. Dermatoscopic findings suggestive of Wickham striae may represent white structureless areas corresponding to the spaces between the brown reticular network typically seen in urticaria

pigmentosa, leading to potential misinterpretation. Long-standing, slowly progressive, pruritic hyperpigmented macules should prompt consideration of mastocytosis in the differential diagnosis. Notably, the absence of Darier's sign or mediator-related symptoms does not exclude mastocytosis. Given that adult-onset cutaneous mastocytosis may be associated with systemic involvement, including indolent or smoldering forms with silent organ infiltration without overt dysfunction, comprehensive systemic evaluation is essential for accurate diagnosis and appropriate management.

EA DV CONGRESS
VIENNA
30 SEP - 3 OCT 2026

Abstract N°: 2628

A Rare Case of Noma-Like Orofacial Disease in a Patient with HIV-Related Immunosuppression

Fatih Karakaş*[1], Hilal Avsar[1], Hazel Kaya[1], Aslı Aksu[1, 1], Ilknur Altunay[1]

[1] Department of dermatology, Şişli Hamidiye Etfal Training and Research Hospital, Seyrantepe Campus, İstanbul, Türkiye

Introduction
Noma-like disease is a rare, opportunistic, polymicrobial condition that resembles classical noma and is primarily observed in immunocompromised individuals. While classical noma predominantly affects malnourished children in socioeconomically disadvantaged regions, noma-like presentations have increasingly been described in adults with underlying conditions such as HIV infection. The pathogenesis is multifactorial, involving immune suppression, disruption of mucosal barriers, and subsequent polymicrobial colonization. Due to its rarity and variable clinical presentation, noma-like disease may be underrecognized in clinical practice.

Case Presentation
A 64-year-old male patient presented with ulcerative lesions involving the perioral region and oral cavity that had been progressing over approximately four months. His complaints included painful oral ulcers, changes in speech and voice associated with velopharyngeal insufficiency, nasal regurgitation of fluids, and nasal discharge entering the oral cavity. The patient had a known history of HIV infection diagnosed six months earlier and reported poor adherence to antiretroviral therapy. Laboratory evaluation revealed a CD4 count of 131 cells/μL, consistent with significant immunosuppression.
Clinical examination revealed extensive destructive and irregularly bordered ulcerative lesions involving the perioral region and oral mucosa, covered with yellowish exudate and areas of fissuring, with marked intraoral involvement including complete loss of the uvula and tonsillar structures. The lesions exhibited a destructive but non-classical appearance, lacking the black necrotic eschar characteristically seen in noma.

Microbiological analysis revealed polymicrobial growth, including bacterial species and Candida spp. Histopathological examination demonstrated non-specific squamous epithelial hyperplasia, parakeratosis, and moderate perivascular lymphoplasmacytic infiltration without evidence of malignancy. Direct immunofluorescence and ANCA tests were negative. In the absence of a specific infectious, malignant, or autoimmune etiology, these clinicopathological findings supported the diagnosis of noma-like disease. The findings also suggested secondary opportunistic infection facilitated by impaired mucosal integrity. The patient was treated with broad-spectrum antibiotics in combination with systemic antifungal therapy. Following treatment, lesion progression was halted, and clinical stabilization was achieved.

Conclusion
This case highlights a noma-like clinical presentation in an immunocompromised adult with poor adherence to antiretroviral therapy. Although Candida spp. infection alone is unlikely to account for the extent of tissue destruction, it may contribute by disrupting the mucosal barrier and facilitating secondary polymicrobial infection. Noma-like disease should be considered in HIV-positive patients presenting with atypical destructive oral lesions. Early recognition and prompt, aggressive treatment are crucial to prevent further tissue loss and associated morbidity.

EA DV CONGRESS
VIENNA
30 SEP - 3 OCT 2026

Abstract N°: 2634

A Rare Case of Noma-Like Orofacial Disease in a Patient with HIV-Related Immunosuppression

Fatih Karakaş[1], Hilal Avsar[1], Hazel Kaya[1], Aslı Aksu[1], Ilknur Altunay*[1]

[1] Department of dermatology, Şişli Hamidiye Etfal Training and Research Hospital, Seyrantepe Campus, İstanbul, Türkiye

Introduction
Noma-like disease is a rare, opportunistic, polymicrobial condition that resembles classical noma and is primarily observed in immunocompromised individuals. While classical noma predominantly affects malnourished children in socioeconomically disadvantaged regions, noma-like presentations have increasingly been described in adults with underlying conditions such as HIV infection. The pathogenesis is multifactorial, involving immune suppression, disruption of mucosal barriers, and subsequent polymicrobial colonization. Due to its rarity and variable clinical presentation, noma-like disease may be underrecognized in clinical practice.

Case Presentation
A 64-year-old male patient presented with ulcerative lesions involving the perioral region and oral cavity that had been progressing over approximately four months. His complaints included painful oral ulcers, changes in speech and voice associated with velopharyngeal insufficiency, nasal regurgitation of fluids, and nasal discharge entering the oral cavity. The patient had a known history of HIV infection diagnosed six months earlier and reported poor adherence to antiretroviral therapy. Laboratory evaluation revealed a CD4 count of 131 cells/μL, consistent with significant immunosuppression.

Clinical examination revealed extensive destructive and irregularly bordered ulcerative lesions involving the perioral region and oral mucosa, covered with yellowish exudate and areas of fissuring, with marked intraoral involvement including complete loss of the uvula and tonsillar structures. The lesions exhibited a destructive but non-classical appearance, lacking the black necrotic eschar characteristically seen in noma.

Microbiological analysis revealed polymicrobial growth, including bacterial species and Candida spp. Histopathological examination demonstrated non-specific squamous epithelial hyperplasia, parakeratosis, and moderate perivascular lymphoplasmacytic infiltration without evidence of malignancy. Direct immunofluorescence and ANCA tests were negative. In the absence of a specific infectious, malignant, or autoimmune etiology, these clinicopathological findings supported the diagnosis of noma-like disease. The findings also suggested secondary opportunistic infection facilitated by impaired mucosal integrity. The patient was treated with broad-spectrum antibiotics in combination with systemic antifungal therapy. Following treatment, lesion progression was halted, and clinical stabilization was achieved.

Conclusion
This case highlights a noma-like clinical presentation in an immunocompromised adult with poor adherence to antiretroviral therapy. Although Candida spp. infection alone is unlikely to account for the extent of tissue destruction, it may contribute by disrupting the mucosal barrier and facilitating secondary polymicrobial infection. Noma-like disease should be considered in HIV-positive patients presenting with atypical destructive oral lesions. Early recognition and prompt, aggressive treatment are crucial to prevent further tissue loss and associated morbidity.

EA DV CONGRESS
VIENNA
30 SEP - 3 OCT 2026

Abstract N°: 2655

Cutaneous manifestations in inflammatory bowel disease in the era of biologics: a real-world analysis of event timing, cumulative exposure, disease control, and current therapy

Ruggero Cascio Ingurgio*[1, 2], Laura Loy[3], Angela Alfano[1, 2], Alessandro Armuzzi[2, 3], Riccardo Borroni[1, 2]

[1] Dermatology Unit, IRCCS Humanitas Research Hospital, Rozzano (Milan), Italy

[2] Department of Biomedical Sciences, Humanitas University, Pieve Emanuele (Milan), Italy

[3] IBD Center, IRCCS Humanitas Research Hospital, Rozzano, Italy

Introduction

Cutaneous manifestations in inflammatory bowel disease (IBD) include classical extraintestinal manifestations and therapy-associated dermatologic events. In the biologic era, the dermatologic spectrum may increasingly reflect treatment exposure and immune modulation rather than intestinal inflammation alone. However, event timing and cumulative exposure across sequential therapies are rarely integrated into dermatologic risk assessment. We aimed to characterize dermatologic phenotype distribution and evaluate its association with IBD control, current therapy class, on-treatment latency and cumulative therapeutic exposure.

Materials and Methods

We conducted a retrospective real-world study including adult patients with IBD and confirmed dermatologic diagnoses during IBD management between January 2017 and March 2026. Analyses were performed at the event level. Dermatologic events were classified as IBD-related, associated dermatoses or treatment-induced manifestations. Time-to-onset was defined as the interval from current IBD therapy initiation to dermatologic event onset. Cumulative recorded exposure was calculated by summing available treatment intervals from prior therapy lines, current therapy and concomitant IBD therapy. Associations were assessed using χ^2 or Fisher's exact tests, and continuous variables using Kruskal–Wallis tests.

Results

Among 1343 IBD patients, 137 (10.2%) experienced at least one dermatologic event, contributing 171 events. The most frequent diagnoses were atopic dermatitis (20.5%), psoriasis (19.3%), folliculitis (7.0%), erythema nodosum (5.3%), pyoderma gangrenosum (5.3%), hidradenitis suppurativa (4.7%) and melanoma (4.7%). Overall, associated dermatoses and treatment-induced manifestations accounted for most events, whereas IBD-related manifestations represented a smaller proportion. Phenotype distribution differed significantly according to IBD control status (Pearson $\chi^2(4)=19.72$, $p=0.001$): IBD-related manifestations were enriched in uncontrolled disease, while associated dermatoses predominated in controlled or partially controlled IBD. Distribution also varied across current therapy classes (Pearson $\chi^2(6)=19.73$, $p=0.003$), with IBD-related manifestations more frequent under conventional therapy and treatment-induced manifestations more represented under advanced therapies. Among 159 on-treatment events, median latency from current therapy initiation to dermatologic onset was 12.68 months (IQR 3.02–35.51) and increased with better IBD control, from 6.99 months in uncontrolled disease to 15.41 months in controlled disease ($p=0.0097$). Total cumulative recorded exposure differed across phenotype groups ($p=0.0085$), being lower in IBD-related manifestations (median 27.32 months) than in associated dermatoses (89.95 months) or treatment-induced manifestations (73.78 months). Among exposed events, cumulative anti-TNF exposure also differed significantly across phenotypes ($p=0.0006$), with the shortest exposure observed in

treatment-induced manifestations.

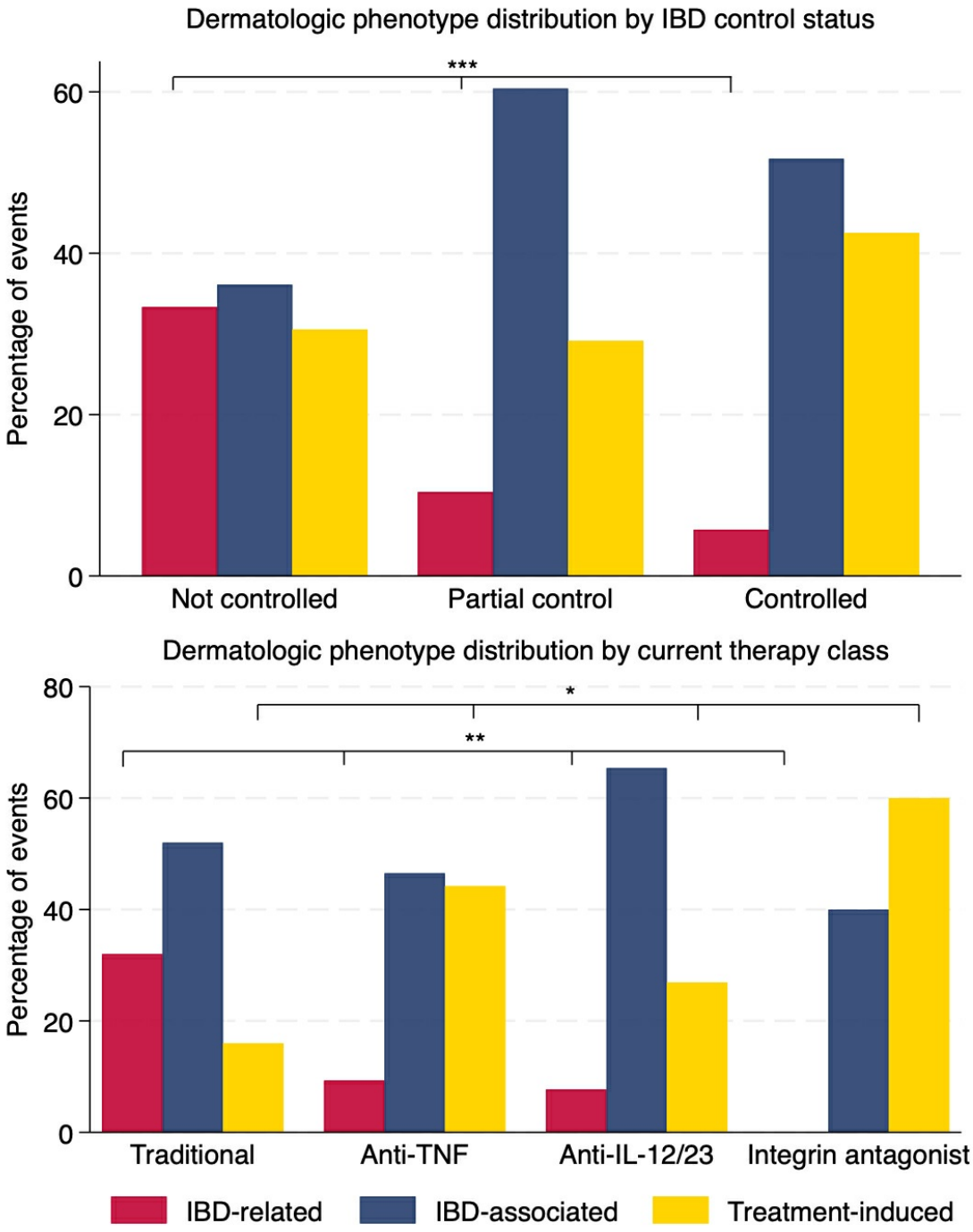

Conclusions

Dermatologic events in IBD show distinct patterns according to intestinal disease control, current therapy and cumulative therapeutic exposure. Classical IBD-related manifestations were linked to uncontrolled disease, whereas associated and treatment-induced dermatoses predominated in patients with controlled IBD and greater therapeutic exposure. These findings support a therapy-modulated framework for interpreting cutaneous manifestations in contemporary IBD care and highlight the value of dermatologic assessment in multidisciplinary treatment decisions.

EA DV CONGRESS
VIENNA
30 SEP - 3 OCT 2026

Abstract N°: 2690

Lucio's Phenomenon: A Rare Presentation of a Neglected and Mimicking Disease. A Case Report.

Igor da Costa Viana[1], Maria Tavares da Rosa*[1], Louise Soares Amado[1], Natan de Oliveira Faria Machado[1], Mariana Nunes Sharp[1], Gabriela Teixeira Peixoto[1], Mariana Teixeira Konder[1], Jorge da Silva Soares Pinto[1]

[1] State University of Rio de Janeiro, Rio de Janeiro, Brazil

Introduction

Leprosy is a neglected chronic infectious disease caused primarily by Mycobacterium leprae and, less commonly, by Mycobacterium lepromatosis. It is transmitted predominantly through the respiratory route and affects the skin and peripheral nerves. In Brazil, its epidemiological relevance remains significant, with a prevalence of 10.6 cases per 100,000 inhabitants. Diffuse lepromatous leprosy is a rare multibacillary variant characterized by a high bacillary load, diffuse cutaneous infiltration, and immunologic anergy. Lucio's phenomenon is a severe type 2 leprosy reaction associated with this variant, characterized by purpuric-ulcerative lesions resulting from necrotizing vasculopathy related to endothelial bacillary invasion.

Case Presentation

We report the case of a 30-year-old woman with a prior history of hypertension who sought medical care for an erythematous papule on the left heel, initially treated with beta-lactam plus clavulanate. After three days of therapy, she developed retiform purpura and hemorrhagic bullae, progressing to ulcerations of the lower limbs. The medication was discontinued. During hospital investigation, she reported a 24-kg weight loss over the previous 2 years associated with alopecia. Physical examination revealed hemorrhagic bullae on the digits of the hands, similar to the initial lower-limb lesions, in addition to extensive ulceronecrotic lesions of the lower limbs associated with edema. There was facial hyperpigmentation and edema, with madarosis and mild infiltration of the earlobes. No nerve thickening or other abnormalities were detected.

Laboratory tests showed microcytic hypochromic anemia, leukopenia with lymphopenia, high creatinine (1.61 mg/dL), urea (104 mg/dL), C-reactive protein levels and erythrocyte sedimentation rate. Urinalysis elicited dysmorphic red blood cells. Abdominal computed tomography revealed hepatosplenomegaly. Autoantibody screening was negative for ANA, anti-dsDNA, anti-Ro, anti-La, anti-RNP/Sm, c-ANCA, p-ANCA, anti-MPO, and anti-PR3. Antiphospholipid antibodies were initially reactive but became negative after 12 weeks. Serum complement was depleted (C3 of 26 mg/dL and C4 of 9.6 mg/dL). Rheumatoid factor titer was 1:16. Serum cryoglobulins were weakly positive, anti-HCV antibody was negative, no monoclonal protein was detected, and a direct Coombs test was positive with negative eluate. A kidney biopsy demonstrated pauci-immune proliferative glomerulonephritis with focal crescent formation, compatible with ANCA-associated vasculitis or infection-related glomerulonephritis.

A diagnosis was established after a bacilloscopy of intradermal scrapings of the earlobes and elbow, using Ziehl-Neelsen staining, was positive (5+ left earlobe, 4+ right earlobe and 4+ left elbow). Also a punch skin biopsy of the right lower limb, using the Fite-Faraco method, was compatible with lepromatous leprosy (6+), with a positive acid-fast bacilli testing and a negative molecular test for Mycobacterium tuberculosis complex.

Relevant differential diagnoses for a clinical picture of retiform purpura associated with glomerulonephritis and positive autoantibodies should include infections, vasculitides, and thrombotic disorders, especially systemic lupus erythematosus, small-vessel vasculitis, antiphospholipid syndrome, and purpura fulminans. Positive autoantibodies do not exclude multibacillary leprosy, a major mimicker of rheumatologic diseases, since humoral immune dysregulation, hypergammaglobulinemia, and autoantibody production may occur as an epiphenomenon of

chronic immune activation in an infectious setting.

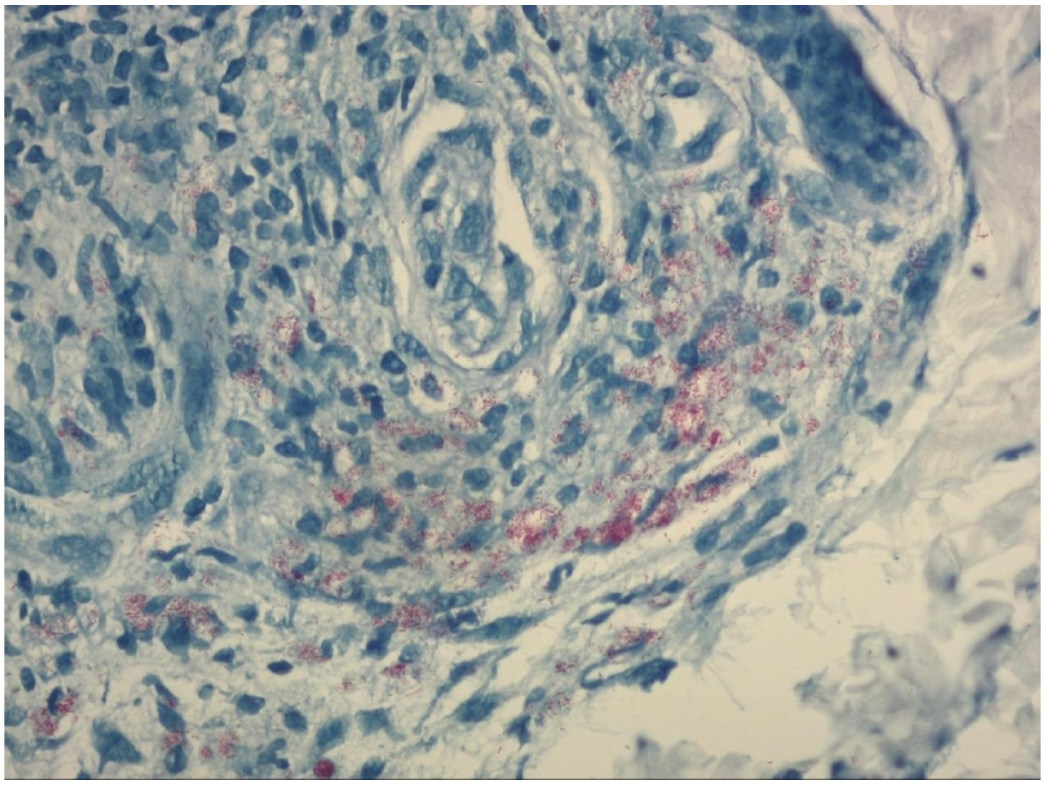

Punch skin biopsy of the right lower limb, using the Fite-Faraco method, compatible with lepromatous leprosy (6+).

Conclusion

This case highlights the diagnostic complexity of Lucio's phenomenon in a patient without a previous diagnosis of leprosy and underscores the need to consider this disease in the differential diagnosis of ulceronecrotic purpuric lesions with systemic involvement, especially in endemic regions, where early recognition has therapeutic, prognostic, and epidemiological impact.

EADV CONGRESS
VIENNA
30 SEP - 3 OCT 2026

Abstract N°: 2699

When a Genital Ulcer Is Not What It Seems: Vulvar Pyoderma Gangrenosum Mimicking Infectious and Autoimmune Disease

Maria Lúcia Paysano*[1], Karime Menezes[1], Luiza Soares Berenbaum[1], Fabiano Leal[1], FELIPE AGUINAGA[1]

[1] Instituto de Dermatologia Professor Rubem David Azulay - Santa Casa da Misericórdia do Rio de Janeiro, Rio de Janeiro, Brazil

Introduction

Pyoderma gangrenosum (PG) is a rare neutrophilic dermatosis frequently associated with inflammatory bowel disease. Genital involvement is exceedingly uncommon and may mimic sexually transmitted infections, Behçet disease, and other inflammatory disorders, often leading to delayed diagnosis and significant psychosocial burden. Vulvar PG in young patients represents a particularly challenging scenario, as a painful and disfiguring genital ulcer during formative years may profoundly affect body image, psychosexual development, and social functioning.

Case Presentation

A 24-year-old female student, with ulcerative colitis (UC) diagnosed since age 11 and a first-degree family history of UC, presented with a painful vulvar ulcer and left inguinal adenopathy. She also developed disabling polyarthritis involving the knees, shoulders, fingers, and ankles. During hospitalization, a bullous lesion emerged at the intravenous cannula insertion site, consistent with iatrogenic pathergy. A previous history of recurrent malleolar ulcers triggered by a dog bite further supported this phenomenon. Infectious investigations, including STI screening, were negative. Laboratory evaluation revealed leukocytosis (21,040/mm^3), ESR 10 mm/h, and CRP 0.64 mg/dL. Histopathology demonstrated an ulcerated lesion with acute suppurative and chronic nonspecific inflammation

Behçet disease was initially considered given the combination of genital ulceration, arthritis, and pathergy. However, the absence of oral ulcers and uveitis, together with the underlying UC, supported the diagnosis of PG. The genital location and chronic painful course resulted in substantial psychosocial distress, affecting the patient's body image, academic performance, and daily functioning

Systemic corticosteroids achieved partial improvement. Following negative IGRA testing, infliximab 200 mg IV was initiated at weeks 0, 2, and 6, followed by maintenance every 8 weeks, with complete cutaneous remission at 3-month follow-up and sustained remission at 9 months, accompanied by normalization of inflammatory markers.

Conclusion

Vulvar PG is a rare and frequently misdiagnosed condition that can mimic infectious and autoimmune diseases, delaying diagnosis and compounding psychosocial harm in young patients. Early recognition of pathergy, exclusion of infectious etiologies, and awareness of the association with inflammatory bowel disease are key to accurate diagnosis. Timely intervention is essential to prevent both physical morbidity and lasting psychosocial impact during formative years.

EA DV CONGRESS
VIENNA
30 SEP - 3 OCT 2026

Abstract N°: 2748

Efficacy of real-world off-label anifrolumab use in isolated CLE or CLE with concomitant SLE: a systematic literature review

François Chasset*[1, 2], Ruth Ann Vleugels[3, 4], Sonya Egodage[5], James Frampton[6], Amber Martin[5], Ayobami Olojo[7]

[1] Sorbonne Université, Faculté de médecine, AP-HP, Service de Dermatologie et Allergologie, Hôpital Tenon, Paris, France

[2] Sorbonne Université, Inserm U-1135, Centre d'Immunologie et des Maladies Infectieuses (Cimi-Paris), Paris, France

[3] Department of Dermatology, Brigham and Women's Hospital, Harvard Medical School, Dermatology Program, Division of Immunology, Boston Children's Hospital, Harvard Medical School, Boston, United States

[4] Dermatology Program, Division of Immunology, Boston Children's Hospital, Harvard Medical School, Boston, United States

[5] Thermo Fisher Scientific, Waltham, United States

[6] Evidera, London, United Kingdom

[7] BioPharmaceuticals Medical, AstraZeneca, Cambridge, United Kingdom

Introduction

Cutaneous lupus erythematosus (CLE) is a chronic, heterogeneous, immune-mediated disease that can occur in the presence or absence of systemic lupus erythematosus (SLE). In patients with CLE, increased disease activity is associated with reduced quality of life and persistent psychological burden related to disease progression and skin damage. Chronic upregulation of type I interferon (IFN-1) signalling is a contributing factor in the pathogenesis and disease severity of both SLE and CLE. Anifrolumab is a human IgG1κ monoclonal antibody that inhibits IFN-1 signalling and is approved for the treatment of moderate-to-severe SLE. This systematic literature review (SLR) assesses the real-world efficacy and safety of anifrolumab in patients with CLE.

Materials and Methods

This SLR was conducted in accordance with Cochrane and Preferred Reporting Items for Systematic Reviews and Meta-analyses guidelines. MEDLINE, EMBASE (July 2021 to January 2026), and conference proceedings (January 2021 to January 2026) were searched for real-world studies reporting anifrolumab treatment in pediatric or adult patients with isolated CLE or CLE with concomitant SLE. Dual independent screening was performed according to protocol-defined study selection criteria. Data extraction was conducted by one reviewer and validated by a second, with author adjudication of study design. Here, we report aggregate Cutaneous Lupus Erythematosus Disease Area and Severity Index Activity (CLASI-A) outcomes from cohort studies and case series including at least 5 patients.

Results

A total of 63 unique studies were identified, of which 11 were real-world cohort studies (N=213 CLE patients) and 3 were case series reporting aggregate CLASI-A data (N=29 patients). Median age at baseline ranged from 17–56.5 years, most patients were female (≥55%), and median baseline CLASI-A scores ranged from 8–28. In 10 studies, all patients had a concomitant diagnosis of SLE. CLE subtypes included discoid CLE (23.1–100%), acute

CLE (0–50%), subacute CLE (11–100%), and chilblain CLE (0–38.5%), with multiple subtypes per patient reported in 8 studies. Conventional previous lupus treatments included antimalarials (57.1–100%), systemic glucocorticoids (50–100%), methotrexate (19.1–100%), azathioprine (20–77.8%), and mycophenolate mofetil (10–100%). Prior biologic use was most commonly belimumab (13.3–89.9%). Where specified, all patients were treated with intravenous anifrolumab 300 mg Q4W, the approved dosage for SLE. CLASI-A response rates varied by population and follow-up duration **(Table).** In one refractory mucocutaneous lupus erythematosus cohort (Carter 2023), all 7 patients achieved ≥50% reduction in CLASI-A (CLASI-50) at 3 months (M) and response was maintained at 6M. In 2 studies, 60-100% of SLE patients with active CLE achieved CLASI-50 response at 6M (Carter 2023 and Oke 2024). In a multicentre prospective cohort study (de La Rochefoucauld 2026), response at 6M ranged by CLE subtype for CLASI-50 (75–100%) and CLASI-70 (67–100%) (N=47). CLASI 0-1 response was also reported in de La Rochefoucauld 2026 (37–100%), and CLASI 0 achievement was reported in Chasset 2023 (54%), Martin-Torregrosa 2025 (89%), and Garbarino 2025 (60%). In Carter 2023, 80% of patients had sustained oral glucocorticoid dose reduction at 6M. In 7 cohorts and 3 case series, 0–67% of patients experienced an adverse event. In 3 cohorts and 1 case series, herpes zoster incidence ranged from 0–9%, with no associated treatment discontinuations reported.

Outcome[a]	Range in reported percentage proportions of patients with outcome (%)	Total number of patients evaluated[b] (N)
CLASI-50 response at:		
2 months	20%	15
3 months	100%	7
4 months	100%	9
6 months	60–100%	69
Mean (SD): 8.5 (4.6) months	89%	18
CLASI-70 response at:		
6 months	67–100%	47
CLASI 0-1 response at:		
6 months	37–100%	47
CLASI 0 response at:		
4 months	88.9%	9
Mean (range): 5 (2, 9) months	60%	10
Last follow–up: Up to 9 months	54%	11
Sustained OGC dose reduction at:		
6 months	80%	5
Any AE at:		
2 months	0%	8
Median (range): 3.5 (2, 10) months	67%	6
Last visit: Mean 5.3 months	0%	10
6 months	14.3–37%	64
Mean (SD): 6.1 (4.1) months	20%	15
Median (range): 9 (1, 17) months	30%	10
Last visit: Up to 11 months	33.33%	9
12 months	14.3%	42
Timepoint not specified	30.8%	13
Any SAE at:		
Median (range): 3.5 (2, 10) months	0%	6
Median: 4 (1, 6) months	0	20
6 months	9%	57
Herpes zoster infection at:		
Median: 4 (1, 6) months	5%	20
4 months	9%	11
Last visit: Up to 11 months	0%	9
Timepoint not specified	0%	13

Title: Parameter-defined CLASI-A efficacy outcomes and safety outcomes in 11 real-world cohort studies and 3 case series of anifrolumab use in isolated CLE or CLE with concomitant SLE. Abbreviations: AE, adverse events; CLASI-50, ≥ 50% reduction in CLASI-A; CLASI-70, ≥ 70% reduction in CLASI-A; CLASI-A, Cutaneous Lupus Erythematosus Disease Area & Severity Index-Activity; CLE, cutaneous lupus erythematosus; OGC, oral glucocorticoids; SAE; serious adverse events; SD, standard deviation SLE; systemic lupus erythematosus; Footnotes: aAll outcome timepoints converted into months for table comparison; bTotal sum of patients evaluated for the parameter-defined CLASI-A outcome of interest, at the specified timepoint, across 11 unique cohort studies and 3 unique case series

Conclusions

In real-world studies of patients with isolated CLE or CLE with concomitant SLE, anifrolumab demonstrates rapid and meaningful reductions in skin disease activity, with a large proportion of patients achieving CLASI 0-1. These data support investigation into the efficacy and safety of anifrolumab in patients with CLE, which is currently ongoing in the phase 3 LAVENDER study (NCT06015737).

EA DV CONGRESS
VIENNA
30 SEP - 3 OCT 2026

Abstract N°: 2811

A Study of Acanthosis Nigricans in Patients with Angina Pectoris: A Cross-sectional Study

Prerna Nagi*[1]

[1] Lok Nayak Hospital , Maulana Azad Medical College New Delhi, Delhi, India

Introduction
Acanthosis nigricans (AN), characterized by velvety, hyperpigmented skin lesions, primarily affecting the neck, axillae, and groin, is recognized as a cutaneous marker for subclinical atherosclerosis. It is linked to hyperinsulinemia and metabolic syndrome (MetS) thereby increasing cardiovascular risk. Angina pectoris is characterized by chest pain due to myocardial ischemia. Although chest pain frequently accompanies myocardial ischemia, it is not always present. The development of Coronary artery disease (CAD) is attributed to multiple interrelated factors, including age, hypertension, diabetes, insulin resistance, and MetS. Among these, insulin resistance and MetS are the most significant risk factors for atherosclerosis, creating a common link between AN and CAD.

Hence, a careful examination of clinical indicators such as AN can be valuable in identifying CAD in high-risk individualsHowever, the prevalence of AN in patients with angina pectoris remains unexplored. This study aimed to determine this prevalence and associated factors.

Materials and Methods
This cross-sectional study included 500 patients diagnosed with angina pectoris (classical, unstable, NSTEMI, and STEMI). Data collection involved detailed medical history, including age, sex, Body mass index (BMI), comorbidities (Diabetes mellitus {DM}, hypertension, dyslipidemia), and type of angina. Grading of AN was done clinically and the severity of angina was assessed as per Burke's et al and NYHA grading respectively.

The collected data was entered into a Microsoft Excel spreadsheet, and graphs and tables were generated using Microsoft Word and Microsoft Excel. Categorical variables were presented as percentages, frequency, and proportions and compared using Pearson's chi-square test or Fisher's exact test, as appropriate. $p < 0.05$ was considered statistically significant. Quantitative data was expressed as mean ± standard deviation (SD) and compared using an independent sample t-test or Mann-Whitney U test while comparing more than two means, one-way ANOVA or Kruskal-Walli's test was utilized.

Results
In this study, 204 out of 500 (40.8%) patients with angina pectoris had AN, which was much higher compared to the prevalence of AN in the general population in India. The most common AN locations were the neck and axillae. Patients with AN experienced significantly earlier angina onset compared to those without ($p<0.001$). Univariate analysis showed associations between AN in patients with angina pectoris with age, weight, height, waist circumference, BMI, HTN, DM, and dyslipidemia. NSTEMI and STEMI patients had significantly higher odds of AN than classical angina patients.

Conclusions
This study demonstrates a 40.8% AN prevalence in angina patients, with severity of AN correlating with the

severity of angina. Age, obese category as per BMI, dyslipidemia, NSTEMI, and STEMI were independently associated with AN, with NSTEMI and STEMI patients exhibiting a higher likelihood of AN compared to classical angina. This demonstrates the potential of AN as a valuable clinical marker in patients with angina.

EA DV CONGRESS
VIENNA
30 SEP - 3 OCT 2026

Abstract N°: 2870

Patient Perspectives on the Burden of Cutaneous Lupus Erythematosus: Qualitative Results from Phase 3 LAVENDER In-trial Interviews

Victoria P. Werth*[1, 2], Ruth Ann Vleugels[3, 4], Miriam Wittmann[5], Sascha Gerdes[6], Manuel Sanchez-Diaz[7], Ilimbek Beketaev[8], Marta Forcadell[9], Sule Yavuz[10], Laura Gleeson[11], Isabelle Guillemin[12], Livia Lai[13], Emuella Flood[10]

[1] Department of Dermatology, University of Pennsylvania, Philadelphia, United States
[2] Corporal Michael J. Crescenz VAMC, Philadelphia, United States
[3] Department of Dermatology, Brigham and Women's Hospital, Harvard Medical School, Boston, United States
[4] Dermatology Program, Division of Immunology, Boston Children's Hospital, Harvard Medical School, Boston, United States
[5] Department of Dermatology, Johannes Gutenberg University, Mainz, Germany
[6] Department of Dermatology, Kiel University, Kiel, Germany
[7] Department of Dermatology, University Hospital Virgen de las Nieves, Granada, Spain
[8] Respiratory & Immunology, BioPharmaceuticals R&D, AstraZeneca, Durham, United States
[9] Respiratory & Immunology, BioPharmaceuticals R&D, AstraZeneca, Barcelona, Spain
[10] Respiratory & Immunology, BioPharmaceuticals R&D, AstraZeneca, Gaithersburg, United States
[11] Patient Centred Solutions, IQVIA, Dublin, Ireland
[12] Patient Centred Solutions, IQVIA, Lyon, France
[13] Patient Centred Solutions, IQVIA, London, United Kingdom

Introduction
Cutaneous lupus erythematosus (CLE) is an immune-mediated skin disease that substantially impacts patients' quality of life. Here, we explore the patient experience of living with CLE by reporting the symptoms and impacts on quality of life and activities of daily living from the optional qualitative patient interview sub-study of an ongoing interventional trial of anifrolumab, a monoclonal antibody that inhibits type-1 interferon signalling.

Materials and Methods
LAVENDER (NCT06015737) is a phase 3 multicentre, randomised, double-blind, placebo-controlled trial to evaluate the efficacy and safety of subcutaneous anifrolumab QW in adults with CLE. Patients with a confirmed diagnosis of chronic and/or subacute CLE with or without systemic lupus erythematosus (SLE), inadequate response or intolerance to antimalarial therapy, and CLASI-A ≥10 at screening and randomisation were eligible for the trial. Enrolled patients from Argentina, Australia, Austria, Canada, Chile, Colombia, Germany, Mexico, Poland, Spain, UK, and US were invited to participate in semi-structured telephone interviews in local language lasting ~60 minutes. An entry interview was conducted prior to randomisation and focused on patient experience of CLE symptoms and impacts on their daily life. Interviews were transcribed verbatim, translated, and analysed using thematic as well as content coding approaches. Symptom/impact saturation was also assessed to confirm adequacy of sample size.

Results
As of December 12, 2025, 24 patients had participated in the entry interview. The majority of patients were female (n=19, 79%) and white (n=19, 79%), with a median age (range) of 49.5 (22–70) years A total of 17 (71%) patients

were diagnosed with chronic CLE and 7 (29%) with subacute CLE; 6 (25%) patients had concomitant SLE. In all, 8 (33%) patients were from the US, 7 (29%) from Germany, 4 (16%) from Spain, 2 (8%) each from Australia and Austria, and 1 (4%) from the UK. A total of 28 different symptoms were reported by ≥2 patients, the most frequently experienced were skin redness (n=24, 100%), lesions/thick skin and fatigue (both physical and mental) (n=23, 96% each), followed by dyspigmentation, itching, hair loss, and skin scarring (**Figure**). Of 6 patients with concomitant SLE, 5 reported fatigue. In general, most symptoms had a high average rating (>6/10) for both severity and bothersomeness. A total of 12 different symptoms were ranked as the most bothersome by ≥1 patient, with fatigue (n=6), hair loss (n=4), and skin redness (n=3) ranked as the most bothersome symptoms. No additional symptoms emerged after the 17th interview. A total of 18 different impacts were reported by ≥2 patients, the most common of which were clothing restrictions and difficulty performing daily activities (n=21, 87% each), followed by social isolation, impact on leisure activities/hobbies, difficulty sleeping, difficulty with self care and personal hygiene, impact on family relationships, impact on work and employment, and difficulty with reactions from others (**Figure**). In all, 5 of 6 patients with concomitant SLE reported difficulties with daily activities. Within emotional impacts, embarrassment (n=5) and feeling sad/feeling depressed (n=4) had high mean impact ratings (≥8/10) among ≥4 patients. Difficulty with self care and personal hygiene was reported as the most bothersome impact (n=4), followed by social isolation and impact on leisure activities/hobbies (n=3, each). No new impacts emerged after the 8th interview.

Conclusions

Results of the entry interviews, conducted across a geographically diverse group of countries, highlight the high symptom burden of CLE which leads to a substantial impact on many facets of daily life, including social interactions, self care, and the ability to perform daily activities. These results reinforce the need for early management of patients and novel therapies which may reduce disease activity and prevent skin damage.

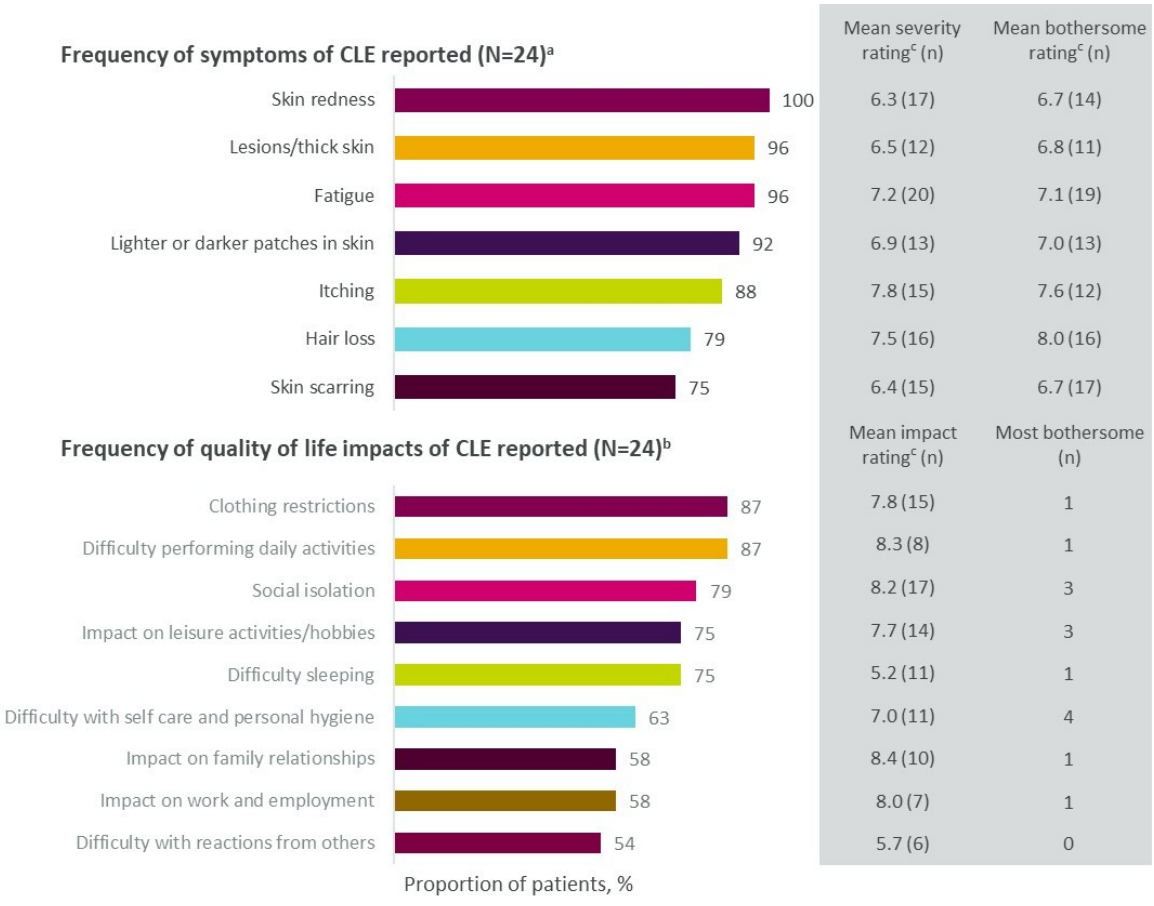

aSymptoms reported by ≥75% of patients; bImpacts reported by ≥50% of patients; cOn a scale of 0–10, where 0=least severe/bothersome/impact and 10=most severe/bothersome/impact; CLE, cutaneous lupus erythematosus

EADV Congress 2026, VIENNA
30 SEPTEMBER - 03 OCTOBER 2026
POWERED BY M-ANAGE.COM

EADV CONGRESS
VIENNA
30 SEP - 3 OCT 2026

Abstract N°: 2871

Lymphoproliferative Disorder in an HIV-Positive Patient with Extensive Cutaneous Involvement

Claudio Lelis Souza[1], Julia Nakano*[2], Guilherme Gonçalves Nascimento[2], Ana Laura Ritter[1], Mônica Linhares Sachett[2], Julia Coffler[3]

[1] unifenas, alfenas, Brazil

[2] FMABC, Santo Andre, Brazil

[3] EMESCAM, Vitória, Brazil

Introduction

Lymphoproliferative disorders are a group of diseases with diverse manifestations characterized by abnormal production of lymphoid cells, classically associated with Epstein-Barr virus (EBV), post-transplant immunosuppression and HIV infection. Cutaneous involvement may occur, however, exuberant presentations are rare and represent a significant diagnostic challenge.

Case Presentation

A 63-year-old Black male with HIV infection diagnosed more than 10 years earlier, on regular antiretroviral therapy, evaluated during a dermatology outreach project aimed at socially vulnerable populations. The patient reported previous evaluation by four dermatologists without diagnostic definition or resolution of the condition. The patient presented with an approximately three-year history of progressive skin lesions. The initial lesion consisted of an extensive infiltrated erythematous-violaceous plaque with centrifugal growth, circinate scaly borders and central nodular lesions ranging from a few millimeters to 3 centimeters in diameter, initially located on the flexural surface of the right upper limb. Subsequently, new infiltrated violaceous plaques developed on the lower limbs. The lesions were asymptomatic, with the main complaint related to aesthetic concerns. According to his daughter, HIV infection remained clinically controlled throughout the disease evolution. Biopsies were performed from four different sites of the lesions, demonstrating dermal lymphocytic proliferation suggestive of a lymphoproliferative process. Due to inconclusive findings, immunohistochemical analysis was performed, revealing mixed T- and B-cell infiltrates without criteria for malignancy, supporting the diagnosis of polymorphic immunodeficiency-associated lymphoproliferative disorder. Following diagnostic confirmation, the patient was referred for reconstructive plastic surgery evaluation because of the extensive and deforming cutaneous lesions. However, he progressed to death secondary to septicemia caused by urinary tract infection before definitive therapeutic intervention could be performed.

Conclusion

This report highlights an unusual and exuberant cutaneous manifestation of polymorphic immunodeficiency-associated lymphoproliferative disorder in an HIV-positive patient, with a prolonged three-year evolution and substantial diagnostic delay. The case underscores how these disorders may clinically simulate chronic inflammatory or neoplastic dermatoses, particularly in immunosuppressed individuals. Furthermore, it reinforces the importance of maintaining a high index of suspicion for lymphoproliferative disorders in patients presenting with persistent violaceous infiltrated plaques and nodular lesions, especially when conventional diagnostic approaches fail. Early clinicopathological correlation and immunohistochemical investigation are essential to avoid delayed diagnosis and potentially improve outcomes.

EADV CONGRESS
VIENNA
30 SEP - 3 OCT 2026

Abstract N°: 2880

Evaluation of Dermatological Findings in Inflammatory Bowel Disease and Their Evaluation According to Sociodemographic Characteristics

Müberra Meral Özdemir*[1], ETEM ARICA[1], Arzu Ferhatosmanoğlu[1], Sami Fidan[2]

[1] Karadeniz Technical University, Faculty of Medicine, Department of Dermatology and Venereology, Trabzon, Türkiye

[2] Karadeniz Technical University, Faculty of Medicine, Department of Internal Medicine, Division of Gastroenterology, Trabzon, Türkiye

Introduction

Inflammatory bowel disease (IBD) is a multisystemic disorder often associated with various mucocutaneous manifestations. These findings are categorized based on their pathophysiological relationship with the underlying disease, ranging from specific lesions to treatment-related reactions. This study evaluates the frequency and spectrum of dermatological findings in IBD patients and their relationship with sociodemographic characteristics.

Materials and Methods

This study evaluated the frequency and spectrum of dermatological findings in IBD patients and their sociodemographic correlations. Participants from a tertiary care outpatient clinic underwent detailed dermatological examinations, supplemented by dermoscopy and histopathology when necessary. Clinical and sociodemographic data were recorded after obtaining ethical committee approval. Statistical analysis was performed using SPSS v24.0, with significance set at $p < 0.05$.

Results

The study included 100 patients (53% male; mean age 40.14 ± 18.12 years; mean disease duration 77.8 ± 81.49 months), comprising 53 UC, 46 CD, and 1 IBD-U case. Mucocutaneous manifestations were identified in 87% of patients (90.6% in UC, 82.6% in CD). The presence of mucocutaneous manifestations was not significantly associated with age, sex, age at IBD onset, disease duration, treatment status, smoking habits, comorbidities, type of comorbidity, or history of IBD-related surgery. A broad spectrum of dermatological findings was observed among the patients. Frequent findings included fungal infections (26%), cutaneous contiguous CD (13%), psoriasis (13%), and oral aphthous stomatitis (11%). Less frequent findings were paradoxical psoriasis (3%), corticosteroid-induced acne (6%), and infliximab-related anaphylaxis (1%). Premalignant and malignant cutaneous lesions, including actinic keratosis, squamous cell carcinoma, and basal cell carcinoma were detected in 6% of patients. Infectious dermatological conditions were predominantly fungal infections (26%), followed by bacterial infections (8%) and viral infections, including HPV, HSV, and herpes zoster. In addition, various non-specific dermatological conditions, such as acne vulgaris, seborrheic dermatitis, xerosis cutis, and different types of alopecia, were commonly identified.

Premalignant/malignant lesions (6%) significantly correlated with male sex ($p = 0.028$) and IBD onset ≥40 years ($p = 0.007$). UC patients had significantly higher rates of total fungal infections (p = 0.005), tinea pedis ($p = 0.003$), and onychomycosis ($p = 0.016$) compared to CD. In the CD subgroup, corticosteroid therapy was significantly associated with cutaneous contiguous CD ($p = 0.022$), and rural residency with higher fungal infection rates ($p = 0.041$).

Conclusions

This study demonstrates that dermatological manifestations in IBD encompass a broad clinical spectrum and may arise both as direct findings related to the disease and complications associated with treatment. The high prevalence of mucocutaneous manifestations observed in our cohort highlights the importance of routine dermatological evaluation in patients with IBD, particularly for suspicious cutaneous lesions. Early recognition and appropriate management of these manifestations may help reduce disease burden, optimize treatment outcomes, and improve patients' quality of life.

EADV CONGRESS
VIENNA
30 SEP - 3 OCT 2026

Abstract N°: 2890

Erythema Nodosum Associated with Idiopathic Granulomatous Mastitis During Pregnancy

Khadija Essekakri*[1], Bouchra Baghad[1], Soumiya Chiheb[1]

[1] University hospital Ibn Rochd, CASABLANCA, Morocco

Introduction

Idiopathic granulomatous mastitis (IGM) is a rare chronic inflammatory breast disease affecting mainly women of reproductive age. Its association with erythema nodosum (EN) and inflammatory arthralgias is uncommon and supports the hypothesis of an underlying autoimmune or autoinflammatory mechanism. Occurrence during pregnancy remains exceptional and may represent a diagnostic challenge.

Case Presentation

A 35-year-old pregnant woman at 20 weeks gestation presented with fever, a painful inflammatory breast mass, erythema nodosum of both lower limbs, and inflammatory arthralgias evolving for two months. Physical examination revealed multiple tender erythematous nodules on the legs and a large irregular inflammatory mass involving the left breast without nipple retraction. Breast ultrasonography showed mastitis classified as BIRADS 3. Core needle biopsy demonstrated non-caseating epithelioid granulomas with multinucleated giant cells and mixed inflammatory infiltrate, without evidence of malignancy or infection. GeneXpert testing for Mycobacterium tuberculosis was negative. Skin biopsy confirmed septal panniculitis compatible with erythema nodosum. The patient received short-course systemic corticosteroids with rapid improvement of the cutaneous lesions.

Conclusion

This case emphasizes that idiopathic granulomatous mastitis should be considered among the potential etiologies of erythema nodosum associated with inflammatory breast lesions during pregnancy. Early recognition may facilitate appropriate diagnostic evaluation and avoid unnecessary aggressive interventions.

EADV CONGRESS
VIENNA
30 SEP - 3 OCT 2026

Abstract N°: 2935

Diffuse Cutaneous Sclerosis Beyond Autoimmunity: A Diagnostic Challenge Revealing Scleromyxedema

Maria Lúcia Paysano*[1], Livia Ribeiro[1], Danielle Quintella[1], Tullia Cuzzi[1], FELIPE AGUINAGA[1]

[1] Instituto de Dermatologia Professor Rubem David Azulay - Santa Casa da Misericórdia do Rio de Janeiro, Rio de Janeiro, Brazil

Introduction

Scleromyxedema is a rare chronic cutaneous mucinosis characterized by dermal mucin deposition, fibroblast proliferation and progressive skin sclerosis, frequently associated with monoclonal gammopathy. Due to its overlapping clinical presentation with autoimmune and metabolic sclerosing disorders, diagnosis may be significantly delayed. Diagnostic differentiation from other causes of diffuse cutaneous sclerosis remains clinically challenging.

Case Presentation

A 62-year-old woman with type 2 diabetes mellitus presented with a two-year history of progressive cutaneous induration initially affecting the cervical region and later extending to the arms and forearms. The patient had previously been evaluated at another institution and treated with systemic corticosteroids and methotrexate under the presumptive diagnosis of morphea, achieving only transient initial improvement. Over time, she developed marked functional impairment, including difficulty opening her eyes and inability to receive intramuscular vaccination in the upper limbs due to severe skin hardening.

Physical examination revealed diffuse skin thickening with an edematous and sclerotic appearance.Autoimmune investigation yielded negative results, including antinuclear antibodies, anti-dsDNA, anti-Ro, anti-La, and anti-Scl-70 antibodies. Given the atypical clinical course, negative autoimmune investigation, and inadequate response to immunosuppressive therapy, the diagnosis was reconsidered. The coexistence of diabetes mellitus and the diffuse posterior cervical and upper trunk sclerosis initially raised suspicion for scleredema diabeticorum, while scleromyxedema, generalized morphea, and systemic sclerosis were also considered in the differential diagnosis.

New biopsies obtained from cervical, dorsal and axillary regions demonstrated histopathological findings compatible with scleromyxedema. Additional investigation revealed positive urinary Bence-Jones protein immunofixation, while serum protein electrophoresis remained normal. The patient was referred for hematologic evaluation, and treatment with intravenous immunoglobulin.

Conclusion

This case highlights the diagnostic complexity of diffuse cutaneous sclerosis and emphasizes the importance of reconsidering the diagnosis in patients with atypical clinical progression, negative autoimmune serology and poor response to conventional immunosuppressive therapy. Recognition of scleromyxedema is essential due to its potentially severe and life-threatening systemic manifestations, association with monoclonal gammopathy and hematologic disorders, chronic progressive course, and the need for prompt multidisciplinary evaluation and treatment.

EADV CONGRESS
VIENNA
30 SEP - 3 OCT 2026

Abstract N°: 2973

Oncologic Malnutrition Reflected Through the Skin: A Case of Secondary Pellagra

Georgiana-Maria Vesa*[1], Simona Frățilă[1]

[1] Bihor County Emergency Clinical Hospital, University of Oradea, Oradea, Romania

Introduction

Pellagra is a rare disorder caused by vitamin B3 deficiency or impaired niacin metabolism. Its clinical manifestations include cutaneous lesions, gastrointestinal signs and symptoms, and neuropsychiatric disturbances. Pellagrous dermatitis belongs to the group of photodermatoses, with symmetric, well-demarcated eruptions involving ultraviolet-exposed areas. Although traditionally regarded as a historical disorder linked to poverty and maize-based diets, pellagra persists today in specific high-risk populations, including oncologic patients.

Case Presentation

We present the case of a 49-year-old chronic smoker, severely underweight, with squamous cell carcinoma of the left hemilingual region undergoing radiochemotherapy, admitted to the Dermatology and Venereology Clinic for an asymptomatic photodistributed cutaneous eruption with onset three months prior. The lesions initially appeared on the dorsal aspects of the hands and the right elbow region, subsequently extending symmetrically to the contralateral side. Physical examination revealed, on the distal arms and bilateral elbow regions, well-demarcated irregular plaques with central hypopigmentation and hyperpigmented, hyperkeratotic, wrinkled margins covered by coarse white scales. Bilateral dorsal hand hypopigmentation and xerosis were also observed. Based on the clinical presentation, a diagnosis of pellagrous dermatitis was established and confirmed ex juvantibus: nicotinamide 300 mg/day was initiated for four weeks, followed by a maintenance dose of 100 mg/day. This proved that the principal contributor to his nutritional deficiency was reduced oral intake secondary to tumor-related dysphagia and odynophagia. Marked improvement was evident within two weeks, with complete resolution of the hyperpigmentation and hyperkeratosis, as well as improvement of the xerosis and hypopigmentation.

Conclusion

Oncologic patients are predisposed to multiple nutritional deficiencies, particularly when tumor location or treatment compromises alimentation. Pelagra should therefore be considered in the differential diagnostic of any photodistributed dermatosis in this population, where the skin may be the first accesible indicator of an underlying nutritional crisis, and the dermatologist, first to detect it.

EA DV CONGRESS
VIENNA
30 SEP - 3 OCT 2026

Abstract N°: 3003

Revisiting Retinal Effects in Hydroxychloroquine Therapy: Insights From 35 Years of Continuous Use

Rossel Ahmad*[1], Maryam Kakar[1], Sam Hughes[2], Nina Muirhead[2], Kim Varma[2]

[1] King's College London, London, United Kingdom
[2] Guy's and St Thomas Hospital, London, United Kingdom

Introduction

Hydroxychloroquine (HCQ), an anti-malarial drug, is commonly used for a wide range of autoimmune and chronic inflammatory dermatoses. By accumulating within the lysosomes of antigen presenting cells, the drug creates an alkaline environment, inhibiting dendritic cells to present antigens to the immune system. For decades, it's use in dermatology has been common place for systemic lupus erythematosus, lichen planus and frontal fibrosing alopecia.

Retinal toxicity is a concern due to drug accumulation the retinal pigment epithelium, causing irreversible photoreceptor apoptosis. As a well recognised, dose-dependent side effect, the Royal College of Ophthalmologists (RCOphth) recommend a daily dose of up to 5mg/Kg/day (based on real body weight). By adhering to this rule, the rate of HCQ-induced retinopathy in the UK, is estimated to be <1% at 5 years and <2% at 10 years. That said, risk rises markedly after 10 years of use, with figures rising to almost 20% after 20 years of use, indicating a sharp inflection once a toxic threshold is reached.

Aside from dose, the two main other risk factors for retinopathy, include an eGFR of <60mL/min/1.73 m^2 and concurrent Tamoxifen use. Should patients have either of these risk factors, the RCOphth recommend commencing annual retinal screening with Spectral-Domain Optical Coherence Tomography (SD-OCT) after 1 year of treatment, instead of the standard 5 years.

Case Presentation

We report a 61 year old female with frontal fibrosing alopecia treated with uninterrupted hydroxychloroquine therapy since 1995, representing 35 years of continuous drug exposure. The dose throughout was 200mg once daily, corresponding to an estimated daily exposure of [?] mg/kg/day at a body weight of [?] kg, with an estimated cumulative dose of [?] g. The patient had no underlying risk factors for retinal toxicity such as renal impairment or tamoxifen use.

Unfortunately, due to a lack of continuity in healthcare provision / prescribers, the patient at no point, had undergone any retinal screening. Upon realisation of this, the drug was temporarily withheld and an urgent ophthalmology referral was made, which upon serial SD-OCT imaging, has thankfully confirmed no evidence of retinopathy.

The risk of HCQ-induced retinopathy increases markedly after 10 years of treatment—rising to approximately 20% after 20 years, reflecting a threshold phenomenon rather than a linear relationship with duration alone. Previous retrospective analyses of patients receiving long-term hydroxychloroquine therapy (exceeding 20 years) demonstrate that the risk of retinopathy does not correlate with treatment indication, age, or gender. Moreover, although smoking is known to reduce the therapeutic efficacy of hydroxychloroquine, available evidence does not support a protective effect against retinal toxicity.

This case illustrates that retinal toxicity risk correlates more accurately with daily dose relative to body weight than with cumulative duration of therapy. Maintenance of a consistently low daily dose, well below the recommended threshold of 5 mg/kg/day, likely limited intra-retinal drug accumulation in this case. In addition, the absence of recognised risk modifiers, including renal impairment and concurrent tamoxifen use, further reduced the likelihood of toxicity despite prolonged exposure.

Conclusion

The Royal College of Ophthalmologists guidance recommends a maximum HCQ dose of 5 mg/kg/day, with UK retinopathy rates estimated at <2% at 10 years when adhered to. Risk rises sharply beyond 10–20 years, suggesting a toxic threshold effect. This case demonstrates that daily dose relative to body weight is a more important predictor of retinal toxicity than cumulative duration alone. Conservative dosing and appropriate patient selection may confer significant protection, even with prolonged exposure. This case also highlights the critical importance of regular ophthalmological screening, particularly when prescribing responsibility is shared across specialties.

EA DV CONGRESS
VIENNA
30 SEP - 3 OCT 2026

Abstract N°: 3005

Bullous Sweet syndrome with pulmonary involvement in a neutropenic patient: case report

Nathaly Liliana Castro Barreto*[1], Harold Farit Arenas Torrado[1], Hector Perez[1]

[1] Universidad Nacional de Colombia, Bogotá, Colombia

Introduction

Bullous dermatoses in immunocompromised patients pose a diagnostic challenge because of overlapping clinical features and immunologic backgrounds, requiring consideration of autoimmune, paraneoplastic, and infectious causes. Bullous Sweet's syndrome, though rare, should be a differential diagnosis, described in chronic illness or hematolymphoid neoplasms.

Case Presentation

A 71-year-old woman with myelodysplastic syndrome with 5q deletion, receiving third-line therapy with decitabine and venetoclax, presented with a urinary tract infection treated with parenteral antibiotics. On day four, she developed persistent high fever, prompting antibiotic escalation. She subsequently developed vesicles and tense bullae on a violaceous base over the limbs and trunk, along with erythematous papules on the forehead, hard palate, and palms. Her condition worsened with respiratory symptoms, hypotension, and hypoperfusion, requiring ICU admission and vasopressor support due to suspected sepsis.

Chest CT showed multilobar basal consolidations and peribronchovascular nodules. Bronchoalveolar lavage demonstrated neutrophilic predominance. She received 18 days of broad-spectrum antimicrobial therapy (ceftazidime/avibactam, linezolid, amphotericin B, and caspofungin) for suspected invasive fungal infection.

Given the cutaneous findings, differential diagnoses included erythema multiforme major and bullous Sweet's syndrome, with disseminated herpes and vasculitis considered less likely. Skin biopsy revealed a neutrophilic dermal infiltrate with intraepidermal vesicles and no interface dermatitis, confirming bullous Sweet's syndrome. Treatment with methylprednisolone 40 mg daily for 14 days led to marked improvement in both skin lesions and pulmonary infiltrates. She was discharged with gradual steroid tapering and has had no relapse.

Sweet's syndrome is a rare neutrophilic dermatosis of noninfectious origin, classified as classic, drug-induced, or malignancy-associated (approximately 21% of cases, most commonly linked to hematologic neoplasms such as myelodysplastic syndrome). It may involve extracutaneous organs; pulmonary involvement is uncommon but potentially severe, characterized by infiltrates and neutrophilic predominance on bronchoalveolar lavage with negative cultures.

Although some cases resolve spontaneously, treatment is indicated in extensive or systemic disease. Corticosteroids remain first-line therapy (prednisolone 0.5–1 mg/kg/day or methylprednisolone pulses). Alternatives include indomethacin, colchicine, acitretin, dapsone, and biologic agents such as anti-TNF or anti–IL-1 therapies.

Conclusion

The case presented highlights the diagnostic challenge posed by the bullous presentations of Sweet's syndrome, especially in immunosuppressed patients with underlying malignancies. Additionally, it may have rare and

potentially life-threatening manifestations, such as pulmonary involvement, where clinical suspicion and early use of corticosteroids can change the prognosis.

EADV CONGRESS
VIENNA
30 SEP - 3 OCT 2026

Abstract N°: 3012

Epidemiology and Outcomes of Neurofibromatosis Type 1 (NF-1): Multicenter Tertiary Experience

Fares Alammari*[1], Rayan Alkhodair[2], Mohammed Almuqbil[2]

[1] College of Medicine, Almaarefa university, Riyadh, Saudi Arabia

[2] King Saud Bin Abdulaziz University for Health Sciences (KSAU-HS), Riyadh, Saudi Arabia

Introduction

Neurofibromatosis type 1 (NF-1), or von Recklinghausen's disease, is an autosomal dominant multisystem disorder with an incidence of 1 in 2,000-3,000, caused by mutations in the NF1 gene on chromosome 17q11.2 encoding neurofibromin. Cutaneous features are typically the earliest and most recognizable manifestations, placing dermatologists at the forefront of diagnosis. Café-au-lait macules (CALMs), skin-fold freckling (Crowe's sign), and cutaneous and plexiform neurofibromas form the dermatological cornerstones of the revised 2021 NIH diagnostic criteria, which also integrated molecular testing and refined phenotypic features to distinguish NF-1 from Legius syndrome. Data on the dermatological spectrum of NF-1 from Saudi Arabia remain limited. This study evaluated the cutaneous and systemic features of NF-1 using the revised criteria.

Table 1 Revised Diagnostic Criteria

Revised Diagnostic Criteria	Frequency	Percentage
≥ 6 Café-au-lait macules	157	85.3
Skin-fold freckling	64	34.8
≥2 *Neurofibromas*	79	42.9
Plexiform neurofibroma	43	23.4
Dermal neurofibroma	22	12.5
Both	8	4.3
Unspecified	6	3.3
Iris Lisch nodules	67	36.4
Distinctive osseous lesion	12	6.5
Sphenoid wing dysplasia	7	3.8
Pseudoarthrosis of a long bone	3	1.6
Anterolateral bowing of tibia	2	1.1
Optic nerve glioma	38	20.7
Visual impairment	16	8.7
Optic atrophy	1	0.5
Orbital nerve affected	7	3.8
Chiasm involvement	12	6.5
Heterozygous pathogenic NF1 variant in apparently normal tissue (50%)	90	48.9
First degree relative with NF1	43	23.5
Mother	9	4.9
Father	34	18.5

Materials and Methods

A retrospective, cross-sectional, observational study was conducted across the Ministry of National Guard Health Affairs (MNGHA) network in Saudi Arabia, encompassing four tertiary hospitals and 51 primary care centers in Riyadh, Jeddah, Al-Ahsa, Dammam, and Medina. Electronic medical records (BESTCare 2.0A) from April 2015 to April 2021 were reviewed. All pediatric and adult patients fulfilling the revised 2021 NIH diagnostic criteria for NF-1 were included; patients with NF-2 or Legius syndrome were excluded. Demographics, cutaneous and extracutaneous manifestations, neuro-oncological findings, and comorbidities were extracted via standardized chart review. Descriptive statistics were performed with SPSS v27; continuous non-normally distributed variables were reported as median and interquartile range (IQR).

Results

184 patients (53.3% female, 46.7% male) met the revised criteria, with a median age of 16 years (IQR: 9.0-16.0) and median age at diagnosis of 11 years (IQR: 4.0-20.3). Cutaneous findings dominated the phenotype: ≥6 café-au-lait macules were the most prevalent feature in 157 patients (85.3%), at a median age of 8 years. Skin-fold freckling occurred in 64 patients (34.8%), most commonly axillary (26.1%). Neurofibromas were documented in 79

patients (42.9%): plexiform in 23.4% (28 required surgery), cutaneous in 12.5%, and both subtypes in 4.3%. Iris Lisch nodules were present in 36.4% (median age 12 years). A heterozygous pathogenic NF1 variant was confirmed in 48.9%, and 23.5% had a first-degree relative with NF-1. Distinctive osseous lesions occurred in 6.5% (sphenoid wing dysplasia 3.8%). Optic pathway glioma was present in 20.7%, with visual impairment in 8.7%. Tumors of any type were seen in 26.6%, including extra-neural tumors in 14.1% and neurofibrosarcoma in 1.1%. Systemic features included headache (27.7%), epilepsy (11.4%), scoliosis (14.1%), macrocephaly/hydrocephalus (14.7%), cardiovascular abnormalities (9.8%), short stature (9.2%), and precocious puberty (2.2%). Among 67 pediatric patients, neurodevelopmental disorders included communication disorders (33.8%), learning disorders (20.9%), ADHD (14.9%), motor disorders (13.4%), intellectual disability (10.5%), and ASD (3.0%).

Conclusions

Cutaneous manifestations - café-au-lait macules, skin-fold freckling, and cutaneous and plexiform neurofibromas - remain the most frequent and earliest recognizable features of NF-1 and position dermatologists as key gatekeepers for timely diagnosis using the revised 2021 NIH criteria. Recognition of these dermatological hallmarks should prompt comprehensive multidisciplinary evaluation for ophthalmologic, neuro-oncologic, skeletal, cardiovascular, and neurodevelopmental complications. Early dermatologic identification facilitates accurate diagnosis, appropriate genetic counseling, and timely intervention, improving overall outcomes for patients with NF-1.

EADV CONGRESS
VIENNA
30 SEP - 3 OCT 2026

Abstract N°: 3028

Buschke Scleredema, the Cutaneous Reflection of Glycemic Imbalance: A Report of Four Cases

Nouhaila Amrani*[1], ines lahouel[1], mariem mohamed[1], yosra soua[1], Monia Youssef[1], hichem Belhadjali[1], Jameleddine Zili[1]

[1] Dermatology Department, CHU Fattouma Bourguiba Monastir, Monastir, Tunisia

Introduction

Buschke Scleredema is a rare scleroderma-like disorder of unknown etiology, characterized by thickening and induration of the dermis and subcutaneous tissues. It predominantly involves the posterior neck and upper trunk, typically sparing the distal extremities, in contrast to systemic sclerosis. Its prevalence among patients with diabetes mellitus is estimated to range from 2.5% to 14%; however, the condition remains largely underdiagnosed. Through this case series, we highlight the clinical heterogeneity, endocrine implications, and therapeutic challenges associated with scleredema of Buschke.

Case Presentation

We report four patients (two women and two men), aged 36 to 65 years, who presented with painless, non-pitting, sclerotic skin thickening predominantly affecting the nuchal region and upper trunk. The diagnosis of scleredema of Buschke was histologically confirmed in all cases. Long-standing, complicated diabetes mellitus was documented in three patients, whereas in one patient diabetes was previously undiagnosed, with scleredema serving as the revealing manifestation in the context of moderately elevated glycated hemoglobin (HbA1c). An unusual association with scalp mucinosis was observed in one case. Therapeutic management mainly consisted of systemic corticosteroid therapy, leading to variable clinical improvement; however, one patient developed iatrogenic adrenal insufficiency as a complication. Another patient was treated with topical corticosteroids combined with vitamin D analogues, achieving marked clinical improvement. Optimization of glycemic control was systematically implemented in all cases.

Conclusion

The pathophysiology of diabetic scleredema is thought to involve chronic hyperglycemia inducing non-enzymatic glycation of collagen fibers, rendering them resistant to degradation. This process is associated with fibroblast stimulation and subsequent accumulation of glycosaminoglycans within the dermis. Our observations illustrate the variability of clinical presentations, the potential role of scleredema of Buschke as a presenting sign of previously unrecognized diabetes mellitus, and the endocrine complications related to therapeutic interventions, particularly systemic corticosteroid therapy

Buschke Scleredema represents a rare cutaneous manifestation of diabetes mellitus that may reveal an underlying metabolic imbalance. It requires thorough endocrine evaluation and a tailored multidisciplinary management approach

EA DV CONGRESS
VIENNA
30 SEP - 3 OCT 2026

Abstract N°: 3038

Linear Gluteal Ulceration Mimicking Cutaneous Crohn's Disease: An Unexpected Diagnosis

Durreshahwar Hashmi*[1], David Jackson[1]

[1] Walsall Healthcare NHS Trust, Birmingham, United Kingdom

Introduction

Bile acid malabsorption (BAM) is an under-recognised cause of chronic diarrhoea resulting from impaired enterohepatic recycling of bile acids. Excess colonic bile acids can cause epithelial injury, secretory diarrhoea, and chronic perianal irritation. Cutaneous manifestations are rarely reported and may closely mimic inflammatory dermatoses, creating significant diagnostic uncertainty. We present an unusual case of chronic perianal ulceration secondary to BAM, initially suspected to represent cutaneous Crohn's disease, with the final diagnosis established nine years after initial symptom onset.

Case Presentation

A 58-year-old woman presented with a three-year history of painful ulcerated "kissing" lesions extending from the natal cleft to the perineum, although symptoms had initially begun nine years prior to the eventual diagnosis. The lesions were intensely pruritic, intermittently weeping, and progressively impairing mobility and sleep. Potent topical corticosteroids provided only transient improvement. Examination demonstrated extensive perianal ulceration with deep linear fissuring, clinically raising suspicion for cutaneous Crohn's disease or pyoderma gangrenosum.

Further history revealed chronic diarrhoea with bowel frequency of up to ten times daily and significant urgency, suggesting an underlying gastrointestinal disorder. Blood tests demonstrated chronic microcytic iron deficiency anaemia with persistent folate and zinc deficiencies, raising suspicion of malabsorption. FIT testing was positive. TTG IgA and total IgA levels were within normal limits.

Histology from multiple biopsies demonstrated reactive epidermal changes consistent with lichen simplex chronicus and non-specific ulceration, without granulomatous inflammation or features of pyoderma gangrenosum. Colonoscopy with duodenal biopsies and oesophagogastroduodenoscopy demonstrated no evidence of inflammatory bowel disease, coeliac disease, or malignancy. Despite negative endoscopic findings, the clinical appearance and gastrointestinal symptoms continued to raise suspicion for cutaneous Crohn's disease.

Given ongoing diarrhoea and concurrent opiate use, the patient was referred to colorectal surgery to exclude overflow diarrhoea. Subsequent SeHCAT scanning demonstrated reduced bile acid retention, confirming bile acid malabsorption. Empirical antimicrobial therapy and zinc supplementation were ineffective, while topical dermovate and trimovate provided only temporary symptomatic relief. Following diagnosis and management of BAM, the patient experienced improvement in both diarrhoeal symptoms and ulceration.



Figure 1 - Extensive bilateral linear ulceration and fissuring involving the natal cleft and perianal region.

Conclusion

This case highlights an atypical presentation of BAM manifesting as chronic perianal ulceration closely resembling cutaneous Crohn's disease. Persistent diarrhoea, micronutrient deficiencies, and reactive non-specific histology ultimately supported a secondary irritant process rather than a primary inflammatory dermatosis. The prolonged nine-year diagnostic delay further emphasises the importance of maintaining a broad differential diagnosis in chronic perianal ulceration and considering gastrointestinal causes, including BAM, even where initial endoscopic investigations are unremarkable.

EADV CONGRESS
VIENNA
30 SEP - 3 OCT 2026

Abstract N°: 3050

A case report of non-healing dorsal hand fish tank granuloma mimicking SCC: the importance of clinicopathological correlation

Ahmed F Hawwa*[1], Yen Xi Low[2], Raman Bhutani[1]

[1] Salford Royal Hospital, Dermatology Centre, Manchester, United Kingdom

[2] Stepping Hill Hospital, Department of Cellular Pathology, Stockport NHS Foundation Trust, Poplar Grove, Stockport, United Kingdom

Introduction

Mycobacterium marinum can cause infections in humans especially fish handlers, hence referred to as 'fish tank granuloma'. Due to its indolent course and non-specific clinical features, diagnosis is frequently delayed. Histological diagnosis can also be difficult as Ziehl-Neelson staining is frequently negative due to very low concentration of microorganism making confirmation from staining procedure difficult.

Case Presentation

We present a case of fish tank granuloma misdiagnosed as recurrent cellulitis for 30 months, highlighting the utility of histology even when special stains are negative.

A 60-year-old male presented with 2.5-year history of a non-healing indurated lesion on the right dorsal hand. It measured 80x45mm in size and had intermittent purulent discharge. Multiple courses of antibiotics for presumed cellulitis have only led to transient improvement but never a complete resolution. He initially attributed the lesion to a lobster prick, but detailed exposure history revealed exposure to multiple fish tanks and a garden pond without wearing gloves. Incisional biopsy was taken diagnose the lesion.

Histopathology showed pseudo-epitheliomatous hyperplasia of the epidermis with spongiosis and focal erosion. The dermis contained occasional multinucleated giant cells and scattered eosinophils. Areas of neutrophilic abscess formation and occasional foci of poorly formed granuloma were present. Although Ziehl-Neelsen stain did not identify organisms and DPAS/Grocott stains were negative for fungi, histopathological appearance was consistent with granulomatous inflammation compatible with fish tank granuloma. After clinicopathological correlation, the patient was treated successfully with 4-week course of oral doxycycline which resulted in complete resolution of the lesion.

Conclusion

The present case demonstrated the complexity of diagnosing infections by non-tuberculous mycobacteria, especially *Mycobacterium marinu* resulting in increasing infections related to fish tank hobby. Pseudo-epitheliomatous hyperplasia can mimic SCC and special stains are often negative highlighting the utility of clinicopathological correlation and importance of obtaining a detailed exposure history.

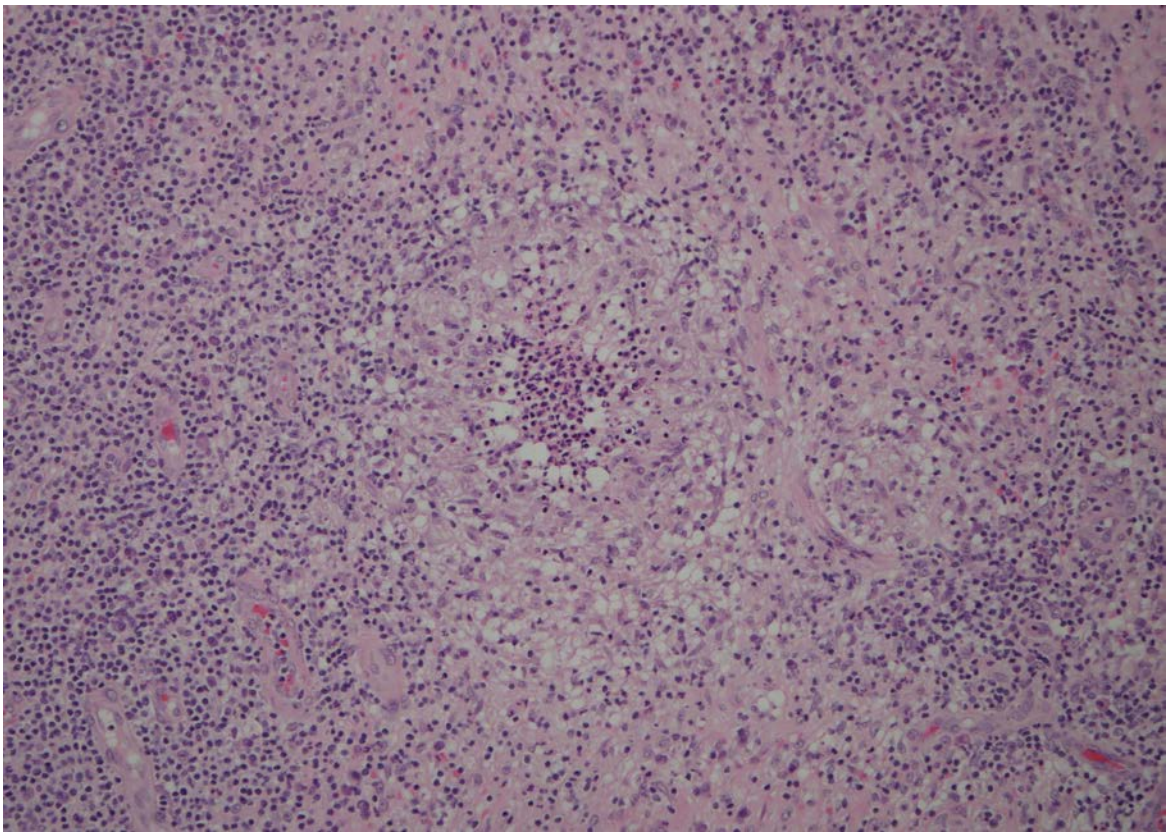

Histopathology at 100x showing multinucleated giant cells and scattered eosinophils

EA DV CONGRESS
VIENNA
30 SEP - 3 OCT 2026

Abstract N°: 3051

PORPHYRIA CUTANEA TARDA: a case report of the diagnostic challenge within a public healthcare system

Amanda Zanini*[1], Sarah Acedo[2], Raisa Resende[3], Estela Pimenta[3]

[1] Franca Municipal University Center, Franca, Brazil
[2] University Nove de Julho, São Paulo, Brazil
[3] Marília College, Marília, Brazil

Introduction

Porphyria cutanea tarda (PCT) is a rare metabolic disorder affecting approximately 5–10 individuals per 100,000, mainly middle-aged and older adults. It results from a partial deficiency of uroporphyrinogen decarboxylase (UROD), which may be inherited or acquired, leading to the accumulation of uroporphyrin and 7-carboxyl porphyrinogen, primarily in the liver. Most patients do not carry pathogenic UROD mutations but present risk factors that reduce hepatic enzyme activity, including hepatitis C, alcohol consumption, iron overload, estrogen use, HIV infection, smoking, and HFE gene mutations associated with haemochromatosis, which are important to identify due to the potential classification into PCT subtypes. The condition may regress following removal of the triggering factors.

Case Presentation

The case concerns a 53-year-old male patient who reported a four-month history of asymptomatic bullous lesions on the dorsum of the hands, appearing spontaneously without associated trauma and with no history of addictions or identifiable triggering factors. Laboratory investigations, including screening for hepatitis B and hepatitis C, were non-reactive. Physical examination revealed a tense blister on the left thumb and atrophic scars with a keratotic centre on the dorsum of the hands, with no evidence of miliaria, hypertrichosis, facial lanugo, or clinical signs of scarring alopecia. The main diagnostic consideration was an undetermined bullous disease, and an incisional biopsy from the blister edge was performed for further evaluation. Histopathology demonstrated a subepidermal blister without significant content, festooning of the dermal papillae, and absence of inflammatory infiltrate, while PAS staining showed mild hyalinisation of superficial dermal vessels. Despite limitations in ancillary testing, a high index of clinical suspicion may facilitate a more accurate diagnosis.

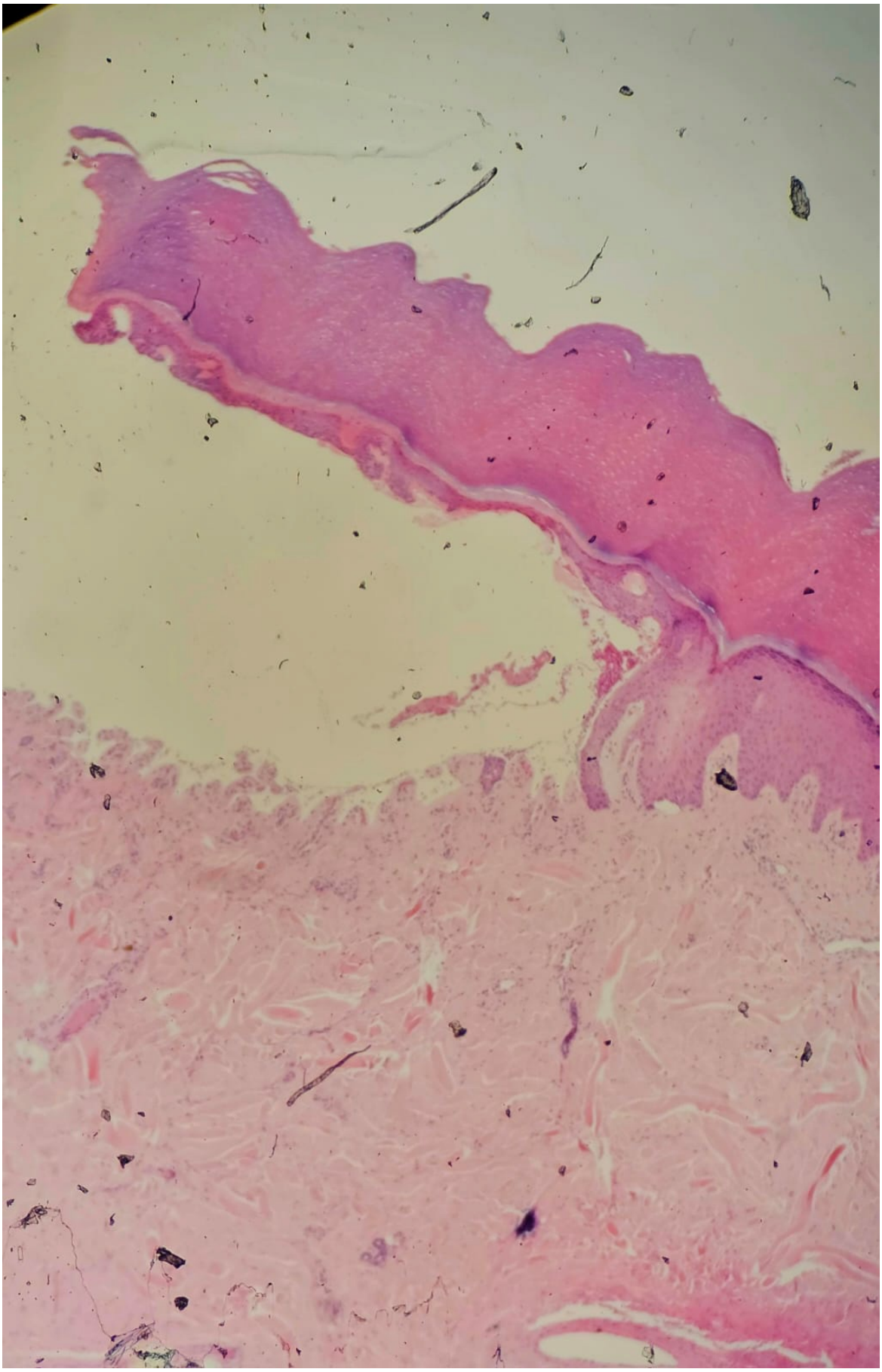

Histopathological examination revealing subepidermal blister without significant content, festooning of the dermal papillae and absence of inflammatory infiltrate

Conclusion

Clinically, PCT is characterised by skin fragility with vesicles, blisters, erosions and crusts in sun-exposed areas such

as the face, dorsum of the hands and feet, often resulting in scarring with pigmentary changes, milia and diffuse hyperpigmentation. Histopathology shows a subepidermal blister with festooning of dermal papillae due to upper dermal rigidity from eosinophilic vascular deposits, with minimal or absent inflammation. Thus, the present case is clinically and histologically compatible with PCT; however, further investigations are essential, as diagnosis is primarily based on elevated porphyrins in plasma, urine and faeces, while ferritin levels, liver disease and genetic factors may support clinical assessment. This study highlights the importance of considering PCT even in settings with limited diagnostic resources, given its classification and potential complications.

EADV CONGRESS
VIENNA
30 SEP - 3 OCT 2026

Abstract N°: 3060

Primary cutaneous nodular amyloidosis: a case report

Cristian Pizarro Vargas*[1], Vicente Bravo-Ovando[2], Camilo Barraza[1]

[1] Hospital Base Osorno, Osorno, Los Lagos, Chile
[2] Universidad Austral de Chile, Osorno, Los Lagos, Chile

Introduction

Amyloidoses comprise a heterogeneous group of diseases characterized by extracellular deposition of amyloid material. They may present in systemic or localized forms, including primary cutaneous variants. Primary cutaneous amyloidoses are classified as macular, lichenoid, and nodular, with the latter being the least frequent, accounting for approximately 1.5% of cutaneous forms.Primary cutaneous nodular amyloidosis (PCNA) is characterized by dermal and subcutaneous deposits of immunoglobulin light chains produced by plasma cells infiltrating the skin and deep tissues.

Case Presentation

A 66-year-old female patient of Mapuche-Huilliche descent, with no known medical history and no regular medication use, was referred for evaluation during hospitalization due to a one-year history of multiple subcutaneous nodules on both lower extremities, some of which were ulcerated and superinfected.

Physical examination revealed multiple deep subcutaneous nodules and masses on both legs, some adherent to deep planes and others ulcerated. Several lesions were tender on palpation and presented associated exudate.

The initial differential diagnosis included primary cutaneous B-cell lymphoma of the leg type, and a skin biopsy was performed. Histopathological examination showed amyloid deposits associated with an atypical plasma cell infiltrate, with kappa light chain restriction, CD138 positive, lambda negative, and positive Congo Red and Von Kossa stains — findings suggestive of plasma cell proliferation.

Evaluation by hematology-oncology was performed, a bone marrow biopsy was performed, which revealed hematopoietic marrow with reactive lymphoplasmacytosis and no signs of neoplasia. Immunohistochemistry was notable for interstitial CD3 positivity and interstitial CD20 positivity. Serum free light chain analysis showed kappa 58 mg/l, lambda 49 mg/l, with a preserved

kappa/lambda ratio. The remainder of the workup, including hepatic, renal, and cardiac studies, was unremarkable, effectively ruling out systemic amyloidosis. Subsequently, a new biopsy of the skin and a deep subcutaneous nodule was performed, confirming amyloid deposits and establishing the diagnosis of PCNA.

The patient received two cycles of Rituximab, one course of PUVA, and three sessions of intralesional Triamcinolone, resulting in a progressive reduction in the size of subcutaneous nodules, gradual healing of ulcerations, and no development of new lesions during follow-up.

Conclusion

PCNA is a rare disease that primarily affects adults. It carries a risk of progression to systemic amyloidosis of approximately 7%, thus requiring a thorough initial evaluation and long-term follow-up. The literature is

dominated by isolated case reports, with variable treatments that include surgery, intralesional corticosteroids, laser therapy, and systemic therapies such as cyclophosphamide and JAK inhibitors. Surgery has been one of the most frequently used strategies for localized lesions. In this case, rituximab was chosen for treatment, considering the presence of CD20-positive cells in the bone marrow and the multifocal extension with deep involvement, which limited surgical management. Cyclophosphamide was also ruled out due to its safety profile and potential adverse effects. Currently, there is no standard treatment for PCNA due to its low frequency and high recurrence rate. This case highlights the need to individualize therapeutic management and consider systemic alternatives in extensive or complex presentations.

EA DV CONGRESS
VIENNA
30 SEP - 3 OCT 2026

Abstract N°: 3060

Describing clinical characteristics and disease burden of paediatric patients with moderate-to-severe Atopic Dermatitis in real-world clinical practice in Kingdom of Saudi Arabia.

Maysa Tariq Eshmawi[1], Hind Alshihry[2], Adeeb Bulkhi[3, 4], Mufaddal Alaithan[5], Dana Alessa[6], Tamara Talhouk[7], Maryam Alessa[7], Niamh Harvey*[8], Oliver Howell[8], Yousef Binamer[9]

[1] Assistant Professor, College of Medicine, Imam Mohammad Ibn Saud Islamic University, Riyadh, Saudi Arabia

[2] consultant dermatologist, King Abdullah Medical Complex, Riyadh, Saudi Arabia

[3] Department of Internal Medicine, College of Medicine, Umm Al-Qura University, Makkah, Saudi Arabia

[4] Allergy and Immunology Department, King Abdulla Medical City, Makkah, Saudi Arabia

[5] Eli Lilly and Company, King Abdullah Medical Complex, Riyadh, Saudi Arabia

[6] College of Medicine, King Saud bin Abdulaziz University for Health Sciences (KSAU-HS) and Division of Dermatology, Department of Medicine, King Abdulaziz Medical City (KAMC), National Guard Health Affairs (NGHA),, Riyadh, Saudi Arabia

[7] Eli Lilly and Company, Riyadh, Saudi Arabia

[8] Adelphi Real World, Bollington, United Kingdom

[9] King Faisal Specialist Hospital & Research Centre, Adjunct Associate Professor, Alfaisal University, Riyadh, Saudi Arabia

Introduction

Atopic dermatitis (AD) is a chronic inflammatory skin condition characterised by intense itching and eczematous lesions. While up to 20% of paediatric patients experience AD globally, there is limited real-world research into paediatric AD in the Kingdom of Saudi Arabia (KSA). This study aims to describe patient demographics reported by physicians, clinical characteristics, disease burden and the satisfaction with disease control, alongside patient/caregiver-reported impact on patient/family quality of life (QoL) and satisfaction with disease control in moderate-to-severe paediatric patients with AD.

Materials and Methods

Data for patients aged <18 years with a history of moderate-to-severe AD were drawn from the Adelphi Real World paediatric AD II Disease Specific Programme™, a cross-sectional survey (with retrospective elements) of physicians, patients, and their caregivers conducted in the KSA between July−December 2025. Physicians provided data on patient demographics, clinical characteristics (including investigator global assessment (IGA), body surface area (BSA %), symptomatology, physician reported disease severity), treatment history and satisfaction with disease control. Patients and/or their caregivers completed the patient-oriented eczema measure (POEM), children's dermatology life quality index (CDLQI) and dermatitis family index (DFI) and reported satisfaction with disease control. A subgroup of patients with a physician reported disease severity of moderate-to-severe at data collection were also observed. Data were reported descriptively.

Results

In this analysis, 52 physicians reported data for 252 patients, of which, 54% (n=135/252) were male with a mean (standard deviation; SD) age of 9.6 (4.8) years and a median (IQR) disease duration of 1.9 (0.8, 5.3) years. At data collection, physicians reported most patients were experiencing dry skin (98%), pruritus (97%), skin pain (90%), sleep disturbance (88%) and scratching (83%). Mean (SD) BSA was 34.2% (19.8), 60% of patients had an IGA score of 3/4, and 79% of patients were moderate-to-severe as defined by the physician. 151 Patients (n=54) and

caregivers (n=97) reported mean (SD) POEM scores of 12.3 (4.7) and 10.7 (5.5) respectively, both indicating moderate disease. Using the CDLQI, 72% of patients (n=37/52) reported a ‘very - extremely large’ effect on their QoL and mean (SD) DFI score of 13.2 (5.9) were reported by patients/caregivers (n=140). Of those with moderate-to-severe physician reported disease severity at data collection who have ever received treatment (n=198), 51% were receiving an advanced therapy (n=89 receiving a biologic and n=23 receiving a Janus Kinase inhibitor). Patients (n=51) and caregivers (n=69) reported mean (SD) POEM scores of 12.6 (4.6) and 12.8 (5.1) respectively, a CDLQI of 16.2 (5.9) (very large effect on QoL) and DFI of 14.5 (5.6,) at data collection. Despite 82% (n=98/119) of patients/caregivers reporting satisfaction with disease control, 61% believe better control could be achieved; while 18% reported dissatisfaction. Physicians reported dissatisfaction with control in 15% (n=29/200) of patients and satisfaction with disease control for 85% of patients. However, for 46% of patients (n=105/200), physicians reported that despite being satisfied better control could be achieved.

Conclusions

These data suggest a high level of disease burden amongst moderate-to-severe paediatric AD patients from both physician and patient/caregiver perspectives. Physicians reported high symptomatic burden and skin coverage. Patients/caregivers reported the large impact of AD on their QoL as well as for their families. While physician, patient and caregiver reported disease control satisfaction is high, unmet need remains an important consideration for patients/caregivers, with many who were satisfied believing better control could still be achieved. Future research on treatment patterns and impact on outcomes is needed.

EA DV CONGRESS
VIENNA
30 SEP - 3 OCT 2026

Abstract N°: 3064

Paraneoplastic dermatomyositis revealing breast carcinoma

Tarek Mansoul*[1], Safa Djebbas[1], Ahmed Samaouel Chehad[1]

[1] Department of Dermatology, Benbadis University Hospital Center, University of Constantine 3, Constantine, Algeria

Introduction
Dermatomyositis is a rare disease of unknown etiology characterized by marked clinical and evolutionary heterogeneity, combining inflammatory involvement of striated muscles with characteristic cutaneous manifestations. A paraneoplastic origin has been reported in 6% to 60% of cases according to different series. The malignancies most frequently associated are ovarian and breast cancers in women, and bronchopulmonary, gastrointestinal, and nasopharyngeal cancers in men.

We report here a case of dermatomyositis revealing an underlying breast carcinoma.

Case Presentation
A 70-year-old woman with a medical history of hypertension and type 2 diabetes mellitus was referred to the dermatology department for a cutaneo-muscular syndrome evolving over the previous 6 months.

Clinical examination revealed an impaired general condition, heliotrope erythema, a “V-sign” involving the neckline, erythema affecting the extremities, extensor surfaces of the limbs, proximal thighs, and metacarpophalangeal joints. Poikilodermatous plaques of the upper chest and flagellate erythema of the back were also observed. Examination of the fingernails showed diffuse periungual erythema with a positive “manicure sign.” Capillaroscopy demonstrated giant capillaries and glomerular-shaped vascular loops.

Breast examination revealed a painful, firm left breast mass measuring approximately 3 cm in diameter, fixed to both superficial and deep planes. Tumor marker assessment showed elevated CA15-3 levels exceeding 53 IU/mL. Breast ultrasonography and mammography demonstrated mastitis-associated changes and an irregular posterior attenuation area with multiple suspicious microcalcifications, classified as ACR 5. Bone scintigraphy as well as thoraco-abdomino-pelvic and cerebral computed tomography scans showed no evidence of metastatic disease. Core needle breast biopsy was consistent with an atypical breast carcinoma classified as Scarff-Bloom-Richardson grade II (SBR II). Hormonal receptor status assessment is currently ongoing.

Laboratory investigations demonstrated elevated muscle enzyme levels. Electromyography revealed a predominantly proximal myogenic syndrome. The patient was started on prednisone at a dose of 1 mg/kg/day while awaiting initiation of neoadjuvant chemotherapy followed by mastectomy, as recommended during the multidisciplinary breast oncology meeting.

Conclusion
Since the first observation reported by Stertz in 1916, describing a patient with dermatomyositis associated with gastric adenocarcinoma, the association between dermatomyositis and malignancy has been well established. Neoplasia is usually diagnosed within the first year following the diagnosis of dermatomyositis but may occur up

to 5 years later. Dermatomyositis precedes cancer diagnosis in 60% to 80% of cases.

Compared with the general population, the risk of malignancy is estimated to be 3- to 6-fold higher in patients with dermatomyositis. Various malignancies have been reported in association with dermatomyositis, and virtually any anatomical site may be involved. However, gynecological malignancies, including breast cancer, appear to be particularly frequent.

Several clinical and biological features have been statistically associated with cancer-related dermatomyositis, including abrupt onset of cutaneo-muscular symptoms, low complement C4 levels, elevated erythrocyte sedimentation rate and C-reactive protein levels, and hypoalbuminemia. Advanced age over 50 years and male sex have also been considered predictive factors for an associated malignancy.

The course of dermatomyositis does not always parallel that of the underlying tumor. Nevertheless, malignancy remains the leading cause of death in patients with paraneoplastic dermatomyositis.

EA DV CONGRESS
VIENNA
30 SEP - 3 OCT 2026

Abstract N°: 3068

Pediatric case of chronic erythema nodosum

Tarek Mansoul*[1], Asma Djabri[1], Ahmed Samaouel Chehad[1]

[1] Department of Dermatology, Benbadis University Hospital Center, University of Constantine 3, Constantine, Algeria

Introduction

Erythema nodosum (EN) is the most common type of panniculitis, clinically characterized by tender nodules predominantly affecting the lower limbs. EN was long considered an acute disorder; however, several clinical forms have now been individualized, including chronic erythema nodosum. We report a case of chronic erythema nodosum in a 7-year-old girl.

Case Presentation

A 7-year-old girl was admitted to the dermatology department for chronic dermohypodermitis evolving over four years.

Clinical examination revealed cutaneomucosal pallor. Dermatological examination showed multiple painful inflammatory nodules embedded within erythematous and hyperpigmented plaques involving both legs. The remainder of the physical examination was unremarkable except for the presence of multiple dental caries.

Laboratory investigations demonstrated an inflammatory syndrome with an erythrocyte sedimentation rate of 75 mm/h and a C-reactive protein level of 43 mg/L. Antistreptolysin O (ASLO) titers were markedly elevated at 800 IU/mL. Complete blood count revealed neutrophilic leukocytosis (13,000/mm^3) associated with hypochromic microcytic anemia, low serum iron levels (27 µg/dL), and normal ferritin levels. Immunological investigations, 24-hour urinary calcium excretion, and alpha-1 antitrypsin levels were within normal limits.

Tuberculin skin testing was negative. Chest radiography showed no abnormalities, whereas panoramic dental radiography revealed multiple dental caries.

Histopathological examination demonstrated septal and perivascular inflammatory infiltrates within the hypodermis, composed predominantly of lymphocytes with a few neutrophils and occasional eosinophils, associated with fibrosis.

Management consisted of dental surgery for caries treatment, nonsteroidal anti-inflammatory therapy (niflumic acid 400 mg/day for 5 days), and long-term antibiotic therapy with benzathine benzylpenicillin (one injection every three weeks), resulting in complete remission.

Conclusion

Chronic erythema nodosum is a non-ulcerative inflammatory nodular eruption affecting the lower limbs, usually occurring in adult women and characterized by a prolonged and unpredictable course that may persist for years. Histopathologically, chronic EN is characterized by mild septal thickening, limited fibrosis, and perivascular lymphohistiocytic inflammation, sometimes associated with focal granulomatous formations, phlebitis, and hemorrhage.

The most commonly used treatments include nonsteroidal anti-inflammatory drugs, potassium iodide, colchicine, hydroxychloroquine, and systemic corticosteroids in refractory cases.

Although chronic EN is generally idiopathic, it may share the same etiologies as classical EN in some cases. In our patient, the elevated ASLO titers, the presence of multiple dental caries, and the favorable response to benzathine penicillin strongly support a post-streptococcal etiology.

EA DV CONGRESS
VIENNA
30 SEP - 3 OCT 2026

Abstract N°: 3108

Beyond infection: pediatric Behçet disease with overlapping pyoderma gangrenosum presenting as recurrent ulcerative dermatosis

João Pedro Carrijo Cunha Camara*[1], Ana Carolina[1], Silvia Soutto Mayor[1], Carolina Contin[1], Luana Estanqueiro[1], Iona Moreira[1], Luiza Zetone[1], Mariana Risso[1], Tifany Ito[1], Juliana Mathias Bertonha[1], Beatriz Farias[1], Amanda Ferrari[1]

[1] Santa Casa de São Paulo, São Paulo, Brazil

Introduction

Chronic ulcerative dermatoses in children represent a significant diagnostic challenge, given the substantial overlap between infectious and inflammatory etiologies. Conditions such as pyoderma gangrenosum (PG) and Behçet disease, both capable of presenting with severe mucocutaneous ulcerations, are frequently misinterpreted as recurrent infections, resulting in delayed diagnosis, repeated ineffective antibiotic courses, and progressive morbidity

Case Presentation

A 10-year-old girl presented, six years ago, with a two-week history of painful skin lesions on the lower limbs, initially attributed to insect bites. Lesions rapidly progressed to erythematous nodules and ulcerations with spontaneous purulent discharge and crusting, accompanied by an isolated febrile episode at onset. Despite multiple courses of systemic antibiotics, improvement was only partial and transient.

Over the following months, the patient followed a relapsing course with progressive dissemination to the upper limbs, scalp, perinasal region, and face. Lesions characteristically began as erythematous papules or pustules evolving into painful ulcers with well-demarcated borders, central necrosis or granulation tissue, and hemorrhagic or meliceric crusts. Residual hyperpigmented macules marked previously affected areas. Microbiological studies repeatedly isolated *Staphylococcus aureus* from nasal swabs and cutaneous lesions, with sensitivity to trimethoprim-sulfamethoxazole; however, clinical relapses persisted despite targeted therapy. Extensive workup excluded fungal, mycobacterial, and parasitic infections. Histopathological examination demonstrated chronic inflammatory dermatitis with perivascular and interstitial infiltrate composed of lymphocytes, neutrophils, and eosinophils, without specific infectious findings.

Disease progression was further marked by recurrent oral aphthous ulcers, ocular involvement, lymphadenopathy, and persistently elevated inflammatory markers, ultimately requiring hospitalization due to lesion severity. In later stages, deeply ulcerated lesions with undermined borders and necrotic features emerged. The combination of recurrent mucocutaneous and systemic manifestations, together with the neutrophilic histopathological pattern and the characteristic ulcer morphology, supported a diagnosis of Behçet disease with overlapping pyoderma gangrenosum-like neutrophilic dermatosis.

Conclusion

Pyoderma gangrenosum is a rare neutrophilic dermatosis in the pediatric population, with an estimated incidence of approximately 1 in 100,000 persons per year and children accounting for only 3–4% of all reported cases. Associated conditions include inflammatory bowel diseases, hematologic disorders, vasculitis, immune deficiencies, and PAPA syndrome. Behçet disease, though uncommon in childhood, represents an

underrecognized association with PG in the pediatric setting, likely reflecting shared pathogenic mechanisms involving neutrophil dysregulation. The present case underscores that painful, undermined ulcerations unresponsive to antibiotic therapy should raise suspicion for neutrophilic dermatoses, and that early recognition of an underlying systemic condition is critical to guide therapeutic strategy and prevent cumulative morbidity.

EADV CONGRESS
VIENNA
30 SEP - 3 OCT 2026

Abstract N°: 3113

Exfoliative erythroderma concealing cutaneous T-cell lymphoma: a diagnostic and therapeutic challenge

Isabella Andrade Mariano*[1], Caio Araujo Martins[1], René Garrido Neves Neto[2], Luciana Pantaleão[2], Veronica Rodrigues Bogado Leite[1]

[1] Department of Dermatology, Antônio Pedro University Hospital, Fluminense Federal University, Niteroi, Brazil
[2] Department of Pathology, Antônio Pedro University Hospital, Fluminense Federal University, Niteroi, Brazil

Introduction

Erythroderma is a severe inflammatory syndrome characterised by erythema and scaling involving more than 90% of the body surface area [1]. It represents a shared clinical phenotype associated with chronic dermatoses, drug reactions, and malignancies [1,2]. Owing to marked clinical overlap and inflammation-related masking of histopathological findings, identifying the underlying aetiology remains challenging. Cutaneous T-cell lymphomas (CTCL), particularly Mycosis Fungoides (MF) and Sézary Syndrome (SS), are important differential diagnoses because their polymorphic presentations may mimic benign inflammatory dermatoses [3–5]. We report a case of delayed diagnosis concealed within the spectrum of refractory psoriasiform erythroderma.

Case Presentation

A 65-year-old man with no relevant medical history presented with progressive pruritus and diffuse scaling evolving into exfoliative erythroderma, painful palmoplantar fissures, and trachyonychia. The disease was refractory to full-dose methotrexate and systemic corticosteroids, requiring hospital admission one year after symptom onset. Examination revealed confluent erythrodermic plaques with scattered spared hypochromic areas.
During admission, he developed acute skin failure characterised by chills, haemodynamic instability, persistent sinus tachycardia, and severe hypoxaemia. A previous external biopsy had suggested psoriasiform dermatitis. Given the clinical severity and histopathological findings, empirical treatment for erythrodermic psoriasis was initiated with ciclosporin (5 mg/kg/day) and secukinumab (300 mg), resulting in partial improvement and discharge.
A repeat biopsy demonstrated confluent parakeratosis, subcorneal pustules, regular acanthosis, and suprapapillary thinning, findings classically associated with psoriasis. However, the presence of an eosinophil-rich superficial perivascular infiltrate suggested additional diagnostic complexity.
Six months later, the patient was readmitted because of severe relapse, presenting with worsening erythroderma, chronic watery diarrhoea, lower-limb oedema, and bulky right axillary lymphadenopathy. One month after admission, he developed an ischaemic stroke involving the right occipital lobe. Viral serologies were negative. Excisional lymph node biopsy demonstrated dermatopathic lymphadenitis. Peripheral blood immunophenotyping subsequently revealed an aberrant T-cell population (CD3+, CD4+, partial CD7 loss), with a CD4/CD8 ratio of 74 and lactate dehydrogenase levels of 303 U/L, supporting the diagnosis of Sézary Syndrome.
Bone marrow analysis disclosed dual clonality, comprising 39.2% aberrant T-cells consistent with chronic T-cell lymphoproliferative disease and 4% aberrant plasma cells with kappa light-chain restriction. The latter accounted for the monoclonal IgA kappa peak identified on serum protein electrophoresis. Despite intensive supportive management, the patient died from multiorgan failure two months after readmission.

Conclusion

This case highlights the diagnostic challenges posed by erythroderma and cutaneous lymphoid proliferations. In erythrodermic patients, diagnoses should be reassessed continuously, particularly in cases of therapeutic refractoriness or paradoxical deterioration following systemic treatment [3,6]. Progression towards an infiltrative pattern or the rapid development of lymphadenopathy, fever, and weight loss should raise suspicion for underlying malignancy [4,5]. A shift from a purely morphological assessment towards an integrated systemic and molecular approach is essential in suspected neoplastic disease [3,4]. Serial skin biopsies, peripheral blood flow cytometry, and T-cell receptor gene rearrangement studies may provide valuable diagnostic support [3,4,7]. Recognition that apparently benign erythroderma may conceal aggressive haematological malignancy is critical to reducing diagnostic delay, minimising iatrogenic harm, and enabling appropriate management.

EADV CONGRESS
VIENNA
30 SEP - 3 OCT 2026

Abstract N°: 3144

The use of dermoscopy in Ukrainian kidney transplant recipients as a method of early detection, diagnosis and prophylaxis of non-melanoma skin cancers

Iuliia Shcherbakova*[1], Viktor Litus[1], Liudmyla Verbytska[1]

[1] Shupyk National Healthcare University of Ukraine, dermatovenereology, allergology, clinical and laboratory immunology, SE "Institute of Dermatology and Venerology of the National Academy of Medical Sciences of Ukraine", Kharkiv, Ukraine

Introduction
Kidney transplant recipients (KTR) are at increased risk of skin cancer development compared to the general population. More than 90% of these cancers are keratinocyte cancers, namely basal cell carcinomas (BCC) and squamous cell carcinomas (SCC). Dermoscopy has been studied as a diagnostic tool for the diagnosis of skin cancer in kidney transplant patients. This will help reduce the number of unnecessary skin biopsy procedures, which has great importance for KTR, who may be more vulnerable to complications arising from invasive procedures.

The aim of this work is to assess the effectiveness of dermoscopy in the management of KTR as a method of early detection, diagnosis, monitoring and prevention of non-melanoma skin cancers (NMSC).

Materials and Methods
130 KTR were examined, including clinical examination, digital dermoscopy and automated mapping of the whole body.

Results
The frequency of diagnosed cases of NMSC in the KTR was 6.15 ± 2.1%. Characteristic dermoscopy signs of SCC were: linear vessels - 80.7 ± 2.8%, pin-shaped vessels - 56.6 ± 3.6%, erosions - 62.5 ± 3.5%, white structureless areas - 35.8 ± 3.5%, ulcers - 73.2 ± 3.2%, central keratin masses - 40.6 ± 3.5%, hemorrhagic crusts - 10.7 ± 2.2% and yellow opaque scales 12.3 ± 2.4% of cases. In actinic keratosis the "strawberry" pattern was evident in 52.4 ± 3.6% of cases.

The predominant dermoscopy feature of BCC was tree-like, centrally oriented vessels, telangiectasias - 56.7 ± 3.6%, half of the dermoscopy findings in KTR were shiny white structures - 45.5 ± 3.6%. The detection of white-red structureless areas was 40.1 ± 3.6%, multiple small erosions - 39.0 ± 3.6%, large blue-gray ovoid nests - 32.0 ± 3.4% of recipients. Important and frequent findings were multiple blue-gray dots and globules - in 22.9 ± 3.0% of recipients. Typical for BCC leaf-shaped areas were diagnosed in 25.6 ± 3.1% of patients, and more pronounced centrally oriented vessels were 3 times more common in nodular forms (79.1 ± 2.9%) than in superficial (25.1 ± 3.1%) forms of BCC. Most BCC are presented without any classic pigmented structures - 89.3 ± 2.2%. The presence of brown-gray pigment detected in 88.2 ± 2.3% of cases (superficial forms of BCC), while blue pigment - in 58.8 ± 3.6% (nodular). When assessing the correspondence of

Dermoscopy clinical diagnosis in correlation with histological examination data in KTR were detected in 87.5 ± 11.6%. There was a high indicator of diagnostic efficiency of dermoscopy.

Conclusions
The use of dermoscopy in routine clinical conditions has shown promise in the diagnosis of NMSC in KTR. This

method allows for a quick, non-invasive, and non-specific examination of patients at risk. Dermoscopy expands the possibilities of assessing the prevalence and characteristics of NMSC in kidney transplant recipients: it allows for the analysis of skin condition and the influence of concomitant risk factors (presence of lesions, xerosis, pigmentation, photodamage of the skin, scars after previous neoplasia); to observe changes in neoplasms in dynamics; in most cases, the clinical diagnosis correlates with the results of histological examination. Dermoscopy allows for the assessment of the effects of local therapy and postoperative observation of patients, which is necessary when examining KTR. Early detection of NMSC in KTR allows for minimizing surgical intervention. Also, the use of dermoscopy allows for timely diagnosis of pathological skin changes and secondary prevention of malignant neoplasms.

EADV CONGRESS
VIENNA
30 SEP - 3 OCT 2026

Abstract N°: 3151

Pancreatic Panniculitis: A Potential Index of Severity in Pancreatic Disease

Anastasia Moschona[1], Eleftheria Vryzaki[1], Georgios Depountis[2], Odysseas Abatzis2[2], Kyriaki Kekebanou[3], Dimitrios Karagkiozidis[3], Sophia Georgiou[1], Constantinos Thomopoulos[2], Katerina Grafanaki*[1]

[1] Department of Dermatology - Venereology, School of Medicine, University of Patras, Patras, Greece
[2] Department of Gastroenterology, School of Medicine, University of Patras, Patras, Greece, Patras, Greece
[3] Department of Pathology, School of Medicine, University of Patras, Patras, Greece, Patras, Greece

Introduction

Pancreatic panniculitis (PP), first described by Hans Chiari in 1883, is a rare cutaneous manifestation occurring in 0.3–3% of pancreatic disorders. It is most commonly associated with acute or chronic pancreatitis and, less frequently, pancreatic malignancies or pancreatitis–panniculitis–polyarthritis (PPP) syndrome. Whether PP reflects disease severity remains unclear.

Case Presentation

An 87-year-old woman with recurrent acute pancreatitis was admitted with a severe episode characterized by intense abdominal pain. Her history included diabetes mellitus, hypertension, dyslipidemia, and prior biliary obstruction treated surgically. During hospitalization, she developed tender, well-demarcated, violaceous nodules on both lower extremities.

Histopathology of a deep skin biopsy revealed lobular panniculitis with fat necrosis and characteristic anucleated adipocytes (“ghost cells”), confirming PP. Laboratory tests showed markedly elevated pancreatic enzymes (amylase 1452 U/L, lipase 399 U/L, urine amylase 4553 U/L), increased inflammatory markers (CRP 15.32), and hypocalcemia, a known marker of severe pancreatitis. Imaging excluded malignancy.

The patient received supportive treatment, with complete resolution of skin lesions prior to discharge. Notably, at recurrence of pancreatitis four months later, no cutaneous lesions were observed.

Conclusion

PP is an uncommon manifestation of pancreatic disease, likely related to systemic release of pancreatic enzymes causing fat necrosis. Clinically, it presents as painful subcutaneous nodules, predominantly on the lower extremities. In this case, PP coincided with a particularly severe episode, supported by hypocalcemia and significant biochemical derangement, yet was absent during a milder recurrence.

These observations raise the possibility that PP may correlate with disease severity rather than occur randomly. Further studies are needed to evaluate PP as a potential clinical marker, highlighting the importance of interdisciplinary collaboration between dermatologists and gastroenterologists.

EA DV CONGRESS
VIENNA
30 SEP - 3 OCT 2026

Abstract N°: 3164

Beyond simple folliculitis.lupus folliculitis in a male patient:A diagnostic dilemma

Durreshehwar Pirzada*[1]

[1] Ayub Medical teaching Institute, Abbottabad, Pakistan

Introduction

Lupus folliculitis is a rare manifestation of cutaneous lupus erythematosus, and presents as a diagnostic challenge in clinical practice due to its close similarities to other common follicular and acneiform disorders like acne vulgaris, rosacea, simple folliculitis and sycosis barbae.This diagnostic ambiguity leads to prolonged and ineffective treatments.

Case Presentation

We present a case of 32 years old male shopkeeper who presented to our outpatient department with 15 years history of treatment resistant facial pustular lesions especially involving his beared area.On inquiry patient reported a notable history of photosensitivity and hyperpigmentation on his face,however he had no symptoms pertaining to other organ systems and his mucosae were also spared. The patient had failed multiple topical and systemic treatments, including antibiotics(metronidazole,ampicillin,azithromycin,clindamycin,doxycycline) and retinoids(oral and topical isotretinoin) for treating acne rosacea and folliculitis.Cutaneous examination revealed hyperpigmentation involving his malar(butterfly) region,multiple milia on zygomatic region,fine wrinkles in periocular region,there were multiple erythematous plaques studded with pustules distributed asymmetrically in his beared area of face and neck,with few areas of scarring,however no such lesion was present on his scalp,and his mucosae were healthy looking.All laboratory parameters were noramal including ANA and anti dsDNA.skin biopsy done for histopathological evaluation showed acanthosis with slight hyperkeratosis along with follicular plugging.upper dermis showed solar elastosis along with dense lymphocytic infiltrate no neutrophils or eosinophils were seen,lymphocytic aggregates were seen around hair follicles.There was no atypia or exocytosis noted.dermoepidermal junction showed vacuolar degeneration of basal keratinocytes and thickening of basement membrane.On the basis of these histopathological findings diagnosis of cutaneous lupus-lupus folliculitis was made.The patient was advised sun protection,Oral Hydroxychloroquine,and topical steroids.On his follow up visit after 4 weeks he showed marked improvement in his symptoms.

Conclusion

lupus folliculitis is a rare variant of cutaneous lupus erythematosus which is an autoimmune disorder and is underreported in male patients.Due to low incidence and less index of suspicion this patient remained misdiagnosed and maltreated for over a decade .furthermore one important finding in this case was negative antinuclear antibody test which does not rule out lupus because a negative ANA test is common(36%) in cutaneous lupus erythematosus.This highlights the necessity and importance of clinicopathological correlation in atypical, refractory dermatological disorders to make a correct and timely diagnosis.

EADV CONGRESS
VIENNA
30 SEP - 3 OCT 2026

Abstract N°: 3178

Dupilumab for refractory eosinophilic dermatosis associated with chronic lymphocytic leukaemia: a case report and review of the literature

Gianmarco Silvi*[1], Elia Rosi[1], Antonella Di Cesare[1], Cecilia Giorgi[1], Alfredo Pellegrino[1], Marco Belletti[1], Guia Luisa Mosca[1], Francesca Prignano[1]

[1] Department of Health Sciences, Section of Dermatology, University of Florence, Florence, Italy

Introduction

Eosinophilic dermatosis associated with hematologic malignancies is a rare inflammatory condition most frequently observed in patients with chronic lymphocytic leukaemia. Clinically, it is characterized by recurrent pruritic papules, nodules, urticarial plaques, or bullous lesions, often showing poor response to systemic corticosteroids and significant impact on quality of life.

Case Presentation

A 67-year-old woman with chronic lymphocytic leukaemia diagnosed in 2016 achieved complete remission after first-line chemoimmunotherapy. Following hematologic relapse with abdominal bulky disease, she received second-line treatment with a BCL-2 inhibitor combined with anti-CD20 monoclonal antibody therapy, obtaining a further complete hematologic response. During treatment, she developed intensely pruritic papulo-nodular lesions and urticarial plaques involving the face, neck, and upper limbs, with a relapsing course and seasonal worsening during spring and summer. Histopathological examination demonstrated a dense eosinophilic infiltrate, supporting the diagnosis of eosinophilic dermatosis associated with hematologic malignancy after exclusion of other causes of tissue eosinophilia. Systemic corticosteroids induced only partial and transient improvement, with rapid relapse during dose tapering. Due to persistent symptoms and corticosteroid dependence, dupilumab therapy was initiated according to the approved regimen for atopic dermatitis. Rapid improvement of pruritus and cutaneous lesions was observed after treatment initiation, with sustained clinical benefit and no significant adverse events during follow-up. Review of the available literature identified only a limited number of reported cases describing successful treatment with dupilumab in refractory disease, predominantly in patients with chronic lymphocytic leukaemia.

Conclusion

This case highlights dupilumab as a potential steroid-sparing therapeutic option for eosinophilic dermatosis associated with hematologic malignancies refractory to conventional treatment. Modulation of type 2 inflammatory pathways may represent a promising therapeutic strategy in relapsing disease.

EADV CONGRESS
VIENNA
30 SEP - 3 OCT 2026

Abstract N°: 3262

Dermatologic adverse events associated with sacituzumab govitecan: an international retrospective study from the EADV Task Force "Dermatology for Cancer Patients"

Alexander Cawley[1], Ioannis-Alexios Koumprentziotis[2], Kara Heelan[1], Elliot Ewig[3, 4], Alexandre Gérard[3, 4], Maëlys Labat[5], Grażyna Kamińska-Winciorek[6], Marcin Kubeczko[6], Luca Rapparini[7, 8], Michela Valeria Rita Starace[7, 8], Katerina Grafanaki[9], Maria Kamaratou[10], Dimitrios Mavroudis[10], Vasiliki Nikolaou[2], Dimitra Koumaki*[11]

[1] Dermatology Department, Skin Unit, Royal Marsden NHS Foundation Trust, London, United Kingdom
[2] 1st Department of Dermatology and Venereology, Andreas Sygros Hospital, National and Kapodistrian University of Athens, Medical School of Athens, Athens, Greece
[3] Department of Clinical Pharmacology, Université Côte d'Azur, University Hospital Centre of Nice, Nice, France
[4] Laboratory of Molecular Physio Medicine (LP2M), UMR 7370, CNRS, Université Côte d'Azur, Nice, France
[5] Saint Louis Régional Pharmacovigilance Centre, Clinical Investigation Centre, Saint-Louis Hospital, Paris, France
[6] Maria Sklodowska-Curie National Research Institute of Oncology, Gliwice Branch, Gliwice, Poland
[7] Dermatology Unit, IRCCS Azienda Ospedaliero-Universitaria di Bologna, Bologna, Italy
[8] Department of Medical and Surgical Sciences, Alma Mater Studiorum University of Bologna, Bologna, Italy
[9] Department of Dermatology-Venereology, School of Medicine, University of Patras, Patras, Greece
[10] Department of Medical Oncology, University Hospital of Heraklion, Heraklion, Greece
[11] Dermatology Department, University Hospital of Heraklion, Heraklion, Greece

Introduction

Sacituzumab govitecan (SG) is a Trop-2-directed antibody-drug conjugate approved for the treatment of advanced or metastatic triple-negative and hormone receptor (HR)-positive/HER2-negative breast cancer. Mucocutaneous adverse events (AEs) reported in randomised controlled trials include stomatitis, mucositis, alopecia, pruritus, and various cutaneous eruptions; however, real-world data characterising the spectrum and severity of SG-associated dermatologic AEs (dAEs) remain limited.

Materials and Methods

We conducted a retrospective, multicentre observational study across five expert dermatology centers affiliated with the EADV Task Force "Dermatology for Cancer Patients". All patients who received at least one dose of SG and developed at least one dAE were included. Baseline demographic and clinical data (age, sex, cancer subtype, best oncologic response, and SG discontinuations/interruptions) and dAE-related characteristics (type, CTCAE grade, and time from SG initiation to first dAE) were collected and analysed.

Results

A total of 56 female breast cancer patients with a median (IQR) age of 56.3 (30, 82) years were included, all receiving SG monotherapy. At data collection, the majority (53.5%) had achieved a partial response to SG. Thirteen distinct types of dAEs were identified; 66.1% of patients experienced a single dAE. Median (IQR) time to first dAE was 56 (28, 88) days. The most frequent dAEs were alopecia (41.1%) and stomatitis/mucositis (30.1%), followed by pruritus (12.5%) and xerosis (12.5%). Less common events included eczematous rash (10.7%), acneiform dermatitis (10.7%), maculopapular rash (5.3%), erythematous rash (3.5%) and scalp ulceration (1.7%). Two infectious dAEs were observed in the same patient: herpes zoster occurring one week after SG initiation and erysipelas of the breast region two months after initiation. Most dAEs were grade 1 (53.5%) or grade 2 (42.8%). Two patients experienced grade 3 toxicities, both discontinuing treatment (one serious infusion reaction and one

grade 3 mucositis).

Conclusions

The real-world dermatologic toxicity profile of SG aligns with that reported in clinical trials, with most dAEs being mild (grade 1 or 2) and rarely requiring treatment interruption. These findings provide reassurance regarding the tolerability of SG in clinical practice. Limitations of this study include the relatively small sample size and retrospective design. Further large-scale pharmacovigilance studies are warranted to better characterise rare SG-associated dAEs.

Abstract N°: 3274

Erythroderma in a 5-year-old girl with lymphadenopathy, hypercalcemia, polyuria, polydipsia

Zhen Zhang*[1], Yan Lei[1], jiahui Jin[1], jianying Liang[1], Zhirong Yao[1]

[1] Xinhua Hospital, Shanghai Jiaotong University School of Medicine, Shanghai, China

Introduction

Hypercalcemia affects approximately 1% of the general population and approximately 2% of patients with cancer. It may be due to any of a large number of disorders. Optimal management requires identifying the etiology of hypercalcemia. Mild hypercalcemia is typically asymptomatic, while severe hypercalcemia is associated with nausea, vomiting, dehydration, confusion, somnolence, and coma.Hypercalcemia was detected in 6% of patients with sarcoidosis, which is an inflammatory, chronic granulomatous disorder that may affect multiple organs.

Case Presentation

Here, we present a case of a 5 - year - old girl who presented with hypercalcemia, polyuria, polydipsia, erythroderma, lymphadenopathy, and fever. The patient has had intermittent hypercalcemia for two years, and the cause remains unknown. She reported polyuria and polydipsia for one year.Notably, at the age of 2, she initially developed some reddish - brown papules on her chest. Over the next 3 years, the rash gradually spread to cover nearly the entire body, presenting erythrodermic - like manifestations. Physical examination revealed several firm, mobile, non - tender bilateral cervical, axillary, and inguinal lymph nodes.Histopathological examination of skin and lymph node biopsy revealed diffuse non - caseating epithelioid granulomas. Laboratory findings revealed a high serum calcium concentration (3.44 mmol/L, normal range: 2.1 - 2.8), elevated calcitonin (9.46 pg/mL, normal range < 5.0), and a low parathyroid hormone (PTH) concentration (0.909 pmol/L, normal range: 1.59 - 6.89). Angiotensin - converting enzyme was elevated (249.7 U/L, normal range: 5 - 52).The results of clinical, histologic, and laboratory investigations indicated that the patient had systemic sarcoidosis, which caused the hypercalcemia, erythroderma and lymphadenopathy. Hypercalciuria causes polyuria and volume depletion, resulting in polydipsia. This can explain why our patient presented with polydipsia and polyuria. After the initiation of methylprednisolone treatment, blood calcium levels rapidly returned to normal on the second day of treatment.The erythroderma and lymphadenopathy improved markedly two weeks after treatment.

Conclusion

This case highlights the importance of identifying the underlying cause of hypercalcemia. Furthermore, it emphasizes the necessity of differentiating the rash manifestations of erythroderma from those of sarcoidosis, while also demonstrating the clinical diversity of sarcoidosis, which can mimic various other diseases.

EA DV CONGRESS
VIENNA
30 SEP - 3 OCT 2026

Abstract N°: 3278

Biopsy analysis of Erythema Annulare Centrifugum: treatment and main triggering factors

Ana Carolina Oliveira Bizinoto[1], Ana Julia Aparecida Deckers[1], Anna Carolina Souto Perez[1], Bárbara Elias do Carmo Barbosa[2], Brunna Monteiro de Souza[1], Laís Saggin Furtado[3], Geisa Costa*[4]

[1] Universidade de Uberaba, Uberaba, Brazil

[2] Universidade Estadual Paulista, Botucatu, Brazil

[3] Art Beauty Center, Uberaba, Brazil

[4] Art Beauty Center, Faculdade São Leopoldo Mandic, Uberaba, Brazil

Introduction

Erythema Annulare Centrifugum (EAC) is a rare inflammatory dermatosis characterized by erythematous plaques with central clearing, typically located on the trunk and extremities. It occurs more frequently in young and middle-aged adults, affecting both sexes equally. The superficial form reveals a mild perivascular lymphohistiocytic infiltrate, spongiosis, and focal parakeratosis microscopically, while the macroscopic hallmark is the presence of scaly borders. EAC is often associated with conditions such as neoplasms. However, literature is limited on this subject. Thus, this study aims to describe a case of EAC, focusing on clinical presentation, histopathological findings, and response to phototherapy, while exploring its possible association with systemic diseases and shedding light on its clinical course and therapeutic approaches.

Case Presentation

This case report was approved by the Research Ethics Committee of the Clinical Hospital of the Federal University of Triângulo Mineiro, under approval number 7,578,783 (CAAE 87191725.8.0000.8667). This study reports a 60-year-old male patient with erythematous lesions on the lower limbs. The lesions appeared initially on the right lower limb and later on the left lower limb, five months prior to consultation. The patient had self-medicated without medical guidance and reported no improvement. On clinical examination, the left lower limb showed an erythematous macule with irregular, raised, annular borders. The right lower limb had a larger erythematous macule with raised borders and a centrally erythematous area. Laboratory tests and skin biopsy were performed. The patient also had a pulmonary nodule detected by MRI and CT, but declined further investigation of the nodule. Histopathological analysis showed alterations in both samples. In the LLL, the epidermis showed reduced rete ridges, a frequently diminished or absent granular layer, and parakeratosis replacing the lamellar stratum corneum. Moderate spongiosis and lymphocytic exocytosis were observed, with the basal layer preserved. In the RLL, the epidermis was thickened with acanthosis and a parakeratotic crust containing serous material. Moderate spongiosis and lymphocytic exocytosis were also seen, with basal layer preservation. In both regions, fibroblast proliferation, collagen fibers, and blood capillaries were observed, with moderate perivascular lymphomononuclear infiltrate. In the RLL, interstitial edema was noted. Prussian blue and PAS staining were negative for hemosiderin and fungal structures, respectively. The histopathological diagnosis was superficial perivascular spongiotic dermatitis, consistent with EAC. The patient received vitamin and mineral supplementation and six phototherapy sessions alternating between yellow and red light, resulting in immediate clinical improvement. The patient also began home treatment with a red LED mask. After six months, the patient experienced lesion remission and reported being “very pleased with the result.” Figure 1 shows the macroscopic aspects of the superficial perivascular spongiotic dermatitis on the right and left lower limbs, as well as the visual progression of lesion recovery six months after treatment.

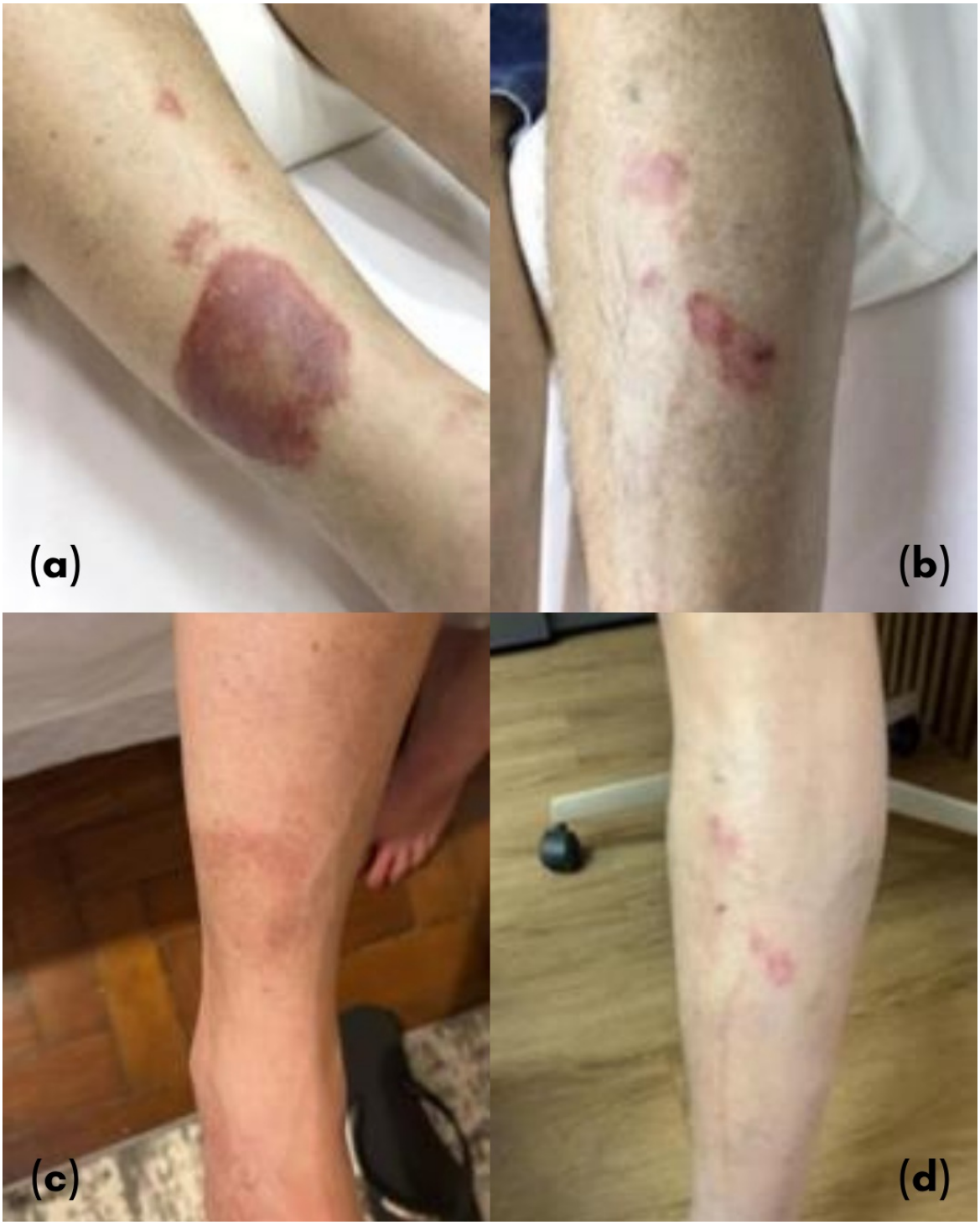

Figure 1. (a) Initial lesion on the right lower limb, showing spongiotic dermatitis with a parakeratotic crust in the distal third. (b) Initial lesion on the left lower limb, showing spongiotic dermatitis with continuous parakeratosis. (c) Progress of lesion recovery six months after treatment, with remission of the lesions on the right lower limb. (d) Recovery of the lesion with continuous parakeratosis on the left lower limb.

Conclusion

This case report highlights the importance of a multidisciplinary approach in the evaluation and management of EAC. The potential association between this cutaneous condition and underlying malignancies, such as pulmonary neoplasms, underscores the need to investigate comorbidities—even in the absence of systemic symptoms. Phototherapy demonstrated a favorable clinical response in the management of EAC, promoting significant improvement in cutaneous lesions and contributing to patient satisfaction.

EADV Congress 2026, VIENNA
30 SEPTEMBER - 03 OCTOBER 2026
POWERED BY M-ANAGE.COM

EADV CONGRESS
VIENNA
30 SEP - 3 OCT 2026

Abstract N°: 3280

Cutis Verticis Gyrata as an Early Manifestation of Acromegaly?

Betsy Yosia Nadeak*[1], Elvira Lesmana[1], Lili Legiawati[1], Hanny Nilasari[1], Rahadi Rihatmadja[1], Henry Riyanto Sofyan[2], Ihza Fachriza[3], Sondang P. Sirait[1]

[1] Department of Dermatology and Venereology, Faculty of Medicine Universitas Indonesia, Dr. Cipto Mangunkusumo National Central General Hospital, Jakarta, Indonesia

[2] Department of Neurology, Faculty of Medicine Universitas Indonesia, Dr. Cipto Mangunkusumo National Central General Hospital, Jakarta, Indonesia, Jakarta, Indonesia

[3] Department of Surgery, Faculty of Medicine Universitas Indonesia, Dr. Cipto Mangunkusumo National Central General Hospital, Jakarta, Indonesia

Introduction

Cutis verticis gyrata (CVG) is an uncommon scalp disorder characterized by thickened skin forming cerebriform folds and furrows. Although often regarded as a benign primary scalp condition, CVG may also occur secondary to systemic disease, including endocrine disorders such as acromegaly. Recognizing CVG as a potential visible marker of systemic disease is important when it is accompanied by acromegaly features. We report a case of rapid-onset CVG in which directed systemic history raised suspicion for previously unrecognized acromegaly.

Case Presentation

A 37-year-old male presented with multiple prominent scalp folds developing over several days, accompanied by severe headache. Neurological examination was within normal limits. Initial imaging suggested a soft-tissue mass, but further vascular evaluation did not reveal any vascular abnormality.

Dermatological examination showed multiple deep, symmetric longitudinal folds extending from the vertex to the occipital region, with additional horizontal occipital sulci. Dermoscopy revealed a honeycomb pattern with perifollicular reticular hyperpigmentation and fine white scales, consistent with concomitant seborrheic dermatitis. Laboratory evaluation showed elevated C-reactive protein, while complete blood count, renal function, and thyroid function were within normal limits. Punch biopsy from a ridge crest revealed normal epidermis, thickened eosinophilic collagen bundles in the upper dermis, mild perivascular inflammatory infiltrate, tufted hair follicles, focal follicular rupture with perifollicular fibrosis, and no mucin or amyloid deposition. These findings supported CVG but were not specific.

Directed systemic history-taking became the diagnostic turning point, revealing progressive increase in shoe size, perceived enlargement of the right lower limb, and arthralgia. The severe headache improved after nerve block injection. Given the combination of CVG and acromegaly features, the patient was evaluated by endocrinology and assessed as having suspected acromegaly. Further workup, including serum insulin-like growth factor-1, HbA1c, and thyroid-stimulating hormone testing, was planned.

Local treatment was initiated with intralesional hyaluronidase injection and laser diode/ light-emitting diode therapy. However, only the initial treatment session was completed, no visible improvement was documented in the early post-treatment period, and the patient was subsequently lost to follow-up, preventing biochemical confirmation and assessment of therapeutic response.

Conclusion

This case underscores that CVG is more than a scalp disorder. It can be the first visible sign of systemic endocrine disease. Rapid-onset scalp folds accompanied by severe headache, increased shoe size, acral enlargement, and arthralgia should prompt urgent evaluation for secondary CVG, with acromegaly at the top of the differential. As histopathology is frequently non-specific, targeted systemic history and multidisciplinary clinicopathologic correlation remain essential. Dermatologists serve a key frontline role in recognizing CVG as a window into occult endocrine disease and in initiating the workup that may uncover a treatable pituitary lesion.

EADV CONGRESS
VIENNA
30 SEP - 3 OCT 2026

Abstract N°: 3306

Pancreatic panniculitis masquerading as soft tissue infection: diagnostic delay, concomitant wound sepsis, and an incidental pancreatic cystic lesion — a case report

Weijia Yi*[1]

[1] Department of Dermatology, John Hunter Hospital, New South Wales, Australia

Introduction

Pancreatic panniculitis (PP) is a rare cutaneous complication of pancreatic disease, estimated to affect 0.3–3% of patients with pancreatitis or pancreatic neoplasia. PP is driven by systemic liberation of pancreatic lipase and other enzymes. Clinically, PP presents as tender erythematous subcutaneous nodules predominantly affecting the lower extremities, and may precede systemic features of the underlying pancreatic condition by one to seven months, contributing substantially to diagnostic delay. Characterised histologically by lobular panniculitis with saponification necrosis of adipocytes, it involves pathognomonic "ghost adipocytes", reflecting calcium deposition from enzymatic fat necrosis. Due to the rarity of the condition and non-specific appearance, it is frequently misdiagnosed as cellulitis, erythema nodosum, or soft tissue infection. Large-scalpel incisional biopsy of a fully developed lesion is essential for histological confirmation.

Case Presentation

We report a 37-year-old female with a history of a single prior alcoholic pancreatitis episode who presented with extensive erythematous, indurated, haemorrhage-crusted nodules on the right lower limb. The diagnostic course was significantly confounded by the appearance of cellulitis with elevated serum inflammatory markers, particularly C-reactive protein. Tissue cultures grew vancomycin-resistant Enterococcus faecium and Finegoldia magna, necessitating multiple operative debridements, vacuum-assisted closure, and ultimately split-skin grafting. Biopsy of a new left lower limb lesion demonstrating lobular panniculitis with saponification necrosis and ghost adipocytes, alongside serially elevated serum lipase and amylase later confirmed the diagnosis. Abdominal imaging identified a hypoechoic pancreatic body lesion further characterised on MRCP as a small loculated cystic structure with high-risk features, warranting further oncological referral.

Conclusion

This case illustrates the substantial diagnostic challenge posed when concurrent soft tissue infection obscures the characteristic features of PP, leading to significant surgical morbidity before the underlying aetiology is established. It highlights the importance of including PP in the differential diagnosis of lower limb panniculitis when subclinical pancreatic enzyme elevation is identified, and of pursuing comprehensive pancreatic imaging in all confirmed cases to exclude occult neoplasia.

EA DV CONGRESS
VIENNA
30 SEP - 3 OCT 2026

Abstract N°: 3361

Erythroderma Beyond the Obvious: A Case Series Highlighting Diagnostic and Therapeutic Challenges in Three Refractory Cases

Surabhi Sahu*[1]

[1] ESIC Medical College and Hospital Basaidarapur, Delhi, India

Introduction

Erythroderma is a potentially life-threatening dermatological emergency and poses significant diagnostic and therapeutic challenges due to overlapping clinical and histopathological features among inflammatory dermatoses, cutaneous lymphomas, infections and systemic disorders. Delayed diagnosis despite repeated clinicopathological evaluation and evolving phenotypes remains a major challenge in refractory erythroderma. Early recognition of atypical clues are often crucial for definitive diagnosis — a process that, as illustrated here, can span years despite multimodal workup

Case Presentation

Case 1

A 26-year-old female with recurrent childhood-onset papulosquamous disease and palmoplantar keratoderma developed progressive erythroderma with severe scaling and pruritus. Initial clinicopathological impression favored erythrodermic psoriasis, and the patient received multiple therapies including cyclosporine, methotrexate, infliximab, secukinumab and NB-UVB with inadequate response. Subsequent consideration of non-bullous ichthyosiform erythroderma led to partial improvement with acitretin. Re-evaluation revealed salmon-colored plaques, islands of sparing, nutmeg-grater papules and waxy keratoderma. Repeat histopathology demonstrated alternating orthokeratosis and parakeratosis in a checkerboard pattern with psoriasiform hyperplasia, while dermoscopy showed yellow-orange areas with follicular keratotic plugs. A final diagnosis of type III pityriasis rubra pilaris (PRP) was established following years of diagnostic uncertainity. CAPE syndrome was considered owing to childhood onset and psoriasis–PRP overlap phenotype, although CARD14 mutation testing could not be performed. Marked clinical improvement was achieved with ustekinumab.

Case 2

A 60-year-old male presented with rapidly progressive erythroderma over 2 weeks with cephalocaudal progression, characterized by coarse loosely adherent scaling, areas of completely spared skin and painful palmoplantar keratoderma. Differentials of erythrodermic psoriasis, PRP and Sézary syndrome were considered. Peripheral smear and systemic evaluation did not reveal atypical cells or evidence of malignancy. Minimal improvement occurred with cyclosporine, following which acitretin was initiated. Chest X ray shown patch opacities, and TruNAAT was positive for pulmonary tuberculosis. Anti-tubercular therapy with escalation of acitretin dosage resulted in gradual but significant improvement in erythema and scaling over the subsequent months.

Case 3

A 55-year-old male with chronic liver disease presented with diffuse erythema, scaling, pedal edema and multiple erosive and ulcerative lesions involving perioral skin, trunk, oral mucosa and genitalia. Initial diagnosis of erythroderma secondary to atopic dermatitis with eczema herpeticum was considered, and treatment with acyclovir, antibiotics and systemic corticosteroids was initiated. However, the patient subsequently developed rapidly worsening leukocytosis with extreme eosinophilia (absolute eosinophil count ~45,000 cells/mm^3), raising suspicion of Sézary syndrome, mycosis fungoides and hypereosinophilic syndrome. Peripheral smears were

negative for atypical cells. Before further evaluation including lymph node FNAC could be completed, the patient developed sudden cardiovascular collapse and succumbed despite resuscitative efforts, with possible eosinophilic cardiac involvement suspected, although definitive confirmation could not be obtained.

Conclusion

These cases collectively highlight an unclassifiable erythroderma variant at the psoriasis–PRP interface, the potential role of tuberculosis as a disease trigger, and the life-threatening trajectory of hypereosinophilic erythroderma — each representing clinically and academically underreported territory.

EA DV CONGRESS
VIENNA
30 SEP - 3 OCT 2026

Abstract N°: 3475

Glomeruloid hemangiomas as an early diagnostic clue to multicentric Castleman disease

Mónica Ramos Caballo*[1], Laura Nájera Botello[2], Ana María Dotor de Lama[2], Alejandro Callejas Díaz[3], Constanza Martínez Mera[1]

[1] Department of Dermatology, Hospital Universitario Puerta de Hierro Majadahonda, Madrid, Spain
[2] Department of Pathology, Hospital Universitario Puerta de Hierro Majadahonda, Madrid, Spain
[3] Department of Internal Medicine, Hospital Universitario Puerta de Hierro Majadahonda, Madrid, Spain

Introduction

Castleman disease (CD) comprises a heterogeneous group of lymphoproliferative disorders characterized by lymph node hyperplasia and vascular proliferation. These entities share histopathological features and are classified into unicentric CD, multicentric Human Herpesvirus 8 (HHV-8)-positive CD, and multicentric HHV-8-negative CD, the latter of which may occur in association with paraneoplastic syndromes such as POEMS syndrome (polyneuropathy, organomegaly, endocrinopathy, monoclonal protein, and skin changes) or TAFRO syndrome (thrombocytopenia, anasarca, fever, reticulin fibrosis, and organomegaly).

Case Presentation

A 55-year-old woman attended her annual dermatologic follow-up visit for a previously diagnosed basal cell carcinoma. Full-body skin examination revealed two violaceous, firm, dome-shaped, asymptomatic papules on the cervical region (panel A), which had appeared suddenly two months earlier. Dermoscopy showed homogeneous violaceous areas with a central unfocused vessel (panel B).

The patient was currently undergoing evaluation in the Internal Medicine department for inguinal lymphadenopathy. Whole-body computed tomography revealed multiple enlarged lymph nodes with homogeneous hypervascular characteristics, involving the inguinal region, right external (panel C) and common iliac chains, obturator chains, and the retroperitoneum. An excisional lymph node biopsy was scheduled. The patient was otherwise asymptomatic and denied constitutional symptoms.

Given the clinical context, cutaneous metastases were initially suspected, and one of the cervical lesions was excised for histopathological examination. Histopathology revealed a CD31-positive dermal vascular proliferation composed of clustered capillaries resembling renal glomeruli. PAS-positive eosinophilic globules, showing immunoreactivity for immunoglobulins, were identified within the cytoplasm of stromal cells. These findings were consistent with glomeruloid hemangioma. In this context, POEMS and TAFRO syndromes were considered.

Histopathological examination of the inguinal lymph node revealed partially preserved nodal architecture with regressive and hyperplastic follicles showing onion-skin mantle zones, penetrating vessels, and interfollicular plasmacytosis with lambda light-chain predominance. Immunohistochemical studies for HHV-8 and Epstein-Barr encoding region (EBER) in situ hybridization were negative. It was consistent with the diagnosis of multicentric Castleman disease, plasmacytic/mixed variant.

A staging work-up ruled out systemic involvement, showing no serum paraproteinemia, other laboratory abnormalities, or evidence of neuropathy. The final diagnosis was HHV-8-negative multicentric Castleman disease, with no evidence of POEMS or TAFRO syndrome.

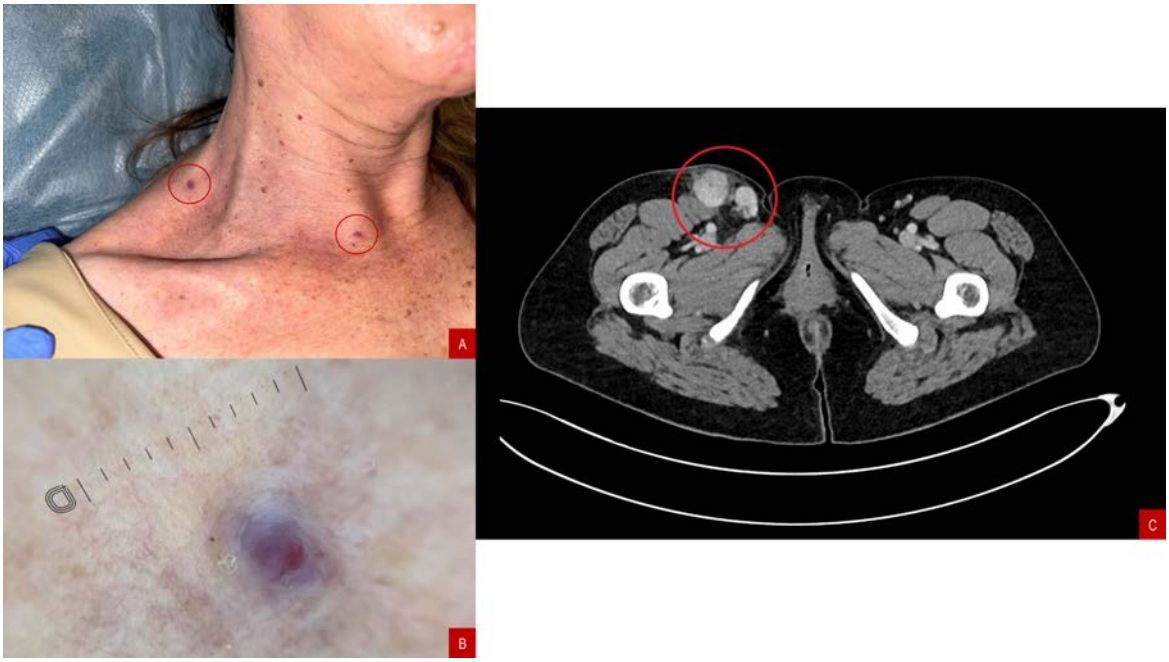

Panels A and B show clinical and dermoscopic features of two violaceous, firm papules in the right and anterior cervical region, consistent with glomeruloid hemangiomas. Panel C shows enlarged lymph nodes involving the right external iliac chain.

Conclusion

Glomeruloid hemangiomas are benign vascular lesions, classically associated with POEMS syndrome and, less frequently, with multicentric Castleman disease. They are thought to result from overproduction of angiogenic cytokines, particularly vascular endothelial growth factor (VEGF), as well as interleukins, such as IL-6, IL-1β, and tumor necrosis factor alpha. They are not pathognomonic and have been reported in healhy individuals, although some of these cases may reflect insufficient follow-up.

They are usually asymptomatic and do not require treatment. However, their clinical and histological recognition is important, as they may precede the diagnosis of POEMS syndrome or Castleman disease by several years, underscoring the importance of recognizing this entity and ensuring long-term follow-up, wich may lead to timely diagnosis and prevention of disease-related complications.

EADV CONGRESS
VIENNA
30 SEP - 3 OCT 2026

Abstract N°: 3480

The petrified skin: diffuse calcinosis revealing amyopathic anti-MDA5 dermatomyositis

lalla safia echarif*[1], Lina Bennis[1], layla bendaoud[1], maryem aboudourib[1], ouafa hocar[1], said amal[1]

[1] Department of Dermatology and Venerology, Mohammed VI University Hospital, Biosciences and Health Laboratory, Faculty of Medicine and Pharmacy of Marrakesh, MARRAKECH, Morocco

Introduction
Dermatomyositis (DM) is an autoimmune inflammatory disorder with a highly heterogeneous clinical spectrum. Although classically characterized by proximal muscle weakness and distinctive cutaneous findings, amyopathic forms may present exclusively with skin manifestations, leading to significant diagnostic delay. In such cases, chronic inflammation may progress silently and result in severe systemic complications before the correct diagnosis is established.



Figure 1 :Erythematous-violaceous scaly plaques on the knees

Case Presentation
A 33-year-old man presented with a 10 year history of progressive physical deterioration associated with persistent erythematous-squamous plaques localized to the elbows and knees, initially interpreted as psoriasis because of their distribution over typical extensor “bastion sites,” associated with inflammatory polyarthralgia.

Over time, the lesions became increasingly violaceous and atrophic, with associated generalized photosensitivity and Raynaud phenomenon. However, the absence of clinically evident myositis led to maintenance of the initial psoriasiform diagnosis.

The patient also developed severe and progressive calcinosis cutis, characterized by multiple stone-hard subcutaneous nodules involving the cheeks, trunk, back, upper and lower extremities, and hands. Despite the extent of the calcinosis, its etiology remained unexplained for several years.

Dermatological reassessment revealed subtle heliotrope erythema and Gottron papules, raising suspicion for dermatomyositis. Neuromuscular examination showed preserved muscle strength, negative Gowers' sign, and normal creatine kinase levels, consistent with an amyopathic phenotype.

Skin biopsy demonstrated histological findings compatible with dermatomyositis and excluded psoriasiform lupus. Immunological investigations revealed isolated anti-MDA5 antibody positivity. Radiological assessment confirmed extensive dystrophic calcinosis. Pulmonary evaluation identified moderate ventilatory impairment and nonspecific subpleural micronodules despite the absence of respiratory symptoms. Cardiac and neurological investigations were unremarkable.



Figure 2 :Erythematous-violaceous plaques involving the extensor surface of the elbow , with an atrophic and lichenoid appearance

Conclusion

This case highlights the diagnostic challenge of amyopathic dermatomyositis when cutaneous manifestations mimic chronic psoriasiform dermatoses. The unusually severe and diffuse calcinosis reflects prolonged, undiagnosed inflammatory disease progression. Recognition of atypical psoriasiform lesions, photosensitivity, and characteristic dermatomyositis signs is essential, even in the absence of muscle involvement. Early dermatologic

evaluation, histopathological confirmation, and immunological assessment are critical to avoid delayed diagnosis and identify potentially associated systemic complications, particularly interstitial lung involvement.



Figure 3 :Thoraco-abdominopelvic computed tomography demonstrating extensive diffuse

subcutaneous calcinosis involving the trunk and lower extremities .

EA DV CONGRESS
VIENNA
30 SEP - 3 OCT 2026

Abstract N°: 3579

Efficacy and Safety of Ivarmacitinib, a Highly Selective JAK1 Inhibitor, in the Treatment of Non-Segmental Vitiligo

Wen jun Zheng*[1]

[1] The First Affiliated Hospital of Guangxi Medical University, Nanning, China

Introduction

Vitiligo is a chronic autoimmune disorder characterized by progressive skin and mucosal depigmentation due to melanocyte destruction. Recent evidence suggests that JAK inhibitors, through immunomodulatory mechanisms, hold promise in vitiligo treatment. Ivarmacitinib, a highly selective JAK1 inhibitor, remains under investigation for this condition. This study evaluates the efficacy and safety of ivarmacitinib in patients with non-segmental vitiligo.

Materials and Methods

All participants received oral ivarmacitinib 4 mg once daily; some were concomitantly treated with topical agents and/or phototherapy based on clinical need. Efficacy and safety were assessed using F-BSA, T-BSA, F-VASI, T-VASI, DLQI, and VitiQoL scores at baseline, week 4, 8, and 12. Preliminary efficacy and safety analyses were performed on the patients who completed the 12-week follow-up.

Results

Between November 4, 2025 and June 18, 2026, 19 patients were enrolled, including 5 pediatric patients. Of 19 patients, 12 (63.2%) were female, and the mean age was 26 years. Overall, at baseline, the mean T-VASI was 1.1, the mean F-VASI was 0.3, the mean duration since vitiligo diagnosis was 346.4 days, and 16 patients (84.2%) had active vitiligo. At week 12, the mean percent change from baseline in F-VASI and T-VASI was −0.6 (SD 0.4). Among the 19 patients, 7 (36.8%) reached F-VASI 50 and 6 (31.6%) reached T-VASI 50. The change from baseline in VIDA score, VitiQoL total score, DLQI score at week 12 were -0.3(SD 0.2), -0.6 (SD 0.4), -0.6 (SD 0.3), respectively **(Table 1).** No adverse events or significant laboratory abnormalities were reported.

Endpoints	
Percent change from BL in F-VASI at week 12, mean (SD)	-0.6 (0.4)
Percent change from BL in T-VASI at week 12, mean (SD)	-0.6 (0.4)
F-VASI 50 at week 12, Responder, n (%)	7 (36.8%)
T-VASI 50 at week 12, Responder, n (%)	6 (31.6%)
Percent change from BL in VIDA score at week 12, mean (SD)	-0.3 (0.2)
Percent change from BL in DLQI score at week 12, mean (SD)	-0.6 (0.4)
Percent change from BL in VitiQoL total score at week 12, mean (SD)	-0.6 (0.3)

Table 1. Week 12 efficacy endpoints

Conclusions

Ivarmacitinib demonstrates early potential in improving vitiligo extent and severity, along with a favorable safety profile over 12 weeks. Although current data are limited by sample size and short follow-up, this study is actively ongoing with extended follow-up up to 12 weeks. Continued enrollment and longer-term data will be essential to confirm its clinical utility in non-segmental vitiligo.

EA DV CONGRESS
VIENNA
30 SEP - 3 OCT 2026

Abstract N°: 3599

Methylprednisolone modulates complement activation in an ex vivo model of pemphigoid diseases

Marvin Tigges[1], Ilaria Piccini[1], Leon F. Schmidt-Jiménez[2], Janin Edelkamp[1], Katja Bieber[2], Andreas Recke[3], Ralf J. Ludwig[1, 2], Marta Bertolini*[1]

[1] QIMA Life Sciences, QIMA Monasterium GmbH, Münster, Germany

[2] Lübeck Institute of Experimental Dermatology, University of Lübeck, Lübeck, Germany

[3] Department of Dermatology, University of Lübeck, Lübeck, Germany

Introduction

Pemphigoid diseases (PD) are autoimmune blistering disorders characterized by autoantibody binding to structural proteins of the dermal–epidermal junction (DEJ), leading to complement activation, linear deposition of complement component 3 (C3), and subsequent subepidermal blistering. Systemic and topical corticosteroids are the current first-line treatment; however, their long-term use is associated with significant adverse effects, and their precise mechanisms of action in PD remain incompletely defined.

Materials and Methods

In this study, we examined the effects of the corticosteroid methylprednisolone (MP) on complement-driven inflammatory processes relevant to PD pathogenesis using an indirect complement fixation assay. Human skin sections from healthy donors were incubated with recombinant PD antibodies or sera from PD patients to induce complement activation and C3 deposition at the DEJ. MP was added at concentrations of 0.3mM, 1mM, or 3mM. Experiments using recombinant autoantibodies were conducted on skin sections from six independent healthy donors, while serum-based experiments were performed on skin sections from five healthy donors using sera from three different PD patients. In selected experiments, other corticosteroids (dexamethasone, prednisolone, and hydrocortisone) were tested for comparison. Complement activation products (C5a, factor B, and C4d) were quantified in assay supernatants.

Results

Recombinant PD antibodies induced pronounced C3 deposition at the DEJ in human skin sections. This effect was inhibited by MP in a dose-dependent manner (0.3mM, 1mM, and 3mM). The inhibitory effect was reproducible in skin sections derived from six healthy donors incubated with recombinant PD antibodies and MP at 3mM. In addition, sera from three PD patients triggered C3 deposition at the DEJ, which was significantly reduced following MP co-incubation. Comparable inhibitory effects were observed with other corticosteroids, including dexamethasone, prednisolone, and hydrocortisone, supporting a class-specific mode of action. Analysis of complement activation products in assay supernatants revealed a marked reduction in C5a levels in MP-treated samples, while levels of factor B and C4d remained unaffected.

Conclusions

These results indicate that MP directly interferes with C3 activation, thereby attenuating downstream complement effector mechanisms without blocking upstream initiation of the classical or alternative pathways. Collectively, our

findings establish a mechanistic link between corticosteroid efficacy and the molecular pathogenesis of PD and identify MP’s site of action within the complement pathway, highlighting complement modulation as a promising therapeutic target.

EA DV CONGRESS
VIENNA
30 SEP - 3 OCT 2026

Abstract N°: 3602

Hereditary Hemorrhagic Telangiectasia: The Dermatologist's Sentinel Role in the Diagnosis of Refractory Iron Deficiency Anemia

Jessenia kathiuska Herrera Rodriguez*[1], Carolina Vitória De Lucia[1], GABRIELA ALENCAR[2], Paula Figueiredo de Marsillac[1]

[1] UERJ Hospital Universitário Pedro Ernesto, UERJ, Rio de Janeiro, Brazil
[2] UERJ Hospital Universitário Pedro Ernesto, Rio de Janeiro, Brazil

Introduction
Hereditary Hemorrhagic Telangiectasia (HHT), also known as Rendu-Osler-Weber Syndrome, is a systemic angiodysplasia inherited as an autosomal dominant trait with variable penetrance. Its prevalence is estimated between 1:5,000 and 1:8,000 individuals[1] The pathogenesis involves mutations in the *ENG* or *ACVRL1* genes, leading to aberrant signaling of the transforming growth factor-beta (TGF-β) superfamily within the vascular endothelium[2] Clinically, it is characterized by mucocutaneous telangiectasias and visceral arteriovenous malformations (AVMs). The dermatologist's role is crucial, as cutaneous manifestations frequently precede life-threatening systemic complications, such as gastrointestinal bleeding and neurological events.

Case Presentation
A 76-year-old female patient, with a medical history of insulin-dependent type 2 Diabetes Mellitus, systemic arterial hypertension, and Primary Biliary Cholangitis, was admitted for the investigation of severe iron deficiency anemia (Hemoglobin: 7.0 g/dL; MCV: 67.5 fL; low ferritin). She reported significant weight loss over the past year and a prior history of blood transfusions.

Dermatological examination revealed multiple 1–3 mm, punctate, reddish-purple lesions located on the tongue, palms, fingertips, and the left hallux. The lesions blanched under diascopy. The patient reported the onset of these lesions three decades ago and a history of recurrent epistaxis, which intensified during the use of antiplatelet agents. Family history revealed a pattern of premature deaths due to vascular events, notably the death of her son at age 18 from a ruptured cerebral aneurysm. Based on the triad of spontaneous epistaxis, typical telangiectasias, and a first-degree family history, a clinical diagnosis of HHT was established according to the Curaçao Criteria[3]

Conclusion

Discussion

Refractory iron deficiency anemia in HHT patients is frequently secondary to chronic occult gastrointestinal bleeding arising from digestive tract telangiectasias [4] Although vasculitis was initially suspected, the morphology and chronology of the lesions pointed toward vascular dysplasia.

Recent literature emphasizes that the presence of telangiectasias on the extremities and oral cavity correlates with an increased risk of pulmonary and hepatic AVMs [5] In this case, the family history of cerebral aneurysm serves as a critical red flag for screening central nervous system (CNS) vascular malformations, as the rupture of these

structures is a preventable cause of sudden death.[2] Management requires a multidisciplinary approach, including imaging screening (Chest and Abdominal CT Angiography) and rigorous hematological monitoring.

Conclusion

The diagnosis of Rendu-Osler-Weber Syndrome is eminently clinical and relies on the dermatologist's expertise in characterizing elementary vascular lesions. This case illustrates how a detailed physical examination can connect seemingly isolated systemic symptoms, enabling preventive intervention and family genetic counseling.

EA DV CONGRESS
VIENNA
30 SEP - 3 OCT 2026

Abstract N°: 3622

Behind the Harlequin's Mask: A Case of Autonomic and Sensory Hemi facialDysfunction

Rihem Godcha*[1], Korbi Mouna[1], Rihab Ben Dhieb[1], Hichem BelhajAli[1], Monia Youssef[1], Jamelledine Zili[1]

[1] Fattouma Bourguiba Hospital, Monastir, Tunisia

Introduction

Introduction
Harlequin syndrome is a rare disorder of the autonomic nervous system, characterized by unilateral facial flushing and hyperhidrosis, contrasting with contralateral pallor and anhidrotic. Symptoms are typically triggered by physical exertion, heat exposure, or emotional stress. The condition may be idiopathic or secondary to disruption of the sympathetic pathways supplying the face, most commonly along the cervicothoracic region.

Case Presentation

Case Report
A 56-year-old woman with a history of poorly controlled rheumatoid arthritis, presented to the Dermatology Department for recurrent episodes of facial flushing, erythema, and angioedema affecting the right hemiface, associated with profuse sweating. These episodes were consistently induced by physical effort and resolved spontaneously within 15 to 30 minutes after cessation of activity. Clinically, the attacks were characterized by marked erythema and hyperhidrosis on the right side of the face, contrasting with pallor and anhidrosis on the left hemiface. The patient also reported a previous episode of right-sided facial paralysis occurring several years earlier, which had resolved spontaneously.
Neurological examination revealed hypoesthesia of the right hemiface without any additional focal neurological deficits. Brain magnetic resonance imaging (MRI) was requested to exclude a central or compressive etiology.
Discussion
According to the literature, Harlequin syndrome results from partial impairment of the sympathetic vasomotor and sudomotor pathways innervating the face. These fibers typically originate between the T2 and T3 thoracic segments before ascending to the superior cervical ganglion. The characteristic asymmetric presentation is explained by ipsilateral sympathetic denervation, leading to compensatory hyperactivity of the contralateral intact pathways.
Most cases reported through literature are idiopathic; however, secondary forms have been associated with peripheral neuropathies, radiculopathies, inflammatory or autoimmune diseases, neoplastic lesions, carotid artery dissection, and cervicothoracic surgical or anesthetic procedures. The coexistence of Harlequin syndrome with autoimmune conditions such as rheumatoid arthritis supports the hypothesis of an underlying inflammatory or immune-mediated mechanism in certain patients. The exact prevalence of Harlequin syndrome remains unknown due to its rarity and likely underdiagnosis. Overall prognosis is favorable, and management primarily focuses on identifying and treating the underlying cause when present. In idiopathic cases, reassurance is usually sufficient, as symptoms are benign and self-limiting.

Conclusion

Harlequin syndrome is a rare and likely underrecognized autonomic disorder that should be considered in patients presenting with exercise- or heat-induced unilateral facial flushing and sweating. Although most cases are idiopathic and benign, the presence of associated neurological symptoms or underlying systemic diseases, particularly autoimmune disorders such as rheumatoid arthritis, warrants careful evaluation to exclude secondary causes. Early recognition and appropriate etiological assessment are essential to ensure reassurance in benign forms and targeted management when an underlying condition is identified.

EA DV CONGRESS
VIENNA
30 SEP - 3 OCT 2026

Abstract N°: 3631

Efficacy of a balm with unique Vaseline-like texture on foot xerosis and superficial fissures in diabetics patients

Jennifer Theunis[1], Jolane Perrin[1], Aurélie Villaret[1], Alexia Brocario*[2], Valérie MENGEAUD[2]

[1] R&D Department, Pierre Fabre Dermo-Cosmetics & Personal Care, Toulouse, France

[2] Medical Direction, Laboratoire Dermatologique A-DERMA, Lavaur, France

Introduction

Skin xerosis, especially foot xerosis, is a common condition among diabetics which can lead to painful cracks and possibly neuropathic ulcers and infections. Regular use of moisturizers is recommended to help manage and prevent xerosis from developing. We assessed efficacy of a balm with unique Vaseline-like texture, who has demonstrated its effectiveness in hydrating the skin durably and intensely in previous clinical studies, on a new target population: diabetics patients suffering from foot xerosis and superficial fissures.

Materials and Methods

Adults suffering from controlled type 1 or 2 diabetes and presenting foot xerosis rated as 6 according to the Xerosis Assessment Scale (XAS) with superficial fissures, have been enrolled in a monocentric, open-labelled study. Patients with diabetes complications (arteriopathy, microangiopathy, neuropathy), presenting deep fissures on feet with damage to the dermis, with infection and vasculitis or suffering from foot ulcer or gangrene were not enrolled. Patients applied the balm containing 100% ingredients of natural origin to both feet, twice a day, for 27 days. At every visit (D1, D5, D28), clinical evaluation of xerosis intensity, evaluation of skin hydration, photographs and pruritus assessment were performed. The repairing effect was assessed by investigator and patient after 4 and 27 days of application. At D1 and D28, quality of life evaluation was performed and cosmetic satisfaction and perceived effect evaluation questionnaire was completed by patients. The global soothing effect and the tolerance were also assessed at D28.

Results

32 patients, aged 33 to 77 years old, with controlled type 1 or 2 diabetes and presenting foot xerosis and superficial fissures, were enrolled. Foot xerosis assessed by the investigator with XAS significantly improved from 4 days of application (-27%, $p<0.001$) and after 27 days of application (-77.6% $p<0.001$). These results were confirmed by hydration index measurement on foot's heel from D5 (+46%; $p=0.008$) and at D28 (+92%; $p<0.001$). Images analysis has shown a significant decrease in skin roughness at D5 (-25.18% of Spa and -25.18% of Spq; $p<0.001$) and D28 (-30,51% of Spa and -30.51% of Spq; $p<0.0001$). A significant decrease of contrast and entropy was also shown at D5 (-42.7% and -8.8%; $p<0.001$) and D28 (-48.3% and -11.4%; $p<0.001$) which suggests a more uniform and regular skin texture. The length and depth of superficial cracks also decreased significantly at D5 (-25.2%; $p=0.004$ and -19,1% $p=0.020$) and D28 (-54.96%; $p<0.001$ and -22.63%; $p=0.016$). The repairing effect on superficial cracks was assessed by the investigator as significant on both feet as well as on a target crack at D28 ($p<0.001$). Patients also perceived this significant global repairing efficacy ($p=0.004$). From the first application, the balm helped to immediately soothe the pruritus in the feet (-49.4% $p=0.004$). These results were confirmed at D5 and D28 (-47.6% $p=0.016$ and -73% $p=0.018$ respectively). 80% of patients saw their quality of life improved after 27 days of application ($p=0.002$) including an improvement in foot comfort. 100% of patients found the

product easy to apply (average rating assigned = 9.5/10) with an enveloping texture (average rating = 9/10) and leaving a protective film on the skin (9.2/10). Soothing effect was significantly appreciated by patients at D28 (p=0.014) and tolerance was judged excellent by the investigator.

Conclusions

This study demonstrates the interest of using a balm with unique Vaseline-like texture to promote optimal repair of skin xerosis and superficial cracks while ensuring comfort and safety for diabetic patients.

EA DV CONGRESS
VIENNA
30 SEP - 3 OCT 2026

Abstract N°: 3644

Hereditary Hemorrhagic Telangiectasia: The Dermatologist's Sentinel Role in the Diagnosis of Refractory Iron Deficiency Anemia

Jessenia kathiuska Herrera Rodriguez*[1], Carolina Vitória De Lucia[1], GABRIELA ALENCAR[1], Paula Figueiredo de Marsillac[1], Doménica Cerón Chimarro[2]

[1] UERJ Hospital Universitário Pedro Ernesto, UERJ, Rio de Janeiro, Brazil

[2] UERJ Hospital Universitário Pedro Ernesto, Rio de Janeiro, Brazil

Introduction

Hereditary Hemorrhagic Telangiectasia (HHT), also known as Rendu-Osler-Weber Syndrome, is a systemic angiodysplasia inherited as an autosomal dominant trait with variable penetrance. Its prevalence is estimated between 1:5,000 and 1:8,000 individuals[1] The pathogenesis involves mutations in the *ENG* or *ACVRL1* genes, leading to aberrant signaling of the transforming growth factor-beta (TGF-β) superfamily within the vascular endothelium[2] Clinically, it is characterized by mucocutaneous telangiectasias and visceral arteriovenous malformations (AVMs). The dermatologist's role is crucial, as cutaneous manifestations frequently precede life-threatening systemic complications, such as gastrointestinal bleeding and neurological events.

Case Presentation

A 76-year-old female patient, with a medical history of insulin-dependent type 2 Diabetes Mellitus, systemic arterial hypertension, and Primary Biliary Cholangitis, was admitted for the investigation of severe iron deficiency anemia (Hemoglobin: 7.0 g/dL; MCV: 67.5 fL; low ferritin). She reported significant weight loss over the past year and a prior history of blood transfusions.

Dermatological examination revealed multiple 1–3 mm, punctate, reddish-purple lesions located on the tongue, palms, fingertips, and the left hallux. The lesions blanched under diascopy. The patient reported the onset of these lesions three decades ago and a history of recurrent epistaxis, which intensified during the use of antiplatelet agents. Family history revealed a pattern of premature deaths due to vascular events, notably the death of her son at age 18 from a ruptured cerebral aneurysm. Based on the triad of spontaneous epistaxis, typical telangiectasias, and a first-degree family history, a clinical diagnosis of HHT was established according to the Curaçao Criteria[3]

Conclusion

Discussion

Refractory iron deficiency anemia in HHT patients is frequently secondary to chronic occult gastrointestinal bleeding arising from digestive tract telangiectasias [4] Although vasculitis was initially suspected, the morphology and chronology of the lesions pointed toward vascular dysplasia.

Recent literature emphasizes that the presence of telangiectasias on the extremities and oral cavity correlates with an increased risk of pulmonary and hepatic AVMs [5] In this case, the family history of cerebral aneurysm serves as a critical red flag for screening central nervous system (CNS) vascular malformations, as the rupture of these

structures is a preventable cause of sudden death.[2] Management requires a multidisciplinary approach, including imaging screening (Chest and Abdominal CT Angiography) and rigorous hematological monitoring.

Conclusion

The diagnosis of Rendu-Osler-Weber Syndrome is eminently clinical and relies on the dermatologist's expertise in characterizing elementary vascular lesions. This case illustrates how a detailed physical examination can connect seemingly isolated systemic symptoms, enabling preventive intervention and family genetic counseling.

EA DV CONGRESS
VIENNA
30 SEP - 3 OCT 2026

Abstract N°: 3646

Multiple myeloma-associated bullous systemic amyloidosis with milia formation

Iva Garkova*[1], Elia Valeva[1], Valeria Mateeva[1], Vessela Ivanova[2], Dimitrina Serafimova[1], Snejina Vassileva[1], Kossara Drenovska[1]

[1] Department of Dermatology and Venereology, Medical University Sofia, Sofia, Bulgaria
[2] Department of General and Clinical Pathology Medical University Sofia, Sofia, Bulgaria

Introduction
Multiple myeloma-associated bullous systemic amyloidosis with milia formation

I Garkova, E. Valeva, V. Mateeva, V. Ivanova*, D. Serafimova, S. Vassileva, K. Drenovska

Department of Dermatology and Venereology, Medical University – Sofia, Sofia, Bulgaria

*Department of general and clinical pathology, Medical University – Sofia, Sofia, Bulgaria

Introduction:

Blistering eruptions are rare manifestations of skin involvement in patients with multiple myeloma (MM) and often present a diagnostic challenge. While acquired autoimmune blistering diseases (AIBD) are the primary suspects in elderly patients with blistering, the presence of an underlying plasma cell dyscrasia necessitates high clinical suspicion for systemic amyloidosis. Bullous systemic amyloidosis (BSA) is an exceptionally rare variant where amyloid deposition leads to vascular fragility and dermo-epidermal separation. We present a case of an elderly MM patient, whose clinical course was suggestive of amyloid-related condition despite the initial clinical suspicion of AIBD, particularly epidermolysis bullosa acquisita (EBA).

Case Presentation
A 79-year-old woman presentedt with a recurrent, generalised blistering eruption of few months duration. An year earlier the patient was diagnosed with MMSET-IgH t(4;14) (p16;q32) positive MM with IgA lambda +FLC lambda paraproteinemia. Dermatological examination upon admission revealed a polymorphic eruption with ill-defined erythematous-purpuric plaques, flaccid haemorrhagic bullae, and large erosions with epidermal detachment, involving large areas on the trunk, axillary folds, and upper extremities. Other clinical signs included marked skin fragility, periorbital ecchymoses ("pinch purpura"), and a pavement of numerous white milium cysts of various shapes and sizes on the chest and axillary folds. Laboratory investigations revealed elevated inflammatory markers (CRP 18.2 mg/l) and mild anaemia. Although histopathology indicated a subepidermal blister formation, direct immunofluorescence (IF) was repeatidly negative, as was indirect IF on salt-split skin substrate, thus ruling out the preliminary diagnosis of EBA. The persistence of haemorrhagic blistering, negative immunofluorescence, and poor response to immunosuppressants, coupled with the underlying MM, strongly suggested BSA. However, further efforts to detect amyloid deposition in the skin biopsies using Congo red staining and immunocytochemistry gave inconclusive results.

Conclusion

Cutaneous involvement is one of the most frequent clinical manifestations of systemic amyloidosis. Purpura, petechiae, papules, nodules, tumors, plaques, lichenoid lesions, scleroderma-like changes, poikiloderma, alopecia, and xanthoma, have all been associated with amyloid deposition in the skin. Bullous lesions, especially when accompanied by skin fragility and milia formation, as those observed in our patient, are extremely rarely reported in the literature. In the context of an underlying MM, this mechano-bullous phenotype should raise the suspicion of BSA, along with that of the classic variant of EBA. Despite the failure to detect amyloid deposition in the skin biopsies in our patient, we consider that the early recognition of the above-described clinical "amyloid clues", including multiple milia formation, is important, since cutaneous BSA often precedes severe internal organ involvement and progression of the underlying haematologic malignancy.

EA DV CONGRESS
VIENNA
30 SEP - 3 OCT 2026

Abstract N°: 3741

Post-traumatic localized hyperhidrosis of the hand: a case report

Hakim Hammadi*[1], Yahya Mamen[1], mounia slaouti[2]

[1] HMUSCORFA, ALGIERS, Algeria
[2] HCA, ALGIERS, Algeria

Introduction

Unilateral localized forms of hyperhidrosis are rare and should prompt investigation for peripheral or central autonomic nervous system involvement. Post-traumatic hyperhidrosis is a condition rarely described in the literature. Therapeutic management is often challenging. We report the case of a young patient presenting with unilateral localized hyperhidrosis of the left hand that appeared suddenly following an elbow injury and was resistant to iontophoresis.

Case Presentation

A 33-year-old man with no significant medical history was diagnosed with a synovial cyst of the left wrist, which was excised in August 2022. The postoperative course was uneventful without any neurological, vascular or functional complications. Six months after the procedure, the patient had a closed trauma of the left elbow in an accidental situation. Initial clinical and radiological assessment did not reveal any associated bone fracture or ligament injury. A few hours after the injury, the patient developed a sudden localized hyperhidrosis of the left hand, persistent and particularly disabling from a functional and socio-professional point of view. Hyperhidrosis was predominantly located in the palm and the palmar surfaces of the fingers. There was no involvement in other areas or on the contralateral side.

Clinically evident unilateral palmar hyperhidrosis was seen on dermatological examination (Fig. 1), with no associated skin changes, cyanosis, oedema or apparent vasomotor disturbances. His neurological examination was unremarkable. Further work up revealed no endocrine, infectious or central nervous system etiology. The onset circumstances, in relation to elbow trauma, suggested secondary post-traumatic hyperhidrosis due to peripheral autonomic dysfunction.
The patient received 24 iontophoresis treatments without significant clinical change in symptoms. The fact that marked hyperhidrosis persisted after treatment supported the conclusion that this localized secondary hyperhidrosis was resistant to iontophoresis.

Unilateral localized secondary hyperhidrosis is a rare clinical condition requiring rigorous etiological analysis. Unlike primary hyperhidrosis, which is generally bilateral and symmetrical, unilateral forms should raise suspicion of a neurological or post-traumatic origin. In our case report, the close temporal relationship between the trauma and the onset of symptoms; the strictly unilateral nature of the condition; the absence of a history of primary hyperhidrosis; and the absence of any identified systemic cause all support a traumatic etiology for the hyperhidrosis. The pathophysiology may be based on functional impairment of the sudomotor sympathetic fibers in the upper limb. Even in the absence of structural lesions visible on imaging, minor trauma can lead to local sympathetic hyperactivity due to nerve irritation or autonomic reorganization.The efficacy of iontophoresis is inconsistent in secondary hyperhidrosis, particularly of neurological origin. The lack of improvement after 12 sessions in our case is indicative of a resistant form. Other treatment options were discussed for this patient, such as: botulinum toxin type A injections, systemic anticholinergic treatments, and thoracic sympathectomy (invasive).

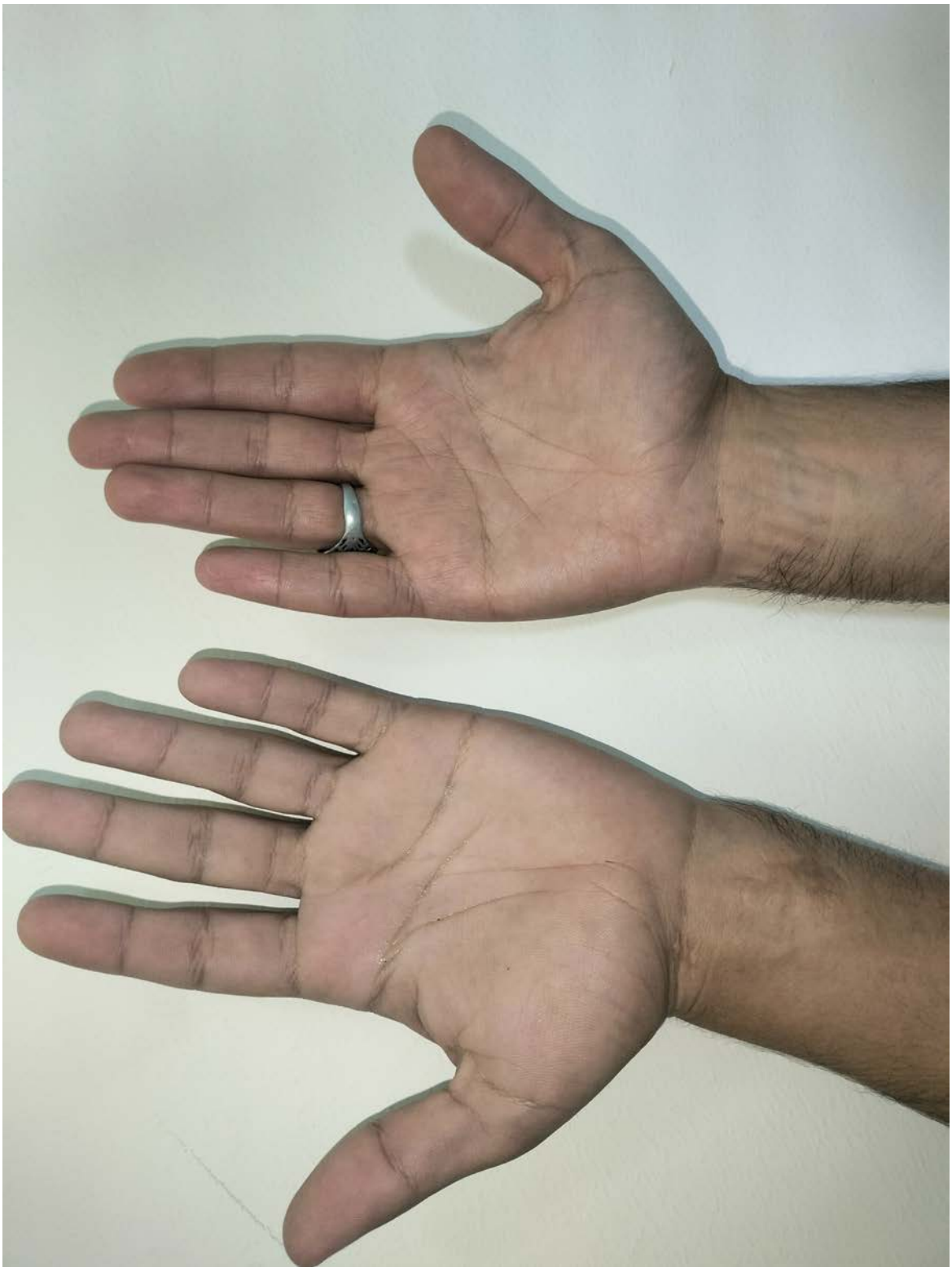

Conclusion

This finding highlights the need to consider a post-traumatic neurological cause in all cases of sudden-onset unilateral hyperhidrosis and underscores the therapeutic limitations of iontophoresis in certain secondary forms.

EADV CONGRESS
VIENNA
30 SEP - 3 OCT 2026

Abstract N°: 3746

Recurrent Facial Edema and Urticarial Dermographism – More Than Meets the Eye: Superior Vena Cava Syndrome Due to Mediastinal Lymphoma

Alexander Romswinkel*[1], Simon Mueller[1], Oliver Brandt[1]

[1] Department of Dermatology, University Hospital Basel, Basel, Switzerland

Introduction

The differential diagnoses of facial swelling are numerous. Angioedema due to allergic or intolerance reactions is one of the most common causes and is usually easy to diagnose, especially when accompanied by wheals. However, in rare cases these symptoms can be misleading, as illustrated in the following.

Case Presentation

An 18-year-old, otherwise apparently healthy female presented with a 5-week history of facial and neck swelling. She reported that symptoms had first appeared during a short-haul flight and that they had been recurrent ever since. As treatment with cetirizine 10 mg had failed to improve, her GP had started a course of prednisone 10 mg/d, which was quickly escalated to 50 mg/d due to a lack of improvement.

Because medical history was unremarkable except for occasional urticaria factitia, physical examination just revealed a slightly pronounced edematous periorbital and neck swelling and facies lunata, and laboratory tests only detected leukocytosis with a left shift, we tentatively diagnosed angioedema of unknown origin and iatrogenic Cushing's syndrome. The patient was recommended to taper prednisone and a follow-up appointment was arranged.

A few days later, she presented to the emergency department after she had become acutely somnolent, developed wheals on the left body side and complained of left-sided chest pain and weakness. Diagnostic imaging revealed superior vena cava syndrome due to a large mass, which appeared to be a primary mediastinal large B-cell lymphoma.

Conclusion

Malignancies should also be included in the differential diagnosis of facial swelling, even if wheals are present.

EADV CONGRESS
VIENNA
30 SEP - 3 OCT 2026

Abstract N°: 3750

The Zinc Sink: a case of Acquired Acrodermatitis Enteropathica post gastric-bypass

Mariam Abu Jubain*[1], Matthew Scorer[1]

[1] University Hospitals of Leicester NHS Foundation Trust, Leicester, United Kingdom

Introduction

Acquired acrodermatitis enteropathica (AAE) is an uncommon disorder of zinc deficiency that can present with nonspecific dermatologic and systemic features. As its signs: acral dermatitis, alopecia, and diarrhoea, overlap with common conditions, and because zinc deficiency is often overlooked, diagnosis is frequently delayed. AAE is most likely in patients with impaired absorption or increased losses (eg, bowel bypass, chronic diarrhoea, malabsorption), and although rare, it can lead to severe complications if untreated.

Case Presentation

A 62-year-old woman presented to dermatology with a 4-week history of a widespread rash that began as scaly erythematous rash on the hands, feet and groin. Her medical history included Roux-en-Y gastric bypass (2014), hypertension and prior meningitis with a spinoperitoneal shunt. Initial differential diagnoses included tinea corporis and later, when she deteriorated, possible erythrodermic psoriasis. Her became secondarily infected, precipitating sepsis and requiring inotropic support in intensive care. While in the intensive care unit, she experienced an abrupt fall in consciousness (drop in GCS) necessitating intubation. Her family revealed that she was suffering from long-standing post-bypass diarrhoea and an intermittent scaly scalp with alopecia. The combination of acral dermatitis, alopecia, chronic diarrhoea, and a history of bariatric surgery prompted measurement of serum zinc, which confirmed marked deficiency. Zinc supplementation was commenced promptly, after which the patient's GCS normalized, vasopressor support was weaned, and the rash resolved.

Conclusion

Although rare, Acquired Acrodermatitis Enteropathica (AAE) should be considered when dermatologic findings occur with diarrhoea or other risk factors for malabsorption, particularly in patients with prior bariatric surgery. Importantly, zinc deficiency and clinically significant AAE can present many years after gastric bypass, so clinicians must remain vigilant long-term. Early recognition and prompt zinc replacement can rapidly reverse neurological and dermatologic deterioration and prevent life-threatening complications.

EA DV CONGRESS
VIENNA
30 SEP - 3 OCT 2026

Abstract N°: 3762

Lupus Erythematosus Panniculitis in Children: A Case Report

Amira Laribi*[1], Meriem Tabka[1], Ahd Jday[1], Asmahane Souissi[1], Mourad Mokni[1]

[1] Rabta Hospital of Tunis, Tunis, Tunisia

Introduction

Lupus erythematosus panniculitis (LEP), also known as lupus erythematosus profundus, is a rare form of chronic cutaneous lupus characterized by lobular inflammation of the adipose tissue. It accounts for 2% to 3% of cutaneous lupus cases and is exceptionally rare in children. We report a case of pediatric LEP that was subject to a prolonged diagnostic delay.

Case Presentation

A 12-year-old boy with no significant medical history presented with an erythematous-pigmented plaque on his right cheek that had been evolving since the age of nine. The lesion initially appeared as a well-defined, slightly infiltrated plaque. Over time, the infiltration deepened, leading to progressive cicatricial atrophy and post-inflammatory hyperpigmentation.

Successive histological examinations were performed throughout the disease course. Initial biopsies suggested an insect bite reaction and, subsequently, cutaneous pseudolymphoma. Due to the persistence of the lesion and diagnostic uncertainty, a new deep incisional biopsy including the hypodermis was performed. Histology revealed a dense lymphocytic infiltrate extending from the dermis to the hypodermis, organized into follicles with germinal centers. This was associated with basal layer vacuolization and lobular fat necrosis, confirming the diagnosis of LEP.

Treatment was initiated with hydroxychloroquine (400 mg/day) combined with oral prednisolone (30 mg/day). The clinical course showed a regression of inflammatory signs and stabilization of the atrophic lesions.

Conclusion

Although rarely described in the pediatric population, LEP in children frequently presents with malar involvement. Diagnosis relies on the histological identification of lymphocytic lobular panniculitis associated with features of cutaneous lupus, such as interface dermatitis and/or dermal mucinosis.

Diagnostic challenges are significant. The organization of the inflammatory infiltrate into lymphoid follicles with germinal centers is a classic pitfall that can lead to a misdiagnosis of cutaneous pseudolymphoma, as seen in our case. Obtaining a sufficiently deep biopsy that includes the hypodermis is therefore essential.

Evolution toward cicatricial atrophy with skin depression reflects irreversible adipocyte destruction. This form of lupus may remain strictly cutaneous for several years without systemic involvement or associated immunological abnormalities.

Regarding management, antimalarials remain the first-line treatment. The addition of oral corticosteroids is often necessary during the initial phase to rapidly control inflammation and limit the progression of lipoatrophy. Early intervention is crucial to prevent permanent aesthetic sequelae, which can have a major psychological impact on children.

Lupus erythematosus panniculitis should be considered in any child presenting with a chronic infiltrated plaque on the face. An early and sufficiently deep biopsy is indispensable for diagnosis. Prompt management is vital to limit irreversible aesthetic damage.

EA DV CONGRESS
VIENNA
30 SEP - 3 OCT 2026

Abstract N°: 3854

Etiopathogenic Diversity of Panniculitis in Tunisia: From Histological Patterns to Systemic Investigation

Ahd Jday*[1], mariem tabka[1], Feryel Amri[1], Asmahane Souissi[1], Ines Chelly[2], Mourad Mokni[1]

[1] Dermatology Department, Rabta Hospital, Tunis, Tunisia

[2] Department of Anatomopathology, Rabta Hospital, Tunis, Tunisia

Introduction

Panniculitis remains a major diagnostic challenge in dermatology, requiring careful clinicopathological correlation between clinical, biological, and histopathological findings. While erythema nodosum is classically considered the most common form of panniculitis, the etiological spectrum in Tunisia is influenced by the endemicity of infectious diseases such as tuberculosis and by the prevalence of systemic inflammatory disorders. This study aimed to analyze the distribution of panniculitis subtypes and identify diagnostic orientation factors in a 20-year hospital-based series.

Materials and Methods

We conducted a retrospective descriptive study including all patients diagnosed with histologically confirmed panniculitis in our Department of Dermatology between 2006 and 2026.

Results

The study included 52 patients, with a marked female predominance (41 women and 11 men; sex ratio: 0.26). The mean age was 42.5 years (range: 3–69 years). The clinical presentation was dominated by inflammatory subcutaneous nodules (79% of cases), predominantly involving the lower limbs (88%). Pain was the most frequently associated symptom. Histopathological examination demonstrated a predominance of mostly lobular panniculitis (50%), followed by mostly septal (33%) and mixed panniculitis (17%), with associated vasculitis identified in 19% of biopsies. Etiological investigation revealed that erythema induratum of Bazin/nodular vasculitis was the most frequent diagnosis (25%), consistently associated with a granulomatous lobular panniculitis pattern and strongly correlated with positive tuberculosis screening tests (Quantiferon and tuberculin skin test). Erythema nodosum accounted for 23% of cases and typically exhibited a septal panniculitis pattern. Its etiologies were mainly post-streptococcal infections but also included systemic diseases such as Behçet disease and spondyloarthritis. Other diagnoses included traumatic panniculitis (10%), lupus panniculitis/profundus (8%), subcutaneous sarcoidosis (6%), and rarer entities such as deep Sweet syndrome associated with Crohn disease, deep morphea, Weber–Christian disease, and deep cutaneous metastases. Despite extensive investigations, approximately 15% of cases remained idiopathic. Therapeutic outcomes were generally favorable under etiologically targeted treatments, including antituberculous therapy, colchicine, or systemic corticosteroids, although relapses occurred in 13% of patients.

Conclusions

This series was characterized by a relatively high frequency of lobular panniculitis and vasculitic patterns, contrasting with Western series in which erythema nodosum is largely predominant. This discrepancy likely reflects

a classic recruitment bias in tertiary referral centers, as clinically typical erythema nodosum rarely undergoes histopathological confirmation in routine practice. Conversely, chronic, atypical, ulcerative, or recurrent nodular lesions suggestive of nodular vasculitis usually require deep skin biopsy and histopathological examination. Our findings confirm that the distinction between septal and lobular panniculitis remains a key step in the diagnostic approach. A predominantly septal pattern strongly supports erythema nodosum, whereas granulomatous lobular panniculitis should prompt investigation for tuberculosis, particularly in endemic settings. Finally, the diversity of etiologies observed in this series underscores the importance of careful clinical examination, histopathological assessment, and targeted investigations in refining or revising the initial diagnostic hypotheses, particularly in atypical presentations.

EADV CONGRESS
VIENNA
30 SEP - 3 OCT 2026

Abstract N°: 3888

Cardiovascular Risk Across Rosacea Subtypes: Are Certain Phenotypes More Systemically Relevant?

Aleksandra Frątczak*[1], Monika Bonczek[2], Joanna Rak[2], Krystian Domeracki[2], Wiktor Kruczek[1, 2, 3], Bartosz Miziołek[1], Beata Bergler-Czop[1]

[1] Department of Dermatology, School of Medicine in Katowice, Medical University of Silesia, Katowice, Poland
[2] Students' Scientific Association at the Department of Dermatology, School of Medicine in Katowice, Medical University of Silesia, Katowice, Poland
[3] Doctoral School, Medical University of Silesia, Katowice, Poland

Introduction
Rosacea is a chronic inflammatory dermatosis with heterogeneous clinical phenotypes (erythematotelangiectatic, papulopustular, ocular, and phymatous). Increasing evidence suggests a potential association with cardiovascular and metabolic dysregulation; however, data remain inconsistent and phenotype-specific cardiovascular risk is insufficiently characterized. The aim of this study was to systematically evaluate associations between rosacea and cardiovascular risk factors, subclinical vascular markers, and cardiovascular outcomes, with a focus on phenotype-stratified evidence.

Materials and Methods
This systematic review was conducted according to PRISMA guidelines. PubMed, Embase, and Cochrane Library were searched up to April 2026. Three independent reviewers performed study selection and data extraction. Observational studies (cohort, case–control, cross-sectional) including adults with clinically diagnosed, ICD-coded, or self-reported rosacea were included. Outcomes comprised hypertension, coronary artery disease, myocardial infarction, stroke, metabolic syndrome, lipid profile abnormalities, blood pressure indices, inflammatory markers, and subclinical atherosclerosis measures. In total, 182 records were screened and 9 studies met inclusion criteria.

Results
A total of 1596 participants (799 rosacea patients and 797 controls) from 9 observational studies were included. Overall, rosacea was associated with a modest but consistent adverse cardiometabolic profile compared with controls, although effect sizes and significance varied across studies. Across studies, the most frequently reported abnormalities were higher total cholesterol and LDL levels, as well as increased inflammatory markers including C-reactive protein (CRP). Several studies additionally reported higher systolic and diastolic blood pressure in rosacea populations. Lifestyle-associated cardiovascular risk factors, including smoking and alcohol consumption, and a family history of premature cardiovascular disease, were more frequently observed in rosacea cohorts in some but not all studies. Evidence for phenotype-specific cardiovascular risk was limited and heterogeneous. One study reported significantly higher estimated cardiovascular risk scores (SCORE) and higher blood pressure in papulopustular rosacea compared with erythematotelangiectatic rosacea ($p = 0.04$ for SCORE), while other studies did not perform or report robust phenotype-stratified analyses. Overall, current evidence suggests a possible but not consistently demonstrated trend toward higher cardiovascular

burden in papulopustular disease. Markers of subclinical atherosclerosis provided additional supportive evidence for a systemic vascular association. Increased epicardial fat thickness (EFT) and carotid intima-media thickness (CIMT) were consistently reported in rosacea patients across imaging-based studies. In multivariable analysis, EFT remained independently associated with rosacea (OR 13.31; 95% CI 4.15–42.68; $p<0.001$) and correlated with CIMT and blood pressure parameters.

Conclusions

This systematic review demonstrates that rosacea is associated with adverse cardiometabolic and inflammatory profiles, including dyslipidemia, elevated blood pressure, and subclinical vascular changes. However, phenotype-specific cardiovascular risk remains insufficiently studied and evidence for a consistent gradient across rosacea subtypes is limited. Available data suggest a potential increased cardiovascular burden in papulopustular rosacea, but findings are not uniform across studies. These results support rosacea as a systemic inflammatory disease with possible cardiovascular implications and highlight the need for well-designed prospective studies with standardized phenotype stratification and cardiovascular endpoints.

EA DV CONGRESS
VIENNA
30 SEP - 3 OCT 2026

Abstract N°: 3894

Cutaneous and mucosal manifestations in ANCA-associated vasculitis: a reflection of systemic disease activity

Cheikh Elkadhi*[1], yosra bouattour[2], Abderrahmen Masmoudi[1], hend gassara[2], sameh marzouk[2], Hamida Turki[1]

[1] Dermatology Department, Hedi Chaker University Hospital, Sfax, sfax, Tunisia
[2] Internal Medicine Department, Hedi Chaker, Sfax, sfax, Tunisia

Introduction

ANCA-associated vasculitides (AAV) are rare and severe systemic vasculitides that predominantly affect small-sized vessels. They include granulomatosis with polyangiitis (GPA), eosinophilic granulomatosis with polyangiitis (EGPA), and microscopic polyangiitis. Their clinical presentation is heterogeneous, mainly characterized by ENT, pulmonary, and renal involvement. Dermatological manifestations are an important diagnostic feature. They reflect small-vessel vasculitis and often indicate severe forms of the disease. We aim to study the specific characteristics of cutaneous involvement in AAV.

Materials and Methods

Retrospective study conducted in an internal medicine department from January 1997 to December 2024. The diagnosis of ANCA-associated vasculitis (AAV) was established according to the 2022 ACR/EULAR criteria. Patients with AAV and cutaneous and/or mucosal involvement were included. Clinical, histological, and immunological data were collected.

Results

Among a series of 35 patients with AAV, cutaneous and/or mucosal involvement was found in 12 patients: 4 cases of GPA and 8 cases of EGPA. The cohort included 6 men and 6 women, with a mean age of 47 years, ranging from 22 to 76 years.

In GPA, all 4 patients had a diffuse and severe form of the disease. Vascular purpura was observed in 2 cases, ulceronecrotic lesions of the lower limbs in 1 case, and non-pruritic maculopapular lesions on both arms in another case. Skin biopsy, performed in 2 cases, showed leukocytoclastic vasculitis in one case and a giant-cell granuloma without caseous necrosis in the other. Ischemia of the left fifth toe requiring amputation was noted in one case. Oral ulcerations were observed in all 4 cases, including giant aphthous ulcers in one case and gingival hypertrophy in another**.**

In EGPA, vascular purpura of the lower limbs was the most frequent manifestation, observed in 7 cases. An extensive and/or ulceronecrotic form of purpura was noted in 3 cases, and a petechial pattern in 2 cases. Erythematous macular lesions were reported in 2 cases, involving the legs in one case and the trunk in the other. Urticaria was reported in one case. In these patients, a vasculitic phenotype predominated, with ANCA positivity in 10 cases: 7 anti-MPO and 3 anti-PR3.

Conclusions

Cutaneous and mucosal manifestations in ANCA-associated vasculitis are heterogeneous and are predominantly represented by vascular purpura. They reflect the systemic activity of the disease and appear to be associated with severe vasculitic forms. Our study highlights the importance of early recognition of cutaneous involvement, which

represents a key diagnostic and prognostic feature.

EA DV CONGRESS
VIENNA
30 SEP - 3 OCT 2026

Abstract N°: 3898

Pyoderma Gangrenosum Following Azathioprine Withdrawal in a Patient with Long-Standing Ulcerative Colitis: A Case Report

Petra Temelkova*[1], Nora Pollozhani[1], Maja Dimova[1], Katerina Damevska[1], Rufie Ziberi Ramuka[1], Anastasija Pesic[1]

[1] PHI University Clinic for Dermatology, Faculty of Medicine "Ss. Cyril and Methodius", Skopje, North Macedonia

Introduction

Pyoderma gangrenosum (PG) is a rare autoinflammatory neutrophilic dermatosis and a recognized extraintestinal manifestation of inflammatory bowel disease (IBD), occurring more frequently in genetically susceptible individuals. It is characterized by painful, rapidly progressive cutaneous ulcers with violaceous, undermined borders. We present a case of PG developing one year after discontinuation of Azathioprine, previously prescribed for long-standing Ulcerative colitis (UC).

Materials and Methods

Detailed medical history, dermatologic evaluation, and laboratory investigations, including a complete blood count with differential and inflammatory markers were performed. Microbiological evaluation of ulcerative lesions was obtained to exclude an underlying infectious etiology. Histopathologic examination of a skin biopsy taken from the active border of an ulcerative lesion was performed. The diagnosis of PG was established using the Delphi consensus (2018) criteria, with a sensitivity of 86% and a specificity of 90%.

Results

A 19-year-old female with a 14-year history of UC, diagnosed at the age of 4, presented with a two-month history of persistent, painful ulcerative lesions localized on the right foot, previously treated with systemic antibiotics without clinical improvement. Azathioprine therapy, previously used for UC, had been discontinued one year prior to the onset of cutaneous manifestations due to sustained remission of the underlying disease. Dermatological examination revealed multiple painful ulcerations and pustular lesions involving the medial and perimalleolar regions as well as the dorsal aspect of the right foot. The ulcers were characterized by central necrosis and violaceous, undermined borders, surrounded by an erythematous halo. Laboratory investigations revealed elevated ESR (75 mm/h), CRP (56.4 mg/L), leukocytosis (11.2 $\times 10^9$/L), and iron deficiency anemia, while all other parameters were within normal limits. Microbiological analysis was negative, with no bacterial growth detected. Histopathology revealed dense neutrophilic infiltration. Progressive clinical improvement was observed following initiation of immunosuppressive therapy, including systemic corticosteroids with gradual tapering and reintroduction of Azathioprine, in combination with local antiseptic and antibiotic treatment. Complete resolution was achieved within 11 months of therapy, with residual cicatricial changes at previously affected sites. As previously stated, the diagnosis of PG associated with UC was made according to the Delphi criteria. The major criterion was fulfilled by histopathologic evidence of a neutrophilic infiltrate. Minor criteria included: exclusion of infection, history of UC, presence of pustules and multiple ulcerations with peripheral erythema, undermined borders, and tenderness, with healed scars and a decrease in ulcer size within 1 month of initiating immunosuppressive therapy. These findings collectively satisfied at least four minor criteria, confirming the diagnosis.

Conclusions

This case highlights the importance of recognizing PG following withdrawal of immunosuppressive therapy initiated for IBD control, even in the setting of clinical remission of UC, underscoring the need for prompt reintroduction of immunosuppressive therapy to achieve improvement of both cutaneous manifestations and potential underlying disease activity.

EADV CONGRESS
VIENNA
30 SEP - 3 OCT 2026

Abstract N°: 3903

Current and emerging therapies for uremic pruritus in hemodialysis patients: from pathogenesis to targeted treatment

Aleksandra Frątczak*[1], Karolina Blady[2], Wiktor Kruczek[2, 3], Karina Polak[1], Bartosz Miziołek[1], Beata Bergler-Czop[1]

[1] Department of Dermatology, School of Medicine in Katowice, Medical University of Silesia, Katowice, Poland
[2] Students' Scientific Association at the Department of Dermatology, School of Medicine in Katowice, Medical University of Silesia, Katowice, Poland
[3] Doctoral School, Medical University of Silesia, Katowice, Poland

Introduction
Uremic pruritus (UP), also referred to as chronic kidney disease-associated pruritus (CKD-aP), affects a substantial proportion of hemodialysis patients worldwide. Characterized by persistent and often severe itching, UP significantly compromises quality of life, leading to disrupted sleep, impaired mental health, and hindered daily activities. Despite its high prevalence, the pathogenesis of CKD-aP remains incompletely understood, and it is regarded as a multifactorial condition. Proposed mechanisms include chronic inflammation, immune system dysregulation, xerosis, neuropathic changes, and disturbances in the opioid receptor system. Recent attention has been directed toward emerging therapies targeting these mechanisms, specifically κ-opioid receptor agonists, which offer potential benefits for patients resistant to conventional therapies.

Materials and Methods
A narrative review of the literature was conducted using the PubMed, Embase, and Cochrane Library databases. Articles on the pathogenesis and treatment of uremic pruritus in hemodialysis patients were analyzed. Relevant clinical trials, review articles, and meta-analyses published in English were included. The following keywords were used: "uremic pruritus", "CKD-associated pruritus", "hemodialysis", "difelikefalin", and "gabapentin".

Results
Current evidence suggests a promising role of novel therapies, particularly κ-opioid receptor agonists, in the management of CKD-aP. Difelikefalin, a selective κ-opioid receptor agonist, has emerged as a new option in UP management, with clinical trials showing positive results in symptom reduction in hemodialysis patients. Difelikefalin's ability to modulate pathways implicated in pruritus with an acceptable safety profile makes it a promising therapeutic option. Furthermore, gabapentin, a medication commonly used for neuropathic pain, has also shown moderate improvements in pruritus control, though evidence is derived mainly from relatively small studies, and its use is limited by side effects such as dizziness and sedation.
Nalfurafine, a κ-opioid receptor agonist, has also demonstrated efficacy in reducing pruritus severity in hemodialysis patients and may represent an alternative therapeutic option.
Conventional therapies, such as antihistamines, generally provide limited symptomatic relief. In contrast, targeted therapies such as difelikefalin may offer advantages in selected patients by modulating pathways implicated in CKD-aP. Additionally, emerging research on the role of the opioid receptor system in CKD-aP and other novel pathways provides a foundation for developing even more effective treatments in the future.

Conclusions

Uremic pruritus remains a challenging and frequently underappreciated complication for patients undergoing hemodialysis, with its complex, multifactorial pathogenesis complicating treatment efforts. Emerging targeted therapies such as difelikefalin, along with adjunctive agents including gabapentin, demonstrate significant potential, with difelikefalin standing out as a therapeutic option that targets one of the proposed mechanisms involved in CKD-aP. However, the evidence supporting these therapies is still limited by the heterogeneity of available studies and variations in treatment regimens. The quality of the current evidence is variable, and further studies are needed to fully elucidate the pathophysiology of uremic pruritus. More research is also required to optimize the use of targeted therapies, taking into account patient-specific factors. Future studies should aim to refine treatment regimens, enhance patient outcomes, and explore potential new drug classes for more personalized and effective management of this debilitating condition.

EA DV CONGRESS
VIENNA
30 SEP - 3 OCT 2026

Abstract N°: 3926

Clinical Features and Treatment of Acanthosis Nigricans: A Systematic Review

Renee Gabrielle Fajardo*[1], Shu Yu Qian[2], Ilya Mukovozov[3]

[1] Schulich School of Medicine and Dentistry, London, Canada

[2] University of Sherbrooke, Sherbrooke, Canada

[3] Toronto Dermatology Centre & MapleDerm, Division of Dermatology, Department of Medicine, Women's College Hospital, Division of Dermatology, Department of Medicine, University of Toronto, Toronto, Canada

Introduction

Acanthosis nigricans (AN) is a dermatological condition characterized by hyperpigmented, thickened, velvety plaques predominantly affecting flexural areas including the neck, axillae, and inframammary folds. While management primarily targets underlying conditions such as insulin resistance and obesity, patients frequently seek cosmetic improvement of skin lesions. Despite a growing body of literature, no standardized treatment algorithm exists, and comparative efficacy across modalities remains poorly characterized. Our objective was to systematically identify and evaluate treatment modalities for AN and their associated clinical outcomes, including treatment response, adverse events, and patient satisfaction.

Materials and Methods

A PRISMA-compliant systematic search of MEDLINE, Embase, and CENTRAL was conducted and prospectively registered in PROSPERO (CRD420251022803). Studies were eligible if they reported primary data on individuals diagnosed with AN receiving any treatment intervention, regardless of disease severity, treatment history, or comorbid conditions. Eligible study designs included randomized controlled trials, cohort studies, cross-sectional studies, and case series of three or more patients. A total of 3,345 unique articles were identified from the databases, and screened by two independent reviewers with discrepancies being resolved through discussion. Data were extracted on patient demographics, AN clinical features, interventions, and outcomes. Given significant heterogeneity in outcome reporting across studies, responses were harmonized into complete (>75% improvement), partial (25–75% improvement), and no response (<25% improvement), and pooled descriptively by treatment category.

Results

Twenty-four studies enrolling 658 unique patients evaluated topical agents, chemical peels, laser-based therapies, and systemic treatments. Topical retinoids (tretinoin 0.025-0.05%, adapalene 0.1%; 11 studies, n=234) demonstrated an overall response rate of 90.5% (complete 56.7%, partial 33.8%). Urea cream (10-20%; 3 studies, n=79) achieved an overall response rate of 100% (complete 36.7%, partial 63.3%), with 20% concentration demonstrating superior efficacy over 10% in direct comparison (melanin index reduction 22.5% vs 10.7%, p=0.001). Topical salicylic acid (1 study, n=19) achieved an overall response rate of 100% (complete 79.0%, partial 21.0%). Chemical peels including trichloroacetic acid (TCA 15–20%), glycolic acid (35–70%), and salicylic-mandelic acid (10 studies, n=250) yielded an overall response rate of 67.0% (complete 12.32%, partial 54.7%), with TCA consistently outperforming glycolic acid. Fractional CO_2 laser (3 studies, n=63) achieved an overall response rate of 100% (complete 32.5%, partial 67.5%). Intralesional vitamin D3 (1 study, n=30) demonstrated an overall response of 83.3% versus 0% in the saline control arm. Oral insulin sensitizers including metformin and alpha-

lipoic acid combination therapy (1 study, n=41) produced significant improvements in AN severity scores in both arms ($p<0.001$), though patient-level responses were not extractable. Adverse events across all modalities were generally mild and transient, most commonly including erythema, burning, and post-inflammatory hyperpigmentation.

Conclusions

All evaluated modalities demonstrated clinically meaningful response rates for AN. Topicals keratolytics including salicylic acid, urea cream, and retinoids showed the highest overall response rates among topical agents, while fractional CO_2 laser achieved the highest response rates among other modalities. TCA outperformed glycolic acid among chemical peels. These findings are limited by heterogeneity in study design and outcome reporting. Standardized outcome measures and larger controlled trials are needed to establish evidence-based guidelines for AN management.

EA DV CONGRESS
VIENNA
30 SEP - 3 OCT 2026

Abstract N°: 4131

The Skin-Brain Axis: Exploring Neuroinflammation's Role in Dermatological and Neurological Disorders

Alicia Kwan Su Huey*[1, 2], Mert Uzun[2, 3], Karan Choudhary[2, 4], Elaf Abdulnasser Alsaab[2, 5], Aman Singh Sengar[2, 6], Olivier Uwishima[2]

[1] Manchester University NHS Foundation Trust, Greater Manchester, United Kingdom
[2] Department of Research and Education, Oli Health Magazine Organization, Kigali, Rwanda
[3] Karadeniz Technical University, Trabzon, Türkiye
[4] Medscan Diagnostics, Delhi, India
[5] Al Iraqia University School of Medicine, Baghdad, Iraq
[6] Yerevan State Medical University after Mkhitar Heratsi, Yerevan, Armenia

Introduction
The skin–brain axis describes bidirectional neuroimmune communication in which psychological stress alters skin inflammation and, conversely, chronic cutaneous inflammation can influence central nervous system (CNS) function. Psoriasis is increasingly linked to neurodegenerative disease risk, including Alzheimer's disease (AD), through shared inflammatory pathways. This literature review aimed to explore mechanistic links between psoriasis and AD across the skin–brain axis, and summarise emerging diagnostic and therapeutic implications for dermatology.

Materials and Methods
A comprehensive literature search was conducted using PubMed, Google Scholar, ScienceDirect, Scopus, and Web of Science to identify peer-reviewed English-language articles relevant to neuroimmune interactions, psoriasis, Alzheimer's disease, neuroinflammation, immune signalling, biomarkers, and treatment within the skin–brain axis context.

Results
Stress-mediated activation of the hypothalamic-pituitary-adrenal axis and neuropeptides, including corticotropin-releasing hormone, cortisol and substance P, modulate keratinocyte, mast-cell and T-cell activity, amplifying cutaneous inflammation. Circulating cytokines central to psoriasis—IL-17, IL-23, TNF-α and IL-6—are also implicated in Alzheimer's disease-associated neuroinflammation and may contribute to blood–brain barrier dysfunction and downstream microglial and astrocyte activation. Systemic inflammatory burden is further shaped by common comorbidities, including obesity, type 2 diabetes, hypertension and dyslipidaemia, which may accelerate later-life cognitive decline. Therapeutic overlap is emerging: biologic agents targeting TNF-α or IL-17 and agents modulating JAK–STAT signalling may plausibly attenuate inflammatory crosstalk across skin and CNS compartments. Diagnostic innovation includes skin-based detection of pathological tau/amyloid signatures and AI-assisted phenotyping to refine classification and support personalised risk stratification.

Conclusions
The skin–brain axis represents a dynamic neuroimmune interface with shared inflammatory pathways underlying chronic skin and neurodegenerative diseases. Targeting common cytokines offers dual therapeutic potential. Advances in skin biomarkers and AI diagnostics provide new avenues for integrated management. Prospective longitudinal studies are needed to clarify causality, validate clinically actionable skin biomarkers, and determine whether systemic anti-inflammatory treatment modifies long-term cognitive outcomes. Dermatology-led screening for neuropsychiatric symptoms and collaborative care pathways may improve holistic patient

management.

EADV CONGRESS
VIENNA
30 SEP - 3 OCT 2026

Abstract N°: 4150

Skin Deep: Estrogen Deficiency and the Dermatologic Challenges of Menopause

Mary Alice Mina*[1]

[1] Baucom & Mina Derm Surgery, LLC, The Skin Real, LLC, Emory University, Department of Dermatology, Atlanta, United States

Introduction

To examine how estrogen deficiency during menopause contributes to structural and functional skin changes and to evaluate the current and emerging treatment strategies, including topical estrogen-based therapies, that address these cutaneous manifestations.

Materials and Methods

A comprehensive review of peer-reviewed studies and clinical trials assessing the impact of menopause-related hormonal changes on skin physiology. Emphasis was placed on histologic and clinical outcomes associated with estrogen loss, including collagen degradation, impaired barrier function, and dermal thinning. Additionally, the efficacy and limitations of systemic hormone therapy, topical estradiol, and investigational agents such as methyl estradiolpropanoate (MEP) will be analyzed and reviewed.

Results

Menopause leads to a constellation of dermatologic changes driven by declining estrogen levels: increased skin dryness, wrinkling, loss of elasticity and volume, poor wound healing, hair changes, and changes in pigmentation to name a few. These effects stem from diminished estrogenic activity in dermal fibroblasts, keratinocytes, melanocytes and vascular structures. While systemic hormone therapy can offer indirect skin benefits, topical estrogen formulations have shown mixed efficacy, particularly limited impact on facial photoaging in controlled trials. Emerging agents like MEP show promising results, with improvements in hydration, laxity, and dermal tone in postmenopausal women, while minimizing systemic exposure.

Conclusions

Estrogen deficiency during menopause significantly accelerates skin aging and compromises skin health. Recognition of these changes is essential for clinicians treating midlife and postmenopausal women. Although no FDA-approved topical estrogens exist for cosmetic skin use, novel skin-targeted estrogen analogs such as MEP may offer a safe, effective pathway forward. Dermatologists and other healthcare providers should be equipped to identify menopausal skin changes and guide evidence-based, individualized treatment, whether hormonal, procedural, or supportive, to optimize skin health during this life stage.

EA DV CONGRESS
VIENNA
30 SEP - 3 OCT 2026

Abstract N°: 4283

Development and Validation of a Patient Reported Experience Measure (PREM) for interdisciplinary care in immune mediated inflammatory diseases with skin manifestations (skIMIDs)

Ellen Van den Steen*[1], Julie Geens[1], Ornella Sacre[1, 1], Karin Melsens[2], Corinne Evers-Lebrun[2], Eden Pierre[1], Benedicte Manderlier[2], Diederik De Cock[3], Jan Gutermuth[1]

[1] Universitair Ziekenhuis Brussel/ Department of Dermatology, Vrije Universiteit Brussel, Brussels, Belgium

[2] Universitair Ziekenhuis Brussel/ Department of Rheumatology, Brussels, Belgium

[3] Biostatistics and Medical Informatics Research Group, Department of Public Health, Vrije Universiteit Brussel, Brussels, Belgium

Introduction

Immune-mediated inflammatory diseases with skin manifestations (skIMIDs) are chronic multisystem disorders (e.g. connective tissue diseases, such as Lupus/Scleroderma or Psoriatic arthritis) that require long-term immunomodulatory or immunosuppressive treatment and monitoring for side effects. Modern immunomodulatory therapies effectively and safely target multiple organ systems simultaneously, which increases both the need for- and additive benefits of interdisciplinary care (IC). However, today IC remains challenged by fragmented care pathways and limited intermural communication, which often leads to suboptimal outcomes and patient and care provider dissatisfaction. Because treatment adherence and outcomes are influenced by patient's care experiences, patient-reported experience measures (PREMs) are important for evaluating care quality and identifying areas for improvement. Currently, convenient tools to assess IC quality in skIMID care are lacking.

We aimed to create a concise and user-friendly PREM questionnaire for evaluating patient experiences in IC settings for skIMIDs. This PREM shall be developed for routine clinical interactions.

Materials and Methods

Relevant items for the PREM were identified in five steps: (1) based on a systematic literature review, (2) subsequent semi-structured interviews with skIMID-patients, (3) refined during multi-stakeholder focus groups, which consisted of skIMID patients, dermatologists and rheumatologists, (4) item formulated into statements, (5) a first internal validation by means of an e-mail round.

In a next phase, the PREM was evaluated for its reliability and validity in skIMID participants. The reliability was measured by the intraclass correlation coefficient (ICC, in a test-retest set-up) and internal consistency (IC). Construct validity was evaluated by a convergent and a divergent validity test (correlation with a similar but longer questionnaire, the Consumer-Quality-Index/Chronic-Skin-Diseases - CQI-CSD- and a non-related questionnaire, the Marlow Crowne Social Desirability Scale - short form; MCSDS-SF).

Results

15 key items were identified via a systematic literature review, 13 semi-structured patient interviews, and subsequent focus groups. The items cover five domains: access to information, care coordination, access to care, patient-centeredness, and patient satisfaction. These items were converted into 15 statements and one open-ended question. Initial internal validation in 17 skIMID patients confirmed clarity, relevance, and adequate domain

coverage.

The final PREM questionnaire was evaluated in 78 skIMID patients in two centers specialized in systemic skin diseases. Test–retest analysis in 31 participants demonstrated good intra-rater reliability (ICC = 0.83). Internal consistency was excellent (Cronbach's $\alpha = 0.93$), supporting the underlying construct of patient experience. Convergent validity was demonstrated by moderate correlations (~0.5) with corresponding CQI-CSD items, indicating that both instruments assess the construct of patient-perceived quality of care in chronic skin disease. Divergent validity showed a weak correlation with the social desirability scale (MCSDS-SF; $r = -0.3$), confirming that the PREM measures a distinct construct.

Conclusions

The final PREM highlights the importance of patient-centeredness, access to care and information, care coordination, and patient satisfaction in interdisciplinary skIMID management.

The skIMIDs PREM is a reliable and validated instrument for assessing patients' perspectives on care quality and identifying areas for improvement in interdisciplinary care delivery. It's concise format supports use in both routine clinical practice and research, with the aim of improving management processes and healthcare outcomes.

EADV CONGRESS
VIENNA
30 SEP - 3 OCT 2026

Abstract N°: 4298

Clinical Spectrum, Metabolic Abnormalities, and Therapeutic Response in Necrolytic Migratory Erythema like rash due to Chronic Calcific Pancreatitis: A Retrospective Case Series

Akshita Singh*[1], Akash Agarwal[1], Maitreyee Panda[1], Ajaya Jena[1]

[1] Institute of Medical Sciences and SUM Hospital, Siksha ' O ' Anusandhan Deemed University, Bhubaneswar, India

Introduction
Necrolytic migratory erythema (NME) is a cutaneous rash classically associated with glucagonoma as a paraneoplastic manifestation. Its occurrence secondary to chronic calcific pancreatitis (CCP) is exceedingly rare, with limited data regarding its incidence.Owing to its varied morphology and rarity,diagnosis is frequently delayed,resulting in prolonged morbidity and adverse therapeutic outcomes.

Materials and Methods
This single-centre retrospective case series included patients diagnosed with NME secondary to CCP between January 2024-March 2026 at a tertiary care centre in India. Diagnosis of NME was established in each case through clinicopathological and radiological correlation. Demographic characteristics,clinical features,laboratory abnormalities,imaging findings, histopathological features,treatment modalities,and therapeutic outcomes were retrospectively analysed.

Results
Our cohort comprised 3 females and 3 males, with a mean age of 43.8 ± 6.4 years. The mean duration of cutaneous manifestations before diagnosis of CCP was 7.58 ± 8.05 months. A history of chronic alcohol consumption was present in 3/6 (50%) patients.All patients presented with cutaneous eruptions involving the extremities, buttocks, lower abdomen, and intertriginous areas. Other cutaneous manifestations included glossitis and stomatitis in 6/6 (100%) patients, angular cheilitis in 4/6 (66.7%), hair abnormalities in 6/6 (100%), and genital edema in 2/6 (33.3%).Systemic manifestations included diarrhoea in 6/6 (100%) patients, steatorrhea in 5/6 (83.3%), weight loss in 5/6 (83.3%), anemia in 6/6 (100%), and diabetes mellitus in 5/6 (83.3%).

Laboratory evaluation revealed low haemoglobin levels with normocytic normochromic anemia. Serum zinc levels were low ranging from 6.9–10.7 µmol/L, while hypoalbuminemia (1.35–2.35 g/dL) was observed in all patients. Serum amylase levels were predominantly normal or mildly elevated (30–125 IU/L), whereas reduced serum lipase levels (3.6–22 IU/L) were observed in the majority, reflecting pancreatic exocrine insufficiency. Deranged blood sugar was seen in 5/6 (83.3%) patients, with HbA1c levels ranging from 4.8–7.9%.

Histopathological evaluation in 3/6 (50%) patients demonstrated features consistent with NME, while diagnosis in the remaining patients was established clinically. Imaging findings were consistent with CCP in all cases, with alcoholic pancreatitis being the most common etiology. All patients received oral zinc supplementation, vitamin B-complex therapy, and pancreatic enzyme replacement therapy (PERT), along-with antidiabetics . Topical mometasone furoate 0.1% cream and oral antihistamines were added for symptomatic relief.

Cutaneous improvement was assessed by reduction in body surface area (BSA) involvement and resolution of

pruritus. Five of six patients (83.3%) showed >75% reduction in BSA involvement within 4-6 weeks of initiating therapy. Repeat serum zinc levels normalized in 4/6 patients (mean post-therapy zinc 12.3 ± 1.8 µmol/L) while two showed partial correction. Four of six patients subsequently underwent surgical management for CCP.

Conclusions

Pseudoglucagonoma syndrome has been reported in association with cirrhosis, celiac disease, inflammatory bowel disease, chronic pancreatitis, hepatocellular carcinoma, bronchogenic carcinoma and nutritional deficiencies (zinc, essential fatty acids, niacin). Its pathogenesis in CCP is likely driven by the metabolic consequences of pancreatic exocrine insufficiency, zinc deficiency, hypoaminoacidemia, and deficiency of essential fatty acids, all of which disrupt epidermal integrity and trigger necrolytic changes. The improvement in zinc levels correlating with clinical resolution of cutaneous lesions, suggests that correction of zinc deficiency, in combination with PERT, plays a therapeutic role in NME.

Our findings suggest that persistent or recurrent NME with normal glucagon levels, should prompt evaluation for underlying CCP. This facilitates early initiation of treatment and favourable outcome.

EA DV CONGRESS
VIENNA
30 SEP - 3 OCT 2026

Abstract N°: 4345

A Systematic Review of Dermatological Manifestations as the First Sign of Internal Malignancy in Patients Under 40-Re-Evaluating the "Rarity Assumption

Krish Lightwala*[1], Chanul Thennekoon[1], Zeel Lightwala[1]

[1] Belarusian state medical university, Minsk, Belarus

Introduction
The clinical dictum that paraneoplastic dermatoses are vanishingly rare in patients under 40 has never been subjected to systematic scrutiny. This assumption perpetuated through textbooks and clinical teaching creates a dangerous diagnostic blind spot. When an atypical rash in a 25-year-old is dismissed as "just eczema," a window for early cancer detection closes. The objective of this review was to systematically aggregate all published evidence of cutaneous signs functioning as the sentinel presentation of previously undiagnosed internal malignancy in young adults, and to construct an evidence-based, risk-stratified diagnostic checklist.

Materials and Methods
We conducted a systematic review of PubMed, Embase, Web of Science, and the Cochrane Library for publications from January 2000 to March 2026. Search terms combined MeSH headings for "paraneoplastic syndromes," "skin manifestations," "delayed diagnosis," and "adult" with age-specific filters. Inclusion criteria: case reports, case series, and cohort studies documenting a dermatological presentation as the index clinical finding leading to diagnosis of a previously unknown internal malignancy in patients aged 18-40. Exclusion criteria: known cancer diagnosis preceding the skin finding, genetic cancer syndromes, cutaneous metastases from known primary. Two reviewers independently screened 1,847 records. Data extracted included: dermatological morphology, malignancy type, diagnostic interval, and patient outcome. A risk-stratified checklist was developed using frequency analysis and diagnostic delay data.

Results
A total of 312 individual cases from 247 publications met inclusion criteria. The most frequently masked malignancies were: hematological (38.1%, predominantly Hodgkin and non-Hodgkin lymphoma, acute leukemia), gastrointestinal (22.4%, predominantly gastric and colorectal adenocarcinoma), and genitourinary (12.8%, predominantly testicular and ovarian). The most frequently misattributed cutaneous presentations were: acquired ichthyosis (17.9%), paraneoplastic pemphigus (14.1%), erythema gyratum repens (11.5%), atypical vasculitis (10.3%), and acute febrile neutrophilic dermatosis/Sweet syndrome (8.7%). Critically, the mean diagnostic delay from first dermatological presentation to malignancy diagnosis was 5.8 months (range 1-21 months), during which 41.3% of patients progressed by at least one cancer stage. In 67.9% of cases, the initial dermatological consultation did not prompt malignancy screening. The pooled evidence directly contradicts the "rarity assumption": these presentations are individually uncommon but collectively constitute a non-trivial diagnostic signal that is systematically missed.

Conclusions
The "rarity assumption" is a dangerous heuristic that delays cancer diagnosis in young adults by an average of nearly six months. We propose the SENTINEL Checklist a seven-item clinical decision tool that risk-stratifies atypical dermatological presentations in patients under 40 based on morphology, systemic symptoms, treatment refractoriness, and laboratory markers. This tool is designed for non-dermatologist clinicians in primary care and emergency settings. Prospective validation is warranted, but current evidence supports immediate integration into

clinical teaching curricula. The skin truly functions as a sentinel organ; the field must learn to read its signals across all age groups.

EA DV CONGRESS
VIENNA
30 SEP - 3 OCT 2026

Abstract N°: 4354

Evaluating the Outcomes and Effectiveness of a Dermatology–Rheumatology Multidisciplinary Team (MDT) Meeting at a Tertiary Centre in the United Kingdom

Henna Ahmed[1], Shayan Saadat*[1], Fatima Dalal[1], Georgina Fremlin[1]

[1] Queen Elizabeth Hospital Birmingham, University Hospitals Birmingham NHS Trust,, Birmingham, United Kingdom

Introduction

A monthly hour-long dermatology-rheumatology multi-disciplinary team (MDT) meeting was initiated in September 2022. The MDT was attended by consultants from both specialties, resident doctors, clinical nurse specialists (CNS) and students. The meeting provided a platform for each specialty to present patient cases requiring dermatology or rheumatology input for discussion. An audit evaluating the effectiveness of the MDT in 2025 found the meeting to be highly effective, with a reduction in referrals. The quality of advice was rated as "excellent" by participating clinicians.

The initial audit demonstrated improved interdisciplinary collaboration and clinical decision-making for complex cases. There was a reduction in the perception of referrals between specialties and a perceived reduction in GP appointments. Following the success of the initial audit, a re-audit was undertaken to evaluate if the MDT remained beneficial and to quantify the number of appointments and cost-effectiveness of each saved appointment.

Materials and Methods

The objectives included evaluating the type of clinical decision-making that was made through the joint MDT and whether it is still successful. Other important objectives ere to assess the number of outpatient and general practitioner (GP) appointments saved (i.e avoided) as a result of MDT input and by implication evaluate the cost-effectiveness of the service.

We conducted a retrospective observational review of MDT data from February 2025 to February 2026. Data collected from the meetings included clinical themes, reason for referrals, and MDT outcomes. Reasons for referrals were categorised into diagnosis, treatment (initiation or change), and management (including monitoring or investigation). In addition, referring consultants were asked whether they believed that a GP or specialist appointment was saved due to MDT input, providing an estimate of cost-effectiveness.

Results

A total of 100 cases were discussed across 9 MDT meetings. Of these, 41 patients were male and 59 were female. Referrals were from rheumatology (77 cases), dermatology (22 cases) and with 1 case jointly referred.

Reasons for referral included diagnosis (45 cases), treatment decisions (40 cases), and management (15 cases). A range of clinical themes were identified, including psoriasis (n=20), lupus (n=14), rash (n=10), arthritis (n=9), connective tissue disorders (n=4), vasculitis (n=2), facial rash (n=2), hand rash (n=2), lesions (n=2), eosinophilic fasciitis (n=1), other conditions (n=15) and other (n=16)

To evaluate the effectiveness, dermatology and rheumatology consultants retrospectively reviewed a random sample of 23 MDT cases and assessed whether MDT discussion had prevented the need for additional GP or specialist appointments. The results showed that 69.6% of consultants reported that the dermatology-rheumatology MDT resulted in an avoidance of specialist appointments. The success of the MDT even extends to primary care as 65.2% of consultants reported a prevention of a GP appointment.

By projection, assuming a GP appointment costs the NHS £37 and specialist appointment costs £170, from the data collected from consultant reviewing 23 MDT cases it was shown that from 23 cases the MDT saved £555 via saved GP appointments and £2720 via specialist appointment. There is no apparent financial cost of the MDT as it is hosted in clinicians lunch hour. Opportunity cost has not been taken into account.

Conclusions

In conclusion the dermatology-rheumatology MDT improves clinical efficiency and suggests cost-effectiveness by facilitating discussion of complex cases requiring multi-specialty input and reducing GP and specialist outpatient appointments. This long-term may reduce the burden on both primary and secondary care services. Further research should focus on incorporating standardised measures to formally document whether appointments are saved, increasing the number of cases being evaluated by consultants allowing to assess cost-effectiveness on a wider scale

EA DV CONGRESS
VIENNA
30 SEP - 3 OCT 2026

Abstract N°: 4429

Cutaneous manifestations in chronic hemodialysis patients

Safae ELMSAYRYB*[1], chaouche mohammed[1], sokaina chhiti[1], mohamed JABRANE[2], radia chakiri[1]

[1] Department of Dermatology, Mohammed VI University Hospital Center, AGADIR, Morocco

[2] Department of Nephrology and Hemodialysis, Mohammed VI University Hospital Center, agadir, Morocco

Introduction

Patients undergoing hemodialysis are exposed to high morbidity and mortality. This may be related to chronic kidney disease itself, hemodialysis procedures, and/or associated comorbidities. The progression of chronic kidney disease is accompanied by multisystem complications, including dermatological involvement. The prevalence of cutaneous manifestations exceeds 50%, with pruritus being by far the most frequent, affecting 50% to 90% of patients. Indeed, the skin is an external organ whose abnormalities are not only visible but also disabling, causing discomfort and having a significant psychological impact. The aim of our study was to investigate the prevalence and the nature of the different dermatoses in patients undergoing chronic hemodialysis.

Materials and Methods

This was a prospective, descriptive, single-center study including patients undergoing chronic hemodialysis 2 to 3 times per week for at least two months at the Regional Hemodialysis Center of Agadir. The study was conducted over an 11- month period, from January 1, 2025, to November 30, 2025.

Results

We examined 31 patients undergoing chronic hemodialysis at the Regional Hemodialysis Center of Agadir. All patients presented with dermatological manifestations (100%). The study population included 13 men and 18 women, with a male-to-female ratio of 0.72. The mean age was 51 years, ranging from 8 to 84 years. The 60–75-year age group was the most represented, accounting for 25.8% of cases. An atopic background was noted in 17 patients (54.8%). Fourteen patients (45%) had a history of dermatological disease prior to the initiation of hemodialysis. Twenty-seven patients (87%) had known hypertension, 14 patients (45%) had diabetes, 4 patients (12.9%) had congenital uropathy, and 1 patient was being followed for an autoimmune disease (lupus). The mean duration of hemodialysis was 8.9 years (106.8 months). We distinguished between cutaneous manifestations potentially specific to chronic kidney disease and/or hemodialysis itself and those that were non-specific. Among the manifestations that could be considered specific to chronic kidney disease and/or dialysis, xerosis, pruritus, and hyperpigmentation were the most frequent. Xerosis was observed in all patients. Pruritus was the second most frequent cutaneous manifestation, reported in 27 patients (87%). It was persistent in 12 patients (38.7%), and its intensity was severe in 8 patients (25.8%). Assessment of quality of life using the DLQI (Dermatology Life Quality Index) in all patients showed a moderate impact of pruritus on quality of life in 38.7% of cases. The third most frequent cutaneous manifestation was hyperpigmentation, found in 22 patients (71%), predominantly on photo-exposed areas. Diffuse alopecia was observed in 20 patients (64.5%), while ecchymoses were also reported in 20 patients (64.5%). Follicular hyperkeratosis was found in 17 patients (54.8%). Nail involvement in the form of half-and-half nails was present in 11 cases (35.5%), and melanonychia in 8 cases (25.8%). Calciphylaxis was observed in only one female patient. In addition, other potentially non-specific cutaneous manifestations were also recorded: plantar keratosis in 20 patients (64.5%), onychomycosis in 17 patients (54.8%), and dermatophytosis of glabrous skin in 5 cases (16%). Keloid and atrophic scars on the fistula site, seborrheic dermatitis, and guttate hypomelanosis were each found in 4 patients (12.9%). Two cases of infectious folliculitis were identified. Perianal condyloma, pediculosis, secondary infected allergic dermatitis, and stasis dermatitis were

each recorded in 1 case (3.2%).

Conclusions

This study confirms the high prevalence of cutaneous manifestations among chronic hemodialysis patients in a resourcelimited setting. These skin disorders may significantly impair quality of life and have psychological repercussions, underscoring the importance of close collaboration between dermatologists and the hemodialysis team.

EADV CONGRESS
VIENNA
30 SEP - 3 OCT 2026

Abstract N°: 4437

Real-World Outcomes in Psoriatic Arthritis from the Joint Psoriasis–Psoriatic Arthritis Clinic (PPAC)

Eleni Sampatakaki[1], Spiridon Katechis[1], Evangelia Papadavid*[2]

[1] Rheumatology And Clinical Immunology Unit, 4th Department Of Internal Medicine, Attikon University Hospital,, Athens, Greece
[2] 2nd Department of Dermatology and Venereology, National and Kapodistrian University of Athens, Attikon University Hospital,, Athens, Greece

Introduction

Psoriasis (PsO) is a chronic immune-mediated disease affecting approximately 2–3% of the population, with up to 30% of patients developing psoriatic arthritis (PsA).
Early detection and treatment are crucial to prevent permanent joint damage and improve patient outcomes

Materials and Methods

Objectives:

- To evaluate the clinical and demographic characteristics of patients with psoriatic arthritis of the Joint Psoriasis Psoriatic Arthritis Clinic (PPAC) of Attikon University Hospital, the first combined Dermatology – Rheumatology outpatient clinic in Greece.
- To assess treatment outcomes and real-world management strategies in patients with PsA.
- To investigate predictors and correlates of difficult-to-treat (D2T) PsA.

We performed a retrospective observational analysis of patients with psoriatic arthritis attending our clinic between 11/2019 and 04/2026. Data on comorbidities, clinical characteristics, disease activity (DAPSA, BSA) and treatment outcomes were collected and analyzed.

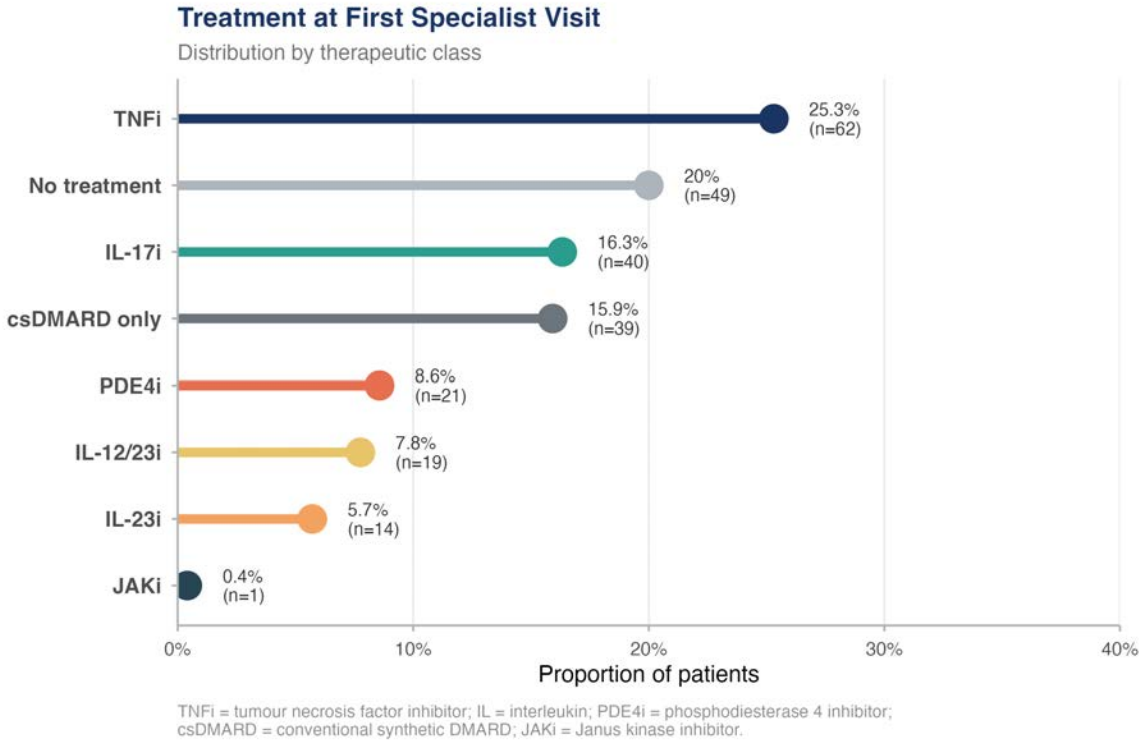

Results

A total of 250 patients were included (63% female; mean age 53 ± 12.8 years).

Regarding PsO phenotype, 44% had onycholysis, 34% scalp psoriasis, and 16% inverse psoriasis. Axial involvement was present in 16%, dactylitis in 20%, and enthesitis in 32%.

In terms of comorbidities, 56% had arterial hypertension, 43% dyslipidemia, 27% type 2 diabetes, 19% depression, and 10% cardiovascular events. Smoking prevalence was 43%. Mean BMI was 23 ± 12.9.

PsA flares occurred in 71% of patients, while 34% experienced at least one psoriasis flare.

Median (IQR) DAPSA and BSA at baseline were 18 (5–34) and 1 (0–4), respectively. Sixty-two patients (20%) were naïve at the time of PsA diagnosis.

Fifty-nine patients were classified as having difficult-to-treat (D2T) disease. These patients had higher baseline disease activity (median DAPSA 32 vs 17, $p<0.001$) and required more bDMARD switches (median 5 vs 1, $p<0.001$).

Significant predictors of the D2T phenotype included depression (OR 4.22, 1.94–9.20), dactylitis (OR 3.08, 1.53–6.21), prior bDMARD use (OR 2.70, 1.34–5.44), and enthesitis (OR 2.06, 1.08–3.90).

Approximately 33% of patients achieved remission and 20% achieved minimal disease activity (MDA; DAPSA <15).

Table 2. Multivariable Logistic Regression: Predictors of D2T Status

| Outcome: Difficult-to-Treat PsA

DAPSA (per 10 units)	**1.35 (1.11-1.65)**	**0.003**
Depression	**5.97 (2.31-15.42)**	**<0.001**
Dactylitis	**3.78 (1.52-9.40)**	**0.004**
Prior bDMARD use	2.34 (0.96-5.71)	0.061
Enthesitis	**2.37 (1.02-5.48)**	**0.044**
BMI (per 5 kg/m2)	1.14 (0.86-1.51)	0.362

OR = odds ratio; CI = confidence interval; bDMARD = biologic disease-modifying antirheumatic drug; BMI = body mass index. Bold rows indicate p < 0.05.

Conclusions

Psoriatic disease is challenging to manage and requires a multidisciplinary approach, early treatment, along with regular, coordinated follow-up to effectively control disease activity.

EA DV CONGRESS
VIENNA
30 SEP - 3 OCT 2026

Abstract N°: 4479

Real-World Impact of a Ceramide and NMF-containing Moisturizer on Clinical Signs of and Quality of Life of Patients with Mature Xerosis

Tara Friel*[1], Duaa Eisa[1], Nada Baalbaki[1]

[1] CeraVe, New York, United States

Introduction
Mature skin is frequently affected by xerosis and pruritus due to alterations in skin barrier function and composition, specifically reduced ceramides and natural moisturizing factors (NMFs). This study evaluated the real-world impact of a moisturizing lotion containing ceramides AP, NP, and EOP and a unique NMF complex, Hydro-Urea, on clinical symptoms of xerosis and patient quality of life (QoL).

Materials and Methods
This global, multicenter, observational study (N=3,077) evaluated the efficacy and tolerance of a ceramide-and NMF-containing lotion in mature patients (≥55 years) with moderate-to-severe xerosis and self-perceived pruritus. Participants were recruited across 14 countries, with the largest cohorts from Greece (38%), Romania (12%), and Brazil (8%). Participants were instructed to apply the moisturizer to the trunk, limbs, and feet as part of their daily regimen: 65% were prescribed twice-daily use and 33% were prescribed once daily use. Clinical assessments were conducted by dermatologists over two visits: baseline and post-treatment. Key exclusion criteria included hypersensitivity to formulation ingredients, history of allergic contact dermatitis to moisturizers, or pre-existing clinical manifestations that could confound objective skin assessments. The primary endpoints included improvements in skin dryness, QoL, and patient satisfaction with the product.

Results
The per-protocol population had a mean age of 56.3 years and was 64% female. All Fitzpatrick types were represented. 43% of patients had active atopic dermatitis lesions, and 51% were taking medications with a side effect of xerosis. 52% were prescribed additional cosmetic products like a cleanser or sunscreen. After 4 weeks of treatment with the ceramide-and NMF-containing lotion, significant reductions were observed in all physician-assessed parameters, including skin dryness (-65%), desquamation/scaling (-77%), roughness (-72%), erythema (-79%), and irritation from scratching (-78%) ($p<0.001$). These clinical improvements translated to QoL benefits with a 79% reduction of impact on sleep and 78% reduction in daily discomfort. Patient assessments also demonstrated significant reductions in itching (-73%) and burning/tingling (-82%). Tolerability was rated as excellent by 83% of physicians and 78% of patients.

Conclusions
The ceramide-and NMF-containing lotion significantly improved clinical signs of xerosis and associated pruritus while achieving high patient satisfaction and improvements in QoL. These improvements underscore its role as an effective management strategy for mature skin barrier maintenance.