EA DV CONGRESS
VIENNA
30 SEP - 3 OCT 2026

Abstract N°: 63

Clinical Efficacy and Safety of Ultrashort-Pulse CO_2 Laser in the Surgical Excision of Ear Keloids

Shady Ibrahim*[1]

[1] Al-Azhar University ,, Cairo, Egypt

Introduction
Earlobe keloids are common fibroproliferative scars that develop following ear piercing or trauma and are associated with significant cosmetic concerns and high recurrence rates after treatment. Conventional surgical excision alone has been associated with recurrence rates ranging from 45% to over 90%. Carbon dioxide (CO_2) laser surgery offers precise tissue ablation with excellent hemostasis; however, conventional continuous or long-pulse modes may produce excessive thermal damage that can stimulate fibroproliferation. Ultrashort-pulse CO_2 laser technology allows highly controlled ablation with minimal collateral thermal injury, potentially improving healing and reducing recurrence.Objective:To evaluate the efficacy and safety of ultrashort-pulse CO_2 laser excision in the management of earlobe keloids and to assess recurrence rates, healing outcomes, and cosmetic results during follow-up.

Materials and Methods
This prospective clinical study included 29 patients with clinically diagnosed earlobe keloids. All lesions were excised using the surgical handpiece of a CO_2 laser operating in H-pulse mode (1–3 W, 50 Hz) under local anesthesia. Layer-by-layer laser excision was performed until normal dermal tissue was reached while preserving surrounding healthy structures. Postoperatively, patients received 3–6 intralesional corticosteroid injections (triamcinolone acetonide diluted with lidocaine) at one-month intervals as adjunctive therapy to reduce recurrence. Patients were followed for 6–12 months to evaluate healing, complications, cosmetic outcomes, and recurrence.

Results
Ultrashort-pulse CO_2 laser excision enabled precise removal of keloid tissue with excellent intraoperative hemostasis and minimal tissue trauma. Postoperative healing was generally satisfactory with favorable cosmetic outcomes. Adjunctive intralesional corticosteroid therapy contributed to effective scar modulation during the healing process. During the follow-up period, most patients demonstrated significant clinical improvement with a low recurrence rate and high patient satisfaction.



A case of Earlobe Keloid was treated with Surgical hand of CO2 laser followed by IL steroid

Conclusions

Ultrashort-pulse CO_2 laser excision using the surgical handpiece represents a precise and effective modality for the management of earlobe keloids. When combined with postoperative intralesional corticosteroid therapy, this approach may reduce recurrence and provide favorable cosmetic outcomes with minimal complications. This technique offers a promising minimally invasive option for the treatment of keloids in cosmetically sensitive areas.



A Csae of Papular Acne Scar was treated with pinhole technique using surgical hand of CO2 laser

EADV CONGRESS
VIENNA
30 SEP - 3 OCT 2026

Abstract N°: 92

Dermatofibrosarcoma protuberans: a 10-year retrospective study on surgical implications and the risk of local and metastatic recurrence

Valentina Celoria*[1]

[1] sant' Andrea hospital, ASL VC Vercelli Italy, Vercelli, italy, Italy

Introduction

Dermatofibrosarcoma protuberans (DFSP) is a rare, slow-growing mesenchymal neoplasm of dermal origin, characterized by locally aggressive clinical behavior. Its metastatic potential is extremely low and is observed mainly in cases exhibiting fibrosarcomatous transformation. The treatment of choice—and the only potentially curative approach—is complete surgical excision with histologically clear margins, usually including the underlying fascia.Despite its locally invasive behavior, DFSP is associated with an excellent prognosis, with 10-year survival rates exceeding 99%.However, local recurrence remains a major concern, particularly in cases with insufficient margins.The purpose of this study is to analyze the main surgical and epidemiological characteristics of DFSP.

Materials and Methods

A retrospective study was conducted on 23 patients diagnosed with dermatofibrosarcoma protuberans (DFSP), including 13 females and 10 males. All patients underwent surgical treatment at the Dermatologic Surgery Unit of our hospital between January 2015 and January 2025. Histopathological confirmation of DFSP was obtained for all cases, with particular attention to the possible presence of a fibrosarcomatous variant, known to be associated with a worse prognosis.Based on the histological outcome of the initial excision, principally with Mohs surgery tecnique, cases showing microscopically positive surgical margins were further analyzed to assess the need for a secondary surgical widening.All patients were followed for a median period of five years after the initial surgery to detect any local recurrence or distant metastasis at the earliest possible stage.

Results

A retrospective study was conducted on 23 patients diagnosed with dermatofibrosarcoma protuberans (DFSP), including 13 females and 10 males. All patients underwent surgical treatment between January 2015 and January 2025.For each patient, demographic data (sex, age), and the date of diagnosis of the primary lesion were recorded.Based on the histological outcome of the initial excision, cases showing microscopically positive surgical margins were further analyzed to assess the need for a secondary surgical widening.
All patients were followed for a median period of five years.Of the total 23 patients, the initial surgical approach consisted of Mohs–Tübingen micrographic surgery in 18 patients (78.26%), allowing for complete intraoperative margin control, while standard wide local excision was performed in 5 patients (21.74%).Among the seven patients (30.4%) who underwent a secondary surgical widening, a lower recurrence rate was observed.Local recurrence occurred in 5 patients, corresponding to a local recurrence rate of 21.74%.The surgical technique employed—Mohs–Tübingen micrographic surgery in 18 patients (78%) versus standard excision in 5 (22%)—significantly influenced recurrence rates, with Mohs surgery associated with lower recurrence risk.

Conclusions

This study presents several limitations that should be acknowledged.First, the limited number of patients.
Mohs micrographic surgery has consistently demonstrated a significant reduction in local recurrence compared to traditional wide excision, reporting local recurrence rates below 2% following Mohs surgery, compared with 10–20% after conventional excision.

Future prospective multicenter studies with larger patient populations and longer follow-up periods will be essential to validate these results and to further clarify the role of adjuvant therapies in improving long-term outcomes.

EA DV CONGRESS
VIENNA
30 SEP - 3 OCT 2026

Abstract N°: 116

Variations and challenges of cutaneous oncological surgery in Morocco

Israe El Ghazouli*[1], Ouiame El Jouari[1], Gallouj Salim[1]

[1] Dermatology department, Mohammed VI Hospital, faculty of medicine and pharmacy- ABdelMALek Essaadi University, Tangier, Morocco

Introduction
Skin cancers are the most common malignancies in adults, with increasing incidence due to aging populations and sun exposure. Surgical excision remains the first-line treatment. In Morocco, malignant skin tumors are a significant public health concern because diagnosis is often delayed and national data are limited.Dermatologists play a central role in the diagnosis and surgical management of skin cancers, guided by established recommendations for melanoma, basal cell carcinoma, and squamous cell carcinoma. As plastic surgeons are less available for superficial skin surgery, the role of dermatologists has become more prominent. This study aims to provide qualitative and quantitative data on this surgical activity.

Materials and Methods
This national cross-sectional study was conducted using an online questionnaire over a six-month period (May–October 2024). Invitations were distributed through national professional associations involved in skin cancer surgery, and only physicians performing wide local excision (WLE) were included. Data on demographics and surgical practices were collected via a Google Forms survey and analyzed using SPSS after transfer from Microsoft Excel.

Results
A total of 156 responses were received, with six excluded because the respondents did not perform wide local excision (WLE). Most participants were dermatologists (81.8%), followed by plastic surgeons (13.3%). The majority were consultants, and most had more than three years of experience. Nearly all respondents reported learning WLE techniques from senior physicians, mainly dermatologists or plastic surgeons.Variations in surgical practice were observed, particularly in incision orientation, consideration of margins from the initial excision, excision depth, and margin measurement. Most surgeons aligned incisions longitudinally or obliquely and marked the skin in a relaxed position.In practice, 71.3% of skin cancer excisions were performed without prior biopsy. One-stage repair was achieved in 92.2% of cases, most commonly by direct closure (83.4%). Complete excision was obtained in 95.2% of cases, with excellent clinicopathological correlation (89.5%). The overall complication rate was low (3%), mainly hematomas, suture failures, edema, infections, vasovagal episodes, and rare necrosis, and was higher in patients receiving antithrombotic therapy.

Conclusions
This study highlights the central role of dermatologists in the surgical management of skin tumors and reflects the growing importance of skin oncology. Variations were observed in how wide local excision (WLE) was planned and performed. Most clinicians learned WLE through mentorship from senior physicians, with limited use of textbooks or videos. The only significant difference between dermatologists and plastic surgeons concerned margin measurement, with dermatologists measuring from the edge of the scar and plastic surgeons more often from the center.Other differences involved consideration of margins from the initial excision, skin tension during marking, and whether incisions were made through, inside, or outside the marked lines. Most clinicians oriented excisions longitudinally or obliquely on the limbs to preserve lymphatic drainage.Previous international studies also confirm

the predominant role of dermatologists in skin cancer surgery, reporting high diagnostic accuracy, high rates of complete excision, and low complication rates. Similarly, our study showed excellent clinicopathological correlation (89.5%) and a high rate of complete excision, supporting the diagnostic and surgical expertise of dermatologists.To our knowledge, this is the first prospective multicenter study evaluating dermatologic surgery activity in Morocco. Despite its limitations, it provides valuable insight and highlights the important role of dermatologists in managing skin tumors in the context of the rising incidence of skin cancer.

EA DV CONGRESS
VIENNA
30 SEP - 3 OCT 2026

Abstract N°: 168

A Decade of Dermatofibrosarcoma Protuberans in Ireland: National Epidemiology and Tertiary Referral Centre Experience

Eimear Duff*[1], Leo Wang[2], Aoibhinn Mooney[1], Benvon Moran[1, 2]

[1] Saint James's Hospital, Dublin, Ireland
[2] Trinity College Dublin, Dublin, Ireland

Introduction

Dermatofibrosarcoma protuberans (DFSP) is a rare, locally aggressive dermal sarcoma with an indolent growth pattern. Although metastasis is uncommon, DFSP carries a high risk of local recurrence. International guidelines recommend micrographically controlled surgery as the treatment of choice.

Materials and Methods

Aims

1. To review national incidence data for DFSP in Ireland.
2. To analyse DFSP management at a tertiary referral skin cancer centre providing a national Mohs micrographic surgery (MMS) service.

Methods

National incidence data were obtained from the National Cancer Registry of Ireland (NCRI) using ICD-O-3 code 8832/3, analysing all cases from 2013–2022. A retrospective review of DFSP cases managed at a tertiary referral centre between 2015 and 2025 was performed using histopathology database records.

Results

NCRI data identified 126 DFSP cases nationally, with a female predominance (60%). Tumours most frequently involved the trunk (48%), followed by the upper limb/shoulder (14%) and lower limb/hip (10%).Thirty-three DFSPs were managed at the tertiary centre.

Patients were aged 23–97 years (mean 43), and 66.7% were female. Prior investigation or treatment elsewhere occurred in 48% of referrals, including excision in another Irish hospital (n=8), biopsy elsewhere (n=4), or excision abroad (n=4; all recurrent DFSP).

At this centre, slow Mohs surgery was performed in 61%, achieving tumour clearance after one layer in 35% and two layers in 60%. Wide local excision was undertaken in 33%, predominantly by plastic surgeons. Mean maximal tumour diameter was 4.8 cm (range 1.2–16 cm).

Conclusions

This is the first presentation of national epidemiological data on DFSP in Ireland. Approximately 25% of national cases were managed at this centre, suggesting possible issues with access to MMS and the need for increased awareness of the use of micrographically controlled excision to completely remove this tumour at initial therapy, where feasible.

EADV CONGRESS
VIENNA
30 SEP - 3 OCT 2026

Abstract N°: 208

Multidisciplinary care pathways and surgical access in epidermolysis bullosa: from perioperative optimisation to system-level integration

Elena Belonogova*[1, 2]

[1] Saint Thomas' Hospital, King's College London, London, United Kingdom
[2] Children of Butterflies Foundation, Moscow, Russia, Moscow, Russian Federation

Introduction
Epidermolysis bullosa (EB) is a severe genetic dermatosis characterised by chronic wounds, systemic inflammation and progressive disability. Reconstructive surgery is often limited due to high perioperative risks, including malnutrition, anaemia and airway fragility. Fragmented care pathways further restrict access to timely multidisciplinary management. There is a need for integrated clinical approaches that combine perioperative optimisation with coordinated care delivery.

Materials and Methods
A multidisciplinary care pathway was implemented integrating paediatric-led perioperative optimisation with dermatology, surgery and anaesthesia coordination. Patients underwent genetic confirmation and were discussed within structured multidisciplinary teams. Optimisation included correction of anaemia, nutritional support, chronic wound management and pain control. Standardised clinical protocols and coordinated decision-making were applied. Fast-track perioperative management was used to minimise hospitalisation.

Results
Thirty-nine children with EB were managed within the pathway, enabling 54 reconstructive procedures, primarily hand and lower-limb interventions. Hospitalisation was reduced to one day for hand surgery and three days for lower-limb procedures. Forty-seven postoperative dressing procedures were performed under anaesthesia. No perioperative complications or mortality were observed.

Conclusions
A multidisciplinary pathway integrating perioperative optimisation with coordinated care can improve surgical access in children with EB. This approach highlights the importance of combining dermatological, surgical and systemic strategies and may represent a transferable model for improving outcomes in complex rare dermatoses.

EADV CONGRESS
VIENNA
30 SEP - 3 OCT 2026

Abstract N°: 298

Oncological Clearance with Enhanced Cosmesis: Flap Surgeries in Basal Cell Carcinoma Management — A Case Series Experience

Diksha Garg*[1], Anuj Bhatnagar[1], Choudhary Sampoorna Raj[1]

[1] Armed Forces Medical College, Pune, India

Introduction

Basal Cell Carcinoma (BCC) is predominantly managed through wide local excision followed by closure or grafting. Flap surgeries, traditionally considered for defect closure post-excision, are being increasingly utilised as a primary reconstructive approach, ensuring tumour clearance and superior cosmetic results.

Case Presentation

Case 1- A 58-year-old female with a BCC on the left cheek, reconstructed with a rhomboid (Limberg) flap, utilizing adjacent lax skin for tension-free closure and minimal distortion.

Case 2- A 48-year-old female with a BCC below right eye, where a rotational flap was designed to redistribute tension and better cosmesis.

Case 3- A 55 year old female with a BCC on the back, reconstructed with a rhomboid (Limberg) flap, utilizing adjacent lax skin for tension-free closure and minimal distortion.

Case 4- A 55-year-old male with a BCC on the left temporal region, managed using a V-Y advancement flap, achieving a scar with excellent tissue match.

In all cases, margins were confirmed negative on histopathology. Postoperative follow-up ranged from 3 to 6 months with no recurrences or major complications. Aesthetic outcomes were rated as excellent by both patients and independent evaluators.Neither recurrence nor any newly-developed lesions were reported during follow-up in any patient.

Conclusion

Local flap surgeries can serve not only as reconstructive tools but as primary definitive management for select BCC cases. They offer a single-stage solution ensuring complete excision, functional preservation, and superior cosmetic outcomes, challenging the paradigm of traditional wide excision. Ideal areas for tissue recruitment should be chosen, based on the size of defect and surrounding tissue mobility.

EADV CONGRESS
VIENNA
30 SEP - 3 OCT 2026

Abstract N°: 428

Combined transposition flap plasty with split-thickness skin grafting for defect coverage of the scalp with exposed calvaria

Marie-Luise Schiffmann*[1]

[1] Fachklinik Hornheide, Münster, Germany

Introduction

Smaller scalp defects can be closed effectively using local flap techniques. Larger defects pose a surgical challenge, especially when the galea is involved. Small local flaps do not provide sufficient tissue, and a split-thickness skin graft will not take in the absence of the galea. For this reason, excisional defects with exposed calvaria represent a particular challenge in wound management. Open wound healing with granulation from the lateral wound margins requires several months to achieve a satisfactory result. During this period, the risk of infection is increased. In addition, there is a risk of the bone drying out, leading to failure of secondary wound healing. If this occurs, refreshing the bone by drilling becomes necessary; however, this can only be performed under general anesthesia, which is often limited or not feasible in patients affected by large tumors of the scalp.

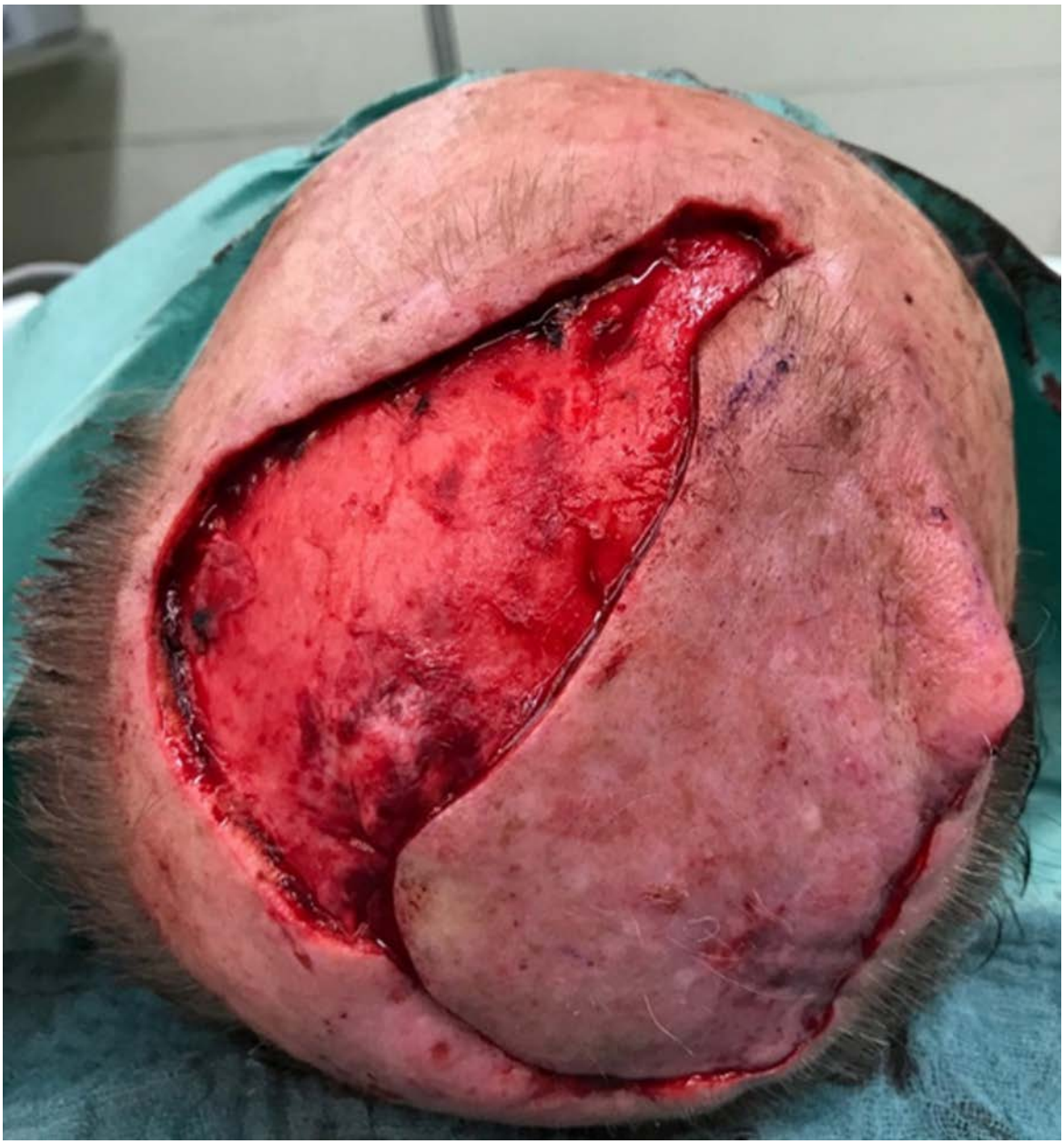

Figure 1: Intraoperative image after transposition of the flap with donor-site defect

Case Presentation

The figures show the case of a 68-year-old patient with an ulcerated squamous cell carcinoma of the scalp. After complete excision of the tumor with histologically controlled margins, the patient was left with a 10 × 10 cm defect of the scalp. We discussed defect closure with the patient using a transposition flap combined with split-thickness skin grafting. After marking the incision lines of the transposition flap, the flap is incised and mobilized. The flap can then be transposed to cover the defect. The resulting donor-site defect is measured, and the split-thickness skin graft is harvested. Closure of the donor-site defect is then performed using the split-thickness skin graft. Two months postoperatively, the flap showed good integration and the split-thickness skin graft was viable. However, a recurrence was noted during clinical follow-up, making renewed radical surgery necessary. Defect closure was again performed using a combined transposition flap plasty with split-thickness skin grafting. In this case as well, good integration of both the flap and the split-thickness skin graft was observed during follow-up.



Figure 2: Postoperative result after split-thickness skin graft and 2 months after surgery; incidentally, a recurrence of PEC is observed

Conclusion

In cases of exposed calvaria without galea, transposition flap plasty followed by split-thickness skin grafting of the donor-site defect represents a good and rapid treatment option. For the patient, this procedure offers many advantages compared with the relatively long granulation phase required for excisional defects prior to graft coverage. In most cases, the operation can be performed under local anesthesia.



Figure 3: Repeat combined transposition flap procedure, postoperative result on the day of surgery and 2 months after surgery

EA DV CONGRESS
VIENNA
30 SEP - 3 OCT 2026

Abstract N°: 475

The use of hybrid fillers successfully in the treatment of Parry Romberg Syndrome and En Coup De Sabre

Hagar El Sayed Abdelghani Anter*[1], Mohammad El Darouti[1]

[1] Kasralainy school of medicine, Cairo University, Egypt, Cairo, Egypt

Introduction

•Parry-Romberg syndrome (PRS) is an uncommon variant of morphea characterized by a slowly progressive hemifacial atrophy that can involve the skin, subcutaneous tissues, muscles, and under-lying bony structures. Clinical and radiographic evidence of underlying central nervous systemic involvement is also frequent in PRS (1).•In some cases, the first symptom represents morphea en coup de sabre, a unilateral frontal or frontoparietal impression of skin and underlying tissues, with scarring of the dermis. The condition is associated with psychological and social drawbacks (2).•Treatment for Parry-Romberg syndrome can be challenging with methotrexate being the most used medication for active disease. The major aesthetic goal of treatment for patients with PRS is the restoration of facial contour and symmetry (3).



Fig (3): (A) Before, (B) 2 weeks after the last session, (C) After 6 months

Case Presentation

Case 1:An 18-year-old female with PRS that progressed through the years since childhood, no neurological symptoms were detected. She was treated with steroids and methotrexate for 4 years and her disease became stable for more than 1 year.She presented with right hemifacial atrophy involving the right frontal, temporomalar area pre-auricular area extending to the right side of the jaw, the upper lip with enophthalmos. Also, the left frontal area was slightly affected. She had affection of the skin, subcutaneous fat and bones.She was treated with 4 ml hyaluronic acid filler over 2 sessions (AMMI crystal for the cheek and mandible, hydra for the frontal area and aqua for the lip), and 5 ml of polylactic acid (Sculptra) was used all over the areas except the lip in a separate session.The photos shows the result after treatment with much improvement and a photo sent by the patient after 1.5 years (as she travelled) with maintained result (Figure 1).

Case 2:A 20 year old male with en coup de Sabre since childhood , he received systemic treatment few years ago with steroids and methotrexate that was stopped 1 year ago with disease stability.He presented by right frontal skin atrophy and hyperpigmentation •He was treated with 4 ml of double diluted combined HA and PLA (Rich) over 2 sessions.•The photos show marked improvement after the sessions and 6 months later in a photo sent by the patient (Figure 2).

Case 3:•A 44-year-old female with 20-year history of en coup de Sabre and deep morphea of both arms, she is on active systemic treatment with steroids and methotrexate with stability of her condition. She has anxiety and depression owing to her condition.•She presented with midline forehead skin and subcutaneous tissue atrophy and hyperpigmentation.• She was treated with 4 ml of double diluted combined HA and PLLA (Rich) over 2 sessions.•The photos show marked improvement after the sessions and 6 months later (Figure 3).







Conclusion

•Hybrid fillers can be a good option in treating PRS and En coup de Sabre both to restore volume loss and

stimulate new collagen formation to keep the results, with good knowledge of the anatomy in professional hands.

EADV CONGRESS
VIENNA
30 SEP - 3 OCT 2026

Abstract N°: 712

COMPARATIVE STUDY OF SAFETY AND EFFICACY OF INTRALESIONAL BLEOMYCIN VERSUS CRYOTHERAPY IN THE MANAGEMENT OF VIRAL WARTS

Swagota Sen*[1]

[1] Department of Dermatology & Venereology, Combined Military Hospital (CMH), Dhaka Cantonment, Dhaka, Bangladesh, Dhaka, Bangladesh

Introduction

Background: Viral warts are among the most common dermatological conditions, with presentations ranging from single self-limiting lesions to multiple recalcitrant warts. Intralesional bleomycin has shown promising results in difficult-to-treat lesions, while cryotherapy remains a widely used conventional modality.

Objective: To compare the efficacy and safety of intralesional bleomycin with cryotherapy in reducing the number and size of viral warts.

Case Presentation

Methods: This comparative study was conducted at the Department of Dermatology and Venereology, CMH Dhaka, involving 124 clinically diagnosed wart patients. Participants were divided into two equal groups (n=62 each): Group A received intralesional bleomycin, and Group B underwent cryotherapy at two-week intervals for up to four weeks. Follow-up evaluations were performed every two weeks, with a final assessment at 12 weeks post-treatment. Data analysis was performed using SPSS (v26). A p-value ≤0.05 was considered statistically significant.
Results: Baseline demographic and clinical characteristics showed no significant differences between groups. Group A demonstrated significantly higher excellent response rates (53.2%) compared to Group B (19.4%) (p=0.001). Side effects—including burning sensation, pain, blistering, dyspigmentation, and skin atrophy—were markedly more frequent in Group B (p<0.001). Persistent adverse effects were also significantly lower in Group A. Recurrence was significantly reduced in the bleomycin group (4.8%) compared to cryotherapy (21.0%) (p=0.007).

Conclusion

Conclusion: Intralesional bleomycin is superior to cryotherapy in both efficacy and safety for treating viral warts. It offers higher clearance, fewer adverse effects, and a lower recurrence rate, making it a preferable therapeutic option.

Key words: Intralesional bleomycin, Cryotherapy, Viral warts, Safety, Efficacy, Recurrence
Contact Details: senswagota63@gmail.com | Phone: +8801761292711

EA DV CONGRESS
VIENNA
30 SEP - 3 OCT 2026

Abstract N°: 731

Reconstruction of Adjacent Cutaneous Defects Using Interdependent Burow's Flaps: A Case Report

Luiz Roberto Dal Bem Pires Júnior*[1], Isabella Motta[1], Hamilton Stolf[1], Thaís Buffo[1]

[1] Hospital das Clínicas da Unicamp, Campinas, Brazil

Introduction

Patients with cutaneous neoplasms are at increased risk of developing new lesions over time, making the need for concomitant or sequential treatment of adjacent skin cancers a common scenario in dermatologic surgery [1].In certain cases, two adjacent lesions may be positioned at a distance that precludes simultaneous excision using a conventional elliptical incision and complicates closure due to excessive tension and limited tissue mobility. In such situations, interdependent Burow's advancement flaps represent an appropriate technical alternative.The Burow's flap is based on converting the surgical defect into a triangle, followed by an incision extending its base, allowing unidirectional tissue advancement. This variation can be interpreted as a modification in which the secondary triangle incorporates one of the lesions to be excised [2]. The transposition movement creates a standing cone deformity that is corrected by excising a similarly sized inverted triangle. After careful undermining of adjacent tissue, simultaneous closure of both triangles is achieved, resulting in a well-oriented linear scar [3,4]. This strategy is advantageous in reconstructing defects following excision of adjacent lesions, as it enables redistribution of tension and preservation of local anatomical integrity.

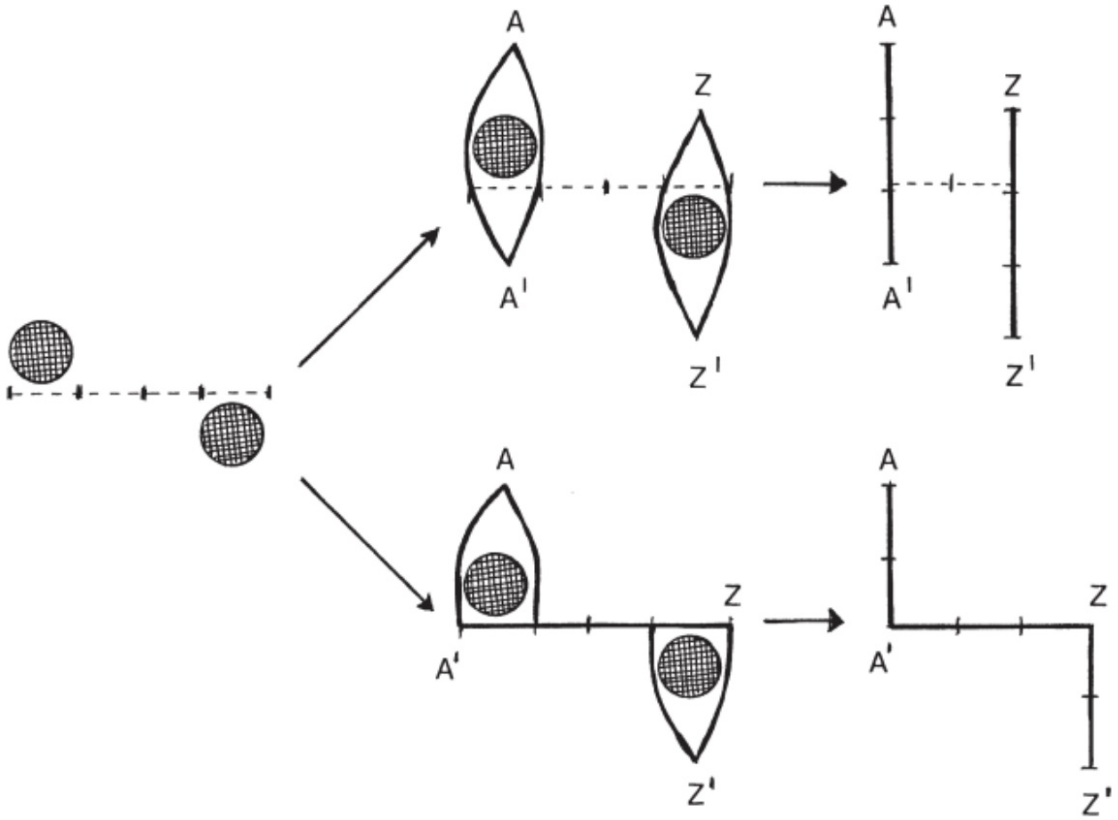

Interdependent Burow's flaps: adjacent defects are converted into triangles, allowing reciprocal advancement and tension-free linear closure.

Case Presentation

A 77-year-old man with a history of multiple squamous cell carcinomas (SCC) and basal cell carcinomas (BCC) presented with two adjacent cutaneous lesions on the right hemiface. Incisional biopsy confirmed BCC (right malar region) and SCC (right preauricular region).Conventional surgical excision was performed with 4 mm margins. Reconstruction was achieved using interdependent Burow's flaps, in which each surgical defect served as a compensatory triangle for advancement of the adjacent defect. After careful subdermal undermining, the flaps were advanced in opposite directions, achieving tension-free primary closure while preserving the facial contour.Layered closure was performed using 4-0 Monocryl for the subdermal plane and 5-0 Nylon for the skin. The postoperative course was uneventful, with good healing and satisfactory aesthetic outcome. Histopathological examination confirmed clear margins in both specimens.

Conclusion

The Burow's flap is based on the creation of triangular flaps at the margins of the surgical defect, which are advanced toward the center, allowing primary closure with excellent match in color, texture, and thickness between the flap and the recipient site [2,5].The main advantage of this approach is the ability to treat multiple adjacent lesions in a single surgical procedure. The use of two opposing triangular flaps redistributes tension forces and enables closure of both defects with minimal distortion of adjacent structures, reducing the risk of dehiscence and unfavorable scarring [1,5].Modifications in triangle design may be implemented to adapt the technique to multiple or contiguous defects, as described in nasal and lip reconstructions, where the geometric versatility of the flap allows precise restoration of anatomical contours [1,4,6].Additionally, the Burow's flap can be combined with other local flaps, expanding its applicability in more complex defects or in areas with limited tissue mobility. Respect for skin tension lines and regional anatomical architecture is essential for surgical success. This technique is simple, safe, and reproducible, can be performed under local anesthesia, and provides highly satisfactory aesthetic and functional outcomes [2,3].In summary, the Burow's flap represents a versatile, efficient, and anatomically conservative solution for cutaneous reconstruction following excision of adjacent lesions, particularly in facial areas, enabling direct closure, harmonious aesthetic integration, and preservation of anatomical structures [1].

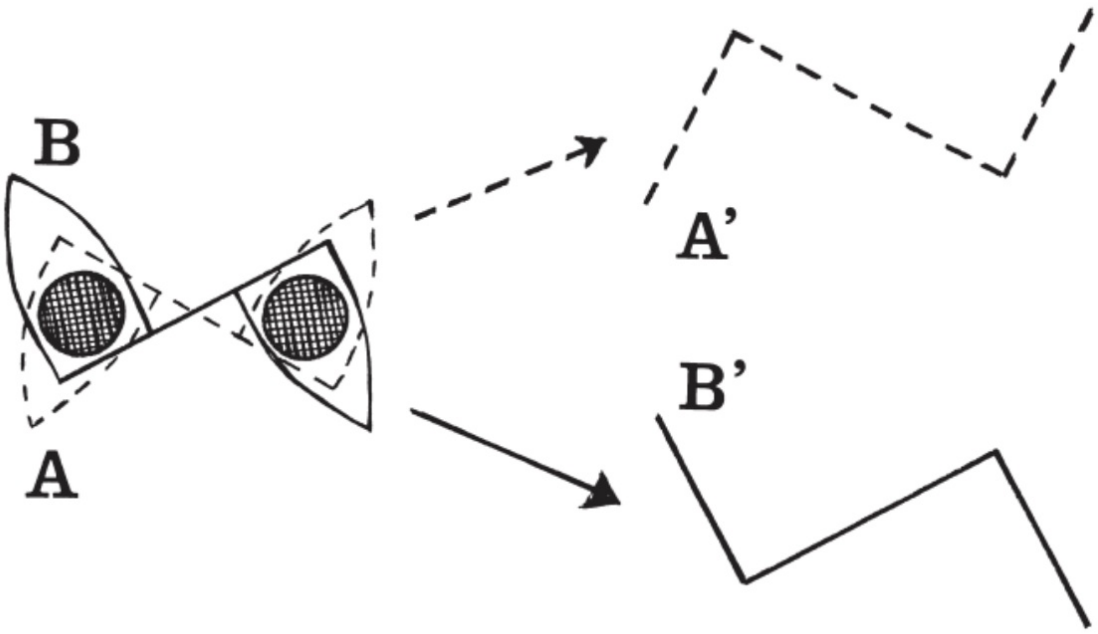

Opposing Burow's triangles enable tissue advancement and defect closure with minimal distortion of adjacent structures.

EADV CONGRESS
VIENNA
30 SEP - 3 OCT 2026

Abstract N°: 732

Viability of a Paramedian Forehead Flap After Postoperative Run-Over Trauma

Luiz Roberto Dal Bem Pires Júnior*[1], Isabella Motta[1], Thaís Buffo[1]

[1] Hospital das Clínicas da Unicamp, Campinas, Brazil

Introduction

The interpolated paramedian forehead flap is a reference reconstructive technique for extensive nasal defects. It stands out for its exceptional vascular robustness and low complication rates, with partial necrosis occurring in only 2.3% and total necrosis in 0.6% [1,2]. The flap's redundant vascularization, supported by multiple arterial sources and an extensive subdermal plexus, provides remarkable resilience even under adverse conditions [2,3,4].The present report describes a unique case of favorable evolution of a paramedian forehead flap that sustained mechanical trauma from a run-over accident on the 13th postoperative day, demonstrating the flap's extraordinary vascular resilience.

Case Presentation

A 69-year-old man underwent Mohs micrographic surgery for the treatment of an extensive basal cell carcinoma involving the nasal ala, dorsum, left nasal sidewall, and medial malar region. Reconstruction of the resulting defect was performed using an interpolated paramedian forehead flap.On the 13th postoperative day, the patient was involved in a motorcycle run-over accident. On evaluation, he presented abrasions associated with dehiscence in the frontal region secondary to trauma. He was referred for emergency care evaluation, and no major injuries were identified.Pedicle division and flap refinement were performed on the 26th postoperative day without complications. The patient achieved an excellent aesthetic and functional outcome, maintaining a high degree of satisfaction throughout follow-up.

Conclusion

The choice of the paramedian forehead flap for reconstruction of complex defects involving multiple nasal subunits is based on its exceptional vascular anatomy.Reece et al., in a dynamic anatomical study using three-dimensional angiography, demonstrated the presence of a robust periorbital plexus extending up to 7 mm above the orbital rim, where the angular, supratrochlear, and supraorbital arteries communicate through an extensive vascular network [2]. Crucially, the deep branch of the supratrochlear artery ascends along the periosteum beneath the flap, while the subdermal plexus of the forehead is sufficiently robust to allow retrograde filling of noncontiguous vessels in the distal portion of the flap [2]. This vascular redundancy explains the flap's ability to tolerate vascular insults and mechanical trauma.Notably, microanatomical studies have shown that the paramedian forehead flap does not depend exclusively on the supratrochlear artery. Stigall et al. demonstrated that forehead flaps designed along the glabellar midline, without Doppler identification of the supratrochlear artery, contained more arteries in their pedicles than Doppler-based flaps ($p < 0.05$), with a predominance of small-caliber arteries [3].The run-over trauma on the 13th postoperative day represents an extreme test of the vascular robustness of the paramedian forehead flap, as it corresponds to the intermediate phase of neovascularization, when circulation through the pedicle remains predominant, but revascularization from the recipient bed is already underway [5].This case illustrates that the paramedian forehead flap, when properly planned with preservation of the vascular pedicle and meticulous surgical technique, has sufficient vascular reserve to withstand adverse events during the maturation period. The vascular redundancy provided by the periorbital plexus, anastomoses between multiple facial arteries, a robust subdermal plexus, and multiple small arteries within the pedicle confers remarkable resilience to the flap [2,3,4].

EADV CONGRESS
VIENNA
30 SEP - 3 OCT 2026

Abstract N°: 825

Utilizing Margin Control for a Technically Challenging Melanoma in Situ Case of an Acral Surface

Dimitra Xenopoulou*[1], Nyousha Yousefi[1], Daniel Siegel[1], Jessica Feig[1]

[1] SUNY Downstate Health Sciences University, Brooklyn, United States

Introduction

Melanoma is a highly aggressive skin cancer with significant metastatic potential. Standard treatment involves wide local excision (WLE) with clear margins; however, in anatomically challenging areas where tissue preservation is critical, alternatives may be warranted. Peripheral Margin-Controlled Excision (PMCE), used in non-melanoma skin cancers (NMSCs) such as basal and squamous cell carcinoma, maximizes margin clearance while minimizing tissue loss. PMCE involves excising peripheral margins while leaving the central tumor intact, enabling precise histologic analysis and tissue preservation. While Mohs micrographic surgery (MMS) offers tissue-sparing benefits, it is time-intensive, costly, and less optimal for melanoma due to melanocyte degradation during frozen section processing. We present a novel use of PMCE to treat melanoma in situ (MIS) on the left lateral heel—an acral, convex, weight-bearing site where functional and cosmetic outcomes are crucial. This case demonstrates PMCE as a viable method for melanoma in sensitive locations, offering oncologic safety and tissue conservation.

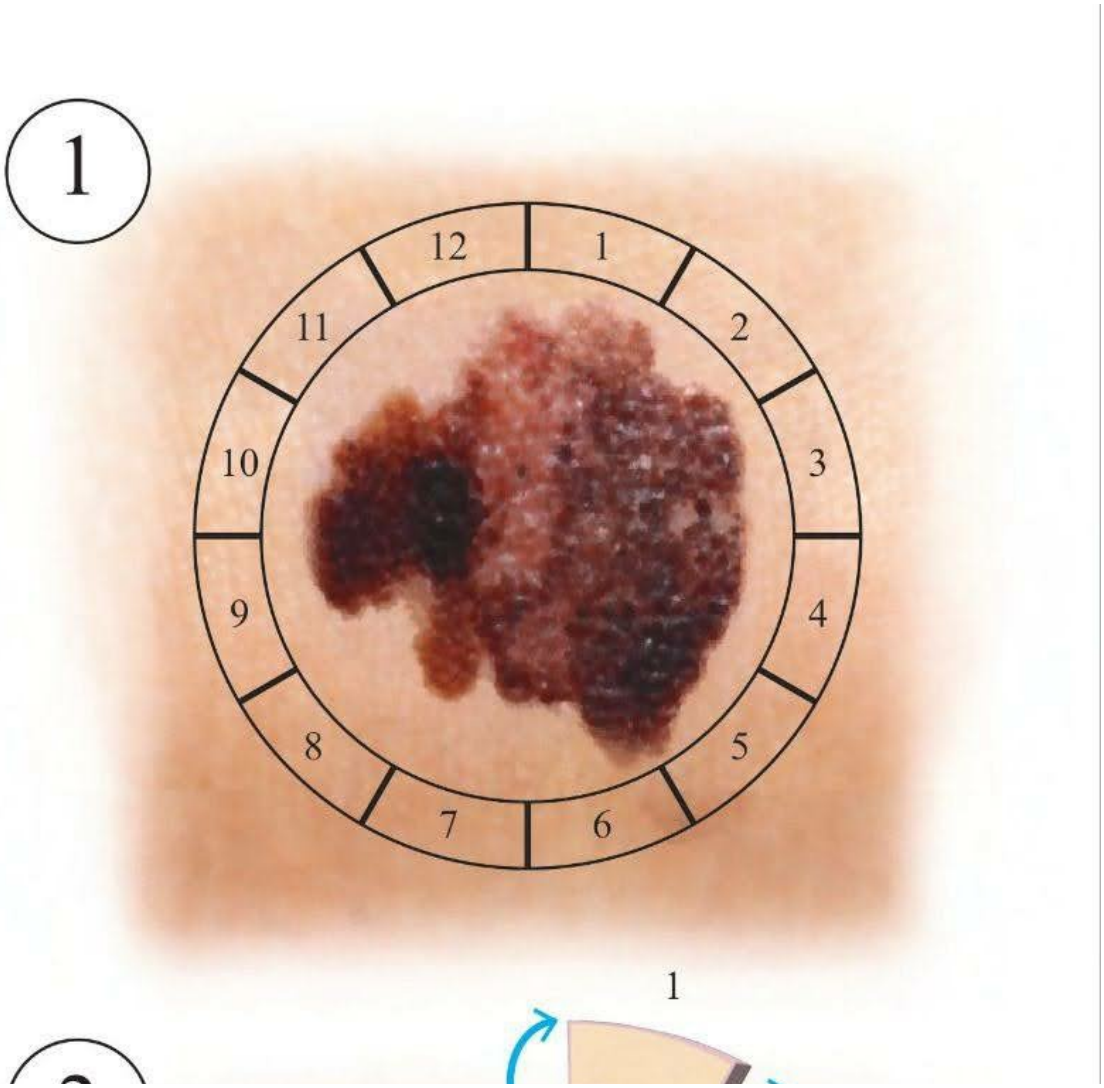

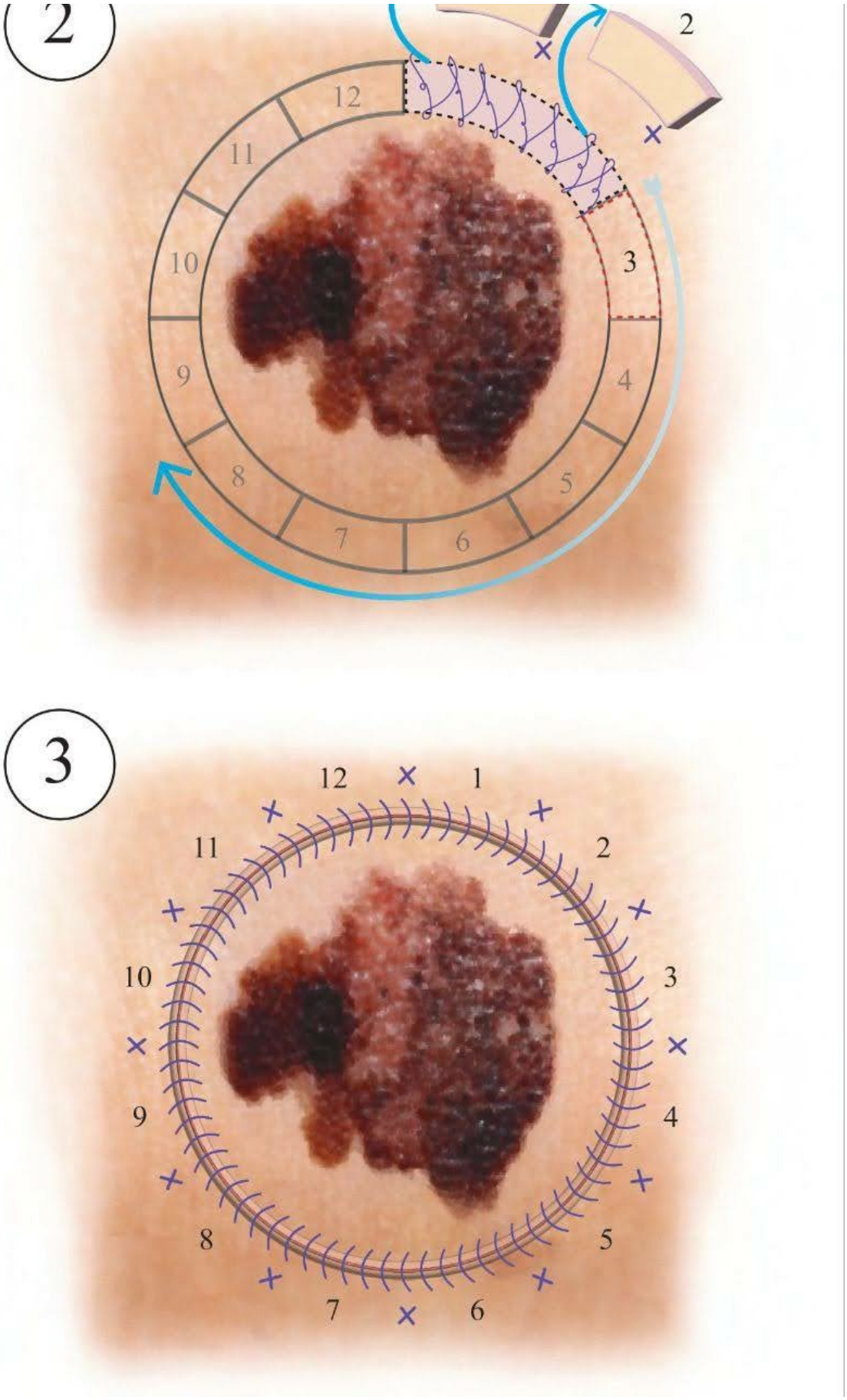

Figure 1. mock up of technique approach

Case Presentation

A 92-year-old male with a history of multiple NMSCs presented with a 5.3 × 5.2 cm pigmented lesion on the left lateral heel (Figure 1.1). It had been enlarging with irregular borders and color variation. Incisional biopsies

confirmed melanoma in situ, superficial spreading type. Due to the lesion's size, convex location, and limited skin laxity, PMCE was chosen to optimize clearance while preserving function and minimizing healing time.Clinical borders were delineated with Wood’s lamp. A 10 mm margin was marked circumferentially, dividing the area into 12 mapped sections (Figure 1.1). Tumescent anesthesia (50 cc lidocaine 1% with epinephrine 1:100,000) was used for hemostasis and to elevate the surgical plane. Each section was excised sequentially using a #10 blade, marked with notches and orientation sutures (Figure 1.2). Simultaneous wound closure was initiated with 4-0 Nylon in a running fashion to manage tension (Figure 1.3). The central tumor was preserved as a biological dressing while awaiting pathology. Excised tissues were mapped and color-coded for orientation, placed on cardboard to minimize contraction, and submitted in formalin. The pathology team was instructed to perform en face longitudinal sectioning along the axis adjacent to the cardboard for accurate margin assessment. Initial pathology revealed two positive margins and two sections with incomplete epidermis due to tissue loss during processing. At follow-up, a second-stage 5 mm re-excision was performed in the previously marked areas. Orientation sutures facilitated accurate resection.Histology confirmed negative margins after the second stage. The central lesion was then excised, and reconstruction employed a subcuticular purse-string technique to reduce wound size and control bleeding. The site was dressed with a dehydrated human amnion/chorion allograft and a fenestrated xenograft, followed by non-adherent dressing, gauze, and layered compression. The patient was followed weekly for dressing changes and xenograft reapplication. Mild granulation tissue was managed with silver nitrate. No functional deficits were noted, and at 3-month follow-up, there was no recurrence or residual melanoma (Picture 1.8).

Conclusion

We demonstrate the effective use of PMCE in treating melanoma in situ at a challenging acral site. PMCE allowed for precise margin control, minimal tissue loss, and functional preservation in this high-tension, weight-bearing area. While MMS is often limited by procedural complexity and the need for specialized histologic techniques, and WLE can be overly aggressive in sensitive areas, PMCE offers a tailored approach that may expand the surgical toolbox for select melanoma cases. While further studies are warranted to validate the broader use of PMCE for melanoma, this case adds to the growing evidence supporting its role in functionally considerate melanoma management.

EADV CONGRESS
VIENNA
30 SEP - 3 OCT 2026

Abstract N°: 847

Basic and clinical study of the effect of exogenous hyaluronic acid on the quality of acellular dermal matrix combined with thin intermediate split thickness skin graft

Fuhuan Chen*[1]

[1] Plastic Surgery Hospital, Chinese Academy of Medical Sciences, beijing, China

Introduction
Skin grafts are commonly used to repair full-thickness skin defects following burn contracture release, large tumor excision, breast cancer surgery, and other injuries. While thick or full-thickness skin grafts offer superior dermal content and lower scar recurrence risk, they are often associated with secondary hypertrophic scarring and delayed healing—limiting their clinical utility. Acellular dermal matrix (ADM), a non-immunogenic scaffold devoid of epidermal and dermal cells, has emerged as a key adjunct in composite skin grafting. Since its introduction, ADM has supported fibroblast proliferation, neovascularization, and neodermis formation—acting as a structural and biological bridge for regeneration. Unlike prior multi-stage approaches, our method achieves composite grafting in a single procedure: combining thin intermediate-split-thickness skin (TS) with ADM yields excellent recipient-site outcomes while reducing donor-site morbidity and scarring compared to conventional TS alone.Despite promising early results, ADM-based composite grafts frequently undergo late contraction at the recipient site. One plausible mechanism is the marked depletion of hyaluronic acid (HA) during ADM decellularization—where extracellular matrix mucopolysaccharides (including HA) are inevitably removed. HA plays critical roles in wound healing: it exerts anti-inflammatory effects, modulates collagen synthesis, and promotes scarless regeneration—as observed in fetal skin. Therefore, supplementing exogenous HA during ADM composite grafting represents a rational strategy to regulate collagen deposition, suppress scar formation, and mitigate graft contracture.This study systematically investigates whether exogenous HA enhances the quality of ADM–TS composite grafts. Using integrated animal and clinical models, we assess its impact on: (1) biomechanical properties (e.g., elasticity, tensile strength); (2) graft contracture rate; (3) microvessel density (MVD); (4) HA content; and (5) expression of type I and type III collagen—key determinants of structural integrity and functional recovery.

Materials and Methods
This study contains animal and clinical experiments. 50 Japanese big ear rabbits were separated into HA1, HA2, PADM, TS, and NS groups. Clinical part included 50 scar patients dividing into 5 groups (TS + HA + ADM 1, TS + ADM2, TS, TS+ADM and normal skin (NS)).

Results
In the animal trial, after 56 days, the grafts contracted least in the HA2 group; HA2 had the highest microvascular density (MVD), HA concentration, and collagen I and III expression. In clinical work, ADM > HA + ADM2 > HA + ADM1 > TS > NS; Type I and III collagen: HA + ADM1 and HA + ADM2 were higher than ADM; HA content: TS>HA + ADM1>HA + ADM 2>ADM.

Conclusions
ADM, exogenous hyaluronic acid mixed with thin skin autograft has better biomechanical qualities and therapeutic impact than acellular dermal matrix alone, and the reconstructive result is near to self-thick skin autograft in all indexes.

EA DV CONGRESS
VIENNA
30 SEP - 3 OCT 2026

Abstract N°: 894

Impact of local anesthesia on preoperative margin assessment of basal cell carcinoma using optical coherence tomography compared to histology in micrographic surgery: a prospective study

Aneta Kolar*[1, 2], Anna Duswald[1], Thomas Volz[1]

[1] Department of Dermatology and Allergology, Technical University of Munich, Munich, Germany
[2] TUM School of Medicine and Health, Technical University of Munich, Munich, Germany

Introduction

Micrographic surgery is the standard of care for basal cell carcinoma (BCC) in the facial region. However, it can require stages of re-excision. Optical coherence tomography (OCT) enables non-invasive preoperative margin assessment and may reduce the rate of re-excision, but remains under investigation. The aim of this study is to assess the impact of preoperatively injected local/tumescent local anesthesia (LA) on OCT image interpretation, which has not yet been evaluated.

Materials and Methods

Preoperatively, 51 clinically diagnosed or biopsy-proven BCC were marked with a clinically defined safety margin and imaged in sections using OCT along the entire margin. Image series of the same margin sections of a lesion were acquired both before and after injection of LA. Micrographic surgery was performed along the same markings. The OCT images were reviewed offline in a blinded manner by two independent investigators (an expert and a novice) to assess for subclinical tumor spread beyond the surgical margin. Findings of histopathology and OCT for both without and with LA were compared to determine the accuracy of OCT in predicting the residual status.

Fig. 1

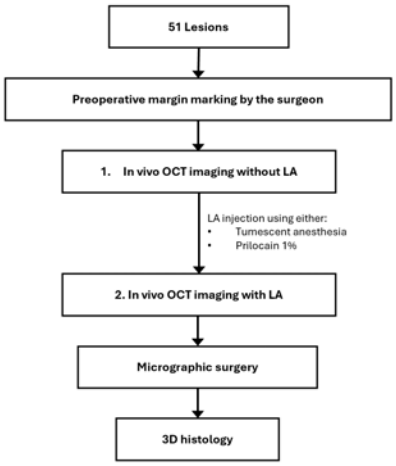

Fig. 2

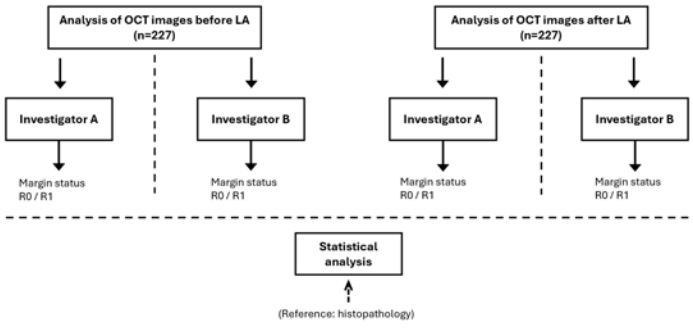

Figure 1: Timeline of the study. Figure 2: Procedure of blinded OCT analysis. During analysis of OCT images, there was no knowledge of histologic findings or of findings reported by the other investigator.

Results

A total of 47 BCC were included, which were analyzed in 227 OCT image sections. The overall accuracy of the

expert investigator was 96,9% (220/227) for images without LA and 94,7% (215/227) with LA (vs. histology). Sensitivity was 82.6% without and 73.9% with LA (p=0.69), and specificity was 98.5% and 97.1% (p=0.38), respectively. For sclerodermiform BCC, sensitivity decreased to 33.3% with LA (vs. 83,3% without LA). In univariate regression analysis of findings with LA, an odds ratio of 0.14 (95% confidence interval 0.03–0.71, p=0.02) was observed for sclerodermiform BCC (vs. nodular). Both investigators achieved an agreement rate of 84,1% for images without LA and 86,3% with LA.

Table 1

Variable	n	in %
Sex		
Male	22	51,2
Female	21	48,8
Age	in years	
Mean	73,5	
Standard deviation	14,3	
Minimum	37	
25th percentile	63	
Median	75	
75th percentile	85	
Maximum	101	
Tumor thickness	in mm	
Mean	1,9	
Standard deviation	1,2	
Minimum	0,2	
25th percentile	1	
Median	1,5	
75th percentile	3	
Maximum	5	
Previous surgery		
No	36	76,6
Yes	11	23,4
Tumor site		
Nose	17	36,2
Forehead	6	12,8
Capillitium	6	12,8
Ear	4	8,5
Cheek	3	6,4
Periorbital	4	8,5
Lip	1	2,1
Temple	6	12,8
Histologic subtype		
Nodular	20	42,6
Superficial	8	17
Sclerodermiform	11	23,4
Cicatrix	8	17
Type of LA		
Tumescent anesthesia (TLA)	41	87,2
Prilocain 1%	6	12,8

Fig. 3

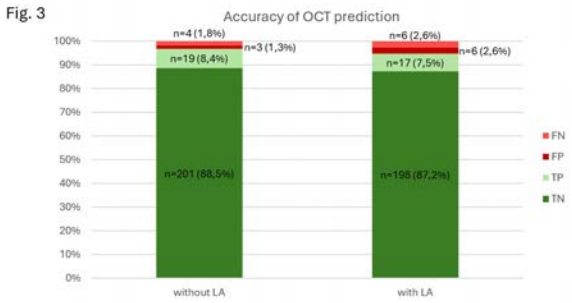

Fig. 4

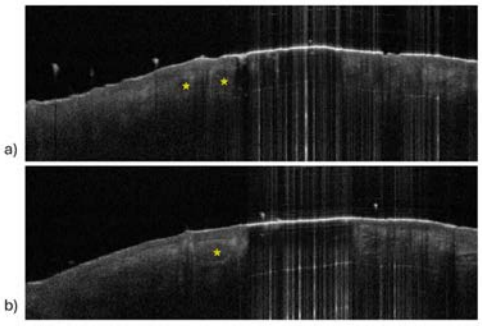

Table 1: Clinical and histologic characteristics of the study population. Figure 3: 100% stacked bar chart illustrating OCT findings for margin sections (n=227). The chart shows the distribution of predictions without and with LA compared to their histologic reference. Green indicates correct classifications (true positives (TP), true negatives (NP)), red indicates misclassifications (false positives (FP), false negatives (FN)). Figure 4: OCT images of a margin section classified as true positive a) before LA, b) after LA. Tumor nests marked with an asterisk are located immediately outside the shadow of the marker (left: outside, right: inside the margin).

Conclusions

OCT may be an useful and accurate tool for determining preoperative resection margins of BCC. LA had little effect on overall accuracy of findings, supporting the flexible use of OCT in the perioperative setting. However, with sclerodermiform subtype, image interpretation may be limited following LA injection, likely due to reduced visualization of its fine branching tumor chords. Therefore, in cases of sclerodermiform BCC, OCT imaging has to be performed prior to administration of local or tumescent local anesthesia.

EADV CONGRESS
VIENNA
30 SEP - 3 OCT 2026

Abstract N°: 924

When it is not dermatofibrosarcoma protuberans: molecular reclassification of two congenital CD34-positive spindle cell tumours in infants

Katharina Fetzer*[1], Stephan Forchhammer[1], Ines Brecht[2], Toni Silber[3], Hans Martin Haefner[1]

[1] Department of Dermatology, Eberhard-Karls-University, Tübingen, Germany

[2] Department for pediatric hematology and oncology, Childrens hospital, Eberhard-Karls-University, Tübingen, Germany

[3] MVZ Obere Waessere, Reutlingen, Germany

Introduction

Congenital CD34-positive spindle cell tumours in infants are frequently diagnosed as dermatofibrosarcoma protuberans (DFSP) on the basis of storiform-myxoid morphology and CD34 positivity. However, DFSP is molecularly defined by a COL1A1:PDGFB fusion or PDGFD rearrangement in over 90% of cases. We present two infants originally diagnosed with congenital DFSP whose diagnoses were fundamentally revised after comprehensive molecular workup.

Case Presentation

Case 1

An 8-month-old infant had a congenital trunk lesion with progressive growth, presenting as an 8x8 cm plaque of confluent reddish nodules that clinically suggested a vascular malformation. Histology showed a dermal-subcutaneous CD34-positive spindle cell tumour in a storiform-myxoid stroma with infiltrative growth, low proliferation and no S100/SOX10/Melan-A/HMB45 expression. Initially the specimen was interpreted as a myxoid variant of DFSP. COL1A1:PDGFB fusion and PDGFD rearrangement were negative. Exome and somatic panel analysis showed no further classifying mutation. RNA transcriptome sequencing identified an LMNA::NTRK1 fusion. The lesion was reclassified as a neonatal spindle-cell CD34-positive plaque-like tumour. A recently described NTRK-fusion-defined entity that mimics congenital DFSP but lies outside the DFSP spectrum. After complete excision with 3D margin control the patient remains recurrence-free at 5 years.

Case 2

A 2-month-old infant with a bathing-trunk giant congenital melanocytic nevus (GCMN) had a congenital exophytic, ulcerated lumbar nodule. Excision was performed torule out melanoma or a proliferative nodule. Histology showed a compound melanocytic nevus colliding with a dermal storiform CD34-positive spindle cell proliferation (Melan-A/HMB45/SOX10/S100 negative, focally increased Ki-67), initially diagnosed as DFSP within a GCMN. COL1A1:PDGFB and PDGFD were negative. Exome and somatic panel analysis of the microdissected spindle cell component revealed an activating NRAS mutation and a high copy-number burden (CNV load 57%) combining whole-chromosome gains, loss of heterozygosity of multiple chromosomes and focal structural aberrations. Transcriptome sequencing showed only two read-through fusions of uncertain significance and no disease-defining fusion. The lesion was reclassified as an NRAS-mutated, CD34-positive atypical proliferative nodule arising within the GCMN with an indolent course over 5 years.

Conclusion

Both congenital tumours convincingly mimicked DFSP clinically and histologically. The CD34-positive phenotype with complete loss of melanocytic markers in case 2 has, to our knowledge, not been described in proliferative

nodules within GCMN. These cases show that CD34 positivity and DFSP-like morphology are insufficient to diagnose congenital spindle cell tumours: fusion testing and broad transcriptome and genomic profiling are essential to reach the correct diagnosis, which carries direct prognostic and therapeutic implications. Tissue-sparing 3D-histology-controlled excision achieved recurrence-free or indolent outcomes in both.

EADV CONGRESS
VIENNA
30 SEP - 3 OCT 2026

Abstract N°: 1117

Xeroderma Pigmentosum: Two Case Reports Highlighting Heterogeneous Responses to Immune Checkpoint Inhibition and the Limits of Dermatologic Surgery

Anna Happe*[1], Nora Schlecht[1], Carsten Weishaupt[1]

[1] University Hospital Münster, Münster, Germany

Introduction

Xeroderma pigmentosum (XP) is a rare autosomal recessive genodermatosis caused by defects in the nucleotide excision repair pathway, leading to extreme sensitivity to ultraviolet (UV) radiation and a markedly increased risk of cutaneous squamous cell carcinoma (cSCC) (1). Patients frequently develop multiple skin cancers at an early age, making dermatosurgery a cornerstone of management. Early surgical excision, often combined with topical treatments such as 5-fluorouracil or imiquimod, is essential for the management of precancerous lesions and early tumors. However, advanced disease may become unresectable and require systemic therapy. Immune checkpoint inhibitors (ICI), particularly the PD-1 inhibitor cemiplimab, have demonstrated promising efficacy in advanced cSCC (2), likely related to the high tumor mutational burden typically observed in these tumors. Clinical evidence for ICI therapy in XP patients, however, remains limited.

Case Presentation

We report two patients with XP who developed advanced cSCC of the facial region despite extensive prior dermatosurgical treatment.

A 35-year-old patient with a history of multiple facial surgeries developed a muscle-invasive cSCC of the right oral commissure that was initially treated surgically. Local recurrence subsequently occurred with satellite metastases of the right cheek, which were considered unresectable. Systemic therapy with the PD-1 inhibitor cemiplimab was initiated but resulted in clinical and radiological disease progression. Subsequent chemotherapy with carboplatin and paclitaxel had to be interrupted repeatedly because of pancytopenia and did not achieve tumor control. Treatment with the EGFR inhibitor cetuximab was likewise ineffective. As further surgical options were not feasible, alternative local treatment strategies, including electrochemotherapy, were discussed. Ultimately, radiotherapy was initiated after careful interdisciplinary consideration of the known radiosensitivity in XP.

The second patient, a 50-year-old man with genetically confirmed XP-A, presented with multiple unresectable cSCCs of the right cheek and temple after numerous previous surgical interventions. His medical history included lymph node–metastatic cSCC of the right fourth finger treated surgically with amputation, as well as a pleomorphic dermal sarcoma managed with orbital exenteration. Due to tumor extent and location, further surgery was not feasible. Treatment with cemiplimab was initiated and resulted in a clinically relevant tumor reduction.

Conclusion

These cases illustrate both the importance and the limitations of dermatosurgical management in XP patients, who frequently develop aggressive and recurrent skin cancers. They also demonstrate the heterogeneous responses to immune checkpoint inhibition in XP-associated cSCC. While one patient showed a clear clinical response to cemiplimab, the other exhibited primary resistance despite several systemic treatment approaches.

Molecular factors such as tumor mutational burden, PD-L1 expression, and XP subtype may influence treatment response and warrant further investigation to guide individualized therapeutic strategies in this rare patient population.

EA DV CONGRESS
VIENNA
30 SEP - 3 OCT 2026

Abstract N°: 1178

V-to-T defect closure for lesions on the lower lip: a novel dermatosurgical technique for skin cancer lesions with mucocutaneous location

Simona Kordeva*[1], Konstantin Tchernev Jr[2], Georgi Tchernev[1, 2]

[1] Medical Institute of Ministry of Interior - Department of Dermatology and Venereology, Sofia, Bulgaria

[2] Onkoderma- Clinic for Dermatology, Venereology and Dermatologic Surgery, Sofia, Bulgaria

Introduction

Reconstruction of lower-lip defects following skin cancer excision poses significant challenges due to the region's unique anatomical and functional complexity. As a key dynamic unit of the lower facial third, the lower lip is fundamental to facial expression, speech formation, and aesthetic balance. The functional outcome in lip restoration is to preserve the integrity of the oral aperture while ensuring adequate restoration of the intraoral mucosal lining.Prevention of microstomia and preservation of normal sensory innervation should always be prioritized, regardless of the extent of the primary defect.

A reconstructive algorithm that prioritizes less invasive reconstructive techniques and incorporates innovative modifications could achieve a more refined balance between aesthetic and functional outcomes while maintaining surgical feasibility and minimizing complications rates. The "V to flying Y" advancement reconstructive technique seems to be till now an excellent option for small-to-medium-sized circular defect.

Case Presentation

We present a case involving a small-to-medium- sized primary defect following surgical excision of a lower lip mucosal/cutaneous lesion (Figure: a). Given the limited tissue integrity, the potential risk for functional impairment and location of the defect, the initial consideration for defect reconstruction was an advancement flap technique. During the procedure, it was observed that the patient had sufficient lip tissue, allowing for direct primary closure in a "V-to-T" pattern (b). The final closure achieved three fine incision lines placed within the patient's natural anatomical boundaries, without distortion of the vermilion or lateral commissures (c,d).



Figure a-d: a: Preoperative view: lesion, located on the right lateral third of the lower lip, involving both the vermilion body and the right oral commissure. b: Intraoperative view: a T-shaped defect, resulting from: 1) Initial tumor excision resulting as irregular in shape (semicircle with an attached equilateral triangle), and 2) two Burrow's triangles excised at the horizontal edges on each side of the initial defect. c: Intraoperative view: Final configuration of the closure resembling a "T", sutured with 5-0 polypropylene single interrupted sutures. Mild swelling is noted. d: 18-days Postoperative view: No signs of postoperative complications.

Conclusion

The remaining lip maintained its full thickness and was reconstructed using exclusively lower lip tissue, thereby avoiding the combination of both mucosal and cutaneous components that would have resulted from an advancement flap technique. By maintaining anatomical alignment along the vermilion border and utilizing careful

undermining, this method allows for an elegant closure across multiple cosmetic subunits, while preserving the patient’s unique anatomical features.

EADV CONGRESS
VIENNA
30 SEP - 3 OCT 2026

Abstract N°: 1308

Innovations in dermatologic surgery: the plesiosaurus flap for scalp reconstruction after skin cancer removal

Georgi Tchernev[1, 2], Konstantin Tchernev Jr[2], Simona Kordeva*[1]

[1] Medical Institute of Ministry of Interior - Department of Dermatology and Venereology, Sofia, Bulgaria
[2] Onkoderma- Clinic for Dermatology, Venereology and Dermatologic Surgery, Sofia, Bulgaria

Introduction

Reconstructive options include rotational, advancement, and transposition flaps. In the scalp region, advancement and transposition flaps may be technically challenging due to the scalp's thickness and limited mobility, often requiring extensive undermining to achieve adequate tissue advancement.

Rotational flaps can provide superior and creative solution for effective scalp defect coverage while maintaining tension-free closure.

Case Presentation

We present a case involving a medium-sized primary defect following surgical excision of a scalp lesion (Figure a). Because the primary defect resulting from excision was circular, primary closure was unsuitable. Healing by granulation or secondary intention would result in prolonged wound recovery and increased infection risk, while skin grafts would cause alopecia and mismatched color and texture. The defect was successfully reconstructed using a novel technique - termed as the Plesiosaurus Flap (Figure b-e). The final scar was planned to be camouflaged within the hair-bearing area region to optimize both functional and aesthetic outcomes.

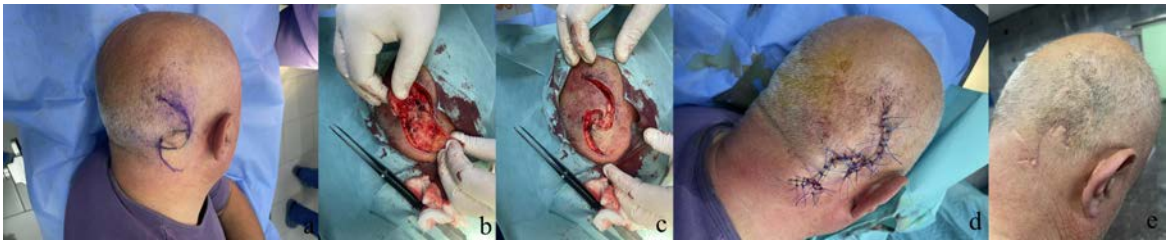

Figure a-e: Intraoperative view: (A) Preoperative marking: A nodular, tumor-like lesion, elevated above the surrounding skin, with irregular borders located in the right occipital region. (B) Careful flap elevation and dissection are performed down to the hypodermis, followed by undermining of both flaps. (C) The resulting defect resembles a shuriken, with an S-shaped configuration. (D) The Plesiosaurus flap: The final defect is closed using single interrupted 2-0/3-0 polypropilene sutures. (E) Postoperative view: The Plesiosaurus flap: 2 month postoperative results

Conclusion

Through the introduction of this new reconstructive approach - the Plesiosaurus Flap technique, our team emphasizes the importance of innovation and adaptability within the surgical mindset.

EADV Congress 2026, VIENNA
30 SEPTEMBER - 03 OCTOBER 2026
POWERED BY M-ANAGE.COM

EADV CONGRESS
VIENNA
30 SEP - 3 OCT 2026

Abstract N°: 1312

Low-cost surgical correction of advanced rhinophyma with high aesthetic impact: a case report with long-term follow-up

Fábio Augusto Peroni Garcia*[1]

[1] UNIVERSIDADE DE SÃO PAULO - USP, UNIVERSIDADE DE TAUBATÉ UNITAU - SÃO PAULO, SÃO PAULO, Brazil

Introduction

Rhinophyma represents an advanced stage of phymatous rosacea, characterized by sebaceous gland hyperplasia and connective tissue overgrowth, leading to nasal enlargement and aesthetic deformity. Medical therapy is often ineffective in fibrotic stages, making surgery the treatment of choice. Various techniques, including tangential excision, carbon dioxide laser, radiofrequency, and dermabrasion, aim to restore nasal contour and function. This report describes a case of advanced rhinophyma with excellent functional and aesthetic outcomes following a single low-complexity surgical procedure.

Case Presentation

An 80-year-old male with Fitzpatrick skin phototype IV presented with progressive nasal enlargement since his fourth decade of life, associated with aesthetic discomfort and psychosocial impact.

Physical examination revealed diffuse nasal hypertrophy with irregular surface, nodular thickening, and deep grooves, predominantly affecting the nasal tip and alae. Nasal airways were patent, with no functional impairment.

A diagnosis of advanced rhinophyma was established, and surgical treatment was indicated. After clinical clearance, the procedure was performed under local anesthesia using tumescent solution.

Tangential excision and volume reduction were carried out using a high-frequency electrosurgical device in spray mode, followed by contour refinement with a ball electrode. The procedure was performed gradually, with effective hemostasis and no intraoperative complications. Postoperative care included topical wound management with healing ointment.

At two-year follow-up, the patient demonstrated a well-defined nasal contour, preserved respiratory function, and no evidence of recurrence.

Conclusion

High-frequency electrosurgery represents a low-cost, accessible, and effective technique for the treatment of advanced rhinophyma, providing satisfactory aesthetic and functional outcomes. This approach may be particularly valuable in resource-limited or humanitarian settings.

EADV CONGRESS
VIENNA
30 SEP - 3 OCT 2026

Abstract N°: 1351

NON VITILIGO INDICATIONS OF MELANOCYTE KERATINOCYTE TRANSPLANTATION PROCEDURE (MKTP)

Madhulika Mhatre*[1]

[1] Skin saga Centre for Dermatology, Mumbai, India

Introduction

Melanocyte Keratinocyte Transplantation Procedure (MKTP) or Non-Cultured Epidermal Cell Suspension is a well-established procedure for vitiligo. However, there are several non vitiligo causes of leukoderma including postburn depigmentation,piebaldism, halo naevus, post laser depigmentation, chemical leukoderma, post discoid lupus erythematosus (DLE) depigmentation and , where MKTP could be a viable treatment option. This study aims to evaluate the efficacy of MKTP in these conditions.

Case Presentation

Materials and methods:

42 cases of non-vitiligo leukoderma were treated with MKTP. These included 12 cases of halo nevus, 1 case of DLE, 13 cases of post burn leukoderma, 11 cases of post laser/chemical depigmentation and 6 cases of nevus depigmentosus. Results were assessed by comparing pre and post treatment photographs.

Results:

3 cases of nevus depigmentosus responded poorly. The remaining 19 cases responded extremely well with 80-100% repigmentation. However the quality of repigmentation was found to be unsatisfactory in nevus depigmentosus. Post burn leukoderma, DLE, post laser/chemical depigmentation and halo nevus all responded well.

Conclusion

MKTP is an effective therapy for the management of non-vitiligo leukoderma however, proper case selection is of paramount importance.

EADV CONGRESS
VIENNA
30 SEP - 3 OCT 2026

Abstract N°: 1352

Trypsinized Split-thickness Grafting: A Novel Technique for Improving Surgical Outcomes in Vitiligo – A Case Series

Madhulika Mhatre*[1]

[1] Skin saga Centre for Dermatology, Mumbai, India

Introduction
Conventional surgical techniques for vitiligo, including split-thickness skin grafting, suction blister grafting, and mini-punch grafting, are limited by technical complexity, time consumption, and inconsistent cosmetic outcomes. Achieving a uniformly thin graft remains operator-dependent. This study evaluates a novel technique of trypsinized split-thickness grafting designed to overcome these limitations.

Case Presentation
This prospective case series included 15 patients with stable vitiligo treated using trypsinized split-thickness grafting. A split-thickness graft was harvested and incubated in trypsin solution to facilitate separation at the dermo-epidermal junction. The epidermal graft was then washed with anti-trypsin solution and transplanted onto a dermabraded recipient site. Patients were followed up for 12 months, and repigmentation was graded as excellent (≥90%), good (65–89%), fair (25–64%), and poor (<25%).

Of the 15 patients, 12 (80%) achieved excellent repigmentation, while 3 (20%) demonstrated good response. No patients showed fair or poor response. Graft uptake was consistent, with uniform pigmentation and minimal textural irregularities. No cobblestoning or significant complications were observed. The patients were followed up for 12 months post procedure, with repigmentation being maintained. The technique allowed predictable harvesting of ultra-thin grafts with reduced procedural variability.

Conclusion
Trypsinized split-thickness grafting is a simple, reproducible, and effective modification that addresses key limitations of conventional grafting techniques in vitiligo. High rates of excellent repigmentation and favorable cosmetic outcomes highlight its potential as a preferred surgical approach in selected patients.

EADV CONGRESS
VIENNA
30 SEP - 3 OCT 2026

Abstract N°: 1429

Squamous cell carcinoma in situ in a 92-year-old woman after trauma: surgical approach with Mustardé flap reconstruction

Marcele Trindade[1], Leticia Azevedo[1], Bianca Fuser[1], Emilia Ulerio[1], Eduarda Gregório Arnaut Lima*[1]

[1] Policlínica Geral do Rio de Janeiro, Rio de Janeiro, Brazil

Introduction

Squamous cell carcinoma in situ of the skin is a malignant epidermal neoplasm with potential for progression if left untreated. Its recognition in elderly patients is crucial, especially when the lesions mimic benign post-traumatic changes.

Case Presentation

A 92-year-old woman, previously healthy, presented with a solitary lesion in the left malar region, which had evolved over the last year. The lesion appeared after being scratched by a domestic cat and gradually increased in size. She did not report pain, bleeding or pruritus. On physical examination, a well-defined erythematous plaque with slight scaling and firm consistency was observed, measuring approximately 1.2 cm in diameter. Given the suspicion of epithelial neoplasia, an excisional biopsy was performed. Histopathology confirmed squamous cell carcinoma in situ (SCCIS).

Surgical excision was performed with 6-mm lateral margins, in accordance with current recommendations for SCCIS in high-risk anatomical sites such as the face. The resulting surgical defect was reconstructed with a bilateral Mustardé advancement flap, a technique widely indicated for malar defects, especially in elderly patients, as it preserves skin tension lines and provides excellent aesthetic results.

At 6-month follow-up, the patient presented complete wound healing, with no signs of recurrence and an excellent cosmetic result.

Conclusion

SCCIS, although noninvasive, may present subclinical extension, particularly in chronically sun-exposed skin, which justifies surgical margins of at least 5 to 6 mm in selected cases. In elderly patients, surgery remains the treatment of choice when functional and aesthetic results can be safely achieved. The Mustardé flap allows redistribution of tension and minimizes distortion of adjacent anatomical structures, with low complication rates even in advanced age.

This case highlights the importance of a detailed clinical history, including minor trauma as a possible triggering factor, and the role of individualized surgical planning in achieving curative and functional results in dermatologic oncology.

POWERED BY M-ANAGE.COM

EA DV CONGRESS
VIENNA
30 SEP - 3 OCT 2026

Abstract N°: 1532

Dermatosurgery rounds: the double rotation (Ying-Yang) flap as basic weapon in the fight against keratinocyte cancer of the scalp

Georgi Tchernev[1, 2], Konstantin Tchernev Jr[2], Simona Kordeva*[1]

[1] Medical Institute of Ministry of Interior - Department of Dermatology and Venereology, Sofia, Bulgaria
[2] Onkoderma- Clinic for Dermatology, Venereology and Dermatologic Surgery, Sofia, Bulgaria

Introduction

The reconstructive ladder has been utilized for many decades as a standard framework in complex trauma reconstruction, aiming to repair and preserve anatomical structures while restoring their functional integrity.

Materials and Methods

When opting for reconstruction, every dermatosurgeon should consider several key aspects of the defect being managed - firstly the location and size of the defect, particularly when it is situated in a challenging anatomical region with rich vascularity and innervation. It is also important to consider the potential tension that may be generated and how and in which direction it should be redistributed, as well as the expected aesthetic and functional outcomes. Classical techniques, although not new, have proven to be safe and reliable over time and should always be considered when selecting the most appropriate reconstructive approach.

We present a case of a successfully reconstructed with a Ying-Yang flap a small-to-medium-sized circular scalp defect following excision of a squamous cell carcinoma (Figure 1a-d).

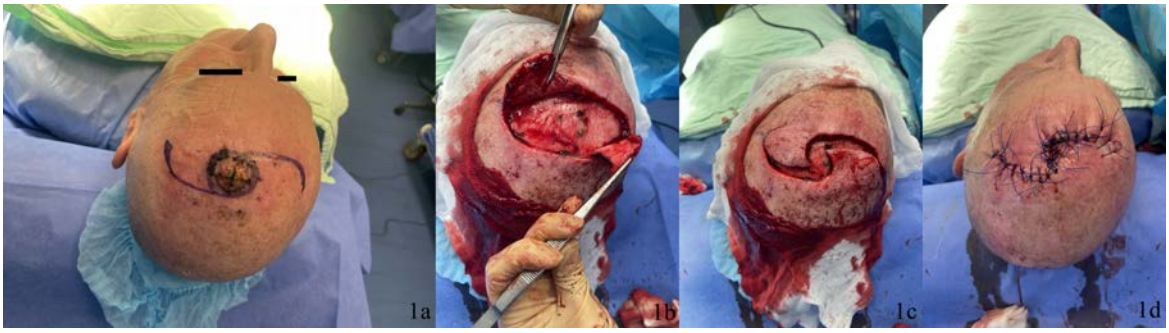

Figure 1: 1a: An exophytic tumorous formation measuring approximately 1,5 cm in diameter, with visible telangiectasias, occasional bleeding, and areas covered with crusts, located in the left frontal region. 1b-d: Intraoperative view: The flaps are carefully undermined down to the hypodermis in order to preserve the vascular supply and maintain the subcutaneous pedicle (b). The resulting secondary defect resembles a shuriken with an “S” configuration (c). The secondary defect is closed using single interrupted sutures (d).

Results

We achieved an optimal final aesthetic outcome (Figure 2). This approach remains a preferred option compared

with other techniques in terms of effective tension distribution, maintenance of functional anatomy, and preservation of surrounding tissue.



Figure 2: 1 month follow-up

Conclusions

The guiding principle is to choose the least invasive technique whenever possible, particularly in regions characterized by multiple tension vectors, limited skin mobility, thick skin, and high cosmetic visibility, such as the frontal scalp region.

The double (bilateral) opposing rotation (Ying-Yang) flap is a versatile reconstructive technique used primarily in the scalp region for the reconstruction of small-to-medium-sized defects, providing effective tension distribution across multiple vectors while remaining less invasive than many conventional techniques. The evenly distributed tension promotes fast wound healing, preserves the anatomical integrity of surrounding tissues, and often results in a well-camouflaged final result.

EA DV CONGRESS
VIENNA
30 SEP - 3 OCT 2026

Abstract N°: 1721

Advancement rotation flap for skin cancer of the paranasal area and the link to drug mediated Nitrosophotocarcinogenicity: the role of drug structure and polypharmacy as generators for phototoxicity

Georgi Tchernev[1, 2], Simona Kordeva*[1], Konstantin Tchernev Jr[2]

[1] Medical Institute of Ministry of Interior - Department of Dermatology and Venereology, Sofia, Bulgaria
[2] Onkoderma- Clinic for Dermatology, Venereology and Dermatologic Surgery, Sofia, Bulgaria

Introduction

Reconstructive surgery plays a central role in the management of skin cancer in anatomically complex regions, such as the facial subunits, including the cheek, eyelids and nose. The classical reconstructive approaches, progressing from less complex to more advanced techniques, have long been established in surgical practice.

Skin cancer, particularly in the facial region, may lead to significant distortion and functional impairment if left untreated. The pathogenesis of skin cancer is progressively being clarified, with emerging concepts such as nitrosogenesis and photo nitrosogenesis gaining increasing attention and recognition worldwide.

Materials and Methods

Geographical variations in the incidence of skin tumors may,can be explained by 1) exogenous drug related Nitroso contamination during the manufacturing process, and 2) the endogenous nitrosogenesis, secured by the availability of secondary and tertiary amines in medical products in combination with the nutritional/dietary mediated nitrosogenesis, secured by nitrite-rich food by the intake. All these processes could lead to the formation of nitrosamines, which are well-known photocarcinogens. Even in the absence of exogenous nitrosamine contamination (during manufacturing processes), endogenous nitrosamine formation prior to hepatic metabolism may represent a critical, previously underrecognized step in the pathogenesis of skin cancer pathogenesis in relation to phototoxicity and photocarcinogenicity. This concept is based on the chemical structure of certain drugs, particularly those containing secondary or tertiary amino groups, which under gastric conditions and in the presence of nitrite-rich food may undergo nitrosation to form nitrosamines. These compounds may subsequently achieve systemic bioavailability and accumulate in the skin, where, upon exposure to UV radiation, they can undergo photodecomposition. The resulting reactive intermediates may induce DNA damage in keratinocytes and melanocytes, thereby contributing to the initiation and progression of skin cancer.

Results

We present a 76-year-old male with a primary defect on the left cheek, following skin cancer excision, which was reconstructed with an advancement rotation flap (Figure a-e). The patient was on long-term systemic therapy with furosemide (secondary amine), rivaroxaban (secondary amine), amlodipine (secondary amine), rosuvastatin (tertiary amine), and teophiline (tertiary amine).

The role of endogenous nitrosamine formation in the context of polymedication and drug-related oncopharmacogenesis will be presented.



Figure a-e: Intraoperative view (A): Preoperative view: A tumor-like lesion in the left infraorbital cheek region, covered with crusts, clinically suspected for basal cell carcinoma (B-D) Intraoperative view: The skin is carefully undermined in all directions within the infraorbital and partly within the zygomatic subunits. The flap is then elevated (b) and advanced (c) toward the defect. The secondary defect is closed using single interrupted sutures (d). (E) Two-month follow-up

Conclusions

The cheek advancement rotation flap remained a highly effective, single-stage reconstructive technique, particularly suitable for moderate to larger skin cancer defects. Further refinement of the wound edges contributed to cosmetically favorable and functionally satisfactory result. The postoperative period was uneventful, and patient satisfaction remained an essential indicator of surgical success. The role of exogenous and endogenous nitrosamine formation in the context of polymedication and drug-related oncopharmacogenesis will be presented.

EA DV CONGRESS
VIENNA
30 SEP - 3 OCT 2026

Abstract N°: 1883

Secondary and tertiary amino groups in metformin and hydrochlorothiazide within the polypharmacy as cofactors for nitrosoformation, drug-related phototoxicity and subsequent multiple keratinocyte cancer development and progression

Georgi Tchernev[1, 2], Valentina Broshtilova-Nikolova[3], Konstantin Tchernev Jr[2], Simona Kordeva*[1]

[1] Medical Institute of Ministry of Interior - Department of Dermatology and Venereology, Sofia, Bulgaria

[2] Onkoderma- Clinic for Dermatology, Venereology and Dermatologic Surgery, Sofia, Bulgaria

[3] Sofia University Saint Kliment Ohridski, Faculty of Medicine - Department of Internal Diseases, Pharmacology and Clinical Pharmacology, Pediatrics, Epidemiology, Infectious Diseases, and Skin Diseases, Sofia, Bulgaria

Introduction

The issues that have been identified to date as potentially pivotal in relation to skin cancer in general, but also keratinocytic cancer in particular, mainly concern the permanent potentiation of concepts such as phototoxicity and hence its subsequent photocarcinogenicity over time.

Studies by scientific teams dating back more than 50 years have defined the phototoxicity of nitrosamines as a rather nonspecific property, regardless of whether the last mentioned have a carcinogenic effect or not. Recently or in 11/ 2024, hydrochlorothiazide was officially declared by the IARC/ International agency on cancer research as carcinogenic to humans due to its phototoxicity. Similar to sartans, metformin, beta blockers and calcium antagonists, hydrochlorothiazide are also associated with contamination from nitrosamines and all of them are scientifically and pathogenetically linked to phototoxicity and carcinogenicity in humans.

According to a number of international clinical observational studies, concomitant use of more than 1 antihypertensive drug is also associated with a significantly higher risk of developing skin cancer, and in patients with diabetes mellitus this risk is further increased.

Materials and Methods

Polymedication of drug production containing secondary and tertiary amino groups like 1) metformin (secondary and tertiary amine), 2) bisoprolol (secondary amine), 3) amlodipine (secondary amine)/ valsartan (tertiary amine)/hydrochlorothiazide (secondary amines), is logically associated pathogenetically with the intake of a larger amount of photocarcinogens and/or mutagens in parallel.

Results

We present two cases of patients who developed scalp tumors treated successfully with double hatchet flap (Figure a-d).

The first patient (a,b) developed a scalp tumor but also an additional auricular tumor in the context of endogenous/exogenous nitrosamine formation within the polymedication regimen , including secondary/tertiary amines 1) metformin (secondary and tertiary amine), 2) bisoprolol (secondary amine), 3) amlodipine (secondary amine)/ valsartan (tertiary amine)/hydrochlorothiazide (secondary amines). Once ingested, under gastric conditions and in the presence of nitrite rich foods, a nitrosamine formation can occur. The subsequent systemic bioavailability and skin deposition, followed by skin photodecomposition under UV light, can induce skin

carcinogenesis and progression.

The second patient (Figure c,d) had similar polymedication in the past, which couldn’t be clarified at the time of hospitalization. However, the patient has a systemic medication with valproic acid, which can lead to NO release, responsible regarding different studies for the development of keratinocyte cancer.



Figure a-d: Patient 1 (a,b): tumor-like formation located on the scalp, with an irregular shape and nodular structure, measuring approximately 2 cm indiameter, with superficial ulceration and areas covered by yellowish squamous crusts can be noted (a). A second lesion, located on the right auriclecharacterized as a nodular, rounded, well-demarcated pigmented formation, approximately 1.2 cm in diameter, can be also noted (a). Closure is achieved using a double hatchet flap technique with single interrupted sutures applied to the secondary wound defect (b). Patient 2 (c,d): Preoperative view: A round tumor-like formation with erosion and purulent discharge in the left temporoparietal region of the scalp(c). Intraoperative view: Postoperative view: The secondary wound defect is closed with single interrupted sutures (d)

Conclusions

The double hatchet flap technique and the role of drug-induced Nitroso Carcinogenesis/ Photo Nitroso Carcinogenesis/Oncopharmacogenesis due to the permanent intake of amino groups present within the chemical structure of each drug, is commented.

EA DV CONGRESS
VIENNA
30 SEP - 3 OCT 2026

Abstract N°: 1887

Fine scalpel surgery as dermatosurgical approach: Preserving the dartos muscle in patient with scrotal and perigenital giant Buschke-Löwenstein tumors

Simona Kordeva*[1], Konstantin Tchernev Jr[2], Georgi Tchernev[1, 2]

[1] Medical Institute of Ministry of Interior - Department of Dermatology and Venereology, Sofia, Bulgaria
[2] Onkoderma- Clinic for Dermatology, Venereology and Dermatologic Surgery, Sofia, Bulgaria

Introduction

Giant condyloma acuminatum (GCA), alternatively referred to as a Buschke-Löwenstein tumor (BLT), is an uncommon, benign but locally aggressive form of verrucous carcinoma. The condition usually affects the male population under the age of 50, however, there have been rare reports of pediatric cases.

Materials and Methods

Various estimated risk factors such as smoking, diabetes, promiscuous behavior, poor hygiene, immunosupression and others, are linked to the development of this condition. Differential diagnosis for BLT, can include anal verrucous carcinoma and squamous cell carcinoma (SCC).

Results

We present a case with a 26-year-old male patient who came to the dermatology department with primary complaints of a 10-year-old verrucous tumor formations located in the perigenital and perianal areas (Figure a). Serological tests for AIDS, Hepatitis B, Hepatitis C, Chlamydia trichomatis and syphilis were negative. The routine blood tests were slightly abnormal. Histological verification of condylomata acuminata of Buschke-Löwenstein was made. Given the sensitive areas, surgery was advised. With several fine undermining scalpel excisions, the lesions in the scrotal and perigenital areas were removed and the dartos muscle was preserved. Electrodissection and shave curettage were not performed (Figure b,c). The postoperative period went without complications and no recurrences in the perigenital area were reported. The postoperative period went without complications and no recurrences in the perigenital area were reported (figure d).



Fig.1a-d: (A)Verrucous tumorous lesions located on the skin of the penis, scrotum and anus. (B,C) The lesions in the scrotal and perigenital areas were removed with several fine scalpel excisions only. (D) The remaining defect was closed with single interrupted sutures.

Conclusions

For extensive tumors, preoperative chemotherapy or radiotherapy may be beneficial, as it can induce tumor shrinkage, thereby making the debulking procedure safer and securing a penile conservation. Other treatment options may include – topical therapy with podophyllotoxin, 5-Fluorouracil or radiotherapy; lesion removal with CO2 laser therapy, electrocautery; immunotherapy with imiquimod; therapy with sinecatechins, cryotherapy, topical photodynamic therapy, Gardasil 9 (HPV vaccine for HPV types 6,11,16,18,31,33,45,52 and 58) and chemotherapy if necessary.

Despite the availability of the different treatment options, it can be concluded that the most effective approach involves a personalized strategy for each patient. Furthermore, if there are no contraindications, surgery emerges as the preferred choice because: 1) it ensures clear surgical margins, 2) reduces the chances of future recurrence and 3) minimizes the number of required treatment sessions. Other treatments, exhibit outcomes lacking statistical relevance.

EA DV CONGRESS
VIENNA
30 SEP - 3 OCT 2026

Abstract N°: 1970

Curettage and electrodesiccation versus curettage alone for basal cell carcinomas on the lower legs: a randomized controlled trial

Eva Backman*[1], Alexandra Sjöholm[1], Maja Modin[1], Martin Gillstedt[1], Sam Polesie[1], John Paoli[1]

[1] Department of Dermatology and Venereology, Institute of Clinical Sciences, Sahlgrenska Academy, University of Gothenburg, Gothenburg, Sweden, Department of Dermatology and Venereology, Sahlgrenska University Hospital, Gothenburg, Region Västra Götaland, Sweden, Gothenburg, Sweden

Introduction
Basal cell carcinomas (BCCs) are highly prevalent and place a substantial burden on healthcare systems. Surgical excision remains first-line treatment, but management of lower-leg BCCs may be challenging due to limited skin laxity and impaired wound healing. Curettage followed by electrodesiccation (C&ED) is a commonly used destructive treatment, although prospective comparative data are limited and the added benefit of electrodesiccation beyond curettage alone remains unclear.

Materials and Methods
This randomized non-inferiority trial was conducted at the Department of Dermatology and Venereology, Sahlgrenska University Hospital, Gothenburg, Sweden. Lower-leg BCCs measuring 5–20 mm were randomized to treatment with either curettage followed by electrodesiccation (C&ED) or curettage alone using standardized protocols. The primary endpoint was 1-year clinical clearance. Secondary outcomes included 3-year recurrence-free survival (RFS), wound healing time, cosmetic outcome, patient satisfaction, and operator dependency. Most lesions were treated by a senior board-certified dermatologist.

Results
A total of 197 BCCs in 100 patients were included. Superficial subtype (59%) and pretibial location (56%) were most frequent. One-year clearance rates were 98% (95% CI 93–100%) for C&ED and 95% (95% CI 88–98%) for curettage alone (P=0.27). Although observed differences were small, predefined criteria for non-inferiority were not formally met. Three-year RFS rates were 96% (95% CI 92–100%) for C&ED and 94% (95% CI 89–99%) for curettage alone (P=0.49). In a post-hoc analysis, physician experience was associated with outcomes following curettage alone (P=0.002), but not C&ED (P=0.54). Median duration of wound oozing was 1 week in both groups, while median time to complete healing was 6 weeks for curettage alone and 7 weeks for C&ED. Patient satisfaction was high and concerns regarding scarring were low in both groups.

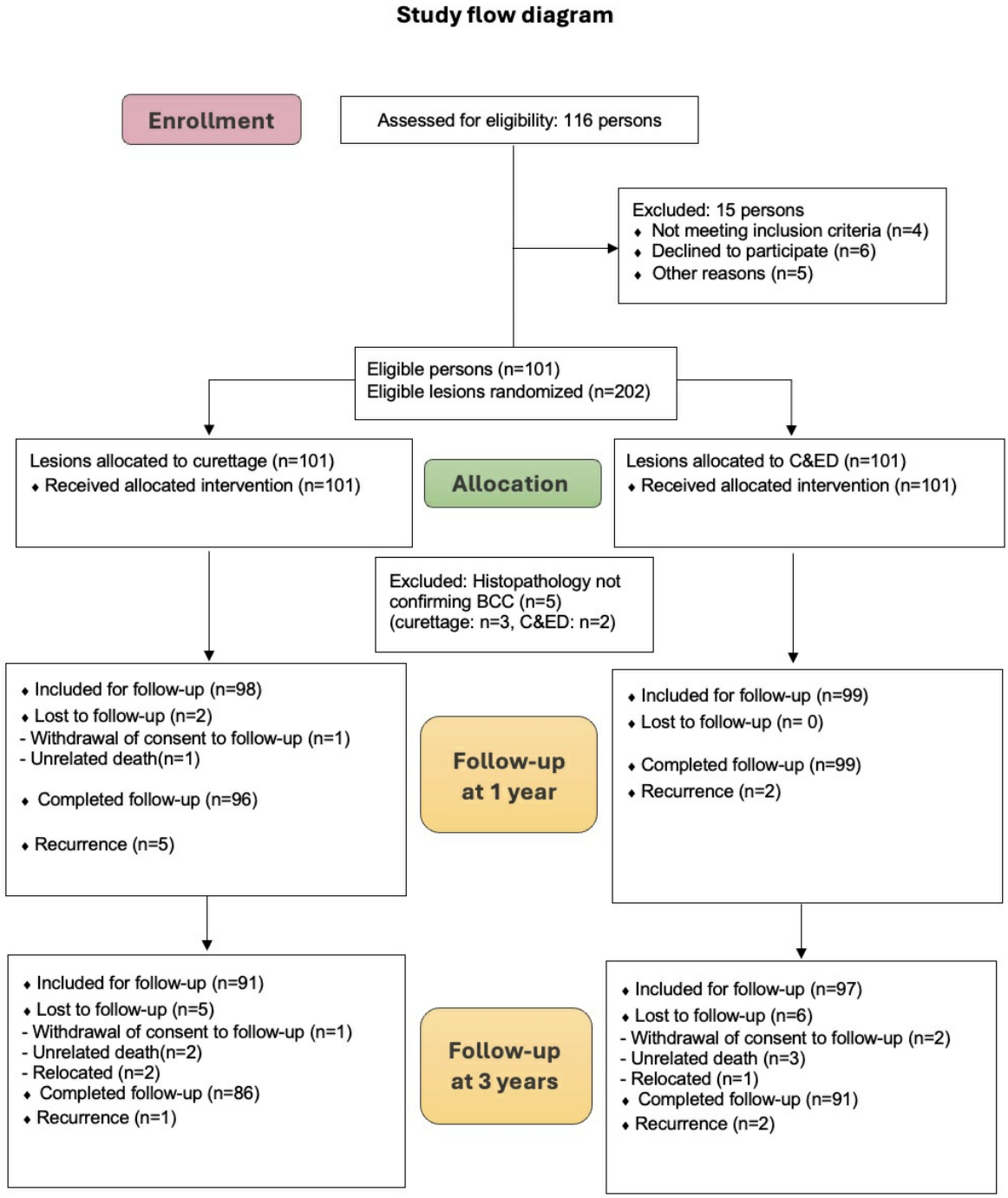

Study flow diagram of included basal cell carcinoma lesions.

Conclusions

Both C&ED and curettage alone achieved high clearance rates for lower-leg BCCs, although outcomes after curettage alone appeared more operator-dependent. These findings support destructive treatments as effective and resource-conscious treatment options for selected lower-leg BCCs.

EA DV CONGRESS
VIENNA
30 SEP - 3 OCT 2026

Abstract N°: 2002

The Nasolabial Burows Advancement (NBA) flap allows esthetic closure of large, multi-subunit defects

Paul Salmon*[1]

[1] Waikato Hospital Gate 2, Hamilton Central, New Zealand

Introduction
Large Multi-subunit defects of the nasal sidewall, ala and dorsum commonly require mulitple flaps and grafts or two stage procedures for reconstruction. We will describe the use of Nasolabial Burow's Advancement flaps (previously known as perialar crescentic advancements) to repair multi-subunit defects of the nasal sidewall including the adjacent cheek, dorsum, tip and ala without the need of additional flaps.



Figure 9 A A defect of the lower sidewall and a large portion of the ala is planned for repair with a distally-based NBA over a cartilage batten harvested from the ipsilateral anti-helix. B Pexing sutures are placed to recreate the alar groove C, D. Result at 6 months without revision

Materials and Methods
This single centre study analysed 6 month post-operative photographs using the Manchester Scar scale. The operative technique is described in detail. Demographics, wound location and size, and complications were recorded. Manchester Scar Scale was used to assess results by an independent dermatologic surgeon.

Results
Of 355 cases, 336 were available for analysis. The median Manchester Scar scale was 7 for both sidewall defects and multi-subunit defects. There were low rates of infection or necrosis.

Short video clips will demonstrate the key features of design and execution.



Figure 4 A. This defect extends inferiorly below the highest point of the alar crease necessitating a distal Burow's triangle/crescent. B. The patient is on anti-coagulant therapy and a small drain is left in situ for 48 hours. The blue stars indicate the location of those 2 key subcuticular sutures and the green stars the key pexing suture.

Conclusions

With the correct technique, the Nasolabial Burow's Advancement alone is capable of use to repair even large multi-subunit defects involving the nasal sidewall, cheek , dorsum, tip and ala with high-level aesthetic and functional results.

EA DV CONGRESS
VIENNA
30 SEP - 3 OCT 2026

Abstract N°: 2003

Quantifying Nasal Morphological Change After Mohs Surgery for Skin Cancer: A Prospective Photographic Rhinometry Study

Georgios Kounidas*[1], Yasin al-Tawarah[2], Sanjay Rajpara[3]

[1] Cambridge University Hospitals, Cambridge, United Kingdom

[2] University of Aberdeen, Aberdeen, United Kingdom

[3] Aberdeen Royal Infirmary, Aberdeen, United Kingdom

Introduction

Alterations in nasal morphology are frequently observed following dermatological and Mohs surgery, yet objective assessment remains limited. Conventional anthropometric techniques are time-consuming and not routinely used in dermatology. Photographic rhinometry offers a rapid, non-invasive alternative for quantifying nasal changes. The aim of the study was to evaluate the feasibility of photographic rhinometry and to quantify post-operative changes in nasal morphology following skin cancer surgery.

Materials and Methods

In this prospective multi-centre study, patients undergoing surgery for basal cell carcinoma of the nose were assessed using standardised pre- and post-operative profile photographs. Measured parameters included nasal projection, nasal length, radix height, columella dimensions, nasal aperture, and alar base width. Statistical analysis utilised paired t-tests or Wilcoxon signed-rank tests, with regression modelling to assess associations with age, gender, and defect size.

Results

Patients (mean age 73.6 years) demonstrated statistically significant reductions in all measured nasal parameters post-operatively. Mean nasal projection decreased by 0.26 (95% CI −0.30 to −0.21, p <0.001) and nasal length by 0.25 (95% CI −0.28 to −0.22, p <0.001). Significant reductions were also observed in radix height, columella length and width, nasal aperture, and alar base width (all p <0.01). Regression analysis identified a small but significant association between increasing defect size and reduced nasal projection (β = −0.0004, p =0.04), with no significant influence of age or gender.

Conclusions

Photographic rhinometry provides a simple, reproducible, and objective method for assessing nasal morphological change following dermatological surgery. Significant structural reductions were demonstrated across multiple parameters. This technique has potential utility in outcome assessment, surgical audit, and improving patient counselling.

EADV Congress 2026, VIENNA
30 SEPTEMBER - 03 OCTOBER 2026
POWERED BY M-ANAGE.COM

EA DV CONGRESS
VIENNA
30 SEP - 3 OCT 2026

Abstract N°: 2006

Who needs a Keystone? Scope and utility of the Bipedicled Bridge Flap (BBF)

Paul Salmon*[1]

[1] Waikato Hospital Gate 2, Hamilton Central, New Zealand

Introduction

The Keystone flap has been popularised as a reconstructive technique predominantly for challenging wounds on the lower limb but also on the head, neck, and trunk. The Keystone flap has two significant disadvantages: Firstly, the blood supply is tenuous, being derived from small segmental deep fascial perforating blood vessels; secondly, it is prone to pin cushioning leading to an often unesthetic result, which is a more concerning cosmetic issue when it is used on the face.

We propose instead that the bipedicled Bridge Flap (BBF) should be considered in many of the situations in which a clinician may think of using a Keystone flap.

Materials and Methods

A prospective cohort single institution study of all BBFs between March 2013 and March 2025. Recorded data are location, size of defect, sex, single or double flap, infection, necrosis, hematoma, revisions.

Short video clips will demonstrate the design and execution.

Results

From March 2013 to March 2025 we performed 530 cases of BBF reconstructions following excision of both melanoma and non-melanoma skin cancers with a mean age of 68. In 17 instances, a double bridge flap was utilized to achieve sufficient tissue movement. The median defect size was 2.7 cm, ranging from 1.0 cm to 4.7 cm. There were four cases of superficial partial flap necrosis in patients with prior adjacent flap surgery, one on the forehead, two on the scalp and one on the lower leg below the calf. All were minor and resolved without further intervention. There were no flap failures, even below the knee.



A large defect with periosteal loss is reconstructed with bilateral bridge flaps and the result at 6 months.

Conclusions

The development of the BBF has provided a robust and reliable reconstructive option for the repair of surgical defects where a keystone flap may previously have been considered. Additionally, the BBF has several applications outside of the scope of a Keystone flap. Its utility on the nasal bridge, lower leg and forehead have made it our closure of choice in these locations when primary closure is not possible .

EA DV CONGRESS
VIENNA
30 SEP - 3 OCT 2026

Abstract N°: 2355

Nonmelanoma Skin Cancer at an Academic Healthcare Center: Analysis of Mohs Micrographic Surgery Cases and Non-Melanoma Skin Cancer Cases from a Tertiary Care Center

Firas Haddad*[1], Jihane Abou Rahal[1], Dana Khoury[1], Ranay Ishak[1], Yasmina Kobeissi[1]

[1] American University of Beirut Medical Center, Department of Dermatology, Beirut, Lebanon

Introduction
Nonmelanoma skin cancers (NMSCs), primarily basal cell carcinoma (BCC) and squamous cell carcinoma (SCC), are the most common malignancies worldwide, with increasing incidence. Ultraviolet (UV) radiation is the main risk factor, particularly affecting sun-exposed areas such as the head and neck. Additional contributors include age, sex, skin type, immunosuppression, and genetic predisposition. In the Middle East and North Africa (MENA) region, high UV exposure and occupational factors may increase disease burden, especially among men. Although mortality is low, NMSCs can cause significant morbidity, making early detection and optimal treatment essential. Mohs micrographic surgery (MMS) provides superior margin control and tissue preservation.

Materials and Methods
This retrospective cohort study includes patients diagnosed with BCC and/or SCC between 2018 and 2026 at a tertiary care center. Data collected from electronic medical records will include demographics, risk factors, tumor characteristics, and treatment details. Variables include age, sex, tumor site, histologic subtype, treatment modality, surgical margins, reconstruction type, and complications. For MMS cases, additional details such as number of stages and defect size will be recorded. Outcomes include recurrence, metastasis, and follow-up. Data will be de-identified and analyzed using descriptive statistics and regression models to assess associations between clinical variables and outcomes.

Results
736 Mohs procedures have been conducted between 2018-2026, and so far a total of 74 tumors were collected and analyzed across 51 unique patients who underwent Mohs micrographic surgery (MMS). The cohort was predominantly male (54.9%; n = 28) with a mean age at diagnosis of 68.5 years (median 70.5; range 35–87), and 75.0% of patients were aged 60 years or older at the time of diagnosis. The majority of patients presented with Fitzpatrick skin type II (67.7%), followed by type III (26.2%) and type I (6.1%).

Basal cell carcinoma (BCC) was the most common histologic diagnosis, accounting for 78.4% of tumors (n = 58), while squamous cell carcinoma (SCC) comprised 21.6% (n = 16). Among BCC subtypes, nodular BCC was the most prevalent, followed by infiltrative and superficial variants. Nearly all tumors arose in the head and neck region (92.0%), with the scalp, forehead, nose, and cheeks representing the most frequently involved anatomic sites. High- and medium-risk anatomic locations accounted for 47.3% and 50.0% of cases, respectively, with only 2.7% occurring in low-risk areas. Notably, 57.8% of patients had a history of tobacco use, and 20.3% were immunosuppressed at the time of treatment. The mean number of mohs micrographic surgery stages required was 1.75; 44.4% of cases were completed in a single stage, 40.3% required two stages, and 15.3% required three or more stages. Peripheral and deep frozen section margins were clear in 100% of cases, and complete excision was achieved in all patients with no need for re-excision. The mean interval from diagnosis to treatment was 56.2 days (median 34 days; IQR 15–57 days). Wound reconstruction was most commonly performed via linear closure (53.3%), followed by flap-based reconstruction including advancement, bilobed, and adjacent tissue transfer flaps (22.7%). No postoperative tumor recurrence was documented at the time of last follow-up. Complication rates were low, with dehiscence reported in one case.

Conclusions

These findings underscore the high efficacy and safety profile of MMS for nonmelanoma skin cancers in this regional cohort, and highlight the predominance of BCC in high-risk facial and scalp locations among an older, predominantly male population with significant tobacco exposure.

EA DV CONGRESS
VIENNA
30 SEP - 3 OCT 2026

Abstract N°: 2356

Performance of a Large Language Model in Reconstructive Decision-Making After Mohs Surgery

Firas Haddad*[1], Jihane Abou Rahal[1], Dana Khoury[1], Dana Saade[1]

[1] American University of Beirut Medical Center, Department of Dermatology, Beirut, Lebanon

Introduction
Mohs micrographic surgery (MMS) is the gold standard for non-melanoma skin cancers, offering high cure rates and tissue preservation. However, reconstruction after tumor extirpation remains highly variable, requiring individualized decisions that balance function and cosmesis. No universal algorithm exists for selecting optimal closure techniques, and choices are often guided by surgeon experience. Large language models such as ChatGPT have shown promise in medical reasoning and may assist in surgical planning. To evaluate the ability of ChatGPT to recommend appropriate closure techniques for MMS defects, compare its performance with that of two Mohs surgeons, and assess the plausibility and educational value of its outputs.

Materials and Methods
Seventy-four de-identified MMS defect images from distinct patients across multiple anatomical sites (nose, cheek, lips, periocular region, scalp/forehead, neck, ears) were analyzed. A standardized prompt and a curated list of 28 closure techniques were presented to ChatGPT-4.5 and two fellowship-trained Mohs surgeons, who independently selected first and second reconstruction choices. Surgeons subsequently rated ChatGPT's recommendations using a 5-point Likert scale. Concordance was assessed using percentage agreement and Cohen's κ statistics.

Results
Inter-surgeon agreement exceeded agreement between either surgeon and ChatGPT. For first-choice closures, surgeons demonstrated fair agreement (28.4%, κ=0.22), while concordance with ChatGPT was lower (12.2–21.6%, κ=0.079–0.16). Second-choice agreement was minimal across all comparisons. Overall partial agreement between surgeons reached 64.9%, compared with 39.2–56.8% between surgeons and ChatGPT. ChatGPT misidentified the anatomical location in 44.6% of cases, most frequently on the nose and neck, often leading to inappropriate reconstruction choices. Correcting anatomical inputs resulted in only modest improvements in agreement. Likert ratings suggested moderate perceived plausibility (mean 3.41–4.01), though a substantial proportion of responses were rated <3, indicating disagreement or clinical inappropriateness.These findings highlight the inherent variability in MMS reconstruction, reflected even among experienced surgeons. While ChatGPT demonstrated the ability to generate structured and occasionally reasonable suggestions, its overall concordance with expert opinion was low. Errors were partly attributable to incorrect anatomical localization, which was influenced by image quality and framing, but persisted even after correction, suggesting deeper limitations in clinical reasoning. Importantly, surgeons more frequently agreed within closure categories (e.g., flap types) than with ChatGPT, indicating consistent reconstructive patterns not fully captured by the model.

Conclusions
ChatGPT shows limited reliability in recommending MMS closure techniques, with performance inferior to expert surgeons and significant susceptibility to input quality. While it may offer educational value and serve as an adjunctive tool for generating reconstructive options, its outputs require careful critical appraisal. AI should not replace expert surgical judgment. Future research with larger, multicenter datasets and optimized multimodal inputs is needed to better define the role of AI in dermatologic surgery decision-making.

EADV CONGRESS
VIENNA
30 SEP - 3 OCT 2026

Abstract N°: 2373

Efficacy and Safety of a Novel 760 kDa Botulinum Toxin Type A in Moderate-to-Severe Glabellar Lines: Phase II Results and 1-Year Repeat-Dose Extension Study Design

Tsau Tzu Wen*[1]

[1] OBIGEN pharma, Taipei city, Taiwan

Introduction

Background:
Achieving both rapid onset and prolonged duration remains an unmet need in aesthetic botulinum toxin therapy. A novel 760 kDa botulinum toxin type A (BTX-A) complex has been developed to optimize clinical performance and deliver a differentiated efficacy profile.

Objective:
To evaluate the efficacy, safety, onset, durability, and dose response of the 760 kDa BTX-A in subjects with moderate-to-severe glabellar lines, and to inform the design of an ongoing pivotal Phase III program and a 1-year repeat-dose extension study, with Phase III efficacy and safety results to be presented at the congress.

Materials and Methods

This clinical program comprised a Phase II randomized controlled study followed by a 1-year repeat-dose extension study. In the Phase II multicenter, randomized, double-blind, placebo-controlled trial, subjects received a single treatment of 760 kDa BTX-A (10 U or 20 U) or placebo and were followed for 24 weeks. Efficacy was assessed using validated 4-point Glabellar Line Severity (GLS) scales, with responders defined as achieving a ≥2-grade improvement by both investigator and subject assessments. Additional endpoints included Global Aesthetic Improvement Scale (GAIS) and subject satisfaction. Safety evaluations included treatment-emergent adverse events and immunogenicity.
An ongoing multicenter, open-label, single-arm extension study was designed to evaluate long-term safety and sustained efficacy following repeat dosing. Eligible subjects receive 20 U injections administered across five standardized glabellar sites, with up to four repeat treatments permitted at intervals of ≥12 weeks based on recurrence of glabellar line severity.

Results

At Week 4, 74.4% of subjects in the 20 U group and 58.7% in the 10 U group achieved a ≥2-point GLS improvement assessed by both investigators and subjects, compared with 0% in the placebo group ($p < 0.001$ for both active groups). Both active doses demonstrated rapid onset, with GLS 0–1 responder rates observed by Day 3 and peak efficacy at Week 2. From Week 4 through Week 20, the 20 U dose consistently showed higher responder rates. Sustained efficacy was maintained through Week 24 in both dose groups. Over 90% of subjects achieved ≥1-point improvement by Week 4, with sustained responses in more than 60% through Week 24. GAIS and satisfaction scores peaked at Week 2 and remained favorable in the 20 U group through Week 24, with nearly 60% of subjects reporting satisfaction at study end. The 760 kDa BTX-A was well tolerated, with no treatment-related serious adverse events or new anti-drug antibody development observed.

Ongoing Extension Study:

A multicenter, open-label, 1-year repeat-dose extension study is currently ongoing in a large patient population to further evaluate long-term safety, immunogenicity, and durability of OBI-858 across multiple treatment cycles. Eligible subjects receive fixed-dose repeat administrations based on recurrence of glabellar line severity, with a minimum interval of 12 weeks between treatments. The study is designed to characterize retreatment intervals, cumulative safety outcomes, and sustained clinical response under conditions that reflect routine aesthetic practice.

Conclusions

The novel 760 kDa BTX-A demonstrated dose-dependent efficacy, rapid onset, sustained aesthetic effect, and a favorable safety and immunogenicity profile in treating glabellar lines. The 20 U dose showed superior durability and sustained patient satisfaction, supporting its selection for further clinical development.

EA DV CONGRESS
VIENNA
30 SEP - 3 OCT 2026

Abstract N°: 2375

Wide advancement flap reconstruction of a large facial defect after tumor excision performed with local anesthesia in a 91-year old patient

Preslav Vasilev*[1, 2], Sibel Ramadan[3], Martin Karamanliev[2, 4]

[1] Department of Dermatology, Venereology and Allergology, Faculty of Medicine, Medical University Pleven, Bulgaria, Pleven, Bulgaria

[2] Centre of Competence in Personalized Medicine, 3D and Telemedicine, Robotic Assisted and Minimally Invasive Surgery „Leonardo da Vinci“, Pleven Bulgaria, Pleven, Bulgaria

[3] Department of Oncology, Faculty of Medicine, Medical University Pleven, Bulgaria, Pleven, Bulgaria

[4] Surgical Oncology Department, University Hospital “Dr. Georgi Stranski”, Faculty of Medicine, Medical University-Pleven, Bulgaria, Pleven, Bulgaria

Introduction

Reconstruction of large facial defects in elderly patients remains a major surgical challenge due to the increased operative risk, limited tissue elasticity and the need to preserve both function and aesthetic appearance. The temporal region is particularly demanding because of the proximity to the lateral canthus, facial nerve branches and hair-bearing scalp. Wide advancement flaps provide an effective reconstructive option by utilizing adjacent well-vascularized tissue while minimizing donor-site morbidity.

Case Presentation

We present a 91-year-old patient with a rapidly enlarging painful nodular lesion located in the left temporal region. Clinical examination demonstrated a solitary oval, nodular, ulcerated and crusted tumor formation with surrounding infiltrative changes. Surgical excision with safety margins 6mm resulted in a soft tissue defect measuring approximately 60 mm in diameter extending to the superficial muscular fascia. Histopathological and immunohistochemical examinations established the diagnosis of cutaneous leiomyosarcoma after diffuse α-smooth muscle actin positivity and negative cytokeratin and S100 staining. Subsequent imaging studies revealed no metastatic disease.

The major surgical challenge in this case was reconstruction of the extensive temporal defect while avoiding excessive tension, distortion of the periocular region and functional impairment. Reconstruction was achieved using just local anesthesia, beacause of the age of the patient and his concomitant diseases. A wide advancement flap mobilized from the entire buccal and preauricular facial regions. The flap was carefully dissected within the mid-hypodermal plane to preserve vascular supply and protect branches of the facial nerve. Additional mobility was obtained through creation of a Burow’s triangle beneath the auricle. The flap was subsequently advanced and partially rotated in the tip to achieve tension-free closure of the defect.

The postoperative period was uneventful. Complete restoration of skin integrity was achieved without flap necrosis, infection, hematoma or facial nerve dysfunction. Sutures were removed on the seventh postoperative day. Follow-up demonstrated excellent flap viability, satisfactory contour restoration, preservation of facial symmetry and a favorable cosmetic outcome two months after surgery.

Discussion:

Large lateral temporal defects represent a reconstructive challenge because of limited local tissue mobility and the risk of distortion of adjacent anatomical structures. Wide advancement flaps from the buccal and preauricular regions provide several advantages – sufficient vascularization, favorable tissue match and preservation of facial

contour. Creation of a Burow’s triangle significantly improves flap mobility and reduces tension during closure.

In elderly patients, local flap wide reconstruction may be preferable to more complex reconstructive techniques because it allows shorter operative times, reduced morbidity, and reliable postoperative healing. The use of local anesthesia is also very important for elderly patients. Careful surgical planning and successful preservation of the temporal branch of the facial nerve are essential for optimal functional and aesthetic outcomes.

Conclusion

Wide advancement flap reconstruction using tissue from the buccal and preauricular regions is an effective and reliable option for closure of large temporal facial defects. The technique provides excellent tissue compatibility, tension-free closure, preservation of facial symmetry and satisfactory cosmetic results, even in very elderly patients with extensive postoperative defects.

EA DV CONGRESS
VIENNA
30 SEP - 3 OCT 2026

Abstract N°: 2401

Full-Thickness Alar Reconstruction With Versus Without CartilageSupport

Fabiola Silva*[1], Beatriz Ximenes Mendes[2], Lilia Maria de Oliveira[3], Marina Burla[4]

[1] Federal University of Bahia/Brazil, Salvador/BA, Brazil
[2] ChristusUniversity Center, Fortaleza, Brazil
[3] Harvard T.H. Chan SchoolofPublic Health, Boston, United States
[4] Estacio de Sa Vista Carioca University, Rio de Janeiro, Brazil

Introduction
The nasal ala is a complex structure essential to nasal form and function. Full-thickness defects, often from oncologic resection, pose major reconstructive challenges. Repairs must restore contour and function while minimizing complications. Despite many techniques, inconsistent outcome reporting limits comparison.

Objectives: To synthesize the available evidence on reconstructive strategies and outcomes for full-thickness nasal alar defects after oncologic resection.

Materials and Methods
PubMed, Embase, Web of Science and Cochrane Library were systematically searched for studies on surgical reconstruction of full-thickness nasal alar defects after oncologic resection, following PRISMA guidelines. Assessed outcomes included aesthetics, nasal function, complications, patient satisfaction, number of stages, and revision rates.

Results
Thirty-three studies comprising 360 full-thickness alar defects were included. Among cases with explicitly reported histology, 96% were nonmelanoma skin cancers, predominantly basal cell carcinoma (78%). Most studies originated from plastic surgery departments (73%), followed by otolaryngology (12%) and dermatology (15%). Among 25 studies reporting sex distribution, 65.4% of patients were male, and the mean age was 65 years. Structural cartilage support was not used in 50% of reconstructions. Cutaneous flap–based techniques were the predominant method of internal lining reconstruction. In the non-cartilage group, 22 complications were identified among 180 reconstructions (12.2%), compared with 30 complications among 180 reconstructions (16.6%) in the cartilage-supported group. Partial and/or total necrosis was reported in 7 cases in each group. Most studies reported satisfactory functional and aesthetic outcomes, although outcome assessment was largely subjective.

Conclusions
Full-thickness alar defect reconstruction shows low complication rates and satisfactory outcomes. Diverse techniques are effective, with cartilage graft omission rarely leading to major issues. Standardized assessments are needed to improve outcome comparisons.

EADV CONGRESS
VIENNA
30 SEP - 3 OCT 2026

Abstract N°: 2489

Initial Surgical Margin Predicts Multi-Stage Mohs Micrographic Surgery: A Retrospective Cohort Study from a Tertiary Center in Indonesia

Raissa Putri Raspati*[1], Danang Tri Wahyudi[1], Aida Hoemardani[1], Agassi Suseno Sutarjo[1], Fadhli Aulia Mughni[1], Inadia Putri Chairista[1], Nuril Ilmi[1], Reinaldo Mukti[1]

[1] Dharmais National Cancer Hospital, Department of Pulmonology and Respiratory, Jakarta, Indonesia

Introduction

Mohs micrographic surgery (MMS) provides high cure rates for non-melanoma skin cancer (NMSC) through complete margin control. The number of stages required for tumor clearance varies and reflects operative complexity, surgical time, and reconstructive burden. Identifying predictors associated with multi-stage MMS may enhance preoperative planning and optimize the use of surgical time and intraoperative decision-making. This study aims to evaluate clinicopathological factors associated with multi-stage MMS and to identify independent predictors of surgical complexity.

Materials and Methods

A retrospective cohort study was conducted on 109 histopathologically confirmed NMSC cases treated with MMS performed between 2020 and 2025 at a tertiary cancer center in Indonesia. Each tumor was analyzed as an independent case. Variables included tumor size (≤2 cm vs >2 cm), anatomical location (high-risk [H] vs non-H area), and initial surgical margin (<3 mm vs ≥3 mm). The primary outcome was the requirement for multi-stage MMS. Associations were assessed using chi-square test, followed by multivariate logistic regression to identify independent predictors. Adjusted odds ratios (aOR) with 95% confidence interval (CI) were reported.

Results

Multi-stage MMS was required in 29 (26.6%) of cases. Tumors treated with initial margins <3 mm had a significantly higher rate of multi-stage procedures compared to those with margins ≥3 mm (34.5% vs 17.6%, p=0.047). Tumor size > 2 cm and H-area location were not significantly associated with multi-stage MMS (p=0.512 and p=0.392, respectively). In multivariate analysis, initial margin <3 mm remained an independent predictor of multi-stage MMS (aOR 3.05; 95% CI 1.17 – 8.01; p=0.023), while tumor size and anatomical location were not independently associated.

Conclusions

Initial surgical margin is a key determinant of MMS complexity. Margins <3 mm significantly increases the likelihood of requiring multiple stages, independent of tumor size and location. These findings support the role of margin selection in optimizing surgical efficiency and facilitating preoperative planning. Further studies with larger cohorts are warranted to validate these findings.

EADV CONGRESS
VIENNA
30 SEP - 3 OCT 2026

Abstract N°: 2499

Mohs micrographic surgery for dermatofibrosarcoma protuberans: a single center retrospective case series

José Javier Mateos Rico*[1], Araceli Sánchez Gilo[1], Marta Gutiérrez Pascual[1], María Dolores Caro Gutiérrez[1], Cristina Marcos Rodríguez[1], Javier De Quadros Malagón[1], Mario Porto Souto[1], Francisco Javier Vicente Martín[1]

[1] Hospital Universitario Rey Juan Carlos, Móstoles, Spain

Introduction
Dermatofibrosarcoma protuberans (DFSP) is the most common cutaneous sarcoma. It is a slow-growing tumour with low metastatic potential but marked local aggressiveness and infiltrative growth. Early lesions are often asymptomatic and nonspecific, and the diagnosis is frequently delayed, leading to larger surgical defects. Mohs micrographic surgery (MMS) may reduce recurrence while preserving healthy tissue.

Materials and Methods
We conducted a retrospective case series of 31 histologically confirmed DFSPs treated with staged MMS between March 2012 and April 2026. Variables included demographic data, tumour site and size, immunohistochemistry, number of stages, final defect size, reconstruction, recurrence and metastasis.
Our objective was to describe the epidemiological, clinical, histopathological, surgical and outcome features of patients with DFSP treated with MMS.

Results
The cohort included 21 women and 10 men, with a mean age of 47.5 years. The trunk was the most common site (32.2%). Most tumours were primary and protuberant at diagnosis. Conventional DFSP was the predominant subtype (96.8%); fibrosarcomatous transformation was found in one case (3.2%). All cases were CD34-positive, and factor XIIIa was negative in most cases (72.2%). One MMS stage was sufficient in 87.5% of cases. The mean maximum (longest-axis) defect diameter was 7.16 cm. Reconstruction was by primary closure in 51.6% and local flaps in 48.4%. No local recurrences or metastases were observed during a median follow-up of 110 months.

Conclusions
MMS provides precise margin control, preserves healthy tissue, and may facilitate reconstruction while achieving excellent short and long-term oncological outcomes in dermatofibrosarcoma protuberans.

EADV CONGRESS
VIENNA
30 SEP - 3 OCT 2026

Abstract N°: 2550

Scaling Surgical Care for Podoconiosis: Lessons from Decentralized Nodulectomy to Primary Health Centers in Southern Ethiopia

Wendemagegn Enbiale*[1], Alemayehu Bekele[1], Fikre Hailekirkos[2]

[1] Arba Minch University, College of Medicine and Health Sciences, Bahir Dar University College of Medicine and Health Science, Arbaminch Zuriya, Ethiopia

[2] National Action for Podoconiosis Network, Addis Ababa, Ethiopia

Introduction

Podoconiosis is a neglected tropical disease that causes chronic lymphedema and painful nodules, significantly affecting quality of life. In Ethiopia, access to surgical care for podoconiosis remains limited, particularly in rural areas. This initiative aimed to decentralize nodulectomy services to primary health facilities to expand access and improve clinical outcomes.

Materials and Methods

In April 2025, trained mid-level healthcare workers across five health centers in Southern Ethiopia began performing nodulectomies. Data were collected from 93 patients who underwent surgery between April t December 2025. Variables included demographic and clinical characteristics, surgical process details, and post-operative outcomes. Descriptive statistics, bivariate tests, and multivariable models were used to evaluate predictors of wound infection and healing duration.



45 years old patient with podoconiosis before the surgery and 2 months after the surgery

Results

Among the 93 patients (mean age 48.1 years; 63% male), most were from Boreda district (88%). The majority (90%) required a single surgical session, with an average wound healing time of 20.8 days. Common pre-surgical concerns included difficulty walking (69%) and social stigma (58%).

The overall wound infection rate was low (5.4%) but differed significantly across health centers (**$p = 0.0003$**). Infection rates did not differ by sex or age. Healing duration was not significantly affected by infection status, number of sessions, or nodule site. However, **male patients had a significantly longer healing time by approximately 2.5 days** (**$p = 0.014$**). Other factors, including age and district, were not significant in the multivariable model.

Conclusions

Decentralizing nodulectomy for podoconiosis to primary healthcare facilities is feasible and effective, with generally favorable surgical outcomes and minimal complications. The statistically significant variation in infection

rates across centers underscores the need for continued quality assurance. The finding that male patients heal more slowly warrants further investigation. Ongoing investments in training, surgical supplies, and stigma reduction are essential to sustaining and scaling this intervention.

EADV CONGRESS
VIENNA
30 SEP - 3 OCT 2026

Abstract N°: 2628

Clinical Predictors of Surgical Margins in Mohs Micrographic Surgery for Basal Cell Carcinoma: A Single-Center Retrospective Study

Bingning Jiang*[1], Bingyu Li[1], Dian Chen[1], Yi Zhao[1]

[1] Beijing Tsinghua Changgung hospital, Beijing, China

Introduction
To analyze the distribution of surgical margin widths in patients undergoing Mohs micrographic surgery (MMS) for basal cell carcinoma (BCC) and identify associated clinical factors, aiming to inform preoperative assessment and surgical planning.

Materials and Methods
This single-center retrospective cohort study included 83 patients treated with MMS for histologically confirmed BCC at Beijing Tsinghua Chang Gung Hospital over the past five years. Demographic data, tumor characteristics, clinical presentation, prior interventions, and comorbidities were collected. Tumor locations were classified according to anatomical risk zones (H, M, L). The primary outcome was the surgical margin width (mm) during MMS. Descriptive statistics characterized margin distribution. Unsupervised clustering grouped patients by clinical phenotype, with intergroup differences compared. Supervised machine learning was applied to identify clinical factors associated with wider surgical margins.

Results
The median patient age was 72 years (IQR 69–79). Tumors predominantly involved the H zone (59/83, 71.1%), followed by M zone (20/83, 24.1%) and L zone (4/83, 4.8%). The median MMS margin width was 3.0 mm (IQR 2.0–3.0; range 1.0–8.0 mm). Unsupervised clustering identified two groups: Group A had significantly wider margins than Group B [3.0 mm (2.0–4.0) vs 2.0 mm (2.0–3.0), P=0.009]. Group A was more likely to present with ulceration and pain and to have prior biopsy or treatment (all $P<0.05$). Supervised analysis indicated that age positively correlated with margin width (Spearman r=0.292, P=0.008), and both sex (P=0.011) and pain (P=0.016) were significantly associated with margin width, whereas tumor size, disease duration, and anatomical risk zone showed no significant correlation (all $P>0.05$).

Conclusions
Surgical margin widths in BCC patients undergoing MMS vary considerably. Age, sex, and pain are associated with wider margins, while ulceration and prior interventions may further identify high-margin phenotypes. Preoperative evaluation of these clinical factors can optimize surgical strategy, resource allocation, and patient communication.

EADV CONGRESS
VIENNA
30 SEP - 3 OCT 2026

Abstract N°: 2673

The Importance of Mohs Micrographic Surgery in Evaluating the Subclinical Extension of Basal Cell Carcinomas

Marcus Studart Frota*[1], Isabela Guimarães[1]

[1] HUCFF-UFRJ, Rio de Janeiro, Brazil

Introduction

Basal cell carcinoma (BCC) is the most common skin cancer and is strongly associated with chronic ultraviolet (UV) exposure. The increasing prevalence of photodamage and aging populations has led to a growing incidence of multiple and recurrent BCCs, especially in anatomically critical areas such as the nose. Mohs micrographic surgery (MMS) has become the gold-standard treatment for high-risk BCCs because it allows complete intraoperative margin assessment while preserving healthy tissue. This case highlights the importance of MMS in detecting subclinical tumor extension not evident on clinical examination.

Case Presentation

A 65-year-old woman with extensive photodamage and a history of multiple basal cell carcinomas (BCCs) presented with two lesions on the nasal tip. The first lesion was an erythematous papule with a pearly appearance associated with polymorphic vessels and globules on dermoscopy. The second lesion was a hyperpigmented black papule with a central crust. Incisional biopsies confirmed the diagnosis of BCC in both lesions.

The patient underwent Mohs micrographic surgery with initial 2-mm margins. Intraoperative microscopic analysis demonstrated significant subclinical tumor extension. Lesion 2 required four Mohs stages to achieve tumor-free margins, while Lesion 1 required two stages. Progressive enlargement of the surgical margins resulted in confluence of both defects into a single operative wound. Reconstruction was performed using an H-plasty advancement flap (Hintala flap), achieving satisfactory functional and cosmetic outcomes.

This case demonstrates the ability of Mohs micrographic surgery to identify microscopic tumor spread not clinically visible, ensuring complete excision while maximizing tissue preservation in cosmetically sensitive areas, which would likely not be possible with conventional surgery.

Conclusion

Mohs micrographic surgery remains the gold-standard treatment for high-risk facial BCCs due to its superior margin control, high cure rates, and tissue-sparing approach. The technique is particularly valuable in anatomically and functionally critical areas where subclinical extension is common. This case reinforces the importance of MMS in the management of complex facial BCCs, highlighting its role in achieving optimal oncologic, aesthetic, and functional outcomes.

POWERED BY M-ANAGE.COM

EA DV CONGRESS
VIENNA
30 SEP - 3 OCT 2026

Abstract N°: 2754

Reconsidering Reconstructive Choice in Nasal Defects: A Systematic Review and Meta-Analysis of Local Flaps versus Full-Thickness Skin Grafts

Mohammed A. Zailai*[1], Osama Mobarki[1], Alaa Hakami[2]

[1] Jazan University, Faculty of medicine, Jazan, Saudi Arabia

[2] Department of Surgery, College of Medicine, Jazan University, Jazan, Saudi Arabia

Introduction

Nasal reconstruction after skin cancer excision remains challenging. Local flaps and full-thickness skin grafts (FTSG) are commonly used, but comparative outcomes remain inconsistent. This study evaluates cosmetic outcomes and complication rates between both techniques.

Materials and Methods

PRISMA-based systematic review and meta-analysis (PROSPERO: CRD420261363919). PubMed and Web of Science were searched up to March 2026. Four studies were included. Risk ratios (RR) with 95% CI were calculated using fixed- and random-effects models. Heterogeneity assessed using I^2.

Results

Cosmetic outcomes:

Pooled analysis using a fixed-effect model demonstrated significantly better cosmetic outcomes with local flaps (RR = 1.63, 95% CI: 1.28–2.08). However, this difference was not statistically significant under a random-effects model (RR = 1.63, 95% CI: 0.99–2.69; I^2 = 70.9%).

The apparent advantage of local flaps disappears when accounting for heterogeneity.

Complications:

Pooled analysis demonstrated no statistically significant difference in complication rates between techniques (RR = 0.53, 95% CI: 0.16–1.73; I^2 = 0%).

Key finding :

No reconstructive technique demonstrated consistent superiority.

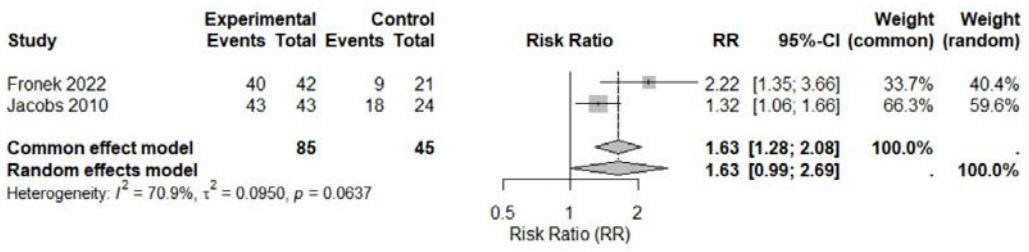

Figure: Forest plot comparing cosmetic outcomes between local flaps and full-thickness skin grafts.

Conclusions

Local flaps show a trend toward improved cosmetic outcomes, but this is not consistent when accounting for heterogeneity. Both techniques demonstrate comparable safety. Reconstructive decisions should be defect-driven rather than technique-driven.

EA DV CONGRESS
VIENNA
30 SEP - 3 OCT 2026

Abstract N°: 2777

Resource use in skin lesion excisions across dermatology and plastic surgery theatres: A comparative study

Alvin Leung*[1], Ocean Chan[1], Louis Naraine[2], Jessica Edwards[2], Daniel James Keith[2], Charankumal Thandi[2]

[1] Bristol Medical School, Bristol, United Kingdom
[2] North Bristol NHS Trust, Bristol, United Kingdom

Introduction
In many dermatology services, skin lesion excisions are performed by both dermatology and plastic surgery teams. Consequently, there may be different surgical equipment usage and staffing for the same procedure, raising questions regarding cost-efficiency. This study aimed to compare the costs of skin lesion excisions between the departments to explore savings and to improve sustainability and service capacity.

Materials and Methods
A cost-comparison analysis was performed using data collected at a regional dermatology centre in the United Kingdom. Varying surgical equipment use was observed in five dermatology surgery and five plastic surgery lists; this was recorded and compared with swab and instrument count sheets. Autoclaving and disposable instruments costs were acquired from the dermatology centre's sustainability management team. Staffing costs were calculated using the "NHS Agenda for Change" pay system and made on the assumption of each employee having completed over two years of service. Patient volumes for each operating list were obtained from Bluespier, a surgical patient booking system, and Careflow, an electronic reporting system. Mean case numbers were calculated over three months. To enable annual comparison, these figures were extrapolated based on an assumption of 46 operational weeks per year.

Results
Average dermatology surgery lists have five patients, while plastic surgery lists have four, showing 25% more output in dermatology surgery per operating space. After accounting for the number of operative spaces for both specialties, dermatology and plastic surgery were calculated to perform 2,760 and 5,520 skin lesion excisions per year, respectively. Dermatology surgical packs contained 6 fewer items requiring autoclaving, saving £7.38 per case. The unit cost of a disposable plastic surgery gown (£2.30) was about 14-fold higher than that of a dermatology disposable apron (£0.16). Extrapolating equipment figures over 5,520 plastic surgery cases suggested a potential saving of £52,550 per year in equipment should all of these cases be performed by dermatology instead. In the dermatology centre, plastic surgery theatres require nurses that are more senior with a higher salary when compared to dermatology surgery operating rooms, which translates to a difference of £11,198 per year in staffing costs, assuming that the nurses receive a full-time salary. The estimated total saving by having dermatology perform all skin lesion excisions is over £63,700 per year.

Conclusions
The dermatology outpatient surgery service at the regional dermatology centre in the United Kingdom showed an efficient model for skin lesion excisions. Both output and cost varied for the same procedure performed across

dermatology and plastic surgery, and optimising equipment usage and staffing allocation may offer the greatest potential for improvement. The utilisation of a standardised operating protocol that prioritises dermatology surgery operative spaces over those of plastic surgery in skin lesion excisions should also be considered to enhance efficiency and promote sustainability.

Limitations of the study include the small sample size (data from one regional dermatology centre with limited operative lists), assumptions made for annual data extrapolation, and lack of amendment for case complexity, as plastic surgery teams may perform excisions of a greater complexity and duration. This analysis could be expanded in the future to involve multiple hospitals to help investigate whether similar trends exist in different dermatology services, and to assess the need for wider procedural standardisation.

EADV CONGRESS
VIENNA
30 SEP - 3 OCT 2026

Abstract N°: 2822

Bilateral Axillary Tattoo Pigment Deposition Mimicking Metastatic Melanoma

Charlotte Meagher*[1], Ashley Costello[2], Peter Meagher[1]

[1] St Vincent's University Hospital, Dublin, Ireland
[2] Cork University Hospital, Cork, Ireland

Introduction

Tattoo pigment deposition within regional lymph nodes is a recognised phenomenon that may complicate melanoma staging. Migration of tattoo ink through dermal lymphatics can produce nodal pigmentation macroscopically indistinguishable from metastatic melanoma, creating a potential intraoperative diagnostic pitfall during sentinel lymph node biopsy. We present an unusual case of extensive bilateral axillary tattoo pigment deposition mimicking disseminated metastatic melanoma in a heavily tattooed patient undergoing melanoma staging.

Case Presentation

A 24-year-old male was referred with a biopsy-proven superficial spreading malignant melanoma arising within a benign compound naevus on the posterior thorax. Histopathology demonstrated a Breslow thickness of 1.0 mm, Clark level III, and AJCC stage pT1b disease. Following multidisciplinary discussion, the patient was scheduled for wide local excision and sentinel lymph node biopsy.

On the day of surgery, the melanoma site was injected with an intradermal tracer, and two draining sentinel lymph nodes were identified in the bilateral axillae. Exploration of the right axilla revealed several darkly pigmented lymph nodes, concerning for metastatic melanoma. Similar findings were identified in the contralateral axilla, raising suspicion of disseminated nodal disease. However, the patient was noted to have extensive tattooing across the thorax and abdomen, prompting consideration of tattoo pigment deposition.

Histopathological examination demonstrated preserved nodal architecture with pigment-laden macrophages and no evidence of metastatic melanoma on level sectioning or immunohistochemistry. No residual melanoma was identified in the wide local excision specimen.

Conclusion

Extensive tattoo pigment deposition may closely mimic disseminated nodal metastatic melanoma, particularly in heavily tattooed patients. Alternative causes of nodal pigmentation should be considered when assessing suspicious lymph nodes during melanoma staging. Awareness of this phenomenon is important to avoid misinterpretation of intraoperative findings and unnecessary escalation of surgical management. Histological confirmation, rather than macroscopic appearance alone, remains essential for accurate diagnosis.

POWERED BY M-ANAGE.COM

EADV CONGRESS
VIENNA
30 SEP - 3 OCT 2026

Abstract N°: 2893

Mohs Micrographic Surgery Utilization for Malignant Skin Tumors at Special Body Sites: A Single-Center Experience

Mariana Zamir*[1], Sivan Sheffer-Levi[2]

[1] Sheba Medical Center, School of Medicine, Faculty of Medical and Health Sciences, Tel Aviv University, Ramat Gan, Israel

[2] Hadassah Medical Center, Faculty of Medicine, The Hebrew University, Jerusalem, Israel

Introduction
Mohs micrographic surgery is widely accepted for treating skin cancers in cosmetically and functionally important areas, particularly the head and neck. However, its use on other anatomically sensitive sites - such as the genitalia and hand digits for example - is less frequently described. We present our institution's experience with Mohs micrographic surgery usage in these uncommon locations.

Materials and Methods
We conducted a retrospective review of patients treated with Mohs micrographic surgery for skin tumors located on special and sensitive body sites between July 1, 2022 and June 30, 2025. Collected data included patient demographics, tumor type and location, number of Mohs stages, reconstruction method, recurrence status and postoperative complications.

Results
A total of 20 cases were treated during the period. The main locations were male and female genitalia and hand digits. Tumor types included dermatofibrosarcoma protuberans (n=6), digital squamous cell carcinoma (n=7), penile intraepithelial neoplasia (n=4), vulvar basal cell carcinoma (n=1), genital extramammary Paget's disease (n=1) and malignant melanoma in situ (n=1). Margin clearance was achieved in up to four Mohs stages. Complex reconstruction using local flaps or grafts was performed in 20% of cases. Two recurrences were documented, no major complications were observed.

Conclusions
Mohs micrographic surgery is a safe and effective modality for the treatment of skin tumors on special body sites, offering precise margin control and maximal tissue preservation. Our experience supports the use of Mohs micrographic surgery in these challenging anatomical areas, with excellent oncologic and functional outcomes. Further studies may help refine treatment algorithms and reconstructive approaches for these rare but clinically significant presentations.

EA DV CONGRESS
VIENNA
30 SEP - 3 OCT 2026

Abstract N°: 2928

Reinforced Interpolation Flap with Cartilage Graft for Full-Thickness Nasal Defects following Mohs Surgery in Asian patients: A Case Series

Xin Yi Lee*[1], Hui Xin Seetow[1], Min Wee Chia[2]

[1] Yong Loo Lin School of Medicine, Singapore, Singapore
[2] National University Hospital, Singapore, Singapore

Introduction
Reconstruction of full-thickness nasal defects following Mohs micrographic surgery poses significant functional and aesthetic challenges, especially when essential structural components are compromised. Loss of the nasal framework often result in alar collapse and external nasal valve dysfunction. These challenges may be further exacerbated in Asian patients, whose nasal skin is typically thicker and more sebaceous, potentially affecting contour definition and cosmetic outcomes. Although interpolation flaps are traditionally used for large nasal defects, their application as foldover flaps for full-thickness nasal reconstruction is less commonly described, especially in the Asian population. Due to the characteristics of Asian skin, there remain concerns about its cosmetic suitability. This case series evaluates the use of interpolation flaps, combined with auricular cartilage grafts, as a foldover flap for reconstruction of full-thickness nasal defects in Asian patients.

Materials and Methods
A retrospective review was conducted on six Asian patients who underwent nasal reconstruction following Mohs surgery for non-melanoma skin cancer. All patients presented with full-thickness nasal defects involving the ala, sidewall or tip after Mohs surgery. Reconstruction was performed utilising interpolation flaps, reinforced by auricular cartilage harvested from the ipsilateral ear. The cartilage graft provided enhanced support to the nasal framework, maintaining nasal contour and external nasal valve patency following tumour extirpation. Photographic documentation, clinical and patient-reported outcomes were assessed over a 12-month follow-up period.

Results
All six patients achieved successful reconstruction with preserved nasal contour and patency of the external nasal valve. The flaps maintained viability with no necrosis or infection. Cartilage graft integration was successful, with no distortion or resorption observed. Despite theoretical concerns regarding skin texture and sebaceous mismatch in Asian patients, the flaps demonstrated favourable cosmetic integration and high patient satisfaction. No tumour recurrence was observed within the follow-up period. No revision surgery was performed.

Conclusions
Interpolation flaps reinforced with auricular cartilage grafting may be a useful and reliable option for reconstruction of full-thickness nasal defects following Mohs surgery in Asian patients. This approach offers high structural support and favourable cosmetic outcomes, reinforcing its value in complex nasal reconstructions. This technique may be particularly useful for Asian patients, bypassing difficulties presented by the sebaceous nature

of their skin and yielding satisfactory cosmetic results.

EADV CONGRESS
VIENNA
30 SEP - 3 OCT 2026

Abstract N°: 2950

IMAGE-GUIDED DERMATOLOGIC SURGERY: THE EVOLVING ROLE OF OPTICAL COHERENCE TOMOGRAPHY

Hiba Al-Rawi*[1]

[1] University of Exeter, Exeter, United Kingdom

Introduction
Optical coherence tomography (OCT) is a non-invasive imaging modality that enables real-time visualization of epidermal and dermal structures. Increasing interest in image-guided dermatologic surgery has expanded the role of OCT across diagnostic, perioperative and treatment-monitoring settings.

Materials and Methods
A literature review was conducted using PubMed and the TRIP database, focusing on studies published within the last 10 years. Clinical trials, randomized controlled trials and clinically relevant observational studies evaluating the use of OCT in dermatologic surgery were included.

Results
OCT demonstrated utility in multiple areas of dermatologic surgery, particularly in skin cancer assessment, preoperative tumour margin delineation and intraoperative support during Mohs micrographic surgery. Additional applications included evaluation of treatment response following laser therapy for acne scarring, assessment of hyperhidrosis and management of lentigo maligna. Reported advantages included real-time imaging, non-invasive assessment and the potential reduction of unnecessary biopsies or staged procedures. Current limitations include restricted imaging depth, reduced diagnostic performance in heavily pigmented lesions, cost and variability in image interpretation.

Conclusions
OCT represents a promising adjunctive technology in dermatologic surgery, with expanding applications in diagnosis, surgical planning and treatment monitoring. Further standardization, integration into clinical workflows and validation in larger, diverse patient populations are required to define its role in routine dermatologic surgical practice.

EADV CONGRESS
VIENNA
30 SEP - 3 OCT 2026

Abstract N°: 2955

High-risk nasal basal cell carcinoma with perineural invasion: multistage Mohs surgery and bilateral paramedian forehead flap reconstruction of a full-thickness defect

Marcelo Pacheco Silva*[1], Joana Margarida Reis[1], Ana Filipe Monteiro[1], João Goulão[1], João Alves[1]

[1] Unidade Local de Saúde Almada-Seixal, Almada, Portugal

Introduction

Basal cell carcinoma (BCC) of the nasal “H-zone” represents a high-risk entity due to its aggressive behavior, subclinical spread and functional and aesthetic implications. High-risk features, including infiltrative histology and perineural invasion, are associated with increased recurrence and demand optimal surgical management. Mohs micrographic surgery (MMS) provides complete margin control and is recommended as first-line treatment. Reconstruction of large, full-thickness nasal defects remains surgically challenging. We aim to present a complex case of high-risk nasal BCC highlighting the role of staged MMS and advanced reconstructive techniques in achieving oncological clearance and functional-aesthetic restoration.

Case Presentation

This is a case report of a 72-year-old woman who presented with a 15-year history of a progressively enlarging lesion on the left nasal sidewall extending to the alar groove. Clinical examination revealed a 22 × 16 mm infiltrated plaque with central retraction. Incisional biopsy demonstrated nodular and micronodular BCC with perineural invasion. Staged MMS was performed due to tumor extent and aggressive features. Reconstruction was planned following complete margin clearance.
Three delayed stages of MMS were required to achieve tumor clearance. Histopathology confirmed nodular, micronodular and infiltrative BCC with deep extension involving dermis, hypodermis, skeletal muscle and mucosal structures.
The final surgical defect measured approximately 39 × 39 mm and was full-thickness, involving the left nasal sidewall, ala and adjacent cheek.
Reconstruction was performed under local anesthesia using a right paramedian forehead flap for internal lining and a left paramedian forehead flap for external coverage. This approach allowed restoration of nasal structure and airway patency with satisfactory functional and aesthetic outcomes.

Conclusion

This case illustrates the aggressive potential of long-standing BCC with multiple high-risk features, including perineural invasion and deep tissue involvement. MMS remains the gold standard for achieving complete tumor clearance in such scenarios.
Extensive full-thickness nasal defects require a layered reconstructive approach. The bilateral paramedian forehead flap represents a reliable and versatile option, enabling simultaneous restoration of internal lining and external coverage.
An integrated oncologic and reconstructive strategy is essential to optimize outcomes in complex nasal BCC.

EADV CONGRESS
VIENNA
30 SEP - 3 OCT 2026

Abstract N°: 2969

Handheld Reflectance Confocal Microscopy–Guided Margin Mapping for Recurrent Facial Lentigo Maligna

Federico Venturi*[1], Emy Dika[1]

[1] Università di Bologna, Department of Medical and Surgical Sciences, Bologna, Italy

Introduction

Lentigo maligna (LM) poses significant management challenges when recurrent, owing to post-surgical scarring and subclinical tumor extension that limit reliable clinical margin assessment.
In this prospective, single-center study, we evaluated the impact of handheld reflectance confocal microscopy (HH-RCM) on pre-surgical margin delineation and surgical outcomes in patients with recurrent facial LM.

Materials and Methods

Adults previously treated with complete surgical excision of facial LM who developed a histologically confirmed recurrence at the same anatomical site within 24 months were enrolled. Recurrent LM was defined as a new lesion arising after a disease-free interval and confirmed by biopsy or excision. Patients were managed either with HH-RCM-guided margin mapping (n = 21) or with standard clinical and dermoscopic assessment alone (n = 33). In the HH-RCM group, tumor margins were systematically mapped using a standardized adhesive tape technique to delineate the outermost confocal extension of LM prior to surgery. Surgical margins were verified by permanent-section histopathology in all cases. The primary outcome was the rate of invasive reconstruction, while secondary outcomes included post-clearance defect size and local recurrence at 12 months.

Results

Complete margin clearance in a single surgical stage was achieved more frequently in the HH-RCM group (85.7%) compared with the clinical group (60.6%). HH-RCM mapping resulted in significantly smaller surgical defects (mean diameter 1.7 ± 0.6 cm vs 2.4 ± 0.8 cm; $p < 0.01$) and a reduced need for invasive reconstructive procedures (28.6% vs 60.6%; $p = 0.009$). Local recurrence rates at 12 months were low and comparable between groups (4.7% vs 6.1%).

Conclusions

HH-RCM-guided margin mapping improves surgical planning in recurrent facial LM by enabling precise delineation of subclinical tumor extension, allowing more conservative resections and reducing reconstructive burden without compromising short-term oncologic control.

EADV CONGRESS
VIENNA
30 SEP - 3 OCT 2026

Abstract N°: 2975

An unexpected spark; complication of topical haemostatic use in skin surgery

Sumbel Khan*[1], Anastasia Therianou[2]

[1] Imperial College Healthcare NHS Trust, Imperial College London, London, United Kingdom
[2] Imperial College, London, Private Clinic London, London, United Kingdom

Introduction
Topical haemostatic and antiperspirant preparations containing aluminium chloride are commonly used in clinical practice for control of minor bleeding and hyperhidrosis. Driclor is a commonly used agent and contains Alcohol and Aluminium Chlroride and therefore potentially flammable, creating an under-recognised fire risk in procedural settings where electrocautery or other ignition sources are present.

Case Presentation
We report a case of an operating room fire associated with the use of a topical aluminium chloride preparation (Driclor) applied to gauze for haemostasis during a minor procedure. Shortly after application, the gauze ignited following exposure to an ignition source within the procedural field. The fire was rapidly extinguished, preventing significant patient harm. The attending doctor sustained minor superficial burn injuries to the hand, requiring only basic first aid and no time away from work. No long-term sequelae occurred.

Conclusion
This incident highlights the potential flammability hazards associated with alcohol-containing aluminium chloride solutions when used in environments involving heat or electrical equipment. Although aluminium chloride itself is not inherently combustible, the solvent vehicle used in commercial preparations may be highly flammable. Inadequate awareness of this risk may contribute to preventable operating room fires. Consideration should be given to allowing complete evaporation prior to proceeding, avoiding pooling on gauze or drapes, and using non-flammable alternatives where ignition sources are present.Clinicians should be aware that topical aluminium chloride preparations such as Driclor may pose a fire risk in procedural and operative environments due to their alcohol content. Increased awareness, clearer labelling, and adherence to fire safety precautions may help prevent similar incidents.

EADV CONGRESS
VIENNA
30 SEP - 3 OCT 2026

Abstract N°: 3088

Results of Mohs Micrographic Surgery at Hospital Universitario Araba: Our Experience Over Five Years

Javier Gimeno Castillo*[1], Mathilde Ramirez[1], Andrea Berrueta Navascues[1], Jone Lopez[1], Amaia Barrutia[1], Nicolas Ramirez-Escudero[1], Zuriñe Martinez-de-Lagran[1], LUCIA CARNERO GONZALEZ[1], RICARCO GONZALEZ PEREZ[1]

[1] Hospital Universitario Araba, Vitoria, Spain

Introduction

Introduction

Mohs micrographic surgery (MMS) is a specialized surgical technique for the excision of cutaneous tumors that provides high cure rates while maximizing tissue preservation. The indications with the strongest scientific evidence are basal cell carcinoma and squamous cell carcinoma. Other indications include dermatofibrosarcoma protuberans (DFSP), microcystic adnexal carcinoma, extramammary Paget disease (EMPD), and lentigo maligna.

Materials and Methods

Materials and Methods

The aim of this study is to present the outcomes of this surgical technique in patients treated over the last five years in the Department of Dermatology at Hospital Universitario Araba. We conducted a retrospective study using data collected from the medical records of all patients who underwent MMS between 2020 and 2024. All procedures were performed by a dermatologist with the assistance of a dermatopathologist.

Results

Results

A total of 124 MMS procedures were performed, of which 96% were basal cell carcinomas. Facial localization accounted for 98% of cases. Fifty-five percent of tumors were recurrent (previously operated on). The most common reconstruction techniques were flaps (35%), primary closure (32%), grafts (25%), or a combination of the above. The recurrence rate was 0.04% during five years of follow-up, and the complication rate was 2%, with the most frequent complications being wound dehiscence and surgical site infection.

Conclusions

Conclusions

The five-year recurrence rate observed in our patients (0.04%) was lower than that reported in previous studies, while the complication rate was similar to published data (2–3%).

In conclusion, our series confirms that MMS offers lower recurrence rates for high-risk tumors, maximal tissue preservation in cosmetically and anatomically sensitive areas, and immediate reconstruction in most cases.

EADV Congress 2026, VIENNA
30 SEPTEMBER - 03 OCTOBER 2026
POWERED BY M-ANAGE.COM

EADV CONGRESS
VIENNA
30 SEP - 3 OCT 2026

Abstract N°: 3280

Outcomes for patients with Melanoma-In-Situ: A Retrospective Observational Study

Karisma Sharma*[1], Danning Li[2], Neenu Sebastian[1], Maryam Salimi[3], Mun-Wai Lam[1], Kashini Andrew[4]

[1] Queen Elizabeth Hospital, University Hospitals Birmingham NHS Trust, Birmingham, United Kingdom
[2] Warwick Dermatology Centre, South Warwickshire NHS Foundation Trust, Warwick, United Kingdom
[3] Solihull Hospital, University Hospitals Birmingham NHS Trust, Birmingham, United Kingdom
[4] Faculty of Medicine and Dentistry, Department of Medicine, Division of Dermatology, University of Alberta, Edmonton, Canada

Introduction

Melanoma-in-situ (MIS) represents a significant burden of cancer in the United Kingdom, with approximately 17,600 cases diagnosed annually [1,2]. National guidelines recommend a wide local excision (WLE) margin with at least 5mm clinical margins for in-situ disease, however evidence on optimal margins to reduce the risk of recurrence remains limited [3-6]. Increasing evidence suggests that excisional biopsies with clear margins may be sufficient in selected cases [7]. This study evaluated histopathological margins and recurrence in patients managed with and without WLEs for MIS at a tertiary centre in the United Kingdom (UK).

Materials and Methods

This retrospective observational study included all patients diagnosed with MIS between 2021 and 2022. Patients who did and did not undergo WLE were included. Data was collated from electronic patient records including clinic letters, multidisciplinary (MDT) meeting documents and histopathology reports. Variables collected included patient demographic (age and gender), lesion subtype, anatomical site, histopathological margins and outcomes (recurrence or metastasis). Descriptive statistical analysis was performed. Due to the noninterventional retrospective nature of the study and use of deidentified data, formal research ethical committee approval was not required in accordance with the UK Health Research Authority (HRA) decision tool, and the project was registered in as a service evaluation in line with local governance procedures.

Results

25 patients underwent WLE for MIS, including five patients with the lentigo maligna (LM) sub-type, with a mean age of 67 years. Lesions were most located on limb extremities (n= 13), head and neck (n= 7) or trunk regions (n= 5). A 5mm clinical margin was used in most cases, achieving a mean histopathological margin of 5.1mm (range 1mm – 11.5mm). One lesion had a target clinical margin of 10mm, achieving a mean histopathological margin of 2mm. Residual disease following excision biopsy was identified in five specimens, four with LM and one with non-LM lesions. WLE achieved histopathological clearance for all 25 patients. One case of local recurrence (5%) was identified in a non-LM lesion and no metastatic disease was observed. Three patients did not undergo WLE and had a median follow up duration of seven months: one was offered slow Moh’s surgery, one patient died prior to intervention, and in one case, the MDT recommended no further excision following a histopathological 3 mm margin. Among these cases, two had non-LM, one had LM. No recurrence was seen during follow-up.

Conclusions

Histopathological clearance was achieved for all lesions despite variations in margin, reflective of surgical restrains and anatomical site. Surgical management of MIS includes surgical excision (WLE) or margin-controlled techniques, such as Mohs micrographic and staged excision ("Slow Mohs"), particularly for LM which is associated with subclinical spread [4-5]. Alternative treatments, including topical imiquimod and radiotherapy, may be considered where surgical risk is unacceptable [3-5]. Lesions in anatomically sensitive areas, particularly the head and neck, may benefit from reduced margins to decrease morbidity [8]. LM is associated with higher recurrence rates [5-6, 9]. These findings contribute to the evidence base suggesting that patients with LM managed without WLE may not necessarily experience early recurrence when histopathological margins are clear. A cohort study of patients with non-LM lesions demonstrated no local recurrence, metastasis or melanoma-related mortality following excision biopsy in patients with histopathological clear margins [7]. Limitations include the small sample size and retrospective design limiting further statistical analysis, as well as the potential effects of the Covid-19 pandemic on capturing cases and underrepresentation of community-managed cases. Large prospective studies are required to define optical surgical margins.

EADV CONGRESS
VIENNA
30 SEP - 3 OCT 2026

Abstract N°: 3364

Local anesthetic dose for skin tumor excision

Yoko Akamatsu*[1], Toshihiko Morinaga[2]

[1] Japan Community Health Care Organization(JCHO) Shimonoseki Medical Center, Dermatology, Shimonoseki City, Japan
[2] Japan Community Health Care Organization(JCHO) Shimonoseki Medical Center, Anesthesiology, Shimonoseki City, Japan

Introduction

Dermatologists frequently administer local anesthesia for skin biopsies and minor surgeries; however, because lidocaine infiltration anesthesia is painful, pain should be minimized as much as possible. Knowledge of the appropriate dosage is essential for adequate infiltration anesthesia. While many reports have examined the maximum doses of local anesthetics, few reports have examined the relationship between skin tumor excision and the amount of local anesthetic used.

Therefore, in 2023, based on an analysis of 19 patients, we reported the approximate formula y = 0.0101ab, where y represents the volume of 1% lidocaine (mL), a represents the longest diameter of the excision area (mm), and b represents the maximum diameter perpendicular to a (mm). Because of the small sample size, we conducted a study with a larger sample size.

Materials and Methods

From January 2023 to December 2025, we retrospectively examined the amount of local anesthetic (1% lidocaine containing epinephrine diluted 1:100,000) used for infiltration anesthesia during skin tumor excision in our department, based on surgical records.

Results

We analyzed 147 cases (72 men and 75 women) . The patients' ages ranged from 9 to 101 years, with a mean age of 75 years. The analysis included 147 skin tumors (62 of squamous cell carcinoma, 36 basal cell carcinoma, 3 malignant melanoma, 1 T-cell lymphoma, 10 seborrheic keratosis, 7 melanocytic nevus, 6 hemangioma, 5 verruca vulgaris, and 17 other benign tumors). The procedures were performed by seven surgeons (dermatologists with 3 to 32 years of experience).

Let y denote the volume of 1% lidocaine (mL), a denote the major axis of the resected tumor (mm), and b denote the maximum diameter perpendicular to a (mm). The approximate equation was y = 0.0052ab + 0.7666(Figure 1).

Next, we analyzed the data by body region. The results for the cheeks (28 cases), nose (22 cases), eyelids (10 cases), head (18 cases), limbs (32 cases), and trunk (9 cases) were as follows: cheeks: y = 0.0038ab + 0.7153; nose: y = 0.0066ab + 0.2864; eyelids: y = 0.0062ab + 0.1564; head: y = 0.0060ab + 1.0343; limbs: y = 0.0072ab + 0.5558; trunk: y = 0.0030ab + 1.8808.

Although these values are not intuitive to calculate, referring to the scatter plot and considering the range of y =

0.005ab to 0.01ab—that is, 0.5 to 1 mL per cm^2—facilitates determination of the appropriate dose of local anesthetic in clinical practice.

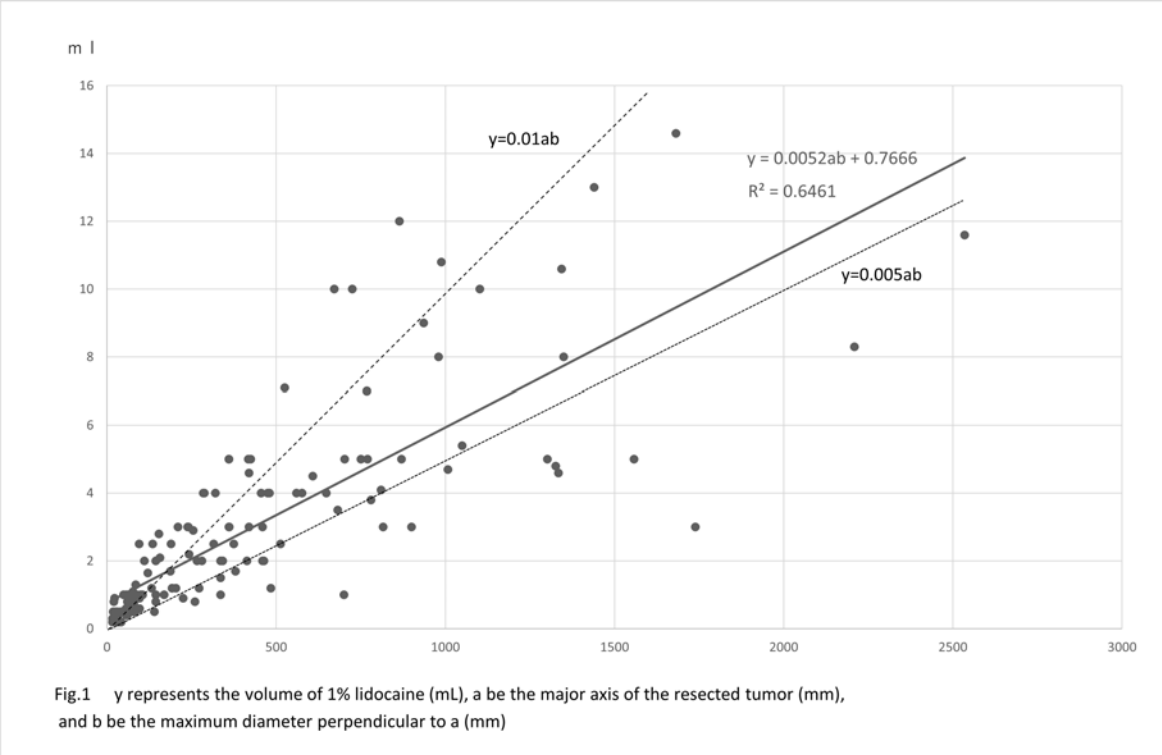

Fig.1 y represents the volume of 1% lidocaine (mL), a be the major axis of the resected tumor (mm), and b be the maximum diameter perpendicular to a (mm)

Fig.1 y represents the volume of 1% lidocaine (mL), a be the major axis of the resected tumor (mm), and b be the maximum diameter perpendicular to a (mm)

Conclusions

When performing skin tumor excision, using 0.5 to 1 mL of local anesthetic per 1 cm^2 of tumor size provides a simple and effective method for pain relief.

EA DV CONGRESS
VIENNA
30 SEP - 3 OCT 2026

Abstract N°: 3532

COMPLEX FULL-THICKNESS NOSE RECONSTRUCTION AFTER MOHS SURGERY FOR RECURRENT AGGRESIVE BASAL CELL CARCINOMA

Marian-Aurelian Closca*[1], Teodora Ruxandra Nestian[1], Andreea Daniela Cretu[2], Stefania Teodora Buzatu[1], Konstantinos Koutsioukis[3]

[1] Colentina Clinical Hospital, Bucharest, Romania

[2] Carol Davila Military Hospital, Bucharest, Romania

[3] Dermashape Clinic, Bucharest, Romania

Introduction

Basal Cell Carcinoma (BCC) is the most common keratinocyte-derived skin cancer and when located in cosmetically sensitive areas should ideally be treated using Mohs micrographic surgery (MMS) since it spares the tissue and offers best esthetic outcomes and lowest reccurence rates. Following complete tumor excision, reconstruction of the resulting defect may be technically challenging and requires a high level of surgical expertise. Nasal reconstruction can be achieved through multiple techniques, some of which are complex and time-consuming, yet provide superior aesthetic and functional outcomes

Case Presentation

We present the case of a 68-year-old female diagnosed with recurrent infiltrative and nodular basal cell carcinoma involving the anteroinferior region of the nose. The patient had previously undergone conservative treatment with 5-Fluorouracil, including with clinical and dermoscopic recurrence five years apart from the initial treatment. She was subsequently referred to our clinic for MMS since it was a reccurent aggressive BCC. The lesion macroscopically involved both alae nasi and the columella. Histopathological examination of frozen sections revealed tumor extension into the right septal mucosa and philtral region, without evidence of perineural invasion, vascular invasion, or cartilage destruction. Tumor-free margins were achieved after two stages of MMS.

The resulting defect was complex, involving both alae nasi, the columella, the anterior portion of the nasal vestibule. Bilateral cutaneous hinge flaps were used for the continuity of mucosal lining. Reconstruction of the columella and alar cartilages was achieved using auricular cartilage grafts harvested from the right ear (conchal bowl and antihelix). The cartilage was sculpted into two perpendicular components: one for columellar support and the other for reconstruction of the alar cartilages. Cutaneous reconstruction was subsequently performed using a pedicled paramedian forehead flap to provide optimal vascular support for the cartilage grafts.

Division of the forehead flap pedicle was performed three weeks postoperatively. All flaps remained viable, the cartilage grafts maintained adequate positioning, and both functional and aesthetic outcomes were considered satisfactory by both the patient and the surgical team.

Conclusion

We report a challenging case of full-thickness nasal reconstruction following MMS for recurrent

aggressive BCC, treated initially with topical chemotherapy. The reconstruction combined three local flaps (bilateral cutaneous hinge flaps for mucosal lining and a pedicled paramedian forehead flap) with auricular cartilage grafting, achieving favorable aesthetic and functional outcomes.

EA DV CONGRESS
VIENNA
30 SEP - 3 OCT 2026

Abstract N°: 3592

Combining the Limberg and Dufourmentel techniques - for reconstruction of primary defects following skin cancer excision in the zygomatic region: optimal final dermatosurgical results in an 82 years old lady

Georgi Tchernev[1, 2], Konstantin Tchernev Jr[2], Simona Kordeva*[1]

[1] Medical Institute of Ministry of Interior - Department of Dermatology and Venereology, Sofia, Bulgaria
[2] Onkoderma- Clinic for Dermatology, Venereology and Dermatologic Surgery, Sofia, Bulgaria

Introduction

Skin cancer in the zygomatic region can be reconstructed with different reconstructive techniques, such as transposition, rotation-advancement and rhomboid flaps. The Limberg (rhomboid) flap present the most utilized technique in the region. The Dufourmentel flap is a variation to the classical Limberg flap, and can also be employed.

Case Presentation

We present a case involving a medium-sized defect on the zygomatic subunit following surgical excision of a cutaneous lesion within the right cheek unit (figure a). Reconstruction was performed using a full-thickness modified rhomboid transposition flap, with an irregular rhombus design tailored to the patient's specific defect, combining the advantages of both the Limberg and Dufourmentel flaps to achieve a more patient-orientated approach (Figure b,c).

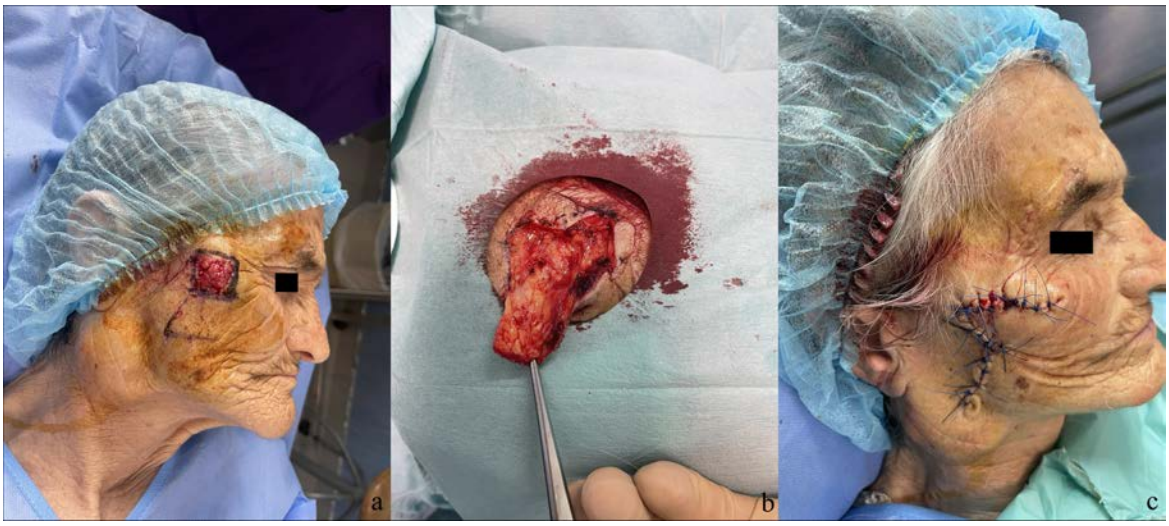

Figure a-c: (a) An achromatic tumorous lesion, measuring 1.5 cm x 1.5 cm, protruding above the surrounding skin, covered with hemorrhagic crust, irregular borders, located in the right zygomatic region. Additionally, a solitary formation is observed in the right parotid region, suspected to represent a lymph node conglomerate. (b) The designed flap base is carefully undermined and elevated in the subcutaneous plane. (c) The resulting secondary defect is subsequently closed using single interrupted sutures.

Conclusion

Modifications to the Dufourmentel flap have been reported to yield improved outcomes compared to the classical design, although these techniques have been predominantly applied to the extremities rather than the facial region, as in the present case. Modifications of both designs may allow for further refinement of the technique and improved postoperative outcomes, including enhanced wound healing and a potentially reduced risk of recurrence.

The modified technique employed an irregular rhombus, approaching a square configuration without strict geometric angles, in order to preserve as much tissue as possible. In addition, the flap differed from the classical Dufourmentel approach by utilizing the long diagonal, as in the classic Limberg flap. By integrating these features, a modified rhomboid transposition flap was achieved, combining both classical techniques and allowing for a more patient-orientated approach.

EA DV CONGRESS
VIENNA
30 SEP - 3 OCT 2026

Abstract N°: 3600

Auricular Reconstruction Using Posterior Auricular Sulcus Full-Thickness Skin Grafts: A Two-Case Report

Bianca Miyazawa*[1], Joao Marcos de Souza[1], Barbara Messias Pereira[1], Rogerio Kondo[1], Amanda Alencar dos Anjos[1], Marcos Vinícius Borges Martins[1], Karoline Rodrigues Crevelim[1]

[1] State University of Londrina, Londrina, Brazil

Introduction

Basal cell carcinoma (BCC) and squamous cell carcinoma (SCC) are the most common skin cancers. Reconstruction of defects involving the upper third of the auricle may be challenging due to the complex three-dimensional anatomy, scarcity of adjacent tissue, and the presence of natural grooves and depressions. Although local flaps are often preferred, they may require more complex or staged procedures. Full-thickness skin grafts represent a valuable alternative; however, donor-site selection is essential to optimize contour, texture, and color match. We report two cases reconstructed with full-thickness skin grafts harvested from the posterior auricular sulcus, achieving favorable aesthetic outcomes.

Case Presentation

Two patients with basal cell carcinoma involving the upper third of the right auricle underwent surgical excision followed by reconstruction using full-thickness skin grafts harvested from the posterior auricular sulcus.

Patient 1 was a 76-year-old man, phototype III, presenting with a 12-mm nodular BCC involving the scaphoid fossa, helix, superior and inferior crus of the antihelix, and triangular fossa. Excision with 3-mm margins resulted in an 18-mm defect.

Patient 2 was an 81-year-old woman, phototype II, presenting with a 15-mm erythematous scaly plaque involving the scaphoid fossa, superior and inferior crus of the antihelix, and triangular fossa. Histopathology confirmed SCC in situ. Excision with 3-mm margins resulted in a 21-mm defect.

In both cases, the procedures were performed under local anesthesia with 2% lidocaine. After tumor excision down to the cartilage level, full-thickness skin grafts harvested from the posterior auricular sulcus were positioned over the recipient sites and secured with cardinal and simple interrupted 5-0 nylon sutures, followed by Brown’s tie-over dressing. Donor sites were primarily closed.

Both patients had an uneventful postoperative course with satisfactory graft integration and favorable wound healing. Good aesthetic outcomes were observed, with adequate adaptation of the grafts to the local auricular contours and minimal donor-site morbidity.

Conclusion

Auricular reconstruction remains challenging due to the need to preserve both structural integrity and symmetry. Although wedge excision and interpolation flaps may be employed for upper auricular defects, these techniques can result in asymmetry or require staged procedures.
The posterior auricular sulcus represents an excellent donor site for full-thickness grafting because it provides thin skin with limited photodamage and appropriate texture for the auricular region. In addition, donor-site scars remain well concealed within the natural posterior auricular fold. In the presented cases, grafts adapted well to the complex topography of the upper auricle, including depressions and grooves, with satisfactory cosmetic outcomes.
Full-thickness skin grafts harvested from the posterior auricular sulcus may represent an effective reconstructive option for defects involving the upper third of the auricle, providing favorable cosmetic integration and low donor-site morbidity.

EADV CONGRESS
VIENNA
30 SEP - 3 OCT 2026

Abstract N°: 3636

Is surgical excision necessary for histologically proven cutaneous squamous cell carcinoma with a clinically resolved biopsy site?: A retrospective cohort UK study

Sara Lupita O'Kelly*[1], Sanchita Thakur[1], Feroza Ahmad[1], Emma Brew[1], Andrew Birnie[1]

[1] East Kent Hospitals University NHS Foundation Trust, Canterbury, United Kingdom

Introduction

Current treatment of cutaneous squamous cell carcinomas (cSCCs) mostly involves surgical excision, with few studies examining tumours managed by watchful waiting when the lesion resolves following biopsy or curettage and cautery.[1]

Squamous cell carcinoma (SCC) is a non-melanoma skin cancer (NMSC), and the second most common type of skin cancer in the UK. NMSC currently accounts for 20% of all cancers. National Disease Registration Service (NDRS) demonstrates that there were 224,000 skin cancers in England in 2019 and over 1.4 million skin cancers between 2013-2019. This makes skin cancer the most common cancer diagnosed in the UK. The data shows that the incidence of skin cancer has increased from 177,677 in 2013 to 224,092 in 2019, a 26.1% increase over six years. There were 47,977 cutaneous squamous cell carcinomas (cSCC) in 2019, up from 34,672 in 2013. Worldwide data on squamous cell carcinoma incidence indicates a rising trend, particularly in regions with high sun exposure and aging populations seen throughout Europe.

Materials and Methods

Aims: To describe oncologic outcomes for patients diagnosed with biopsy proven cSCC that clinically resolved at follow-up and subsequently managed conservatively.

Methods: A single-centre, retrospective cohort study including patients with histopathologically confirmed SCCs, with no residual tumour clinically apparent, managed by a watchful waiting approach over a 5-year period (September 2020 to August 2025) in South East England, United Kingdom.

Results

A total of 535 patients had biopsy proven invasive SCCs (as opposed to the majority who were referred directly for surgical excision). The most common site was head and neck, with mean age of 81 years, and two-thirds were male. The majority of the lesions were well (17%) to moderately (50%) differentiated tumours.

One fifth were managed with watchful waiting and the majority (95%) had specialist skin cancer nurse follow up with no recurrence. The remaining patients either passed away from unrelated

causes (5%) or were lost to follow up (1%). 68% had curative intent curettage and cautery, whilst the remaining 32% had diagnostic biopsies. Of these, 59% were punch and 41% were curette.

The majority of patients (79%) had further surgical excision and one-third were deemed high risk based on British Association of Dermatologists guidelines.[2] Only one-third had residual tumour in the surgical specimen, with the others containing scar tissue or actinic keratoses. Of this cohort, only 1% (n=4) recurred, with one having involved margins on re-excision and requiring adjuvant radiotherapy.

Conclusions

These local recurrence rates compare very favourably to reported recurrence for surgically managed SCCs. Additionally, recent studies have demonstrated that well-differentiated cSCCs may spontaneously resolve following partial, diagnostic biopsy more often than previously reported.[3] These findings have implications when considering treatment options, especially among frail elderly patients with comorbidities. We therefore propose a watchful waiting approach for the management of clinically resolved, low risk lesions in appropriate cases thus reducing unnecessary patient morbidity and utilising resources more efficiently

EADV CONGRESS
VIENNA
30 SEP - 3 OCT 2026

Abstract N°: 3644

Post-surgical laser treatment for scar optimisation in Asian skin

Naomi Chia*[1], Paul Min Wee Chia[2]

[1] Yong Loo Lin School of Medicine, National University of Singapore, Singapore, Singapore
[2] Division of Dermatology, National University Hospital, Singapore, Singapore

Introduction
Skin of colour or Asian skin is predisposed to post-inflammatory hyperpigmentation and scarring, particularly following post-surgical laser treatment. Inappropriately selected laser parameters, such as high fluence, high density or low pulse duration, can result in bulk dermal heating and increased skin discolouration. Despite these risks, evidence guiding post-surgical laser scar management in skin of colour is limited, with most data focused on fair skin. The objective is to evaluate the safety and clinical outcomes of early post-surgical laser intervention in Asian patients and to propose practical laser parameter strategies for scar optimisation while minimising pigmentary complications.

Materials and Methods
Eight Asian patients aged 25–62 years with Fitzpatrick skin types III–V underwent post-surgical laser treatment following excision of benign lesions, scar revision, or Mohs micrographic surgery for skin cancers. Laser treatment was initiated immediately after suture removal, followed by 3 laser sessions at monthly intervals. Treatment consisted of 595nm pulsed dye laser (PDL) with short pulse width (1.5-3 milliseconds) and moderate fluence (4-6.5J/cm2), combined with fractional CO2 at high energy and low density (HELD) settings. Photographic documentation, clinical and patient-reported scar outcomes were assessed 6 months post-surgery.

Results
Seven cases demonstrated excellent results with clinically imperceptible scars. One case showed a moderate result with improvement but still perceptible scar. Of note, this patient had a large right alar defect after Mohs surgery, and needed a flap repair with high wound tension. Other than that, no cases of post-inflammatory hyperpigmentation or scar worsening were observed.

Conclusions
Early, appropriately parameterised post-surgical laser treatment is safe and effective for scar improvement in Asian skin. Early laser therapy using pulsed dye laser at moderate fluence combined with high-energy, low-density fractional CO_2 laser led to significant scar improvement without pigmentary adverse effects. Nonetheless, meticulous surgical technique, particularly low-tension closure, remains essential for optimal outcomes.

EADV CONGRESS
VIENNA
30 SEP - 3 OCT 2026

Abstract N°: 3647

Management of Pincer Nail Deformity Through Nail Bed Plasty with Osteophyte Excision and Double-Z Plasty

Naomi Chia*[1], Paul Min Wee Chia[2]

[1] Yong Loo Lin School of Medicine, National University of Singapore, Singapore, Singapore

[2] Division of Dermatology, National University Hospital, Singapore, Singapore

Introduction

Pincer nail deformities present as excessive transverse curvature of the nail plate, leading to compression of the nail bed and surrounding soft tissue. This condition causes functional limitations, significant pain and cosmetic concerns. Conservative treatment may provide temporary relief. However, most cases, especially those severe and recurrent, require definitive surgical correction. Nevertheless, many existing surgical methods fail to address the underlying pathology, leading to high recurrence rates, or have suboptimal aesthetic outcomes. The objective was to present a surgical approach combining nail avulsion, osteophyte removal, and double Z-plasty nail bed repair for the correction of pincer nail deformities and to report the clinical and cosmetic outcomes.

Materials and Methods

Between 2023 and 2024, three patients with severe hallux pincer nails, pain rating 7–8/10, nail widths 6–12 mm, and prior conservative treatment failure, underwent surgery with the proposed techniques. Clinical assessment, photographic documentation, and patient-reported outcomes were recorded over six months.

Results

All patients reported pain relief and functional improvement within four weeks. Nail regrowth demonstrated normal curvature, and cosmetic outcomes were rated highly by patients. No postoperative complications or revisions were required.

Conclusions

This combined surgical approach is safe and effective for correction of severe pincer nail deformities with long-term beneficial outcomes. By addressing nail plate, soft tissue, and bony abnormalities, the technique preserves nail function while achieving favourable aesthetic results.

EA DV CONGRESS
VIENNA
30 SEP - 3 OCT 2026

Abstract N°: 3654

Can´t you see? It's a Cupids Bow BCC!

Simona Kordeva*[1], Konstantin Tchernev Jr[2], Georgi Tchernev[1, 2]

[1] Medical Institute of Ministry of Interior - Department of Dermatology and Venereology, Sofia, Bulgaria
[2] Onkoderma- Clinic for Dermatology, Venereology and Dermatologic Surgery, Sofia, Bulgaria

Introduction
Epithelial tumors, and in particular BCC, extremely rarely affect the area known as Cupids bow, and their treatment remains a serious challenge. The Cupid's bow is the double curve of the upper lip.
The typical treatment for BCC is a standard resection with postoperative marginal assessment, either with Mohs micrographic surgery or standard surgical excision. Additionally, topical chemotherapy/immunotherapy (with 5-fluorouracil or imiquimod), photodynamic therapy could be applied, however recurrences are high.
Expandable plastic surgery with or witout flap reconstruction seems to be suitable for that region.

Case Presentation
We present a 53-year-old patient with a history of painful sunburns in the past and basal cell carcinomas of the neck, successfully treated surgically. The reason for the hospitalization was the appearance of a new nodular achromic lesion in the area of ″Cupid's bow″ (upper lip) (Figure 1 a-c), which preoperatively was verified histopathologically as basal cell carcinoma.



Fig 1a/1b: Achromictumourous formation in the area of the upper lip or the so-called Cupids bow. Fig 1c: Preoperative marking of the resection lines before anesthetic administration.

Conclusion
Elliptical excision under local anesthesia was performed (Figure 2a), and the resulting defect was closed using an undermining surgical approach, followed by single skin sutures (Figure 2b). The patient's 4-month follow-up was

uneventful with no evidence of recurrence (Figure 2c,d).

Treatment options for basal cell carcinomas in the area of Cupid's bow and the advantages of elliptical excision in the area are presented.

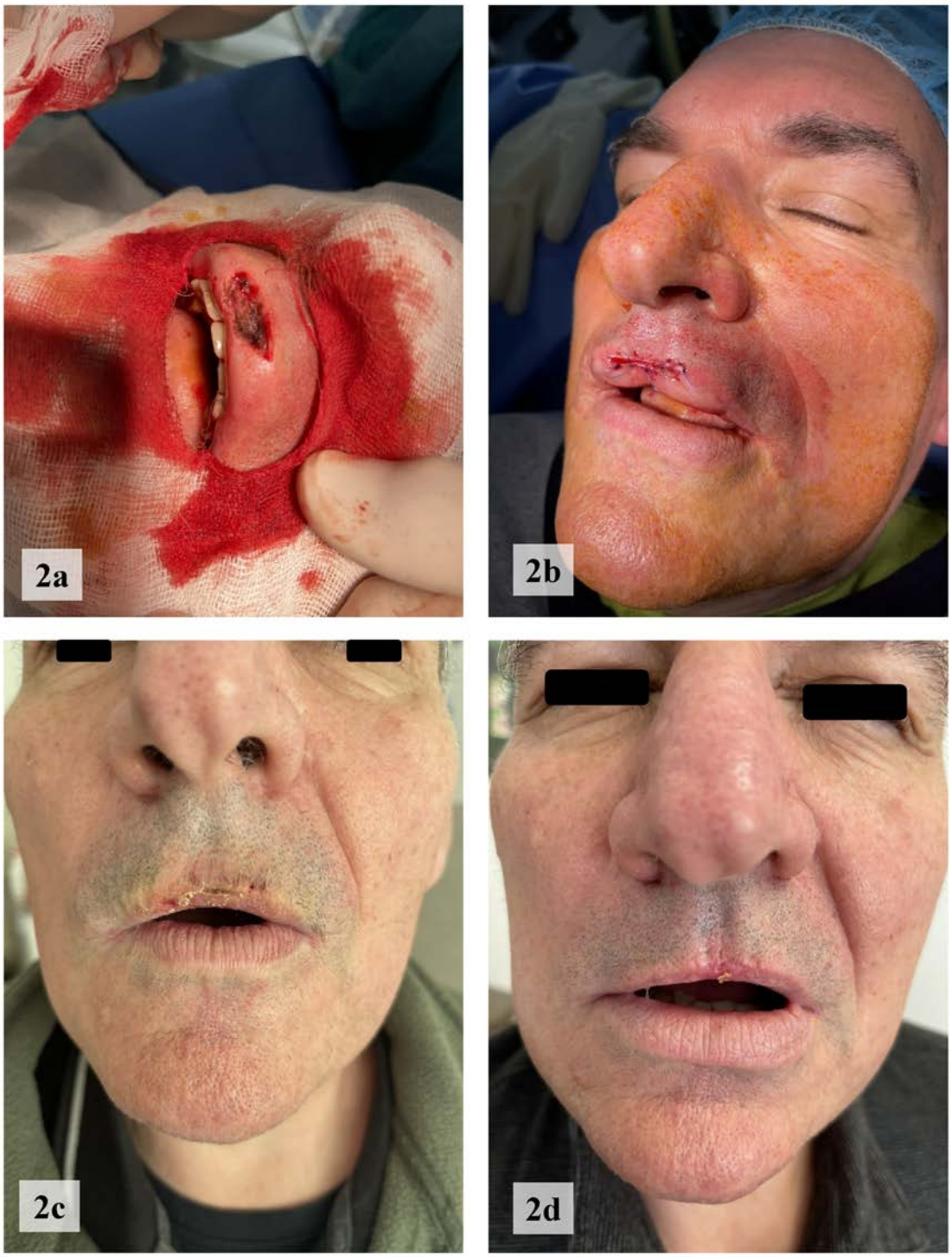

Fig 2a: Intraoperative finding after removing the tumor formation and stopping the bleeding with electrocautery. Fig 2b: Intraoperative finding immediately after closure of the defect with single skin sutures. Fig 2c: Postoperative finding on day 10. Fig 2d: Clinical status after 4 weeks.

EADV CONGRESS
VIENNA
30 SEP - 3 OCT 2026

Abstract N°: 3656

Pinwheel Flap for Scalp Reconstruction Beyond the Vertex: A Two-Case Series

Joao Marcos de Souza*[1], Barbara Messias Pereira[1], Bianca Miyazawa[1], Marcos Vinícius Borges Martins[1], Karoline Rodrigues Crevelim[1], Amanda Alencar dos Anjos[1], Rogerio Kondo[1], Airton dos Santos Gon[1]

[1] State University of Londrina, Londrina, Brazil

Introduction

Background:

Scalp reconstruction following skin cancer excision may be challenging because of limited tissue elasticity, convex anatomy, and the need to preserve hair-bearing scalp and cosmetic landmarks. Local rotational flaps are valuable options for tension redistribution and single-stage reconstruction.

Objective:

To describe the versatility of the pinwheel flap for reconstruction of scalp defects in different anatomical locations following skin cancer excision.

Case Presentation

Methods:

Two patients underwent reconstruction using a pinwheel flap after excision of biopsy-proven skin cancers of the scalp. Case 1 involved a 57-year-old man with cutaneous Squamous Cell Carcinoma on the vertex scalp, resulting in a 29-mm postoperative defect. Case 2 involved a 47-year-old woman with Basal Cell Carcinoma in the frontal scalp, resulting in a 26-mm defect. Reconstruction was performed using rotational advancement lobes configured as a pinwheel flap.

Results:

Both procedures were completed in a single surgical stage with satisfactory functional and cosmetic outcomes. Adequate tension redistribution and defect closure were achieved without grafting. In the female patient, flap planning allowed preservation of the frontal hairline and hair-bearing scalp. No postoperative complications or tumor recurrence were observed during follow-up.

Conclusion

The pinwheel flap represents a versatile reconstructive option for small-to-medium scalp defects beyond the vertex region. Its geometric design allows effective tension redistribution, preservation of hair-bearing scalp, and favorable cosmetic integration in anatomically challenging areas.

EA DV CONGRESS
VIENNA
30 SEP - 3 OCT 2026

Abstract N°: 3687

Optimized the removal technique for double-armed sutures

ChunYiu Leung[1], Sien Mai[1], Ziqin Gan[1], Jianjian Li[1], WengIoi Mio[1], Han Ma*[1]

[1] Department of Dermatology, The Fifth Affiliated Hospital, Sun Yat-sen University, Zhuhai, Guangdong Province, 519000 China, Zhuhai, Guangdong Province, China

Introduction

Conventional removal of double-armed sutures involves grasping one needle, withdrawing the suture, and cutting, which frequently displaces the unused strand. This can lead to entanglement, accidental needle loss, contamination, and increased risk of needle-stick injuries. We developed and evaluated an optimized technique that uses the sterile packaging sleeve to shield the unused strand and its attached needle during withdrawal, aiming to minimize displacement and preserve a sterile field.

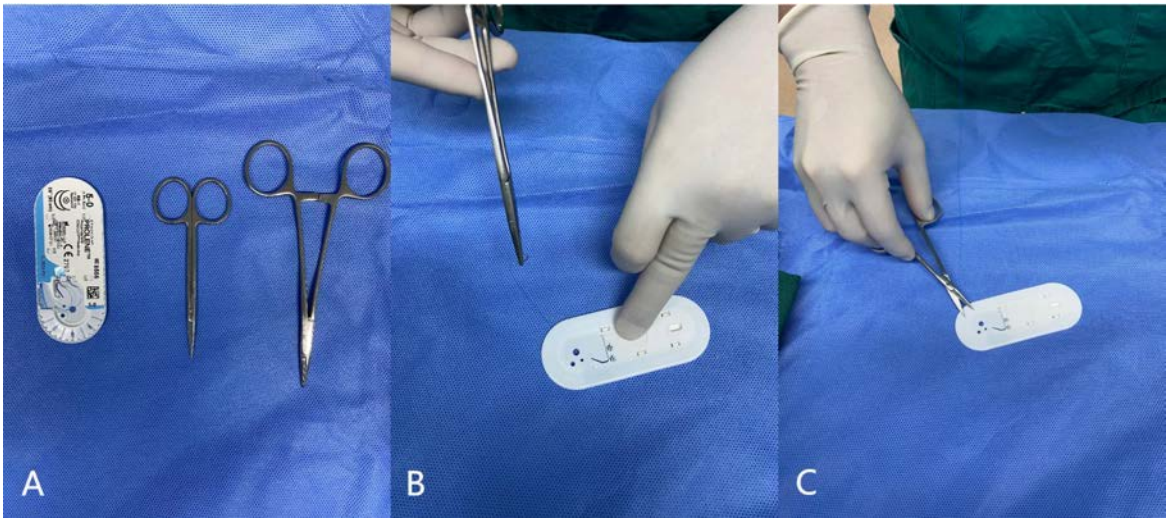

Materials and Methods

Sixty 5-0 Prolene double-armed sutures were tested. Needle A was defined as the upper and Needle B as the lower needle in the sleeve. For each needle position (n=30), 15 removals were performed using the optimized technique and 15 using the conventional method by a single experienced surgeon.

Optimized technique: The surgeon grasps the tip of the target needle with needle holders, withdraws a short segment, then flips the sterile sleeve toward the user to cover the unused suture strand and its attached needle with the inner aspect of the paper. Gentle pressure is maintained on the sleeve to stabilise the unused strand while the suture is pulled to the desired length and cut.

Conventional technique: The target needle is grasped and directly withdrawn without shielding the opposite end.

All sutures were withdrawn to a standardized length of ≥30 cm. The primary endpoint was displacement grade: Grade 0 (end remains within sleeve limits) vs. Grade 1 (protrudes beyond sleeve, indicating displacement and loss risk).

Figure 1. Grade 0 : suture completely within the sleeve.

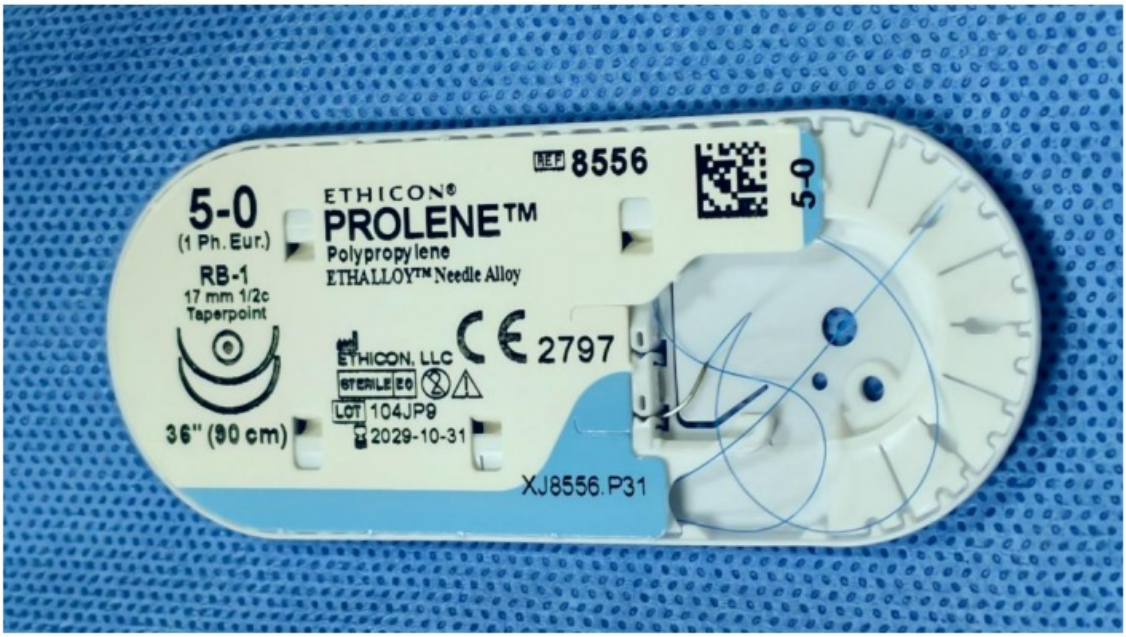

Figure 2. Grade 1 : suture protruding, indicating exposure risk.



Results

The optimized technique achieved a significantly higher overall Grade 0 rate (90.0% [27/30]) compared with the conventional technique (43.3% [13/30]; $P<0.001$). For Needle A removal, Grade 0 was 80.0% (optimized) vs. 40.0% (conventional) ($P=0.025$); for Needle B, 100% vs. 46.7% ($P<0.001$). Withdrawn suture length did not correlate with displacement grade ($P>0.05$).

Table 1. Comparison of displacement grade between the optimized technique and the conventional technique.

		Conventional technique	Optimized technique	P value
Needle A group, No. (%)	Grade 0	6 (40.0%)	12 (80.0%)	0.025
	Grade 1	9 (60.0%)	3 (20.0%)	
	Total	15 (100.0%)	15 (100.0%)	
Needle B group, No. (%)	Grade 0	7 (46.7%)	15 (100.0%)	0.001
	Grade 1	8 (53.3%)	0 (0.0%)	
	Total	15 (100.0%)	15 (100.0%)	
Overall group, No. (%)	Grade 0	13 (43.3%)	27 (90.0%)	0.001
	Grade 1	17 (56.7%)	3 (10.0%)	
	Total	30 (100.0%)	30 (100.0%)	

Table2. Correlation results between free suture length and displacement grade.

Variable	Value/Statistic
Analysis Variable 1	Displacement Grade
Analysis Variable 2	Free Suture Length
Pearson Correlation	-0.083
P value	0.531
N	60

Conclusions

The optimized sleeve-cover technique substantially reduces suture displacement and needle exposure by physically isolating the unused strand. This effectively lowers contamination and needle-stick injury risk without extra instruments or steps. Its superior performance, especially when removing the lower needle (B) first, supports routine adoption in dermatologic surgery to enhance safety and workflow efficiency.

EADV CONGRESS
VIENNA
30 SEP - 3 OCT 2026

Abstract N°: 3835

Post-operative topical antibiotic prophylaxis and surgical site infection in Mohs Micrographic Surgery – a comparative cohort study of 1,200 patients in a tertiary dermatology centre in the UK

Wei Ming Benjamin Sim*[1], Wei Wean Ooi[1], Karmen Cheung[1], Fasiha Arshad[1], Kai Harrington[1], Harvinder Ghura[1], Nicholas Telfer[1], Melanie Page[1], Vishal Madan[1]

[1] Mohs Surgery Unit, Department of Dermatology, Salford Royal Hospital, Northern Care Alliance NHS Foundation Trust, Salford, United Kingdom

Introduction

The British Society of Dermatological Surgery considers Mohs Micrographic Surgery (MMS) as high risk for developing surgical site infection (SSI) [1], but there is still limited clinical evidence and no formal guidelines on the use of post-operative topical antibiotic prophylaxis (PTAP) in preventing surgical site infection (SSI) in MMS, with Mohs surgeons varying in their practice of PTAP [2].

Materials and Methods

The primary objective was to evaluate the effect of PTAP on SSI in MMS. The secondary objectives were to evaluate if there were any patient or procedural factors associated with SSI in MMS, and if they influenced the association between PTAP and SSI in MMS.

This was a 1:1:1 retrospective comparative cohort study conducted at a tertiary dermatology centre in the UK. Participants were excluded if they received post-operative oral antibiotics or if they were referred to another institution for reconstruction or follow-up. A total of 1200 patients, treated with MMS between March 2015 and December 2025, were entered into the study.

Post-operatively, patients received the following: (i) no topical antibiotics (ii) 7 days twice daily application of Polymyxin B Sulphate 10,000 units and Bactracin Zinc 500 units per gram ointment (iii) 7 days twice daily application of Mupirocin 2% ointment.

An SSI was diagnosed on clinical assessment during follow-up within 14 days of MMS, if it met ≥1 criteria established by the UKHSA – (i) purulent drainage from the superficial incision (ii) organisms are cultured from a wound swab and pus cells are present (iii) ≥2 of the following symptoms and signs, including pain or tenderness, localized swelling, redness and heat [3].

Descriptive statistics of mean (SD) or count (percentage) were used to summarize baseline characteristics. Univariate and multivariate analyses were conducted using binary logistic regression, adjusting for patient factors (obesity and diabetes) and procedural factors (anatomical location, number of Mohs stages and type of repair) known to influence SSI. For all tests, 2-sided p-values <0.05 were considered to indicate statistical significance. All statistical analyses were performed using STATA 19 software [4].

Table 1: Characteristics of 1200 patients treated with MMS

Parameters	No post-op antibiotics N=400 (%)	Post-op Polymyxin B and Bacitracin ointment N=400 (%)	Post-op Mupirocin ointment N=400 (%)
Age – mean (SD), years	69.4 (12.4)	68.1 (12.4)	69.0 (11.5)
Gender			
Female	192 (48)	187 (46.8)	181 (45.2)
Male	208 (52)	213 (53.2)	219 (54.8)
Obesity			
No	316 (79)	356 (89)	340 (85)
Yes	84 (21)	44 (11)	60 (15)
Diabetes			
No	364 (91)	372 (93)	361 (90.2)
Yes	36 (9)	28 (7)	39 (9.8)
Immunocompromise			
No	396 (99)	392 (98)	392 (98)
Yes	4 (1)	8 (2)	8 (2)
Anatomical location			
Forehead	82 (20.5)	95 (23.8)	95 (23.8)
Periocular	36 (9)	28 (7)	39 (9.8)
Nose	139 (34.8)	123 (32)	128 (32)
Cheek	73 (18.2)	65 (16.2)	69 (17.2)
Ear	27 (6.8)	34 (8.5)	23 (5.8)
Perioral	36 (9)	29 (7.2)	29 (7.2)
Scalp	7 (1.8)	18 (4.5)	14 (3.5)
Neck	0 (0)	3 (0.8)	3 (0.8)
Number of Mohs stages			
1	300 (75)	248 (62)	231 (57.8)
2	86 (21.5)	130 (32.5)	147 (36.8)
≥3	14 (3.5)	22 (5.5)	22 (5.5)
Type of repair			
Secondary intention	44 (11)	32 (8)	29 (7.2)
Primary closure	125 (31.2)	118 (29.5)	135 (33.8)
Graft	47 (11.8)	31 (7.8)	34 (8.5)
Flap	184 (46)	219 (54.8)	202 (50.5)
SSI on follow-up			
No	394 (98.5)	394 (98.5)	395 (98.8)
Yes	6 (1.5)	4 (1)	5 (1.2)

Results

The odds of developing SSI appear to be lesser when PTAP was utilized, however associations were statistically non-significant for both Polymyxin B and Bacitracin zinc ointment and Mupirocin ointment, with crude OR 0.66 (0.19 – 2.37), p-value 0.53, and crude OR 0.83 (0.25 – 2.74), p-value 0.76, respectively. The associations remained non-significant on multivariate analysis, for both Polymyxin B and Bacitracin zinc ointment and Mupirocin ointment, with adjusted OR 0.44 (0.11 – 1.72), p-value 0.24 and adjusted OR 0.60 (0.17 – 2.10), p-value 0.43, respectively.

Moreover, of all patient and procedural factors analyzed, patients who underwent MMS with ≥3 Mohs stages were found to be more likely to develop SSI. This association was statistically significant, with a crude OR of 6.02 (1.51 – 23.91), p-value 0.01. This association remained significant on multivariate analysis, with an adjusted OR 13.47 (2.92 – 62.11), p-value 0.001.

There was no statistically significant interaction between PTAP and the number of Mohs stages, and no effect modification of the number of Mohs stages on the association between PTAP and SSI. There was also no statistically significant interaction between PTAP and type of repair performed.

Table 2: Effect of patient and procedural factors on risk of SSI

Parameters	SSI on follow-up N (%)	Crude OR (95% CI)	p-value
No post-op antibiotics	6/400 (1.5)	-[a]	-
Post-op Polymyxin B and Bacitracin ointment	4/400 (1)	0.66 (0.19 – 2.37)	0.53
Post-op Mupirocin ointment	5/400 (1.2)	0.83 (0.25 – 2.74)	0.76
Age			
<41	2/30 (6.67)	0.98 (0.94 – 1.02)[b]	0.33[b]
41 – 59	2/221 (0.90)		
60 – 74	5/506 (0.99)		
>74	6/443 (1.35)		
Gender			
Female	5/560 (0.89)	-[a]	-
Male	10/640 (1.56)	1.76 (0.60 – 5.19)	0.30
Obesity			
No	13/1012 (1.28)	-[a]	-
Yes	2/188 (1.06)	0.83 (0.18 – 3.69)	0.80
Diabetes			
No	13/1097 (1.19)	-[a]	-
Yes	2/103 (1.94)	1.65 (0.37 – 0.74)	0.51
Immunocompromise			
No	15/1180 (1.27)	-[a]	-
Yes	0/20 (0)	-[c]	-
Anatomical location			
Forehead	2/272 (0.74)	-[a]	-
Periocular	1/103 (0.97)	1.32 (0.12 – 14.75)	0.82
Nose	5/395 (1.27)	1.73 (0.33 – 8.99)	0.51
Cheek	2/207 (0.97)	1.32 (0.18 – 9.43)	0.78
Ear	2/84 (2.38)	3.29 (0.46 – 23.74)	0.24
Perioral	1/94 (1.06)	1.45 (0.13 – 16.19)	0.76
Scalp	2/39 (5.13)	7.30 (1.00 – 53.37)	0.05
Neck	0/6 (0)	-[c]	-
Number of Mohs stages			
1	7/779 (0.90)	-[a]	-
2	5/363 (1.38)	1.54 (0.49 – 4.89)	0.46
≥3	3/58 (5.17)	6.02 (1.51 – 23.91)	0.01
Type of repair			
Secondary intention	0/105 (0)	-[a]	-
Primary closure	6/378 (1.59)	1.38 (0.46 – 4.13)	0.57
Graft	2/112 (1.79)	1.55 (0.32 – 7.58)	0.59
Flap	7/605 (1.16)	-[d]	-

a – Taken as base level for reference
b – odds ratio for Age analyzed as a continuous variable
c – observations omitted due to perfect prediction
d – observations omitted due to collinearity

Conclusions

This study suggests that PTAP do not appear to influence the risk of SSI, however it did report an increased rate of SSI among patients who underwent a procedure with ≥3 stages.

Based on these findings, we suggest that routine PTAP is not required for standard MMS. However, clinicians should consider closer monitoring or targeted prophylaxis for complex cases requiring ≥3 stages.

This study may be underpowered to detect small differences in SSI rates given the low overall incidence of infection in MMS.

Further research including clinical trials are warranted to inform clinical practice.

Table 3: Multivariate analysis between use of post-operative topical antibiotic prophylaxis and SSI

Parameters	Adjusted OR (95% CI) [ab]	p-value
No post-op antibiotics	-[c]	-[c]
Post-op Polymyxin B and Bacitracin ointment	0.44 (0.11 – 1.72)	0.24
Post-op Mupirocin ointment	0.60 (0.17 – 2.10)	0.43
Number of Mohs stages		
1	-[c]	-[c]
2	1.60 (0.48 – 5.31)	0.44
≥3	13.47 (2.92 – 62.11)	0.001

a – Adjusted for the following variables: Age, Gender, Diabetes, Obesity, Anatomical location, Number of Mohs stages, Type of repair
b – N=1070 as the following variables were omitted due to perfect prediction: Immunocompromise, Anatomical location (Neck), Type of repair (Secondary intention); while the variable Type of repair (Flap) was omitted due to collinearity
c – Taken as base level for reference

References

[1] British Society for Dermatological Surgery. Workshop Manual [online]. 2024. [Accessed 12 May 2026]. Available from: https://bsds.org.uk/wp-content/uploads/2024/05/BSDS-ASW-Manual-2024.pdf

[2] Aizman L, Barbieri JS, Lukowiak, TM, et al. Attitudes on Prophylactic Antibiotic Use in Dermatologic Surgery: A Survey Study of American College of Mohs Surgery Members. Dermatol Surg [online]. 2021 Mar 1;47(3):339-342. [Accessed 12 May 2026]. Available from: <doi: 10.1097/DSS.0000000000002676>

[3] UK Health Security Agency. Protocol for the Surveillance of Surgical Site Infection: Surgical Site Infection Surveillance Service [online]. 2023. [Accessed 13 May 2026]. Available from https://assets.publishing.service.gov.uk/media/61e989028fa8f505985ef463/Protocol_for_the_Surveillance_of_Surgical_Site_Infection.pdf

[4] StataCorp. Stata statistical software: release 19. College Station, Texas (US): StataCorp LLC, 2025.

EADV CONGRESS
VIENNA
30 SEP - 3 OCT 2026

Abstract N°: 3853

Outcomes of endoscopic treatment versus flap reconstruction for pilonidal sinus disease: a systematic review with a single-centre V–Y advancement flap case series

Celia Ziane*[1], Anirban Mandal[2]

[1] Countess of Chester NHS Foundation Trust, Chester, United Kingdom

[2] The Mersey Regional Burns and Plastic Surgery Unit, Mersey and West Lancashire Teaching Hospitals NHS Trust, Knowsley, United Kingdom

Introduction

Endoscopic techniques, including endoscopic pilonidal sinus treatment (EPSiT) and video-assisted ablation of pilonidal sinus (VAAPS), have emerged as minimally invasive alternatives to reconstructive flap procedures in pilonidal sinus disease (PSD). Although these techniques offer potential advantages in early recovery, their long-term durability compared with flap reconstruction remains uncertain.

Materials and Methods

A PRISMA 2020 systematic review was conducted using MEDLINE and EMBASE. Studies published between January 2000 and July 2025 evaluating EPSiT/VAAPS or flap reconstruction in adults with sacrococcygeal PSD were included if they reported ≥50 patients and ≥12 months' mean or median follow-up. The primary outcome was disease recurrence; secondary outcomes included postoperative complications, healing time, and length of hospital stay. Due to substantial heterogeneity, findings were synthesised narratively. A single-centre retrospective V–Y advancement flap case series was analysed separately.

Results

Forty-seven studies were included, comprising two comparative studies and 45 single-arm observational studies. EPSiT/VAAPS demonstrated favourable short-term recovery, including shorter hospital stay and low early postoperative complication rates, generally ≤6%. Reported recurrence following EPSiT/VAAPS ranged from 0% to 26.9% and appeared higher in studies with longer follow-up. Flap reconstruction demonstrated lower and more consistent long-term recurrence rates, typically below 6% for commonly performed techniques, although complication rates and hospital stay were generally greater.

In the V–Y advancement flap case series (n=15), no recurrences were observed during a median follow-up of 6 months. Postoperative complications occurred in five patients, including surgical site infection in four patients and prolonged wound healing in one patient.

Conclusions

EPSiT/VAAPS offers favourable short-term recovery, whereas flap reconstruction demonstrates more consistent long-term disease control. These findings highlight the need to balance early recovery with long-term durability when selecting management strategies for PSD. Recurrence following EPSiT/VAAPS may be underestimated in studies with limited follow-up. Further high-quality comparative studies with standardised long-term follow-up are required.

EADV CONGRESS
VIENNA
30 SEP - 3 OCT 2026

Abstract N°: 3936

Perioperative Outcomes of Direct Oral Anticoagulant Use in Mohs Micrographic Surgery: A Propensity-Matched Analysis

Robert Adler*[1], Carl Tucci[2], Maressa Criscito[2]

[1] SUNY Downstate College of Medicine, Brooklyn, United States

[2] The Ronald O. Perelman Department of Dermatology, New York University Grossman School of Medicine,, New York, United States

Introduction

Evaluation of perioperative management of direct oral anticoagulants (DOACs) in Mohs micrographic surgery (MMS) remains uncertain.

Materials and Methods

We conducted a retrospective cohort study using the TriNetX US Collaborative Network. Patients undergoing MMS were stratified by perioperative DOAC use (apixaban, rivaroxaban, dabigatran, or edoxaban) versus no anticoagulant or antiplatelet therapy. Propensity score matching (1:1) yielded 11,752 patients per cohort. Outcomes within 7 days included bleeding, infection, arterial thrombosis/stroke, emergency visits, inpatient admissions, swelling, and rash. Risk ratios (RR) were calculated.

Results

DOAC use was associated with increased risk of bleeding (0.8% vs 0.3%; RR 3.19, 95% CI 2.14-4.78), arterial thrombosis/stroke (0.5% vs 0.2%; RR 2.29, 95% CI 1.42-3.70), emergency visits (1.1% vs 0.5%; RR 2.49, 95% CI 1.81-3.42), and inpatient admissions (1.6% vs 0.5%; RR 3.22, 95% CI 2.41-4.29). Infection rates were similar (0.7% vs 0.7%; RR 1.03, p=0.875), and differences in swelling and rash were not statistically significant. All-cause mortality was too infrequent for meaningful analysis, consistent with the low short-term mortality risk of MMS.

Conclusions

Perioperative DOAC use in MMS is associated with increased risks of bleeding, thromboembolic events, and healthcare utilization without increased infection risk. The rarity of mortality events underscores the overall short-term safety of MMS and supports individualized perioperative anticoagulation management.

EA DV CONGRESS
VIENNA
30 SEP - 3 OCT 2026

Abstract N°: 4020

Simulation-based Dermatological Procedural Training Using Affordable Low-Fidelity Banana Model in an LMIC Residency Programme: A Pilot quality Improvement Study

Mahendra Pandeya*[1], Madhu Gyawalee[1]

[1] Patan Academy of Health Sciences, Lalitpur, Nepal

Introduction

Incoming dermatology postgraduate trainees in LMIC settings may be expected to perform procedures such as punch biopsy, skin excision, and suturing early in residency, often with variable prior hands-on exposure. This creates an educational and ethical need for structured rehearsal before patient-based procedures. A low-cost simulation-based procedural training session was developed for new dermatology postgraduate trainees. A banana-based model was used to evaluate whether a structured, affordable simulation-based procedural training session could improve self-reported procedural confidence, reduce procedural anxiety, improve procedural knowledge, and enhance perceived readiness among incoming dermatology postgraduate trainees.

Materials and Methods

A pilot pre–post quality improvement study was conducted among all four incoming PGY-1 dermatology trainees. Participants completed a locally developed pre-simulation questionnaire assessing prior procedural exposure, confidence, anxiety, and procedural knowledge. After a structured training session on banana model, post-simulation questionnaire assessing the same confidence, anxiety, and knowledge domains, along with training effectiveness, model fidelity, facilitation quality, qualitative feedback, and ethical/patient-safety readiness were completed. The questionnaire scoring guide defined total confidence as 22 Likert items (maximum score of 110), procedural anxiety as 7 Likert items (maximum score of 35), and knowledge as 7 MCQs scored out of 7. The tool was developed by adapting principles from Simulation-Based Mastery Learning, DREEM-informed educational environment assessment, and published dermatology simulation literature. The simulation session included theoretical instruction, facilitator-guided hands-on practice, and structured debriefing by Dermatology Consultant along with PGY2 facilitator. Total material cost per session was NPR 500 (<EUR 3). Wilcoxon signed-rank test was applied for pre-post comparision.

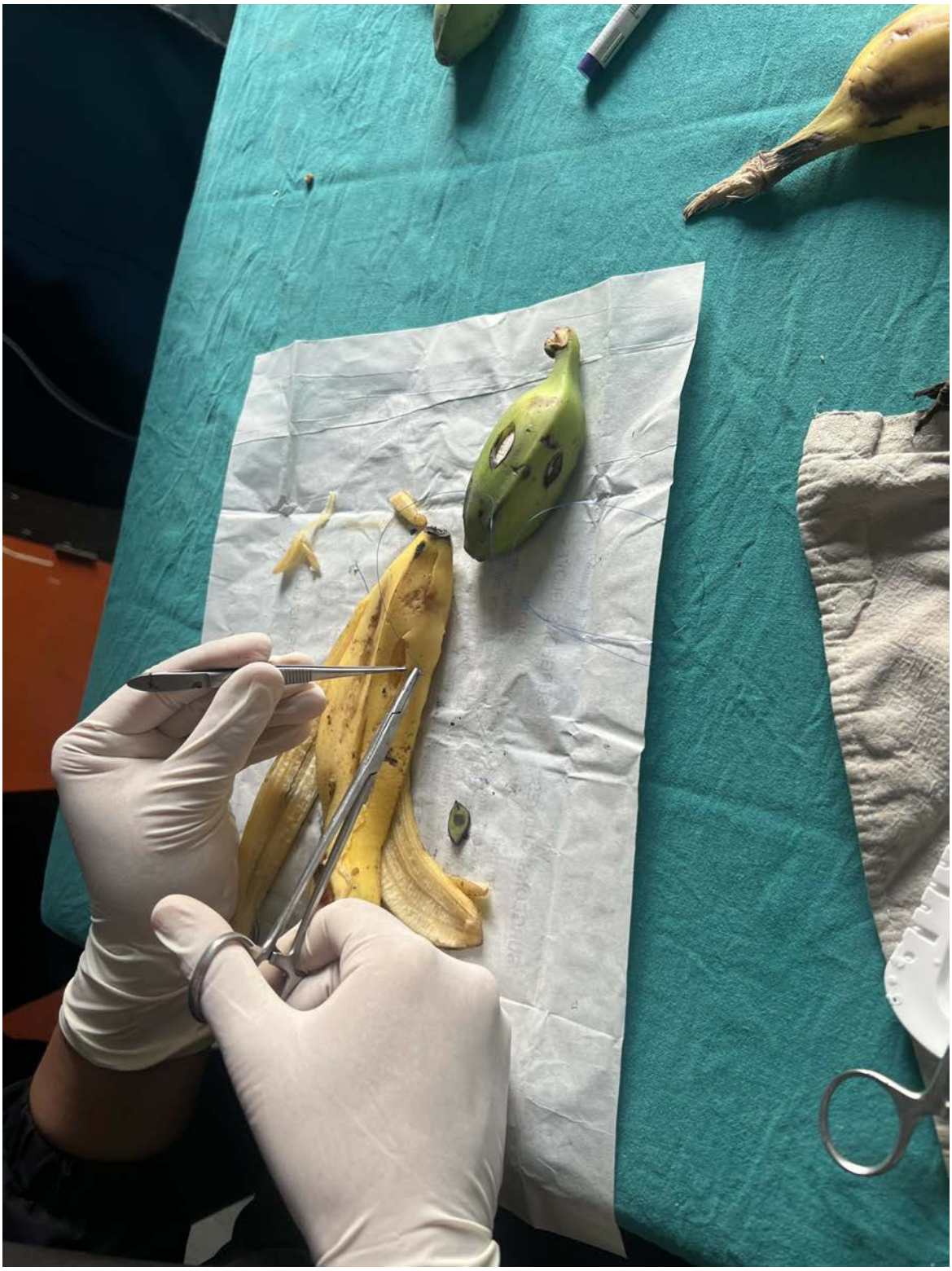

Results

All four participants completed paired pre- and post-simulation assessments. Mean total procedural confidence increased from **32.3 ± 10.5 to 65.3 ± 11.6 out of 110**, representing a mean gain of **33.0 points** and approximately **102% improvement**. Individual confidence gains ranged from **+24 to +42 points**. Mean procedural anxiety decreased from **21.3 ± 4.6 to 12.8 ± 3.7 out of 35**, representing approximately **40% reduction (8.5 points)**. Mean procedural knowledge score improved from **3.8 ± 0.5 to 6.3 ± 0.96 out of 7**, corresponding to approximately **90% post-simulation accuracy**. Overall session rating was **8.0 ± 0.8 out of 10**, with all participants rating the session between **7 and 9**. Mean training effectiveness was reported as **4.2 out of 5**, indicating strong perceived educational value. Given the small pilot sample size, findings were interpreted descriptively. All four participants

improved in confidence, anxiety, and knowledge domains; however, no inferential statistical claims could be made because the cohort size was limited.

Outcome Domain	Pre (mean ± SD)	Post (mean ± SD)	Change	% Change	Statistical Test
Procedural Confidence (max 110)	32.3 ± 10.5	65.3 ± 11.6	+33.0	+102.2%	T=0, p<0.05*
Procedural Anxiety (max 35)	21.3 ± 4.6	12.8 ± 3.7	−8.5	−39.9%	T=0, p<0.05*
MCQ Knowledge (max 7)	3.8 ± 0.5	6.3 ± 0.96	+2.5	+65.8%	T=0, p<0.05*
Session Rating (out of 10)	—	8.0 ± 0.82	—	—	Range 7–9
Training Effectiveness (max 5)	—	4.2 ± est.	—	—	84% of max

Conclusions

A single structured simulation session using affordable low-fidelity banana-based model was associated with improved procedural confidence, reduced procedural anxiety, improved procedural knowledge, strengthened perceived ethical readiness among new dermatology postgraduate trainees. This pilot suggests that low-cost simulation may provide a feasible, ethically grounded, and resource-appropriate bridge between theoretical learning and first supervised patient-based procedures in LMIC dermatology training. Future cycles should include larger cohorts, objective procedural skill checklists, predefined mastery standards, delayed retention testing, and supervised real-patient performance assessment. Importantly, this study demonstrates that the ethical imperative to rehearse before first patient contact does not require expensive equipment; it requires only the deliberate act of practice with feedback on low-fidelity models like banana at a cost of less than EUR 3 per session.

EADV CONGRESS
VIENNA
30 SEP - 3 OCT 2026

Abstract N°: 4139

Wood's Lamp-Assisted Identification of Retained Suture Material

Jessica Bulluss*[1, 2], Paul Chee[1, 2], Matthew Verheyden[1, 2, 3], Sarah Nowak[1], Er Tsing Vivian Tng[1, 2]

[1] Department of Dermatology, John Hunter Hospital, School of Medicine and Public Health, The University of Newcastle, Newcastle, Australia

[2] School of Medicine and Public Health, The University of Newcastle, Newcastle, Australia

[3] Sydney Medical School, The University of Sydney, Sydney, Australia

Introduction

Retained suture material embedded within postoperative wounds is a common and often frustrating problem in dermatologic and general surgical practice. Sutures may be concealed beneath crust, granulation tissue, or re-epithelialised skin, making identification difficult under standard illumination. We describe a simple technique using a Wood's lamp to aid identification of retained suture material.

Materials and Methods

A Wood's lamp, emitting ultraviolet light in the 320–400 nm range, was applied to postoperative wounds in which retained suture material was suspected but not visible to the naked eye. The technique was also assessed in vitro, including identification of suture material dropped intraoperatively. Fluorescence of commonly used suture types was assessed and subsequently applied in vivo within a public hospital dermatology outpatient clinic.

Results

Under Wood's lamp examination, several commonly used suture materials demonstrated visible fluorescence, including Monosyn, Dermalon, Dafilon, Prolene, Novafil, and three variants of Vicryl (coated Vicryl, Vicryl Rapide, and Vicryl Plus antibacterial). This technique was applied in a case series of ten patients with suspected retained sutures. In all cases, fluorescent suture material was successfully identified and removed after previous unsuccessful attempts using visible light alone. Use of the Wood's lamp allowed rapid localisation of suture material with minimal tissue manipulation.

Conclusions

Wood's lamp examination represents a simple, low-cost, and widely accessible adjunct for identifying retained suture material through fluorescence of multiple commonly used suture types. This technique may reduce procedural time, patient discomfort, and prolonged wound morbidity associated with retained sutures. Additional applications include identification of dropped suture material intraoperatively. To our knowledge, fluorescence of commonly used suture materials under Wood's lamp has not been previously described. Further evaluation may help define the broader applicability of this technique across surgical settings.

POWERED BY M-ANAGE.COM

EA DV CONGRESS
VIENNA
30 SEP - 3 OCT 2026

Abstract N°: 4146

PICO™ single-use negative pressure wound therapy following lower limb skin grafts: a case series in dermatologic surgery

Pau Forte Genescà*[1], LORENA LEAL CANOSA[1], Mireia Yébenes[1], Marc Aparicio Rovira[1], Eulalia Baqué[1], Mar Fabregues[1], Veronica Navarro-García[1], Gladys Benitez-Acosta[1], Emilia Tarragó[1], Lucica Hirjaba[1], Fernando Gallardo Hernandez[1]

[1] Hospital del Mar - Department of Dermatology, Barcelona, Spain

Introduction

Negative pressure wound therapy (NPWT) improves skin graft take by exerting uniform pressure and effectively managing exudate. While meta-analyses highlight its benefits in complex anatomical sites, the lower limbs present specific challenges such as poor tissue compliance, compromised vascularization, and a high risk of necrosis. We evaluated the effectiveness of the PICO™ portable NPWT system following full-thickness skin grafts (FTSG) on the lower extremities.

Materials and Methods

An ambispective observational study was conducted including patients treated with PICO™ NPWT after FTSG between 2024 and 2026. Grafts were secured with staples, and PICO™ was maintained for a minimum of two weeks with weekly dressing changes. Data was collected via the RedCAP platform, including clinical and surgical variables. Final outcomes were assessed using the Patient and Observer Scar Assessment Scale (POSAS).

Results

Fifteen patients were included (9 males, 6 females; mean age 84 ± 7.5 years). Surgical indications included basal cell carcinoma (n=6), squamous cell carcinoma (n=6), and melanoma (n=3). Locations were the leg (n=13) and foot (n=2). The mean surgical defect area was 9.3 ± 6.4 cm^2.

Five mild postoperative haemorrhages occurred (3 in patients on antithrombotic or antiplatelet therapy). Mean PICO™ duration was 16.1 ± 6.2 days. Upon device removal, partial graft loss occurred in 86% (n=13) cases, with a mean loss of 32 ± 30.5% of surface area. Patients reported high satisfaction (8 ± 1.9 points) with minimal discomfort with PICO™ use. Despite prophylactic antibiotics in 86% (n=13) of cases, surgical site infections (SSI) occurred in 33% (n=5); notably, these were caused by pathogens not covered by the initial antimicrobial treatment. SSI was the primary driver of both pain (NRS 5.16 vs. 0.34) and graft loss (52% vs. 22%). While total graft size

did not influence loss, longer PICO™ duration showed a moderate correlation with improved graft take in uninfected cases, although this did not reach statistical significance (Pearson's R = -0.419, R^2 = 0.18, p = 0.224). Regarding scar outcomes, patients were generally satisfied, though pigmentation and scar depression were the primary concerns for both patients and physicians.

Conclusions

Portable NPWT with PICO™ is a well-tolerated and effective tool for optimizing FTSG in lower limb dermatologic surgeries. Our findings suggest SSI remains the most significant barrier to successful outcomes, directly impacting both graft survival and patient pain. While higher treatment durations may benefit graft take, careful microbiological monitoring and optimized treatment length are essential to mitigate complications. Overall, this technique provides acceptable scar quality for both patients and healthcare providers.

EA DV CONGRESS
VIENNA
30 SEP - 3 OCT 2026

Abstract N°: 4183

Handheld Reflectance Confocal Microscopy for Head and Neck Basal Cell Carcinoma: Diagnostic Performance, Subtyping, and Potential to Replace Presurgical Biopsies

Yannick Elshot*[1, 2], Wouter Ouwerkerk[2], Biljana Zupan-Kajcovski[1], Mijke Bol[1], Erienne de Cuba[1], Lies Jaspars[2], Giulia Briatico[3], Giuseppe Argenziano[3], Nicole Kukutsch[1], Salvador Gonzalez[4], Manu Jain[5], Alfons Balm[1], W. Martin Klop[1], Marcel Bekkenk[2], Menno de Rie[2]

[1] Netherlands Cancer Institute, Amsterdam, Netherlands
[2] Amsterdam University Medical Center, Amsterdam, Netherlands
[3] University of Campania, Napoli, Italy
[4] Universidad de Alcalá, Alcalá de Henares, Spain
[5] Memorial Sloan Kettering Cancer Center, New York, United States

Introduction
Background: Management of head and neck basal cell carcinoma (BCC) relies on punch biopsies for confirmation and subtyping, despite substantial biopsy–excision discordance, added morbidity, and treatment delay.

Objectives: To assess the diagnostic accuracy and subtyping performance of dermoscopy plus handheld reflectance confocal microscopy (DS+HH-RCM) for primary head and neck BCC, and to explore its potential to guide indications for Mohs micrographic surgery (MMS) according to international guidelinesObjectives: To assess the diagnostic accuracy and subtyping performance of dermoscopy plus handheld reflectance confocal microscopy (DS+HH-RCM) for primary head and neck BCC, and to explore its potential to guide indications for Mohs micrographic surgery (MMS) according to international guidelines

Materials and Methods
In this prospective, single-centre, fully paired diagnostic comparison study, 340 consecutive head and neck lesions with naked-eye suspicion of BCC underwent dermoscopy and HH-RCM, followed by 3-mm punch biopsy and excision or MMS. Two blinded expert dermatopathologists independently assessed biopsy and excision specimens; discrepancies were resolved by a third dermatopathologist, and the most aggressive subtype in either biopsy or excision was used as the histological reference standard. Blinded experts independently evaluated dermoscopy and HH-RCM images for diagnosis, subtype and diagnostic features, and recorded diagnostic confidence on a 3-point Likert scale.

Results
Of 340 lesions, 286 (84%) were histologically confirmed BCC. Histological subtyping showed substantial biopsy–excision discordance: the most aggressive subtype at biopsy was concordant with excision in 61% and discrepant in 33%, with 24% of lesions upstaged after excision. For BCC diagnosis, DS+HH-RCM achieved a sensitivity/specificity of 97.5% (95.0–99.0) and 85.2% (72.9–93.4), increasing to 98.8% (96.5–99.7) and 94.1% (80.3–99.3) in high-confidence cases. For non-superficial BCC, sensitivity was 95.5% (92.9–98.1) and specificity 44.8% (26.7–62.9); for infiltrative BCC, sensitivity was 58.8% (45.3–72.3) and specificity 79.6% (74.3–84.9). Applying four international MMS criteria to high-confidence DS+HH-RCM diagnoses would have resulted in excision of <0.7% benign lesions in this hypothetical scenario.

Conclusions
DS+HH-RCM provides very high sensitivity and increases diagnostic confidence for head and neck BCC, while

biopsy–excision discordance confirms the limitations of relying on punch biopsy alone for subtype-based management. In carefully selected high-confidence cases, DS+HH-RCM could potentially replace presurgical confirmation biopsies when planning MMS, although punch biopsy remains necessary when surgical margin selection depends solely on precise histological subtype.

EA DV CONGRESS
VIENNA
30 SEP - 3 OCT 2026

Abstract N°: 4197

Impact of Simulation-Based Training on Resident's Competency and Confidence : A descriptive study

Salma Abid*[1], Syrine Hamada[1], Hasnae Zerhouni[1], Narjess Er-rachdy[1], Najoua Ammar[1], Mariame Meziane[1], Nadia Ismaili[1], Laila Benzekri[1]

[1] Dermatology Department of University Hospital Ibn Sina, Rabat, Morocco

Introduction
Dermatologic surgery is a cornerstone of residency, yet structured curricula are often lacking. Traditionally, the "see one, do one, teach one" model prevails, frequently generating anxiety and clinical heterogeneity. We evaluated the impact of structured suture workshops on the acquisition of surgical skills among dermatology residents.

Materials and Methods
Population: A cross-sectional descriptive study was conducted among a sample of 33 dermatology residents, with a majority of first-year residents.

Intervention: Two pedagogical workshops were organized. The program combined theoretical refreshers (suture material selection, surgical indications) and supervised intensive hands-on exercises on simulators.

Evaluation: Data were collected through a 20-item post-workshop questionnaire, utilizing 5-point Likert scales and open-ended questions.

Results
- Technical proficiency: 93.8% of participants reported an immediate improvement in their daily suture quality, and 75% achieved a mastery score of 5/5 for basic technical gestures.

- Clinical confidence: 93.7% felt more comfortable in real clinical settings, with 66.6% reporting a significant reduction in procedure-related anxiety.

- Autonomy and safety: 84.4% felt more autonomous, and 81.9% reported increased confidence in surgical safety and precision.

- Educational Paradigm: 72.7% rated simulation as more effective than exclusive operating room learning. 90.9% considered simulation a mandatory prerequisite before patient contact.

- Satisfaction: 100% of participants recommended a hybrid curriculum consisting on workshops and clinical practice.

Discussion:
Our results demonstrate a disconnect between traditional apprenticeship and resident needs. While 66.7% of residents already performed sutures, the high demand for structured simulation highlights a gap in formal training. The focus on aesthetic outcomes (63.6% of concerns) confirms the need for low-stress environments to

refine technique. Integration of "flipped classroom" models and objective assessment tools (e.g., OSATS) are the next steps to standardize excellence.

Conclusions

Simulation-based training is no longer an optional adjunct but an ethical imperative in dermatology. It significantly flattens the learning curve and enhances patient safety. We advocate for the institutionalization of permanent simulation labs within dermatology residency programs to ensure standardized surgical excellence.

EA DV CONGRESS
VIENNA
30 SEP - 3 OCT 2026

Abstract N°: 4217

A Systematic Review of Cosmetic Outcomes, Efficiency, and Complications in Dermatological Surgery: Cyanoacrylate Tissue Adhesives and Traditional Sutures

Ibtihaj Irfan*[1, 2], Aleena George[1], Naveenkishan Elamurugan[1], Riya Mathew[1, 2], Rachel Manoj[1, 2], Tishya Mukherjee[1, 2]

[1] Nicolae Testemițanu State University of Medicine and Pharmacy, Chisinau, Moldova
[2] InciSioN Moldova, Chisinau, Moldova

Introduction
Achieving the optimal closure requires a delicate interplay among cosmetic outcomes, procedural efficiency, patient comfort, and postoperative safety. Traditional sutures are an established practice for approximating the epidermis, but it can lead to patient discomfort, an extended procedure duration, suture-track scarring, and the need for a follow-up appointment for suture removal. Cyanoacrylate tissue adhesives provide swift closure and waterproof coverage, thus offering a convenient protective closure. Recent findings in facial and dermatological surgery encourage the use of tissue adhesives, as they can produce better or equal cosmetic results when compared to traditional sutures, while being more efficient and improving the experience for the patient.

Materials and Methods
This systematic review, following PRISMA 2020 guidelines, aimed to compare cyanoacrylate tissue adhesives to traditional sutures for cutaneous wound closure in dermatological surgery, covering studies published in English from January 2021 to May 2026. Literature was searched across PubMed/MEDLINE, Embase, Scopus, and Google Scholar. Included studies addressed dermatological surgeries, facial reconstruction, Mohs micrographic surgery, periocular procedures, graft fixation, cosmetic excisions, and facial lacerations. Studies involving internal, orthopedic, or non-cutaneous surgical closures were excluded.

Results
A total of 59 studies were reviewed, with the majority involving facial wounds, Mohs surgical repair, pediatric lacerations, periocular procedures, and cosmetic dermatological closures. Cyanoacrylate tissue adhesives resulted in shorter closure times than conventional sutures, with approximately 30–50% reductions in procedural times reported in some studies. Their use also eliminated the need for suture removal, thereby reducing follow-up visits.

Cosmetic outcomes of adhesive closure were comparable to or better than those of sutures. Adhesives used for facial lacerations improved cosmetic appearance and patient satisfaction, attributed to narrower scars and improved wound management. Adhesives were also favoured in pediatric patients, as they improved laceration closure, reducing procedural stress and discomfort without the use of needles.

Cyanoacrylate adhesives and sutures showed little difference in infection rates and wound dehiscence, though some studies reported lower infection rates with cyanoacrylate tissue adhesive, possibly due to their occlusive and bacteriostatic properties. Pain scores were consistently lower with tissue adhesives than sutures, as they eliminated needle placement and suture removal. Adhesive closure systems were associated with comparable or lower overall costs, driven by shorter closure times and fewer follow-up visits, despite higher material costs.

Parameter	Cyanoacrylate Adhesives	Conventional Sutures
Closure Time	Faster wound closure (approximately 30–50% reduction in procedure time)	Longer procedural time
Cosmetic Outcome	Comparable or improved cosmesis	Good cosmetic healing
Pain & Comfort	Less pain; no removal	More discomfort; removal needed
Wound Support	Lower tensile strength	Better tensile support
Best Applications	Low-tension cosmetic wounds	High-tension/deep wounds
Overall Conclusion	Efficient and patient-friendly	Preferred for stronger closure

Table 1: Comparison of Cyanoacrylate Tissue Adhesives and Conventional Sutures in Dermatological Surgery

Conclusions

Cyanoacrylate tissue adhesives are a valuable addition to the wound closure options available in dermatological surgery. They provide rapid closure of skin wounds with excellent cosmetic outcomes and increased patient satisfaction with minimal adverse effects. They are well-suited for pediatrics, periocular and low-tension facial wounds, and Mohs micrographic surgery.

EADV CONGRESS
VIENNA
30 SEP - 3 OCT 2026

Abstract N°: 4240

Exploring ChatGPT-Assisted Nasal Reconstruction Planning Following Mohs Surgery: A Qualitative Case-Based Analysis

Khalid M. A. Ahmed*[1], Arif Aslam[1]

[1] Leeds Centre of Dermatology, Leeds Teaching Hospitals, Leeds, United Kingdom

Introduction
Artificial intelligence is increasingly being explored in dermatology and Mohs micrographic surgery, particularly in tumour detection and histological margin assessment; however, its role in reconstructive planning following Mohs surgery remains poorly defined. This study explored how ChatGPT-4.0 interprets postoperative nasal defects and proposes reconstructive strategies following Mohs micrographic surgery.

Materials and Methods
An exploratory qualitative comparison was conducted using five representative nasal defects following Mohs micrographic surgery for basal cell carcinoma. ChatGPT-4.0 was provided with postoperative defect photographs and prompted to suggest reconstructive approaches. Responses were qualitatively compared with surgeon-performed repairs, focusing on anatomical interpretation, recognition of nasal subunits, reconstructive reasoning, and clinical applicability.

Results
ChatGPT identified several commonly used reconstructive options and demonstrated logical understanding of basic flap principles and procedural sequencing. Performance was strongest in simpler defects, where partial or complete concordance with the surgeon's approach was observed. However, limitations became more apparent in anatomically complex cases involving the alar subunit, nasal tip, and sidewall junction. These included inconsistent interpretation of defect depth, imprecise appreciation of subunit boundaries, vague characterisation of flap variants, limited integration of patient-specific factors, and failure to identify more specialised reconstructive options such as the myocutaneous nasalis sling flap.

Conclusions
ChatGPT demonstrated meaningful but incomplete reconstructive reasoning in the assessment of post-Mohs nasal defects. While capable of recognising standard reconstructive concepts, its outputs lacked the anatomical precision, biomechanical understanding, and contextual surgical judgement required for independent clinical application. These findings highlight both the emerging potential and current limitations of generative artificial intelligence in reconstructive dermatologic surgery and support the need for continued expert oversight as multimodal AI systems evolve.

EA DV CONGRESS
VIENNA
30 SEP - 3 OCT 2026

Abstract N°: 4319

Perioperative Use of Adalimumab and Infliximab in Hidradenitis Suppurativa Surgery: A Systematic Review of Clinical and Patient-Reported Outcomes

Sheeda Jabeen*[1], Summayya Ansari[2], Mohammed Mujtaba Latifee[3], Eman Firdaous[4], Amaan Siddiqui[4], Mohd Faizan Siddiqui[4]

[1] Faculty of Medicine, Tbilisi State Medical University, Tbilisi, Georgia
[2] Faculty of Medicine, David Tvildiani Medical University, Tbilisi, Georgia
[3] Faculty of Medicine, Ken Walker International University, Tbilisi, Georgia
[4] International Medical Faculty, Osh State University, osh, Kyrgyzstan

Introduction

Hidradenitis suppurativa (HS) is a chronic, inflammatory skin condition with recurrent, painful nodules, abscesses and scarring. A biosurgical approach (biologics plus surgery) is increasingly used for moderate-to-severe HS. However, clinicians face a critical dilemma on whether to continue or hold anti-TNF agents (Adalimumab/ Infliximab) perioperatively. Concerns regarding wound healing and infection risk conflict with the need to prevent postoperative flares. No prior systematic review has synthesized evidence on this question. This review therefore evaluates perioperative anti-TNF management in HS surgery, focusing on patient-reported outcomes, quality of life (QoL), pain and satisfaction; alongside surgical complications, disease flares, and the role of multidisciplinary care.

Materials and Methods

A systematic search of PubMed and Scopus (inception to May 2026) was performed using MeSH and free-text terms for “Hidradenitis suppurativa”, “anti-TNF agents”, “adalimumab”, “infliximab”, and “perioperative surgery”. Eligible studies included randomized controlled trials (RCTs), cohort studies, case series (≥10 patients) reporting HS patients receiving perioperative anti-TNF therapy. Two reviewers independently screened titles/abstracts and full texts with discrepancies resolved by a third reviewer. Initial search yielded 76 records. The study selection process is summarized in a PRISMA flowchart.

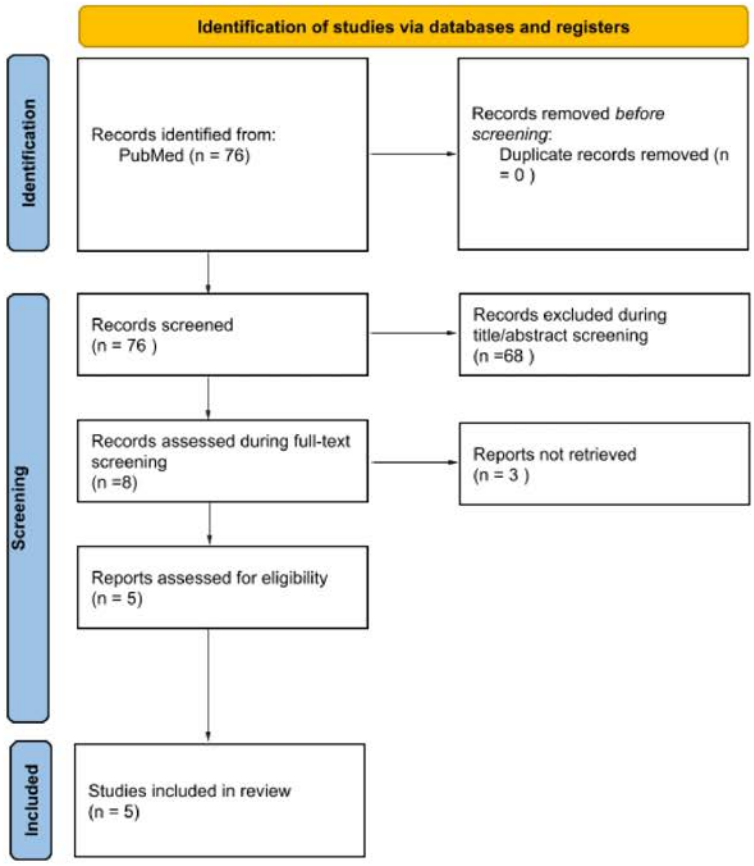

Figure 1: PRISMA Flow Diagram for Study Selection

Figure 1: PRISMA Flow Diagram for Study Selection

Results

Five studies met inclusion criteria (2 RCTs, 2 cohort studies, 1 prospective case series; total N = 212 patients). Both RCTs reported that perioperative continuation of adalimumab significantly improved Dermatology Life Quality Index (DLQI) scores versus placebo or adalimumab alone (mean DLQI reduction 8.2-9.4 points; $p<0.05$). Vu et al. (2025) found deroofing combined with adalimumab reduced pain and improved QoL, with 10-11% recurrence at 12 months. Esme et al. (2025) directly compared continuation versus stopping, finding no significant difference in total wound closure time after confounder adjustment ($p=0.076$), indicating continuation does not impair healing.

Shanmugam et al. (2018) reported that patients receiving biologic therapy (adalimumab/infliximab) plus surgery achieved a 75% reduction in active nodules more often than surgery alone (p=0.017), with recurrence lower in the combination group. No study reported increased surgical site infections or serious adverse events attributable to perioperative anti-TNF use.

Conclusions

Perioperative continuation of anti-TNF therapy in HS surgery appears safe and is associated with improved PROs and disease control compared to no anti-TNF or surgery alone. Only one study directly compared continuation vs. stopping, finding no significant difference in wound healing. Current evidence supports continuation of therapy, but firm guidance is pending a dedicated trial. Future studies should investigate long-term biosurgical synergy across various patient cohorts to optimise multidisciplinary management of complex HS.

EA DV CONGRESS
VIENNA
30 SEP - 3 OCT 2026

Abstract N°: 4375

Karapandzic flap for skin cancer affecting the lower lipp: Nitroso-Eprosartan as possible link to Nitrosophototoxicity/Nitroso photo carcinogenicity

Georgi Tchernev[1, 2], Ilia Lozev[3], Ivan Pidakev[3], Konstantin Tchernev Jr[2], Simona Kordeva*[1]

[1] Medical Institute of Ministry of Interior - Department of Dermatology and Venereology, Sofia, Bulgaria
[2] Onkoderma- Clinic for Dermatology, Venereology and Dermatologic Surgery, Sofia, Bulgaria
[3] Medical Institute of Ministry of Interior - Department of Common and Vascular Surgery, Sofia, Bulgaria

Introduction

The new and modern aspects involving the pathogenesis of keratinocyte tumors, but not only, is based on the exogenous and endogenous formation of nitrosamines. The nitroso formation is set to appear following nitrosation of secondary and/or tertiary amines within the chemical structure of each drug under specific conditions. The exogenous formation is placed outside the body during manufacturing processes from the chemical structure/secondary and tertiary amino groups/ under specific conditions.

In the case of sartan used as monotherapy or in a regimen, nitroso impurities have been identified during the manufacturing process and classified further as Nitroso Impurities by the FDA.

The endogenous formation is placed inside the human body. When the specific drug is taken, in the stomach under acidic conditions and in the presence of nitrite-rich foods, the secondary and tertiary amino functional groups within the chemical structure undergo nitrosation. Following systemic absorption and skin deposition, the amines under UV irradiation undergo photodecomposition, leading to NO release and ROS interaction, DNA damage and subsequent skin cancer development and progression.

Materials and Methods

In the case of eprosartan, which does not contain secondary nor tertiary amino groups within its chemical structure, skin cancer development can still be developed as a “side effect”. The nitrosation occurs even without the need of secondary or tertiary amino groups.

At the moment, there are numerous international studies that connect the use of sartans with the development of keratinocyte tumors - either single or multiple.

We describe the first case of a patient with skin cancer on the lower lipp region (Figure 1 a-c) who took eprosartan at a dose of 600 mg once a day for a total period of about 15 years with intake interruptions of no more than 6 years. Primary complaints in the lower lip area are from about 6 months. A multidisciplinary team performed a successful surgical treatment using the Karapandzic method, achieving an optimal aesthetic result.

Based on the available literature data, the possible role of endogenous nitroso formation as a potential inducer for the development and progeression of squamous cell carcinoma is presented.



Fig.1a-c: Dense tumor formation with irregular borders located on the left lower lip with presence of central necrosis and hemorrhagic crusts.

Results

The tumor formation located on the lower left lip was preoperatively marked (Fig.2a). Under general endotracheal anesthesia, the tumor formation was excised (Fig.2b), involving about 2/3 of the lip length with resection lines of 10 mmfor each side of the formation. After the radical excision (Fig.2b), careful hemostasis was performed. According to the Karapandzic method, two flaps were formed (Fig.2c-e). During the mobilization of the orbicularis oris muscle, the depressors and levators of the lower lip, the branches of the facial artery and facial nerve that feed the flaps were preserved. Thorough hemostasis was again performed (Fig.2e). The surgical wound was closed in layers, anatomically, starting with a single interrupted sutures of the mucosa, orbicularis oris muscle, subcutaneous tissue and the skin (Fig.2f).



Fig.2a-f: Intraoperative view of the surgical process 2a: Preoperative marking of the resection lines 2b: Intraoperative finding: tumor excision with thorough hemostasis afterwards 2c,d: Intraoperative findings: mobilization of the grafts, which will be used to close the remaining defect. Thorough hemostasis. 2e: Intraoperative view:Thorough hemostasis 2f:Intraoperative view: The remaining defect was closed with single interrupted sutures

Conclusions

Histopathological verification of squamous cell carcinoma was made.Smooth postoperative period was observed. The operative wound was left to heal primarily.

EADV Congress 2026, VIENNA
30 SEPTEMBER - 03 OCTOBER 2026
POWERED BY M-ANAGE.COM

EADV CONGRESS
VIENNA
30 SEP - 3 OCT 2026

Abstract N°: 4377

Re-excision or observation for completely excised severely dysplastic nevi: a systematic review

Pablo Balado-Simó*[1], Felipe Alcayaga de la Ribera[2], Felipe Henriquez-Ortega[2], Daniel Morgado Carrasco[3]

[1] Dermatology Department, Hospital Clínic Barcelona, Barcelona, Spain, Melanoma Group, August Pi Sunyer Biomedical Research Institute (IDIBAPS), Barcelona, Spain, University of Barcelona, Barcelona, Spain., Barcelona, Spain

[2] Dermatology Department, Hospital Clínico Universidad de Chile, Chile, Santiago, Chile

[3] Dermatology Department, Hospital Clínic Barcelona, Barcelona, Spain, Barcelona, Spain

Introduction

The management of completely excised severely dysplastic melanocytic nevi (CE-SDMN) remains controversial. Although their biological risk after complete excision appears to be low, surgical re-excision is frequently performed despite negative histological margins, mainly because of diagnostic uncertainty and lack of robust outcome-based evidence. This may result in unnecessary procedures, costs and patient burden. We aimed to systematically review the evidence comparing clinical observation and surgical re-excision in CE-SDMN, focusing on local recurrence, melanoma development at the biopsy site, metastasis and melanoma-related mortality.

Materials and Methods

A systematic review was conducted according to PRISMA guidelines and registered in PROSPERO. PubMed was searched from inception to December 31, 2025, and Cochrane CENTRAL was also reviewed. Eligible studies included patients or lesions diagnosed as CE-SDMN and managed with clinical observation, re-excision with 5-mm margins, or conservative re-excision with narrower margins, mainly 2–3 mm. Studies were required to include more than 20 patients, report clinically relevant oncological outcomes, and provide a median follow-up longer than 2 years. Study selection and data extraction were performed independently by three reviewers, with disagreements resolved by consensus or by a fourth reviewer. Risk of bias was assessed using ROBINS-I. Due to methodological heterogeneity, findings were synthesized qualitatively.

Results

Four retrospective studies published between 2017 and 2025 met the inclusion criteria. Overall, they included 1,232 biopsy-proven severely dysplastic melanocytic nevi, of which 823 were completely excised at initial biopsy. Follow-up ranged from a median of 26 months to 11.9 years. No randomized or prospective studies were identified.

A total of 420 CE-SDMN were managed with clinical observation without re-excision. Across these lesions, only one local event was reported, corresponding to melanoma in situ at the biopsy site. No cases of invasive local recurrence, locoregional or distant metastasis, or melanoma-related death attributable to the index CE-SDMN were observed. Studies evaluating re-excision also showed very low event rates. In one multicentre study, 31 CE-SDMN were re-excised with predefined 5-mm margins, with no local recurrence, melanoma development at the excision site, or metastatic progression after a mean follow-up of 67.7 months. Another study evaluated conservative re-excision with 2–3-mm margins in 271 CE-SDMN and reported no clinically detected local recurrence, no histological upstaging to melanoma, and no melanoma development at the excision site after a median follow-up of 26 months.

Overall, available data did not show a measurable oncological benefit of routine re-excision compared with clinical observation after complete excision. All included studies were retrospective and showed moderate to serious risk of bias, mainly due to confounding, selection bias, heterogeneous definitions and variable outcome reporting.

Conclusions

Available evidence suggests that clinically relevant adverse outcomes after complete excision of SDMN are exceedingly rare. In the included studies, routine surgical re-excision did not show a clear oncological benefit over clinical observation. Re-excision appears most appropriate in selected cases with diagnostic uncertainty, such as partial biopsies, positive histological margins, or concern for an inadequately sampled melanoma. When re-excision is chosen, conservative margins of 2–3 mm may be sufficient in appropriately selected cases. These findings support a risk-stratified, patient-centred approach that balances oncological safety with avoidance of unnecessary surgical procedures. Prospective studies with standardized histopathological definitions and long-term follow-up are needed to confirm these findings.

EADV CONGRESS
VIENNA
30 SEP - 3 OCT 2026

Abstract N°: 4420

O-Z flap for scalp reconstruction: a case series

Patrícia Moreira Gomes*[1], Ruben Nogueira Costa[1], Bárbara Vieira Granja[1], Ana Margarida Barros[1], Miguel Costa Silva[1]

[1] Department of Dermatology and Venereology, São João Local Health Unit, Porto, Portugal

Introduction
The O-Z flap is a rotation flap based on two opposing curvilinear arcs, particularly indicated for the reconstruction of round or oval scalp defects. This technique enables balanced mobilization of adjacent tissues and is especially useful for intermediate-sized defects, representing an effective alternative to skin grafting or more complex flap reconstructions.

Materials and Methods
A retrospective study was conducted, including seven clinical cases in which the O-Z flap was used for scalp reconstruction following surgical excision.

Results
The series included three squamous cell carcinomas, three basal cell carcinomas, and one pleomorphic dermal sarcoma. All defects were intermediate in size (3–5 cm in diameter). In all but one case, reconstruction was performed in a single stage, and intraoperative frozen section analysis was used in three cases. All flaps demonstrated good viability, with uneventful healing and preservation of scalp function. No significant postoperative complications were observed. Functional and aesthetic outcomes were satisfactory in all patients, with balanced tension distribution and preservation of hair-bearing scalp.

Conclusions
The O-Z flap is a versatile and reliable option for scalp reconstruction in selected intermediate-sized defects. Its main advantages include preservation of hair-bearing tissue, balanced tension distribution, low complication rates, and favorable aesthetic and functional outcomes achieved in a single-stage procedure. Our experience in seven cases supports its role as a first-line reconstructive option for appropriately selected scalp defects.

EADV CONGRESS
VIENNA
30 SEP - 3 OCT 2026

Abstract N°: 4447

Frailty Assessments and Surgical Outcomes in Older Adults undergoing Mohs Micrographic Surgery

Alicia Goh*[1], Grace Boyd[1], Matthew Costley[1], John McKenna[1], Olivia Dolan[1]

[1] Mohs Micrographic Surgery Unit, Royal Victoria Hospital, Belfast, United Kingdom

Introduction
As skin cancer incidence rises, increasing numbers of older adults are undergoing Mohs micrographic surgery (MMS). Although MMS is generally well tolerated, frailty may influence postoperative burden and patient experience. Our primary aim was to evaluate the association between frailty and postoperative outcomes in adults aged ≥75 years. Our secondary aims were to assess changes in frailty status from initial MMS evaluation to surgery and to evaluate patient acceptability of MMS.

Materials and Methods
A retrospective cohort study of adults (aged ≥75) who underwent MMS over a 7-month period. Frailty was assessed at initial Mohs consultation and repeated at surgery using the Rockwood Clinical Frailty Scale and Geriatric-8 (G8) screening tool. A Rockwood score of ≥4 was defined as vulnerable or frail, a G8 score of ≤14 was considered abnormal. Outcomes included number of Mohs stages, reconstructive method, postoperative wound reviews, and adverse outcomes. Adverse outcomes included delayed wound healing, defined as failure to achieve wound healing by 8 weeks; and infection, defined as swab positive and responsive to oral antibiotics. Participants were surveyed regarding willingness to undergo MMS again.

Results
Twenty patients were included (mean age 82 years, range 76–88) who underwent a mean of 2 Mohs stages (range 1–3). Reconstruction included flap repair (30%), partial closure or secondary intention healing (25%), skin grafting (20%), and primary closure (20%). The mean interval between assessment and surgery was 357 days (IQR 160). Between time of assessment and time of surgery, there was a significant decrease in mean G8 score from 14.6 to 11 (p-value 0.017) and increase in mean Rockwood score from 2.65 to 3 (p-value 0.011), demonstrating increasing frailty over time. Postoperative adverse outcomes occurred in 20% (n=4), including surgical site infection (n=2) and delayed wound healing (n=2). In the group with adverse outcomes, there was a trend towards higher frailty (mean G8 12.75; mean Rockwood 4.5) compared to those without (mean G8 14.18; mean Rockwood 2.8). Four patients declined further MMS; this subgroup demonstrated higher frailty at the time of surgery (mean G8 12.7; mean Rockwood 4.25), alongside greater reconstructive complexity and increased postoperative burden.

Conclusions
We see a trend towards greater frailty in those with adverse post-operative outcomes and a significant increase in frailty between time of initial MMS assessment and time of surgery. Most were willing to undergo MMS again, however those who declined further surgery demonstrated higher frailty scores. Our findings suggest that by incorporating routine frailty screening, it can help us identify vulnerable patients early. This may help guide shared decision-making, optimise perioperative planning and prompt consideration of alternative management strategies.

EA DV CONGRESS
VIENNA
30 SEP - 3 OCT 2026

Abstract N°: 4480

Periocular reconstruction in the Dermatology Department: outcomes after Mohs' micrographic surgery

Danae Trokoudes[1], Ying Teo[1], Fiona Robinson[1], Kathleen Fan[1], Saqib Bashir*[1]

[1] King's College Hospital, London, United Kingdom

Introduction

Introduction

The periocular area is a challenging site for reconstruction, often requiring cross-specialty collaboration with oculoplastic surgery.There are limited data on secondary intention healing versus surgical repair with secondary intention healing historically used for only small superficial defects. We explore this under studied area of reconstructive dermatological surgery in more detail.

Materials and Methods

A retrospective review was performed over a 5 year period between August 2019 and March 2024 in a tertiary dermatology/oculoplastic centre. All patients undergoing Mohs micrographic surgery (MMS) were identified, those having MMS in the periocular area were included. The periocular region was defined as upper eyelid (UE), lower eyelid (LE), medial canthus (MC), lateral canthus (LC). The eyebrow (EB) was included if the lesion extended to the upper eyelid. Data included tumour location, histology, defect dimensions and area pre and post MMS, and type of reconstruction. Complications were defined as ectropion, epiphora, notching, tethering, hypertrophy. Patients were seen 1, 2 & 4 weeks post surgery. Reviews at 3 or 6 months were arranged for patients with larger defects or complex reconstruction.

A previous retrospective analysis was performed at the same centre in 2009-2015 and the data from this study was combined with the current study in a further analysis.

Results

458 Mohs cases were identified. 100 cases were identified from the database as periorbital cases. 4 cases were excluded for incomplete notes. 96 patients were included in the study. The mean age was 69.5 +/- SD 13.7. There were 57 females and 39 males. 54/96 tumours were nodular BCCs, followed by noduloinfiltrative 19/96. 11/96 tumours were SCCs. 35/96 of cases were on the lower eyelid with, followed by the medial canthus 25/96, the upper eyelid 9/96 and the lateral canthus 6/96. 21/96 lesions affected multiple subunits as follows (summarise in a chart): LE/MC 2, UE/EB 6, LE/LC/UE 1, MC/UE 1, LE/infraorbital cheek 5, UE/EB/temple 2, MC/infraorbital cheek 2. Post MMS dimensions (horizontal x vertical) measured 14.1 +/-SD 9.4 x 13.0 +/-SD 9.1. The mean defect area post Mohs was 257.8mm.

In 13 patients there was involvement of the eyelid margin: 6 of these had secondary intention healing, 1 of which developed mild notching of the lower eyelid. 89/96 patients had reconstruction within dermatology with 7 patients requiring specialist input for their reconstruction. Six patients were operated on by oculoplastics and 1 jointly by maxillofacial and oculoplastics. Secondary intention healing was used in 44% of patients (42/96). 11/96 were direct closures, 6/96 patients had FTSGs.

In terms of reconstructions 17 patients had advancement flaps, 2 of which were V to Y island pedicle flaps, 2 were O to T and 2 were tarsoconjunctival advancement flaps (Hughes). One of the patients who underwent a Hughes repair had joint reconstruction under the oculoplastics and maxillofacial team and had right lower lid and upper lid reconstruction with a hard palate graft followed by a Hughes repair. 9 patients had rhombic transposition flaps & 7 patients had rotation flaps. One patient proceeded to have exenteration. Four patients had a combination of repairs: V to Y and secondary intention healing, V-Y and rotation flap, cheek rotation flap and FTSG.

Conclusions

11 patients had mild complications, mostly mild ectropion not needing intervention; 2 were referred for oculoplastics input but both declined surgery. One patient who had a 24x27mm defect of the MC allowed to heal by secondary intention developed mild ectropion and epiphora. She was referred for correction however declined further surgery as she was asymptomatic and the ectropion was mild. A patient with a 10x5mm of the lower eyelid allowed to heal by secondary intention developed lower lid notching one month postoperatively and was offered a wedge excision. He declined surgery as he was asymptomatic and was discharged.

EA DV CONGRESS
VIENNA
30 SEP - 3 OCT 2026

Abstract N°: 4491

EFFECT OF RELAXING MUSIC ON PAIN AND ANXIETY DURING DERMATOLOGIC SURGICAL PROCEDURES : A PROSPECTIVE STUDY OF 310 PATIENTS

Hajar Dahmani*[1], Ouiame El Jouari[1], Salim Gallouj[1]

[1] University Hospital Center Mohammed VI of Tangier, Tangier, Morocco

Introduction
Dermatological procedures, although most often performed under local anesthesia, can still be a source of pain and anxiety for patients. Among non-pharmacological approaches, relaxing music represents a promising option. However, the available literature remains limited, with still heterogeneous results.
In this context, this study aims to evaluate the effect of natural sounds on patients' pain and anxiety, as well as on the stress perceived by physicians, during various dermatologic surgical procedures performed in our dermatology department.

Materials and Methods
A prospective randomized controlled, non-blinded study was conducted in our department on 310 patients undergoing dermatologic surgery over an 8-month period. Procedures performed under general anesthesia, pediatric patients, and individuals with a diagnosed or treated anxiety disorder were excluded.
Two groups were formed: a "Music" group, exposed during the surgical procedure to relaxing music inspired by natural sounds broadcast through a loudspeaker (also audible to the physician), and a "Control" group with no auditory stimulus.
Sociodemographic data, the type of procedure, and its anatomical location were collected. Patient anxiety was assessed using the Visual Analog Scale (VAS) and the 6-item short version of the State-Trait Anxiety Inventory (STAI) before, during, and after the procedure. Measurements were performed by an investigator different from the one responsible for randomization.
The perioperative anxiety of the operating physician was evaluated using the same tool. Multivariate analyses and interaction tests were performed to adjust the results for potential confounding variables, with a significance threshold set at $p < 0.05$.

Results
A total of 310 participants were included: 155 in the "Music" group and 155 in the "Control" group. No significant differences were observed between the two groups regarding sociodemographic characteristics, anatomical location, or the type of procedure performed.
Overall, the Music group showed a moderate reduction in pain (Δ VAS = −0.90 ± 0.25), which was more pronounced in women (Δ VAS = −1.10 ± 0.30), compared with the Control group (Δ VAS = −0.40 ± 0.22), although this difference did not reach statistical significance.
The Music group demonstrated a significant reduction in perceived anxiety (VAS: 4.5 ± 0.9 vs 3.0 ± 0.8; $p < 0.0001$) as well as measured anxiety (short-form STAI: 11.8 ± 2.3 vs 7.7 ± 2.3; $p < 0.0001$).
Multivariate analyses confirmed the independent effect of music, particularly during procedures performed on the lower limbs ($p < 0.0001$).
No significant interaction was found with age, sex, or type of procedure. No adverse effects were reported.
Physicians' stress levels were significantly lower in the Music group ($p < 0.0001$), with a moderate positive correlation between patient anxiety and physician stress ($r = 0.26$), suggesting a link between patient well-being and caregiver well-being.

Conclusions

Relaxing music appears to be an effective analgesic and anxiolytic tool that is inexpensive, safe, and easy to implement, which dermatologists may consider integrating into their routine clinical practice.

A contextualized evaluation, taking into account the type of procedures, cultural preferences, and clinical situations, could help optimize its integration into dermatological practice.

EA DV CONGRESS
VIENNA
30 SEP - 3 OCT 2026

Abstract N°: 4552

Eyebrow Transplantation Using Long-Hair Follicular Units: A 114-Patient Single-Surgeon Experience

Luísa Groba Bandeira*[1]

[1] Private Practice in Dermatology, Sao Paulo, Brazil

Introduction
Eyebrow transplantation demands precise intraoperative control of graft direction, angulation, and curvature, parameters that determine the naturalness of the final result. Conventional short-hair FUE provides no real-time feedback on these variables once grafts are placed. The long-hair follicular unit excision (FUE) technique addresses this limitation by preserving the hair shaft, enabling continuous intraoperative visualization. I describe a refined long-hair FUE protocol based on consecutive series, including patient selection, technical protocol, management of complex cases, and critical pitfalls.

Materials and Methods
Retrospective descriptive analysis of 114 consecutive patients (112 women, 2 men; age 24–70 years) undergoing long-hair FUE eyebrow transplantation between July 2023 and September 2025 (follow-up 6–12 months). Absolute contraindications included active alopecia areata, trichotillomania, and cicatricial alopecias in the inflammatory phase; selected cicatricial cases were considered after at least one year of documented stability.[1] Harvesting: 0.95-mm oscillatory punch; [2] grafts dissected into single-hair units under microscopy, trimmed to ~3 cm. Implantation: sharp 0.7-mm implanters, coronal orientation, 5–10° insertion angle; spin maneuver applied when indicated.[3] Fibrotic recipient beds (post-micropigmentation or laser): pre-incisions with 24-gauge needle + stick-and-place technique with dull implanter.[4] Preoperative botulinum toxin A (~40 U onabotulinumtoxinA) offered routinely to minimize graft misalignment during early healing. Oral minoxidil prescribed postoperatively in most cases.

Results
Long-hair visualization enabled real-time correction of direction, angulation, and density throughout implantation. Mean graft count: 200–300 single-hair units per eyebrow. No major complications or infections were recorded. One case of herpes zoster occurred postoperatively, attributed to stress-induced varicella-zoster virus reactivation. 30% of patients underwent an elective secondary session for density refinement, an outcome disclosed in preoperative counseling. Adjuvant protocols (microneedling with topical actives, hyperbaric oxygen) were explored in selected cases with promising preliminary observations.

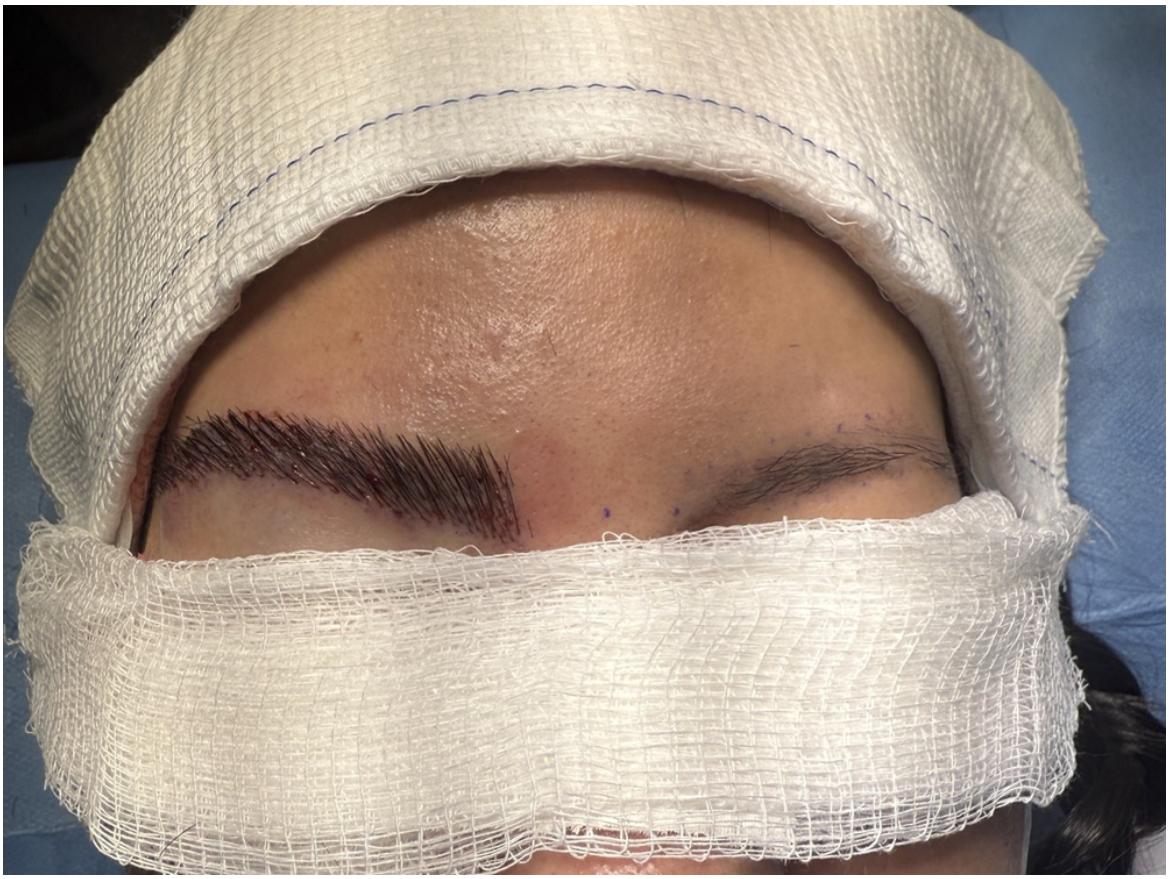

Figure 1. Intraoperative view during long-hair follicular unit eyebrow transplantation, illustrating real-time assessment of hair direction, angulation and density as grafts are placed.

Conclusions

Long-hair FUE offers a technically meaningful advancement in eyebrow restoration, providing intraoperative feedback unavailable with short-hair techniques. Optimal outcomes depend on recipient bed assessment, individualized adaptations for challenging anatomies, and structured patient counseling. This series demonstrates that, with appropriate surgical expertise and patient selection, the technique yields consistent, aesthetically superior results, supporting its broader adoption in hair restoration practice.