Abstract N°: 9

Primary Cutaneous B-Cell Lymphomas: A 13-Case Series from a Referral Center inBuenos Aires, Argentina

Marianela Luján Geloso*[1, 1], paula Enz[1], martina granara[1], jenny baquero[1], belen luengo[1]

[1] hospital italiano de buenos aires, buenos aires, Argentina

Introduction
Los linfomas cutáneos primarios de células B (LCPBC) son neoplasias linfoides poco frecuentes que surgen en la piel sin afectación extracutánea al momento del diagnóstico, según la clasificación de la OMS-EORTC. El comportamiento clínico y el pronóstico varían según el subtipo histológico, por lo que es fundamental una clasificación clinicopatológica e inmunohistoquímica precisa. Los datos de Latinoamérica siguen siendo limitados.

Case Presentation
MethodsA retrospective, descriptive observational study was conducted including patients with histopathologicallyconfirmed PCBCL treated between 2010 and 2025. Classification followed WHO–EORTC criteria.Demographic characteristics, histological subtype, lesion distribution, initial staging, treatment modalities,and clinical outcomes were analyzed.ResultsThirteen patients were included, with a mean age of 70 years (range: 57–90) and a slight femalepredominance (7:6). Histological subtypes included primary cutaneous marginal zone lymphoma (PCMZL)(n=6), primary cutaneous follicle center lymphoma (PCFCL) (n=3), and primary cutaneous diffuse large B-cell lymphoma, leg type (PCDLBCL-LT) (n=4).Therapeutic strategies comprised intralesional corticosteroids, surgical excision, radiotherapy, rituximab,and systemic chemotherapy (R-CHOP), depending on histological subtype, disease extent, and patientcomorbidities. During follow-up, nine patients achieved complete response, two experienced relapse, andthree showed disease progression. No lymphoma-related deaths were recorded. One patient with PCMZLdeveloped secondary nodal involvement.

Conclusion
This series demonstrates a predominance of indolent PCBCL subtypes, consistent with internationalreports. Histopathological subtype remains the main prognostic determinant and the cornerstone guidingtherapeutic decision-making. Reporting regional case series contributes to improving epidemiologicalknowledge and optimizing the management of these rare lymphomas in Latin America.
Learning Objectives:To describe the clinical, histopathological, therapeutic features, and outcomes of patients with PCBCLtreated at a referral center.

Abstract N°: 13

Rapidly Progressive In-Transit Metastases in BRAF-Mutated Scalp Melanoma: A Case Report

Carina Mihu-Silaghi*[1], Mircea Negrutiu[2], Lorena Calancea-Lisencu[3]

[1] Medlife, Cluj-Napoca, Romania
[2] UMF "Iuliu Hatieganu", Cluj-Napoca, Romania
[3] Medispa, Cluj-Napoca, Romania

Introduction

Scalp melanoma is an uncommon subtype of cutaneous melanoma, accounting for about 2–5% of cases, but it is associated with a worse prognosis than melanoma at other sites. Delayed recognition due to hair coverage, rich lymphatic and vascular supply, and a tendency toward greater tumor thickness at diagnosis contribute to its aggressive behavior. Scalp melanomas are more frequently associated with regional and distant metastases. Molecular alterations, particularly involving the MAPK pathway such as BRAF mutations, may influence both tumor progression and therapeutic options.

Case Presentation

Materials and MethodsWe report the case of a 58-year-old man presenting with a pigmented scalp lesion with a five-year history of gradual enlargement, recently becoming painful. His medical history was significant for a recent ST-segment elevation myocardial infarction treated one month earlier by PTCA and stent implantation. Clinical, dermoscopic, histopathological, and imaging evaluations were performed.Dermoscopic FindingsDermoscopy showed an asymmetric multicomponent lesion with dark brown, black, gray-blue, and light brown areas, along with focal whitish zones. Irregular black blotches, blue-gray structureless areas, peppering, and regression features were present. The lesion also showed crusting and adherent scale, while vascular structures were not clearly visible because of dense pigmentation and hyperkeratosis. Overall, the dermoscopic appearance was highly suggestive of melanoma.Treatment and EvolutionThe lesion was excised with narrow margins (0.5 cm anteriorly, 0.8 cm posteriorly, and 0.2 cm medially and laterally). Histopathology revealed superficial spreading melanoma in vertical growth phase, with Breslow thickness 9.2 mm and Clark level V. Immunohistochemistry was positive for HMB45, SOX10, PRAME, and p16, with a mitotic rate of 4 mitoses per high-power field. Molecular analysis identified a BRAF V600 mutation. Although wide local re-excision was initially planned, it was no longer feasible because, within three weeks, the patient developed rapidly progressive in-transit metastases involving approximately 35% of the scalp surface. PET imaging also identified a vertebral metastasis. First-line systemic treatment with nivolumab and ipilimumab was started, resulting initially in disease stabilization. No new in-transit lesions appeared, but a necrotic ulcer of about 3 cm developed within the regressing metastatic area. Four months later, follow-up imaging showed hepatic and nodal metastases, prompting a switch to dabrafenib. After one month of targeted therapy, the patient is clinically stable, with no new lesions identified.

Conclusion

Scalp melanoma is a particularly aggressive form of cutaneous melanoma that may remain unnoticed until advanced stages. This case highlights the importance of careful scalp examination and dermoscopy, especially in hair-bearing areas where diagnosis may be delayed. Early recognition and prompt multidisciplinary management are essential, as rapid locoregional progression can quickly limit therapeutic options and worsen prognosis.

POWERED BY M-ANAGE.COM

EA DV CONGRESS
VIENNA
30 SEP - 3 OCT 2026

Abstract N°: 15

Primary cutaneous diffuse large B-cell lymphoma: Case report and Literature review

Norma Angelica Diaz Sandoval*[1]

[1] Instituto mexicano del Seguro Social, Ciudad de México, Mexico

Introduction

Initially identified in the lymph nodes, non-Hodgkin lymphoma was first described in 1832 and since then, its clinical, histopathological, immunopathological and molecular genetic characteristics have been widely investigated, which have led to various classifications. By definition, it is an entity that affects the lymph nodes, but primarily and in order of frequency, it involves the central nervous system, gastrointestinal system, genitourinary system and skin.1Primary cutaneous B cell lymphoma (PCCL) is a neoplastic proliferation of immunophenotype B lymphocytes that typically presents as a neoformation of exclusive cutaneous location, painless and with a good prognosis, although its incidence, classification and cellular origin are controversial.The mechanisms involved in the presentation and persistence of malignant B cells in the dermis are unknown. In rare cases it has been related to persistent antigenic stimulation secondary to the action of infectious agents, including viruses

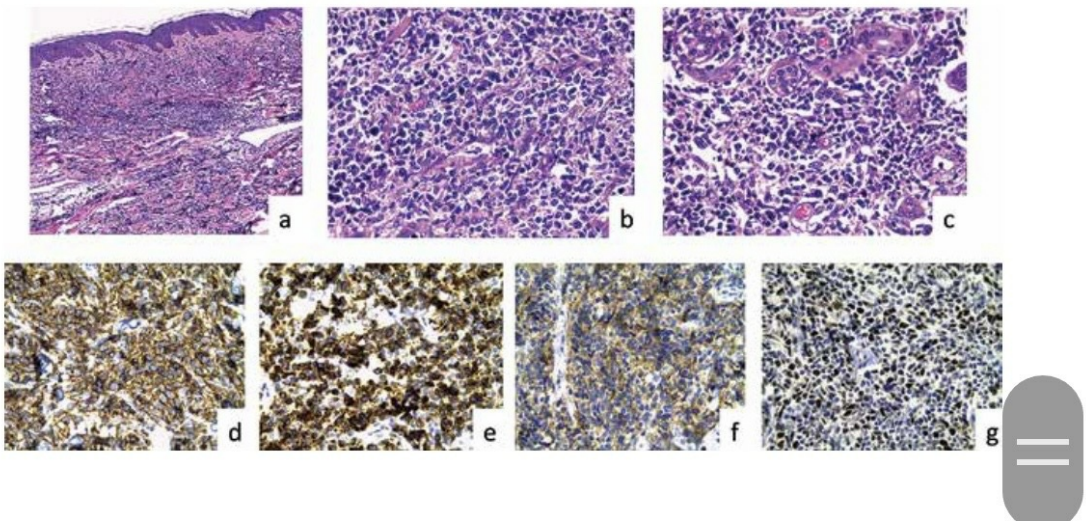

Histopathology images of biopsies stained with hematoxylin and eosin (H&E, 40X). CD20, CD10, Ki-67 (immunohistochemical markers, 40X).

Case Presentation

An 82-year-old male patient, previously healthy, presented with a dermatosis located on his left forearm. The lesion, which had appeared in June 2021, was progressively and rapidly growing and characterized by three erythematous-violaceous, infiltrated, non-mobile, nodular tumors measuring 3, 4, and 6 cm in diameter. These tumors coalesced, causing swelling and deformity of the affected area, accompanied by intermittent itching and pain, as well as easy bleeding. At that time,

The histopathological result was marginal zone B-cell lymphoma. His clinical course has been protracted, with lesions appearing gradually and growing rapidly on his scalp, face, left upper eyelid, upper dental arch, neck, arms, forearms, hands, legs, and dorsal and lumbar regions. Dermatological examination revealed a dermatosis

consisting of multiple bleeding, erythematous-violaceous nodular lesions with poorly defined borders and multiple firm papules on their surface, situated on an erythematous base, with evidence of infiltration upon palpation. Disseminated dermatosis on both legs, consisting of multiple ulcerated, friable, infiltrated, erythematous-violaceous nodular lesions, varying in size from 3 to 5 cm in diameter, with irregular surfaces, poorly defined borders, and multiple firm papules on their surface, situated on an erythematous base, already showing evidence of infiltration upon palpation, and ulcerated, deforming the affected area. Both hands showed swelling, deformity, and functional limitation, with infiltration. In the distal regions of both hands, dry gangrene and ulcerations were present, along with absent distal capillary refill and complete functional limitation, with no range of motion.

Histological sections stained with hematoxylin and eosin revealed a normal epidermis. The superficial and deep dermis and hypodermis showed diffuse infiltration of lymphoid cells with abundant, partially defined eosinophilic cytoplasm, ovoid nuclei with a prominent nucleolus, and finely granular, spaced chromatin; foci of recent hemorrhage were also present. Subsequent immunohistochemistry yielded the following results: CD20-positive in neoplastic cells, MUM-1-positive in neoplastic cells and Ki-67-positive in 90% of cells, leading to the histopathological conclusion of diffuse large B-cell lymphoma.



It is observed that the tumor infiltrates the upper dental arch

Conclusion

The aim of reporting this case was to highlight the atypical clinical presentation of primary cutaneous B-cell lymphoma (PCBCL) in an immunocompromised patient in their eighth decade of life, given the rarity of disseminated primary cutaneous B-cell lymphomas. Likewise, the intention was to emphasize the importance of early clinical and histopathological diagnosis for a favorable outcome; however, in this patient, the course has been poor, with no response to three lines of chemotherapy, and unfortunately, the patient requires palliative care.



Tumor infiltration is shown in both hands, with erosion and destruction of the distal phalanges.

EA DV CONGRESS
VIENNA
30 SEP - 3 OCT 2026

Abstract N°: 27

Beyond a Persistent Scaly Rash: An Unusual Presentation of Peripheral T-Cell Lymphoma, Not Otherwise Specified (PTCL-NOS)

Xin Yun Teoh*[1], Ling Fong Ng[1], Sook Yee Michelle Voo[1]

[1] Hospital Queen Elizabeth, Kota Kinabalu, Malaysia

Introduction

Primary cutaneous peripheral T-cell lymphoma, not otherwise specified (pcPTCL-NOS), is a rare and highly aggressive subtype of cutaneous T-cell lymphoma, accounting for approximately 2% of primary cutaneous lymphomas. It demonstrates heterogeneous clinical presentations, often mimicking benign inflammatory dermatoses, leading to delayed diagnosis and poor outcomes.

Case Presentation

A 46-year-old man presented with a 3-year history of a progressive, generalized pruritic rash that was initially diagnosed clinically as tinea corporis. He was treated empirically with itraconazole but subsequently defaulted follow-up and self-administered over-the-counter topical preparations, with no significant improvement. One year later, he re-presented with erosions developing within pre-existing lesions.Cutaneous examination revealed widespread annular hyperpigmented scaly patches with erythematous borders, and erosion (Figure 1), without clinically palpable lymphadenopathy. Histopathologic examination demonstrated a dense dermal lymphohistiocytic infiltrate composed of atypical medium-to-large lymphoid cells without epidermotropism (Figure 2). Immunohistochemistry showed a cytotoxic T-cell phenotype (CD3+, CD5+, CD7+, CD8+), negative for CD4 and CD20, with expression of TIA-1, granzyme B, and TCR-α, and a high Ki-67 proliferation index (~70%). Extensive immunophenotyping excluded other primary cutaneous T-cell lymphomas, confirming a diagnosis of pcPTCL-NOS.Imaging revealed axillary and inguinal lymphadenopathy (measuring 1cm). However, lymph node biopsy was not performed as the patient declined lymph node biopsy and was clinically unstable for the procedure. He was treated with CHOP chemotherapy but developed progressive disease with worsening cutaneous involvement and ultimately succumbed from recurrent severe sepsis.

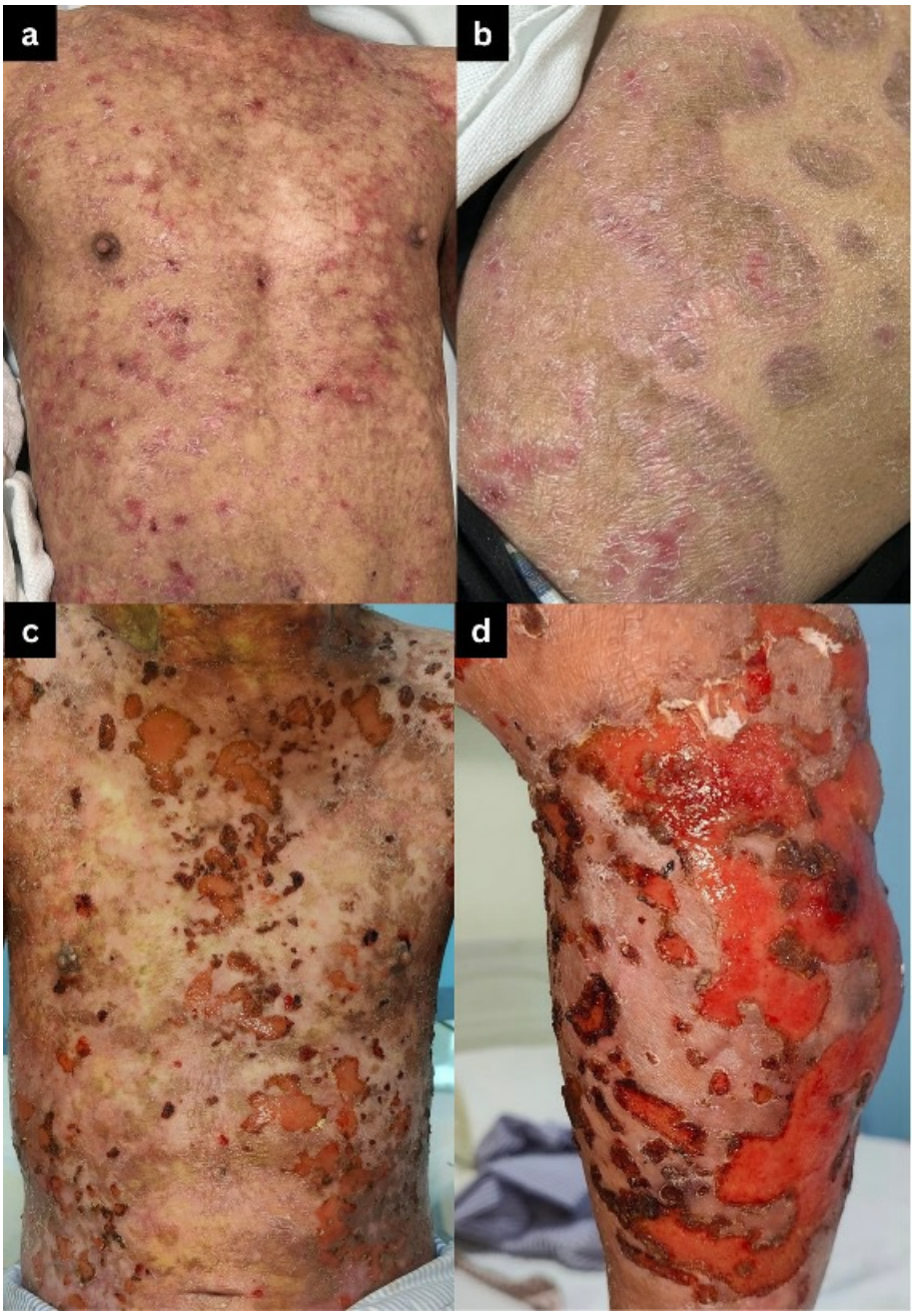

Figure 1: (a) Generalized annular erythematous scaly patches with multiple erosions on the trunk (b) Close-up view of the lesions on the left thigh (c) The multiple annular patches progressed, showing increased erosion and crusting (d) A tumor with granulation tissue is observed on the mid-portion of the right forearm

Conclusion

Primary cutaneous peripheral T-cell lymphoma, not otherwise specified (pcPTCL-NOS), is a rare and aggressive lymphoma that often mimics inflammatory dermatoses, leading to delayed diagnosis. Persistent, atypical, or treatment-refractory skin lesions should prompt early biopsy and close clinicopathologic correlation, as timely recognition and treatment may improve outcomes despite the overall poor prognosis.

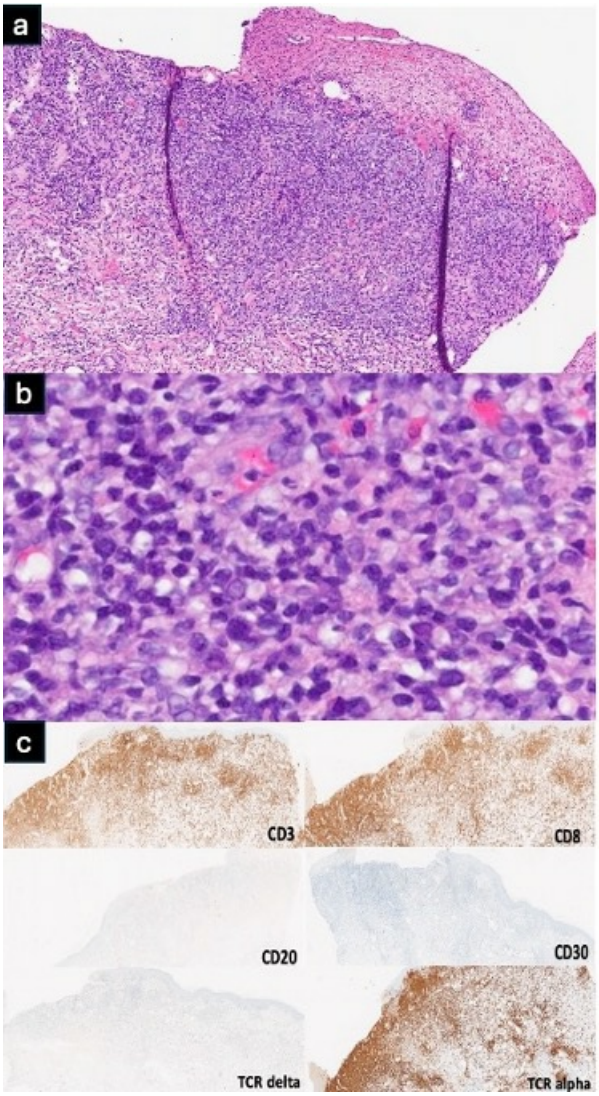

Figure 2: (a) Skin biopsy revealed a dense, band-like lymphohistiocytic infiltrate with scattered atypical medium-to-large lymphoid cells (H and E, x 40) (b) The close up view of atypical medium-to-large lymphoid cells, exhibiting nuclear hyperchromasia, irregular nuclear membranes, and atypical mitoses (H and E, x 400) (c) Immunohistochemical staining showed tumour cells express CD3, CD8, TCR alpha. CD20, CD30 and TCR delta were negative in large, atypical cells

EA DV CONGRESS
VIENNA
30 SEP - 3 OCT 2026

Abstract N°: 29

Cutaneous nodular AL-amyloidoma in a patient with Sjögren syndrome

Yi-Kuan Chiang*[1, 2], Tzu-Hang Kao[2, 3], Yi-Hsin Ho[1, 2]

[1] Department of Dermatology, Taipei Veterans General Hospital, Taipei City, Taiwan
[2] School of Medicine, National Yang Ming Chiao Tung University, Taipei City, Taiwan
[3] Department of Pathology and Laboratory Medicine, Taipei Veterans General Hospital, Taipei City, Taiwan

Introduction

Nodular amyloidosis is the rarest form of cutaneous amyloidosis, characterized by deep dermal deposition of amyloid composed of amyloid light chain (AL) proteins and a small risk of progression to systemic amyloidosis. The term “amyloidoma” was coined to describe localized tumoral deposits of amyloid in the absence of systemic involvement. It has been suggested that AL amyloidomas with light chain–restricted plasma cells may represent a rare manifestation and subtype of primary cutaneous marginal zone lymphoma (pcMZL) with indolent behavior and rare systemic involvement. Therefore, screening for underlying autoimmune connective tissue diseases may be beneficial. Herein, we present a case that highlights this association.

Case Presentation

A woman in her 50s with a history of Sjögren syndrome and markedly elevated serum anti-SSA and anti-SSB titers (both >240 U/mL; reference <7 U/mL) presented with several months of asymptomatic, clustered, waxy, firm, yellowish papules on the left lateral thigh. An excisional biopsy revealed nodular eosinophilic amorphous deposits centered in the lower dermis, demonstrating apple-green birefringence on Congo red staining under polarized light, along with foci of deep perivascular plasma cells showing predominant kappa light chain restriction and scant CD20-positive B lymphocytes (Figure 1). A comprehensive systemic workup—including serum and urine immunoelectrophoresis, serum immunoglobulin (Ig) levels, computed tomography, positron emission tomography, and bone marrow biopsy—was unremarkable except for an elevated serum IgG level (3480 mg/dL; reference 700-1600 mg/dL) without monoclonal band or IgG4 elevation. These findings excluded systemic light chain diseases, including systemic B-cell lymphoma, monoclonal gammopathy, and plasmacytoma. Four years after excision, a recurrent nodule developed on the lower back. Histopathological examination following re-excision revealed identical findings. Based on the latest definition in the World Health Organization 5th edition and the known increased risk of lymphoproliferative disorders in patients with Sjögren syndrome, the patient was managed as having pcMZL and referred for localized radiotherapy to prevent recurrence.

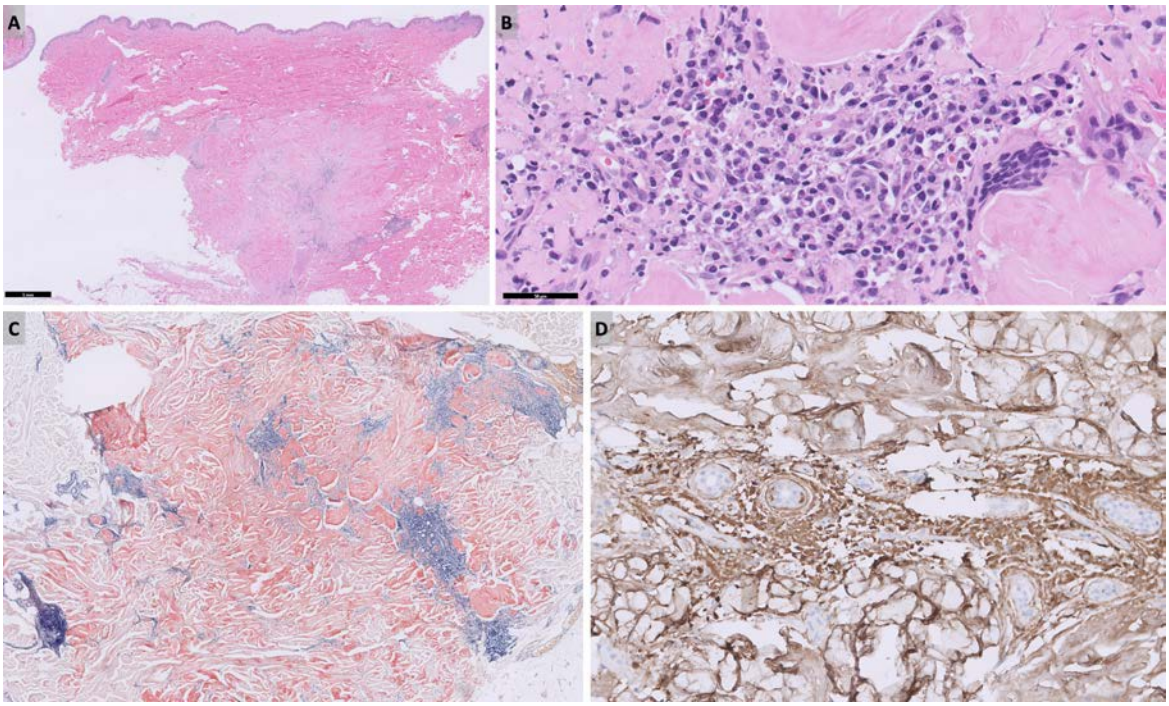

Figure 1. Skin histopathological examination shows nodular eosinophilic amorphous deposits centered in the lower dermis (A, hematoxylin and eosin [H&E] 1x), with foci of plasma cells and scant lymphocytes (B, H&E 40x). The deposits exhibit apple-green birefringence on Congo red staining under polarized light (C). The plasma cells show predominant kappa light chain positivity (D, kappa light chain immunostain).

Conclusion

This case highlights the potential association between Sjögren syndrome and B-cell lymphoproliferative disorders. Localized cutaneous AL amyloidoma with light chain restriction may represent a rare manifestation of pcMZL. Therefore, screening for Sjögren syndrome and careful exclusion of other light chain–related disorders are essential.

Abstract N°: 31

Adult onset Nodular mastocytosis : A rare presentation

Rashmi Sriram*[1]

[1] BGS MCH HOSPITAL, bengaluru, India

Introduction

Mastocytosis is a rare disorder characterized by the abnormal accumulation of mast cells in various tissues. We present a case of a forty-year-old female from Tamil Nadu, India, who presented with multiple hyperpigmented nodules over her neck, chest, abdomen, and extremities, along with systemic symptoms including diminished vision, respiratory distress, epistaxis, joint pain, and weight loss. Initial investigations revealed severe anemia, osteolytic lesions on imaging, and mast cell infiltration on skin biopsy. Subsequent bone marrow examination confirmed the diagnosis of systemic mastocytosis. Treatment with Imatinib mesylate was initiated, leading to a reduction in skin lesions. Comparison with similar cases highlights the diverse clinical manifestations and management approaches for this condition. This case underscores the diagnostic challenges and therapeutic considerations in adult-onset systemic mastocytosis, emphasizing the potential efficacy of Imatinib therapy in cases with multiorgan involvement.

Case Presentation

We present the case of a forty-year-old female from Tamil Nadu, India, who presented with multiple hyperpigmented nodules over her neck, chest, abdomen, and extremities, along with systemic symptoms including diminished vision, respiratory distress, epistaxis, joint pain, and weight loss.Neurological and motor examinations were normal. Differential diagnosis considered for this case included Histoid Leprosy, cutaneous tuberculosis, sarcoidosis, granuloma annulare, rheumatoid nodules, and nodular Mastocytosis. Initial investigations revealed severe anemia, osteolytic lesions on imaging, and mast cell infiltration on skin biopsy. Immunohistochemistry revealed the infiltrating cells were positive for CD117 and CD68. Subsequent bone marrow examination confirmed the diagnosis of systemic mastocytosis..
The patient was started orally on Imatinib mesylate , and she is currently undergoing treatment. Reduction in the size of skin lesions has been noted since the initiation of therapy.

Conclusion

This case adds to the existing literature on mastocytosis by illustrating the diagnostic and therapeutic challenges encountered in managing this condition. The differences and similarities identified with other reported cases underscore the heterogeneity of mastocytosis presentations and the importance of individualized treatment approaches. Additionally, our case highlights the rarity of presentation as nodular mastocytosis and effectiveness of Imatinib therapy in managing systemic mastocytosis with multiorgan involvement, suggesting its potential as a treatment option in similar cases.

EA DV CONGRESS
VIENNA
30 SEP - 3 OCT 2026

Abstract N°: 51

MELAPRED : A Parsimonious Clinical–Genetic Algorithm for Melanoma Risk Prediction

Meriem BENFODDA[1], Vincent Descamps[1], Madjlessi-Ezra Nika[2], Celeste Lebbe[2], Basset-Seguin Nicole[2], Archimbaud Alain[2], Baccard Michel[2], Opletalova Kristina[3], Vuong Valerie[3], Nicaise-Bergère Caroline[3], Renard Frederic[3], Massart-Manile Sandrine[3], JEGOU Juliette[3], COLOMB Michel[3], Saiag Philippe[4], Nicolas Dupin[5], Pierre Wolkenstein[6], Ribas Gloria[7], Nagore Eduardo[8], KUMAR Rajiv[9], Fargnoli Maria-Concetta[10], PERIS Ketty[11], Florent Grange[12], Nadem Soufir*[1]

[1] University Paris Cité, Paris, France
[2] Department of Dermatology, Saint-Louis Hospital, AP-HP, Paris, France
[3] Private Dermatology, Paris, France
[4] Department of Dermatology, Ambroise-Paré Hospital, AP-HP, Boulogne, France
[5] Department of Dermatology, Tarnier Hospital, AP-HP, Paris, France
[6] Department of Dermatology, GHU Henri-Mondor, AP-HP, UPEC, Creteil, France
[7] Department of Haematology and Medical Oncology, Fundacion Investigacion Hospital Clinico-INCLIVA,, Valencia, Spain
[8] Department of Dermatology, Instituto Valenciano de Oncología, Valencia, Spain
[9] Division of Molecular Genetic Epidemiology, German Cancer Research Center (DKFZ), Heidelberg, Germany
[10] Department of Dermatology, University of L'Aquila, L'Aquila, Italy
[11] Department of Dermatology, Università Cattolica del Sacro Cuore, Fondazione Policlinico Universitario A. Gemelli IRCCS, Roma, Italy
[12] Department of Dermatology, Valence Hospital Centre, Valence, France

Introduction
Accurate melanoma risk stratification may enable targeted surveillance while avoiding the complexity of large polygenic risk scores. We developed MELAPRED, a parsimonious clinical–genetic prediction model designed for routine clinical implementation.We aim to externally validate MELAPRED across independent European populations, quantify the incremental contribution of genetic information beyond clinical phenotype, and assess model calibration and geographical transportability.

Materials and Methods
A clinical model (MC) and a combined clinical–genetic model (MCG, MELAPRED) were developed by logistic regression in a Paris discovery cohort and evaluated in four independent European replication cohorts from Valencia, Madrid, L'Aquila and a French familial/multiple-melanoma population. Analytic samples comprised 895 cases/858 controls in Paris, 731/1,101 in Valencia, 178/166 in Madrid, 260/156 in L'Aquila and 156/105 in the familial/multiple-melanoma cohort. Discrimination was assessed by area under the ROC curve (AUC), incremental performance by DeLong testing and continuous net reclassification improvement (cNRI), and calibration by Hosmer–Lemeshow and Cox calibration analyses. Population-specific logistic recalibration was performed when required.

Results
The final MELAPRED model retained only five predictors: naevus count, eye colour, MC1R genotype, rs16891982 in SLC45A2 and rs10757257 near MTAP. In Paris, adding genetic information increased AUC from 0.70 to 0.75

(DeLong $p=1.14\times10^{-10}$). Risk estimates were upgraded in 62.5% of melanoma cases and downgraded in 57.5% of controls, yielding a cNRI of 39.8%. The combined model outperformed the clinical model in all four replication cohorts, with AUCs of 0.71 in Valencia (95% CI 0.69–0.73), 0.69 in Madrid (0.63–0.74), 0.66 in L'Aquila (0.61–0.71) and 0.89 in the familial/multiple-melanoma cohort. Calibration was satisfactory in Valencia and the familial cohort but suboptimal in Madrid and L'Aquila. Cox analysis identified slope-dominated miscalibration, with calibration slopes of 0.57 (95% CI 0.36–0.87) in Madrid and 0.63 (0.40–0.87) in L'Aquila versus 0.89 (0.77–1.03) in Valencia. Two-parameter logistic recalibration restored adequate calibration in all replication cohorts (post-recalibration Hosmer–Lemeshow p=0.21–0.90) without altering discrimination.

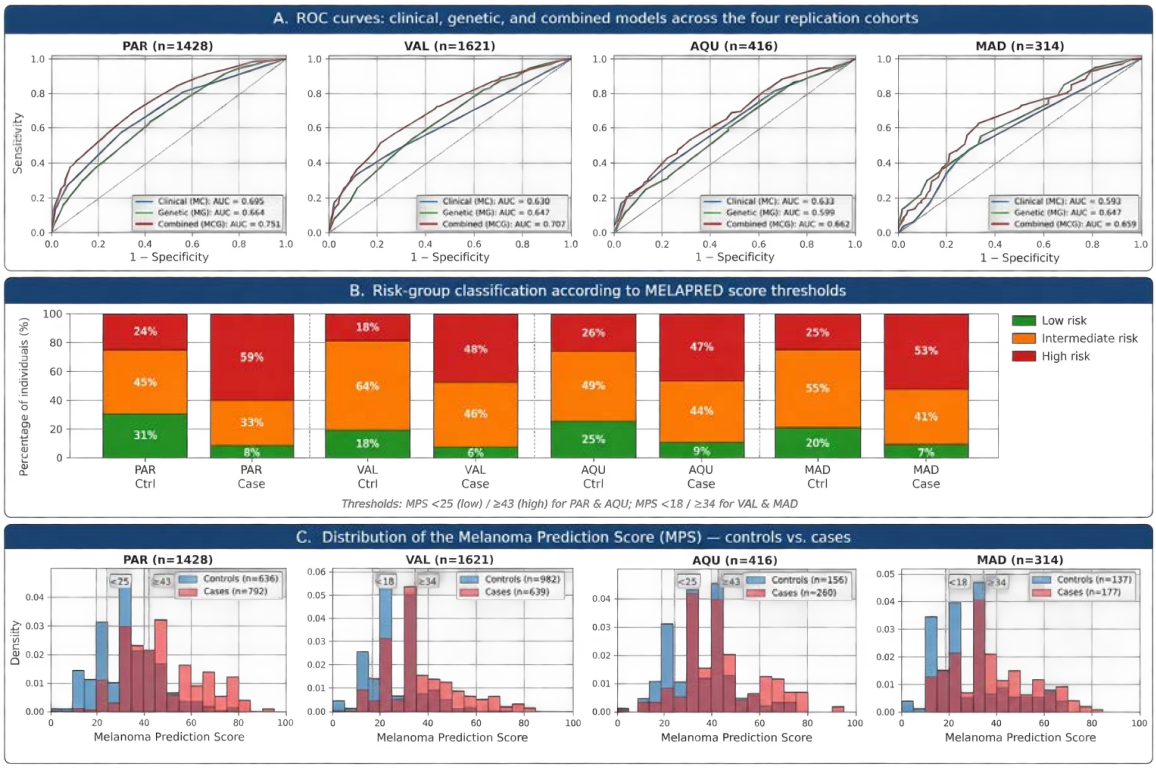

Conclusion

MELAPRED demonstrates that substantial improvement in melanoma risk stratification can be achieved using only two clinical and three genetic predictors. Its performance replicated across independent European populations, while simple population-specific recalibration corrected geographical differences in calibration without loss of discrimination. As a clinical perspective, re-analysis of previously reported prospective high-risk follow-up yields an estimated number needed to screen of 10.3 over 6 years, supporting further evaluation of MELAPRED as a tool for risk-stratified dermatological surveillance.

Abstract N°: 92

Skin Cancer in a Testicular Germ Cell Tumor Survivor: A Case Highlighting the Need for Dermatologic Surveillance

Fatma Hande Kaçar*[1], Duru Onan[2]

[1] Ankara Research and Training Hospital, Ankara, Türkiye

[2] Ankara Baskent University, Department of Dermatology, Ankara, Türkiye

Introduction

Testicular germ-cell tumors (TGCT), comprising both seminomas and non-seminomas, have become the most frequently diagnosed cancers in young adult men, with incidence rates consistently increasing. This case highlights the potential increased risk of skin cancer in patients with a history of testicular germ-cell tumors and emphasizes the role of additional risk factors and prior treatments. It also underlines the importance of regular dermatologic follow-up and patient education regarding UV protection. In addition, this case illustrates a possible association between TGCT survivorship and an increased risk of cutaneous neoplasms.

Case Presentation

A 46-year-old man presented for evaluation of a scalp lesion. He had a history of right testicular seminoma diagnosed five years earlier. His medical history also included an eccrine poroma arising on a nevus sebaceus, excised from the same region ten years earlier.The lesion was located in the left temporal region and had been gradually enlarging over the past 2–3 years. Dermoscopic examination revealed features compatible with basal cell carcinoma (BCC). The lesion was excised, including the residual areas of the underlying nevus sebaceus. A neck ultrasound (USG) was performed and showed normal findings. Histopathological evaluation confirmed superficial basal cell carcinoma.During total-body dermoscopic examination and digital mole mapping, a suspicious nevus on the anterior abdominal wall was also detected and excised. Histopathological examination revealed a dysplastic compound nevus with mild cytological and architectural atypia.Risk factor assessment revealed that the patient had more than 50 melanocytic nevi, fewer than five dysplastic nevi, Fitzpatrick skin type II, and no history of blistering sunburns or a family history of skin cancer. Although he reported regular sunscreen use, he had a history of significant sun exposure. No regional lymphadenopathy or metastatic findings were detected. The patient was advised to attend regular dermatologic follow-ups.

Conclusion

Survivors of testicular germ-cell tumors may have an increased risk of developing second primary malignancies, including skin cancer. Previous epidemiological studies have suggested a statistically significant increase in the risk of melanoma and non-melanoma skin cancers among TGCT survivors compared to the general population.Although further studies are needed to clarify the association between TGCT and skin cancer, TGCT survivors should be considered for lifelong dermatologic monitoring due to their increased skin cancer risk. Moreover, patient education regarding UV protection and self-skin examination should remain a cornerstone of long-term management.The coexistence of multiple cutaneous lesions in this patient further supports the importance of comprehensive dermatologic evaluation in TGCT survivors. This case highlights the importance of dermatologic surveillance in TGCT survivors and suggests that careful skin examination should be integrated into the long-term follow-up of these patients.

POWERED BY M-ANAGE.COM

EA DV CONGRESS
VIENNA
30 SEP - 3 OCT 2026

Abstract N°: 105

A 13-Gene Hedgehog Signature Distinguishes Basal Cell from Squamous Cell Carcinoma and Identifies FBN3 as a Candidate Regulator of Tumor Growth

Solomone Somani*[1], Ally-Khan Somani[2, 3]

[1] Illinois Math and Science Academy, Aurora, United States

[2] SkinMD, L.L.C., Orland Park, Illinois, USA, Orland Park, United States

[3] Division of Dermatologic Surgery and Cutaneous Oncology, Department of Dermatology, Indiana University School of Medicine, Indianapolis, United States

Introduction

Basal cell carcinoma (BCC) is the most common malignancy worldwide, characterized by constitutive activation of the Hedgehog pathway, yet paradoxically slow growth. While PTCH1 mutations drive ~85% of sporadic BCCs, the molecular mechanisms restraining BCC proliferation despite active Hedgehog signaling remain poorly understood. We aimed to identify a high-confidence, BCC-specific gene expression signature and characterize its biological implications.

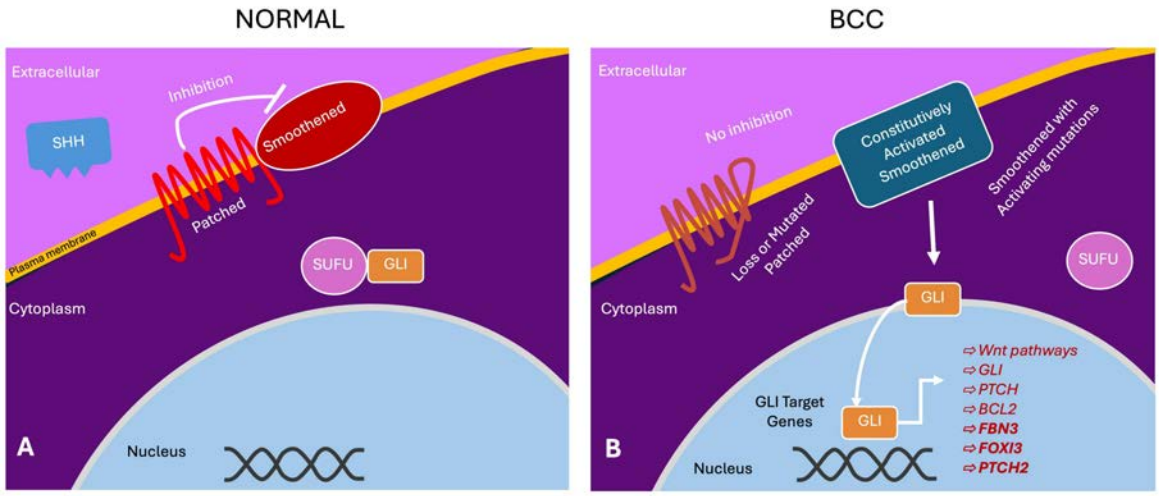

Hedgehog signaling in normal skin vs. BCC. In BCC, PTCH1 inactivating mutations (~85%) or SMO activating mutations (~10%) lead to constitutive GLI nuclear translocation and transcription of target genes including PTCH2, FOXI3, and FBN3.

Materials and Methods

We reanalyzed our published RNA-seq dataset (GSE125285; Wan et al., 2021), comprising 25 BCC and 10 SCC tumors with matched adjacent normal skin. Stringent filtering ($Log_2FC > 4$, FDR $< 10^{-15}$, paired t-test with Benjamini-Hochberg correction across all expressed genes) was applied to identify genes with extreme, reproducible upregulation. Signature genes were validated for BCC-specificity by direct comparison with SCC expression patterns.

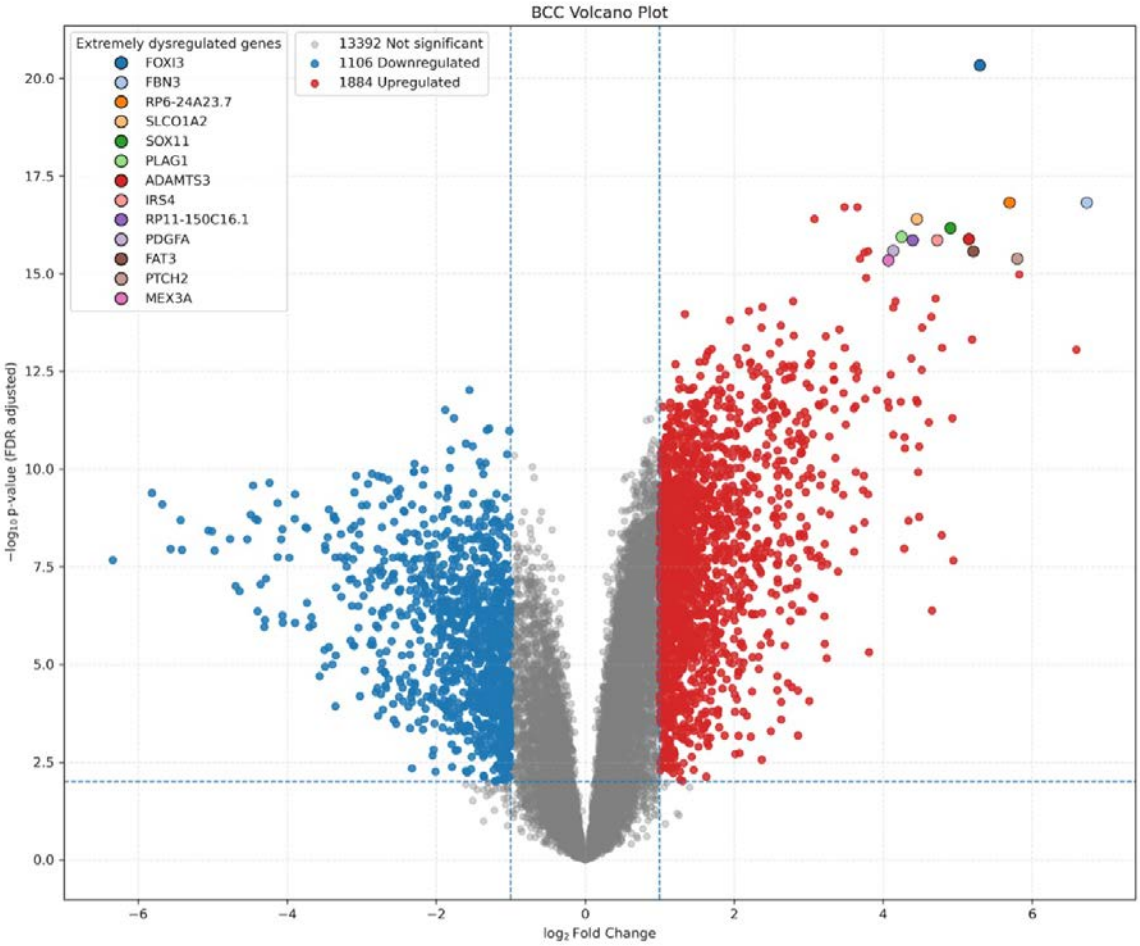

Volcano plot of differential gene expression in BCC versus matched normal skin (GSE125285; n=25 pairs). Red points: 13 genes meeting stringent criteria ($Log_2FC > 4$, FDR $< 10^{-15}$). Dashed lines indicate signature thresholds. FBN3 shows the highest fold-change (106×).

Results

Thirteen genes met stringent criteria (fold-change range: 17×–106×), representing three biological programs: Hedgehog target activation (PTCH2, 56×), arrested hair follicle differentiation (FOXI3, 39×; FAT3, 37×; ADAMTS3, 35×; SOX11, 30×), and ECM remodeling (FBN3, 106×). Ten of 13 genes (77%) were previously unreported as major BCC markers. Critically, 11 of 13 genes showed downregulation or no change in SCC; six showed strongly opposite regulation, FBN3 (↓2.0× in SCC vs. ↑106× in BCC), PTCH2 (↓3.6×), ADAMTS3 (↓2.1×), FAT3 (↓1.7×), RP6-24A23.7 (↓1.5×), and FOXI3 (↓0.75×), validating BCC-specificity. FBN3, the most highly upregulated gene (106×) and previously unreported in BCC, encodes an ECM glycoprotein that regulates TGF-β bioavailability through reversible LTBP binding. We hypothesize that abundant FBN3 in BCC stroma creates sustained TGF-β signaling through intact receptors (maintained in BCC, unlike SCC, where TGFβRII is lost in ~70% of cases), driving SMAD2/3-mediated cell cycle arrest via p15/p21/p27, explaining BCC's paradoxically slow growth.

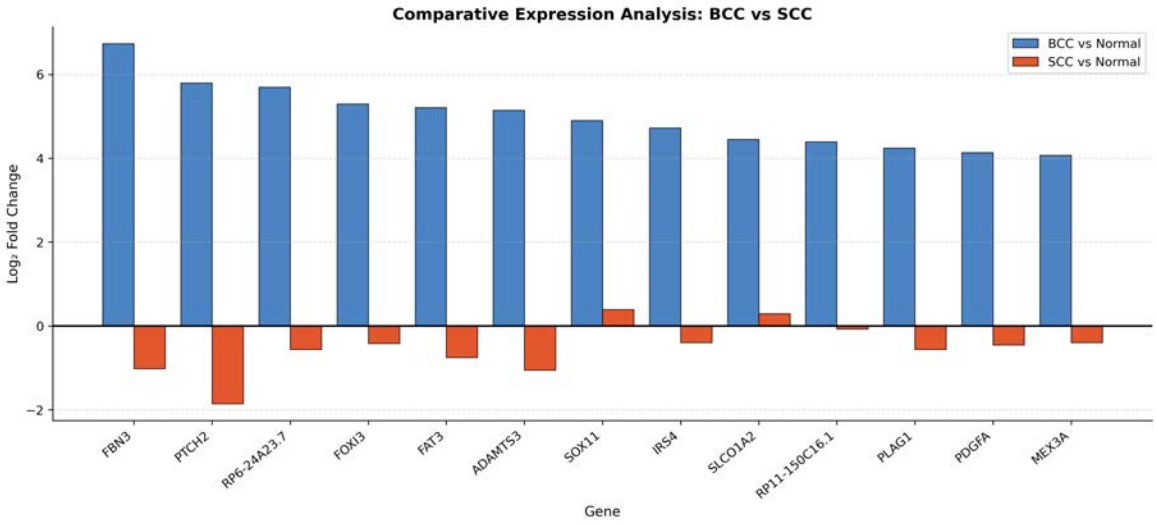

Log₂ fold-changes of all 13 signature genes in BCC (blue) versus SCC (red) relative to matched normal skin. ★ marks six genes with opposite or minimal regulation in SCC (FBN3, PTCH2, RP6-24A23.7, FOXI3, FAT3, ADAMTS3), validating BCC-specificity. Data from GSE125285.

Conclusions

We identified a 13-gene BCC-specific signature extending well beyond canonical Hedgehog signaling. The FBN3-TGF-β axis represents a novel, testable hypothesis for BCC growth control. This signature provides a molecular framework for BCC diagnosis, differential distinction from SCC, and identification of therapeutic targets warranting functional validation.

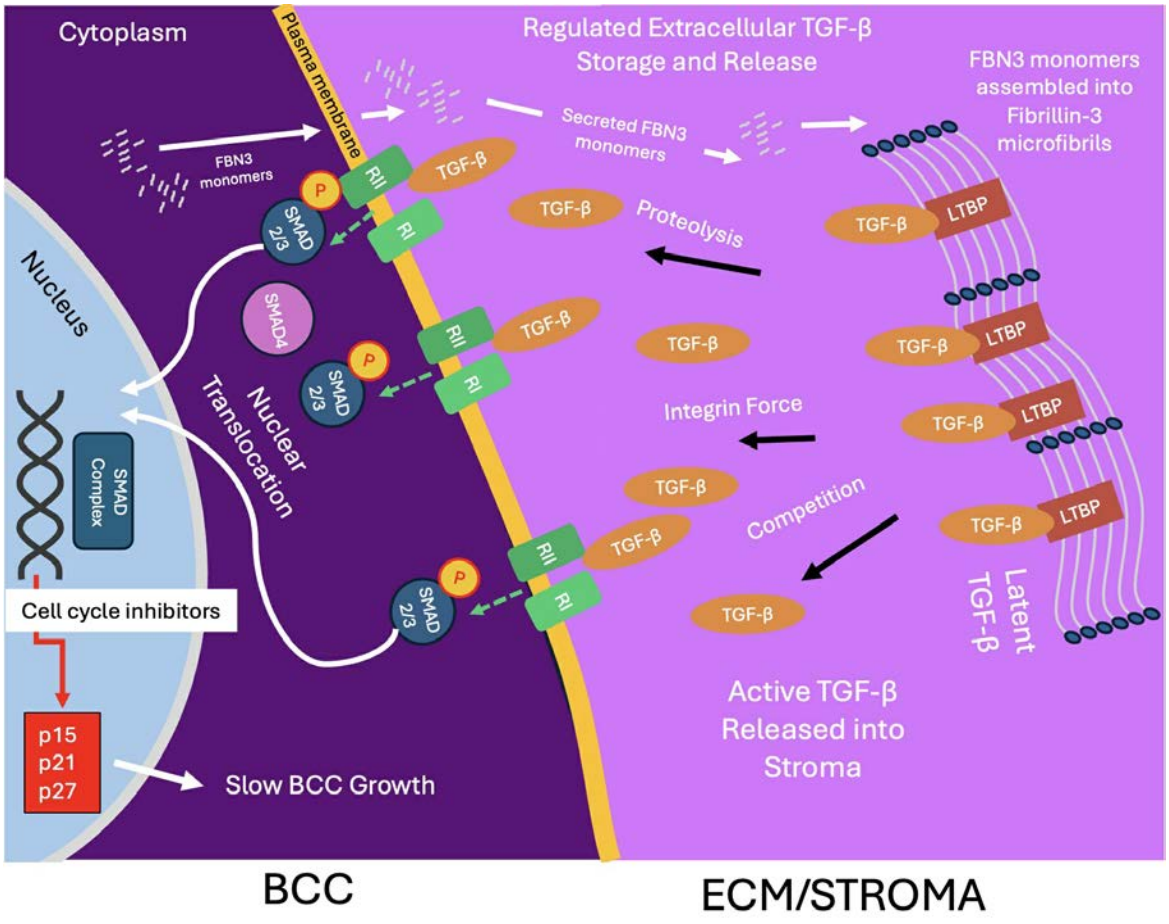

Proposed FBN3-TGF-β growth control model. FBN3 monomers synthesized in BCC cells are secreted across the plasma membrane and assembled into fibrillin-3 microfibrils in the ECM/stroma, where they sequester LTBP-associated latent TGF-β. Active TGF-β is released via proteolysis, integrin-mediated force, or competitive displacement, and signals through intact BCC receptors (RI/RII) to drive SMAD2/3

phosphorylation, nuclear translocation, and transcription of cell cycle inhibitors (p15, p21, p27), explaining BCC's characteristically slow growth. LTBP, latent TGF-β binding protein; ECM, extracellular matrix. Data from Wan et al., Genes Dis. 2021;8(2):181-192.

EADV CONGRESS
VIENNA
30 SEP - 3 OCT 2026

Abstract N°: 106

Atypical Facial Pilomatricoma Mimicking Keratinocytic Malignancy: A Diagnostic Challenge

Alessandra Oliva*[1], Sandra Paola Gualán Guamangate[1], Omar Lupi da Rosa Santos[1]

[1] General Polyclinic Of Rio de Janeiro, Rio de Janeiro, Brazil

Introduction

Pilomatricoma is a benign follicular adnexal tumor arising from hair matrix differentiation and is frequently associated with dysregulation of the Wnt/β-catenin signaling pathway. Although traditionally described in pediatric populations, a substantial proportion of cases occur in adults, most commonly in the head and neck region. Its clinical presentation is heterogeneous and may extend beyond the classic deep-seated nodule to include superficially located, erythematous, or hyperkeratotic lesions. This phenotypic variability contributes to the consistently low rates of accurate preoperative diagnosis reported in the literature. In adult patients, particularly in sun-exposed facial sites, pilomatricoma may clinically overlap with keratinocytic premalignant and malignant neoplasms, representing a significant diagnostic pitfall. Here, we report a case of an adult facial pilomatricoma with an atypical hyperkeratotic presentation and dermoscopic features suggestive of keratinocytic malignancy, emphasizing the importance of clinicopathologic correlation.

Case Presentation

A 46-year-old woman presented with a long-standing solitary papule on the right malar region that had recently become pruritic. Clinical examination and dermoscopic assessment were performed. Examination revealed a well-defined, firm, erythematous hyperkeratotic papule measuring 6 mm in diameter, adherent to the overlying epidermis. Dermoscopic evaluation demonstrated confluent whitish structureless areas corresponding to keratinization, subtle bluish homogeneous zones reflecting underlying basaloid cell aggregates, and fine linear irregular vessels. Although such features have been described in pilomatricoma, they are not specific and may overlap considerably with keratinizing malignancies, thereby limiting diagnostic confidence. Given the suspicion of hypertrophic actinic keratosis or early squamous cell carcinoma, complete surgical excision was undertaken for definitive histopathological evaluation. Histopathological analysis revealed a well-circumscribed dermal epithelial proliferation composed of peripheral basaloid matrical cells transitioning abruptly into anucleate ghost cells through trichilemmal-type keratinization. Multifocal calcification and an associated foreign body–type granulomatous reaction were observed. No significant cytologic atypia, increased mitotic activity, or infiltrative growth pattern was identified. These findings confirmed the diagnosis of pilomatricoma.

Conclusion

This case illustrates the expanded clinical spectrum of pilomatricoma in adulthood and its potential to mimic keratinocytic malignancies both clinically and dermoscopically. Given the well-documented limitations in preoperative diagnostic accuracy, histopathological confirmation remains essential. Increased awareness of atypical presentations and careful dermoscopic–histologic correlation are crucial to prevent overtreatment and unnecessary wide excision.

EADV CONGRESS
VIENNA
30 SEP - 3 OCT 2026

Abstract N°: 111

When Leukemia Takes a Cutaneous Turn: Secondary Cutaneous Histiocytic Sarcoma in a Young Adult

Sonal Fernandes*[1]

[1] FATHER MULLER MEDICAL COLLEGE, MANGALORE, India

Introduction

Histiocytic sarcoma (HS) represents an exceptionally rare and aggressive malignant neoplasm of haematopoietic derivation, arising from non-langerhans histiocytic cells of the monocyte-macrophage system. Once termed true histiocytic lymphoma or malignant histiocytosis, it constitutes less than 0.5% of all haematolymphoid malignancies and demonstrates a bimodal age incidence with a predilection for males. The clinical panorama of HS is protean, encompassing indolent localised lesions and fulminant disseminated disease affecting the skin, soft tissues, lymph nodes, and visceral organs. It's cutaneous expression,although infrequent, assumes diagnostic importance owing to its potential to masquerade as diverse dermatological and vascular neoplasms.

Case Presentation

A 23-year-old man, hitherto in good health, presented with a brief history of fever and profound weakness. Initial evaluation revealed thrombocytopenia; bone-marrow aspirationand biopsy confirmed B-cell acute lymphoblastic leukaemia (ALL). The patient commenced induction chemotherapy with vincristine, daunorubicin, and L-asparaginase. Three months later, he developed numerous asymptomatic red raised lesions distributed over the trunk, face, and upper limbs, which had emerged over the preceding three days. Cutaneous examination showed multiple, discrete, well-defined, glistening erythematous papules and plaques varying in size across the upper trunk, upper extremities, nape of the neck and face. Histopathological examination revealed a dense dermal proliferation of large polygonal to rhabdoid cells exhibiting abundant eosinophilic cytoplasm with conspicuous vacuolation, vesicular nuclei, and prominent nucleoli, accompanied by frequent atypical mitotic figures. Immunohistochemical analysis demonstrated strong positivity for CD163, CD68, vimentin,and BRAF V600E, with focal weak expression of CD45. The tumour cells were negative for CD3, CD20, CD34, HMB-45, MPO, and PAX8. The Ki-67 proliferation index measured 60-70%, signifying marked proliferative activity. PET-CT imaging disclosed splenomegaly with mild fluorodeoxyglucose uptake in the bone marrow. In light of the histopathological architecture and immunophenotypic signature, a diagnosis of secondary cutaneous histiocytic sarcoma was established. Following the diagnosis of secondary cutaneous histiocytic sarcoma, the patient continued on the planned acute lymphoblastic leukemia–directed chemotherapy. The cutaneous lesions showed gradual regression during the course of re-induction therapy, suggesting chemosensitivity of the histiocytic component to the ongoing regimen.

Conclusion

Secondary histiocytic sarcoma constitutes a discrete entity, believed to emerge through lineage transdifferentiation or clonal divergence from an antecedent haematolymphoid malignancy, and is consistently associated with a prognosis inferior to that of de novo disease. Crucially, this distinction cannot be reliably established on morphological or immunophenotypic grounds alone, given the substantial overlap in histiocytic marker expression; instead, accurate classification depends upon rigorous clinical correlation and molecular evidence demonstrating a shared neoplastic origin. Secondary histiocytic sarcoma has been described most commonly in association with B-cell and T-cell lymphoid neoplasms, including acute lymphoblastic leukaemia, and is characterised by an aggressive clinical course with limited responsiveness to conventional cytotoxic therapy. In this context, comprehensive molecular profiling assumes particular importance, as the identification of targetable

alterations such as BRAFV600 mutations may offer therapeutic opportunities and alter the otherwise unfavourable disease trajectory. This report highlights a rare link between secondary cutaneous histiocytic sarcoma and B-cell acute lymphoblastic leukemia. Recognizing such entities broadens dermatology, aids early intervention, and could lead to targeted treatments for histiocytic cancers.

EADV CONGRESS
VIENNA
30 SEP - 3 OCT 2026

Abstract N°: 112

Malignant Transformation in Pseudoepitheliomatous Keratotic and Micaceous Balanitis: A Rare Case

Sonal Fernandes*[1]

[1] FATHER MULLER MEDICAL COLLEGE, MANGALORE, India

Introduction

Lesions on the penis can be a challenge to diagnose often due to late presentation, self-medication, or prior ineffectual treatment causing alarm to the patient. Certain rare conditions of the penis can progress into malignant growths requiring invasive surgery. One such exceedingly rare premalignant lesion is pseudoepitheliomatous keratotic andmicaceous balanitis (PKMB) which is outlined by mica-like scales and keratotic horny masses over the glans penis. Although the etiology of PKMB is perplexing, it is generally seen in the elderly male population. It has a potential to evolve into squamous cell carcinoma and verrucous carcinoma rarely.

Case Presentation

A 45-year-old male presented with asymptomatic keratotic penile growths of 8-month duration. He first noticed it as a small elevated keratotic growth post circumcision, which was done for preexisting phimosis 10 months back. The lesions had been gradually increasing in size and number. There was no history of preceding trauma or any systemic disease. He gave no history of exposure to the risk of sexually transmitted disease. Prior treatment included the use of topical antibiotic cream without any improvement in symptoms. Clinical examination showed multiple bark-like, hard, yellowish horny masses over the glans penis sparing the urethral meatus. Lesions were confined to the glans penis, whereas examination of the penile shaft and scrotum was normal. Inguinal lymph nodes were not palpable. The patient's serology was negative for HIV, syphilis, and hepatitis B and C viruses. Routine laboratory investigations which comprised basic blood counts, levels of blood glucose, and tests for renal and liver function showed normal values. Based on these findings, excisional biopsy of the lesion was performed heeding toward a diagnosis of PKMB. Histopathology of the lesion revealed pseudoepitheliomatous hyperplasia with extensive hyperkeratosis, parakeratosis, acanthosis, individual cell keratinization, and atypical cells. Dermis showed dense lymphoplasmacytic inflammatory infiltrate. A final diagnosis of PKMB evolving to squamous cell carcinoma ofthe glans penis was made, and the lesions were surgically excised with wide margins. No recurrence was observed during a five year follow up period.

Conclusion

Our patient presented at a relatively young age with preexisting long-standing phimosis. Adult circumcision could be a possible trigger for PKMB in our patient. PKMB being a rarity should be recognized early due to its association with penile malignancy. Early clinical as well as histopathological identification and prompt treatment is undoubtedly the best course of action for the management of this condition. The basic understanding of this limitative ailment could be better inferred with a lifelong follow-up of the patient.

EA DV CONGRESS
VIENNA
30 SEP - 3 OCT 2026

Abstract N°: 128

WHEN DERMOSCOPY AND HISTOLOGY DISAGREE: A CASE OF VULVAR MELANOMA MIMICKING BENIGN PIGMENTED LESIONS

Arina Kogadei*[1], Kristina Khazhomiya[2], Semen Belozerov[1], Irina Smirnova[2], Sofiia Tymchuk[2], Irina Fedorova[3], Valeriia Golovchenko[3], Polina Ptashnikova[2], Arina Vashkevich[1]

[1] North-Western State Medical University named after I.I. Mechnikov, Saint-Petersburg, Russian Federation

[2] Saint Petersburg State University, Saint-Petersburg, Russian Federation

[3] St. Peterburg State University Hospital, Saint-Petersburg, Russian Federation

Introduction

Pigmented lesions of the vulvar region represent a diagnostic challenge in dermatological practice. Dermoscopic evaluation of mucosal surfaces is complicated by their specific anatomical characteristics, which may lead to dermoscopic patterns suggestive of malignancy even in benign lesions. This overlap may result in diagnostic uncertainty and unnecessary biopsies. The most common pigmented vulvar lesions are melanocytic nevi (approximately 55%), followed by vulvar melanosis (around 17%). Malignant tumors of the vulva are relatively rare, and melanoma accounts for only 1–10% of vulvar malignancies.

Case Presentation

We report a clinical case of a female patient presenting with progressive enlargement and pruritus of a long-standing pigmented vulvar lesion. Clinical and dermoscopic examinations were performed using a polarized dermatoscope with 10× magnification. Dermoscopy revealed several suspicious features, including a negative pigment network, irregular grouped pigmented dots and globules in both central and peripheral areas, and a prominent blue-white veil covering the lesion. Due to diagnostic uncertainty, five biopsies were performed with subsequent histopathological and immunohistochemical analysis. The first four examinations suggested melanocytic nevus and vulvar melanosis, findings that were inconsistent with the dermoscopic pattern. The final histopathological evaluation revealed fragments of epithelioid cell vulvar melanoma with high mitotic activity (4 mitoses per 1 mm^2). Breslow thickness could not be reliably assessed due to tissue fragmentation. No lymphovascular or perineural invasion was identified. The patient subsequently underwent surgical resection of the affected labium with lymph node dissection.

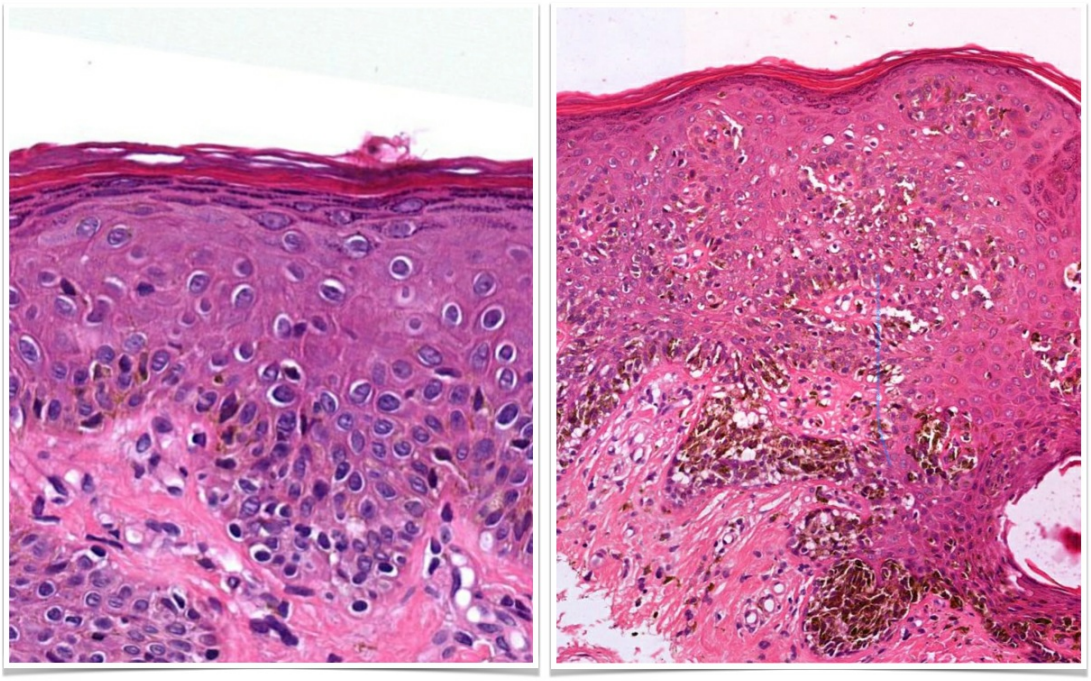

Histopathological examination (H&E staining) in the same patient demonstrating vulvar melanosis (left) and epithelioid cell vulvar melanoma with increased mitotic activity (right)

Conclusion

Pigmented vulvar lesions require careful evaluation because dermoscopic patterns may overlap between benign and malignant entities. Suspicious dermoscopic structures such as a blue-white veil, irregular dots or globules, and a negative pigment network should raise suspicion for melanoma even in mucosal lesions. Dermoscopy should therefore be interpreted in close correlation with clinical findings and histopathological examination.

EA DV CONGRESS
VIENNA
30 SEP - 3 OCT 2026

Abstract N°: 139

Cutaneous Pseudolymphoma Mimicking Lymphoma: A Case ReportBackground:Cutaneous pseudolymphoma is a benign reactive lymphoid proliferation that can closely resemble malignant lymphoma both clinically and histologically, making accurate diagnosis essential to avoid overtreatment.

Sofiia Plaksina*[1]

[1] Dermacenter, Nitra, Slovakia

Introduction

Cutaneous Pseudolymphoma Mimicking Lymphoma: A Case ReportBackground:Cutaneous pseudolymphoma is a benign reactive lymphoid proliferation that can closely resemble malignant lymphoma both clinically and histologically, making accurate diagnosis essential to avoid overtreatment.

Case Presentation

Case Presentation:A 40-year-old female presented with a solitary nodular lesion on the middle third of the left forearm measuring 2 × 2.5 cm. The lesion had been gradually increasing in size over the course of one year and was asymptomatic. The patient reported no exposure to arthropods, including ticks, and had no history of allergies. Clinically, the lesion was soft and lilac-pink in color. Dermoscopic evaluation showed no inflammatory signs. The patient had previously used topical corticosteroids for five months without improvement.An excisional biopsy was performed. Initial histopathology raised suspicion for cutaneous lymphoma. Immunohistochemical analysis revealed a mixed lymphoproliferation with a predominance of B cells (CD20+, Bcl-2−, Bcl-6+), forming nodules and bands with some reactive germinal centers. The proliferation index (Ki-67) was up to 5%. There was no plasma cell differentiation or convincing expression of monotypic cytoplasmic immunoglobulin. The T-cell component showed no significant phenotypic aberrations (CD3+, CD4/CD8 variable, CD30 rare blasts).



Conclusion

The findings were consistent with reactive cutaneous lymphoid hyperplasia (CLH), i.e., mixed-type cutaneous pseudolymphoma, without evidence of malignancy. This case underscores the importance of clinicopathological correlation and immunohistochemical evaluation in differentiating pseudolymphoma from true cutaneous lymphoma.

EADV CONGRESS
VIENNA
30 SEP - 3 OCT 2026

Abstract N°: 152

Bullous Cutaneous Relapse of Nodal Diffuse Large B-Cell Lymphoma: A Rare Case of Disease Progression

Saber Zerriaa*[1], Haj Messaoud Hamza[2], Yosra Gzam[1], Moez Hamdani[3]

[1] Internal Medicine department, Sadok M'kaddem Hospital, Djerba, Tunisia
[2] Hematology department, Sadok M'kaddem Hospital, Djerba, Tunisia
[3] Histopathology department, Sadok M'kaddem Hospital, Djerba, Tunisia

Introduction

Cutaneous involvement of lymphoma is broadly categorized into primary and secondary forms. Primary cutaneous lymphomas originate solely in the skin at the time of diagnosis and generally carry a more favorable prognosis. In contrast, secondary skin involvement is defined as the cutaneous infiltration of an already established systemic lymphoma. We report a case of cutaneous relapse signaling disease progression in a patient previously treated for nodal diffuse large B-cell lymphoma (DLBCL).

Case Presentation

A 70-year-old man with a medical history of hypertrophic cardiomyopathy and type 2 diabetes had been diagnosed one year prior with nodal DLBCL involving the cervical, mediastinal, axillary, and inguinal regions (Ann Arbor stage III). The patient had received eight cycles of R-COP (rituximab, cyclophosphamide, vincristine, and prednisone), achieving partial remission.

Three months after treatment completion, he was referred to the dermatology department for new-onset skin lesions involving the proximal right lower limb. On physical examination, the patient presented with firm, non-pitting edema of the scrotum, along with a highly infiltrated, erythematous, and bullous plaque at the root of the right thigh.

Histopathological examination of a skin biopsy revealed a dense, diffuse dermal infiltrate of large atypical mononuclear cells suggestive of lymphomatous proliferation. Immunohistochemical analysis showed tumor cells positive for CD20, CD79a, and Bcl6, confirming secondary cutaneous involvement of nodal DLBCL.

The patient was subsequently initiated on salvage chemotherapy with three cycles of R-GEMOX (rituximab, gemcitabine, and oxaliplatin). However, the clinical course was complicated by severe sepsis, resulting in the patient’s death.

Conclusion

This case illustrates a rare and aggressive presentation of nodal DLBCL relapsing as a bullous cutaneous plaque. It underscores the critical importance of a thorough dermatological evaluation during the follow-up of patients with systemic lymphomas, as skin lesions may be the first clinical indicator of disease progression. Despite the availability of salvage regimens such as R-GEMOX, the prognosis for secondary cutaneous DLBCL remains guarded, particularly in elderly patients where treatment-related toxicities and infectious complications like sepsis significantly impact survival.

EADV CONGRESS
VIENNA
30 SEP - 3 OCT 2026

Abstract N°: 155

Amelanotic Melanoma arising on a pre-existing dermal nevus: A diagnostic challenge

Elmijola Janushaj*[1], Daniela Nakuci[2]

[1] Doc Derma Clinic, Tirana, Albania

[2] The Obstetrics and Gynecology University Hospital Queen Geraldina, Innovation Laboratory, Tirana, Albania

Introduction

Amelanotic melanoma is a very aggressive form of melanoma, characterised of no pigmentation, skin-coloured or erythematous nodule, often leading to diagnostic delays due to its resemblance to benign, inflammatory or non-melanocytic lesions. When arising on a pre-existing dermal nevus, clinical suspicion may be further reduced, making early diagnosis particularly challenging.

Case Presentation

A 79-year-old female patient presented with a pre-existing dermal nevus dimensions 1x2cm, located on the back, which had been stable for many years. Over the course of several weeks, the lesion developed into a non-healing ulcer. Initial management consisted of local treatment with antibiotic oinment for 10 days, without any clinical improvement. Dermoscopic examination was inconclusive due to a highly vascularization and absence of specific melanocytic features, limiting diagnostic accuracy. Given the rapid evolution, ulceration, and strong clinical suspicion for malignancy, a wide local excision was performed with approximately 2 cm margins from the lesion borders.The histopathological report confirmed the diagnosis of amelanotic melanoma arising in association with a pre-existing dermal nevus. The histopathological examination revealed a proliferative lesion composed of diffusely arranged atypical cells with hyperchromatic nuclei and sparse cytoplasm. The nuclei were variably shaped, including rounded forms and elongated, wavy configurations. Areas of hemorrhage and superficial ulceration were present. At the epidermal-dermal junction nests of atypical cells with horizontal spread were observed. Surgical margins lateral and deep were free of tumor. Immunohistochemical examination was requested to conclude the definitive diagnosis, considering also squamous cell cacinoma as differential diagnosis.

Conclusion

Amelanotic melanoma can mimic benign or inflammatory conditions, particularly when presenting as a non-healing lesion on a pre-existing nevus. This case underscores the importance of maintaining a high index of suspicion and proceeding to early surgical excision in atypical or non-responsive lesions. Prompt recognition is essential to avoid diagnostic delay and improve patient outcomes.

EA DV CONGRESS
VIENNA
30 SEP - 3 OCT 2026

Abstract N°: 161

Comparison of Clinical and Demographic Characteristics Between Different Types of Photoaging

Damla Değirmenci*[1], Nilay Duman[1], Işıl Karaarslan[1]

[1] Ege University Faculty of Medicine,Department of Dermatology and Venereology, Izmir, Türkiye

Introduction
Photoaging is a form of premature skin aging caused by chronic exposure to ultraviolet (UV) radiation and is associated with a wide spectrum of cutaneous changes. Clinically, in recent years photoaging is commonly classified into atrophic and hypertrophic types. Emerging evidence suggests that atrophic and hypertrophic photoaging phenotypes may differ in their association with skin cancers; however, definitive data are lacking.Therefore, in this study, we aimed to highlight the clinical and demographic differences between clinically diagnosed atrophic and hypertrophic photoaging types, to emphasize that photoaging is not only a cosmetic concern but also a potential oncological risk factor, and to contribute to the literature in the development of preventive strategies against skin cancer.

Materials and Methods
This ethically approved cross-sectional study included 60 patients aged ≥45 years. Individuals younger than 45 years, pregnant patients, those who had undergone cosmetic or aesthetic procedures on the face, and patients in whom a clear clinical distinction between atrophic and hypertrophic photoaging could not be established were excluded. The presence of benign, premalignant, and malignant skin lesions was evaluated through clinical and dermoscopic examination, patient history, and medical records. Skin phototype was determined by clinical assessment and Fitzpatrick skin type classification. Photoaging subtype (atrophic or hypertrophic) was defined based on established clinical criteria described in the literature. Photoaging severity was assessed using the Glogau Photoaging Scale, SCINEXA score, Physician Global Assessment (PGA) of Photoaging, and a Numeric Scale for Photodamage. Statistical analyses were performed to compare differences between groups.

Results
Among the 60 patients, 20 (33.3%) exhibited atrophic photoaging and 40 (66.7%) hypertrophic photoaging. The mean age was 68.45 ± 10.6 years in the atrophic group and 66.35 ± 10.3 years in the hypertrophic group. The female-to-male ratio was 14/6 in the atrophic group and 20/20 in the hypertrophic group. Although male sex was more prevalent in the hypertrophic group (50% vs. 30%), differences in age and sex distribution were not statistically significant. Chronic sun exposure was reported in 55% of the atrophic group and 45% of the hypertrophic group, while intermittent intense sun exposure was present in 100% and 92.5% of patients, respectively, with no significant differences between groups. A history of skin cancer was observed in 70% of patients with atrophic photoaging and 52.5% of those with hypertrophic photoaging. Although the mean number of skin cancers was higher in the atrophic group (2.6 vs.1), this difference did not reach statistical significance. Actinic keratosis was more frequent in the atrophic group (80% vs. 55%). Squamous cell carcinoma in situ was significantly more common in patients with atrophic photoaging compared to those with hypertrophic photoaging (60% vs. 25%; p = 0.008). While basal cell carcinoma, invasive squamous cell carcinoma, and melanoma were more frequently observed in the atrophic group, these differences were not statistically significant. A history of skin cancer was not significantly associated with photoaging subtype but showed a significant association with chronic sun exposure (p = 0.032).

Conclusions

Both atrophic and hypertrophic photoaging may be associated with the development of skin cancers. Cumulative sun exposure emerged as a more significant determinant of skin cancer presence than the specific clinical subtype of photoaging. However, atrophic and hypertrophic photoaging phenotypes demonstrate distinct clinical profiles, particularly regarding the prevalence of premalignant lesions such as squamous cell carcinoma in situ. These findings suggest that photoaging subtypes may reflect different carcinogenic pathways and risk profiles.

EADV CONGRESS
VIENNA
30 SEP - 3 OCT 2026

Abstract N°: 162

Melanoma and Renal Cell Carcinoma: A Shared Path in the Age of Immunotherapy

Ana-Maria Toma*[1], Mara Mădălina Mihai[1]

[1] Elias Emergency University Hospital- Department of Oncologic Dermatology, Bucharest, Romania

Introduction

Melanoma incidence is rising globally, especially among older adults, increasing the likelihood of multiple primary malignancies. Epidemiological studies have shown a significantly increased incidence of melanoma in patients with RCC and vice versa, independent of conventional risk factors like chemotherapy or immunosuppression. These findings highlight the importance of internal cancer screening in dermatologic settings and support further research into common pathways and integrated treatment approaches.

Case Presentation

We present the case of a 70-year-old female diagnosed in early 2024 with stage IIB cutaneous melanoma (Breslow 2.1 mm, ulcerated, mitotic index 12/mm^2) on the proximal lateral hip. Staging investigations revealed no metastases, and the patient underwent wide local excision with negative margins, followed by adjuvant immunotherapy with pembrolizumab. Approximately one month into follow-up, routine surveillance imaging (contrast-enhanced CT of the abdomen and pelvis) revealed 10 mm enhancing lesion in the upper pole of the left kidney. The lesion was radiologically characterized as possibly consistent with a renal neoplasm. Therefore, a subsequent partial nephrectomy was performed and histopathological evaluation confirmed a pT1a papillary renal cell carcinoma (PRCC), type I, Fuhrman grade 2. Three months later, new lymphadenopathies and pulmonary nodules raised concern for progression, but PET-CT findings were interpreted as pseudoprogression secondary to immunotherapy. Pembrolizumab was continued with close oncologic surveillance.
While pembrolizumab is an established adjuvant treatment for resected high-risk melanoma, it has more recently demonstrated efficacy in renal cancer, particularly in high-risk localized clear cell RCC. This therapeutic overlap highlights the expanding role of immune checkpoint inhibitors (ICIs) across multiple tumor types. Although our patient's papillary RCC (pT1a) would not currently qualify for pembrolizumab, given the fact that she did indeed recieve it for another malignancy as per current guidelines, the case illustrates the potential relevance of shared immunologic pathways in patients with dual immunogenic malignancies.The subsequent appearance of lymphadenopathy and pulmonary nodules, initially suspicious for disease progression and later interpreted as immune-related pseudoprogression highlights a known phenomenon in ICI-treated patients and underscores the complexity of interpreting imaging findings during immunotherapy and the importance of multidisciplinary assessment

Conclusion

This case illustrates the challenges of managing synchronous primary malignancies, emphasizing the importance of thorough evaluation, close monitoring, and interdisciplinary collaboration when treatment pathways overlap.

EADV CONGRESS
VIENNA
30 SEP - 3 OCT 2026

Abstract N°: 180

Topical Imiquimod for Lentigo Maligna in a Nonagenarian

Sarah Hosseini*[1], Georgios Kravvas[2], Sandra Jerkovic Gulin[1, 3]

[1] Division of Cell Biology, Department of Biomedical and Clinical Sciences, Faculty of Medicine and Health Sciences, Linköping University, 581 83 Linköping, Sweden, Jönköping, Sweden

[2] Department of Dermatology, University College London Hospitals, 235 Euston Road, London NW1 2BU, UK. 4 Division of Medicine, University College London, Rayne Building, 5 University St, London WC1E 6JF, London, United Kingdom

[3] Department of Dermatology and Venereology, Ryhov County Hospital, Sjukhusgatan, 553 05 Jönköping, Sweden., Division of Cell Biology, Department of Biomedical and Clinical Sciences, Faculty of Medicine and Health Sciences, Linköping University, 581 83 Linköping, Sweden, Jönköping, Sweden

Introduction

Lentigo maligna (LM) represents melanoma in situ and predominantly affects elderly individuals, typically arising on chronically sun-exposed skin of the head and neck. Although LM usually shows slow horizontal growth and a favorable prognosis, progression to invasive lentigo maligna melanoma may occur, making timely treatment essential. Surgical excision remains the standard of care; however, advanced age, comorbidities, lesion size, and cosmetic or functional considerations may limit surgical options.

Case Presentation

We present the case of a 93-year-old woman with no prior history of skin cancer who was diagnosed with a large lentigo maligna lesion on the forehead. Clinically, the lesion measured 2.5 × 2.7 cm and demonstrated irregular pigmentation. Multiple biopsies confirmed melanoma in situ of the lentigo maligna type, with adnexal extension but no evidence of dermal invasion.Given the patient’s advanced age and lesion location, a non-surgical treatment approach was selected. Topical imiquimod 5% cream was applied five times per week for 12 weeks, including a 2 cm margin around the visible lesion. The patient was closely monitored throughout therapy. Local inflammatory reactions were mild to moderate and expected, consisting mainly of erythema, crusting, and superficial ulceration, without systemic adverse effects.At treatment completion, marked clinical improvement was observed, with near-complete resolution of pigmentation. Follow-up dermoscopic examination revealed only minimal residual granular pigmentation. Two post-treatment biopsies taken from different areas of the treated site confirmed complete histological clearance of atypical melanocytic cells. The therapeutic response and cosmetic outcome are illustrated with high-quality clinical photographs documenting baseline appearance, inflammatory treatment response, and post-treatment healing.

Conclusion

This case demonstrates that topical imiquimod can be a safe and effective alternative to surgery in carefully selected elderly patients with lentigo maligna. Close clinical follow-up and histological confirmation of clearance remain essential. Non-invasive treatment may offer excellent therapeutic and aesthetic outcomes when surgical management is not feasible.

EA DV CONGRESS
VIENNA
30 SEP - 3 OCT 2026

Abstract N°: 206

NOT SO SUPERFICIAL: SUPERFICIAL SPREADING BASAL CELL CARCINOMA OF THE FOREHEAD WITH PROMINENT STROMAL RETRACTION CLEFTS

Richin Anna Johnson*[1]

[1] DR SMCSI MCH, Karakonam, India

Introduction

Basal cell carcinoma (BCC) is the most common type of non-melanoma skin cancer. The nodular, superficial spreading and infiltrating variants are the three most commonly encountered types of BCC in descending order of prevalence. Superficial spreading basal cell carcinoma (SSBCC) accounts for approximately 15-26% of cases, which usually occurs on the trunk and upper extremities. Surgical excision is the treatment of choice.

Histopathological examination remains the gold standard for diagnosis. On histopathology, SSBCC typically exhibits basaloid tumor buds arising from the epidermis with lateral spread along the under surface, accompanied by mild cytologic atypia and relatively inconspicuous peripheral palisading and stromal retraction clefts. In contrast, the present case demonstrated conspicuous peripheral palisading and well-defined stromal retraction clefts despite a superficial architectural pattern. TImmunohistochemistry serves as a useful adjunct in confirming superficial basal cell carcinoma. Lesional cells typically show diffuse nuclear positivity for p63 and strong membranous staining for BerEP4, supporting basal cell lineage. While treatment of Nodular BCC is primarily surgical and limited to destructive therapies, SSBCC may be amenable to non-surgical management such as 5FU (5 Fluro uracil), Imiquimod, PDT (Photo Dynamic Therapy). Patients have been reported to prefer topical treatments and value cosmetic results which highlight the importance of diagnosing SSBCC which will allow physician to give non-surgical treatment option to the patients and thereby improving patient adherence to treatment. However, BCC arising within the H zone of face demonstrate a higher likelihood of aggressive behaviour and recurrence, even when lesions are small. Thus, surgical modalities are preferred irrespective of histological subtype.

This case highlights the histopathological overlap between superficial spreading and nodular BCC, highlighting the importance of clinico-pathological correlation in skin tumours.

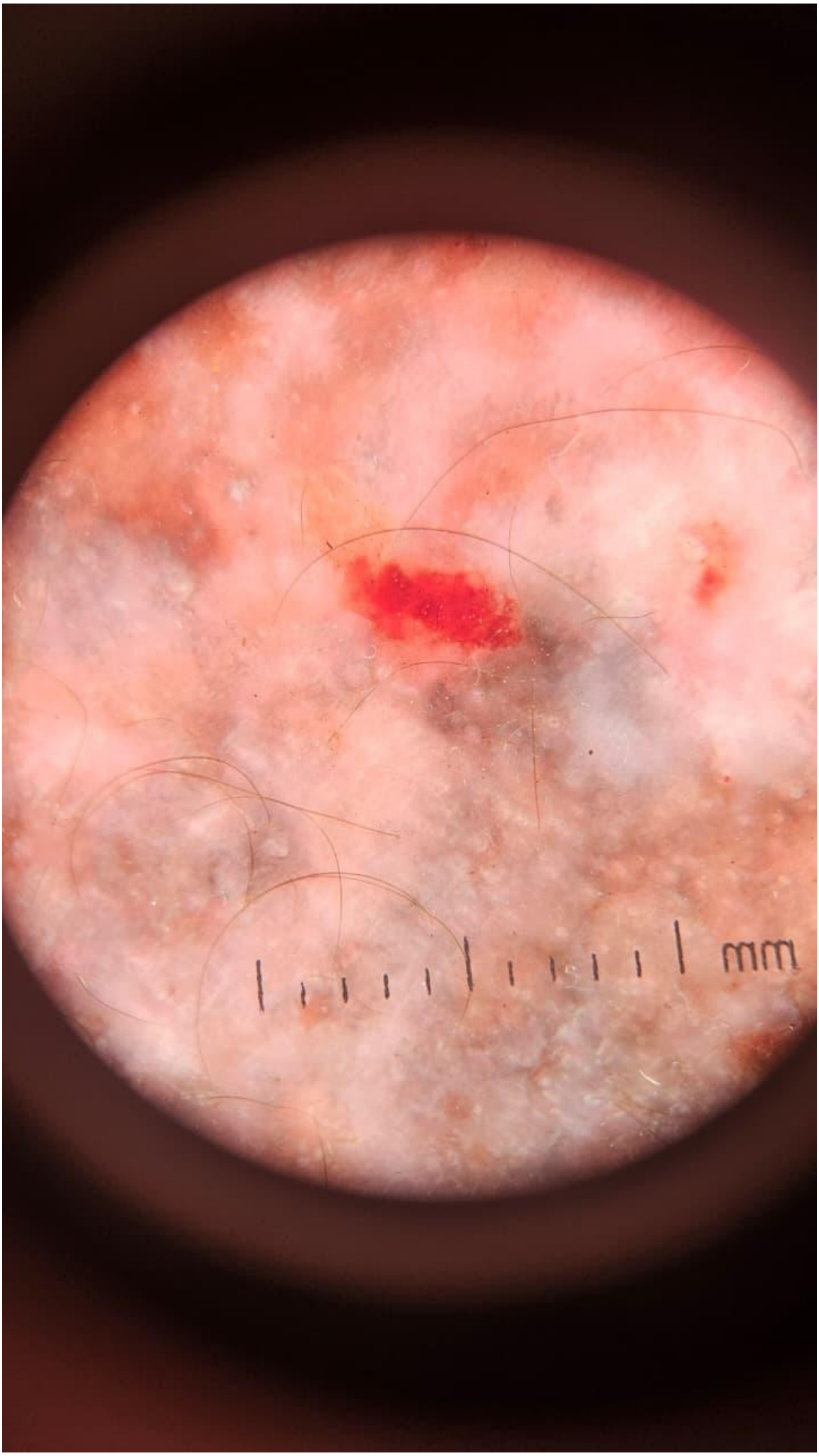
mm

Clinical and dermoscopic pictures of superficial BCC. The black arrow indicates maple leaf areas, red arrow indicates focal erosion and the white arrow indicates white-to-pink structureless zones

Case Presentation

A 56-year-old female presented with an asymptomatic solitary dark flat lesion over the right forehead, which gradually increased in size since last two years. The lesion was well circumscribed, irregular grey brown plaque measuring 2×1cm over right side of forehead. There was no associated lymphadenopathy. She reported no exposure to other risk factors such as radiation or arsenic and no family history of skin cancer.Dermoscopy demonstrated maple leaf–like areas associated with white-to-pink structureless zones and focal erosions.Histopathological examination was suggestive of SSBCC showing nests of atypical basaloid cells exhibiting moderate atypia with hyperchromatic nuclei and inconspicuous nucleoli extending into superficial dermis from the basal layer. In addition, Peripheral palisading and stromal retraction clefts were also observed which are more common in Nodular BCC and uncommon with SSBCC. These cells showed strong positivity to p63 and BerEP4 on IHC, confirming the diagnosis of BCC.

FOLLOW UP

In view of histopathological overlap between SBCC and Nodular BCC, we decided to do a histopathological examination of the whole lesion. So, the patient was referred to the plastic surgery, where a wide local excision with 4 mm margins and reconstruction of the defect was performed under regional anaesthesia.

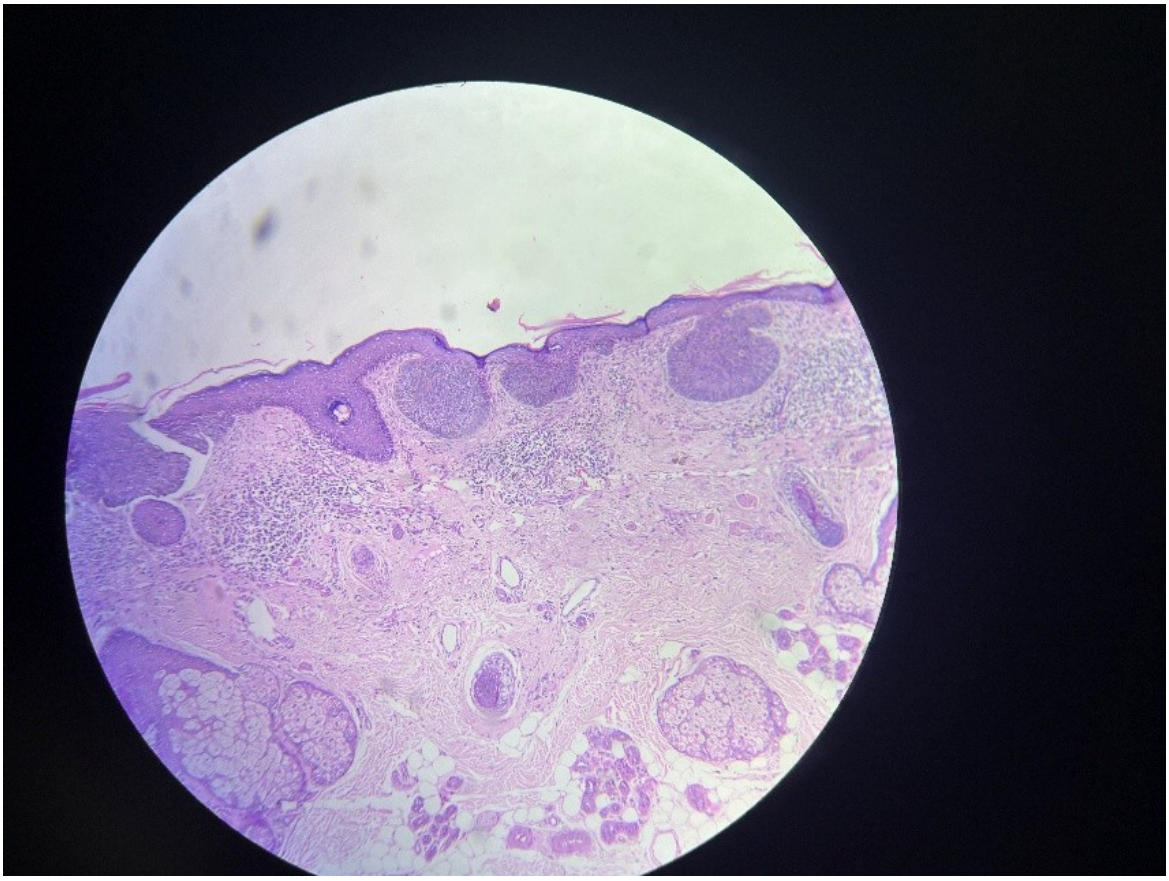

H & E Stain (40x): In this tumor section, shows interconnected superficial tumor islands attached to the under surface of the epidermis with peripheral palisading and stromal retraction clefts

Conclusion

This case underscores the importance of recognizing uncommon histopathologic features in superficial basal cell carcinoma (SSBCC) to prevent misclassification that may limit the use of non-surgical treatment options. Careful clinicopathologic correlation in atypical presentations can facilitate accurate classification, thereby improving patient compliance and treatment outcomes. This case aims to sensitise clinicians and pathologists regarding the

possibility of overlap in histopathological features especially in lesions with atypical locations or morphology.

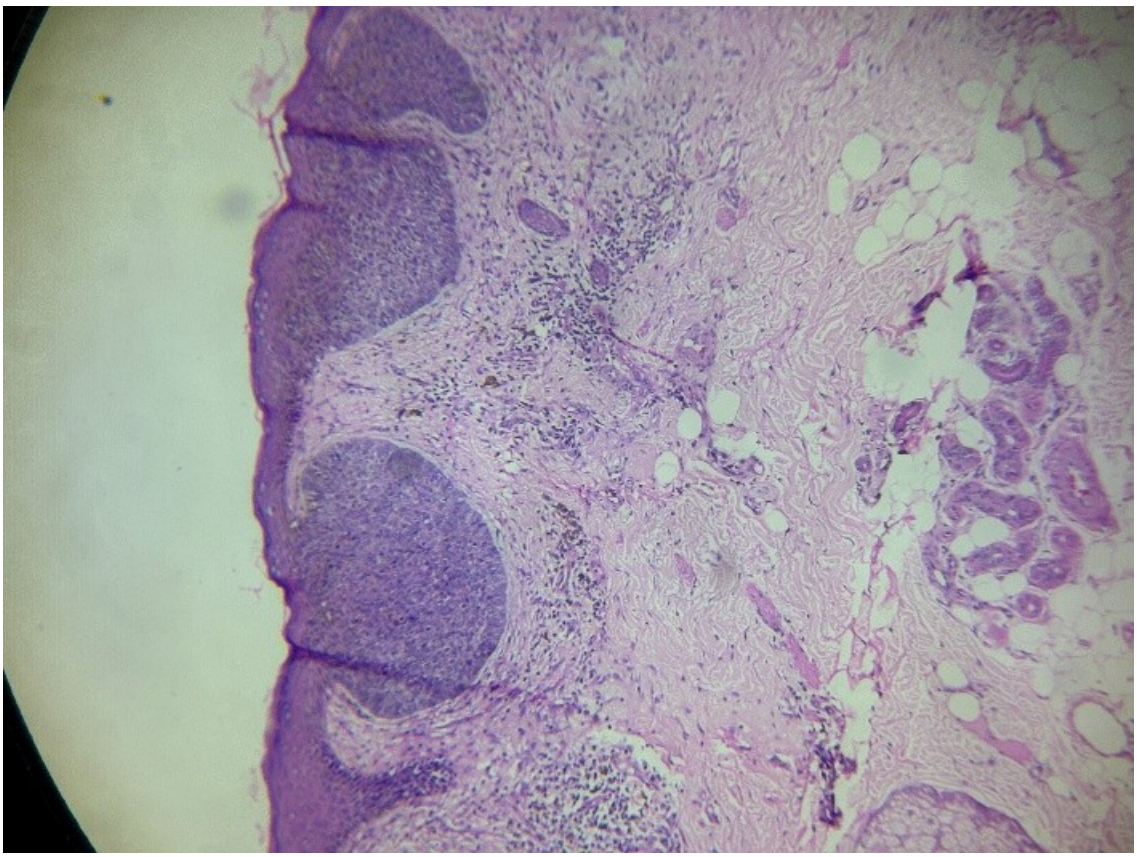

H & E Stain(100x): Section shows basaloid tumor cells with hyperchromatic nuclei, peripheral palisading and peritumoral clefting

EA DV CONGRESS
VIENNA
30 SEP - 3 OCT 2026

Abstract N°: 234

A mimicker of squamous cell carcinoma - a chronic scalp erosion case report with use of LC-OCT

Mateusz Koper*[1], Piotr Sobolewski[1, 2], Irena Walecka[1, 2]

[1] Dermatology Clinic, National Institute of Medicine of the Ministry of Interior and Administration, Woloska 137, 02-507 Warsaw, Poland, Warsaw, Poland

[2] Chair and Clinic of Dermatology and Pediatric Dermatology, Centre of Postgraduate Medical Education, Woloska 137, 02-507 Warsaw, Poland, Warsaw, Poland

Introduction

Cutaneous squamous cell carcinoma (cSCC) ranks as the second most common non-melanoma skin cancer, frequently manifesting on chronically sun-exposed sites such as the scalp, where chronic non-healing erosions or ulcers in elderly patients warrant high suspicion for malignancy. Videodermatoscopy enhances diagnostic precision by revealing characteristic features including ulceration, structureless red/pink areas, and polymorphic vascular patterns (glomerular, hairpin, polymorphous vessels) suggestive of invasive growth. Line-field confocal optical coherence tomography (LC-OCT) represents an advanced non-invasive imaging modality, delivering near-histological resolution (~1 µm laterally, ~500 µm depth) of epidermal/dermal architecture in real-time vertical and horizontal planes, bridging dermoscopy and histopathology. Despite these tools, inflammatory and infectious dermatoses can mimic cSCC both clinically and dermoscopically. This case report illustrates the diagnostic challenges of a long-standing scalp erosion initially suggestive of cSCC, underscoring the pivotal role of multimodal imaging, histopathology, and microbiology in establishing accurate diagnosis and guiding targeted therapy.

Case Presentation

A 77-year-old patient without comorbidities presented with an extensive chronic scalp erosion for several years. Clinical examination revealed an extensive superficial ulceration exhibiting morphology highly suspicious for cSCC. Videodermatoscopy substantiated this clinical impression, demonstrating ulceration, homogeneous red/pink structureless zones, and atypical vascular patterns (glomerular, hairpin, polymorphous vessels) indicative of potential invasion. LC-OCT imaging proved non-specific, revealing hyperkeratosis, acanthosis, dyskeratosis, absence of dermo-epidermal junction (DEJ) destruction with flattened DEJ, and inflammatory infiltrates of small round cells in the epidermis/upper dermis—findings inconsistent with basal cell carcinoma or cSCC hallmarks like irregular tumor nests or stromal clefting. Given the equivocal clinical and LC-OCT findings, punch biopsy was performed. Histopathology excluded malignancy, disclosing inflammatory granulation tissue with ulceration. The lesion manifested purulent exudate, necessitating procurement of microbiological swabs for comprehensive bacteriological evaluation. Empirical treatment with amoxicillin/clavulanic acid was initiated. After that, culture identified methicillin-sensitive Staphylococcus aureus (MSSA) and Escherichia coli; targeted trimethoprim-sulfamethoxazole was instituted per antibiogram.Follow-up, revealed substantial improvement with erosion size reduction and good treatment tolerance, confirmed videodermatoscopically by diminished ulceration and inflammatory features. Antibiotic therapy continued effectively.

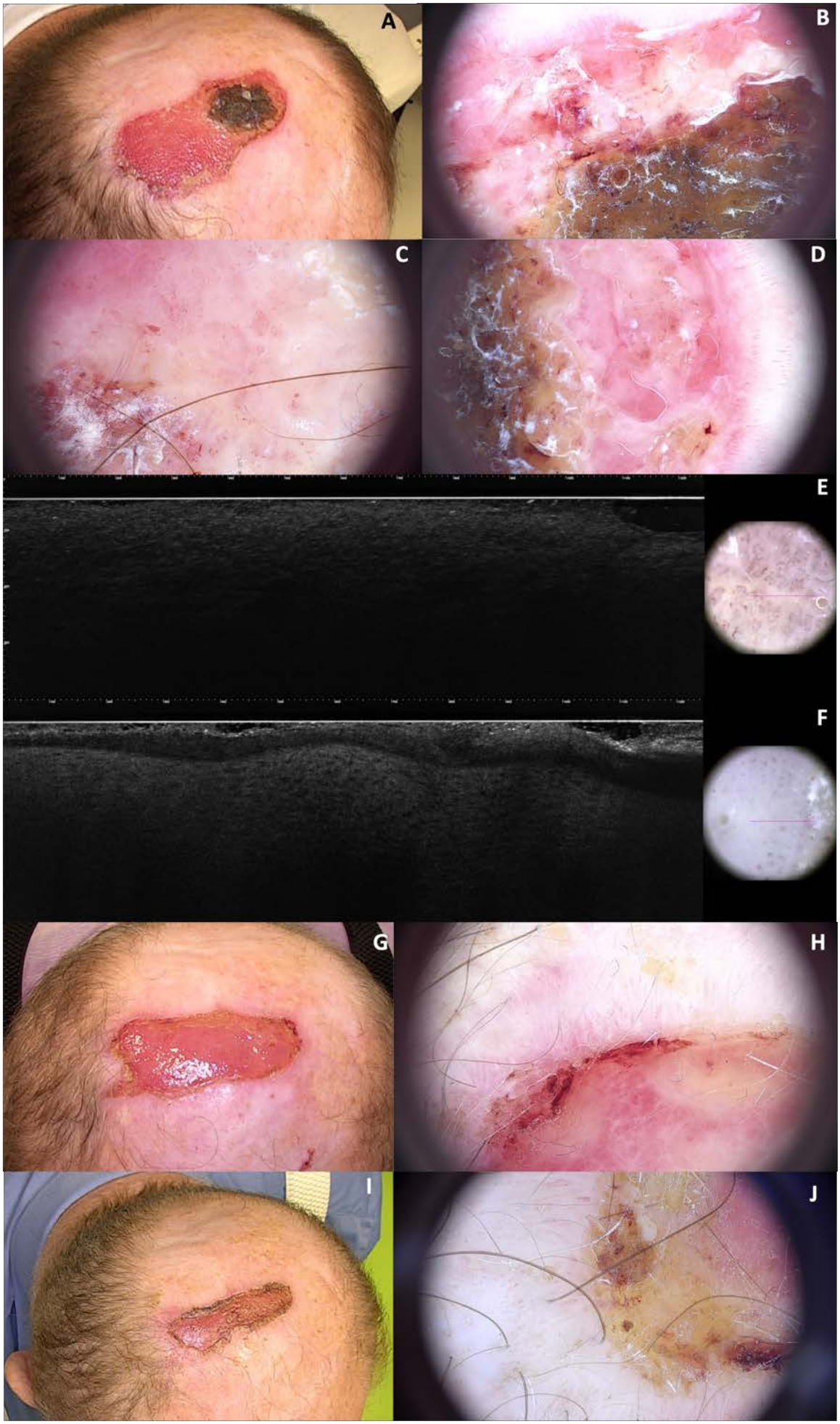

Figure 1. A – Clinical photograph showing extensive scalp erosion before treatment; B, C, D – Videodermoscopic images revealing ulceration and polymorphic vascular patterns; E, F – LC-OCT images demonstrating non-specific architectural disorganization without features typical of squamous

cell carcinoma; G – Clinical photograph after 1 month of therapy showing significant reduction in erosion size; H – Videodermoscopic image after 1 month demonstrating decreased ulceration and inflammatory features; I – Clinical photograph after 2 months of therapy confirming progressive healing; J – Videodermoscopic image after 2 months showing further resolution of erosion and vascular pattern.

Conclusion

This case exemplifies the diagnostic pitfalls of chronic scalp erosions masquerading as cSCC. LC-OCT's near-histological resolution facilitated early recognition of inflammatory changes (hyperkeratosis, acanthosis, preserved DEJ), prompting biopsy that excluded neoplasia and revealed granulation tissue. While videodermatoscopy detects surface vascular/atypical patterns and LC-OCT elucidates subsurface architecture, severe inflammation/ulceration may induce artifacts mimicking invasion, necessitating histopathological and microbiological correlation. Multimodal approaches integrating advanced imaging reduce misdiagnosis risk, potentially sparing unnecessary excisions while enabling precise infectious management. LC-OCT emerges as invaluable for non-invasive triage of ambiguous scalp lesions, supporting stepwise multidisciplinary evaluation in high-stakes sun-damaged sites to optimize outcomes and avoid overtreatment.

EADV CONGRESS
VIENNA
30 SEP - 3 OCT 2026

Abstract N°: 240

Microsatellite Instability in Sebaceous Carcinomas in Organ Transplant Recipients

Elena Lucia Pinto Pulido*[1], Isabel Polo Rodríguez[1], Maria Dolores Vélez[1], Laura Martínez Alcalde[1], Alicia Urbano Bueno[1], Susana Medina[1]

[1] Hospital Universitario Príncipe de Asturias, Alcalá de Henares, Spain

Introduction

Sebaceous carcinoma (SC) is an infrecuent cutaneous tumot associated with immunosuppressive drugs, up to 25 times more common in transplant recipients. Three mutational mechanisms have been described for its development: microsatellite instability (MSI, classically associated with Muir-Torre syndrome [MTS], which has a more indolent course), ultraviolet radiation damage (greater histological aggressiveness), and paucimutational mechanisms (age-related single-nucleotide polymorphisms, primarily periocular). On the other hand, cases have been described of transplant patients with the onset of SC with MSI, without germline alterations, as well as the development of other tumors associated with MTS. The aim of this study is to characterize the SCs diagnosed at our center, evaluating the loss of DNA repair proteins and their association with transplant patients.

Materials and Methods

Retrospective observational study including patients with SC removed at our center between 1999 and 2025.

Results

A total of 26 patients were enrolled, of whom 3 had received a solid organ transplant (in 1975, 2003, and 2018). These three patients presented with IHC loss of repair proteins, developed SC in 2025 (1/3 trunk, 2/3 extraocular facial), and had no other tumors or family history associated with MTS. They were receiving treatment with tacrolimus, tacrolimus + mycophenolate, and sirolimus. The IHC expression of MLH1/PMS2/MSH2/MSH6 was analyzed in 16 of 26 patients, with loss of expression observed in 7/16: 3/7 solid organ transplant pecipients, 1/7 receiving other immunosuppressive therapy, and 2/7 with a pathogenic SMT mutation.

Conclusions

At our center, all transplant recipients with SC had MSI without evidence of germline mutations. Among patients with SC and MSI, immunosuppression was more common than SMT. These findings, together with those described in the literature, suggest that MSI may be the primary mutational mechanism underlying SC in transplant recipients. Investigating this association through multicenter studies would have prognostic implications due to the lower histological aggressiveness of SC with MSI and the possibility of developing other MSI associated tumours. Our center experienced an increase in the incidence of CS in transplant recipients in 2025, which could be coincidental or, if repeated at other centers, associated with changes in immunosuppressive treatment regimens, other drugs, etc.

EADV CONGRESS
VIENNA
30 SEP - 3 OCT 2026

Abstract N°: 242

Cutaneous Involvement of Underlying T-cell/Histiocyte-Rich B-cell Lymphoma

Wei Qiang Chng*[1], Soo Yong Tan[2], Joel Lim[1]

[1] National Skin Centre, Singapore, Singapore
[2] National University Hospital, Singapore, Singapore

Introduction

A woman in her 60s presented with an indolent 3-month duration of left pre-auricular ulceration. She was previously healthy. Examination revealed an ulcerated and indurated plaque overlying the left temporomandibular joint. No cervical lymphadenopathy was appreciated. On further questioning, she had experienced occasional pain but she was otherwise constitutionally well. Within a week, she was admitted into the hospital due to a left lower motor neuron facial nerve 7 palsy. A skin biopsy of the indurated area was performed, which was diagnostic of the disease.

Case Presentation

On low power, the dermis contains a dense lymphoid infiltrate without epidermotropism. Within this infiltrate, there are sparse large and atypical B-cells within a background rich in morphologically normal T-cells and histocytes. The neoplastic large B-cells did not exceed >10% of the infiltrate and bore irregular nucleoli and nuclear pleomorphism. The neoplastic B-cells expressed pan-B markers including CD20 and CD79a and was also positive for Bcl-6 (Figure 2A&B). MUM-1, Bcl-2 and EBER in-situ hybridisation were negative in this atypical population. B-cell clonality via heavy chain rearrangements were unyielding. A dense infiltrate of reactive T-cells stained positive for CD3 (Figure 2C), CD4 and CD8, while retaining decoration of CD5. Numerous histocytes highlighted by CD163 (Figure 2D) was also detected in the milieu. Ki-67 showed a proliferation index of around 40%. Staging scans showed nodal and osseous involvement with locoregional invasion of the tumor into the mastoid segment of the left facial nerve canal. She was diagnosed with systemic T-cell/histiocytic-rich B-cell lymphoma, presenting first with a cutaneous plaque. She received 3 cycles of Rituximab, Cyclophosphamide, Doxorubicin, Vincristine and Prednisolone (R-CHOP), and demonstrated excellent response both clinically and radiologically.

Conclusion

We highlight this exceptional case to remind clinicians of this uncommon but devastatingly aggressive entity.

EADV CONGRESS
VIENNA
30 SEP - 3 OCT 2026

Abstract N°: 245

A peculiarly evolving nodular lesion of the forehead

Nicholas Kormos*[1], Alin Stefan Vizitiu[1], Raluca Ghete[1]

[1] Iuliu Haţieganu University of Medicine and Pharmacy, Dermatology, Cluj-Napoca, Romania

Introduction

Extraocular sebaceous carcinoma is a rare skin finding. Although overlooked as a first clinical diagnosis, there are some characteristics that can give away the tumor's true nature. Of which is the rapid pace of growth.

Case Presentation

An 82-year-old female with a 12-month history of a single evolving tumour on the right upper forehead, a 2-month history of increasing pain of the lesion, and occasional bleeding was admitted for surgical excision. Her past medical history included osteoporosis and atrial fibrillation with a moderate ventricular rate; she was otherwise healthy, with no other significant skin findings or internal malignancies. Her family history was negative for malignancies. Initially, the lesion evolved from a small erythematous macule to an 18 × 16 mm nodule covered by a yellowish crust and erosions. Dermatoscopy revealed a relatively well-defined lesion with inhomogeneous architecture and an extensive yellow crust covering an erythematous area. Globular blood vessels, white streaks, and superficial erosions were observed. Wide local excision was performed as the appropriate treatment, followed by histological and immunohistochemical evaluation. Undifferentiated pleomorphic basaloid cells with reduced eosinophilic cytoplasm, large hyperchromatic and atypical nuclei with vesicular chromatin, prominent nucleoli, and numerous mitoses were observed in the epidermis without crossing the dermo-epidermal junction or invading the adnexal appendages. Additionally, a moderate lymphoplasmacytic infiltrate, vascular congestion, and solar elastosis were observed. In the peritumoral epidermis, numerous cytonuclear atypia and parakeratosis were noted. The dermis contained a granulomatous reaction with multinucleated giant cells, histiocytes, macrophages, and neutrophils. The tumour cells were positive for EMA and androgen receptor immunohistochemistry, with focal positivity for CK7, and were negative for p16 and CEA. The Ki-67 index was approximately 60%.

Conclusion

Although poorly differentiated sebaceous carcinomas are considered highly aggressive and require extensive treatment, some cases may present a favourable course with slower natural progression.

EA CONGRESS
VIENNA
30 SEP - 3 OCT 2026

Abstract N°: 249

Facial Verrucous Epidermal Nevus with pruritus: Successfully treated with photodynamic therapy

Qiying Zhang*[1], Hui Sun[2], Xuefeng Fu[1], Meiyan Wang[1]

[1] Jinhua Municipal Central Hospital, Jinhua, China

[2] Huzhou Central Hospital, Huzhou, China

Introduction

Verrucous epidermal nevus (VEN) is uncommon and is typically present at birth. The disorder is essentially cosmetic and is found more often in females which features were brown and skin-colored verrucous papules or plaques distributed linearly along Blaschko's lines. VEN on the face often adversely affect the patient's self-esteem. While complete excision of the lesion is curative, it may leave disfiguring scars. The treatment of VEN on the face is challenging. We report a case of a woman who presented with a wart-like lesion on her face which was accompanied by pruritus. She was treated with the carbon dioxide(CO2) laser and aminolevulinate photodynamic therapy (ALA-PDT). The patient experienced a significant reduction in psychological stress with marked alleviation of the pruritis.

Case Presentation

The patient was a 28-year-old woman with a wart-like lesion on the left side of her face since birth. Physical examination showed a brown and skin-colored verrucous papillomatous lesion, approximately 2.8×2 cm in size, with hyperkeratotic papules distributed along the Blashko's line on the left face. Dermoscopy of the mass revealed a hyperplastic verrucous structure with light brown pigmentation against a pink background and localized white fibrous hyperplasia. One part of the papillary bulge of the lesion was removed for histopathological examination. Hematoxylin and eosin (HE) staining showed the presence of hyperkeratosis, papillomatosis, and thickening of the spinous layer. The patient underwent carbon dioxide laser treatment at the age of 10, but the wart-like lesion recurred two months post-treatment. Topical applications (Chinese herbal ointment and tretinoin cream) had also been unsuccessful. The lesion was accompanied by pruritus (Visual Analogue Scale score of 8), significantly impacting her daily life and causing unconscious scratching of the area during daily activities. These observations led to a diagnosis of verrucous epidermal nevus (VEN). The wart-like growths could not be concealed with makeup, and the patient reported feeling self-conscious about the mass on her face since childhood, inducing social stress. The primary concern of the patient was to improve the smoothness of the skin at the lesion site for aesthetic reasons and to alleviate the pruritus. Since the verrucous nevus was large and located on the face, surgical excision was likely to leave disfiguring scars, and the patient refused surgery. It was thus decided to use a combination of photodynamic therapy (PDT) and carbon dioxide laser. The carbon dioxide laser was applied to remove the hypertrophic lesion and enable the transdermal absorption of aminolevulinic acid. The first step was the topical application of a cream with 20% ALA to the lesion, after which the area was sealed for three hours to block light before PDT treatment. After 4 sessions of ALA-PDT, the lesion showed significant improvement. At the six-month follow-up, only slight elevation of the skin at the tumor site was observed, and the lesion could be concealed with makeup, thereby achieving a superior cosmetic effect. The patient experienced a significant reduction in psychological stress during social interactions, with marked alleviation of the pruritis, evident on the Visual Analogue Scale score of 3. The patient was very satisfied with the results.

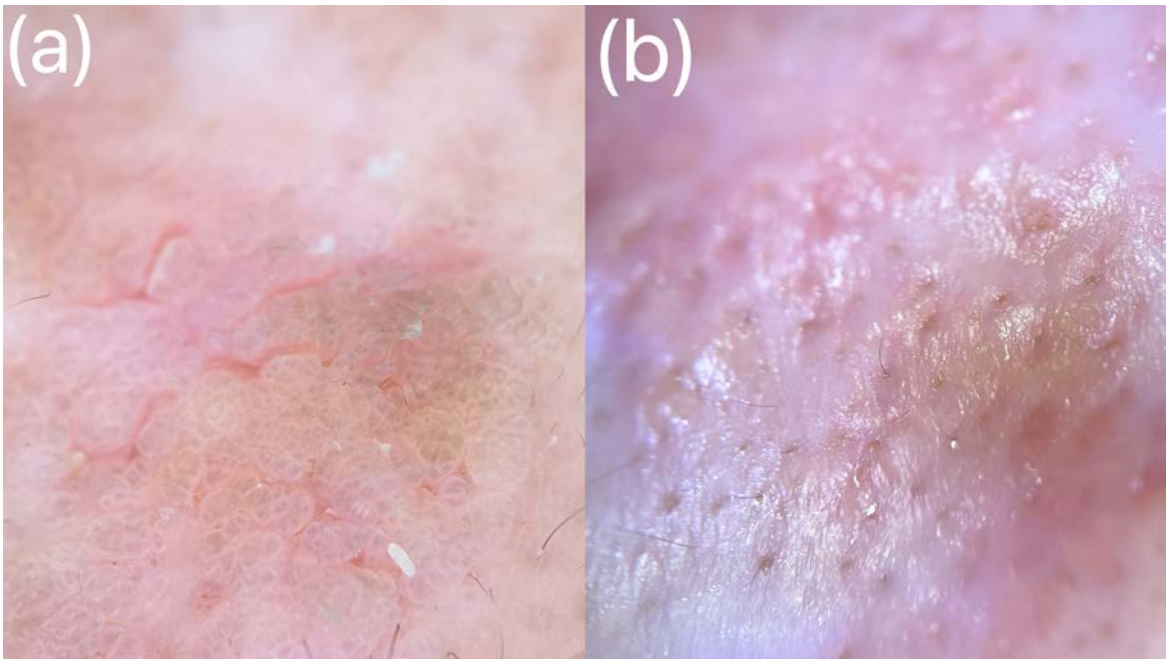

(a) Dermoscopy of the mass revealed a hyperplastic verrucous structure with light brown pigmentation against a pink background and localized white fibrous hyperplasia. (b)The dermoscopy which was taken 6 months after photodynamic therapy.

Conclusion

In our case, we first use the combination of photodynamic therapy and CO2 laser to treat a facial verrucous epidermal nevus and relieve pruritus. Before the ALA-PDT treatment, carbon dioxide laser was used to remove thickened proliferative material, thereby enabling effective ALA absorption. After PDT, the patient experienced a significant reduction in itching, resulting in improved quality of life. The results demonstrated good tolerance and cosmetic outcomes of this treatment. It is concluded that the combined application of ALA-PDT and carbon dioxide laser is both effective and safe for treating facial verrucous epidermal nevus.

EADV CONGRESS
VIENNA
30 SEP - 3 OCT 2026

Abstract N°: 250

Signet ring cell carcinoma: metastasis or primary tumor?

Ana Ferreirinha*[1], Cândida Fernandes[1], Ricardo Veiga[1], Alexandre João[1], Inês Aparício Martins[1]

[1] ULS São José, Hospital Santo António dos Capuchos, Lisbon, Portugal

Introduction
Signet ring cells are histologically characterized by intracellular accumulation of mucin that displaces the nucleus to the periphery. In the skin, this finding is classically associated with metastatic adenocarcinoma, although it may also occur in primary cutaneous neoplasms.

Case Presentation
A previously healthy 46-year-old man was admitted to the maxillofacial surgery department due to cervicofacial edema evolving over one year. Physical examination revealed an indurated, erythematous, bosselated plaque involving the bilateral preauricular, malar, mandibular, submental, and anterior cervical regions. Cervicofacial CT and MRI demonstrated edema of the deep cervical and submaxillary planes with cutaneous thickening, suggesting an inflammatory process. Ultrasound-guided biopsy of the subcutaneous tissue showed no abnormalities; however, skin biopsy revealed atypical epithelial cells scattered between collagen fibers of the dermis and hypodermis, several with signet ring morphology. Immunohistochemistry showed CK AE1/AE3+, CK7+, GATA3+, p40−, CK20−, CDX-2−, and PSAP−, consistent with signet ring cell adenocarcinoma. Thoracoabdominopelvic CT, laboratory evaluation, thyroid ultrasound, upper gastrointestinal endoscopy, and PET imaging revealed no significant abnormalities, and a diagnosis of primary cutaneous signet ring cell carcinoma was considered at this stage. Two months after the initial discharge, the patient was readmitted with dyspnea. A repeat thoracoabdominopelvic CT revealed pulmonary and bone metastases. The patient experienced rapid clinical deterioration and died before completion of the diagnostic workup.

Conclusion
Despite increasing sophistication in diagnostic methods, the primary tumor remains unidentified in approximately 3–5% of metastatic neoplasms. In the skin, signet ring cell carcinoma is a rare and aggressive variant, most commonly of gastrointestinal origin. Primary cutaneous signet ring cell carcinoma is a diagnosis of exclusion and can only be considered after rigorous exclusion of a visceral primary tumor. This case highlights the diagnostic complexity associated with the identification of signet ring cells in a skin biopsy and underscores the importance of thorough clinical, radiological, and immunohistochemical investigation to achieve an accurate diagnosis.

EADV CONGRESS
VIENNA
30 SEP - 3 OCT 2026

Abstract N°: 265

Active Prevention of Keratinocyte Carcinomas in Europe: Therapeutic Choices and Decision-Making Rationales

Marek Jankowski*[1], Andrea Carugno[2]

[1] Nicolaus Copernicus University, Faculty of Medicine, Department of Dermatology and Venereology, Torun, Poland

[2] University of Insubria, Department of Medicine and Surgery, Dermatology Unit, Varese, Italy

Introduction

The global incidence of keratinocyte carcinomas (KCs) is consistently rising. While consensus-based guidelines for active chemoprevention exist (recommending modalities like oral acitretin, nicotinamide, and photodynamic therapy), their real-world adoption and the rationales driving European dermatologists' therapeutic choices remain largely unclear. The objectives of the study were to evaluate the real-world adoption rates, therapeutic preferences, and underlying decision-making rationales of European dermatologists regarding the active prevention of KCs.

Materials and Methods

A web-based survey was distributed to 9,469 active European dermatologists. The survey assessed the frequency of preventive practices, treatment rankings, and the importance of various rationales (e.g., scientific evidence, familiarity, legal status, affordability) for both adopting and rejecting specific methods.

Results

Data from 1,274 respondents for primary prevention and 517 for secondary prevention (20.1% response rate) were analysed. Approximately 25% of practitioners seldom or almost never offer active prevention, with significant inter-country variability ($p < 0.001$). Topical imiquimod emerged as the most popular preventive method, significantly outpacing guideline-endorsed systemic options. "Scientific evidence" was the primary rationale for adopting a therapy, whereas "lack of familiarity" was the leading reason for rejection, particularly concerning oral nicotinamide. Lack of access and off-label legal status acted as major deterrents, while potential profitability was the least significant decision factor. The diagnosis of a previous KC increased the willingness to engage in prevention but did not alter the underlying rationale for method selection.

Conclusions

There is a significant discrepancy between current KC chemoprevention guidelines and everyday clinical practice among European dermatologists. A widespread preference for topical field therapies over systemic agents highlights a prevalent "systemic therapy hesitancy". To optimize healthcare resources and effectively change clinical behaviour efforts must go beyond raising awareness; they must focus on revising educational curricula, improving drug accessibility, and clarifying labelling regulations.

EADV CONGRESS
VIENNA
30 SEP - 3 OCT 2026

Abstract N°: 305

Non-Alcoholic Beverage Intake and Risk of Cutaneous Malignancies: A Systematic Review

Kim Tran*[1], Kimia Ameri[2], Quyen Pham[1], Eunice Chow[3], Mariusz Sapijaszko[3]

[1] Faculty of Medicine and Dentistry, University of Alberta, Edmonton, Canada
[2] Faculty of Medicine, University of British Columbia, Vancouver, Canada
[3] Division of Dermatology, Department of Medicine, University of Alberta, Edmonton, Canada

Introduction

Coffee, citrus juices, and tea contain bioactive compounds that may influence cutaneous carcinogenesis. Caffeine, chlorogenic acids, and polyphenols can exert antioxidant, anti-inflammatory, and anti-proliferative effects, whereas furocoumarins may interact with ultraviolet radiation (UVR) to promote phototoxic or mutagenic responses. Thus, beverage intake could mitigate or exacerbate skin cancer risk depending on dose and UVR exposure. Given inconsistent epidemiologic findings across beverage types and cancer subtypes, we systematically examined associations between beverage consumption and cutaneous malignancy.

Materials and Methods

This systematic review was conducted in accordance with the Preferred Reporting Items for Systematic Reviews and Meta-Analyses (PRISMA) guidelines. The review protocol was registered prospectively with the International Prospective Register of Systematic Reviews (PROSPERO; registration number CRD420251171224). Medline, EMBASE, and Web of Science were systematically searched for original studies, including case-control and cohort designs, published up to December 2025. Eligible exposures included coffee, tea, sweetened beverages, and fruit juices; alcohol was excluded due to a pre-existing PRISMA protocol. Reference lists of included articles were manually searched.

Results

Of 474 screened articles, 31 met inclusion criteria. Caffeinated coffee (n=10) was consistently associated with reduced basal cell carcinoma (BCC) risk and, to a lesser extent, cutaneous malignant melanoma (CMM). Seven studies demonstrated clear dose-response relationships with ≥4 cups of caffeinated coffee/day conferring the strongest protective effects. Decaffeinated coffee (n=4) and five unspecified studies on coffee type showed no meaningful association with any skin cancer subtype. Evidence for tea consumption (n=19) was mixed: four studies reported an inverse association with squamous cell carcinoma (SCC) and BCC, with black tea showing the most consistent effect, whereas 15 studies found no relationship or modestly elevated CMM risk. Citrus juice intake (n=6), especially orange juice, was repeatedly associated with increased skin cancer risk, potentially due to furocoumarin content. Studies examining soft drinks (n=2) showed null findings while milk (n=2) showed increased risk.

Beverage	BCC	SCC	CMM	Consistency between studies
Caffeinated coffee	↓↓↓	↓↓	↓/↔	Moderate–high
Citrus juice	↑↑	↑↑	↑/↔	Moderate
Tea	↓/↔	↓/↔	↔/↑	Low
Soft Drinks	N/A	N/A	↔	Low
Low fat/skim Milk	↑*	N/A	↑*	Limited studies

BCC = basal cell carcinoma; CMM = cutaneous malignant melanoma; N/A = not available; SCC = squamous cell carcinoma

*Limited studies, interpret with caution

Overview of reported associations between beverage consumption and skin cancer outcomes

Conclusions

These findings highlight that habitual beverage consumption may be a relevant factor in the overall risk profile for patients predisposed to skin cancer. Improved understanding of beverage-specific bioactive compounds and their interaction with ultraviolet radiation may help refine dietary guidance for individuals at increased risk of skin cancer, i.e., organ transplant recipients.

EA DV CONGRESS
VIENNA
30 SEP - 3 OCT 2026

Abstract N°: 331

Pyogenic Granuloma–Like Kaposi's Sarcoma of the Sole in an HIV-Negative Patient: A Diagnostic Pitfall

Imene Mahiou*[1], rahma boudjelal[1], meryem benhamed[1], Samira Zobiri[1]

[1] mustapha bacha hospital center, algiers, Algeria

Introduction

Pyogenic granuloma-like Kaposi's sarcoma is a recently described skin tumor showing features both of pyogenic granuloma and Kaposi's sarcoma. The differential diagnosis is often challenging.

Case Presentation

A 64-year-old hypertensive man presented with a plantar lesion evolving over eight months, associated with discomfort while walking. There was no history of trauma.Physical examination revealed two contiguous plantar nodules, violaceous, round, well-demarcated, and firm, surrounded by a 1–2 cm epidermal collarette. The remainder of the clinical examination was unremarkable.Histopathological analysis showed two nodules forming a single tumoral focus composed of a spindle-cell proliferation, occasionally containing erythrocytes, exhibiting cytonuclear atypia and mitotic figures. The proliferation infiltrated the dermis and ulcerated the overlying epidermis. Numerous variably sized vascular channels were observed, with focal red blood cell extravasation.Immunohistochemistry demonstrated CD34 positivity, ERG positivity, and strong nuclear HHV-8 expression, while HMB-45 was negative, confirming the diagnosis of Kaposi's sarcoma.Viral serology including HIV and staging investigations were negative. Complete surgical excision was performed, with an uneventful postoperative course and no evidence of recurrence.

Conclusion

This case highlights an uncommon plantar presentation of Kaposi's sarcoma in an HIV-negative elderly man. Classical KS usually begins as macules or plaques on the lower limbs before progressing to nodules. In contrast, our patient presented with two contiguous exophytic nodules without preceding lesions, creating a significant diagnostic challenge.Clinically, the main differentials included Acral lentiginous melanoma and Eccrine poroma, both common causes of solitary acral nodules in older individuals. The violaceous color and epidermal collarette further increased diagnostic ambiguity.Histopathology was decisive, demonstrating spindle-cell proliferation with slit-like vascular spaces and erythrocyte extravasation. Strong nuclear HHV-8 expression confirmed KS, while HMB-45 negativity excluded melanoma. Despite focal atypia and mitoses, the immunophenotype supported nodular-stage classical KS rather than angiosarcoma.The strictly localized plantar involvement may reflect HHV-8–driven angiogenesis amplified by chronic microtrauma in weight-bearing areas. Complete surgical excision was curative, with no recurrence to date.

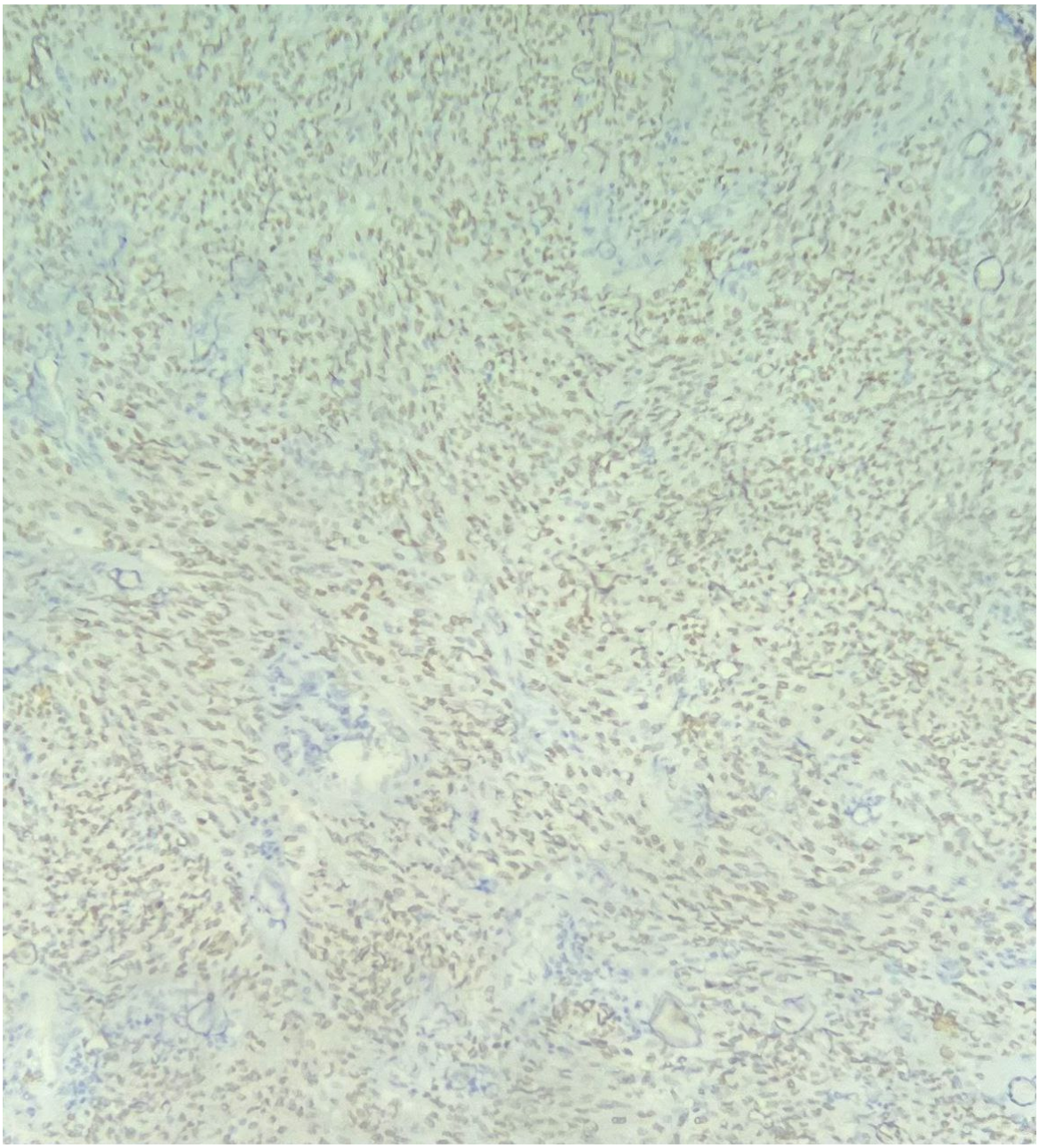

HHV8 positif

EA DV CONGRESS
VIENNA
30 SEP - 3 OCT 2026

Abstract N°: 337

Real-world use and safety of sonidegib in locally advanced basal cell carcinoma (laBCC) from the post-authorisation study NISSO: Cross-country differences between Germany, Italy and Spain cohorts

Josep Malvehy*[1], Ralf Gutzmer[2], Ulrike Leiter[3], Katharina Kähler[4], Paolo Ascierto[5], Massimiliano Scalvenzi[6], Ketty Peris[7], Gemma Pérez-Pastor[8], Sonia Ardébol[9], Reinhard Dummer[10], Serena Martelli[11], Ramon Arntz[11], Axel Hauschild[12]

[1] Dermatology Department, Hospital Clinic of Barcelona, University of Barcelona, Barcelona, Spain, Barcelona, Spain

[2] Universitätsklinik für Dermatologie, Venerologie, Allergologie und Phlebologie, Johannes Wesling Klinikum Minden UK der Ruhr-Universität Bochum, Minden, Germany

[3] Department of Dermatology, University Hospital Tübingen, Tübingen, Germany

[4] Department of Dermatology, University of c, Kiel, Germany

[5] National Tumour Institute "Fondazione G. Pascale" Unit of Melanoma Cancer Immunotherapy and Innovative Therapy, Naples, Italy

[6] Department of Dermatology, University of Naples Federico II, Naples, Italy

[7] UOC di Dermatologia, Dipartimento di Scienze Mediche e Chirurgiche, Fondazione Policlinico Universitario A. Gemelli-IRCCS, Rome, Italy

[8] Hospital General Universitario de Valencia, Servicio de Dermatologia, Valencia, Spain

[9] Dermatology Department, Ramon y Cajal University Hospital, University of Alcala, Instituto Ramón y Cajal de Investigación Sanitaria (IRYCIS), Madrid, Spain

[10] Department of Dermatology, University Hospital Zurich, Zurich, Switzerland

[11] Sun Pharmaceutical Industries B.V., Hoofddorp, Netherlands

[12] Department of Dermatology, University of Kiel, Kiel, Germany

Introduction

Following the BOLT study, sonidegib was approved for treating adults with locally advanced basal cell carcinoma (laBCC) not amenable to surgery or radiotherapy. The NISSO study confirmed that sonidegib treatment is well-tolerated and manageable in clinical practice. This analysis examines differences in patient characteristics, treatment approaches, and safety outcomes among Germany, Italy, and Spain cohorts.

Materials and Methods

NISSO is a partially prospective, observational, multinational, post-authorisation safety study (NCT04066504). laBCC patients (pts) were treated with oral sonidegib 200 mg once daily and followed for up to 3 years. Dose modifications were allowed according to the local prescribing information.

Results

Between May 6, 2019, and March 15, 2022, 309 laBCC pts were treated at 46 European sites (data cut September 30, 2025), of which 160 in Germany, 88 in Italy, 51 in Spain and 10 in Switzerland. Median age and primary tumour location on the head were consistent across countries. Tumour size differed substantially: Germany presented with the smallest median primary tumour diameter (8 mm) compared to Italy (25 mm) and Spain (30 mm). Infiltrative subtype was most prevalent in Spain (52.9%) vs. Germany (14.4%) and Italy (26.1%). Surgery was the most common previous intervention across all countries. Radiotherapy use varied considerably: Italy had low rates (2.3%) while Germany and Spain had rates of 12.5% and 13.7%, respectively. Clear differences emerged in the

systemic therapy use prior to sonidegib initiation. German and Spanish pts had similarly high rates of systemic pre-treatment (39.4% and 41.2%, respectively), whereas Italy had the lowest (8.0%). The median follow-up time was 18.9 months in Italy, 28.6 months in Germany and 33.9 months in Spain. The median duration of sonidegib treatment was longest in Italy (13.4 months including days off, 11.9 months excluding days off) and shortest in Spain (10.3 months both including and excluding days off). The proportion of pts who temporarily interrupted treatment was double in Germany and Italy (58.8% and 52.3%, respectively) than in Spain (27.5%). Dose reductions were also less common in Spain (31.4%) than in Germany (43.7%) and Italy (51.1%). Treatment-emergent adverse event (TEAE) rates were comparable across all countries (80.7%–93.1% of pts), with the lowest rate in Italy. Incidence of AE over time was consistent with known sonidegib safety profile and broadly comparable across countries (Figure 1). However, Spain showed higher incidences of alopecia, fatigue, and dysgeusia compared to other countries. Nausea exceeded 10% only in Germany (22.5%). Noticeably more pts discontinued due to TEAEs in Spain (41.2%) than in Germany (25.0%) and Italy (20.5%).

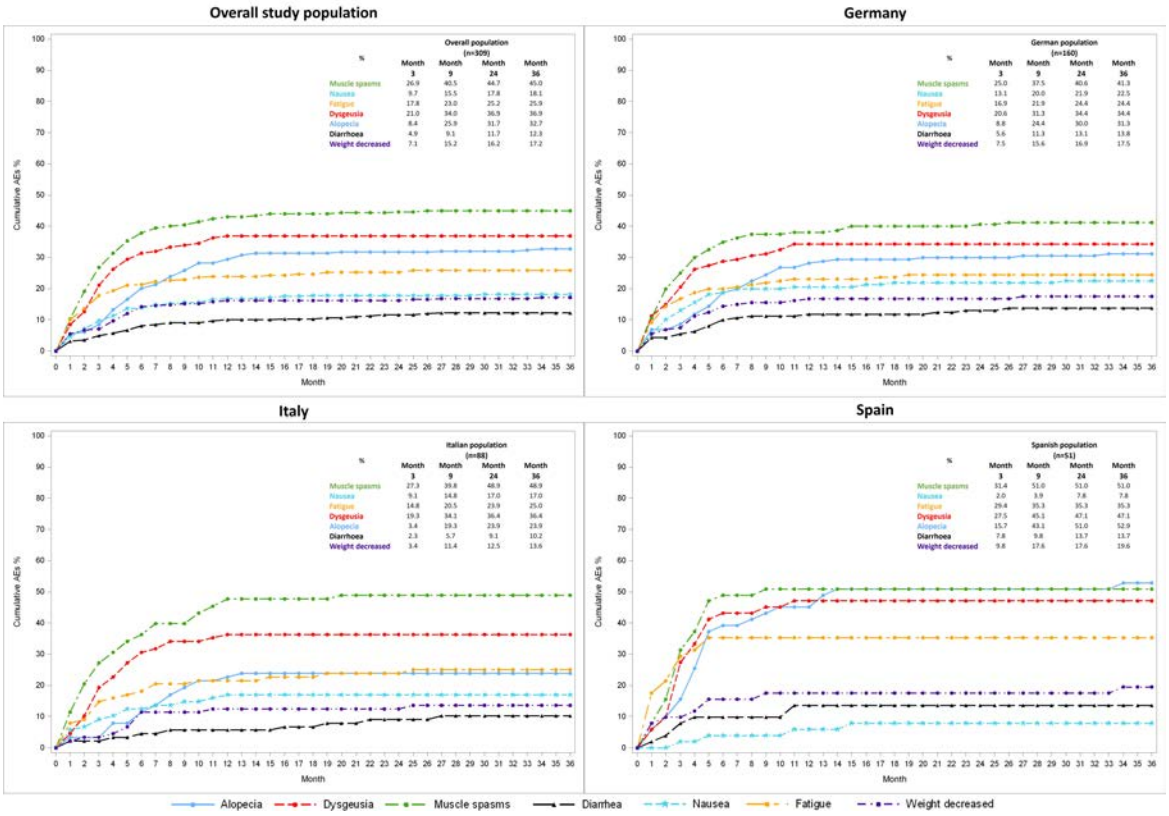

Fig. 1 Cumulative onset and frequency of TEAE over time

Conclusions

This cross-country comparison of the real-world NISSO safety data demonstrates notable differences in tumour burden, treatment histories and management strategies across Germany, Italy and Spain. Notably, Germany exhibits smaller tumour sizes, Italy shows potential earlier systemic therapy introduction and longer sonidegib treatment duration while Spain presents more infiltrative lesions at baseline, along with fewer dose modifications. These variations in real-life laBCC population and sonidegib use offer valuable insights for managing laBCC across Europe and may aid in harmonizing clinical practice and informing future guideline development.

EA DV CONGRESS
VIENNA
30 SEP - 3 OCT 2026

Abstract N°: 339

The integrated 31-gene expression profile (i31-SLNB) identifies patients with a low risk of sentinel lymph node positivity and 31-GEP identifies patients with high 5-year recurrence risk: The largest prospective, multicenter study of GEP for cutaneous melanoma

Adam Luber[1], Joseph Gadzia[2], James Ouellette[3], Angela Wingfield[4], Brian Martin*[5], Etan Marks[6]

[1] USDP Southwest Skin Specialists, Phoenix, United States

[2] Kansas Medical Clinic, Topeka, United States

[3] Wright State University/Premier Health, Dayton, United States

[4] The Dermatology Clinic, Gulfport, United States

[5] Castle Biosciences, Friendswood, United States

[6] Advanced Dermatology and Cosmetic Surgery, Delray Beach, United States

Introduction

Patients with cutaneous melanoma (CM) and their treating clinicians face two primary decisions after a CM diagnosis. First, should the patient undergo a sentinel lymph node biopsy (SLNB)? Second, how should the patient be followed with clinic visits and adjunctive surveillance (e.g. imaging, ctDNA) and is treatment with adjuvant/neoadjuvant therapies warranted? The current National Comprehensive Cancer Network (NCCN) guidelines recommend avoiding SLNB in patients with cutaneous melanoma if the risk of a positive SLN is <5% and discussing SLNB if the risk is ≥5%. Further, the NCCN recommends patients with early-stage disease (stage I-IIA) be followed with clinic visits every 6-12 months, with no adjunctive surveillance. In contrast, patients with more advanced disease (stage IIB-IV) should have more frequent follow-up and consider surveillance. However, management of early-stage patients based on these staging groups inadequately addresses individual patient risk, resulting in unnecessary sentinel lymph node biopsies and later detection of recurrences, when disease burden is greater and more difficult to treat. Incorporating the patient's molecular risk information alongside staging augments risk stratification to improve decision-making. In the largest prospective, multicenter study on gene expression profile (GEP) testing in CM to date, we demonstrate the 31-GEP provides significant prognostic information beyond current risk factors used to guide patient care. We also demonstrate that the i31-SLNB predicted risk score (an integrated result that combines the independently validated 31-GEP Class score plus select clinicopathologic factors) identifies patients with <5% risk who can safely avoid SLNB.

Materials and Methods

In this prospective study, patients were enrolled from 2020–2026 at 29 U.S. centers (n=2799). The 31-GEP returns results as low risk (Class 1A), increased risk (Class 1B/2A), and high risk (Class 2B). The i31-SLNB integrates the 31-GEP result with clinicopathologic factors (Breslow thickness, ulceration status, mitotic rate, and age) to provide an individualized percentage risk of a positive SLN. Kaplan-Meier analysis assessed 31-GEP recurrence risk stratification, log-rank test assessed differences between groups, and significant predictors of recurrence were identified by multivariable Cox regression.

Results

Patients with a Class 1A 31-GEP result had significantly higher RFS than those with a Class 1B/2A or 2B result (98.7% vs. 87.8% vs. 76.8%, p<0.0001). Patients with stage I-IIA disease and Class 2B results had RFS rates that were not statistically different than patients with stage IIB disease (85.3% vs. 86.1%, p=0.95). Multivariable Cox modeling demonstrated that Class 1B/2A (HR=3.30, p=0.004), Class 2B (HR=3.49, p=0.008), Breslow depth (HR=1.19, p=0.027), ulceration (HR=1.86, p=0.050), mitotic rate (HR=1.05, p=0.038), and positive SLN (HR=2.95,

p<0.001) were significant predictors of recurrence.

Among patients who underwent SLNB and received an i31-SLNB result (n=676), the i31-SLNB identified 27% (182/676) as low risk (i31-SLNB <5% predicted risk), of whom only 4.4% (8/182) had a positive SLN. By comparison, those with an i31-SLNB-predicted risk >10% (267/676) had a 22.8% (61/267) SLN positivity rate, a 5.2-fold increase over those with <5% i31-SLNB-predicted risk. Among SLNB-eligible patients with <5% i31-SLNB-predicted risk who did not undergo SLNB (n=565), 5-year RFS was 99.6% (95% CI=98.7-100%).

Conclusion

In the largest prospective, multicenter study of GEP in CM, the 31-GEP refined recurrence risk stratification, identifying patients with early-stage disease wherein considering adjunctive surveillance and treatment may be warranted. Importantly, the i31-SLNB accurately identified patients with a true risk of SLN positivity of <5% and those predicted low risk who did not undergo SLNB had 99.6% 5-year RFS, supporting use of the i31-SLNB as a tool to identify patients who can safely avoid SLNB.

EADV CONGRESS
VIENNA
30 SEP - 3 OCT 2026

Abstract N°: 346

Metastatic melanoma complicated by spinal cord compression during pregnancy: a multidisciplinary management challenge

Giulia Goedert*[1], Barbara Brunca[1], Ana Weber[1], Leticia Nunes Tajra[1], Antonio Gomes Neto[1]

[1] Pontifícia Universidade Católica de Campinas, Campinas, Brazil

Introduction

Melanoma in pregnancy represents a rare but clinically challenging condition, particularly in advanced stages, due to diagnostic constraints and limited therapeutic options, requiring a careful balance between maternal prognosis and fetal safety.

Case Presentation

A 32-year-old woman (G2P1), a public healthcare system patient, with a history of cutaneous melanoma diagnosed at the age of 29, arising from a congenital lesion on the right gluteal region, initially presented with a thick, non-ulcerated tumor (Breslow 16 mm, pT4a) showing angiolymphatic and perineural invasion. After wide excision and lymph node dissection confirming nodal metastases (pN2b), she was staged as IIIC (M0) and maintained under regular oncologic follow-up. At the age of 32, during routine staging imaging, newly detected hepatic nodules raised suspicion for metastatic disease. Subsequent magnetic resonance imaging was inconclusive, and further characterization with hepatocyte-specific contrast was indicated. However, this investigation was deferred after the patient was found to be pregnant, limiting diagnostic clarification and delaying systemic treatment decisions. At 25 weeks of gestation, she developed acute spinal cord compression due to vertebral metastasis, presenting with rapidly progressive neurological deficits. Urgent neurosurgical decompression with laminectomy and partial tumor resection was performed. Despite intervention, the patient experienced further neurological deterioration, evolving to paraplegia and persistent sensory loss. Serial imaging demonstrated progression of metastatic disease, including vertebral, pulmonary, and skeletal involvement. Given the advanced stage and clinical deterioration, a multidisciplinary team opted for planned delivery at 32 weeks of gestation to enable systemic treatment. The neonate was born in good clinical condition and showed favorable evolution, with no skin lesions identified on physical examination. In the postpartum period, the patient was initiated on palliative chemotherapy with dacarbazine and cisplatin, as immunotherapy (the preferred first-line treatment for advanced melanoma) was not available through the public healthcare system. Placental histopathological examination revealed ischemic changes without evidence of metastatic melanoma on immunohistochemistry (Melan-A, HMB-45, S100 negative), despite melanoma being the malignancy most frequently associated with placental metastasis.

Conclusion

This case underscores the aggressive course of advanced melanoma during pregnancy and highlights the impact of gestational physiological changes, including enhanced angiogenesis and immune tolerance, on tumor progression. The occurrence of spinal cord compression represents a severe and life-threatening complication requiring urgent intervention. Management is further complicated by the contraindication or limited safety data of standard systemic therapies during pregnancy, often necessitating postponement of optimal treatment. Additionally, restricted access to immunotherapy (the current standard of care for metastatic melanoma) due to healthcare system limitations may significantly impact prognosis and should be acknowledged in the global oncology discussion. Metastatic melanoma in pregnancy may demonstrate rapid progression with severe neurological complications. Early multidisciplinary planning is essential to balance maternal and fetal risks and to

allow timely initiation of appropriate oncologic therapy.



CARTER, Thomas J.; GEORGE, Christina; HARWOOD, Catherine; NATHAN, Paul. Melanoma in pregnancy: Diagnosis and management in early-stage and advanced disease. European Journal of Cancer, v. 166, p. 240-253, May 2022. DOI: 10.1016/j.ejca.2022.02.016. Garbe C, Amaral T, Peris K, Hauschild A, Arenberger P, Basset-Seguin N, Bastholt L, Bataille V, Brochez L, Del Marmol V, Dréno B, Eggermont AMM, Fargnoli MC, Forsea AM, Höller C, Kaufmann R, Kelleners-Smeets N, Lallas A, Lebbé C, Leiter U, Longo C, Malvehy J, Moreno-Ramirez D, Nathan P, Pellacani G, Saiag P, Stockfleth E, Stratigos AJ, Van Akkooi ACJ, Vieira R, Zalaudek I, Lorigan P, Mandala M; European Association of Dermato-Oncology (EADO), the European Dermatology Forum (EDF), and the European Organization for Research and Treatment of Cancer (EORTC). European consensus-based interdisciplinary guideline for melanoma. Part 1: Diagnostics - Update 2024. Eur J Cancer. 2025 Jan 17;215:115152. doi: 10.1016/j.ejca.2024.115152. Epub 2024 Nov 28. PMID: 39700658. Garbe C, Amaral T, Peris K ...Diretriz interdisciplinar europeia baseada em consenso para melanoma. Parte 2: Tratamento – Atualização 2024 Revista Europeia do Câncer, 2024; 215 Pelczar P, Kosteczko P, Wieczorek E, Kwieciński M, Kozłowska A, Gil-Kulik P. Melanoma in Pregnancy-Diagnosis, Treatment, and Consequences for Fetal Development and the Maintenance of Pregnancy. Cancers (Basel). 2024 Jun 7;16(12):2173. doi: 10.3390/cancers16122173. PMID: 38927879; PMCID: PMC11202133.

EA DV CONGRESS
VIENNA
30 SEP - 3 OCT 2026

Abstract N°: 350

Efficacy and tolerability of topically applied tirbanibulin on actinic keratoses with downward-directed proliferation patterns

Marcus Kuchner*[1], Thomas Dirschka[1], Lutz Schmitz[1]

[1] CentroDerm Clinic, Wuppertal, Germany

Introduction

Actinic keratoses (AK) are intraepidermal premalignant lesions with variable biological behaviour. Lesions showing downward-directed basal proliferation (PRO II/III) are considered to have increased risk of progression to invasive squamous cell carcinoma. These high-risk growth patterns cannot be reliably assessed by clinical grading. Non-invasive line-field confocal optical coherence tomography (LC-OCT) enables real-time visualization of proliferation architecture. We therefore investigated whether topical tirbanibulin modifies downward-directed proliferation patterns in AK.

Materials and Methods

In this prospective observational study, adults with non-hyperkeratotic actinic keratoses of the face or scalp demonstrating downward-directed basal proliferation patterns (PRO II or III) were treated with topical tirbanibulin applied once daily for 5 consecutive days. Longitudinal LC-OCT imaging was performed to assess changes in proliferation architecture of a target lesion at baseline, day 14 and day 70. Clinical clearance and changes in the actinic keratosis area and severity index (AKASI) were evaluated as secondary outcomes. Nineteen of 20 enrolled patients completed the study according to protocol.

Results

At day 70, LC-OCT demonstrated complete clearance of the target lesion in 63.2% of patients. Improvement of proliferation architecture, defined as transition to lower PRO grade or clearance, occurred in 89.5% ($p=0.002$). Clinical clearance was observed in 68.4% of lesions. Mean AKASI significantly decreased from 2.6 to 1.2 ($p<0.001$). Local skin reactions occurred in 89.5% of patients and were predominantly mild to moderate.

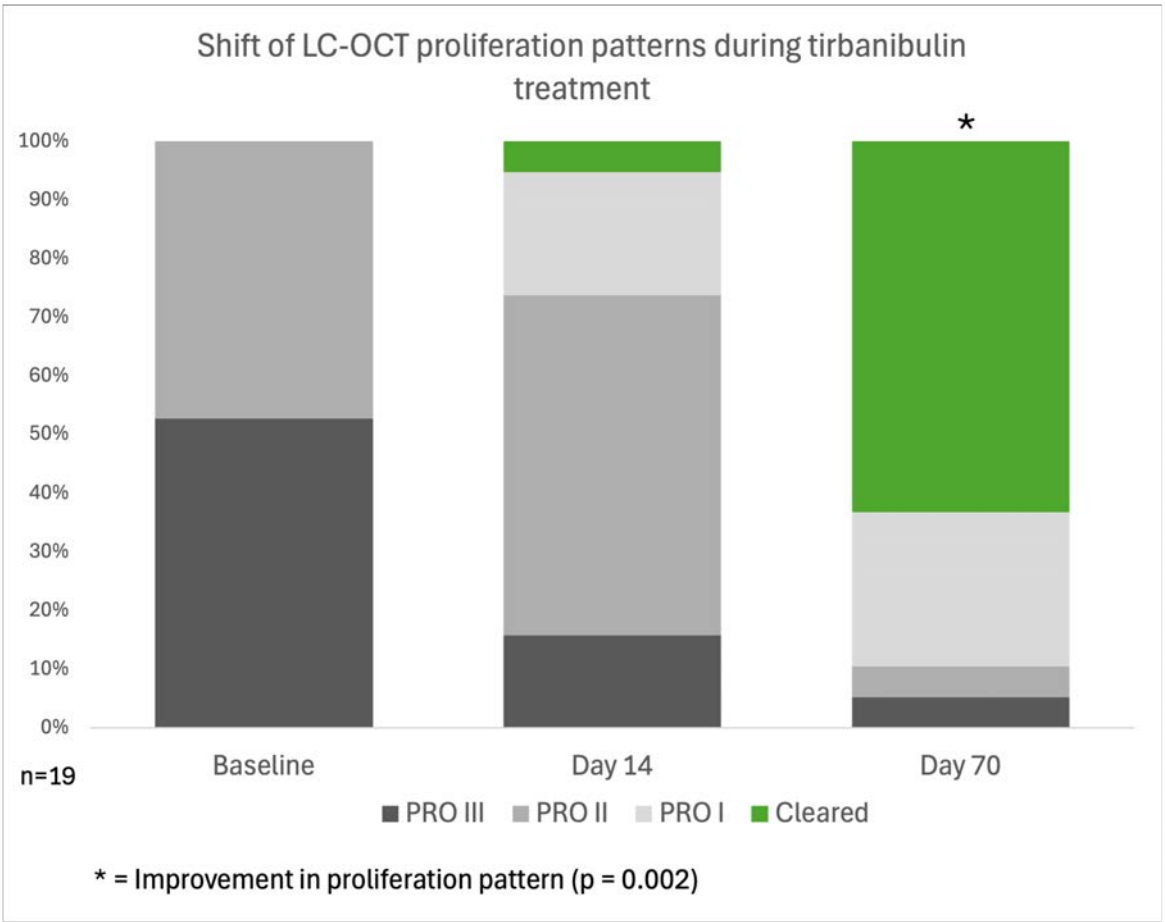

Distribution of LC-OCT proliferation patterns at baseline, day 14 and day 70 following topical tirbanibulin treatment (n=19). Improvement in proliferation pattern was observed in 89.5% of lesions (p=0.002)

Conclusions

Topical tirbanibulin was associated with significant reduction of high-risk downward proliferation patterns in AK as visualized by LC-OCT. As higher PRO scores are linked to increased risk of progression to invasive squamous cell carcinoma and PRO III lesions may show reduced responsiveness to established AK therapies, these findings support a biology-driven treatment approach beyond conventional clinical clearance assessment.

EADV CONGRESS
VIENNA
30 SEP - 3 OCT 2026

Abstract N°: 353

Pleomorphic Dermal Sarcoma of the Posterior Cruris in an Elderly Woman Presenting as an Exophytic Noduloulcerative Lesion: An Uncommon Clinicodemographic and Anatomic Presentation

Deniz Kızartıcı*[1], Isil Inanir[1], Gizem Kaya Efe[1], Peyker Temiz[2]

[1] Manisa Celal Bayar University, Faculty of Medicine, Department of Dermatology, Manisa, Türkiye
[2] Manisa Celal Bayar University, Faculty of Medicine, Department of Pathology, Manisa, Türkiye

Introduction

Pleomorphic dermal sarcoma (PDS) is a rare dermal-based malignant mesenchymal neoplasm with an estimated incidence of fewer than 1 per 1,000,000 per year. It predominantly affects elderly men and arises on chronically sun-damaged skin of the head and neck, with the scalp being the most frequently reported site. The pathogenesis is closely linked to ultraviolet radiation-induced DNA damage, accounting for its strong predilection for sun-exposed skin. PDS is distinguished from atypical fibroxanthoma by adverse histopathological features — subcutaneous invasion, tumour necrosis, lymphovascular and/or perineural invasion — conferring a higher risk of recurrence and metastasis. Occurrence in women and presentation at sun-protected sites such as the lower extremities are vanishingly rare, with only isolated cases documented in the literature, rendering this combination a particularly uncommon and diagnostically challenging presentation.

Case Presentation

We report a 79-year-old woman presenting with a 4-month history of a progressively enlarging lesion on the right posterior cruris. Physical examination revealed an exophytic noduloulcerative mass characterized by violaceous discoloration at the periphery, a firm indurated nodule on palpation, central ulceration, tumour necrosis, and foci of active bleeding at the ulcer base. No palpable regional lymphadenopathy was detected at the time of presentation. The clinical appearance raised concern for a primary cutaneous malignancy; the differential diagnosis included squamous cell carcinoma, atypical fibroxanthoma, angiosarcoma, and metastatic disease.Her past medical history was significant for hypertension and prior coronary angiography; current medications included amlodipine, valsartan, and aspirin. No history of prior radiotherapy to the affected area, immunosuppression, or significant chronic sun exposure of the lower extremity was documented.The lesion was surgically excised with wide local margins. Histopathological examination demonstrated a pleomorphic dermal sarcoma composed of highly pleomorphic spindle and epithelioid cells with bizarre nuclei, prominent nucleoli, and atypical mitotic figures. Invasion into the subcutaneous adipose tissue and areas of tumour necrosis were identified, fulfilling the diagnostic criteria for PDS. Immunohistochemical analysis revealed positivity for CD10 and smooth muscle actin (SMA). Staining for CD31, CD34, pancytokeratin (AE1/AE3), EMA, desmin, HMB45, and S100 were all negative, effectively excluding vascular, epithelial, and melanocytic differentiation. The tumour was graded as FNCLCC (Fédération Nationale des Centres de Lutte Contre le Cancer) grade III, indicating high-grade malignancy, with tumour-free surgical resection margins. For staging, F-18 FDG PET/CT imaging was performed, revealing increased FDG uptake in the bilateral hilar lymph nodes (SUVmax: 3.1). Given the symmetrical distribution and relatively low SUVmax value, this was interpreted as reactive/inflammatory change rather than metastatic involvement. No distant metastatic disease was identified. Following multidisciplinary tumour board evaluation, adjuvant radiotherapy to the primary tumour site was planned to minimize the risk of local recurrence given the high-grade nature of the tumour.

Conclusion

This case broadens the recognized clinicodemographic and anatomic spectrum of pleomorphic dermal sarcoma,

demonstrating that PDS can occur in elderly women at sun-protected sites such as the posterior cruris, presenting as an ulcerated exophytic noduloulcerative lesion. Clinicians and pathologists should maintain a high index of suspicion for PDS when evaluating atypical ulcerated soft tissue lesions of the lower extremity, even in the absence of classic risk factors such as male sex or head and neck location. Multidisciplinary management including wide local excision and adjuvant radiotherapy remains the recommended approach for high-grade tumours.

EADV CONGRESS
VIENNA
30 SEP - 3 OCT 2026

Abstract N°: 357

Rapidly progressive violaceous hemifacial pigmentation mimicking angiosarcoma: a diagnostic pitfall revealing melanoma

Andrea Danese*[1]

[1] Section of Dermatology, Department of Medicine, University of Verona, Italy, Verona, Italy

Introduction

Melanoma may rarely present with atypical clinical features, including violaceous or bruise-like pigmentation, closely mimicking vascular or hemorrhagic conditions. These presentations represent a major diagnostic pitfall and may lead to significant delays in diagnosis. Differentiating melanoma from vascular malignancies such as angiosarcoma is particularly challenging in facial lesions.

Case Presentation

A 69-year-old man presented with a 4–5 month history of progressively enlarging violaceous pigmentation involving the left hemiface. The patient had previously been evaluated twice in the emergency setting and discharged with a diagnosis of post-traumatic hemorrhage. Systemic symptoms included unintentional weight loss (4–5 kg) and occasional night sweats.

Clinical examination revealed an extensive blue–violaceous pigmentation involving the temporal, parietal, frontal, and malar regions, with partial extension beyond the midline and relative sparing of the periorbital area. Margins were irregular and partially ill-defined.

Dermoscopy showed a dark violaceous background with peripheral reddish globules, suggestive of hemorrhagic features.

Based on clinical and dermoscopic findings, a vascular neoplasm, particularly angiosarcoma, was strongly suspected. An urgent biopsy was performed. Histopathological examination demonstrated a densely cellular melanocytic proliferation involving the dermis and subcutis, associated with marked solar elastosis. The tumor was composed of epithelioid melanocytes arranged in nests, lobules, and single-cell dispersion, with cytologic atypia, absence of maturation, and mitotic activity (up to 3 mitoses/mm^2). No junctional component was identified in the examined specimen.Immunohistochemistry showed diffuse positivity for Melan-A and HMB45, with strong nuclear PRAME expression, supporting the diagnosis of invasive melanoma.

Staging imaging revealed pleural and pericardial effusion, raising suspicion of advanced disease.

The patient’s condition rapidly deteriorated, leading to death before completion of staging.

Conclusion

This case illustrates a rare and clinically deceptive presentation of melanoma as an extensive violaceous facial pigmentation with clinical and dermoscopic features strongly suggestive of a vascular malignancy that is exceptionally uncommon and represents a high-risk diagnostic pitfall. Lesions resembling ecchymosis that fail to regress and demonstrate progressive centrifugal growth should not be considered benign and early biopsy is essential, as delayed recognition may critically impact patient outcomes.

EADV CONGRESS
VIENNA
30 SEP - 3 OCT 2026

Abstract N°: 359

Dermatomyositis-like presentation of angioimmunoblastic T-cell lymphoma

Juan BAI*[1], Xinyi CHEN[1], Jianjun QIAO[1]

[1] The first affiliated hospital of Zhejiang university school of medicine, Hangzhou, China

Introduction

Angioimmunoblastic T-cell lymphoma (AITL), recently reclassified by the World Health Organization as nodal T-follicular helper cell lymphoma, angioimmunoblastic-type (nTFHL-AI), is a highly aggressive peripheral T-cell lymphoma. Cutaneous involvement is reported in up to half of the patients, presenting with highly polymorphic lesions that often mimic viral exanthems, drug eruptions, or autoimmune connective tissue diseases. However, a classic dermatomyositis-like presentation is exceptionally rare, representing a significant diagnostic challenge for dermatologists and rheumatologists.

Case Presentation

A 78-year-old male presented with a 2-month history of recurrent fever, dry cough, and polyarthralgia, which were unresponsive to empirical systemic antibiotics . Two weeks prior to admission, he developed a generalized, non-pruritic erythematous macular rash predominantly on the trunk and extremities, accompanied by non-pitting edema of the limbs. Physical examination revealed violaceous macules on the eyelids, dusky erythema on the anterior neck, and periungual erythema. Limb muscle strength was completely intact without overt myalgia. Laboratory investigations revealed negative autoimmune panels for antinuclear antibodies, antineutrophil cytoplasmic antibodies, and antiphospholipid antibodies. Infectious workups, including T-SPOT, GeneXpert, Mycoplasma, and fungal assays, were also unremarkable. Inflammatory markers were elevated, with a C-reactive protein level of 62 mg/L and an erythrocyte sedimentation rate of 68 mm/h. Creatine kinase was mildly increased to 320 U/L. A complete blood count showed a normal white blood cell count with 85% neutrophils. Positron emission tomography-computed tomography imaging demonstrated splenomegaly alongside diffuse hypermetabolic generalized lymphadenopathy involving the cardiophrenic, hepatic portal, retroperitoneal, iliac, inguinal, and cervical regions.A skin biopsy from the erythematous lesion showed hyperkeratosis with superficial and deep perivascular lymphocytic infiltration in the dermis. Immunohistochemistry of the skin was positive for CD3, CD4, CD8, PD-1, ICOS, and Bcl-6, and partially positive for CXCL13 and CD30. Staining was negative for EBER, MPO, CD20 and CD79a, with a Ki-67 proliferation index of 40%. A subsequent excision and histopathological examination of an enlarged right cervical lymph node confirmed the definitive diagnosis of nodal T-follicular helper cell lymphoma, angioimmunoblastic-type.

Conclusion

Skin lesions in angioimmunoblastic T-cell lymphoma can be deceivingly diverse. A dermatomyositis-like presentation poses a significant diagnostic pitfall and can be easily misdiagnosed as paraneoplastic dermatomyositis or a primary autoimmune disease. This case highlights the critical importance of maintaining a high index of suspicion for underlying peripheral T-cell lymphomas in elderly patients presenting with atypical autoimmune skin signs and systemic B-symptoms. Concurrent histopathological and immunohistochemical evaluations of both skin and lymph nodes, particularly focusing on the expression of T-follicular helper cell markers such as PD-1, ICOS, CXCL13, and Bcl-6, are imperative for establishing an accurate diagnosis and avoiding treatment delays.

EA DV CONGRESS
VIENNA
30 SEP - 3 OCT 2026

Abstract N°: 368

The rising incidence of penile squamous cell carcinoma in England 2013-2022.

Cherry Choudhary*[1, 2], Ryan Beazley[3], Priya Patel[4], Birgitta van Bodegraven[5], Asif Muneer[6], Georgios Kravvas[6, 7], Zoe Venables[4, 8], Christopher Bunker[6]

[1] Chelsea and Westminster Hospital NHS Foundation Trust, St John's Institute of Dermatology, London, United Kingdom
[2] St John's Institute of Dermatology, London, United Kingdom
[3] London North West Healthcare NHS Trust, London, United Kingdom
[4] Norfolk and Norwich University Hospitals NHS Foundation Trust, Norwich, United Kingdom
[5] British Association of Dermatologists, London, United Kingdom
[6] University College London, London, United Kingdom
[7] Whittington Health NHS Trust, London, United Kingdom
[8] National Disease Registration Service, Data and Analytics, NHS England, Leeds, United Kingdom

Introduction
Penile squamous cell carcinoma (PeSCC) is an uncommon cutaneous malignancy associated with human papilloma virus (HPV) and lichen sclerosus (LSc). Here, we report the contemporary epidemiology of invasive PeSCC in England.

Materials and Methods
National cancer registry data for invasive PeSCC were extracted from a publicly available national cancer registry database Get Data Out (2013-2022). Annual crude and European age-standardised rates (EASR) per 100,000-person-years (PY) were reported. Joinpoint regression analysis (v5.4.0) was used to report annual percentage changes (APC). Further comparisons were performed on survival, deprivation, ethnicity, treatment and route to diagnosis using χ^2 and odds ratios (ORs). All statistics were calculated using Python (v3.14).

Results
A total of 5,482 PeSCC cases were recorded (median 536 per-year, IQR 498-591). Crude incidence increased from 1.83 PY in 2013 to 2.24 PY in 2022, with a significant upward trend (APC 2.05%, 95% Confidence Interval (CI) 1.11-3.00, p<0.001). A similar rise was noted in EASR, increasing from 1.79 (2013) to 2.18 (2022). Incidence fell in 2020 compared to 2019 (Incidence Rate Ratio (IRR) 0.78, p<0.001) and rebounded in 2021 (IRR 1.16, p = 0.017). Most cases were diagnosed at early stage (Stage 1–2 ~71%), with approximately one quarter presenting with advanced disease (Stage 3–4 ~27%) and a small proportion reported as unknown stage (~2%).Cases were most common in the 65-69 age group (12.9% cases), with 55.4% of cases occurring in men age ≥60 years and 31.1% in those aged ≥70 years. Only 13.4% of cases were recorded in men under 40 years of age. Formal ethnicity analyses were limited due to incomplete data (unknown ethnicity: 4.79%). Distribution was skewed towards higher deprivation overall (IMD 1–2: 41.2% vs IMD 4–5: 39.1%; p = 0.005). This difference was significant in early-stage disease (Stage 1–2: 42.0% vs 38.6%; p = 0.029). Emergency presentation was more common in advanced disease (Stage 3–4: 126/826, 15.25% vs Stage 1–2: 149/2169, 6.87%; OR 2.44, CI 1.90–3.14, p<0.001)).Chemotherapy and radiotherapy were utilised more for stage 3-4 versus stage 1-2, at 31.02% to 2.99%, and 40.54% to 4.91% respectively. The 5-year net survival, comparing survival of cancer patients against the general population, for the 2013-2015 diagnoses at stage 1-2 was 86.9% (CI: 82.7–91.1), while stage 3-4 was 38.7%, (CI 31.6–45.9). 5-year Kaplan-Meier showed similar effect of later-stage presentation (Stage 1–2: 74.8%, CI 71.5–77.8; Stage 3–4: 35.2%, CI 29.1–41.3).

Conclusions

The incidence of PeSCC in England increased significantly between 2013 and 2022. Socioeconomic, ethnic and presentation timing disparities were noted which highlight potential inequalities in access. Alongside this, the differences between early and late disease survival have clear implications for service provision. Beyond epidemiological description, these findings reinforce the value of prevention underpinned by elucidating interactions between pathomechanisms viz. HPV and LSc.

EA DV CONGRESS
VIENNA
30 SEP - 3 OCT 2026

Abstract N°: 375

A Red Herring: Primary Cutaneous Marginal Zone B-cell Lymphoma Mimicking Benign Inflammatory Nodules in a Young Asian male

Isabelle Xiaorui Yang*[1], Hakan Aydin[1], Taige Cao[1]

[1] Sengkang General Hospital, Singapore, Singapore

Introduction

Primary cutaneous marginal zone B-cell lymphoma (PCMZL) is an indolent extranodal B-cell lymphoproliferative disorder confined to the skin at diagnosis. It is characterised by benign clinical behaviour, low risk of systemic dissemination, and an excellent prognosis, with disease-specific survival approaching 100% even without aggressive therapy. Despite being one of the more common subtypes of primary cutaneous B-cell lymphoma, PCMZL remains under-diagnosed due to its polymorphous and often deceptively benign clinical appearance, which may lead to lesions being overlooked and result in diagnostic delay.

Case Presentation

We report the case of a 32-year-old Chinese male who presented with a two-year history of intermittently pruritic, well-circumscribed erythematous papules on the bilateral forearms. The lesions waxed and waned over time and were clinically indistinguishable from arthropod bites or a chronic inflammatory dermatosis. There was no history of trauma, insect exposure, or systemic symptoms, and the patient was otherwise well with no significant past medical history. Physical examination revealed solitary, non-tender, non-indurated papules without surface change. No additional cutaneous lesions, lymphadenopathy, or hepatosplenomegaly were detected. Initial laboratory investigations were unremarkable apart from a mild isolated transaminitis.

Histopathological examination of the initial punch biopsy demonstrated a transdermal, bottom-heavy lymphoid infiltrate, sparing the epidermis by a Grenz zone and with focal extension into superficial subcutis. The infiltrate was polymorphic with small, monocytoid and centrocyte-like cells, as well as scattered, nucleolated immunoblasts. Overt plasmacytic differentiation was not identified and nonecrosis was seen. Mitoses were sparse. Immunohistochemistry showed diffuse CD20 positivity, indicating B-cell proliferation, while CD10 and cyclin D1 stains were negative. This staining profile supported a diagnosis of PCMZL, provided systemic origin was excluded, and argued against follicular and mantle cell lymphomas. Proliferation index by Ki-67 was low, in keeping with indolent biology.

A subsequent excision specimen showed similar findings. Staging with positron emission tomography-computed tomography demonstrated no evidence of extracutaneous disease, and the patient was referred to haematology for co-management and remains well.

Conclusion

PCMZL commonly presents as asymptomatic or mildly pruritic pink-to-violaceous papules, plaques, or nodules on the trunk or upper extremities, most commonly in young to middle-aged adults. Constitutional symptoms are characteristically absent. As such, early lesions may closely resemble benign conditions such as insect bites, folliculitis, or chronic eczema. Such presentations may contribute to prolonged diagnostic delay, particularly in younger patients and populations in whom PCMZL is perceived as rare, such as in Asia. Review of the literature suggests that reported cases in the region often describe larger, nodular, or infiltrated lesions, potentially skewing clinical expectations; by extension, this suggests that subtle variants may be frequently under-recognised.

This case highlights the clinical mimicry of PCMZL, which can present as a benign-appearing reactive dermatosis even in younger patients. It underscores the necessity of a low threshold for biopsy in persistent or unexplained solitary lesions, regardless of demographic expectations. Ultimately, rigorous clinicopathological correlation is the gold standard for avoiding diagnostic delay.

EADV CONGRESS
VIENNA
30 SEP - 3 OCT 2026

Abstract N°: 377

Expression of suppressor of cytokine of signalling 3 (SOCS-3) in mycosis fungoides

Hanan Rabeeh Nada*[1]

[1] Cairo University, Giza, Egypt

Introduction

Mycosis fungoides (MF) is the commonest type of CTCL.SOCs-3 role in CTCL is not fully understood.

Results

Thirty patients in MF and thirty age & sex -matched healthy control were enrolled into this study.
SOCS-3 protein expression in lesional and perilesional skin of MF and from normal control skin were assessed by ELISA technique.

Conclusions

The level of SOCS-3 is upregulated in MF. This may shed the light on its role in that important disease.

EA DV CONGRESS
VIENNA
30 SEP - 3 OCT 2026

Abstract N°: 377

Real-world effectiveness and safety of avelumab in an older, clinically heterogeneous population with advanced Merkel cell carcinoma: a nationwide Austrian multicentre study

Magdalena Forstinger*[1, 2], Matthias Barta[3], Matthias Brandlmaier[4], Christine Hafner[5], Maximilian Lammer[6], Lukas Muigg[7], Angela Öllinger[8], Anja Pinczker[9], Lisa Zahn[9], Timna Vith[10], Christian Posch[1, 2, 11]

[1] Sigmund Freud Privatuniversität, Vienna, Austria
[2] Klinik Hietzing, Vienna, Austria
[3] Klinikum Wels-Grieskirchen, Wels, Austria
[4] Universitätsklinikum Salzburg, Salzburg, Austria
[5] Universitätsklinikum St. Pölten, St. Pölten, Austria
[6] Universitätsklinikum Innsbruck, Innsbruck, Austria
[7] Universitätsklinikum Wiener Neustadt, Wiener Neustadt, Austria
[8] Kepler Universitätsklinikum, Linz, Austria
[9] Klinik Landstraße, Wien, Austria
[10] Klinikum Klagenfurt am Wörthersee, Klagenfurt, Austria
[11] Klinik und Poliklinik für Dermatologie und Allergologie, School of Medicine and Health, Deutsches Konsortium für Translationale Krebsforschung (DKTK), Technische Universität München, München, Germany

Introduction

Merkel cell carcinoma (MCC) is a rare and aggressive neuroendocrine skin cancer with a high risk of early metastasis and poor prognosis. Avelumab is an established treatment for advanced MCC, but evidence from routine clinical practice remains limited, particularly in older, comorbid, immunocompromised, and otherwise less-selected patients who are underrepresented in prospective trials.

Materials and Methods

We conducted a nationwide Austrian multicentre retrospective chart review of patients with histologically confirmed inoperable locally advanced or metastatic MCC who received at least one cycle of avelumab between September 2017 and December 2023. The primary endpoint was real-world progression-free survival (rwPFS). Secondary endpoints included real-world overall survival (rwOS), objective response rate (rwORR), duration of response (rwDOR), time to response (rwTTR), and safety. Exploratory analyses included real-world time to treatment discontinuation (rwTTD), univariable subgroup analyses, and post hoc multivariable Cox regression models.

Results

Forty-nine patients were included. Median age at avelumab initiation was 81 years (range 62–96), 59.2% were male, 77.6% had ECOG performance status ≤1, and 16.3% were immunocompromised or immunosuppressed. Median age-adjusted Charlson Comorbidity Index was 5.0 (range 2–11). At treatment initiation, 42.9% had stage IIIB and 57.1% stage IV disease. Only 16.3% met the retrospectively assessable eligibility criteria corresponding to the first-line JAVELIN Merkel 200 Part B setting, underscoring the less-selected nature of this real-world population. Avelumab was administered as first-line monotherapy in 77.6%, while 22.4% received additional

treatment modalities, most commonly radiotherapy. Median follow-up was 8.9 months (range 0–73.1). Median rwPFS was 10.1 months (95% CI 1.8–18.4) and median rwOS was 22.9 months (95% CI 5.0–40.8). rwORR was 47.9% (95% CI 34.5–61.7), median rwTTR was 3.9 months (range 1.4–12.7), and median rwDOR among responders was 19.2 months (95% CI 8.9–29.5). Despite limited cross-study comparability, rwPFS and rwOS were in a similar range to those reported in JAVELIN Merkel 200, whereas rwORR was lower. Median rwTTD was 3.9 months (95% CI 2.3–5.5). Adverse events (AEs) were documented in 71.4% of patients. Immune- and/or treatment-related AEs occurred in 53.1%, including grade ≥3 events in 24.5% of the overall cohort. AEs led to treatment interruption or discontinuation in 28.6%, including permanent discontinuation in 12.2%. In post hoc complete-case multivariable models (n=33) including ECOG status, LDH, and CCI, ECOG ≤1 was associated with lower hazards for rwPFS (HR 0.257, 95% CI 0.100–0.658; p=0.005) and rwOS (HR 0.157, 95% CI 0.047–0.521; p=0.002). LDH <240 U/L showed similar associations with rwPFS (HR 0.293, 95% CI 0.105–0.816; p=0.019) and rwOS (HR 0.134, 95% CI 0.028–0.651; p=0.013). CCI showed a counterintuitive association with rwPFS and no association with rwOS and was therefore not interpreted as a prognostic signal. These analyses were exploratory and hypothesis-generating.

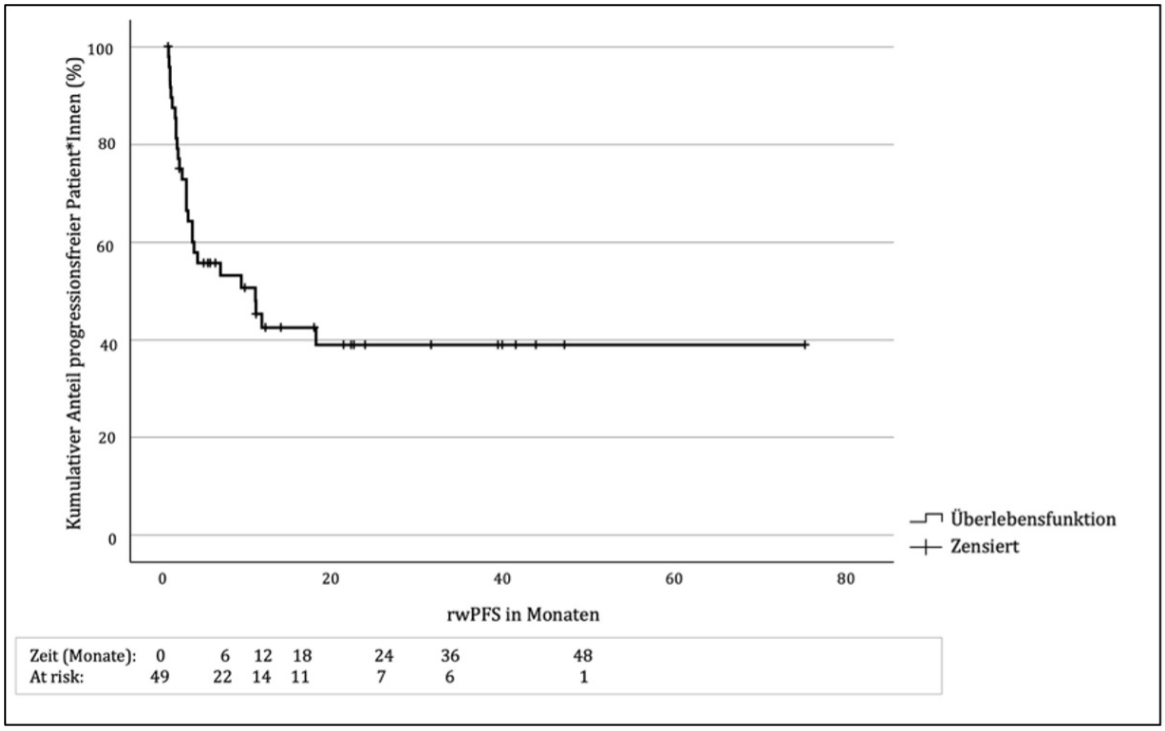

Conclusion

In this nationwide real-world cohort of predominantly older and clinically heterogeneous patients with advanced MCC, avelumab achieved clinically relevant response and survival outcomes despite advanced age, immunocompromising conditions, and treatment heterogeneity. AEs frequently prompted treatment interruption or discontinuation. These data support the effectiveness of avelumab in routine clinical practice, while ECOG status and LDH emerged as hypothesis-generating prognostic signals warranting prospective validation.

EA DV CONGRESS
VIENNA
30 SEP - 3 OCT 2026

Abstract N°: 384

Real-World Efficacy and Safety of Topical 1% Bexarotene GelMonotherapy in Early-Stage Mycosis Fungoides

Semanur Şimşek*[1], Leyla Baykal Selçuk[1], Burak Aksan[2], Osman Metintas[3], Arzu Ferhatosmanoğlu[1], ETEM ARICA[1]

[1] Karadeniz Technical University Faculty of Medicine, TRABZON, Türkiye

[2] Giresun University, Faculty of Medicine, GİRESUN, Türkiye

[3] Ağrı Training and Reseach Hospital, AĞRI, Türkiye

Introduction

Mycosis fungoides (MF) is the most prevalent cutaneous T-cell lymphoma,typically presenting as indolent patches or plaques in early stages (IA-IIA).While topical corticosteroids are standard first-line therapies, clinicalpersistence or steroid toxicity often necessitates alternative skin-directedtherapies (SDTs).Bexarotene, a third-generation retinoid X receptor (RXR)-selective retinoid,modulates cell differentiation and apoptosis. Although approved for early-stage MF, real-world data on its performance as monotherapy remainlimited. This study evaluates the clinical efficacy, safety profile, andtreatment compliance of topical 1% bexarotene gel in a real-world Turkishcohort.

Materials and Methods

Study Design: This retrospective observational study was conducted at twotertiary dermatology departments in Turkey. The study population consistedof patients diagnosed with early-stage mycosis fungoides who receivedtopical bexarotene gel therapy for at least 3 months. The study period andfollow-up intervals were defined based on the availability of clinicaldocumentation and patient records.Inclusion Criteria: Confirmed early-stage MF (IA–IB).Topical 1% bexarotene gel monotherapy (twice daily) for at least 3monthsAssessment: Clinical response was categorized as Clinical CompleteResponse (CCR), Partial Response (PR), Stable Disease (SD), or ProgressiveDisease (PD) per ISCL/EORTC criteria.Statistical Analysis: Descriptive statistics, Kolmogorov–Smirnov test, andPearson's chi-square/Fisher's exact tests (IBM SPSS v23.0). $P < 0.05$ wasconsidered significant.

Results

✓ In the final analysis of 39 patients, the overall response rate (ORR) was calculated as 76.9%, with 25.6% of patients achieving a CCR.
✓ A pivotal finding of the study was that the median treatment duration to achieve CCR was 7 months, emphasizing the necessity of therapeuticpersistence in clinical practice.
✓ A significant association was found between disease stage and treatment response; Stage IA patients achieved significantly higher CCR and PRrates compared to Stage IB ($p = 0.037$).
✓ Patients treated within the first 5 years of disease onset demonstrated significantly better clinical outcomes compared to those with a diseaseduration exceeding 10 years ($p = 0.016$).
✓ No sex-based differences were observed in treatment response, with both male and female patients showing similar efficacy across allresponse categories ($p = 0.919$).
✓ The therapy exhibited an excellent tolerability profile; reported adverse events (erythema, pruritus, irritation) were exclusively local, mild, andmanaged conservatively.
✓ The absence of systemic adverse events or laboratory abnormalities reinforces the long-term safety of bexarotene monotherapy in routinedermatologic practice.
✓ During the follow-up period, the relapse rate was recorded at 12.8%, with no significant difference observed between patients who receivedmaintenance therapy and those who did not ($p = 0.498$).

Conclusions

Topical 1% bexarotene gel is a highly effective monotherapy for early-stage MF, particularly in Stage IA patients. Clinicians should encourage patients to maintain therapy for at least 7 months to maximize the chance of complete remission.

EADV CONGRESS
VIENNA
30 SEP - 3 OCT 2026

Abstract N°: 385

Immune Status and Merkel Cell Carcinoma: Lessons from a 25-Year Institutional experience

Adi Raviv*[1, 2], Tzippy shochat[2], Assi Levi[2], Daniel Mimouni[2], Nadav Astman[1], Batya Davidovici[2]

[1] Tel Aviv Sourasky Medical Center, Tel Aviv, Israel

[2] Rabin Medical Center – Beilinson Hospital, Petach Tikva, Israel

Introduction

Merkel cell carcinoma (MCC) is a rare neuroendocrine tumor characterized by aggressive behavior and poor prognosis. Established risk factors include male gender, advanced age, chronic ultraviolet exposure, and chronic immunosuppression. Survival according to type of immunosuppression has hardly been investigated. In 2017, the Food and Drug Administration approved immune checkpoint inhibitors (ICIs) for the treatment of metastatic MCC. However, real-world efficacy data of their use in immunocompetent vs. immunodeficient patients are limited. The aim of this study was to compare the characteristics and management of these patient groups over a 25-year period, with emphasis on the role of ICIs.

Materials and Methods

The database of a tertiary medical center was retrospectively searched for all patients diagnosed and treated for MCC between 2000 and 2024. The diagnosis was confirmed by immunohistopathological evaluation. Demographic, clinical, treatment and outcome data were collected and analyzed.

Results

A total of 156 patients met the inclusion criteria: 132 (85%) immunocompetent, 10 (6%) solid organ transplant recipients (SOTRs), and 14 with a hematologic malignancy. The SOTR group was characterized by a lower mean age than the other groups (66 vs.74 years, P=0.07) and a longer interval between initiation of immunosuppression and MCC diagnosis than the hematologic malignancy group (13 vs. 4 years, P=0.0052). On multivariate Cox regression analysis, older age, male gender, advanced tumor stage at diagnosis, and solid organ transplantation were independently associated with higher overall and MCC-related mortality. ICIs were included in the treatment regimen of 30% of the SOTR group and 50% of the hematologic malignancy group. A durable partial or complete response was observed in 33% and 57% of treated patients, respectively. Among patients with stage IV disease, ICI therapy was associated with a 72% reduction in overall mortality and an 81% reduction in MCC-related mortality (P<0.03). In the subgroup of patients diagnosed with stage IV from 2017 onward, the 2- and 4-year relative overall survival rates were 43% and 31%, respectively, and the corresponding MCC-related survival rates were 59% and 52%.

Conclusions

In this single-center cohort study, a history of solid organ transplantation appeared to be an independent adverse prognostic factor for MCC whereas the presence of a hematologic malignancy was not. ICI treatment provided a substantial survival benefit in advanced MCC, supporting its selective use even in immunocompromised populations.

EADV CONGRESS
VIENNA
30 SEP - 3 OCT 2026

Abstract N°: 387

Zosteriform Cutaneous Metastases from Melanoma of Unknown Primary: A Case Report

Lorenzo Luotti*[1], Camilla Brunello[1], Nicola di Meo[1], Iris Zalaudek[1]

[1] Department of Dermatology and Venereology, University of Trieste, Trieste, Italy

Introduction

Cutaneous metastases represent a form of tumor dissemination to the skin, occurring in 0.6%–10.4% of all cancer patients and accounting for approximately 2% of all skin tumors. Melanoma is the malignancy most frequently associated with cutaneous metastases. These lesions are often asymptomatic, and their clinical presentation is highly variable; only rarely do they exhibit a dermatomal (zosteriform) distribution. Here, we report the case of an 87-year-old man presenting with zosteriform cutaneous metastases from melanoma of unknown primary origin.

Case Presentation

An 87-year-old man presented to our clinic for evaluation of lower limb ulcers. His medical history was notable for multiple comorbidities, with no personal or family history of melanoma or other skin cancers. A full skin examination revealed multiple bluish-black papular lesions arranged in a zosteriform pattern over the left paravertebral dorsal region. According to the patient, these lesions had been present for approximately two years. A skin biopsy demonstrated superficial dermal infiltration by epithelioid melanoma metastases, consistent with dissemination from an unknown primary tumor. The patient reported no prior history of herpes zoster. Comprehensive staging investigations showed no evidence of additional visceral or nodal metastatic involvement. Following a multidisciplinary discussion and considering the patient’s advanced age and comorbidities, a conservative "watch-and-wait" approach was adopted. A follow-up regimen was established, comprising dermatological evaluations every three months and imaging studies to monitor for disease progression.During 27 months of follow-up, ultrasound examinations revealed the development of multiple enlarged lymph nodes suspicious for metastatic involvement. Additionally, dermoscopic evaluation of the zosteriform metastases demonstrated a progressive increase in regression features, leading to the identification of a brownish macule with pseudopods and globules on dermoscopy. This lesion, which had been previously unidentifiable because it was obscured by the overlying papulonodular metastases, was suspected to represent the primary tumor. The patient declined further diagnostic procedures and any additional treatment.

Conclusion

This case highlights that lesions with a dermatomal distribution are not exclusively attributable to varicella-zoster virus reactivation but may, albeit rarely, represent cutaneous metastases from melanoma. Several mechanisms have been proposed to explain the zosteriform distribution of metastases, among which retrograde lymphatic spread is currently the most strongly supported. The absence of perineural invasion and viral cytopathic changes in most cases further supports this conclusion. Furthermore, the prolonged stability of the disease burden followed by late progression suggests a dynamic interaction with the host immune system, likely shifting from an initially robust immune response to eventual immune evasion via the acquisition of novel mutations.

EADV CONGRESS
VIENNA
30 SEP - 3 OCT 2026

Abstract N°: 393

A Case Report of Local Melanoma Skin Metastasis with Zosteriform Appearance

Daniela Nikolovska Hristova*[1], Maja Ivanova[2]

[1] Public Health Institution - Health Center, Skopje, North Macedonia
[2] Clinic for Oncology and Radiotherapy, Skopje, North Macedonia

Introduction
Local melanoma metastasis with a zosteriform pattern is a rare form of cutaneous spread in which metastatic lesions follow a dermatomal distribution, mimicking herpes zoster. These nodular lesions are often painful or pruritic and typically represent satellite metastases or regional recurrence of a previous melanoma.

Case Presentation
An 86-year-old white man presented with a two-month history of sudden onset of multiple blue-black nodules, measuring 0.2–1 cm in diameter, increasing in number and size. The lesions affected the right T7 and T8 dermatomes on the back.Four months prior, the patient had undergone surgical excision of a malignant melanoma, nodular type with superficial spreading. Histopathological findings revealed a Breslow thickness of 5.2 mm, Clark level III, mitotic rate of 8/mm^2, extensive ulceration, no lymphovascular invasion, and signs of regression in part of the invasive component.Dermoscopic examination showed homogeneous, structureless blue-gray nodules, some of which exhibited white streaks. Due to the advanced stage of the disease, the patient was referred to Oncologist and treatment with immunotherapy (pembrolizumab) was initiated. Because of the extensive area of skin metastases, total excision of the metastatic deposits was not performed by the plastic surgeon.

Conclusion
Skin metastases occur in approximately 10% of cancer patients. They may represent a sign of widespread disease or, in some cases, the first clinical manifestation of malignancy. Clinically, skin metastases can present as nodules, ulcers, blisters, sclerotic, or inflammatory lesions. Cutaneous metastases have been described from cutaneous, visceral, hematological, and vascular primary malignancies.In our case, widespread cutaneous melanoma metastases with a zosteriform appearance were observed as a consequence of a previously diagnosed nodular melanoma.

EA DV CONGRESS
VIENNA
30 SEP - 3 OCT 2026

Abstract N°: 402

Beyond Fair Skin: BCC in Skin of Colour

Diksha Garg*[1], Anuj Bhatnagar[1], Choudhary Sampoorna Raj[1]

[1] Armed Forces Medical College, Pune, India

Introduction
Basal cell carcinoma (BCC) is the most common cutaneous malignancy worldwide, classically associated with fair skin and chronic sun exposure. In skin of colour, its occurrence is less frequent and often under-recognized, leading to diagnostic delays.

Objective: To present a case series of six patients with BCC in skin of colour, emphasizing clinical presentation, diagnostic challenges, and surgical outcomes.

Materials and Methods
We analyzed six patients with histopathologically confirmed BCC presenting to our dermatology department. Lesion sites, clinical morphology, and treatment modalities were documented.

Case 1- A 55-year-old male with a BCC on the left temporal region, managed using a V-Y advancement flap, achieving a scar with excellent tissue match.

Case 2-A 58 year old female with a BCC on the back, reconstructed with a rhomboid (Limberg) flap, utilizing adjacent lax skin for tension-free closure and minimal distortion.

Case 3-A 46-year-old female with a BCC below right eye, where a rotational flap was designed to redistribute tension and better cosmesis.

Case 4-A 52-year-old female with a BCC on the left cheek, reconstructed with a rhomboid (Limberg) flap, utilizing adjacent lax skin for tension-free closure and minimal distortion.

Case 5-A 57-year-old male with a BCC on the left cheek, managed with excisional surgery and closure.

Case 6-A 48-year-old female with a BCC on the left cheek just below the left eye, managed with excisional surgery and closure.

Results
The series comprised four females and two males, aged 45–60 years. The face was the predominant site of involvement, with one case on the back. All lesions were pigmented, clinically mimicking melanocytic or benign pigmented tumors. Histopathology revealed nodular BCC in four cases and pigmented BCC in two. Surgical management was the mainstay: four patients underwent flap reconstruction for facial lesions, while two were treated with wide local excision. All achieved good functional and cosmetic outcomes, with no recurrence during 12–18 months of follow-up.

Conclusions
BCC is not exclusive to fair-skinned individuals. In skin of colour, it frequently presents as pigmented lesions,

leading to diagnostic challenges. A heightened clinical suspicion, supported by dermoscopy and histopathology, ensures timely diagnosis. Surgical excision with appropriate reconstruction remains the treatment of choice, offering excellent oncological and cosmetic results. Basal cell carcinoma is not confined to fair skin and early recognition in skin of colour prevents diagnostic delay and ensures optimal surgical outcomes.

EADV CONGRESS
VIENNA
30 SEP - 3 OCT 2026

Abstract N°: 403

Neoadjuvant Cemiplimab for Rapidly Growing Keratoacanthoma-like cSCC: An Organ-Sparing Strategy in an Anatomically Critical Site

Camilla Brunello*[1], Lorenzo Luotti[1], Marco Zanette[1], Nicola di Meo[1], Iris Zalaudek[1]

[1] Università degli Studi di Trieste, Trieste, Italy

Introduction

Cutaneous squamous cell carcinoma (cSCC) is a common keratinocyte malignancy typically managed with surgical excision. Tumors arising in cosmetically and functionally critical areas may pose significant therapeutic challenges. Keratoacanthoma-like cSCC represents a distinct subtype often characterized by rapid growth. Anti–PD-1 agents such as cemiplimab have shown efficacy in advanced cSCC, with emerging interest in the neoadjuvant setting.

Case Presentation

A 68-year-old woman presented with a rapidly growing lesion of the nasal columella. Her medical history included dyslipidemia treated with ezetimibe; she had Fitzpatrick phototype II, with no prior history of non-melanoma skin cancer or immunosuppression. At initial evaluation, the lesion measured approximately 10 mm and appeared as a nodular tumor with a central keratin plug. The initial differential diagnosis included keratoacanthoma and cSCC.Within 10 days, the lesion enlarged to 35 mm with development of a central necrotic core. Incisional biopsy revealed a well-differentiated (G1) squamous cell carcinoma with verrucous features, consistent with a keratoacanthoma-like subtype, without perineural invasion. Staging was consistent with AJCC (8th edition) stage II disease.Despite technical resectability, a neoadjuvant approach with cemiplimab (350 mg intravenously every 3 weeks) was initiated due to the anticipated surgical burden and risk of significant aesthetic and functional impairment. After one cycle, clinical reassessment showed reduction of the necrotic component without significant size decrease. FDG PET-CT demonstrated hypermetabolic activity of the primary lesion and bilateral laterocervical lymphadenopathy, interpreted as pseudoprogression.After four cycles, the lesion showed marked clinical regression. Repeat FDG PET-CT demonstrated complete metabolic response. Treatment was complicated by grade 2 hepatotoxicity, resolved with corticosteroids, and grade 1 hypothyroidism requiring levothyroxine. Histological mapping biopsies showed no residual carcinoma.A newly multidisciplinary discussion opted for a non-surgical approach, with close follow-up, after the neadjuvant treatment with cemiplimab; follow up is still ongoing, with no evidence of relapses at the 3 months

Conclusion

This case supports the potential role of neoadjuvant anti–PD-1 therapy in selected patients with resectable cSCC located in anatomically critical areas. In our patient, cemiplimab induced significant tumor regression, achieving a complete metabolic response and allowing avoidance of potentially disfiguring surgery. These findings highlight the value of a neoadjuvant approach not only for tumor cytoreduction but also for the preservation of aesthetic and functional outcomes in highly sensitive sites. Recognition of keratoacanthoma-like presentation and awareness of immunotherapy-related pseudoprogression are essential for optimal management. Neoadjuvant immunotherapy may therefore represent a valuable organ-sparing strategy in carefully selected cases of cSCC.

EADV CONGRESS
VIENNA
30 SEP - 3 OCT 2026

Abstract N°: 490

Impact of a Digital Consultation Service on Skin Cancer Detection: A Multidisciplinary Analysis of 130 Cases

Shunichi Jinnai*[1], Noritsugu Sawada[2], Akira Takahashi[1]

[1] National Cancer Center Hospital East, Chiba, Japan
[2] exMedio Inc., Tokyo, Japan

Introduction
Early detection of skin cancer remains a critical challenge in clinical practice. Primary care physicians often encounter suspicious skin lesions but may lack the specialized expertise for definitive triage. To bridge this gap, we established a digital consultation service, provided at no cost to healthcare professionals, connecting skin cancer experts with physicians across various medical specialties through a secure communication platform.

Materials and Methods
We retrospectively analyzed consultation data collected through the system. The analysis included the specialty and location of the consulting physicians, patient demographics, and the urgency of the expert advice provided. All data were anonymized to ensure patient and institutional privacy.

Results
A total of 130 consultations were conducted by 87 distinct physicians. While dermatologists accounted for 18.5% of the inquiries, a significant portion came from non-specialists, including those in general internal medicine (11.5%), home care (6.2%), and other specialties such as gastroenterology and cardiology. Although users were concentrated in urban areas, the service was utilized by clinicians nationwide. The patient population was primarily geriatric, with 62.3% aged 60 or older and 23.1% in their 80s. Gender distribution was relatively even (56.2% male). Diagnostic advice was categorized by urgency: 0.8% were classified as emergency and 5.4% as severe, requiring immediate or high-priority intervention. The majority of cases (59.2% for observation and 32.3% for minor lesions) allowed for reassurance and appropriate follow-up. This indicates the system's ability to capture critical "red flag" signals while managing non-urgent cases effectively.

Conclusions
This digital consultation service functions as an effective "gatekeeper" and educational bridge between primary care and specialized oncology. By facilitating expert input across diverse clinical settings and geographical regions, this initiative enhances the early detection of skin cancer and optimizes specialist referral pathways.

EA DV CONGRESS
VIENNA
30 SEP - 3 OCT 2026

Abstract N°: 516

Tirbanibulin 1% for cutaneous eyelid actinic keratosis: a consecutive five-case series with periocular protection

Jose María Camino-Salvador*[1], Elena Lucia Pinto Pulido[2], Margarita Zamorano-Aleixandre[3], Eva Castillo-Castillo[4], Clara Chiloeches Fernández[4], Consuelo Sánchez Herreros[4], Esther De Eusebio-Murillo[4], Gaston Roustan[1]

[1] Dermatology Department. Hospital Universitario Puerta de Hierro - Majadahonda, Madrid, Spain
[2] Dermatology Department. Hospital Universitario Príncipe de Asturias, Madrid, Spain
[3] Ophthalmology Department. Hospital Universitario Puerta de Hierro - Majadahonda, Madrid, Spain
[4] Dermatology Department. Hospital Universitario Guadalajara, Guadalajara, Spain

Introduction
Eyelid actinic keratosis is an uncommon presentation of chronic actinic damage and may be clinically subtle. Management is challenging because treatment must eradicate a premalignant keratinocytic lesion while minimizing inflammation, ocular toxicity and functional or cosmetic sequelae. Evidence for eyelid-specific management is limited, and no standardized therapeutic approach has been established. We aimed to describe the effectiveness and tolerability of a short-course tirbanibulin 1% regimen for cutaneous eyelid actinic keratosis.

Materials and Methods
We retrospectively reviewed five consecutive patients with cutaneous eyelid actinic keratosis treated with tirbanibulin 1% once nightly for 5 consecutive days. Ocular protection included concomitant vitamin A lubricant and hyaluronic acid artificial tears according to tolerance. Clinical assessments were scheduled at day 5, day 10, day 25/30 and week 8, with subsequent routine follow-up. The main outcomes were complete clinical response and local cutaneous or ocular adverse events, including chemical conjunctivitis and keratitis.

Results
Five eyelid actinic keratoses involving upper or lower eyelid sites were treated. Diagnosis was clinical or clinicopathological, with one lesion confirmed by 3-mm punch biopsy. The cohort included patients with relevant actinic damage and previous keratinocyte carcinomas, including one renal-transplant recipient receiving tacrolimus and mycophenolate. Complete clinical response was achieved in all five cases within 8 weeks after treatment initiation. Responses were observed as early as 5 to 10 days after treatment in some cases, while other lesions cleared by 3 weeks or by week 8. Treatment was generally well tolerated. One patient developed mild eyelid erythema and oedema at day 5, associated with low-intensity pruritus, without keratoconjunctivitis on ophthalmological assessment. Another patient showed mild erythema at day 15. No case of chemical conjunctivitis, keratitis, treatment discontinuation or clinically relevant ocular complication was recorded.

Conclusions
In this consecutive case series, a 5-day course of tirbanibulin 1% achieved complete clinical clearance of cutaneous eyelid actinic keratosis with minimal local reactivity and no observed ocular toxicity. The short regimen may be particularly advantageous in an anatomically delicate site where adherence, inflammation and ocular safety are critical. Larger prospective studies with longer follow-up are needed to define recurrence rates and the role of tirbanibulin among eyelid-sparing treatment strategies.

EA DV CONGRESS
VIENNA
30 SEP - 3 OCT 2026

Abstract N°: 548

Who Detects Melanoma? Evolving Patterns in Melanoma Detection

Joshua Burshtein*[1], Chase Merritt[2], Angela Rosenberg[3], Lauren DeBusk[3], Darrell Rigel[3]

[1] University of Illinois Chicago, Chicago, United States
[2] Ohio University Heritage College of Osteopathic Medicine, Dublin, United States
[3] UT Southwestern Medical Center, Dallas, United States

Introduction
Melanoma has the highest mortality rate of any skin cancer [1]. In 1992, a population-based survey assessed patterns of melanoma discovery [2]. Since then, educational initiatives have been implemented to increase awareness for melanoma detection. The current patterns of melanoma detection in the United States are unknown.

Materials and Methods
A prospective survey was distributed to patients at 8 dermatology clinics across diverse geographic regions in the US between June 2024 and March 2025. Inclusion criteria were any patient ≥18 years with history of melanoma at any point in their lives. This study received IRB approval.

Results
A total of 243 patients completed the survey. Approximately one-third (29%) of melanomas were self-discovered; the remainder were detected by dermatologists (42%), other medical providers (14%) and family members (15%). Nearly 60% could not see their own lesions easily. Women self-detected melanomas more often than men (41% vs 20%, $p<0.001$) and were more likely to have dermatologist detection (48% vs 35%, $p=0.02$). Men more frequently relied on spouses for discovery (11% vs 3%, $p=0.02$). Increasing age correlated with dermatologist detection (women $p=0.04$; men $p<0.001$). Dermatologists were more likely to find lesions that are not easily seen compared to other personnel (60% vs 40%, ($p<0.001$). Self-skin checks were strongly associated with self-detection ($p<0.001$). Detection patterns varied by site: dermatologists were more likely to find upper-body lesions ($p<0.001$), particularly on the back ($p=0.008$). Regression modeling showed lesion visibility and self-skin checks independently predicted self-discovery in both men and women ($p<0.05$). Greater age significantly increased dermatologist discovery in men ($p=0.002$) and each additional year of age raised the odds of a melanoma being discovered by a dermatologist by 6%.

Conclusions
The role of dermatologists and self-skin examination in melanoma detection for both men and women has increased substantially over the past 30 years. This data provides actionable insights for dermatologists, other medical providers, and patients, and can inform targeted public health strategies.

References
1. Aggarwal P, Knabel P, Fleischer AB. United States burden of melanoma and non-melanoma skin cancer from 1990 to 2019. J Am Acad Dermatol. 2021;85(2):388-395. doi:10.1016/j.jaad.2021.03.109
2. Koh HK, Miller DR, Geller AC, Clapp RW, Mercer MB, Lew RA. Who discovers melanoma? Patterns from a population-based survey. J Am Acad Dermatol. 1992;26(6):914-919. doi:10.1016/0190-9622(92)70132-y

EA DV CONGRESS
VIENNA
30 SEP - 3 OCT 2026

Abstract N°: 549

Dermatologist Workforce Trends Not Correlated with Melanoma Incidence in the United States: A Population-Based Longitudinal Analysis

Brooke Bartley[1], Joshua Burshtein*[2], Lauren DeBusk[1], Angela Rosenberg[1], Milaan Shah[3], Darrell Rigel[1]

[1] UT Southwestern Medical Center, Dallas, United States

[2] University of Illinois Chicago, Chicago, United States

[3] Medical University of South Carolina, Charleston, United States

Introduction

Melanoma incidence in the United States continues to increase. Overdiagnosis has been suggested as a causative factor in this increase and has been hypothesized as being driven by increasing dermatologist supply. Yet evidence is conflicting, with other papers showing no meaningful association between dermatologist density and melanoma incidence. To better assess the role of increasing dermatologist workforce supply in contemporary melanoma incidence trends, this relationship was examined using longitudinal data for the 2020-2025 interval.

Materials and Methods

A population-based longitudinal study was conducted using dermatologist workforce data from the American Academy of Dermatology and melanoma incidence data from the American Cancer Society/SEER. Population values to compute incidence and density were obtained from the US Census Bureau. Associations between changes in dermatologist density and melanoma incidence over time were evaluated using linear regression models, with additional comparisons using state-level density groupings.

Results

During the studied interval, US dermatologists increased by 5.70% vs a 0.96% increase in melanoma incidence. A longitudinal analysis demonstrated percent-changes in dermatologist density explained only a negligible proportion of variation in melanoma incidence (R^2=0.05) and was not statistically significant. Absolute-change longitudinal analysis yielded similar findings (R^2=0.06). Furthermore, state-level grouping analyses, including comparisons of the 25 highest versus lowest dermatologist density states, demonstrated no significant association with change in melanoma incidence (P=0.85).

Conclusions

Increasing dermatologist workforce was not materially associated with changes in melanoma incidence rates, suggesting that increasing dermatologist supply does not explain a proposed hypothesis for overdiagnosis of melanoma and related incidence increases.

References:

1. Adamson AS, Welch H, Welch HG. Association of UV Radiation Exposure, Diagnostic Scrutiny, and Melanoma Incidence in US Counties. JAMA Intern Med. Published online October 3, 2022. doi:10.1001/jamainternmed.2022.4342

2. Fleischer AB Jr, Aggarwal P. Lack of Association Between Increase in Number of Dermatologists and Rise in Melanoma Incidence Rate. J Clin Aesthet Dermatol. 2022;15(9):14-15.

3. Siegel RL, Miller KD, Jemal A. Cancer statistics, 2020. CA Cancer J Clin. 2020;70(1):7-30. doi:10.3322/caac.21590

4. Siegel RL, Kratzer TB, Giaquinto AN, Sung H, Jemal A. Cancer statistics, 2025. CA Cancer J Clin. 2025;75(1):10-45. doi:10.3322/caac.21871

EADV CONGRESS
VIENNA
30 SEP - 3 OCT 2026

Abstract N°: 555

TINCR Expression Correlates with Tumor Aggressiveness but is Not an Independent Prognostic Factor in Cutaneous Squamous Cell Carcinoma.

Raquel Santos-Juanes Galache*[1], Marta López-Pando[1], Miguel Plaza López[1], Marta García Puente[1], Iván Fernández-Vega[2], Blanca Vivanco Allende[2], Cristina Emilia Galache Osuna[1], Jorge Santos Juanes[1]

[1] Department of Dermatology. Hospital Universitario Central de Asturias., Dermatology. Faculty of Medicine. University of Oviedo., Oviedo, Spain
[2] Department of Pathology. Hospital Universitario Central de Asturias., Pathology. Faculty of Medicine. University of Oviedo., Oviedo, Spain

Introduction
Long noncoding RNAs (lncRNAs), including terminal differentiation-induced ncRNA (TINCR), have been implicated in tumor biology. However, their prognostic value in cutaneous squamous cell carcinoma (cSCC) remains unclear.

Materials and Methods
We conducted a retrospective study including 116 patients with cSCC. TINCR expression was assessed and correlated with clinicopathological variables and outcomes. Cox regression analyses were performed to evaluate predictors of metastasis, tumor-specific mortality, and all-cause mortality.

Results
TINCR-negative tumors were significantly associated with increased tumor thickness (>6 mm, $p < 0.001$), poorer differentiation ($p = 0.002$), and higher tumor stage ($p = 0.011$). In univariate analyses, TINCR negativity was associated with metastasis (HR 1.88, $p = 0.017$) and tumor-specific mortality (HR 2.02, $p = 0.033$), but not with all-cause mortality. However, TINCR lost statistical significance in multivariate models. Tumor budding emerged as the strongest independent predictor across all outcomes (HR up to 5.97, $p < 0.001$).

Conclusions
TINCR expression is associated with aggressive tumor features but does not independently predict clinical outcomes. Tumor budding remains the most robust prognostic factor in cSCC.

EADV CONGRESS
VIENNA
30 SEP - 3 OCT 2026

Abstract N°: 591

Malignant Blue Nevus with FGFR3/TSC1 Co-mutations and Keloid Diathesis: A Case of Heterogeneous Response to Anti-PD-1 Immunotherapy

Wei Tan*[1], nanhui wu[1], Zhuo Chen[2], Yeqiang Liu[1]

[1] Department of Pathology, Shanghai Skin Disease Hospital, School of Medicine, Tongji University, Shanghai, China

[2] Department of Dermatology, Shanghai Children's Medical Center, School of Medicine, Shanghai Jiao Tong University, Shanghai, China

Introduction

Malignant blue nevus (MBN) is a rare melanocytic neoplasm that arises from a pre-existing blue nevus and is characterized by distinct clinicopathological and molecular features. While BAP1 loss and GNAQ/GNA11 mutations are classic drivers, FGFR3/TSC1 co-mutations in MBN have rarely been reported. We present a case of MBN in a young male patient with a unique molecular profile, keloid diathesis, and a variable response to anti-PD-1 immunotherapy.

Case Presentation

A 21-year-old male presented with a one-year history of an asymptomatic blue-black macule in the left inguinal region, which rapidly enlarged into a painful mass over one month. Wide local excision was performed, and histopathology confirmed malignant transformation of a blue nevus. Immunohistochemistry showed BAP1 (+), HMB45 (+), SOX10 (+), P16 (+), and a Ki-67 proliferation index of 5–10%. Sentinel lymph node biopsy (inguinal) was negative. The patient received 18 months of anti-PD-1 monotherapy. However, 18 months after treatment initiation, imaging revealed inguinal lymph node metastases and a new right pulmonary nodule. Next-generation sequencing identified FGFR3 and TSC1 mutations, along with high PD-L1 expression, which supported continued immunotherapy. Inguinal lymphadenectomy was performed, and anti-PD-1 was resumed. The pulmonary nodule regressed at three months, but after eight additional months of therapy, PET-CT showed new multiple right pulmonary nodules (largest 1.5 × 1.0 cm), indicating acquired resistance to immunotherapy. The patient died 1.5 years later from progressive metastatic disease. Notably, the patient was keloid-prone, developing severe hypertrophic scarring after all surgical procedures.

Conclusion

This rare case of MBN with concurrent FGFR3/TSC1 mutations, high PD-L1 expression, and keloid diathesis highlights the heterogeneous response to anti-PD-1 immunotherapy. FGFR3/TSC1 alterations may represent a novel molecular subset of MBN with potential therapeutic implications. Further investigation is warranted to optimize targeted and immunotherapeutic strategies for this uncommon melanoma subtype.

EADV CONGRESS
VIENNA
30 SEP - 3 OCT 2026

Abstract N°: 596

Age-related differences in urgent suspected cancer referral pathways for skin cancer in England: a national analysis of route-to-diagnosis data, 2013-2020

Nikesh Patel*[1]

[1] St Heliers Hospital, London, United Kingdom

Introduction
Skin tumours are common, but the route to diagnosis may vary by age and tumour subtype. Because basal cell carcinoma (BCC), cutaneous squamous cell carcinoma (cSCC), and melanoma differ in biological behaviour and clinical presentation, age-related patterns in referral through the urgent suspected cancer pathway may not be uniform. This study examined age-specific variation in urgent suspected cancer referral for the major skin tumour subtypes using national English route-to-diagnosis data.

Materials and Methods
We analysed routinely collected national data from the National Disease Registration Service, NHS England Get Data Out programme. The study covered 2013 to 2020 and included 1,700,711 skin tumours overall. For the major tumour subtypes, there were 1,172,072 BCCs, 340,689 cSCCs, and 111,828 melanomas. Analyses examined the proportion of cases diagnosed following an urgent suspected cancer referral within age groups available in the dataset. For BCC and melanoma these were 00-24, 25-59, 60-69, 70-79, and 80+. For cSCC the source data used 00-39, 40-69, 70-79, and 80+.

Results
Clear age-related differences in urgent suspected cancer referral were observed, but the direction of association varied by subtype. For BCC, urgent suspected cancer referral proportions were very low overall, but increased steadily with age, from 0.39% in those aged 25-59 to 0.74% in 60-69, 1.14% in 70-79, and 1.93% in 80+. For cSCC, urgent suspected cancer referral proportions were substantially higher and were also greatest in older adults, at 45.72% in those aged 70-79 and 46.58% in those aged 80+. In contrast, for melanoma, urgent suspected cancer referral proportions declined with increasing age, from 68.53% in those aged 25-59 to 65.58% in 60-69, 59.22% in 70-79, and 51.53% in 80+. This represents an absolute difference of 17.00 percentage points between adults aged 25-59 and those aged 80+, and approximately two-fold higher odds of urgent suspected cancer referral in adults aged 25-59 than in those aged 80+ (OR 2.05, 95% CI 1.95-2.15; $p<0.001$). Thus, unlike BCC and cSCC, where older age was associated with a greater likelihood of diagnosis via the urgent suspected cancer route, melanoma showed the opposite pattern. This suggests that lower urgent referral in older adults is not a general feature of skin tumour diagnosis, but may reflect melanoma-specific differences in presentation, recognition, or referral behaviour in later life. Given the importance of timely melanoma diagnosis, the magnitude of this age-related decline may be clinically significant.

Conclusions
Age-related variation in route to diagnosis for skin tumours is clearly subtype-specific. Older age was associated with a higher likelihood of urgent suspected cancer referral for BCC and cSCC, but a lower likelihood for melanoma. The notably lower urgent referral proportion among older adults with melanoma suggests a potentially important age-related disparity in access to timely specialist assessment. These findings support further investigation into whether melanoma in older adults presents differently, is recognised less readily in primary care, or enters specialist pathways through less urgent routes.

EA DV CONGRESS
VIENNA
30 SEP - 3 OCT 2026

Abstract N°: 615

Lymphomatoid Granulomatosis Presenting as Ulcerative Lesions on the Thigh: A Case Report

Tugba Kevser Uzuncakmak[1], Kadir Atacan Yıldız*[1], Ege Uğur[1], Tuba Özkan Tekin[2], Ayşe Salihoğlu[2], Ahu Senem Demiröz[3], Ayşe Mine Önenerk Men[3]

[1] Istanbul University-Cerrahpasa, Cerrahpasa Medical Faculty, Dermatology and Venereology, Istanbul, Türkiye
[2] Istanbul University-Cerrahpasa, Cerrahpasa Medical Faculty, Hematology, Istanbul, Türkiye
[3] Istanbul University-Cerrahpasa, Cerrahpasa Medical Faculty, Pathology, Istanbul, Türkiye

Introduction

Lymphomatoid granulomatosis is a rare B-cell lymphoproliferative disorder associated with Epstein-Barr virus (EBV). It most commonly involves the lungs; however, it can present with various manifestations including cutaneous lesions. Here, we report the case of an elderly male who presented to the dermatology department with non-healing ulcers.

Case Presentation

A 70-year-old male presented with two painful ulcers on the left posteromedial thigh. The lesions had first appeared 7 months ago as erythematous papules and then slowly enlarged to form indurated ulcers. He had first consulted orthopedic surgery; debridement had been carried out, and two split-thickness skin grafts were performed to cover the ulcers. 6 months later, due to the recurrence of the lesions, he was referred to our dermatology department.

On physical examination, the base of the ulcers was covered with yellow-brown, firm, necrotic material, with focal hemorrhagic areas. No obvious purulent discharge was seen, though serosanguinous exudate was present. A slightly violaceous to erythematous hue was detectable at the periphery. He was admitted to our inpatient service with a preliminary diagnosis of pyoderma gangrenosum. Topical application of an extemporaneous preparation containing balsam of Peru was initiated after incisional biopsy and specimen collection for cultures.

Histopathology revealed extensive epidermal ulceration with a deep angiocentric and angiodestructive infiltrate extending from the dermis into the subcutaneous tissue and skeletal muscle, composed of inflammatory cells admixed with scattered large atypical lymphoid cells showing prominent nucleoli. Immunohistochemical studies revealed that the atypical cells were strongly positive for CD30, variably positive for B-cell markers (CD20, PAX5, CD79a), showed a high proliferative index (Ki-67 up to 90%), and were consistently positive for EBV by EBER in situ hybridization. Positron emission tomography/computed tomography (PET/CT) scan showed two mass lesions in the lungs, one in the right lower lobe and one in the left upper lobe. Endobronchial lavage, transthoracic fine needle aspirate of the lesion on the right lung, and core biopsy of the lesion on the left lung showed necrosis, without any live cells. Together with the histopathologic findings and due to the lack of nodal involvement, a diagnosis of lymphomatoid granulomatosis was made. Systemic chemotherapy with rituximab, cyclophosphamide, etoposide, vincristine, prednisone every 3 weeks was commenced. After 4 cycles of chemotherapy, the ulcers were completely epithelialized and the lung lesions showed significant regression.



Two irregularly shaped, well-demarcated, deep ulcers of the left medial thigh.

Conclusion

This case underscores the importance of considering lymphoproliferative disorders, including lymphomatoid granulomatosis, in the differential diagnosis of atypical or non-healing cutaneous ulcers. Early biopsy and multidisciplinary evaluation are essential for timely diagnosis and management.

EADV CONGRESS
VIENNA
30 SEP - 3 OCT 2026

Abstract N°: 651

CD30 POSITIVE CUTANEOUS T CELL LYMPHOMA OF NECK : A RARE PRESENTATION

Karthi Kishore*[1], anuj bhatnagar[2]

[1] MILITARY HOSPITAL SHILLONG, SHILLONG, India
[2] Armed forces medical college, pune, India

Introduction

Lymphomas are malignant tumors arising from lymphoid cells and are classified into Hodgkin and Non-Hodgkin lymphomas. T-cell lymphomas account for about 10% of Non-Hodgkin lymphomas. Primary cutaneous CD30-positive T-cell lymphoproliferative disorders are the second most common group of cutaneous T-cell lymphomas and include lymphomatoid papulosis and primary cutaneous anaplastic large cell lymphoma, which may show overlapping clinical features. Primary cutaneous large cell lymphoma is a rare entity, and the head and neck involvement is uncommon. We report a case of primary cutaneous CD30-positive T-cell lymphoma involving the neck, a site with very limited literature.

Case Presentation

A 67-year-old male with type 2 diabetes mellitus presented to the Dermatology OPD with a red, raised lesion over the neck of 10 days' duration. There was no history of fever or insect bite. Examination revealed a solitary, well-defined, firm nodule measuring 5 × 4 cm over the left side of the neck above the suprasternal notch. (Fig 1)The lesion was fixed to the overlying erythematous skin with loosely adherent scales, freely mobile over underlying structures, and showed no local rise in temperature. There was no lymphadenopathy. A clinical diagnosis of cutaneous tuberculosis was considered.An incisional biopsy was performed. Histopathology showed eroded epidermis with crusting and mixed inflammatory infiltrate comprising lymphocytes, polymorphs, and plasma cells on the surface. A moderate to dense lymphocytic infiltrate extended from the epidermis into the subcutis, with scattered large atypical lymphocytes showing irregular membranes and hyperchromatic nuclei.(Fig 2 a-d) Immunohistochemistry revealed CD3, CD2, and CD30 positivity with Ki-67 of 90%. CD8, CD56, ALK, LMP1, and EMA were negative. (Fig 3 a- d) A diagnosis of cutaneous CD30-positive T-cell lymphoma was made.Ultrasonography of the neck showed a well-defined heteroechoic lesion in the subcutaneous plane with a hypoechoic necrotic center on the left side. PET-CT revealed nodular cutaneous thickening on the left side of the neck at the level of the thyroid cartilage measuring 3.6 × 1.4 cm. Hematological and biochemical investigations were within normal limits. (Fig 4)The patient was evaluated by the oncosurgeon and hematologist and started on localized radiotherapy. He is tolerating treatment well and remains under regular follow-up.

Conclusion

Primary cutaneous large cell lymphoma can occur anywhere on the skin, but involvement of the head and neck is rare. It is a CD30-positive large T-cell neoplasm composed of large anaplastic, pleomorphic, or immunoblastic cells. CD30 is expressed in more than 75% of tumor cells. The disease occurs more commonly in males and is usually seen in the sixth decade of life. It may also be associated with immunosuppression, including HIV infection and post-transplant states.Histopathology typically shows large atypical CD30-positive cells with abundant cytoplasm, variable nuclear morphology, and a peripheral inflammatory infiltrate. Immunohistochemistry helps distinguish it from other cutaneous T-cell lymphomas. The main differential diagnosis includes transformed CD30-positive mycosis fungoides and lymphomatoid papulosis. According to WHO-EORTC 2018, the main entities include primary cutaneous anaplastic large cell lymphoma and lymphomatoid papulosis. Extracutaneous spread is uncommon but may occur in about 10% of cases, usually to locoregional lymph nodes. Prognosis is generally

favorable, with an approximate 4-year survival of 90%.Treatment depends on the extent of disease. Solitary localized lesions are managed with local excision or radiotherapy, while disseminated disease may require chemotherapy. In this case, because the lesion was solitary and there was no extracutaneous involvement, localized radiotherapy was chosen.

EADV CONGRESS
VIENNA
30 SEP - 3 OCT 2026

Abstract N°: 653

A Study on the Diagnostic Accuracy of Artificial Intelligence Application for Screening of Suspicious Basal Cell Carcinoma (BCC) in Filipino patients

Ma Christina Carmela Ozaeta*[1], Bernardita Policarpio[1], Angelica Guzman-Hernandez[1]

[1] University of Santo Tomas Hospital, Manila, Philippines

Introduction
Basal cell carcinoma (BCC) is the most prevalent skin cancer globally. Artificial intelligence (AI)-based algorithms have been developed to aid in detecting skin cancer, benefiting the scientific community, including non-dermatologists who face diagnostic dilemmas and a lack of expertise in dermatology. Suspicious lesions detected by AI may help the clinician to decide if a referral to a skin specialist is needed for histological evaluation.

Materials and Methods
This was a cross-sectional study at a tertiary hospital in the Philippines, including male and female patients aged 18 years or older with one or more suspicious basal cell carcinoma based on the dermatologist's assessment. Photos of the suspicious lesions were taken using the SkinVision (SkinVision B.V., Amsterdam, Netherlands) application and a skin punch biopsy was done regardless of the results of the application. The histopathological diagnosis was then compared with the AI application assessment.

Results
A total of 87 patients out of 127 were histopathologically diagnosed with BCC, with a prevalence of 68.50%. The sensitivity of the AI application was high at 98.85% (CI: 93.76-99.97%); however, the specificity was low at 65.00% (CI: 48.32-79.37%). The diagnostic odds ratio (DOR) was 105.39 (95% CI: 18.56-598.32).

Conclusions
The AI application can serve as an initial screening tool for patients with suspicious lesions. This can aid general physicians in areas where there is a lack of dermatologists in giving prompt care and referral to a dermatologist for evaluation and management.

EADV CONGRESS
VIENNA
30 SEP - 3 OCT 2026

Abstract N°: 670

Diagnostic accuracy and clinical impact of LC-OCT for the diagnosis of melanoma: a prospective study on 1,818 equivocal melanocytic lesions

Daniele Traini*[1], Gerardo Palmisano[1], Michelangelo Marasco[1], Mariano Suppa[2], Ketty Peris[1], Alessandro Di Stefani[1]

[1] Dermatology, Catholic University Of The Sacred Heart, Rome, Italy, Policlinico Universitario Agostino Gemelli, Rome, Italy, Rome, Italy

[2] Université libre de Bruxelles, Bruxelles, Belgium

Introduction

Prevention and early detection remain the most effective methods to decrease melanoma mortality. However, distinguishing benign melanocytic lesions from melanoma can be a highly challenging task, as these two entities often share overlapping morphological features. This leads to frequent misdiagnoses and unnecessary invasive procedures.

Noninvasive imaging techniques can potentially improve in vivo diagnosis of melanocytic lesions and facilitate the distinction between benign lesions and melanoma. Particularly, line-field confocal optical coherence tomography (LC-OCT) has emerged as a promising noninvasive imaging technique in dermatology, enabling real-time, histological in vivo visualization.

Materials and Methods

We conducted a prospective diagnostic accuracy study including 1,818 consecutive melanocytic lesions from 1,650 patients referred for third-level evaluation at a tertiary dermatology center. Lesions were classified as LC-OCT positive (suspicious for melanoma) or negative. Positive lesions were excised for histopathology, while negative lesions underwent structured clinical and dermoscopic follow-up. Histopathology or stability over 12 months served as the reference standard.

Results

Among 1,818 lesions, 121 melanomas (6.7%) were identified. LC-OCT yielded 116 true positives, 98 false positives, 5 false negatives, and 1,599 true negatives. Sensitivity was 95.9% (95% CI 90.7-98.2), specificity 94.2% (95% CI 93.0-95.2), positive predictive value 54.2%, and negative predictive value 99.7%. Overall diagnostic accuracy was 94.3%. Importantly, 88.2% of lesions were managed conservatively without immediate excision, and all false-negative melanomas were detected at an early stage during follow-up.

Conclusions

LC-OCT demonstrates high sensitivity and an excellent negative predictive value for melanoma diagnosis in a real-world setting, supporting its role as a clinically impactful adjunct in the management of equivocal melanocytic lesions.

EA DV CONGRESS
VIENNA
30 SEP - 3 OCT 2026

Abstract N°: 676

Scalp Nodule Evaluation Through a Clinical Case: A Differential Diagnosis of Melanoma

Carina-Andreea Bazon*[1], Andreea-Caterina Rusu[1], Teodora Alexa-Stratulat[2, 3], Anca Zbranca[1, 2]

[1] "Saint Spiridon" County Emergency Hospital, Iasi, Romania
[2] "Grigore T. Popa" University of Medicine and Pharmacy, Iasi, Romania
[3] Regional Institute of Oncology, Iasi, Romania

Introduction
Malignant melanoma of the scalp accounts for a disproportionate share of melanoma mortality and is frequently diagnosed late, owing to hair coverage, atypical or amelanotic presentation, and broad differential diagnoses with common benign scalp masses. Scalp melanomas often behave aggressively and may show nodular or desmoplastic growth, with non-specific clinical features that overlap with adnexal and cystic lesions, leading to potentially disastrous diagnostic delay. Patient- and physician-related delays are well documented in melanoma, particularly for nodular subtypes, where longer lag time correlates with more advanced disease.

Materials and Methods
In 2025, a 60-year-old woman presented with an extensive left parieto-occipital scalp tumor, satellite nodules and cervical lymphadenopathy. History revealed a nodular scalp lesion, dermoscopically labeled for more than 10 years as a “sebaceous cyst” and monitored without histologic confirmation. Approximately six months before referral, the dermatologist noted recent darkening of the lesion, raised suspicion of malignancy, and recommended excision, which the patient postponed. Clinical examination in the plastic surgery department, followed by incisional biopsy and histopathologic analysis, established the diagnosis. A primary objective of this study is to perform a differential diagnosis between scalp melanoma and other lesions with a similar clinical presentation, focusing on dermoscopic features, while also comparing their epidemiological data, pathophysiological mechanisms, treatment approaches, and prognostic outcomes.

Results
At clinical evaluation, the lesion occupied the entire vertex and part of the occiput, was infiltrative, ulcerated, crusted, irregularly bordered and fixed to deep planes, with rapid enlargement over two months. Histopathology showed malignant melanoma, probably nodular type. Staging investigations revealed an expansive parieto-occipital mass with multiple satellite nodules and level IIb lymphadenopathy, consistent with advanced scalp melanoma, which is known to carry poor 10-year survival and higher recurrence compared with melanomas at other sites. The patient received palliative immunotherapy in the oncology department, but her condition deteriorated rapidly, mirroring reports of fulminant nodular scalp melanomas once they become clinically overt. Retrospectively, the long-standing “cyst” could represent: (i) a misdiagnosed primary melanoma (including desmoplastic melanoma, which may present as an amelanotic scalp lesions and be confused with benign tumors); (ii) a true adnexal or cystic process that later developed an adjacent melanoma, analogous to nevus-associated or collision lesions on the scalp; or (iii) a de novo, probably amelanotic nodular melanoma arising in a clinically bland scalp and then undergoing abrupt pigmentary change and explosive vertical growth.

Conclusions
This case highlights a double delay: a possible late rise in clinical suspicion in a long-standing scalp nodule, and a subsequent six-month patient-related postponement of excision, both occurring in an anatomical site where melanoma is particularly lethal. Any persistent, enlarging or morphologically changing scalp nodule - especially in

older patients - should trigger early biopsy, even when it resembles a benign “sebaceous cyst” , given that a meaningful minority of scalp masses and adnexal tumors hide clinically significant pathology. Routine dermoscopic examination, a low threshold for histologic sampling, and systematic patient education on annual screening and prompt excision of suspicious lesions are essential to improve the prognosis of scalp and nodular melanoma.

EA DV CONGRESS
VIENNA
30 SEP - 3 OCT 2026

Abstract N°: 676

Fractionated ablative laser-assisted methyl aminolevulinate photodynamic therapy with 532-nm KTP activation for multiple basal cell carcinomas in Gorlin syndrome

Colton Jensen*[1], B Kent Remington[2]

[1] University Dermatology Center, Edmonton, Canada
[2] Remington Laser Dermatology Centre, Calgary, Canada

Introduction

Gorlin syndrome, or nevoid basal cell carcinoma syndrome, results from PTCH1 mutation in the hedgehog pathway, predisposing patients to lifelong development of numerous basal cell carcinomas (BCCs). Standard surgical approaches often achieve control but are limited by cumulative morbidity, scarring, and psychological burden in patients with hundreds of lesions. Methyl aminolevulinate photodynamic therapy (MAL-PDT) offers an established tissue-sparing treatment for superficial and selected nodular BCCs, though incomplete photosensitizer penetration and significant pain during illumination limit use in thicker or multiple lesions. Fractionated ablative laser pretreatment has emerged as an effective means to enhance methyl aminolevulinate (MAL) uptake through creation of dermal micro-channels, while vascular-selective lasers such pulsed dye laser (PDL) have demonstrated complementary antitumour activity. This case illustrates a novel combination approach integrating fractionated ablative laser pre-treatment followed by MAL-PDT activated by potassium titanyl phosphate (KTP) vascular laser for multiple BCCs in Gorlin syndrome.

Case Presentation

A 76-year-old man with Gorlin syndrome presented with 54 superficial and nodular BCCs on the chest, back, and shoulders. Over the past 45 years, he had previously undergone more than 850 prior treatments including surgical excision, Mohs micrographic surgery, cryotherapy, CO_2 laser ablation, topical 5-fluorouracil, and standard MAL-PDT, producing substantial scar and psychological burden. Because all current lesions were low-risk and the patient wished to avoid further surgery, a laser-assisted MAL-PDT protocol was performed. After anesthesia with 1% lidocaine with epinephrine, each lesion and a 3 mm margin were superficially curetted and treated using fractionated erbium-doped yttrium aluminium garnet laser (Er:YAG, 22 J/cm^2, 100 ms) to enhance intralesional drug delivery. MAL 160mg/g cream was applied under occlusion with transparent film for 3 hours, followed by removal and photoactivation using a 532-nm KTP laser (12 mm spot size, 5.5 J/cm^2, 10 ms, three pulses per lesion). Expected post-treatment erythema, edema, and mild serous crusting occurred, but the patient reported no pain or need for analgesia.

At 3-month follow-up, all treated lesions cleared clinically with smooth, scar-free surfaces and no pigment alteration. At 12 months, 51 of 54 lesions (94%) remained in remission, corresponding to low lesion-level recurrence rates comparable to or better than conventional red-light MAL-PDT. No infection, ulceration, or delayed healing occurred, and patient satisfaction was high because the session treated dozens of tumours in a single, well-tolerated visit.

Conclusion

This case demonstrates that fractionated ablative laser-assisted MAL-PDT with KTP activation can achieve excellent efficacy and cosmesis in a patient with extensive BCC burden from Gorlin syndrome. The approach is mechanistically appealing: fractionated pretreatment significantly improves MAL penetration into the dermis and adnexal structures, while the 532-nm vascular laser may potentiate PDT efficacy through both protoporphyrin IX activation and selective tumour vascular photothermolysis. Practical advantages include rapid illumination,

reduced discomfort, and potential dual-mechanism tumour targeting. This strategy may serve as a validated, office-based, scar-sparing option for patients in whom repeated surgery is undesirable. Prospective comparative studies are warranted to define optimal laser parameters, confirm histologic clearance, and assess long-term recurrence and safety.

EADV CONGRESS
VIENNA
30 SEP - 3 OCT 2026

Abstract N°: 689

Mogamulizumab-Induced Tumor Lysis Syndrome in a Patient with Advanced Sézary Syndrome: A Case Report

Leonie Adam*[1], Alica Gravius[1], Thomas Vogt[1], Claudia Pföhler[1]

[1] Universitätsklinik des Saarlandes, Homburg, Germany

Introduction

Sézary Syndrome (SS) is an aggressive leukemic variant of cutaneous T-cell lymphoma (CTCL) characterized by significant blood involvement and a poor prognosis. Mogamulizumab, a humanized monoclonal antibody targeting the CC chemokine receptor 4 (CCR4), has emerged as a potent systemic immunotherapy that induces rapid depletion of malignant T-cells through antibody-dependent cellular cytotoxicity (ADCC). However, in patients with high tumor burden and extensive cardiovascular or metabolic comorbidities, its administration necessitates stringent clinical monitoring to manage potential severe systemic complications.

Case Presentation

We report on a male patient (initial diagnosis 01/2023) with Sézary Syndrome, classified as Stage IV A1 (T4 NX B2 M0) according to ISCL/EORTC 2007 criteria. Baseline diagnostics confirmed high leukemic burden (CD4/CD8 ratio: 96.0; CD4+CD26- cells: 8,072/µl). The patient's medical history is significant for extensive comorbidities, including coronary triple-vessel disease treated with quintuple coronary artery bypass grafting, arterial hypertension, type II diabetes mellitus, atrial fibrillation, and a history of splenectomy.Due to the complex internistic profile, Extracorporeal Photopheresis (ECP) was initiated in 09/2023. Attempts with Bexarotene in 03/2025 were discontinued due to gastrointestinal intolerance (nausea/vomiting). Despite ECP, the disease progressed with increasing leukocytosis (33,530/µl) and suspected nodal involvement in PET-CT (08/2025), although histopathology of an inguinal lymph node primarily showed dermatopathic changes. Given the persistent leukemic burden, systemic therapy with the anti-CCR4 monoclonal antibody Mogamulizumab was indicated in 10/2025. Following the first dose of Mogamulizumab, the patient developed severe Tumor Lysis Syndrome (TLS), resulting in acute renal failure and life-threatening hyperkalemia (7.3 mmol/l). The patient required transfer to the intensive care unit for stabilization and fluid substitution. Following successful management of the renal function and electrolyte levels, a therapeutic re-challenge with Mogamulizumab was performed. To mitigate further risks, a premedication protocol (Paracetamol, Metoclopramide, Methylprednisolone, and Clemastine) was implemented alongside a reduced infusion rate. The second administration of Mogamulizumab was completed without acute toxicity or recurrence of TLS. The patient remained in a stable general condition post-infusion. Notably, he showed an excellent clinical response to the therapy, characterized by a rapid reduction in leukemic blood involvement and improvement of cutaneous symptoms.

Conclusion

This case highlights the critical need for high-vigilance monitoring when initiating Mogamulizumab in patients with high tumor burden. TLS and acute renal failure, though rare, are life-threatening risks requiring rapid interdisciplinary management. Our experience demonstrates that a modified administration protocol can facilitate the safe continuation of essential immunotherapy even after severe initial adverse events, preserving the opportunity for a superior therapeutic response.

POWERED BY M-ANAGE.COM

EA DV CONGRESS
VIENNA
30 SEP - 3 OCT 2026

Abstract N°: 700

Unusual Congenital Amelanotic Spitzoid Neoplasm With Intralesional Heterogeneity Across the Malignant Spectrum

Carol Estefania Marquez Maldonado*[1, 2], Guadalupe Maldonado Colin[2, 3], Brenda Hermosillo[4], Margarita Eligio Angeles[3], Sonia Toussaint Caire[4], Lucia Achell Nava[3]

[1] Centro Medico Nacional 20 de Noviembre, Universidad Nacional Autónoma de México, UNAM, Ciudad de México, Mexico
[2] Universidad Nacional Autónoma de México, Ciudad de México, Mexico
[3] Centro Medico Nacional 20 de Noviembre, Ciudad de México, Mexico
[4] Hospital General Doctor Manuel Gea González, Ciudad de México, Mexico

Introduction

Spitzoid melanocytic neoplasms represent a biologic continuum ranging from benign Spitz nevi to melanoma, often posing significant diagnostic challenges, particularly in pediatric patients. Lesions classified as melanocytic tumors of uncertain malignant potential (MELTUMP) reflect true biologic ambiguity rather than diagnostic limitation. Amelanotic congenital melanocytic lesions are uncommon and may further obscure clinical recognition and delay diagnosis.

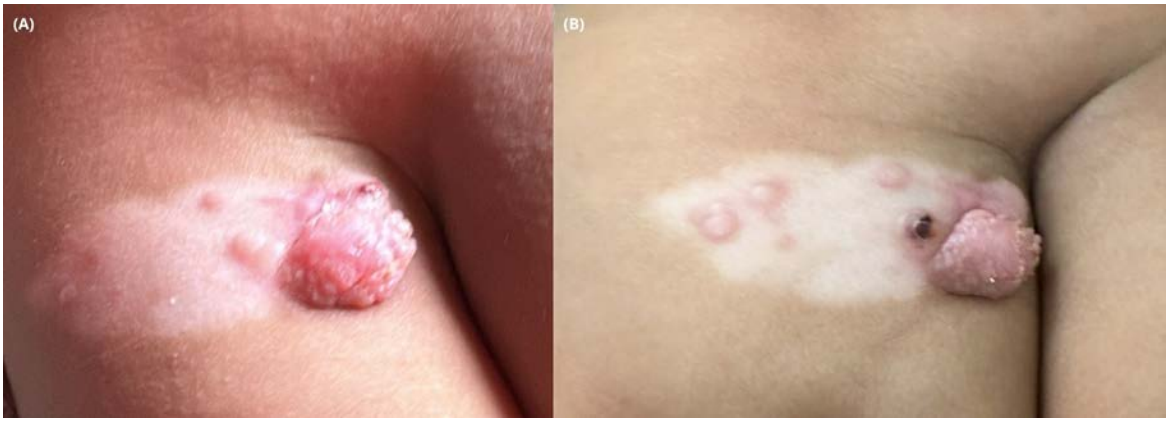

Figure 1. Clinical presentation. (A) Congenital hypopigmented patch (5 cm) on the left gluteal region with multiple erythematous dome-shaped nodules. (B) Close-up showing exophytic nodules and interval development of additional lesions after initial biopsy.

Case Presentation

An 8-month-old male presented with a congenital hypopigmented patch on the gluteal region. At 2 months of age, multiple erythematous, dome-shaped nodules progressively developed within the lesion (Figure 1).

Histopathologic evaluation of three nodules demonstrated marked intralesional heterogeneity (Figure 2). Findings ranged from a spindle-cell spitzoid proliferation with low mitotic activity to a highly atypical epithelioid lesion with increased cellularity, deep infiltration, and a mitotic rate of up to 13 mitoses/mm^2, raising concern for melanoma. Across specimens, partial maturation, absence of necrosis, and variable proliferative indices were observed. Immunohistochemistry showed diffuse SOX10 and MITF positivity, heterogeneous Ki-67 expression (<5% to 20%), and consistent loss of p16. S100, Melan-A, HMB-45, PRAME, BRAF, and ALK were negative or only focally

expressed. Independent dermatopathology evaluations yielded discordant diagnoses, including atypical Spitz tumor, high-risk MELTUMP, and melanoma-suspicious lesion. Staging studies were negative. Following a multidisciplinary tumor board discussion, including pediatric surgical oncology, the patient underwent wide local excision with sentinel lymph node biopsy. Histopathologic evaluation revealed no evidence of nodal metastasis. The patient remains disease-free on follow-up.

This case highlights three key challenges. First, amelanotic congenital melanocytic lesions are rare and may delay recognition of melanocytic origin. Second, eruptive nodular proliferations in infancy raise a critical differential diagnosis between benign proliferative nodules and malignant transformation. Third, and most importantly, marked intralesional heterogeneity within the spitzoid spectrum can lead to significant diagnostic discordance, even among expert dermatopathologists. The coexistence of benign, intermediate, and melanoma-suspicious features within the same lesion underscores the limitations of morphology-based classification. Loss of p16 expression and heterogeneous proliferative indices further support underlying biologic complexity. In this context, management should be guided by the highest-risk histopathologic component, and a multidisciplinary approach is essential. Molecular studies may provide additional diagnostic and prognostic clarification.

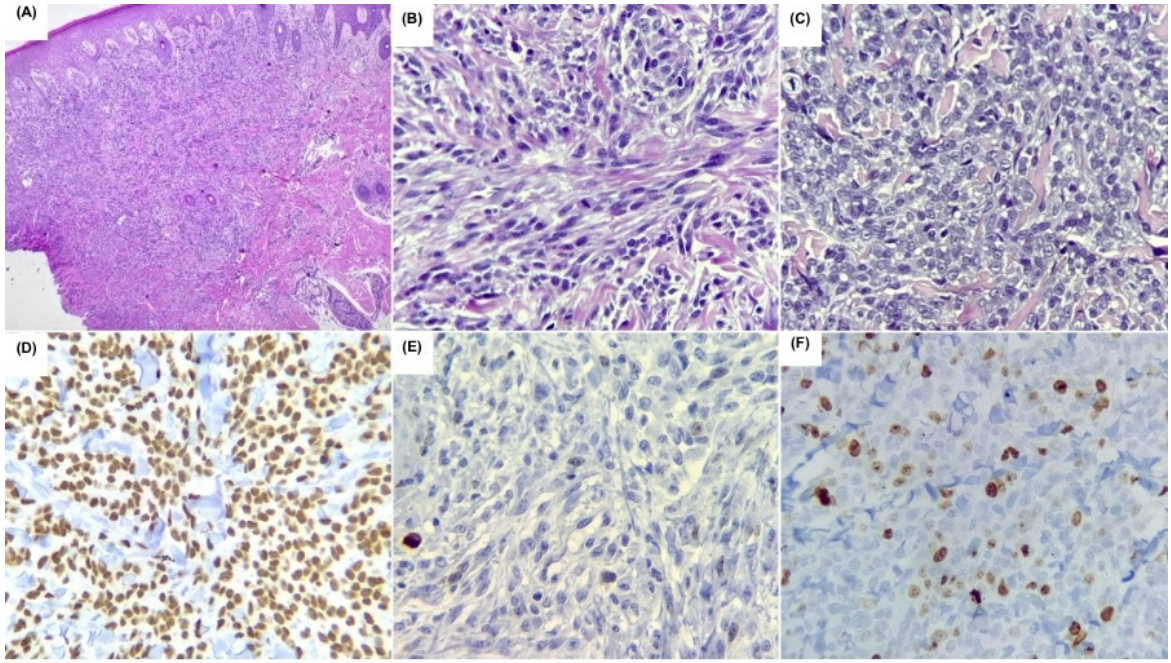

Figure 2. Histopathologic features. (A) Low-power view (4×) showing poorly circumscribed dermal melanocytic proliferation extending into the deep dermis. (B) Spindle-cell component (40×) with fascicular architecture and mild-to-moderate cytologic atypia. (C) Epithelioid component (40×) with increased cellularity and marked atypia. (D) SOX10 immunostain showing diffuse nuclear positivity. (E) Ki-67 demonstrating low proliferative index in spindle areas. (F) Ki-67 demonstrating increased proliferation (20%) in epithelioid areas.

Conclusion

Congenital amelanotic spitzoid lesions may present with eruptive nodules and marked intralesional heterogeneity spanning the full spectrum of malignant potential. Recognition of this pattern is critical, as it may result in diagnostic ambiguity and requires integrated clinicopathologic correlation and multidisciplinary management. Therapeutic decisions should prioritize the highest-risk component, with close long-term follow-up.

EADV CONGRESS
VIENNA
30 SEP - 3 OCT 2026

Abstract N°: 711

Vulvar granulomatous mycosis fungoides

Edwin Tan*[1], Deborah Smith[2], Debra Norris[3], Alexander Tedman[4], Kiarash Khosrotehrani[4], Dominic Wood[1]

[1] IQ Pathology, Brisbane, Australia
[2] Mater Pathology, Brisbane, Australia
[3] QML, Brisbane, Australia
[4] Queensland Institute of Dermatology, Brisbane, Australia

Introduction

Vulvar mycosis fungoides (MF) is exceptionally rare. To the best of our knowledge this is the first reported case of vulvar granulomatous MF.

Case Presentation

We describe a case of a 64-year-old lady with a 3 year history of scaly, eczematous swelling of the vulva. Initial biopsies showed granulomatous inflammation with a differentials that included infection, Crohn's disease and sarcoidosis. The lesion gradually spread to the perineum, buttock and upper gluteal cleft, became indurated and ulcerated. Pendulous skin was absent. Her extensive investigations included a normal serum ACE, microbiological investigations, radiology and colonoscopy. Subsequennt incisional biopsy showed confluent interstitial, perivascular and periadnexal non-necrotizing granulomas extending through the dermis into the subcutis. There were multinucleated giant cells and scant lymphocytic cell infiltrate with minimal cytological atypia. There was no epidermotropism, folliculotropism or syringotropism. The lymphoid infiltrate was predominantly CD4 T cells with no loss of CD2, CD3 and CD5, but complete loss of CD7. Monoclonality was proven with T-cell gene rearrangement studies. The patient's lesions responded well to 10 cycles of 20Gy VMAT radiotherapy.

Conclusion

Granulomatous MF lacks specific clinical features. There may be no prominent epidermotropism or minimal cytological atypia, Furthermore, the granulomatous component may obscure the lymphomatous component. The differential to consider is granulomatous slack skin syndrome, a rare variant of MF characterised by pendulous skin folds in flexural areas and histologically indistinguishable from granulomatous MF. In addition, early treatment may arrest the development of hanging skin folds. This case highlights the need to consider lymphoma in granulomatous vulvar lesions.

EADV CONGRESS
VIENNA
30 SEP - 3 OCT 2026

Abstract N°: 725

PRESSURE-INDUCED ISCHEMIC FASCIITIS: AN UNCOMMON CAUSE OF SOFT TISSUE MASS

Pablo Recalde*[1], Ana Sanchez Moya[1], Natalia Aranda[1], Angel Romo[1], Jorge Martinez[1], Blas Gomez[1], Javier Moreno[1], Paula Blazquez[1], Lucia Florez[1], Laura Fernandez[1]

[1] Complejo Hospitalario Universitario de Toledo, Toledo, Spain

Introduction

Ischemic pressure fasciitis is a rare pseudosarcomatous reactive proliferation of fibroblasts and myofibroblasts, typically developing over bony prominences in elderly or immobile patients. Clinically, it presents as one or multiple subcutaneous masses, sometimes ulcerated, with a tumor-like appearance and slow growth in pressure-prone areas. Definitive diagnosis relies on histopathological examination, which characteristically shows central fibrinoid necrosis and cystic degeneration surrounded by granulation tissue, vascular proliferation, and reactive fibroblasts without significant atypia or mitotic activity. Immunohistochemistry usually demonstrates focal positivity for smooth muscle actin and desmin, and negativity for S-100 and cytokeratins, supporting its fibroblastic/myofibroblastic origin. Management ranges from conservative measures, including local wound care and pressure relief, to surgical excision in selected cases.

Case Presentation

We report two cases of ischemic pressure fasciitis in which malignancy needed to be excluded. The first case involved a 93-year-old man with no prior oncological history who presented with two painful nodules in the lumbosacral region, showing an indurated erythematous base, central ulceration, and atypical vessels on dermoscopy. The second case concerned an 89-year-old institutionalized woman with a progressively enlarging ulcerated lesion on the right costal area, adjacent to a previous rib fracture site with radiological evidence of callus formation. The lesion showed firm consistency and deep adherence, noticeable during respiratory movements. Due to clinical suspicion of malignancy, diagnostic biopsies were performed in both cases. Histopathological examination revealed ischemic changes and fat necrosis without evidence of infiltrative carcinoma. Both specimens showed chronic granulomatous inflammation surrounding adipocytic vacuoles, areas of hypocellular fibrosis, and proliferation of capillary vessels without atypia, with a low Ki-67 index, consistent with ischemic pressure fasciitis. A conservative approach was adopted, including local wound care, frequent repositioning, and pressure offloading. Follow-up showed marked clinical improvement in both patients, with reduction in size, erythema, pain, and inflammation, and complete re-epithelialization.

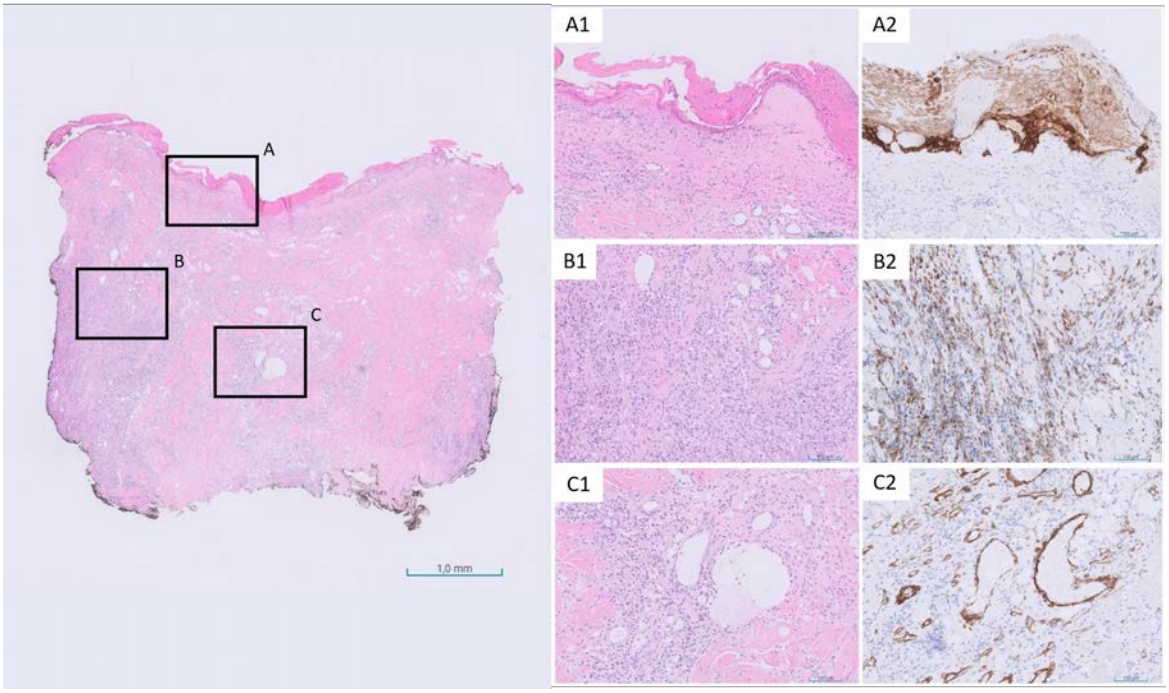

Excisional biopsy of a presacral skin lesion showing ischemic changes and fat necrosis (left panel). Focal epidermal ulceration is observed (A1), with no evidence of infiltrative carcinoma on CKAE1/AE3 immunostaining (A2). The dermis and subcutaneous tissue show extensive chronic granulomatous inflammation surrounding adipocytic vacuoles (B1), positive for CD68 on immunohistochemistry (B2), along with areas of hypocellular scar-like fibrosis. A proliferation of endothelial capillaries without atypia is also noted (C1), with pericytic actin expression (C2) and a low Ki-67 proliferation index.

Conclusion

Ischemic pressure fasciitis is an underrecognized entity that should be considered in the differential diagnosis of tumor-like lesions suggestive of angiosarcoma or squamous cell carcinoma, particularly in elderly or immobilized patients. Histopathological confirmation is essential to exclude malignancy. Although surgical excision has been frequently reported, a conservative approach based on local care and pressure relief may represent a valid management option, as supported by our cases and previous reports, and should be carefully considered given that these patients are often frail and may not be optimal candidates for surgery. While no cases of malignant transformation have been documented, the limited available data highlight the need for larger series and longer follow-up to better define its natural history and optimize management strategies.

EA DV CONGRESS
VIENNA
30 SEP - 3 OCT 2026

Abstract N°: 731

Artificial Intelligence–Assisted Dermoscopic Diagnosis of Skin Cancer: A Combined Segmentation and Classification Approach

Gaurav Sharma[1], Priyanka Karadia*[2], Sumit Kalra[1]

[1] Indian Institute of Technology Jodhpur, JODHPUR, India
[2] ALL INDIA INSTITUTE OF MEDICAL SCIENCES, JODHPUR, INDIA, JODHPUR, India

Introduction

Early detection of skin cancer is critical for reducing morbidity and mortality, yet diagnostic accuracy may be limited by variability in lesion morphology and access to expertise. Artificial intelligence (AI)–based tools offer potential support for rapid and reliable diagnosis.
Objective- To develop and evaluate a deep learning–based framework combining lesion segmentation and classification for automated detection of common skin cancers using dermoscopic images.

Materials and Methods

A dataset of 1,223 dermoscopic images representing four diagnostic categories—basal cell carcinoma, dermatofibroma, melanoma, and seborrhoeic keratosis—was analyzed. Lesion segmentation was performed using the YOLOv8n model with polygon-based annotations to delineate regions of interest. Subsequently, classification was conducted using three convolutional neural network architectures: ResNet50, ResNet101, and ResNet152. Models were trained and tested across multiple image resolutions (100×100 to 534×534 pixels). Performance was assessed using accuracy, precision, recall, F1-score, and confusion matrix analysis.

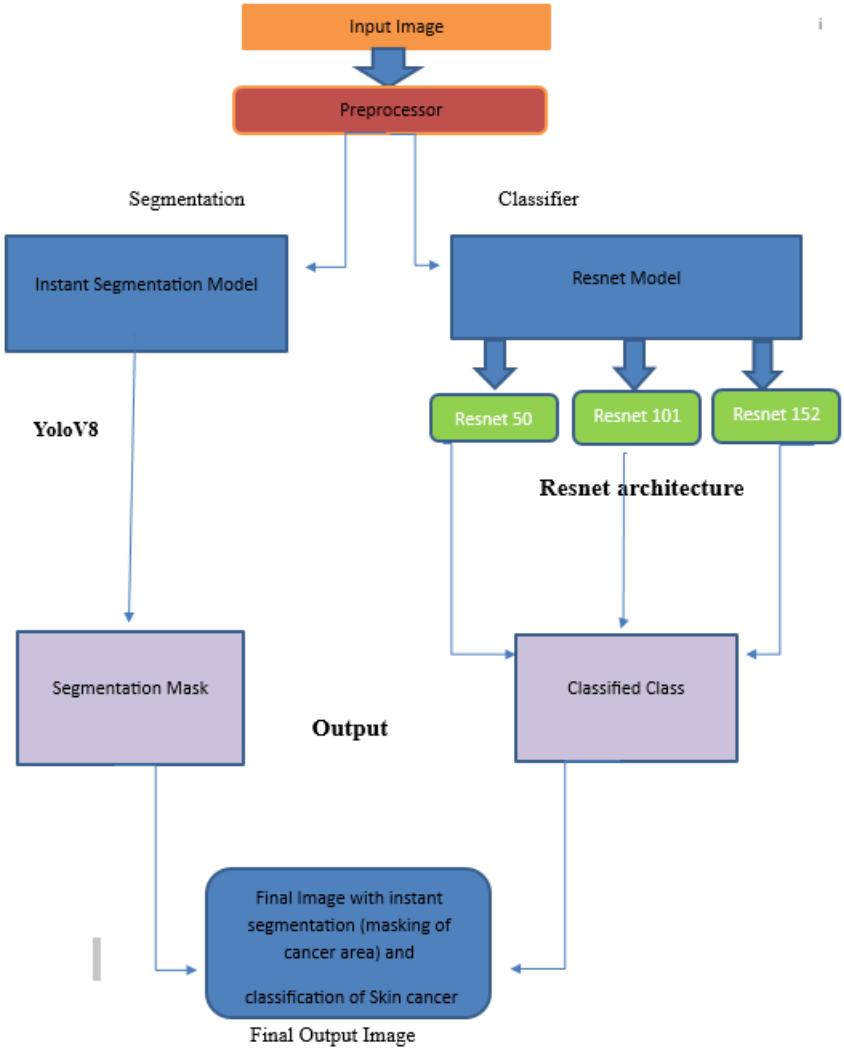

flowchart showing the process of data segmentation and annotations

Results

Across 15 model configurations, ResNet50 consistently demonstrated superior classification performance compared to deeper architectures (ResNet101 and ResNet152), with higher accuracy and stable performance across varying image resolutions. Integration of YOLOv8-based segmentation improved lesion localization and contributed to enhanced classification outcomes.

Conclusions

A combined segmentation–classification framework using YOLOv8 and ResNet architectures provides an effective, non-invasive approach for automated skin cancer detection. This AI-based system has potential clinical utility as a decision-support tool for early skin cancer screening, particularly in resource-limited settings.

Relevance to Dermatology

This study has direct clinical relevance to dermatology by addressing a key challenge in everyday practice—early and accurate detection of skin cancer. Dermoscopic evaluation is highly operator-dependent and requires significant expertise; the proposed AI-based framework serves as a decision-support tool that can augment diagnostic accuracy, particularly for non-expert clinicians and in primary care settings.By integrating lesion segmentation with classification, the model closely mirrors the dermatological diagnostic workflow, where lesion morphology, borders, and color patterns are critically assessed. The ability of the system to reliably differentiate between common entities such as melanoma, basal cell carcinoma, and benign lesions like seborrhoeic keratosis and dermatofibroma enhances its applicability in triaging suspicious lesions and reducing unnecessary biopsies.In

resource-limited settings, where access to trained dermatologists and dermoscopy may be restricted, such AI tools can facilitate early screening and timely referral, potentially improving patient outcomes. Additionally, the demonstrated feasibility of deploying this model on mobile platforms supports its use in teledermatology and community-based screening programs.Overall, this approach aligns with the growing role of artificial intelligence in dermatology by improving diagnostic efficiency, standardizing assessments, and expanding access to skin cancer care.

EADV CONGRESS
VIENNA
30 SEP - 3 OCT 2026

Abstract N°: 733

LC-OCT in diagnosis and subtyping of BCC – a preliminary data from Polish single-centre study.

Aleksandra Anderson*[1], Piotr Konopelski[1], Aleksandra Kuchnicka[1], Joanna Czuwara[1], Lidia Rudnicka[1]

[1] Department of Dermatology, Medical University of Warsaw, Warsaw, Poland

Introduction
Non-melanoma skin cancers (NMSC) account for over 95% of all skin cancers, with basal cell carcinoma (BCC) being the most common subtype. The management of BCC depends on the tumor subtype. Surgical excision remains the first-line treatment; however, in patients with superficial BCC not amenable to surgery, non-surgical modalities may be considered. Several dermoscopic features have been described to predict tumor subtype, nonetheless there is not one specific feature which can definitely predict it. Line-field optical coherence tomography (LC-OCT) has recently emerged as a novel non-invasive skin imaging technique and has shown superiority over dermoscopy in sensivity, specificity, diagnostic accuracy for NMSC. The aim of the study was to assess the diagnostic accuracy of LC-OCT in the diagnosis and subtyping of BCC and NMSC.

Materials and Methods
In this prospective study, we analysed 172 lesions from 122 patients with suspected NMSC, referred for surgical excision or punch biopsy between June 2025 and April 2026. The lesions suspected for NMSC were assessed in dermoscopy independently by two doctors with over 3 years of experience and subsequently referred for LC-OCT examination. LC-OCT was performed by one of two physicians, with over 3 years of experience. Due to the dermoscopy-guided nature of LC-OCT, examiners were not blinded to dermoscopic findings. Criteria for LC-OCT examination for NMSC diagnosis and BCC subtyping were adapted from study by Mtimet et al. published in JEADV in 2025. Dermoscopic and LC-OCT findings were compared with histopathology as the reference standard, and analyzed using McNemar's test in STATA software. A p-value <0.05 was considered statistically significant.

Results
A total of 91 lesions from 66 patients with available histopathological reports were included in the final analysis. The mean patient age was 75.5 years, with a female predominance (58%). Fifteen patients had more than one lesion qualified for surgical removal. The most common lesion location was the face (48), followed by the trunk (30), extremities (9), and scalp (4). BCC was the most frequent histopathological diagnosis (72 lesions), followed by squamous cell carcinoma in situ (10) and actinic keratosis (4). The diagnostic accuracy for NMSC was 71.4% for dermoscopy and 93.4% for LC-OCT ($p<0.001$). For BCC alone, diagnostic accuracy increased to 80.5% for dermoscopy and 98.6% for LC-OCT ($p=0.001$). In BCC subtyping, LC-OCT significantly outperformed dermoscopy (95.8% vs. 52.7%, $p<0.001$). Additionally, LC-OCT detected multicomponent BCCs in 12 out of 13 cases, including aggressive (infiltrative) components in 6 cases.

Conclusions
Our preliminary results indicate that LC-OCT significantly improves the diagnosis of NMSC, particularly BCC, and enhances the prediction of tumor subtypes, especially aggressive variants. However, the study is limited by a small sample size and lack of blinding.

EADV CONGRESS
VIENNA
30 SEP - 3 OCT 2026

Abstract N°: 738

Angioimmunoblastic T-Cell Lymphoma Initially Presenting with Generalized Morbilliform Rash and Facial Edema

Tae Young Han*[1], Yun Jeong Choi[1], Jung Min Lee[1], June Lee[1], Jae Eun Choi[1]

[1] Department of Dermatology, Nowon Eulji Medical Center, Eulji University, Seoul, Korea, Rep. of South

Introduction

Angioimmunoblastic T-cell lymphoma (AITL) represents a distinct clinicopathologic entity within the spectrum of peripheral T-cell lymphomas, characterized by its aggressive behavior and T follicular helper (TFH) cells origin. Typical systemic manifestations include lymphadenopathy, constitutional symptoms, immune dysregulation, and polyclonal hypergammaglobulinemia. Cutaneous involvement occurs in approximately 50% of patients and may precede systemic manifestations in some cases. The skin lesions of AITL are highly polymorphic and often mimic benign dermatoses or drug eruptions, which frequently leads to diagnostic delay.

Case Presentation

A 68-year-old man presented with a 3-month history of asymptomatic, erythematous confluent macules and patches on the trunk and extremities; initial evaluations ruled out causative agents for drug eruption, and a primary skin biopsy showed only nonspecific superficial perivascular lymphohistiocytic infiltration. Following the rapid onset of high-grade fever, pruritus, and progression to near-erythroderma with facial edema, a second skin biopsy revealed dense perivascular infiltration of atypical pleomorphic lymphocytes positive for CD3, CD4, and TFH-associated markers PD-1 and BCL-6. Subsequent contrast-enhanced CT identified generalized lymphadenopathy, and an excisional cervical lymph node biopsy confirmed Ann Arbor stage IV angioimmunoblastic T-cell lymphoma, characterized by diffuse architectural effacement, high endothelial venule proliferation, an expanded follicular dendritic cell meshwork, and neoplastic cells expressing CD3, CD4, PD-1, and BCL-6.

Conclusion

Our case emphasizes that in elderly patients presenting with persistent, treatment-refractory generalized skin eruptions accompanied by systemic symptoms such as fever and lymphadenopathy, AITL and other lymphomas should be strongly considered. Prompt systemic evaluation and timely lymph node biopsy are essential for early diagnosis and initiation of appropriate chemotherapy, which may improve clinical outcomes.

EA DV CONGRESS
VIENNA
30 SEP - 3 OCT 2026

Abstract N°: 741

CUTANEOUS METASTASIS FROM INVASIVE DUCTAL BREAST CARCINOMA PRESENTING AS CONTACT DERMATITIS: A CASE REPORT

Ozlem Sen*[1], Didem Dizman[1], Ozlem Su Kucuk[1], Cuyan Demirkesen[2]

[1] Bezmialem University Faculty of Medicine, Istanbul, Türkiye

[2] Acıbadem University, Pathology Department, Istanbul, Türkiye

Introduction

Cutaneous metastases (CM) occur in approximately 0.7–10.4% of patients with malignancies and account for about 2% of all skin tumors.Although often clinically suspected before biopsy,diagnosis can be challenging when lesions lack typical nodular or mass-like features,particularly in patients without a known primary malignancy.Breast cancer is the most common cause of CM in women,with an incidence of up to 23.9%.The most common presentation includes multiple,firm,painless nodules;however,papules,erysipelas-like lesions, and sclerotic plaques may also occur.These lesions may mimic benign dermatological conditions,leading to delayed or incorrect diagnosis.Therefore, metastatic disease should be considered in the differential diagnosis of atypical dermatological findings.Herein,we present a patient with breast implants who presented with contact dermatitis–like lesions and was subsequently diagnosed with cutaneous metastasis of invasive ductal breast carcinoma.

Materials and Methods

A 47-year-old woman presented with a two-year history of chest erythema and pruritus.Her history included breast implantation 10 years earlier and a 20 pack-year smoking history. The lesions were unresponsive to topical corticosteroids.Dermatological examination revealed an erythematous,infiltrative plaque in the intermammary region. Ultrasonography showed a 20×16 mm irregular,hypoechoic solid lesion in the left parasternal area,extending to the costochondral junction and subcutaneous tissue,suggesting bone invasion.Based on clinical and radiological findings,differential diagnoses included contact dermatitis,dermatofibrosarcoma protuberans, hidradenitis suppurativa, and non-melanoma skin cancer.Biopsy revealed cutaneous involvement of invasive ductal breast carcinoma.Immunohistochemistry was positive for CK7,GATA3,ER, and PR, and negative for CK20.Further evaluation showed HER2 membranous positivity with negative in situ hybridization and a Ki-67 index of 10%.PET-CT demonstrated a hypermetabolic lesion extending from the skin to the pectoral muscles and the upper inner quadrant of the left breast,with suspicious left axillary lymph nodes.No uptake was observed around the implants.Systemic chemotherapy(docetaxel,doxorubicin,cyclophosphamide)was initiated.After seven cycles,partial metabolic and anatomical regression was observed.The patient remains under oncological follow-up.

Results

CM are important prognostic indicators, often reflecting advanced-stage malignancy.Breast cancer is the most common cause in women and may present with a wide spectrum of clinical manifestations,including nodular,inflammatory,telangiectatic, and erysipelas-like variants.This clinical heterogeneity may mimic benign dermatological conditions and lead to delayed diagnosis.In our case, the contact dermatitis–like presentation contributed to this delay,consistent with previous reports.Although the chest wall is the most common site of CM,intermammary and parasternal lesions may be associated with direct extension or lymphatic spread.In this case, parasternal localization with pectoral muscle involvement suggested local invasion.Immunohistochemistry is essential for identifying tumor origin;CK7,GATA3,ER, and PR positivity supports a breast origin,while CK20 negativity aids in differential diagnosis.HER2 and Ki-67 are important prognostic markers; HER2 positivity with negative in situ hybridization may indicate borderline expression.No definitive association has been established

between silicone breast implants and breast carcinoma.However,implants may complicate radiological evaluation and obscure lesions,requiring additional imaging such as ultrasonography or MRI.This case highlights that seemingly benign dermatological lesions may conceal an underlying malignancy.

Conclusions

Although rare,CM presenting with contact dermatitis–like features should be considered,especially in persistent,treatment-resistant lesions.Early diagnosis and appropriate referral are crucial,as they directly impact prognosis.

EADV CONGRESS
VIENNA
30 SEP - 3 OCT 2026

Abstract N°: 746

Kaposi Sarcoma complicating corticosteroid immunosuppression for Leprosy reaction

Charlotte Muehlschlegel*[1, 2], Steve Walker[1, 3, 4]

[1] Hospital for Tropical Diseases, University College London Hospitals NHS Foundation Trust, London, United Kingdom, London, United Kingdom
[2] Internal Medicine, University College London Hospitals NHS Foundation Trust, London, United Kingdom, London, United Kingdom
[3] Faculty of Infectious and Tropical Diseases, London School of Hygiene and Tropical Medicine, London, United Kingdom, London, United Kingdom
[4] Department of Dermatology, University College London Hospitals NHS Foundation Trust, London, United Kingdom, London, United Kingdom

Introduction

Kaposi sarcoma (KS) is a malignant vascular tumour caused by human herpesvirus-8 (HHV-8). It is classified into epidemic (HIV-associated), endemic, classic, iatrogenic (immunosuppression-related), and KS in HIV-negative men who have sex with men (MSM). Increasing attention is being given to classification based on immunocompetency.

Case Presentation

A 55-year-old HIV-negative man from Colombia presented with several months of malaise and widespread erythematous plaques on the limbs and trunk. He received prolonged oral prednisolone for presumed vasculitis with partial response. A diagnosis of lepromatous leprosy with erythema nodosum leprosum (ENL) was made following skin biopsy. He was treated with 12 months antimicrobial therapy and high-dose prednisolone was continued. He developed new asymptomatic violaceous nodules on the plantar aspect of the left foot and right knee. Biopsy confirmed KS. Imaging showed no visceral involvement. ENL flared at prednisolone doses below 45 mg so thalidomide was started. The prednisolone was tapered over 7 weeks and the ENL remained well controlled on thalidomide. At oncology review 14 weeks after stopping prednisolone and 7 weeks after starting thalidomide the KS lesions had improved significantly and he was managed conservatively.

Conclusion

This case highlights the central role of immune dysregulation in KS; HHV-8 infection is necessary and host immune dysfunction is a key permissive factor. Epidemiological classifications may not fully reflect this.Whilst South America is not usually considered an endemic KS region, HHV-8 seroprevalence is high in some areas and may have led to additional risk. Prolonged systemic corticosteroid therapy was the most likely contributor, given the established association in iatrogenic KS and that withdrawal resulted in regression of the lesions. Thalidomide is likely to have contributed to improvement in this patient, with clinical trials and case reports suggesting its clinical utility against KS, likely through its anti-angiogenic effectsThis case underscores the need to consider KS in immunologically complex patients, including those with chronic infections. This may represent an under-recognised at-risk group and supports the need to classify KS by immunocompetency.

EADV CONGRESS
VIENNA
30 SEP - 3 OCT 2026

Abstract N°: 763

A Diagnostic Masquerade: Extranodal NK/T-Cell Lymphoma Presenting With Persistent Facial Edema

Kubra Cicek*[1], Leyla Huseynova Terzi[1], Arzu Saglam[2], Sibel Ersoy Evans[1], Sibel Dogan Gunaydın[1], Basak Yalici Armagan[1], Duygu Gulseren[1], Neslihan Akdogan[1]

[1] Department of Dermatology and Venereology, Hacettepe University School of Medicine, Ankara, Türkiye
[2] Department of Pathology, Hacettepe University, School of Medicine, Ankara, Türkiye

Introduction

Persistent facial edema represents a diagnostic challenge with a broad differential diagnosis including angioedema, inflammatory dermatoses, autoimmune diseases, infections and neoplastic disorders. Extranodal NK/T-cell lymphoma, nasal type, is a rare EBV-associated aggressive lymphoproliferative malignancy that may initially mimic inflammatory or autoimmune conditions, resulting in delayed diagnosis.

Case Presentation

A 40-year-old woman presented with a 6-month history of persistent malar and periorbital edema associated with proximal muscle weakness. She reported recurrent episodes of facial swelling during the previous year, oral aphthae, intermittent urticarial eruptions and significant weight loss. Repeated treatments with antihistamines and corticosteroids provided no sustained benefit. Evaluation for hereditary and acquired angioedema was unremarkable, with normal C1 esterase inhibitor function and negative genetic testing.

Autoimmune serology including ANA, ENA, anti-dsDNA and ANCA was negative. However, SAE1 positivity, elevated creatine kinase and lactate dehydrogenase levels, proximal muscle weakness and electromyographic myopathic findings raised suspicion for inflammatory myopathy. Muscle biopsy was non-diagnostic, while thigh MRI demonstrated panniculitis-like inflammatory lesions without definite myositis. FDG-PET showed increased uptake in the right triceps muscle. Based on the clinical and radiological findings, dermatomyositis was considered and treatment with prednisolone and mycophenolate mofetil was initiated, resulting in only transient improvement.

During follow-up, persistent EBV DNA positivity, pancytopenia, hyperferritinaemia, hypofibrinogenaemia and hypertriglyceridaemia suggested haemophagocytic lymphohistiocytosis/macrophage activation syndrome. Progressive facial edema, necrotic periocular lesions, oral ulcerations, erythematous plaques and panniculitis-like lesions subsequently developed. Infectious causes, including invasive fungal infection and necrotizing fasciitis, were excluded histopathologically and microbiologically.

Repeated deep biopsies demonstrated atypical lymphoid infiltrates extending from the dermis into the subcutaneous tissue with angiocentric and angioinvasive features accompanied by necrosis. Immunohistochemistry revealed diffuse positivity for EBER, CD2, CD3, TIA-1 and granzyme B, supporting the diagnosis of extranodal NK/T-cell lymphoma, nasal type. The patient was subsequently started on the SMILE chemotherapy regimen.

Conclusion

This case highlights extranodal NK/T-cell lymphoma as an important differential diagnosis in patients presenting with refractory facial/periorbital edema, particularly in the presence of EBV positivity, HLH features, progressive necrotic lesions or atypical inflammatory findings. Early repeated deep biopsies and close clinicopathological correlation are essential to avoid diagnostic delay in aggressive NK/T-cell lymphomas with atypical cutaneous presentations.

EADV CONGRESS
VIENNA
30 SEP - 3 OCT 2026

Abstract N°: 766

Topical chlormethine normalizes skin barrier dysfunction and lipid alterations in early-stage mycosis fungoides

Catherine Mergen*[1], Selinde Wind[2], Elise Beljaards[2], Rianne Rijneveld[3], Mick van Schaick[1], Joke Bouwstra[1], Koen Quint[2], Maarten Vermeer[2], Robert Rissmann[1, 2, 3], Jannik Rousel[3]

[1] Leiden Academic Centre for Drug Research, Leiden, Netherlands
[2] Leiden University Medical Center, Leiden, Leiden, Netherlands
[3] Centre for Human Drug Research, Leiden, Netherlands

Introduction
Mycosis fungoides (MF) is the most common subtype of primary cutaneous T-cell lymphoma, in which malignant T lymphocytes infiltrate the skin, resulting in patches and plaques with a reduced barrier function. The skin barrier function depends on the stratum corneum lipid matrix, which is largely composed of ceramides. Alterations in the ceramide profile have been associated with the impaired barrier function in benign inflammatory skin diseases and might also be an underlying factor in MF. This study aims to characterize the stratum corneum ceramide profile and barrier function in lesional and non-lesional skin of MF patients compared to healthy volunteers, and to assess the effect of treatment with chlormethine gel.

Materials and Methods
21 early-stage MF patients and 10 healthy volunteers participated in the study. Ceramides were collected by tape stripping at baseline and after 16 weeks of treatment and analyzed using liquid chromatography-mass spectrometry. Barrier function was assessed by measuring transepidermal water loss.

Results
The ceramide profile of lesional skin in MF was significantly different from non-lesional and healthy skin and correlated with the reduced barrier function. Specifically, lesional skin showed an altered ceramide subclass composition and reduced average ceramide chain length. These changes were partially normalized with chlormethine treatment. Importantly, ceramide characteristics correlated with barrier function and clinical lesional severity over time, highlighting their interdependence.

Conclusions
To conclude, MF lesions exhibit a distinct and altered ceramide profile compared to non-lesional and healthy skin, which can partially be restored with topical chlormethine treatment.

EADV CONGRESS
VIENNA
30 SEP - 3 OCT 2026

Abstract N°: 776

Diagnostic Utility of Acetic Acid–Induced Acetowhite Change in Suspected Penile Intraepithelial Neoplasia

Jawwad Mihran Haider*[1], Syed Kamran[1], Calum Clark[1], Zhi-Yang Low[1]

[1] St George's Hospital, London, United Kingdom

Introduction
Penile intraepithelial neoplasia (PeIN) is a premalignant lesion with clinical features that often overlap with benign inflammatory dermatoses. Although biopsy remains the diagnostic gold standard, topical acetic acid application producing an acetowhite reaction is sometimes used to aid clinical assessment. This study evaluated the diagnostic utility of acetic acid-induced acetowhite change in identifying penile dysplasia or PeIN.

Materials and Methods
A retrospective observational cohort study was conducted at a tertiary penile cancer referral centre. Consecutive patients referred with suspicious erythematous penile lesions between September 2022 and September 2025 who underwent both topical acetic acid application and penile biopsy were included. Acetowhite responses were categorised as negative, mildly positive, or strongly positive based on contemporaneous clinical documentation. Histopathological diagnosis from biopsy specimens served as the reference standard. The association between acetowhite response and histological outcome was assessed using chi-squared analysis.

Results
Fifty-two patients were included. Histopathology demonstrated benign findings in 34 patients, PeIN in 10, mild dysplasia in 1, and moderate-severe dysplasia in 7. Acetowhite change was observed across both benign and dysplastic lesions. No significant association was identified between the presence or degree of acetowhite change and histologically confirmed dysplasia or PeIN ($p = 0.686$).

Conclusions
Acetic acid-induced acetowhite change did not reliably predict the presence of penile dysplasia or PeIN. These findings suggest that acetic acid testing has limited diagnostic utility in the assessment of suspicious penile lesions and should not influence decisions regarding biopsy, which remains essential for accurate diagnosis.

EADV CONGRESS
VIENNA
30 SEP - 3 OCT 2026

Abstract N°: 803

Subcutaneous panniculitis-like T-cell lymphoma in multiple sclerosis on rituximab: a report of two cases

Silvia Abelenda-Marquina*[1], Arantxa Muñiz de Lucas[1], Luis Perna-Monroy[2], Iván Rodrigo Díaz[1], Miriam Cruz-Gómez[1], Ana del Rocío Gamero Rodríguez[1], Javier Alcántara González[1], Tania Marusia Capusan[1], Raquel Cabana Navia[1], thomas stefan akel oberpaur[1], Silvia Manso[1], Mirko Roedig[1], Clara Martinez-Jaimes[1], Maria Sanchez-Largo[1]

[1] Dermatology Department, Hospital Universitario De Torrejón, Torrejón de Ardoz, Spain
[2] Pathology Department, Hospital Universitario De Torrejón, Torrejón de Ardoz, Spain

Introduction
Subcutaneous panniculitis-like T-cell lymphoma (SPTCL) is an uncommon primary cutaneous neoplasm that can mimic inflammatory dermatoses, leading to diagnostic delay. We present two cases of SPTCL in patients with multiple sclerosis (MS) receiving long-term rituximab therapy.

Case Presentation
The first case was a 35-year-old woman with MS treated with rituximab who, in 2024, developed edematous plaques and generalized cutaneous induration predominantly affecting the extremities. A skin biopsy was performed and during the diagnostic work-up she presented hypoalbuminemia, sensorineural hearing loss, hemolytic anemia, and severe hepatitis, requiring multiple hospital admissions and initially receiving alternative diagnoses. Skin biopsy revealed a monomorphic infiltrate of small lymphocytes in the hypodermis with characteristic adipocyte "rimming". Immunohistochemistry showed CD3+, CD8+ cells expressing cytotoxic markers (granzyme, TIA-1, and perforin) and negative for CD4, CD56 and CD30. Molecular analysis demonstrated monoclonal rearrangement of TCR gamma and beta, confirming the diagnosis of SPTCL. A partial response was achieved with corticosteroids, methotrexate and mycophenolate, followed by relapses and progression to fulminant hepatic failure due to lymphoproliferative infiltration.
The second case was a 35-year-old woman with MS, also receiving rituximab, who in 2025 developed annular, erythematous, indurated and pruritic plaques on the lower limbs and abdomen, associated with fever and visible inguinal lymphadenopathies. Morphea was initially suspected although a lymphoproliferative disorder could not be excluded. The skin biopsy showed histological and immunophenotypic findings consistent with SPTCL. Due to suspected hemophagocytic syndrome, CHOEP chemotherapy was initiated, with initial clinical improvement. However, the patient subsequently developed fulminant hepatic failure with rapidly progressive clinical deterioration, and a fatal outcome.

Conclusion
In conclusion, these cases highlight the diagnostic challenge of SPTCL, particularly when presenting as inflammatory panniculitis-like lesions. They underscore the importance of early deep skin biopsy with immunohistochemical and molecular studies, as well as prompt therapeutic intervention. The potential association between rituximab, MS, and SPTCL warrants further investigation.

EADV CONGRESS
VIENNA
30 SEP - 3 OCT 2026

Abstract N°: 810

Rhenium-188 skin cancer therapy (SCT) European Subanalysis: Two-year efficacy and safety from a prospective multicentre phase IV study

Julia Tietze[1], Siroos Mirzaei[2], Nicola Mulholland[3], Martin Heuschkel[1], Giuseppe Cardaci[4], Angela Hong[5], Mike Sathekge[6], Kgomotso Mokoala[6], Siddhartha Baxi[7], Gerhard Dahlhoff*[8]

[1] University Medical Center Rostock, Rostock, Germany
[2] Institute of Nuclear Medicine with PET-Center, Vienna, Austria
[3] Kings College Hospital NHS Foundation Trust, London, United Kingdom
[4] Hollywood Private Hospital, Perth, Australia
[5] GenesisCare, North Shore Health Hub, St Leonards, Australia
[6] NuMeRI, University of Pretoria and Steve Biko Academic Hospital, Pretoria, South Africa
[7] GenesisCare, John Flynn Hospital, Tugun, Australia
[8] Oncobeta GmbH, Munich, Germany

Introduction

Non-Melanoma skin cancers (NMSC) are the most common malignancies worldwide. While surgical excision, including micrographic surgery, achieves clearance rates exceeding 95%, treatment may be associated with disfigurement, functional morbidity, or may not be appropriate in cases of multiple lesions, anatomically difficult locations, due to patient comorbidities or preference. Rhenium-188 Epidermal radionuclide therapy has been used clinically for NMSC since 2008, with retrospective series, pooled analyses, and prospective studies reporting high local control and favourable cosmetic outcomes. The present study built on these findings by evaluating efficacy, patient quality of life and safety in selected NMSC lesions.

Materials and Methods

This prospective, multicentre, single-arm phase IV study enrolled 187 adults with 1-3 biopsy-proven NMSC lesions ≤3mm deep with ≤8cm² area. The European Continent sub-analysis included 85 patients (Austria: 30 patients, Germany: 32 patients, United Kingdom: 23 patients). Patients received a single outpatient treatment with rhenium-188 therapy delivering 50 Gy to the deepest point of the lesion. Clinical response was assessed using modified RECIST criteria. Secondary endpoints included quality of life, treatment comfort, cosmesis and safety.

Results

The preliminary results show 94.7% evaluable lesions (123 of 131 BCC tumours and 39 of 40 SCC tumours) in overall study achieved a complete response at 24 months*. The most common 24-month CTCAE graded Adverse Events of Interest were hypopigmentation (Grades 1/2: 58%/5%); telangiectasia (Grade 1: 15%); alopecia (Grades 1/2: 10.4%/0.9%) and induration (Grades 1/2: 9.6%/0.9%). Twelve Grade 3/4 events occurred at earlier time points, but none persisted past 6 months. Quality of life improved by a mean 7.92 points in SKINDEX-16 scores from baseline. No patients reported pain during procedure. The patient- and clinician-reported cosmesis averages cores (10-point scale) were 8.5 and 7.9, respectively. In the preliminary results of European Continent sub-analysis, 97.0% of 67 evaluable lesions achieved complete response at 24 months (Austria: 95.2%, Germany 97.0%, United Kingdom 100.0%)*. The most common 24-month CTCAE graded Adverse Events of Interest in European Continent

sub-analysis were Grade 1 of hypopigmentation (67.5%), telangiectasia (17.5%); alopecia (15.0%) and induration (12.5%). No Grade 2 or 3 events at 24 months. Grade 3 event (ulceration) occurred in 1 European patient (United Kingdom) at 6 months, but it did not persist to 12 months.
**Global EPIC-Skin longitudinal response analyses are undergoing final harmonisation and validation ahead of manuscript submission*

Conclusions

Rhenium-188 therapy demonstrates durable efficacy at 24 months in appropriate NMSC lesions. Follow-up shows a stable safety profile, without evidence of accumulating late skin toxicity, supporting consideration of Rhenium-188 therapy as a non-surgical option for selected superficial NMSC in patients where surgery is less desirable.

EADV CONGRESS
VIENNA
30 SEP - 3 OCT 2026

Abstract N°: 815

Palmoplantar Mycosis Fungoides: Clinical, Dermoscopic and Histopathological Features in Five Patients

Eya Bouzaien*[1], Anissa Zaouak[1], Raja Jouini[2], Imen Hlel[2], Houda Hammami[1]

[1] Dermatology Department, Habib Thameur Teaching Hospital, Tunis, Tunisia
[2] Anatomopathology Department, Habib Thameur Teaching Hospital., Tunis, Tunisia

Introduction

Acquired palmoplantar keratoderma (PPK) is a rare presentation of mycosis fungoides (MF). The diagnosis may be confused with benign dermatosis such as palmoplantar psoriasis (PPP) and palmoplantar eczema (PPE). We describe clinical, dermoscopic, and histological features of five cases of palmoplantar MF (PPMF).

Case Presentation

We report a series of five patients diagnosed with PPMF. Patients' ages ranged from 38 to 80 years. Three patients had a previous diagnosis of MF with a partial response of extra-palmar lesions, while two patients presented with isolated, long-standing PPK. Clinically, all patients exhibited bilateral, well-demarcated PPK involving the entire palmar and plantar surfaces, psoriasiform and fissured in four cases and dyshidrosiform in one case. Dermoscopy revealed a pale pink background with an erythematous parallel ridge pattern. The vascular pattern consisted of irregularly distributed dotted vessels, associated with rhagades, purpuric dots, pigmented patches, orange-yellow areas, and orthogonal white structures, with preservation of dermatoglyphic architecture. Given the therapeutic resistance of palmoplantar lesions, skin biopsies were performed in all patients. Histopathological examination demonstrated a moderate dermal infiltrate of atypical lymphocytes with epidermotropism, associated with epidermal hyperplasia, acanthosis, exoserosis, and parakeratosis. Immunohistochemical analysis showed a predominance of CD3+ and CD4+ T lymphocytes, confirming the diagnosis of MF.
PPMF is a rare entity that poses a significant diagnostic challenge because of its close clinical resemblance to common inflammatory dermatoses, particularly PPP and eczema. Clinical evaluation alone is insufficient, and histopathological confirmation remains mandatory, although palmoplantar biopsy may be technically challenging. Dermoscopy may provide valuable noninvasive diagnostic clues, especially in isolated or treatment-resistant cases. Dotted vessels and a reddish/pinkish background are observed in PPP. However, in PPP, the vessels are typically evenly distributed. Irregularly distributed dot vessels on a yellow/brown background are suggestive of eczema. Thus, irregular dotted vessels on a reddish/pinkish background would be suggestive of PPMF. Other aspects, described in cutaneous MF, were noted in our patients: purpuric dots, pigmented patches, and orange-yellow patches.

Conclusion

Recognition of dermoscopic and histopathological patterns is crucial to differentiate PPMF from more common chronic inflammatory dermatoses, guiding appropriate management and preventing diagnostic delays.

EA DV CONGRESS
VIENNA
30 SEP - 3 OCT 2026

Abstract N°: 823

Pembrolizumab for the Treatment of Gorlin-Goltz Syndrome in a Pediatric Patient: A Case Report

Analy Gomez-Picos*[1], Guadalupe Maldonado-Colin[1], Lucia Achell-Nava[1], Dolores Arellano-Vivero[1]

[1] ISSSTE Centro Medico Nacional 20 de Noviembre, UNAM, Mexico City, Mexico

Introduction

Gorlin-Goltz syndrome (GGS) is a rare genodermatosis caused by mutations in the PTCH1 gene, leading to constitutive activation of the Hedgehog signaling pathway and the development of multiple neoplasms and skeletal abnormalities. Management remains challenging in pediatric patients, as first-line therapies such as vismodegib are associated with irreversible growth plate toxicity. We report the successful use of pembrolizumab as a first-line systemic treatment in a 6-year-old patient, supporting immunotherapy as a potential alternative in pediatric GGS.

Case Presentation

A 6-year-old male presented with a 4-year history of asymptomatic, disseminated verrucous lesions involving the head, neck, anterior trunk, and all four extremities. Physical examination was notable for macrocephaly and frontal bossing. Dermoscopy revealed non-melanocytic lesions characterized by brown concentric structures, spoke-wheel areas, and arborizing vessels. Histopathological analysis of a skin biopsy confirmed Basal Cell Carcinoma (BCC). Additionally, a head CT scan revealed an odontogenic keratocyst. Based on this constellation of clinical, radiographic, and histopathological findings, a diagnosis of Gorlin-Goltz Syndrome was established. Systemic treatment with vismodegib was deferred because of the patient's age. Consequently, he was initiated on topical imiquimod 5% cream and subsequently 5-fluorouracil (5-FU) cream; however, he showed a poor clinical response to these topical therapies. He was subsequently referred to pediatric oncology, where treatment with pembrolizumab was initiated, achieving disease stability.

Conclusion

GGS, or Nevoid Basal Cell Carcinoma Syndrome, is an autosomal dominant genodermatosis with a prevalence of 1:150,000 characterized by a predisposition to various neoplasms and skeletal abnormalities. Diagnosis requires specific major and minor clinical criteria. Manifestations follow a chronological progression, while macrocephaly and rib abnormalities are often congenital; medulloblastoma risk peaks at age 2; and BCCs typically manifest by the second decade of life, with rates of 51% by age 20 and 71% by age 40.

The genetic basis of GGS is a mutation in *PTCH1*, which fails to inhibit the SMO protein, leading to uncontrolled neoplastic cell proliferation. While vismodegib (an SMO inhibitor) is effective for advanced BCC, it is contraindicated in children due to animal models demonstrating irreversible defects in skeletal development and growth plate toxicity. This has prompted the exploration of alternative therapies. Studies have shown that PD-1 inhibitors (pembrolizumab, cemiplimab, and nivolumab) are effective in advanced BCC in adults, achieving an objective response rate of 31%. However, pediatric data remains limited.

Pembrolizumab is FDA-approved for pediatric patients aged 6 months and older for specific indications, such as classical Hodgkin lymphoma and microsatellite instability-high (MSI-H) solid tumors. The recommended dose for these pathologies is 2 mg/kg (up to a maximum of 200 mg) every 3 weeks. According to the KEYNOTE-051 study, the safety profile in children is consistent with that observed in adults. In this trial, approximately 56% of pediatric

patients experienced treatment-related adverse events; the most frequent were anemia (8%), fatigue (8%), decreased lymphocyte count (7%), and pyrexia (7%).

This case highlights the challenges of managing GGS in children. While SHH pathway inhibitors are standard for adults, their use in pediatric populations is restricted by skeletal toxicity. Our experience suggests that pembrolizumab is a viable and safe alternative for young patients. Further prospective studies are essential to establish the long-term safety and efficacy of immunotherapy in this demographic.

EA DV CONGRESS
VIENNA
30 SEP - 3 OCT 2026

Abstract N°: 907

Complete Remission of Superficial BCC Using APS-Assisted 5-FU Therapy: Preliminary Clinical Evidence

Francesco D'Oria*[1], Giulio Foggi[1], Francesco Piscazzi[1], Marco Ardigò[1]

[1] Dermatology Unit, IRCCS Humanitas Research Hospital, 20089 Rozzano, Italy, Department of Biomedical Sciences, Humanitas University, 20072 Pieve Emanuele, Italy, Milan, Italy

Introduction

Topical 5-fluorouracil (5-FU) is an established non-invasive treatment for superficial basal cell carcinoma (sBCC), but its clinical utility may be limited by suboptimal transdermal penetration and by local inflammatory reactions that can negatively affect tolerability, adherence, and cosmetic outcome. These limitations are particularly relevant in frail or elderly patients, in subjects with multiple lesions, and in cosmetically sensitive sites where tissue-sparing strategies are preferred. Improving local drug bioavailability without proportionally increasing toxicity is therefore of considerable clinical interest. We evaluated a galenic liposomal 5-FU formulation delivered through Automatic Patting System (APS)-assisted transdermal enhancement in patients with sBCC, with non-invasive monitoring supported by Line-Field Confocal Optical Coherence Tomography (LC-OCT).

Materials and Methods

We conducted a prospective observational study including six patients with nine clinically, dermoscopically, and LC-OCT-diagnosed sBCCs. Lesions were treated once weekly for 4 to 7 weeks using APS protocols combining Skin Patting® and iontophoresis. Treatment intensity was adapted according to anatomical site: head-and-neck lesions received 3 minutes of skin patting followed by 3 minutes of iontophoresis at 20% power, whereas trunk and extremity lesions were treated for 3 minutes each at 30% power, reflecting regional differences in skin thickness and mechanical resistance. The galenic preparation consisted of a liposomal 5-FU gel designed to improve epidermal absorption and retention. APS combines controlled epidermal micro-dermoincision, acoustic stimulation, and iontophoretic enhancement to facilitate penetration of hydrophilic molecules. Preclinical support came from ex vivo permeation studies on dermatomed pig ear skin mounted on Franz diffusion cells under occlusive conditions, which compared APS-assisted delivery with passive application and assessed 5-FU permeation and skin retention over 5 hours.

Results

Treatment was well tolerated, with only mild expected procedural bleeding and no major immediate complications or treatment-limiting adverse events. Five of nine lesions achieved complete response, confirmed clinically and by LC-OCT where available, whereas four lesions showed partial response. Complete remission occurred 7 to 11 weeks after treatment initiation, with no recurrence observed during follow-up of up to 9 months in lesions achieving complete response. Partial responders nonetheless showed meaningful tumor reduction and remained suitable for further conservative management or follow-up reassessment. Ex vivo studies demonstrated significantly greater 5-FU permeation with APS-assisted treatment than with passive application at 5 hours, together with increased drug retention within the skin membrane. The combined sequence of skin patting and iontophoresis was more effective than mechanical stimulation alone, supporting a synergistic delivery effect and the formation of a more efficient local cutaneous drug reservoir.

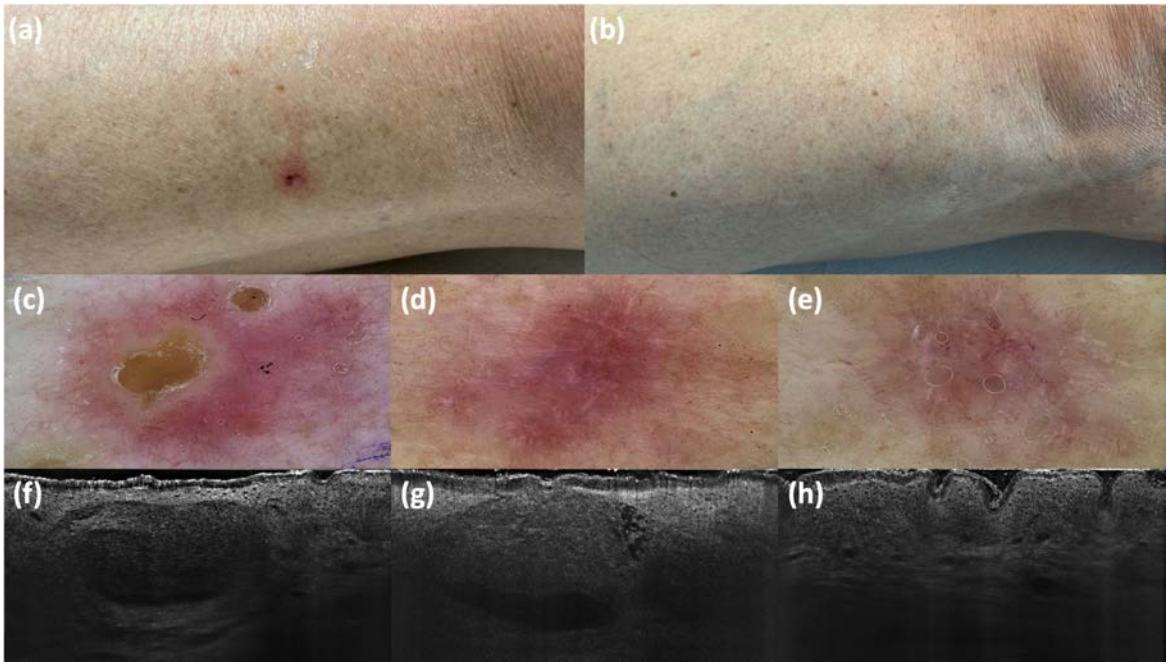

Representative clinical, dermoscopic, and LC-OCT images of lesion 1 (L1) before, during, and after APS-delivered 5-FU treatment. (a) Baseline clinical image of a suspected sBCC on the right lateral thigh. (b) Clinical image at 9 months, showing complete remission with minimal residual erythema. (c) Baseline dermoscopy showing erosions on an erythematous background. (d) Dermoscopy at week 4 showing hairpin vessels and shiny white structures. (e) Dermoscopy at week 7, before the last application, showing lesion reduction. (f) Baseline LC-OCT showing a BCC nest with a millefeuille pattern and clefting. (g) LC-OCT at 1 week showing persistent tumor nests with cell discohesion, suggestive of early treatment effect. (h) LC-OCT at week 7 showing no residual BCC, consistent with remission.

Conclusions

APS-assisted topical 5-FU appears to be a feasible, well-tolerated, and cosmetically favorable option for sBCC. The concordance between ex vivo permeation findings and preliminary clinical outcomes supports the biological plausibility of this approach and suggests that APS may improve the therapeutic performance of topical 5-FU by enhancing local drug penetration while preserving tolerability. Although limited by the small sample size, lack of a control arm, and observational design, these findings provide an encouraging preliminary signal and justify larger controlled studies to confirm long-term efficacy, define optimal treatment parameters, and better assess durability of response and recurrence risk.

EADV CONGRESS
VIENNA
30 SEP - 3 OCT 2026

Abstract N°: 917

Donald Trump's neck rash: A missed opportunity for public skin cancer awareness

Nicolas Kluger*[1, 2, 3]

[1] Aava medical Centre, Dermatology, Kerava, Finland
[2] Tampere University Hospital, Dermatology, Tampere, Finland
[3] Société Francaise des Sciences Humaines sur la Peau, Paris, France

Introduction
The health of world leaders is a legitimate source of concern for the global population. Physical diseases may lead to disability, with an inability to carry out expected duties, or even unexpected death leading to a power vacuum. The question of whether physical diseases may impact cognitive functions and the ability to govern the country also comes to mind. Furthermore, politicians tend to keep their illnesses hidden from the public long before they become obvious. Cutaneous conditions are more difficult to hide when they affect the face or hands, or when systemic treatments have a notable impact on physical appearance. US President Donald Trump recently attracted widespread media attention due to a visible rash on the right side of his neck, first spotted on March 2, 2026, during a Medal of Honor ceremony at the White House. Several US dermatologists publicly speculated that the rash was consistent with the use of topical treatments for actinic keratosis. This study evaluated the impact of this announcement on online search behavior and media coverage and discusses its potential implications for public health awareness.

Materials and Methods
Google Trends data were analyzed for the search terms "actinic keratosis," "imiquimod," "fluorouracil," "rash," and "skin cancer" in the United States from January 1, 2026 to April 2026. Wikipedia Pageviews Analysis was used to assess daily visits to the actinic keratosis, imiquimod, and fluorouracil articles on the English-language Wikipedia (en.wikipedia.org).

Results
Google Trends analysis revealed the highest search peak for "fluorouracil" on March 3, 2026, both in the United States and worldwide. A concurrent peak was observed for "actinic keratosis" on the same date. A secondary peak for "imiquimod" and "actinic keratosis" was noted on March 18, 2026. These peaks represented the highest search volumes recorded during the first three months of the year. From January 1 to March 1, 2026, the English Wikipedia pages for fluorouracil, imiquimod, and actinic keratosis received daily averages of 237, 57, and 379 pageviews, respectively. On March 3, 2026, pageviews rose to 1,001, 149, and 859, representing increases of 422%, 261%, and 226%, respectively, compared to March 1, 2026 (the day preceding the media coverage). Pageviews declined the following day and returned to baseline within 4 to 5 days. No measurable increase in pageviews was observed for "skin cancer" or "rash."

Conclusions
The health of President Donald Trump has been under scrutiny for some time. He has previously been diagnosed with chronic venous insufficiency (manifesting as leg swelling) and dermatoporosis (recurrent bruising of the hands). In the present case, the White House physician was notably vague, describing only a "preventative skin treatment" without further specification, which fueled considerable media speculation. Several dermatologists subsequently shared their opinions with the press, suggesting topical treatments such as imiquimod or 5-fluorouracil as likely candidates.Google Trends and Wikipedia pageview analyses both demonstrate a transient

celebrity effect, with a short-lived but measurable spike in public interest in these treatments and in actinic keratosis. However, the absolute Wikipedia pageview numbers remained relatively low, and interest returned to baseline within 4 to 5 days, suggesting limited sustained impact on public awareness.We believe that the absence of formal confirmation from the White House — combined with the fact that the dermatological information was conveyed through speculative expert commentary rather than an official diagnosis — may have blunted the potential public health benefit of this media event. A transparent and confirmed announcement could have served as a meaningful opportunity to raise awareness of actinic keratoses and their available topical treatments among the general population.

EADV CONGRESS
VIENNA
30 SEP - 3 OCT 2026

Abstract N°: 935

When a painless nodule hides an aggressive malignancy: Merkel cell carcinoma under JAK inhibition

Bianca Alexandra Varga*[1], Ana Olivia Toma[1]

[1] Municipal Emergency Clinical Hospital, Timișoara, Romania

Introduction

Merkel cell carcinoma (MCC) is a rare and aggressive cutaneous neuroendocrine malignancy, typically occurring in elderly or immunosuppressed patients. The increasing use of targeted immunomodulatory therapies may be associated with its occurrence in younger individuals.

Case Presentation

We report the case of a 49-year-old male presenting with a rapidly growing, painless nodular tumor on the right arm, with sudden onset and progressive enlargement. His medical history included high-risk primary myelofibrosis (JAK2-positive) treated with ruxolitinib, as well as toxic-ethanolic liver cirrhosis with stage III esophageal varices.

Clinical examination revealed a firm, erythematous-violaceous nodule. Histopathological and immunohistochemical evaluation confirmed the diagnosis of Merkel cell carcinoma, showing characteristic CK20 perinuclear dot-like positivity and synaptophysin expression, with a high mitotic index (~20 mitoses/mm^2) and infiltrative growth pattern. The tumor thickness was 5.2 mm, with no lymphovascular or perineural invasion identified.

The patient's immunocompromised status, including JAK inhibitor therapy, may have contributed to tumor development. JAK inhibition is known to impair cellular immune surveillance, particularly affecting T-cell and natural killer cell function, which may facilitate the emergence of highly immunogenic tumors such as MCC. The patient was subsequently referred to oncology for further staging and management.

Conclusion

This case highlights that MCC can occur in younger individuals in the setting of immunosuppression. Any rapidly growing, painless nodular lesion should prompt early biopsy, especially in patients receiving immunomodulatory therapy. In the era of targeted therapies, heightened dermatological vigilance is essential for the timely recognition of unexpected malignancies.

EA DV CONGRESS
VIENNA
30 SEP - 3 OCT 2026

Abstract N°: 936

Cutaneous infiltrating neoplasm in a patient with a history of prostate cancer. Case report.

Ana Lucia Anguis Pacheco*[1]

[1] IMSS Hospital General Zona 49, Los Mochis, Mexico

Introduction

Prostate cancer is one of the most common malignant neoplasms in men worldwide and represents a major public health concern. It arises from glandular epithelial cells, with adenocarcinoma as the most frequent histological subtype. Its course is usually slow and asymptomatic in early stages, but it may progress to advanced or metastatic disease without timely diagnosis and treatment. Globally, it is the second most commonly diagnosed cancer in men, with over 1.4 million new cases annually, accounting for approximately 14% of male cancers, and around 375,000 deaths each year. It commonly metastasizes to bone, lung, liver, and lymph nodes. Cutaneous involvement is rare (<1%) and usually presents as papules or nodules in the genital, suprapubic, or proximal thigh regions.

Case Presentation

A 69-year-old man from Sinaloa with a 4-year history of stage IV prostate adenocarcinoma (Gleason 7) underwent radical prostatectomy and one cycle of chemotherapy, which he discontinued, remaining without oncologic follow-up. Eight months prior to admission, he developed a progressive dermatosis in the genital region and inner thighs, initially presenting as an erythematous macule that evolved into firm erythematous-violaceous nodules with irregular borders; some were ulcerated and prone to bleeding, suggesting an aggressive infiltrative process. Dermatological evaluation and skin biopsy revealed a poorly differentiated infiltrating malignant epithelial neoplasm. In the context of his history, findings were consistent with probable cutaneous metastasis from prostate adenocarcinoma. The patient died one week after admission.

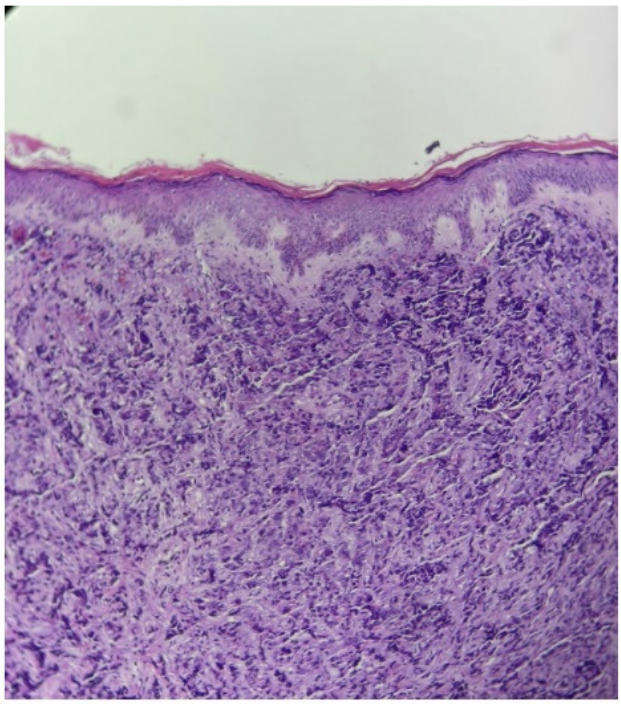

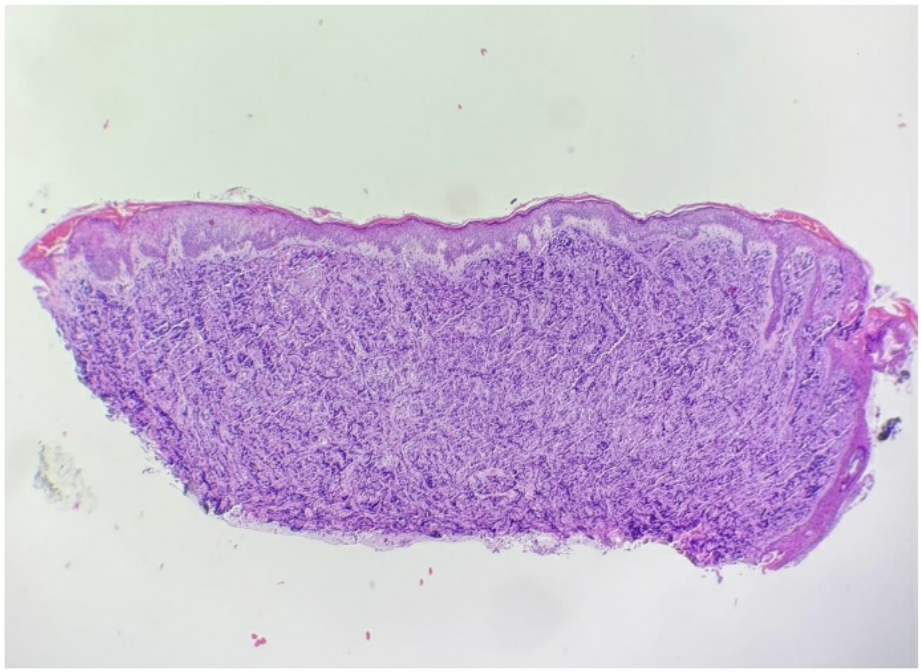

Figure 1. Histologic section of skin showing a preserved epidermis and dermis with an infiltrative cellular pattern. Hematoxylin and eosin (H&E) stain, 20×. Figure 2. Histologic section of skin showing a preserved epidermis and dermis with a diffuse infiltrative cellular pattern. Hematoxylin and eosin (H&E) stain, 10×.

Conclusion

Cutaneous metastasis from prostate cancer is a rare clinical finding and typically reflects advanced-stage disease with an unfavorable prognosis. Although prostate cancer most commonly metastasizes to bone, lymph nodes, and visceral organs, cutaneous involvement remains an uncommon presentation and may be easily overlooked, particularly when lesions appear in atypical locations or mimic benign dermatologic conditions. This case highlights the importance of maintaining a high index of suspicion for metastatic disease when evaluating progressive or unusual skin lesions in patients with a known history of malignancy, especially in those with inadequate oncologic follow-up or incomplete treatment.

The clinical presentation of cutaneous metastases can be highly variable, ranging from nodules and plaques to inflammatory or ulcerative lesions, which may delay diagnosis. Therefore, prompt recognition and thorough evaluation are essential. Histopathological examination, often supported by immunohistochemical staining, plays a crucial role in confirming the diagnosis and identifying the primary tumor origin. Early and accurate diagnosis is particularly important, as the presence of skin metastases is generally associated with a more aggressive clinical course, widespread disease dissemination, and limited survival.

Given these implications, the identification of cutaneous metastasis should prompt comprehensive staging and reassessment of the patient's overall oncologic status. Management typically requires a multidisciplinary approach involving oncology, dermatology, pathology, and palliative care teams, with treatment strategies tailored to disease extent and patient condition. Ultimately, recognizing this rare manifestation can facilitate timely intervention, guide prognosis, and improve the quality of care in patients with advanced prostate cancer.

EADV CONGRESS
VIENNA
30 SEP - 3 OCT 2026

Abstract N°: 943

Subcutaneous Panniculitis-Like T-Cell Lymphoma Following Immune Checkpoint Inhibitor Therapy

Anna Martino[1], Shahab Babakoohi*[2]

[1] Wake Forest University School of Medicine, Winston-Salem, United States
[2] Atrium Health Levine Cancer Institute, Wake Forest University School of Medicine, Charlotte, United States

Introduction

Immune checkpoint inhibitors (ICIs) have revolutionized the treatment of advanced melanoma but are associated with a spectrum of immune-related adverse events, including rare cutaneous and hematologic complications. Subcutaneous panniculitis-like T-cell lymphoma (SPTCL) is an uncommon primary cutaneous lymphoma of cytotoxic αβ T cells that can closely mimic inflammatory panniculitis both clinically and histopathologically, posing significant diagnostic challenges.

Case Presentation

A 58-year-old woman with stage IV melanoma of the left lower extremity was treated with four cycles of ipilimumab/nivolumab followed by six cycles of nivolumab monotherapy. Her course was complicated by immune-related autoimmune hepatitis, managed with systemic corticosteroids. Meanwhile, she developed multiple tender subcutaneous nodules on the extremities.

Initial punch biopsies of lesions on the right forearm and thigh demonstrated fat necrosis without malignancy. Three months later, PET/CT imaging revealed diffuse hypermetabolic subcutaneous nodularity involving the lower abdomen, pelvis, and extremities, concerning for inflammatory or metastatic disease. A repeat biopsy from the left calf showed mixed septal and lobular panniculitis, interpreted as an erythema nodosum–like reaction secondary to ICI therapy. Despite corticosteroid treatment, the nodules continued to increase in number and size.

Given persistent progression, ultrasound-guided deep biopsies of the left calf were obtained. Histopathologic examination revealed cytologically atypical lymphoid infiltrates consistent with subcutaneous panniculitis-like T-cell lymphoma. The patient was treated with CHOP-based multi-agent chemotherapy, resulting in complete clinical resolution of subcutaneous nodules, with follow-up imaging studies confirming remission.

Conclusion

This case suggests a potential association between immune checkpoint inhibitor therapy and the development of subcutaneous panniculitis-like T-cell lymphoma. Differentiating SPTCL from immunotherapy-induced panniculitis is difficult due to overlapping clinical, imaging, and histopathologic features. Persistent or progressive panniculitis-like lesions in patients with prior ICI exposure should prompt repeat deep biopsies and multidisciplinary evaluation. Early diagnosis is essential, as SPTCL is treatable and may carry a favorable prognosis with appropriate therapy.

EA DV CONGRESS
VIENNA
30 SEP - 3 OCT 2026

Abstract N°: 971

HISTOLOGICAL-MOLECULAR ASSOCIATION OF KOILOCYTES AND HUMAN PAPILLOMAVIRUS IN KERATOACANTHOMA

Jessica Plata Lira*[1, 2], Juan Daniel Lira[2], Juan Pedro Iribe[1], César García[1], Irma Natalia López[1], Cristobal Chaidez[2]

[1] Sinaloa Dermatological Center, Culiacán, Mexico

[2] National Laboratory for Food Safety Research (LANIIA) - Food and Development Research Center, Cualiacán, Mexico

Introduction

Human papillomavirus affects the skin and mucous membranes and is a major contributory factor in cancer worldwide. Keratoacanthoma is a rapidly growing skin cancer, considered a well differentiated variant of squamous cell carcinoma, which is mainly associated with exposure to ultraviolet radiation, smoking and immunosuppression. HPV has recently been identified in some lesions by the detection of characteristic structures called koilocytes.Objective: The aim of the study was to establish an association between the presence of koilocytes in histopathological samples of keratoacanthoma lesions and the detection of human papillomavirus (HPV) by polymerase chain reaction (PCR).

Materials and Methods

A cross-sectional analytical study was conducted. Patients over 18 years of age with a histological diagnosis of keratoacanthoma were included between January 2023 and October 2024. Forty paraffin-fixed samples with a diagnosis of keratoacanthoma and the presence or absence of koilocytes were analysed, and the presence or absence of HPV was determined by PCR in the tissue of the formalin- and paraffin-fixed biopsies.

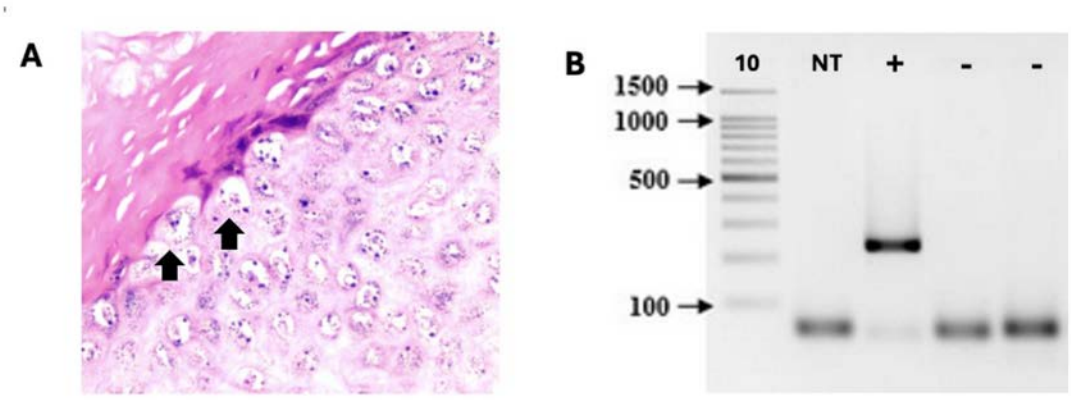

Figure 1. Histological and molecular markers used in this study. A) Histological section with koilocytes presence (black arrows). B) PCR amplicon of L1 region from Human Papillomavirus, (NTC) No template control; (+) positive sample; (-) Negative sample.

Results

Koilocytes were identified in the histopathological study of 24 samples, representing 60% of the total sample.

32.5% (13/40) of these samples were positive for HPV by PCR. A simple logistic regression was performed to assess the association, obtaining odds ratios (OR) and 95% confidence intervals. The resulting OR was 0.55 (95% CI 0.13-2.25), which does not represent a positive association and is not statistically significant (Table 1).
Based on the results, no significant association was found between the histological identification of koilocytes and the detection of HPV DNA using PCR. This finding is consistent with the limited available literature, which, while acknowledging HPV detection using molecular methods, does not establish a clear correlation with specific cytopathic changes at the histopathological level in this type of lesion. However, the results fall within the range of prevalences reported in the literature and reinforce the hypothesis that HPV may play a contributing, rather than a determining, role in the pathogenesis of keratoacanthoma. Although this study did not demonstrate an association between the presence of koilocytes in histopathology and HPV detection via PCR, it does explain the histological presence of koilocytes in samples that were negative for HPV by PCR compared to those that were positive. This could be due to the following factors: (1) The age of the paraffin-embedded samples, which were between 2 and 3 years old. (2) The fixation of the specimen in formalin beforehand can cause changes in the HPV DNA structure, as well as during the deparaffinization process, where the viral DNA can be directly affected and result in false negatives. (3) The clinical characteristics of the lesions, which may have been in a more advanced state of keratinization, could not be established.

Koilocytes, n (%)	Human Papillomavirus (HPV)		Association, OR (CI 95%)
	Positive PCR	Negative PCR	
Presence	9 (22.5)	15 (37.5)	0.55 (0.13 -2.25)
Absence	4 (10)	12 (30)	

Table 1. Association between the presence of koilocytes and Human Papillomavirus in keratoacanthoma samples

Conclusions

This study provides relevant evidence that contributes to the understanding of the association between HPV and keratoacanthoma.Highlighting the limitations of traditional histopathological findings to infer viral infection. The need for further studies with larger samples, more complete clinical information and the use of complementary techniques such as immunohistochemistry to further understand the etiopathogenic mechanisms involved and to optimize the treatment approach is underlined

EADV CONGRESS
VIENNA
30 SEP - 3 OCT 2026

Abstract N°: 1013

A Case of Folliculotropic Mycosis Fungoides Associated with Dupilumab Administration

Xinyi Chen*[1], Juan Bai[1], Jianjun QIAO[1]

[1] Department of Dermatology, The First Affiliated Hospital, Zhejiang University School of Medicine, Hangzhou, China

Introduction

Folliculotropic mycosis fungoides (FMF), a rare variant of cutaneous T-cell lymphoma, can clinically mimic inflammatory dermatoses such as atopic dermatitis (AD), especially in patients with long-standing pruritus, skin lesions and eosinophilia. Biologics and JAK inhibitors for presumed AD may mask symptoms and delay correct diagnosis. We present a case initially misdiagnosed as AD and treated with dupilumab, finally diagnosed with FMF.

Case Presentation

A 61-year-old male presented with generalized erythematous patches, plaques and severe pruritus for over 4 years. Scalp and eyebrow alopecia developed 1 year prior. He was diagnosed with atopic dermatitis at a local hospital, receiving 7 doses of dupilumab, upadacitinib and abrocitinib. Skin lesions improved slightly, but pruritus persisted. Peripheral blood eosinophilia (EOS > 1.5×10^9/L) was repeatedly detected.On admission to our hospital, laboratory tests showed: EOS 3.97×10^9/L; CEA 6.4 ng/mL; SCC 8.7 ng/mL; total IgE 239.0 KU/L. Past history included hypertension. He was admitted with a provisional diagnosis of eosinophilia. Physical examination showed Infiltrated erythematous patches and plaques were distributed on the head, face, trunk and extremities, with scalp hair and eyebrow loss. Further investigations included peripheral blood FIP1L1-PDGFα fusion gene negative. Bone marrow biopsy showed hypercellular marrow with eosinophilia and flow cytometry showed no abnormal blasts. Lymph node aspiration revealed reactive hyperplasia, predominantly paracortical.Skin biopsy was irregular epidermal hyperplasia, intraepidermal lymphoid infiltration; perifollicular and dermal lymphoid infiltrate with atypical cerebriform lymphocytes and numerous eosinophils. Immunohistochemistry: CD3(+), CD4(+), CD8(focal +), Ki-67 20%.And TCR gene rearrangement was positive. The final diagnosis was folliculotropic mycosis fungoides, stage IIA (T2N2M0B0).

Conclusion

FMF can closely mimic AD, especially with marked eosinophilia and pruritus. Treatment with dupilumab and JAK inhibitors may cause partial improvement and delay diagnosis. Skin biopsy with immunohistochemistry and TCR rearrangement is crucial for early accurate diagnosis. Clinicians should be alert to cutaneous T-cell lymphoma in patients with refractory dermatitis and persistent eosinophilia.

EADV CONGRESS
VIENNA
30 SEP - 3 OCT 2026

Abstract N°: 1014

Impact of time to definitive surgery on rates of margin positivity in patients with melanoma: a study of the National Cancer Database

Tejas Joshi[1], Alexa DiNello[2], Ambreen Younas[3], Celina Sit*[4], Michael Migden[5, 6]

[1] Department of Dermatology, Baylor College of Medicine, Houston, United States
[2] School of Medicine, The Ohio State University College of Medicine, Columbus, United States
[3] School of Medicine, Baylor College of Medicine, Temple, United States
[4] School of Medicine, Paul L. Foster School of Medicine, El Paso, United States
[5] Department of Dermatology, University of Texas, MD Anderson Cancer Center, Houston, United States
[6] Department of Head and Neck Surgery, University of Texas, MD Anderson Cancer Center, Houston, United States

Introduction

Time to definitive surgery (TTDS) in melanoma has been shown to impact both cause-specific and overall survival (Xiong et al., 2022; Conic et al., 2018). However, data are limited on how TTDS impacts rates of positive margins. As positive margins would entail need for re-excision, it is valuable to determine the extent to which TTDS may impact rates of margins positivity. Here, we use data from the National Cancer Database (NCDB) to determine the rates of margin positivity following excision for melanoma.

Materials and Methods

We identified patients with melanoma using International Classification of Diseases for Oncology, third edition codes 8720-8723, 8740-45, 8760, 8761, and 8770-8773 and topographical codes C49.0-C49.9 (all skin sites). Only patients with histologically confirmed melanomas were included. Patients who did not undergo definitive excision following biopsy were excluded, as were patients who underwent Mohs micrographic surgery. Patients with unknown margin status were also excluded. TTDS was grouped categorically into time periods of 1-30 days, 31-60 days, 61-90 days, and >90 days, consistent with prior NCDB literature (Conic et al., 2018). Multivariate models, incorporating age, sex, anatomic site, melanoma subtype, Breslow depth, ulceration status, Charlson comorbidity index, facility type, distance to facility, insurance type, income, and rural-urban living, were built to assess rates of margin positivity at time intervals >30 days, relative to TTDS at 1-30 days. Adjusted odds ratios (aORs) were computed at 95% confidence intervals (CIs).

Results

We identified 567,156 patients who met inclusion criteria. 57.3% of patients were male and patients were diagnosed with melanoma at an average age of 63.2 ± 15.4 years. 47.8% of patients underwent definitive surgery within 30 days, while 39.4%, 8.6%, and 4.1% underwent definitive surgery at 31-60, 61-90, and >90 days, respectively (Table I). Overall, we observed TTDS at 31-60 days to result in increased rates of positive margins (aOR 1.06, 95% CI 1.02-1.11, P <0.01). More pronounced odds of margin positivity were observed with treatment delays at 61-90 days (aOR 1.35, 95% CI 1.27-1.4, P <0.01) and beyond 90 days (aOR 1.85, 95% CI 1.72-1.98, P <0.01). Notably, stratification by stage disclosed delays of just 31-60 days to be associated with increased rates of margin positivity for melanoma in situ (aOR 1.33, 95% CI 1.16-1.53, P < 0.01). Across all stages, we observed a consistent trend of increased margin positivity with each successive treatment interval (Table II).

Table I. Demographic and tumor characteristics of study cohort

Characteristic	
Average Age (y) ± SD	63.2 ± 15.4
Sex	
Female	242,305 (42.7)
Male	324,851 (57.3)
Anatomic Site	
Head/Neck	183,367 (32.3)
Trunk	128,427 (22.6)
Extremities	252,783 (44.6)
Other*	2579 (0.5)
Melanoma Subtype	
Superficial Spreading	194,609 (34.3)
Nodular	53,707 (9.5)
Lentigo Maligna/Lentigo Maligna Melanoma	42,270 (7.5)
Acral Lentiginous Melanoma	269,856 (47.6)
Other**	
Stage	
Melanoma in situ	279,745 (49.3)
T1, ≤1.0 mm	69,114 (12.2)
T2, 1.1-2.0 mm	103,877 (18.3)
T3, 2.1-4.0 mm	64,368 (11.3)
T4, >4.0 mm	50,052 (8.8)
Ulceration Status	
Yes	89,011 (15.7)
No	426,888 (75.3)
Unknown	51,257 (9.0)
Charlson Comorbidity Index	
0	480,736 (84.8)
1	61,442 (10.8)
2	15,342 (2.7)
≥3	9,636 (1.7)

*Other sites include topographical codes C44.8 (overlapping lesion of skin) and C44.9 (skin, not otherwise specified)
**Other melanoma subtypes include amelanotic melanoma, balloon cell melanoma, desmoplastic melanoma, epithelioid melanoma, melanoma arising in nevus, regressing melanoma, and spindle cell melanoma.

Table II. Association of positive margins with time to definitive surgery, stratified by stage. Treatment 1-30 days represents the reference interval.

	31-60 days		61-90 days		>90 days	
Stage	aOR (95% CI)	*P*	aOR (95% CI)	*P*	aOR (95% CI)	*P*
Overall	1.06 (1.02-1.11)	<0.01	1.35 (1.27-1.44)	<0.01	1.85 (1.72-1.98)	<0.01
Melanoma in situ	1.33 (1.16-1.53)	<0.01	1.61 (1.33-1.95)	<0.01	2.01 (1.63-2.48)	<0.01
T1, ≤1.0 mm	1.08 (1.01-1.16)	0.01	1.30 (1.17-1.44)	<0.01	1.92 (1.70-2.17)	<0.01
T2, 1.1-2.0 mm	0.93 (0.84-1.02)	0.13	1.17 (1.01-1.36)	0.04	1.76 (1.47-2.09)	<0.01
T3, 2.1-4.0 mm	0.95 (0.85-1.06)	0.36	1.33 (1.14-1.54)	<0.01	1.60 (1.33-1.93)	<0.01
T4, >4.0 mm	0.97 (0.88-1.06)	0.50	1.19 (1.05-1.35)	<0.01	1.54 (1.33-1.77)	<0.01

Table I. Demographic and tumor characteristics of study cohort Characteristic. Table II. Association of positive margins with time to definitive surgery, stratified by stage.

Conclusions

Our finding of increased rates of margin positivity with longer TTDS is quite intuitive for deeper melanomas—being more aggressive, they may exhibit more prolific growth in a shorter time span. Importantly, however, we observed treatment delays of just 31-60 days to be associated with 30% increased odds of margin positivity even for melanoma in situ. Thus, the expeditious treatment of melanoma in situ should not be discounted. An important limitation of our analysis is that conventional margin assessment with vertical sectioning ("bread-loafing") only enables evaluation of 1-2% of the total margin (van Delft et al., 2019); thus, the true rates of margin positivity may be underestimated in our analysis. Recurrence rates, which would represent an important outcome in such cases, are not captured by NCDB.

EA DV CONGRESS
VIENNA
30 SEP - 3 OCT 2026

Abstract N°: 1043

Synchronous Melanomas: Insights from a Five-Year Retrospective Analysis

Yagmur Cicek Akkurt*[1], Fiona Meredith[1], Louise MacFarlane[1], Keith Woo[1]

[1] Raigmore Hospital, NHS Highland, Inverness, United Kingdom

Introduction

Synchronous melanoma (SM) refers to the diagnosis of a second primary melanoma occurring within three months of the initial primary melanoma. Approximately 0.5% of patients with cutaneous melanoma present with synchronous primary lesions.(1) This study aims to review all cases of SM discussed at the melanoma multidisciplinary team (MDT) meeting at this centre over a five-year period.

Materials and Methods

Cases were identified using records from departmental multidisciplinary meetings. Melanoma multidisciplinary team (MDT) lists, histopathology, and clinical records were reviewed for the period January 2021 to December 2025. The study cohort comprises invasive malignant melanoma (MM), lentigo maligna (LM), and melanoma in situ (MIS).

Results

A total of 687 patients were diagnosed with cutaneous melanomas during the five-year period (Table 1). Among these, 9 patients (1.31%) with SMs were identified, comprising 4 males and 5 females. The median age at diagnosis was 78 years (range: 60–88 years). Two patients (22.2%) had SMs diagnosed at the same time, and seven (77.8%) had subsequent melanoma diagnosed within a 3-month period. Identified risk factors included significant sun exposure (n = 5/9, 55.5%), having a first-degree family member with cutaneous melanoma (n = 2/9, 22.2%), and a history of immunosuppression due to breast cancer (1/9, 11.1%). A total of 23 lesions were identified, of which 60.9% (n = 14) were classified as invasive melanomas. Among the invasive melanomas identified, superficial spreading melanoma (SSMM) represented the most prevalent subtype (n = 10, 71.4%), followed by lentigo maligna melanoma (n = 2, 14.3%) and nodular melanoma (n = 2, 14.3%). The majority of lesions (30.5%, n = 7) were located on the trunk, followed by six lesions (26.1%) on the upper limbs, five lesions (21.7%) on the head and neck region, and five lesions (21.7%) on the lower limbs. Of the nine patients with second melanomas, two (22.2%) had only synchronous in situ lesions, five (55.5%) had both LM/MIS and invasive melanoma, one (11.1%) had both stage 1a and 1b melanomas, and one (11.1%) had both stage 1a and 4b melanomas.

Patients (n=9)	Primary malignant melanoma				Synchronous malignant melanoma			
	Site	Subtype	Breslow thickness	Pathological stage	Site	Subtype	Breslow thickness	Pathological stage
1	Upper limb	Mis		pTis	Head&Neck	Mis		pTis
2	Lower limb	SSMM	1	pT1b	Trunk	SSMM	0.2	pT1a
3	Upper limb	NM	13	pT4b	Head&Neck	LMM	0.2	pT1a
4	Lower limb	Mis		pTis	Head&Neck	LM		pTis
5	Trunk	SSMM	2.2	pT3a	Lower limb	LMM	0.3	pT1a
					Lower limb	SSMM	0.45	pT1a
					Lower limb	Mis		pTis
6	Trunk	SSMM	0.9	pT1b	Trunk	SSMM	0.8	pT1b
					Head&Neck	Mis		pTis
7	Upper limb	NM	5	pT4b	Trunk	SSMM		pTis
					Head&Neck	Mis		pTis
8	Upper limb	SSMM	0.4	pT1a	Trunk	SSMM		pTis
					Trunk	SSMM	2.5	pT3a
9	Upper limb	SSMM		pTis	Upper limb	SSMM	0.3	pT1a

Conclusions

Patients diagnosed with melanoma have an increased risk of developing additional lesions. Therefore, thorough assessment during follow-up visits is essential. (2) These findings underscore the importance of prompt diagnosis and comprehensive skin examinations.

EADV CONGRESS
VIENNA
30 SEP - 3 OCT 2026

Abstract N°: 1053

Single-cell transcriptome analysis of primary and recurrent extramammary Paget's disease

Xiaoxiang Xu*[1], Nanhui Wu[1], Guolong Zhang[1], Yeqiang Liu[1]

[1] Shanghai Skin Disease Hospital, School of Medicine, Tongji University, Shanghai, China

Introduction
Extramammary Paget's disease (EMPD) is a rare adenocarcinoma with a high recurrence rate, yet the cellular and molecular mechanisms underlying its recurrence remain poorly understood.

Materials and Methods
We performed single-cell RNA sequencing (scRNA-seq) on tissues from normal skin (NS), primary EMPD (P-EMPD), and recurrent EMPD (R-EMPD) to comprehensively resolve the cellular ecosystem and transcriptional dynamics.

Results
We profiled the transcriptomes of 36,317 cells from two P-EMPD and one R-EMPD patients. Our analysis revealed a distinct immune ecosystem in R-EMPD, characterized by a significant increase in cytotoxic CD8+effector T cells (CD8+ TEFF) and exhausted CD4+ T cells, alongside a decrease in naïve T cells. Trajectory analysis confirmed a terminal differentiation state for CD8+ TEFF in R-EMPD, co-expressing cytotoxic molecules and exhaustion markers. We also uncovered significant heterogeneity within Paget cells, identifying four distinct subclusters. Notably, the CALML5+ Paget cell subcluster was enriched in R-EMPD, exhibited higher copy number variations, and showed enhanced interactions with immune cells via the MIF signaling pathway. Furthermore, Paget cells in R-EMPD underwent metabolic reprogramming, with a significant upregulation of genes (e.g., PRDX1 and GUK1) involved in oxidative phosphorylation. High expression of PRDX1 and GUK1 was validated by IHC and was correlated with poor prognosis in multiple adenocarcinomas.

Conclusions
Our study delineates a unique immunosuppressive and metabolically altered microenvironment in recurrent EMPD, driven by specific T cell exhaustion states and a metabolically reprogrammed, aggressive Paget cell subpopulation. Our findings provide novel insights into the mechanisms of EMPD recurrence and the identification of potential therapeutic targets.

EADV CONGRESS
VIENNA
30 SEP - 3 OCT 2026

Abstract N°: 1089

Teledermatology and Basal Cell Carcinoma: A Retrospective Cohort Study at a Tertiary Hospital in Southern Europe

Marta Cebolla Verdugo*[1], Carlos Llamas-Segura[1], Francisco Almazan-Fernandez[1], Jorge Vega-Castillo[1], Husein Husein-ElAhmed[2], Ricardo Ruiz-Villaverde[1]

[1] Hospital San Cecilio, Granada, Spain

[2] Hospital de Baza, Granada, Spain

Introduction

Teledermatology has expanded markedly in the post-pandemic era; however, its impact on the histopathologic presentation of basal cell carcinoma (BCC) remains insufficiently characterized. Tumor depth and histologic subtype are key prognostic factors and may differ according to diagnostic pathway.

Materials and Methods

We conducted a retrospective observational study at a tertiary referral hospital in southern Europe, including all histologically confirmed BCCs diagnosed in 2019 through face-to-face dermatology and in 2022 through teledermatology. A total of 486 tumors were analyzed (201 face-to-face; 285 teledermatology). Histologic subtypes (superficial, nodular, micronodular, sclerodermiform) were examined individually and grouped into non-aggressive (superficial/nodular) versus aggressive (micronodular/sclerodermiform) categories. Statistical analyses included Welch's t-test, chi-square tests, and multivariable logistic regression.

Results

Mean tumor depth was significantly lower in the teledermatology cohort (1.67 mm vs 2.51 mm; $p < 0.001$). Histologic subtype distribution differed between pathways ($\chi^2 = 41.3$; $p = 0.002$): superficial BCCs were more frequent in face-to-face consultations (15.9% vs 8.8%), whereas nodular and micronodular variants predominated in the teledermatology group (65.6% vs 62.2% and 13.3% vs 4.0%, respectively). Sclerodermiform tumors were slightly more common in face-to-face evaluations (17.9% vs 12.3%). When regrouped into non-aggressive versus aggressive patterns, the distribution differed between pathways, although this categorization did not indicate a predominance of low-risk histology in the teledermatology cohort. In multivariable analysis, tumor depth was the only independent predictor of consultation pathway ($\beta = -1.10$; $p < 0.001$).

Conclusions

Teledermatology was associated with the diagnosis of significantly shallower BCCs, even across subtypes, supporting its role in facilitating earlier histologic detection. Subtype differences were pathway-specific but did not fully account for the depth disparity. These findings highlight teledermatology as an effective diagnostic route for timely identification of BCC in contemporary clinical practice.

EADV CONGRESS
VIENNA
30 SEP - 3 OCT 2026

Abstract N°: 1098

Atypical Squamous Cell Carcinoma of the Thigh Mimicking Chronic Inflammatory Dermatosis

Maroua Berdjane*[1], mira chikhaoui[1], Houria Sahel[1]

[1] Dermatology Department, Bab El Oued University Hospital, Algiers, Algeria

Introduction

Squamous cell carcinoma (SCC) predominantly affects sun-exposed areas. Localization in covered regions is uncommon and poses a significant diagnostic challenge. We report a rare case of primary SCC of the thigh, initially mimicking a chronic inflammatory dermatosis, which led to diagnostic delay and advanced locoregional spread



Erythematous-keratotic papules

Case Presentation

A 79-year-old male presented with a one-year history of painful, unilateral lesions on the anterolateral aspect of the right thigh. Clinical examination revealed a 6 cm superficial ulceration with a haemorrhagic base, associated with multiple erythematous-keratotic papules and extensive lymphedema. Staging revealed fixed inguinal and distant bilateral cervical lymphadenopathies. Biopsy with immunohistochemistry (P40+, CK20-, TTF1-) confirmed a poorly differentiated invasive squamous cell carcinoma. A thoraco-abdomino-pelvic CT scan confirmed stage IV metastatic disease, requiring palliative oncology referral.

This case illustrates a diagnostic trap: while SCC typically presents as a keratotic nodule on sun-damaged skin, it can develop in non-photo-exposed areas as chronic erosive and papulo-keratotic lesions. This atypical morphology can mimic inflammatory conditions such as hypertrophic lichen planus, verrucous lupus, or pyoderma gangrenosum. Contrary to common practice, the absence of sun exposure should not exclude malignancy. Immunohistochemistry is crucial in these poorly differentiated tumors to confirm the squamous origin and rule out distant metastases.

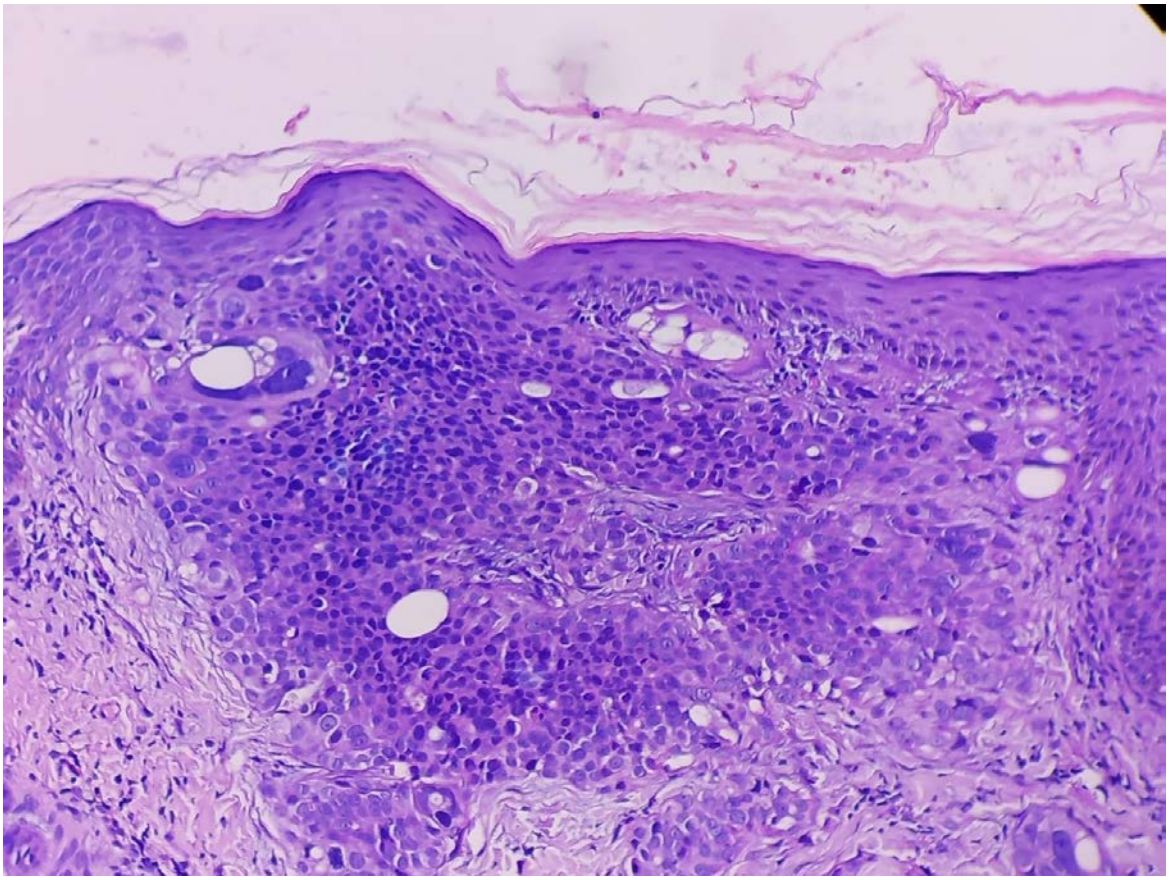

Poorly differentiated, non-keratinizing invasive squamous cell carcinoma with dermal infiltration

Conclusion

Squamous cell carcinoma can develop in sun-protected areas and mimic benign dermatoses. This case underscores that the absence of UV exposure does not rule out cancer. Systematic biopsy remains essential for any persistent or atypical erosive lesion to avoid diagnostic delays and prevent metastatic progression.



A 6 cm superficial ulceration

EA DV CONGRESS
VIENNA
30 SEP - 3 OCT 2026

Abstract N°: 1102

Plantar Marjolin's Ulcer: Cutaneous Squamous Cell Carcinoma Arising from Chronic Fistulized Osteomyelitis

Maroua Berdjane*[1], mira chikhaoui[1], Houria Sahel[1]

[1] Dermatology Department, Bab El Oued University Hospital, Algiers, Algeria

Introduction

Cutaneous squamous cell carcinoma (cSCC) is the second most common skin cancer worldwide. While solar radiation is the primary risk factor, chronic inflammation is a rare but well-established etiology. We report a case of plantar cSCC secondary to fistulized osteomyelitis, illustrating the serious nature of this rare progression known as Marjolin's ulcer.

Case Presentation

We present the case of a 51-year-old male with a history of right fifth toe amputation following a road traffic accident, complicated by chronic infectious osteomyelitis. The patient presented with a right heel ulceration that had been present for several years.Physical examination revealed a 4 cm ulceration on the plantar aspect of the right foot. The lesion featured indurated, hyperkeratotic borders and a fibrinous, budding base, and was painful upon weight-bearing. The surrounding skin was thickened and indurated. No palpable lymphadenopathy was noted.A skin biopsy confirmed a microinvasive cSCC without bone infiltration. A CT scan of the right lower limb revealed calcaneal osteomyelitis fistulizing to the skin, accompanied by talar-plantar cellulitis and muscle atrophy. A multidisciplinary meeting (Dermatology-Orthopedics) was scheduled to determine the therapeutic strategy, but the patient was subsequently lost to follow-up.

Marjolin's ulcer accounts for approximately 2% of cutaneous carcinomas, the majority of which are squamous cell carcinomas. Malignancy develops at sites of chronic inflammation, scarring, or suppuration, where repeated epithelial stimulation and regeneration drive malignant transformation.The development of cSCC on fistulized plantar osteomyelitis in this patient highlights an exceptional clinical evolution. While this transformation is well-documented in burn scars and post-traumatic wounds, localization to the foot is rare and often associated with diagnostic delays. The chronic, indolent, and infectious appearance of the lesion frequently masks the underlying malignancy.





Marjolin’s ulcer

Conclusion

Squamous cell carcinoma can develop on longstanding fistulas independent of sun exposure. This case emphasizes the necessity of clinical vigilance and systematic biopsy of chronic non-healing lesions to prevent delayed diagnosis and ensure timely management.

EADV CONGRESS
VIENNA
30 SEP - 3 OCT 2026

Abstract N°: 1107

Using Congress-Associated Continuing Medical Education as a Tool to Enhance Patient-Centered Care in Nonmelanoma Skin Cancer

Michelle Worst*[1], Andrew Small[1], Megan Cannon[1], Dirk Schadendorf[2]

[1] Medscape Oncology, Newark, United States

[2] Comprehensive Cancer Center University Hospital Essen & Research Alliance Ruhr, Essen, Germany

Introduction

Nonmelanoma skin cancers (NMSCs), including basal cell carcinoma (BCC) and cutaneous squamous cell carcinoma (CSCC), represent the most common malignancies globally. Although many cases are successfully managed with local therapies, recent advances in immunotherapy have expanded treatment options for patients with advanced or high-risk disease. Educational gaps persist in integrating evolving evidence into collaborative, patient-centered treatment planning across specialties and regions. The objective of this analysis was to evaluate the pooled impact of enduring, online continuing medical education (CME) activities associated with EADV programming on the multidisciplinary management of NMSC globally.

Materials and Methods

This analysis included two CME-certified programs consisting of live symposia at the European Academy of Dermatology & Venereology (EADV) Congress with corresponding online enduring activities. The present analysis focuses on the enduring components. Educational impact for clinical themes was measured using a repeated pre-/post-education design consisting of multiple-choice questions assessing knowledge and competence and a 5-point Likert scale assessing confidence. Data were analyzed for global audiences of dermatologists, Mohs surgeons, oncologists, and surgeons who completed pre- and/or post-education assessments. Improvement was measured by relative changes in the percentage of correct responses and the proportion of clinicians reporting confidence (scores of 4 or 5). Statistical significance was determined using McNemar's test, with P-values <.05 considered significant. The endring activities originally launched in October 2024 and September 2025; data were collected until April 2026.

Results

Participation in the enduring CME activities was associated with consistent improvements in the multidisciplinary management of NMSC across specialties (table 1). Globally, the smallest relative gains were related to creating care plans. Stratified analyses demonstrated greater improvements among non-US clinicains, particularly within dermatology, where gains were significant across all clinical themes. In contrast, US clinciains showed more modest improvements with generally higher pre- and post-education perforamnce, suggesting potential ceiling effects.

Learning Theme	% Pre Correct, % Post Correct; *P Value*			
	Dermatologists (n=247)	Mohs Surgeons (n=38)	Oncologists (n=125)	Surgeons (n=261)
Awareness of clinical care principles and ongoing data	27, 42; *<.001*	32, 47; *<.05*	37, 52; *<.001*	26, 35; *<.001*
Creating patient-centered care plans as part of the multidiscplinary team	34, 48; *<.001*	29, 42; *<.01*	40, 55; *<.001*	27, 36; *<.001*
Ability to work with the multidisicplinary team to prioritze shared decision-making	16, 25; *<.001*	21, 29; *NS*	20, 28; *<.01*	12, 19; *<.001*

Table 1: Pooled analysis for United States (US) and non-US by learning theme and specialty

Conclusions

Enduring CME linked to major congress programming can meaningfully enhance multidisciplinary care capabilities in NMSC across diverse clinical audiences. The differential impact observed between regions highlights an opportunity to strategically deploy scalable education to address global disparities in cancer care. Future educational efforts should prioritize specialty-specific gaps, reinforce application of emerging evidence in real-world decision-making, and further integrate multidisciplinary perspectives to optimize patient outcomes.

EA DV CONGRESS
VIENNA
30 SEP - 3 OCT 2026

Abstract N°: 1118

Mycosis Fungoides with Vasculopathic, Granulomatous, and Syringotropic Features Presenting with Severe Ischemia and Digital Necrosis

Inês Tribolet de Abreu*[1, 2], Ivânia Soares[1, 2], Inês Pereira Amaral[1, 2], Filipe Monteiro[1, 2], Gustavo Silva[1, 2], Pedro de Vasconcelos[1, 2], Joana Antunes[1, 2]

[1] Dermatology Department - Unidade Local de Saúde Santa Maria, Lisbon, Portugal
[2] Dermatology University Department - Faculdade de Medicina da Universidade de Lisboa, Lisboa, Portugal

Introduction

Mycosis fungoides (MF) is the most common primary cutaneous T-cell lymphoma, representing about 60% of cases. It typically presents as erythematous patches and plaques on sun-protected areas with an indolent course. However, several variants exhibit atypical features. Granulomatous MF (GMF) accounts for ~6% of cases and shows granulomatous inflammation with a predilection for distal extremities. It carries a worse prognosis than classic MF. Syringotropic MF (STMF) is a rare variant with tropism for eccrine glands. Vasculopathic involvement has rarely been reported, and its clinical consequences, particularly severe ischemia, remain poorly characterized.

Case Presentation

A 49-year-old woman presented to the emergency department with painful digital necrosis. Her disease began seven years earlier with non-pruritic erythematous scaly patches on the thighs, forearms and abdomen, accompanied by xerosis. Two years later, she developed bilateral leg edema, livedo, and paresthesias. A skin biopsy reported “lymphocytic vasculitis”. Autoimmune workup was negative, and she was treated with corticosteroids. Three years later, progressive leg ulcers developed. One year later, an arterial Doppler showed absent posterior tibial flow, leading to angioplasty, after which the ulcers paradoxically worsened. New skin biopsies suggested cutaneous T-cell lymphoma (MF versus Sézary syndrome), though Sézary syndrome was excluded. The patient was lost to follow-up. Eighteen months later, she returned with worsening ulcers, severe pain, digital necrosis and weight loss, prompting emergency referral. Examination revealed extensive right foot ulceration with tendon exposure, necrosis of the fourth toe, and hypoperfusion of adjacent toes. Additional lower limb ulcers and widespread xerosis and poikiloderma were noted, affecting over 80% of body surface area.

Laboratory studies showed anemia, leukocytosis, elevated inflammatory markers, and hypoalbuminemia. Infectious, autoimmune and thrombophilia workups were negative. Imaging excluded significant vascular or systemic disease, although magnetic resonance imaging suggested osteomyelitis. Flow cytometry detected an abnormal CD4+ population without meeting criteria for Sézary syndrome (B0). Cultures from wound exudate and skin biopsy tissue grew multidrug-resistant *Pseudomonas aeruginosa* sensitive only to meropenem and amikacin. Skin biopsies obtained from the leg, thigh, and abdomen reported MF with syringotropic, granulomatous, and vasculopathic features. Clonal T-cell receptor gene rearrangement was identified in both skin and blood. The patient was staged as IIIA (T4N0M0B0).

The patient was admitted to the Dermatology ward and managed by a multidisciplinary team. She received intravenous meropenem for six weeks and underwent amputation of the second to fifth toes of the right foot, followed by further amputation of the hallux due to progressive necrosis. Debridement and vacuum-assisted closure therapy were performed. Systemic treatment with methotrexate (up to 20mg/week) showed limited response, prompting recent initiation of mogamulizumab.

Conclusion

This case represents, to our knowledge, the first report of MF with concurrent vasculopathic, granulomatous, and syringotropic features leading to severe ischemic complications, including digital necrosis and osteomyelitis requiring amputation. While granulomatous syringotropic MF has been previously described, the addition of vasculopathic involvement with resultant tissue loss is novel. It highlights several critical clinical lessions: (1) vasculopathic involvement in MF can be a cause of severe ischemic tissue loss; (2) vascular interventions may be futile or harmful when the underlying cause is lymphomatous vasculopathy; (3) the 7-year diagnostic delay underscores the challenge of diagnosing MF; and (4) early, accurate diagnosis through multidisciplinary collaboration and comprehensive histopathologic evaluation is essential for optimal management of complex MF variants.

EADV CONGRESS
VIENNA
30 SEP - 3 OCT 2026

Abstract N°: 1135

Multimodal AI for BCC Diagnosis, Depth Stratification, and Clinical Translation

Zhaowei Chu*[1], Songmei Geng[1]

[1] The second affiliated hospital of Xi'an Jiao tong university, Xi'an, China

Introduction
Basal cell carcinoma (BCC) is the most common skin cancer, with a steadily rising incidence worldwide. Early diagnosis, subtyping, and depth stratification are critical for treatment planning, yet under traditional treatment paradigms, this information relies on invasive biopsy. Furthermore, access to dermatology specialists and diagnostic equipment remains limited, particularly in underserved settings. Here, we present a clinically aligned multimodal artificial intelligence (AI) framework for BCC diagnosis, subtyping, and depth stratification, together with a majority-voting strategy designed to reflect real-world expert assessment.

Materials and Methods
We curated a multicenter Asian multimodal dermatology dataset comprising 1,611 cases from two tertiary hospitals, including matched clinical photographs, dermoscopic images (n = 261), structured metadata, and clinical symptom records. Models were evaluated on one internal and two external cohorts, including an out-of-continent cohort from Brazil, and benchmarked against 21 board-certified dermatologists across eight hospitals.

Results
The multimodal model integrating clinical images and medical text significantly outperformed the image-only PanDerm baseline in BCC diagnosis (external cohort: AUC, 0.978 vs. 0.899, P = 0.001) and BCC pathological subtyping (external cohort: AUC, 0.899 vs. 0.823, P = 0.001). Incorporating dermoscopic images yielded numerically higher precision for BCC depth stratification than PanDerm on the external cohort (0.865 ± 0.084 vs. 0.787 ± 0.150; P = 0.691). Compared with human readers, the AI system achieved superior performance in both BCC diagnosis and subtyping (diagnosis accuracy, 0.944 ± 0.025 vs. 0.820 ± 0.081, P < 0.001; subtyping accuracy, 0.829 ± 0.026 vs. 0.692 ± 0.071, P < 0.001) and depth stratification under a four-of-five majority-voting protocol (precision, 1.00 vs. 0.919, P = 0.005).

Conclusions
Together, these findings support multimodal AI as a reliable clinical decision-support tool for BCC diagnosis, subtyping and depth stratification, with the potential to improve access to accurate assessment in resource-limited settings and reduce invasive biopsy procedures.

EADV CONGRESS
VIENNA
30 SEP - 3 OCT 2026

Abstract N°: 1150

A Rare Presentation of Poikilodermatous Mycosis Fungoides in a Paediatric Patient.

Rania Elakad*[1], Afnan Samy[1]

[1] Zagazig University Hospitals, Zagazig, Egypt

Introduction

Mycosis fungoides (MF)is the most common type of cutaneous T-cell lymphoma, with several clinical variants. In paediatric patients, hypopigmented MF is the most frequently encountered subtype. Poikilodermatous MF, characterized by atrophy, telangiectasia, and mottled pigmentation, is exceedingly rare in children, with no previously reported cases in the literature.

Case Presentation

A 10-year-old boy who presented with 2-year history of gradually progressive skin lesions associated with moderate pruritus. The lesions predominantly involved the trunk and extremities, sparing of the face. Clinical examination revealed multiple plaques exhibiting atrophy, mottled pigmentation, and telangiectasia, consistent with poikiloderma. Differential diagnoses included congenital poikiloderma, e.g. Rothmund–Thomson syndrome; however, this was excluded based on the late onset, non-photodistributed pattern, and absence of systemic features. Generalized morphea was also considered as a differential diagnosis. A skin biopsy was performed and demonstrated epidermotropism, dermal infiltrate of CD4+, CD8- atypical lymphocytes, dilated vessels and pigment incontinence, confirming the diagnosis of poikilodermatous MF. Staging workup revealed no extracutaneous involvement. The disease was staged as IB and the patient was started on narrowband UVB phototherapy, a safe and effective option in paediatric patients, combined with acitretin 25 mg daily. The skin lesions showed marked improvement with residual skin atrophy and post-inflammatory hyperpigmentation. While hypopigmented MF represents the most common paediatric variant, poikilodermatous MF is exceptionally rare in this age group. It is typically associated with a more indolent course and mild pruritus. This case highlights the diagnostic challenge posed by atypical presentations of MF and emphasizes the importance of histopathological examination in poikilodermatous dermatoses in children.

Conclusion

Poikilodermatous MF should be considered in the differential diagnosis of poikiloderma in children. Early biopsy is essential for accurate diagnosis and appropriate staging.

EADV CONGRESS
VIENNA
30 SEP - 3 OCT 2026

Abstract N°: 1151

Sorafenib-induced keratoacanthoma treated with intralesional methotrexate

Adriana Pessoa Mendes*[1], Guilherme Muzy[2], Marcus Maia[2]

[1] Hospital do Câncer A.C. Camargo, Santa Casa de Misericordia de Sao Paulo, São Paulo, Brazil

[2] Santa Casa Sao Paulo, Sao Paulo, Brazil

Introduction

Sorafenib is an oral small-molecule antineoplastic agent targeting multiple protein kinases and has been approved for the treatment of metastatic renal cell carcinoma and hepatocellular carcinoma. Sorafenib is an inhibitor of the serine/threonine kinase RAF pathway (inhibiting BRAF and RAF-1). Sorafenib inhibits proangiogenic and proliferative tyrosine kinases, including vascular endothelial growth factor (VEGF) 1/2/3, platelet-derived growth factor (PDGFR), c-kit, Flt-3, and RET.Skin reactions are common and can occur in up to 74% of patients under treatment. Hand-foot or palmar-plantar erythrodysesthesia and stomatitis are the most frequent skin reactions and are believed to occur due to both vascular damages induced by VEGFR and PDGFR blockade. Other frequent reactions include non-scarring alopecia in 26% of cases, facial erythema in 64% of cases, subungual hemorrhages in 70%, eruptive keratosis pilaris in 21% of cases, nipple hyperkeratosis in 19%, and the appearance of epidermal cysts in 5%. The appearance of new epithelial neoplasms and inflammation of actinic keratoses occurs in 10% of cases.

Case Presentation

We report the case of a 70-year-old patient with hepatocellular carcinoma with renal metastasis who underwent partial hepactectomy and complete renal resection. He started using Sorafenib as adjuvant treatment. One month after starting targeted therapy, a tumor was observed in the right retroauricular region with progressive growth. On initial dermatological examination, a tumor of approximately 4 cm was present in the right retroauricular region, clinically suggestive of keratoacanthoma. An incisional biopsy was performed, which confirmed the diagnosis.Non-surgical treatment was chosen due to the extent of the lesion, the patient's age, and the associated disease. The neoplasm was treated with an intralesional injection of methotrexate 25mg/ml. The lesion was divided into 4 quadrants, and 0.2ml of methotrexate solution was infiltrated into each point, plus one point in the center of the lesion, using a 3ml syringe and a 30G needle, totaling 1ml. The procedure was repeated after two weeks, with 80% regression of the lesion after 4 weeks. The patient remained without laboratory abnormalities or changes in their Child-Pugh score.

Conclusion

The use of intralesional chemotherapy in non-melanoma skin cancers is not a frequent practice and requires further studies for better standardization; however, there are case reports and systematic reviews that point to this therapeutic modality as an option when patients cannot or do not wish to undergo surgical excision, which remains the first-line treatment option.The emergence of neoplastic lesions during therapy with sorafenib is described in the literature, but its pathogenesis is not well elucidated. It is postulated that blocking the growth factor receptor (EGFR) pathway leads to increased activity of other pathways independent of EGFR blockade, as occurs in squamous cell carcinomas of the head and neck. Furthermore, there are in vitro studies that demonstrate that the drug exerts an inhibitory effect on T cells and dendritic cells, decreasing antigen presentation and leading

to a reduction in the effectiveness of the immune system in detecting cutaneous neoplasms. It is also hypothesized that proliferative keratinocytic skin lesions, specifically squamous-cell carcinomas, are generated due to a paradoxical activation of the mitogen-activated protein kinase (MAPK) signaling in the presence of a pre-existing mutation in *RAS*. The use of these drugs leads to the appearance of different skin reactions, which the dermatologist must be prepared to identify and institute appropriate therapy. The report of a rare skin reaction associated with effective treatment with intralesional methotrexate demonstrates that it is a minimally invasive technique with excellent cosmetic and clinical results, without interfering with the patient's oncologic treatment.

EADV CONGRESS
VIENNA
30 SEP - 3 OCT 2026

Abstract N°: 1161

A Case of Blastic Plasmacytoid Dendritic Cell Neoplasm Involving the Face and Legs

Seowon Song*[1], Subin Lee[1], Yejin Kang[1], Jung Eun Kim[1], Hoon Kang[1]

[1] Department of Dermatology, Eunpyeong St. Mary's Hospital, College of Medicine, The Catholic University of Korea, Seoul, Korea, Rep. of South

Introduction

Blastic plasmacytoid dendritic cell neoplasm (BPDCN) is a rare hematologic malignancy that can involve the bone marrow, peripheral blood, lymph nodes, central nervous system and skin. It accounts for less than 1% of primary cutaneous lymphomas in adults. Approximately 75-90% of patients across all age groups present with cutaneous involvement at diagnosis. These skin manifestations typically appear as solitary, localized, or generalized vascular plaques or tumors, most commonly on the head and neck or upper trunk. Many lesions exhibit a characteristic bruise-like violaceous hue. Herein, we report a case of BPDCN.

Case Presentation

A 68-year-old woman presented with purpuric lesions with a spreading tendency on the face and both lower extremities, accompanied by general weakness for 1 month. Physical examination revealed multiple asymptomatic violaceous macules, patches, and plaques. Her medical history included hypertension, dyslipidemia, hypothyroidism, and prior myocardial infarction, along with a 30-year smoking history. She had also been recently diagnosed with lupus nephritis was treated with pulse cyclophosphamide and corticosteroid therapy. Skin biopsies were performed on the right shin and cheek. Histopathologic findings revealed epidermal thinning and diffuse extravasation of red blood cells in the superficial papillary dermis, along with collagen degeneration. A diffuse infiltrate of medium-sized blast-like cells with slightly irregular nuclei, small nucleoli, and scant cytoplasm was observed throughout the dermis, extending into the subcutaneous tissue, with a prominent Grenz zone. Immunohistochemistry showed positivity for Bcl-2, CD68, Ki-67, CD4, CD123, and CD56, and negativity for CD3, CD5, CD20, MPO, CD34, CD117, and CD38. Peripheral blood smear revealed leukocytosis with 94% blasts. Bone marrow biopsy demonstrated positivity for CD123, CD303, CD304, CD4, and CD56, findings suggestive of BPDCN. Additionally, next-generation sequencing identified mutations in the TET2 and NRAS genes. Based on the clinical presentation and these findings, she was diagnosed with BPDCN. She was transferred to another hospital for chemotherapy but died shortly thereafter due to disease progression.

Conclusion

BPDCN is a rare and aggressive hematologic malignancy that frequently presents with cutaneous lesions mimicking benign dermatologic conditions. This case highlights the importance of early recognition of characteristic skin findings and the role of histopathologic and immunophenotypic evaluation in establishing the diagnosis. Despite prompt diagnostic workup, the disease may progress rapidly with a poor prognosis, underscoring the need for early diagnosis and timely therapeutic intervention.

EADV CONGRESS
VIENNA
30 SEP - 3 OCT 2026

Abstract N°: 1216

Cutaneous angiosarcoma arising in a background of multiple non-melanoma skin cancers

Styliani Kardoutsou*[1], Christina Kordali[1], Efstratios Fragkos[1], Asiminia Papadopoulou[1], Fiori Kousta[1], Eftychia Zouridaki[1], Leonidas Marinos[2], Vasiliki Chasapi[1]

[1] Dermatology Department, "Andreas Syggros" Hospital of Venereal and Dermatological Diseases, University of Athens, Athens, Greece., Athens, Greece
[2] Hematopathology Department, "Evangelismos" General Hospital, Athens, Greece, Athens, Greece

Introduction
Cutaneous angiosarcoma is a rare and aggressive vascular malignancy that frequently presents with nonspecific clinical features, often mimicking benign or inflammatory conditions. We present a case of cutaneous angiosarcoma in a patient with a medical history of multiple basal cell carcinomas (BCCs), many of them were surgically excised in the past, in order to highlight its diagnostic and therapeutic challenges.

Case Presentation
We report the case of a 85-year-old female patient with an extensive history of multiple basal cell carcinomas (BCCs) and repeated surgical excisions over two decades, who presented with progressive erythema and edema involving the right face, scalp and neck. During clinical examination, over 15 basal cell carcinomas (BCCs) were identified clinically, exhibiting typical dermoscopic features, located exclusively on the head and neck, along with extensive scarring from previously excised lesions,. Initial clinical suspicion favored infectious cellulitis, and the patient was treated with intravenous antibiotics without clinical improvement. Given the persistence and progression of symptoms, multiple biopsies were performed from the scalp, right lower eyelid, and right cheek. Differential diagnoses included chronic lymphedema secondary to multiple surgeries, co-existing squamous cell carcinoma, lymphatic carcinomatosis and connective tissue disease. Histopathological and immunohistochemical analysis ultimately confirmed the diagnosis of cutaneous angiosarcoma.

Conclusion
This case highlights the diagnostic complexity of angiosarcoma in chronically altered skin and underscores the importance of maintaining a high index of suspicion in atypical, treatment-resistant presentations, particularly in patients with significant oncologic and surgical histories.

EA DV CONGRESS
VIENNA
30 SEP - 3 OCT 2026

Abstract N°: 1230

Hypopigmented Mycosis Fungoides Revealed by Chronic Pruritus: An Unusual Presentation

Meryem El Moustaoui*[1], Hajar EL HASSANI TAIB[1, 1], Laila Benzekri[1]

[1] Ibn Sina University Hospital, Rabat, Morocco

Introduction

Mycosis fungoides is the most common form of cutaneous T-cell lymphoma, typically presenting with erythematous patches or plaques. The hypopigmented variant is a rare clinical form, often affecting young individuals and characterized by atypical presentations that may delay diagnosis.

Case Presentation

We report the case of an 18-year-old patient with no significant medical history, who presented with chronic pruritus evolving for one year. The patient initially consulted in a dermatology department, where a comprehensive workup for chronic pruritus was performed and returned normal. Despite symptomatic treatment, the pruritus persisted and remained refractory.

Given the persistence and unexplained nature of symptoms, a skin biopsy was performed, revealing histological features consistent with Mycosis fungoides. Subsequently, the clinical course was marked by the appearance of hypopigmented macules on the upper limbs and trunk. A second biopsy of these lesions confirmed the diagnosis of hypopigmented mycosis fungoides.

Mycosis fungoides is a cutaneous T-cell lymphoma classically presenting with patches and plaques, predominantly on non-photoexposed areas. However, it is well known as a “great mimicker” of inflammatory and infectious dermatoses due to its wide spectrum of clinical and histopathological presentations. These atypical forms may lead to significant diagnostic delay, requiring a high index of suspicion and close clinicopathological correlation. The World Health Organization recognizes several variants of MF, including folliculotropic MF, pagetoid reticulosis, and granulomatous slack skin, alongside other uncommon forms such as hypopigmented MF.

In our case, the presentation was particularly atypical, as chronic pruritus preceded the appearance of any visible skin lesions. This highlights an underrecognized feature of MF, especially in its hypopigmented variant, which commonly affects younger patients and may present with subtle or delayed cutaneous signs.

The subsequent development of hypopigmented macules, confirmed histologically as MF, supports the progressive nature of the disease and illustrates the diagnostic challenge in early stages. This case emphasizes that persistent, unexplained, and treatment-resistant pruritus should prompt reconsideration of the diagnosis and, when necessary, repeated skin biopsies.



Conclusion

This case highlights that pruritus may precede the onset of visible skin lesions inMycosis fungoides, particularly in its hypopigmented variant. It underlines the importance of careful and regular follow-up in patients with chronic pruritus, especially when resistant to conventional treatment, to avoid diagnostic delay.

EADV CONGRESS
VIENNA
30 SEP - 3 OCT 2026

Abstract N°: 1234

Zosteriform but Not Zoster: Cutaneous Metastasis of Breast Carcinoma Mimicking Herpes Zoster

Nurefsan Almacı*[1], Zeynep Özdemir[2], Zeki Arıcı[2], Vildan Manav[2], Cem Leblebici[3], Ayşe Esra Koku Aksu[2]

[1] Department of Dermatology and Venereology, University of Health Sciences, Istanbul Training and Research Hospital, Istanbul, Türkiye
[2] Department of Dermatology and Venereology, University of Health Sciences, Istanbul Training and Research Hospital, Istanbul, Türkiye, Istanbul, Türkiye
[3] University of Health Sciences, Istanbul Training and Research Hospital, Istanbul, Türkiye, Istanbul, Türkiye

Introduction

Cutaneous metastases are an important yet often misleading manifestation of breast carcinoma, with presentations that may mimic infectious or inflammatory dermatoses. Lesions with a zosteriform distribution are particularly prone to misdiagnosis as herpes zoster, potentially resulting in diagnostic delay. We present a case highlighting the diagnostic value of Tzanck cytology in antiviral-resistant zosteriform lesions.

Case Presentation

A 59-year-old woman with a history of invasive ductal breast carcinoma, treated surgically inOctober 2022, was referred to our clinic with lesions involving the left parasternal and thoracic regions. The eruption showed a dermatomal distribution and had been treated as herpes zoster with valacyclovir at an outside center, without clinical improvement. Dermatological examination revealed an infiltrative morphology with an atypical clinical pattern. Given the suspicion of malignancy, a Tzanck smear was performed prior to biopsy.Cytological analysis demonstrated clusters of atypical cells with prominent nucleoli and increased apoptotic activity, raising a strong suspicion of malignant infiltration. A punch biopsy was subsequently performed and confirmed cutaneous metastasis of breast carcinoma. Immunohistochemistry demonstrated GATA3 positivity, low-positive estrogen receptor expression (5% of tumor nuclei, strong intensity), progesterone receptor negativity, weak HER2 membranous expression, and a Ki-67 proliferation index of approximately 60%.

Conclusion

Cutaneous metastases most commonly present as nodules or plaques; however, zosteriformdistribution is uncommon and may lead to misdiagnosis as herpes zoster. In the present case, secondary impetiginization further obscured the clinical picture and complicated the diagnosis. Lack of response to antiviral therapy should prompt reconsideration of the diagnosis, particularly in patients with a known history of malignancy.GATA3 positivity and the hormone receptor profile support a breast origin, while the elevated Ki-67 index reflects aggressive tumor biology. Cytological findings on Tzanck smear—namely prominent nucleoli, cellular atypia, and increased apoptosis—correlate with high proliferative activity and tumor progression. Although Tzanck cytology is traditionally employed in the evaluation of infectious dermatoses, this case highlights its underrecognizedvalue in the rapid identification of malignant cells and in guiding subsequent diagnostic procedures.

Metastatic disease should be considered in the differential diagnosis of zosteriform andtreatment-resistant cutaneous lesions. Tzanck cytology represents a rapid, accessible, and underutilized diagnostic modality that can provide critical early diagnostic clues. This case emphasizes the potential for misleading clinical patterns and

highlights the importance of integrating cytological evaluation into dermatological practice to facilitate timely and accurate diagnosis.

EADV CONGRESS
VIENNA
30 SEP - 3 OCT 2026

Abstract N°: 1240

Chronic Arsenic Exposure from Well Water Presenting with Multiple Cutaneous and Pulmonary Squamous Cell Carcinomas: A Case Report

Simge Begümsu Çevik*[1], Melisa Ordu[1], Gizem Özge Öztürk Aktaş[1], Meltem Türkmen[1], Selcen Kundak[1]

[1] İzmir City Hospital, Ministry of Health, İzmir, Türkiye

Introduction

Arsenic is a chemical element implicated in the pathogenesis of various human malignancies. Arsenic-contaminated drinking water is a major global public health concern due to its widespread and toxicity. Chronic exposure to arsenic can play a significant role in the development of cancer and various other systemic disorders. Further studies have indicated that chronic arsenic exposure can lead to various cancers, including those of the skin, lung, liver, kidney and bladder. Dermatological manifestations may represent the initial presentation of chronic arsenic toxicity and include pigmentary changes, arsenical keratosis, and cutaneous malignancies. This study aims to highlight the relationship between chronic arsenic exposure and the development of multiple SCCs.

Case Presentation

A 61-year-old male presented with a long-standing history of multiple cutaneous lesions predominantly affecting acral areas. The patient had a documented history of chronic arsenic exposure due to prolonged well water consumption, confirmed by elevated arsenic levels in urine samples. Dermatological examination revealed widespread involvement of the dorsal hands, forearms, lower extremities, and lateral neck. Numerous hyperkeratotic papules and plaques (few millimeters to 1–2 cm) with verrucous surfaces were observed. Prominent palmoplantar keratoses were present. Several lesions exhibited malignant features, including nodular and ulcerated tumors with irregular and infiltrative borders. The surrounding skin showed xerosis, mottled hyperpigmentation, and hypopigmented macules, consistent with chronic toxic exposure.
Histopathological Findings:
Multiple biopsies demonstrated a spectrum of lesions: actinic keratosis and arsenical keratosis-like changes on the palm and dorsal hand; atypical squamous proliferation on the elbow; invasive SCC on the dorsum of the hand; and SCC in situ on the foot. Neck excisions revealed actinic keratosis, well-differentiated invasive SCC, and SCC in situ.
Systemic evaluation showed extracutaneous involvement. Lung tru-cut biopsy confirmed non-small cell lung carcinoma consistent with SCC, while right axillary lymph node excision revealed metastatic SCC.

Conclusion

This case highlights the carcinogenic potential of chronic arsenic exposure due to long-term well water consumption. The coexistence of multiple cutaneous and pulmonary SCCs, along with nodal metastasis, underscores the importance of early recognition of arsenical dermatoses. Clinicians should maintain a high index of suspicion in patients with multiple or atypical skin cancers, particularly in regions where well water use is common. Early diagnosis is essential for appropriate management and surveillance of associated internal malignancies.

EA DV CONGRESS
VIENNA
30 SEP - 3 OCT 2026

Abstract N°: 1260

Trichilemmal Horn Arising from a Trichilemmal Cyst: A Case Report

Júlia Bittencourt*[1], Isadora Schmidt[1], Julia Loureiro Fontana Bolsoni[1], elisandre maria camelo gomes natario Natario[1], Samara Rabay[1], Elisangela Andraus[1], Flávia Regina Ferreira[1]

[1] TAUBATE UNIVERSITY MUNICIPAL HOSPITAL, TAUBATÉ, Brazil

Introduction

Trichilemmal horn is an uncommon benign follicular neoplasm with trichilemmal differentiation. The essential characteristics of the tumor are its clinical presentation as a cutaneous horn and its histology, which shows trichilemmal keratinization at the base of the lesion. It was first described in 1976 by Headington, who named the lesion trichilemmal keratosis. The term trichilemmal horn was later coined by Brownstein in 1979, in a study that described 19 cases and defined its essential characteristics.

Trichilemmal horns can develop at any age, although they are more common after the age of 50 and more frequent in women. Lesion size varies, usually ranging from 1 to 2 cm in diameter, although larger cases have been reported.

Case Presentation

A 41-year-old female patient, Fitzpatrick phototype IV, working as a cleaning assistant, originally from Brazópolis-MG and living in Campos do Jordão-SP, presented with a complaint of a scalp lesion that had not healed for 3 years.

On dermatological examination, a yellowish conical keratotic projection in the shape of a horn was observed on the right frontoparietal scalp over an erythematous infiltrated base. In the left parieto-occipital region, two nodules covered by normal skin were observed, with cystic consistency, mobile and slightly painful on palpation.

The patient reported that 3 years earlier she had undergone excision of two scalp lesions; however, one of them did not heal and evolved with formation of a cutaneous horn. She denied having received the histopathological results of the excised lesions.

Past medical history included systemic arterial hypertension treated with captopril and epilepsy treated with phenobarbital and carbamazepine. She denied smoking and alcohol use.

The main diagnostic hypothesis was a cutaneous horn overlying squamous cell carcinoma. An incisional biopsy of the lesion base was performed along with excision of the cutaneous horn.

Histopathological examination showed material composed of hyperkeratosis and a trichilemmal cyst, without signs of malignancy, establishing the diagnosis of a trichilemmal cyst underlying a cutaneous horn (trichilemmal horn).

The possibility that human papillomavirus (HPV) may be involved in the pathogenesis of this tumor has been discussed, as intranuclear inclusion bodies morphologically similar to HPV have been found in several electron microscopy studies of the neoplasm. Poblet et al. described 2 cases in which, as in our case, the lesion developed after attempted treatment of a preexisting trichilemmal cyst. Also as in our case, the patients had a personal history of multiple trichilemmal cysts. The authors concluded that in some cases this tumor may be caused by

rupture of the wall of a trichilemmal cyst

Complete excision of the remaining lesion was performed. The patient had a good cosmetic outcome, with no recurrence to date, and remains under outpatient follow-up for planned excision of the remaining nodules.

Conclusion

Trichilemmal horn may be associated with a preexisting trichilemmal cyst and may arise after attempted treatment, possibly related to rupture of the cyst wall. In such cases, the epithelium may continue to proliferate, resulting in an exophytic lesion with cutaneous horn morphology.

Treatment is based on complete excision of the lesion. In cases of cyst rupture, an inflammatory reaction with foreign body granuloma formation may occur. Recurrence after incision is low, similar to that observed in epidermal cysts.

EADV CONGRESS
VIENNA
30 SEP - 3 OCT 2026

Abstract N°: 1261

The use of LC-OCT in planning surgical margins of basal cell carcinoma in post-radiation scar – a case report.

Aleksandra Anderson*[1], Maria Molska[2], Joanna Czuwara[1], Lidia Rudnicka[1]

[1] Department of Dermatology, Medical University of Warsaw, Warsaw, Poland

[2] Department of Plastic Surgery, Centre of Postgraduate Medical Education, Warsaw, Poland

Introduction

Basal cell carcinoma (BCC) is the most common skin cancer. BCC rarely metastasize, yet its' slow growth can lead to severe destruction of underlying tissues. Carcinogenesis can be triggered by several factors, including UV and x-ray radiation. The diagnosis of BCC in scar tissue remains a clinical challenge, as they share similar dermoscopic features, for example presence of arborizing vessels. The line-field confocal optical coherent tomography(LC-OCT) is a novel non-invasive skin imaging technique. It allows visualization of the epidermis and dermis at a cellular level in both vertical and horizontal planes, hence can be compared to "virtual biopsy". Over past years, there has been an increasing data that LC-OCT surpasses the dermoscopy in sensitivity and specificity in BCC diagnosis. Furthermore, some authors suggest its usefulness in establishing margins for surgical excision, comparing the method to "virtual Mosh" surgery. In this case, we present the use of LC-OCT in diagnosis and planning surgical margins in patient with BCC originating from post-radiation scar.

Case Presentation

72-year old patient with the history of multiple BCCs, was admitted to the Outpatients Clinic at the Department of Dermatology, Medical University of Warsaw due to rapidly growing nodule on her philtrum**.** Upon dermoscopy, classical arborizing vessels and central ulceration rose the suspicion of nodular BCC and, therefore, patient was referred for surgical excision. Nodular BCC was confirmed in histopathology. At 1-month follow-up visit, in the proximity of excised tumor, small nodules in post-radiation scar due to hemangioma treatment in childhood were noted. The lesion covered whole upper lip region skin on the left side. Dermoscopy revealed brown globules and spoke-wheel like structures, the LC-OCT showed small lobules with "millefeuille" pattern and visible clefting without connection to the epidermis, corresponding to BCC, divided by hyper-reflective stroma. Due to limited access to Mosh surgery in Poland, LC-OCT was used to establish the surgical margins. The patient was referred to the Department of Plastic Surgery, where the excision on the lesion with subsequent nasolabial flap reconstruction was performed. Thanks to the use of LC-OCT, surgical margins were tumor-free and patient recovered with satisfying visual effect.

Conclusion

The histopathology remains a golden standard for the diagnosis of skin cancers, nonetheless LC-OCT is a useful tool in differential diagnosis of BCC, especially in challenging cases. In the presented case, LC-OCT facilitated the diagnosis of BCC in post-radiation scar and was used to plan surgical margins. Thanks to the use of the technique, the cooperation between dermatologist with plastic surgeon resulted in tumor-free excision and satisfying visual effect.

EA DV CONGRESS
VIENNA
30 SEP - 3 OCT 2026

Abstract N°: 1261

Granuloma Annulare and malignancy- a population based study

Eran Shavit*[1], Yizhak Confino[2], Liat Lev-Shalem[3]

[1] Gray faculty of Medical and Health Sciences, Gray School of Medicine, Tel-Aviv University, Tel-Aviv, Israel, Holon, southern disrict of Tel-Aviv, Israel

[2] Wolfson medical center, Holon, Israel

[3] Health Division, Maccabi Healthcare Services, 27 Ha'mered St., Tel Aviv, Israel., Tel Aviv, Israel

Introduction

Granuloma annulare (GA) is a benign inflammatory cutaneous disease, characterized clinically with annular plaques without epidermal changes, presenting most commonly on the back of hands, elbows. The most common presentation is of a solitary asymptomatic lesion, however, other presentations are also possible including to sun exposed areas etc.. also seldom, lesions are widespread and not solitary, and this may lead to great discomfort and stigmatization. The etiology of GA is unknown. GA has been associated to other clinical illnesses and conditions such as diabetes and dyslipidemia. Little is known, whether there is an association to neoplastic diseases. And only anecdotal reports discussed such potential link, this is essential to know, since monitoring this patient might be important.

Materials and Methods

A population-based retrospective cohort study, using de-identified data from Maccabi Healthcare Services' (MHS) computerized database, Israel's second-largest healthcare provider, which covers a quarter of the country's population with nationwide distribution and an annular turnover of less than 1%. Medical charts of patients with GA in MHS recorded between 01/2000 to 12/2024. Included in the study were only adult patients older than 18 years of age. Their demographics including gender, age and socioeconomic state were matched to control without the diagnosis of GA.

Results

A population-based retrospective cohort study, using de-identified data from Maccabi Healthcare Services' (MHS) computerized database. MHS is Israel's second-largest healthcare provider, which covers a quarter of the country's population with nationwide distribution and an annular turnover of less than 1%. Included in the study were medical charts of patients with GA in MHS between 01/2000 to 12/2024. Included in the study were only adult patients older than 18 years of age.

The study was composed of 2,817891individuals, of which 13,264 cases of GA, and 2,804627 controls. After selection omitting enrollees less than a year in MHS and those patients with prior GA diagnosis and without SES characterization, which is part of the matching characteristics, the study included 12,506 participants in the GA group and 37,518 in the control non-GA group . Each examinee with GA was matched 1: 3 in age, sex and socioeconomic status (SES) matched controls . The cases were examined with neoplastic diseases based on ICD-10 coding. The two groups were matched by age at diagnosis, gender and socioeconomic status hence identical with respect to those characteristics (all $p = 1.000$). Approximately 46% of participants were aged 41–60 years, about 70% were female, and nearly 62% were of high socioeconomic status in both groups.

The GA study group had a higher prevalence of malignant neoplasms of bone, connective tissue, skin, and breast (0.5% vs. 0.3%, $p < 0.001$), as well as a higher prevalence of any cancer recorded in the MHS registry (8.5% vs. 6.8%, $p < 0.001$). Pre-existing dyslipidemia was also substantially more common in the GA group (39.9% vs. 30.3%, $p < 0.001$), as was diabetes (13.6% vs. 9.0%, $p < 0.001$). Malignant neoplasms of digestive organs and peritoneum were slightly less common in the GA group (0.2% vs. 0.3%, $p = 0.001$). No significant differences were observed for genitourinary malignancies ($p = 0.668$), leukemia ($p = 0.204$), malignant neoplasms of the lip, oral cavity, and pharynx ($p = 0.662$), respiratory and intrathoracic malignancies ($p = 0.408$), or lymphatic and hematopoietic malignancies ($p = 0.067$). Although several differences reached statistical significance, most individual cancer types were rare in both groups.

Conclusions

GA is relatively uncommon disease. Our study exhibited a higher prevalence of malignant neoplasms of bone, connective tissue, skin, and breast, as well as a higher prevalence of any cancer recorded in the MHS registry. To the best of our knowledge this is the largest population-based study on GA thus far, examining the association to neoplastic diseases.

EA DV CONGRESS
VIENNA
30 SEP - 3 OCT 2026

Abstract N°: 1280

Primary Cutaneuous Marginal Zone B-Cell Lymphoma Presenting as a Pruritic SolitaryNodule After an Insect Bite: A Case Report

Ahmet Emre Avcı*[1], Faruk Enikonu[1], Zeki Arıcı[1], Cem Leblebici[2], Ayşe Esra Koku Aksu[1]

[1] Department of Dermatology, Istanbul Research and Training Hospital, Istanbul, Türkiye
[2] Department of Pathology, Istanbul Training and Research Hospital, Istanbul, Türkiye

Introduction

Primary cutaneous marginal zone B-cell lymphoma (PCMZL) is an indolent extranodal B-cell lymphoma limited to the skin at diagnosis. It usually presents as erythematous to violaceous papules, plaques, or nodules on the trunk or upper extremities. Because it may clinically mimic benign reactive lesions, histopathologic and immunophenotypic evaluation with systemic staging is essential for diagnosis.

Case Presentation

Case Presentation:A 59-year-old man presented with a 1-month history of a pruritic swelling on the left forearm. Dermatologic examination revealed a solitary, approximately 2 cm erythematous subcutaneous nodule on the extensor surface of the left forearm. The patient reported that the lesion had developed after an insect bite. The clinical differential diagnosis included calcified epidermoid cyst, foreign body granuloma, pseudolymphoma, and lipoma. An excisional biopsy was performed.

Histopathologic examination showed a preserved epidermis and a subepidermal grenz zone, beneath which a nodular and diffuse atypical lymphoid infiltrate extended throughout the dermis into the subcutaneous tissue. The infiltrate was composed predominantly of small- to medium-sized atypical lymphoid cells with irregular hyperchromatic nuclei, admixed with a few large immunoblast-like cells, histiocytes, and mature lymphocytes. Immunohistochemically, the atypical cells were positive for CD20 and BCL2, whereas CD30, CD4, BCL6, CD10, CD8, CD23, CD5, and CD7 were negative. CD21 and CD23 did not reveal a follicular dendritic cell meshwork. Ki-67 showed low proliferative activity. Although light chain restriction was not demonstrated, the overall morphologic and immunophenotypic findings favored marginal zone lymphoma over reactive cutaneous lymphoid hyperplasia.

Systemic evaluation revealed no palpable lymphadenopathy, hepatosplenomegaly, B symptoms, or atypical cells on peripheral smear. Serum immunofixation showed no monoclonal band, immunoglobulin levels were within normal limits, and LDH was normal. PET imaging demonstrated no pathologic hypermetabolic lesion in the arm or elsewhere. Because iron deficiency anemia was detected, upper gastrointestinal endoscopy and colonoscopy were also performed and were unremarkable. Since the initial excision showed focal margin involvement, re-excision was performed, and no residual lesion was identified. The patient was diagnosed with primary cutaneous marginal zone B-cell lymphoma without systemic involvement.

Discussion: PCMZL is a low-grade cutaneous B-cell lymphoma with an excellent prognosis. However, it may present as a solitary lesion and mimic benign or reactive conditions, particularly when associated with a history suggestive of an insect bite or other inflammatory trigger. In the present case, the initial clinical impression favored benign entities, whereas histopathologic and immunophenotypic findings established the diagnosis of PCMZL.

The preserved grenz zone, dermal and subcutaneous B-cell infiltrate, CD20 and BCL2 positivity, low proliferative index, and absence of systemic disease supported the diagnosis. Although monotypic light chain expression was not demonstrated, the morphology and immunophenotype were considered diagnostic in the appropriate clinicopathologic context. This case underlines the importance of considering PCMZL in persistent nodular lesions that do not fit perfectly with common benign diagnoses.

Conclusion

PCMZL should be included in the differential diagnosis of persistent solitary nodules, even when the clinical history suggests a reactive process such as an insect bite. Accurate diagnosis relies on clinicopathologic correlation and appropriate systemic staging. Early recognition of this rare but indolent lymphoma allows proper treatment and confirms its favorable prognosis.

EADV CONGRESS
VIENNA
30 SEP - 3 OCT 2026

Abstract N°: 1284

Blastic Plasmacytoid Dendritic Cell Neoplasm in a 6-Year-Old Boy: Cutaneous Presentation, Diagnosis, and Response to CHOP

Hussein Hassabelnaby[1], Mohamed El-Khalawany[1], Mahmoud Rageh*[1]

[1] Department of Dermatology, Faculty of Medicine, Al-Azhar University, Cairo, Egypt

Introduction

Blastic plasmacytoid dendritic cell neoplasm (BPDCN) is a rare and aggressive hematologic malignancy with frequent cutaneous involvement. It occurs predominantly in older adults and is exceptionally uncommon in children. Early recognition of its skin manifestations is critical because diagnosis may first be suggested by dermatologic examination.

Case Presentation

A 6-year-old boy presented with a 10-month history of gradually progressive, asymptomatic multiple dusky-red nodules and plaques involving the face, neck, trunk, and upper and lower limbs. Examination also revealed multiple enlarged, non-tender left inguinal lymph nodes. Laboratory investigations showed anemia, thrombocytopenia, and elevated ESR. Abdominal ultrasonography demonstrated mild splenomegaly. Histopathological examination of a skin biopsy showed diffuse dermal infiltration separated from the epidermis by a narrow grenz zone. The infiltrate was most prominent in the deep dermis and displayed patchy and interstitial distribution. The infiltrating cells were large, with pale cytoplasm, atypical nuclei, scattered mitoses, and admixed numerous plasma cells. Immunohistochemistry was positive for CD3, CD4, CD43, CD56, and CD123. Based on the clinicopathological findings, BPDCN was suspected. Bone marrow biopsy with immunohistochemistry confirmed the diagnosis. The patient was referred to pediatric oncology and started on CHOP chemotherapy, with marked clinical improvement after 4 cycles.

Conclusion

BPDCN should be considered in children presenting with unexplained multiple violaceous or dusky-red cutaneous nodules and plaques, particularly when accompanied by cytopenias or lymphadenopathy. This case highlights the pivotal role of dermatologic assessment and skin biopsy in the early recognition of this rare but aggressive neoplasm.

EA DV CONGRESS
VIENNA
30 SEP - 3 OCT 2026

Abstract N°: 1306

Skin Sentinels Unveiled: Cutaneous Metastases as Harbingers of Occult Neoplasms

Majd Abu Taleb*[1], Nesrine Ben Salah[1], Samiha Mabrouk[2], Seif Ben Hammouda[2], Wajih Ghribi[3], Nader Slama[4], Youssef Monia[1], Hichem Belhadjali[1], Jameleddine Zili[1]

[1] Dermatology Department, Fattouma Bourguiba University Hospital, Monastir, Tunisia
[2] Anatomopathology Department, Fattouma Bourguiba University Hospital, Monastir, Tunisia
[3] Pulmonology Department, Fattouma Bourguiba University Hospital, Monastir, Tunisia
[4] Hematology Department, Fattouma Bourguiba University Hospital., Monastir, Tunisia

Introduction
Secondary cutaneous involvement by malignant neoplasms is an uncommon but clinically significant manifestation of both solid tumors and hematologic malignancies, often associated with an unfavorable prognosis. Cutaneous lesions may represent the first sign of an underlying cancer or occur during disease progression or relapse. We report a series of patients presenting with secondary cutaneous neoplastic lesions either revealing an underlying malignancy or developing during the course of solid and hematologic cancers.

Materials and Methods
We conducted a retrospective monocentric study including all patients diagnosed with secondary cutaneous neoplastic involvement between 2016 and 2025.

Results
Fifteen patients were included (9 men and 6 women; mean age: 56 years; male-to-female ratio = 1.5). Cutaneous involvement revealed the underlying malignancy in 53.3% of cases (n = 8), occurred during oncologic follow-up in 26.6% (n = 4), and appeared at relapse in 20% (n = 3). Clinically, lesions presented as erythematous–violaceous infiltrated plaques in 46.6% (n = 7), ulcerative-vegetating lesions in 13.3% (n = 2), and nodules in 40% (n = 6). They were asymptomatic in 60% of cases. The most frequent sites were the head and neck (40%, n = 6), followed by the breast (20%, n = 3), scrotum (13.3%, n = 2), and lower limbs (26.6%, n = 4). Underlying neoplasms included T- or B-cell lymphomas in 46.6% (n = 7), among which three were relapses of diffuse large B-cell lymphoma, one hematologic malignancy consistent with leukemia (6.6%, n = 1), and solid tumors including lung cancer (13.3%, n = 2), breast cancer (13.3%, n = 2), colon cancer (6.6%, n = 1), bladder cancer (6.6%, n = 1), and melanoma (6.6%, n = 1). Median survival was 8 months when cutaneous involvement was revealing, compared to 6 months in relapse cases, suggesting a poorer outcome in the latter context.

Conclusions
Secondary cutaneous neoplastic involvement exhibits marked clinical heterogeneity and serves as a pivotal diagnostic and prognostic marker in oncology. In our series, over half of presentations were inaugural, manifesting predominantly as infiltrated plaques, nodules, or ulcerative-vegetating masses on the head, neck, and thorax, morphological and topographical patterns that often mirror the underlying malignancy, particularly lymphomas and carcinomas of the breast and lung.

Critically, cutaneous lesions arising at relapse were associated with significantly shorter median survival, underscoring their value as indicators of heightened tumor aggressiveness and advanced systemic dissemination. These findings establish secondary cutaneous metastases not merely as dermatological findings but as actionable clinical signals: their early recognition should trigger comprehensive diagnostic work-up, refine staging accuracy, and inform therapeutic stratification. For dermatologists, this reinforces the specialty's essential role in multidisciplinary cancer care, where prompt identification of neoplastic skin involvement can alter diagnostic pathways, optimize systemic management, and ultimately influence patient outcomes. Integrating dermatological assessment into oncologic algorithms represents a translational opportunity to enhance precision medicine in patients with solid tumors and hematologic malignancies.

EA DV CONGRESS
VIENNA
30 SEP - 3 OCT 2026

Abstract N°: 1309

Explainable Logistic Regression Using Texture-Based Features Extracted from Reflectance Confocal Microscopy for Skin Cancer Subtyping

Birsen Naz Karadayı*[1], Muhammed Arya[2], Ece Gökyayla[3], Banu Yaman[4], Isil Kilinc Karaarslan[3]

[1] Bulanık State Hospital, Muş, Türkiye
[2] Ege University Faculty of Medicine, İzmir, Türkiye
[3] Department of Dermatology and Venereology, Ege University Faculty of Medicine, İzmir, Türkiye
[4] Department of Pathology, Ege University Faculty of Medicine, İzmir, Türkiye

Introduction
Reflectance confocal microscopy (RCM) enables non-invasive, cellular-level assessment of skin cancers and has emerged as a valuable adjunctive imaging modality in dermatologic oncology. However, the grayscale nature of RCM images, together with frequent imaging artefacts, renders visual interpretation subjective, time-intensive, and highly operator-dependent. Moreover, explainable quantitative models capable of distinguishing basal cell carcinoma (BCC), squamous cell carcinoma (SCC), and malignant melanoma (MM) remain scarce. This study aimed to evaluate whether texture-based quantitative features extracted from RCM images could support the differential diagnosis of BCC, SCC, and MM within an interpretable, probability-based classification framework.

Materials and Methods
In this retrospective single-center study, 31,801 RCM optical sections derived from 175 histopathologically confirmed lesions (60 BCC, 40 SCC, and 75 MM) were analyzed. For each image, 165 quantitative features were extracted, including first-order intensity statistics, gray-level co-occurrence matrix-based texture parameters, and edge- and frequency-domain descriptors. An L1-regularized multinomial logistic regression model was developed using a class-balanced training set. Model performance was evaluated on an independent hold-out test set preserving real-world class prevalence. In addition, isotonic calibration was applied to improve the reliability and interpretability of class probability estimates.

Results
On the independent test set, the model achieved an overall accuracy of 41.3%, a top-2 accuracy of 79.3%, and a macro one-vs-rest area under the curve (AUC) of 0.61. Sensitivity was 0.74 for BCC, 0.46 for MM, and 0.18 for SCC, with the majority of misclassifications occurring between MM and SCC. Importantly, the sparse coefficient profiles identified by the model linked distinct quantitative signatures to established RCM morphologic patterns, such as increased entropy and homogeneity in BCC and greater intensity variance and local contrast in MM. These findings suggest that the model provides an interpretable quantitative framework that may complement conventional visual assessment.

Conclusions
Texture-based quantitative analysis of RCM images, implemented through an explainable L1-regularized logistic regression model, shows potential as a calibrated decision-support approach for skin cancer subtyping. In particular, it may assist in prioritizing BCC-like morphologic patterns and refining the differential diagnosis of diagnostically challenging melanocytic lesions, rather than serving as a substitute for histopathology or expert evaluation. Nevertheless, the findings should be interpreted in the context of the retrospective single-center

design, reliance on a single RCM platform, section-level rather than lesion-level analysis, the relatively limited representation of SCC, and the absence of integrated clinical, dermoscopic, and demographic data.

EADV CONGRESS
VIENNA
30 SEP - 3 OCT 2026

Abstract N°: 1311

Melanoma Prevention Awareness and Behaviors: A Comparative Cross-Sectional Study Between the Residents of Lithuania and Taiwan

Patricija Šmigelskaitė*[1], Augustė Senulytė[1], Tadas Raudonis[1]

[1] Clinic of Infectious Diseases and Dermatovenereology, Vilnius University Faculty of Medicine, Vilnius, Lithuania

Introduction
Melanoma is the most lethal form of skin cancer, accounting for the majority of skin cancer-related deaths worldwide. Its incidence continues to rise globally, with ultraviolet (UV) radiation exposure recognized as the main modifiable risk factor. However, attitudes toward tanning and sun protection vary across cultures. This study aimed to compare melanoma-related knowledge and sun-protective behaviors between residents of Lithuania (LT) and Taiwan (TW), and to evaluate the influence of sociodemographic factors on these outcomes.

Materials and Methods
A comparative cross-sectional study was conducted between October 2025 and March 2026. A total of 918 participants (Lithuania n=471; Taiwan n=447) were recruited via convenience sampling through social media platforms and institutional networks. Data were analyzed using IBM SPSS Statistics (version 30.1). Group differences were assessed using the Mann–Whitney U test for continuous variables and Pearson's chi-square test for categorical variables. Binary logistic regression analysis was performed to identify predictors of melanoma-related knowledge and preventive behaviors, adjusting for key sociodemographic variables. Statistical significance was defined as $p < 0.05$.

Results
The mean age of the LT respondent group was 28 years (SD=8.7), compared to 26 years (SD=6.7) for the TW group. A higher level of education was significantly more prevalent among TW respondents (91.7%; n=410) than among LT respondents (52.2%; n=246) ($p<0.001$). Melanoma-related knowledge was also significantly higher in TW respondents (90.2%; n=403) than in LT respondents (66.2%; n=312) ($p<0.001$). Logistic regression showed that TW respondents had higher odds of having melanoma knowledge (OR = 2.2, $p=0.018$) and of being aware of UV exposure during cloudy conditions (OR = 4.4, $p<0.001$). A reported family history of melanoma was significantly more frequent among LT respondents (13.8%, n=65) than among TW respondents (4.5%, n=20) ($p<0.001$). The distribution of skin phototypes differed significantly: phototype II was more frequently identified in LT (31.2%; n=147), while phototype III predominated in TW (78.1%; n=349) ($p<0.001$). TW respondents reported more frequent use of sun-protective measures, including headgear, long-sleeved clothing, sunglasses, and daily sunscreen application (47.7%; n=213). In contrast, LT respondents more often reported intermittent sunscreen use, mainly during holidays (57.5%; n=271) ($p<0.001$). Risky sun-related behaviors were more common in LT: 23.6% (n=111) of respondents intentionally tanned for longer than two hours, and 47.8% (n=225) perceived a tanned body as more attractive. LT respondents were significantly less likely to use skin-lightening products (83%, n=391) than those in TW (47%, n=210) ($p<0.001$). However, TW reported a higher rate of regular use of self-tanning products (10.1%, n=45) than LT (2.1%, n=10) ($p < 0.001$). The proportion of respondents who had never experienced a sunburn was significantly higher in TW (20.6%; n=92) than in LT (4.9%; n=23). LT respondents were also more likely to have consulted a dermatologist for skin lesions and moles (41.8% vs. 26.8%) ($p<0.001$).

Conclusions

Taiwanese respondents demonstrated higher levels of melanoma-related awareness and more consistent sun-protective behaviors compared to Lithuanian respondents. In contrast, Lithuanian residents exhibited more frequent risky sun-related behaviors, driven by a higher aesthetic preference for tanned skin. These differences may reflect underlying sociocultural influences on health behavior. The findings highlight the need for culturally tailored public health strategies to promote sun-safe behaviors.

EADV CONGRESS
VIENNA
30 SEP - 3 OCT 2026

Abstract N°: 1316

Real-world efficacy and safety of Sonidegib and Cemiplimab in advanced cutaneous carcinomas: a single-center observational study.

Chiara Del Re*[1], Vincenzo Filastro[1], Gaia Fasano[2], Teresa Del Giudice[3], Giancarlo Valenti[4], Pierfrancesco De Giacomo[2]

[1] Magna Græcia University, Catanzaro, Italy

[2] Azienda Ospedaliera di Catanzaro Pugliese Ciaccio, Catanzaro, Italy

[3] Ospedale Ciaccio Presidio 'De Lellis', Catanzaro, Italy

[4] Hospital Pugliese Ciaccio, Catanzaro, Italy

Introduction

Sonidegib (a Hedgehog inhibitor) and cemiplimab (an anti-PD-1) represent two pillars in the treatment of advanced cutaneous carcinomas not amenable to surgery or radiotherapy. The aim of this study was to evaluate, in a real-world setting, the efficacy, safety, and potential factors correlated with treatment response.

Materials and Methods

A single-center observational study was conducted on 29 patients (mean age: 71.8 years): 17 treated with sonidegib and 12 with cemiplimab. Data collected included: clinical characteristics, number of previous surgical and medical treatments, comorbidities, adverse events (AEs, grades 1–3), and response outcomes (complete, partial, stable, or progression). In patients with multiple BCCs/SCCs, the DeltaBCC/DeltaSCC (difference between initial and final lesion count) was also calculated.

Results

Overall, 15/29 patients achieved a complete response, 10/29 a partial response, and 3/29 stable disease; no cases of progression were recorded during or after treatment discontinuation.

- **Multiple Lesions:** In the 12 patients with multiple BCCs, the mean DeltaBCC was 6.17 (50% reduction in lesion count), with a peak response of one patient moving from 15 lesions to 0. In the 4 patients with multiple SCCs, the mean DeltaSCC was 6.25 (61% reduction).
- **Safety:** 10/29 patients reported no AEs. Among the 19 symptomatic patients, 68.4% developed Grade 1 AEs, 26.3% Grade 2, and 5.3% Grade 3 (one fatal rhabdomyolysis with cemiplimab). AEs were more frequent with sonidegib but mostly mild and reversible (myalgias, dysgeusia, actinic keratoses, and one case of visual hallucinations leading to discontinuation). Cemiplimab AEs were less frequent but occasionally more severe (post-infusion fever, gastrointestinal hemorrhage).
- **Correlations:** Better clinical response was associated with younger age, longer treatment duration, and fewer previous surgeries. In the sonidegib group, a trend toward better response was observed in patients experiencing more AEs

Conclusions

In our single-center experience, sonidegib and cemiplimab are confirmed as effective and generally well-tolerated options for advanced cutaneous carcinomas, with a significant impact even on multiple BCCs. These data support the use of systemic therapies in elderly, heavily pre-treated patients, reducing the need for repetitive surgery and improving disease control in the medium and long term.

EA DV CONGRESS
VIENNA
30 SEP - 3 OCT 2026

Abstract N°: 1318

Leiomyosarcoma of the nail bed: a rare malignant tumor of the nail unit

Felipe Middleton*[1], Luiza d'Almeida[1], Ana Clara Braga[1], Fernando Belles de Moraes[1], Andreia Leverone[1]

[1] Instituto de Dermatologia Professor Rubem David Azulay, Rio de Janeiro, Brazil

Introduction

In the evaluation of ulcerated subungual tumor lesions, a wide range of tumors must be considered in the differential diagnosis. However, soft tissue tumors are often mistakenly overlooked due to their rarity. Leiomyosarcoma (LMS) is a rare malignant neoplasm of smooth muscle origin, typically arising from vascular structures or visceral organs. Superficial LMS is an uncommon type that develops in the dermis or hypodermis and is further classified as cutaneous (dermal) or subcutaneous LMS, respectively [1]. These tumors are rarely reported, and to our knowledge, only one other case of LMS arising in the nail bed has been described [2].

Case Presentation

A 54-year-old male patient, Fitzpatrick skin phototype IV, presented with a two-year history of a painful tumor located in the nail bed of the left hallux. He reported onset following local trauma. The nail had been previously avulsed, and the lesion excised at an external center; no specimen was submitted for histopathological evaluation, with subsequent recurrence of the lesion. Physical examination revealed a 3-cm erythematous tumoral lesion at the nail bed, with partially necrotic tissue and purulent exudate, associated with complete onycholysis. Foot radiography showed radiolucent areas with sclerotic borders in the distal phalanx of the hallux, associated with increased volume and density of the adjacent soft tissues. Incisional biopsy showed dermal–hypodermal proliferation of monomorphic spindle cells in fascicles, with frequent mitoses and mild–moderate atypia. Tumor cells were SMA and desmin positive, supporting smooth muscle differentiation and favoring FNCLCC grade 2 LMS. Toe amputation was performed

Conclusion

Superficial LMS is a rare cutaneous neoplasm, representing ~ 2–3% of cutaneous sarcomas. They may arise from dermal smooth muscle structures including arrector pili, sweat gland musculature, dartos and areolar muscles, or from vascular smooth muscle cells in subcutaneous tissue [2, 3, 4]. We report a case occurring in the nail bed, a very uncommon location likely arising from subcutaneous vascular smooth muscle, as this anatomical site lacks dermal structures capable of generating it. Evidence suggests multiple possible cells of origin, including mesenchymal stem cells, pericytes and vascular smooth muscle cells, with differentiation toward smooth muscle modulated by genomic alterations [5]. Subcutaneous LMS most often occurs in lower extremities and affects patients aged 60-80, with a peak incidence in older adults - differing from this case. Clinically, LMS present as painful, slow-growing pink, erythematous or brownish nodules. In recent years, imaging modalities - particularly high-frequency color Doppler ultrasound - are valuable for preoperative differential diagnosis [2]. Definitive diagnosis relies on histopathology with immunohistochemistry. Soft tissue sarcomas are graded by the FNCLCC system, also applied to LMS. Histologically, LMS are highly cellular neoplasms of atypical spindle-shaped cells with fibrillary, eosinophilic cytoplasm and enlarged, hyperchromatic, irregular nuclei, often showing increased mitotic activity, including atypical mitotic figures. Cells are arranged in fascicles, bundles, or nests, and areas of tumor necrosis may also be present. Immunohistochemically, cells co-express α-smooth muscle actin, desmin and h-

caldesmon [4]. Superficial LMS are typically treated with radical surgical excision, generally without the need for adjuvant radiotherapy, with close follow-up recommended. A Danish cohort (661 patients) suggests that grade 2 and 3 subcutaneous LMS should be classified as high-risk sarcomas, with a substantial risk of metastasis and poor overall survival [6]. Despite its rarity, early recognition is essential for appropriate management and reducing recurrence and metastasis.

EA DV CONGRESS
VIENNA
30 SEP - 3 OCT 2026

Abstract N°: 1334

A Long-standing Erythematous Nodule on the Foot: Diagnostic Challenges in Amelanotic Melanoma

Diana Muja*[1], Ermira Vasili[1]

[1] Medicine University of Tirana, Tirana, Albania

Introduction

Background Amelanotic melanoma (AM) is a rare variant of cutaneous melanoma characterized by a lack of pigment, often leading to significant diagnostic delays. Its clinical presentation frequently mimics benign cutaneous conditions, including pyogenic granulomas, hemangiomas, and dermatofibromas. Furthermore, the absence of classic dermoscopic pigment networks and streaks renders dermatoscopy unreliable, often necessitating histopathological evaluation for definitive diagnosis.

Case Presentation

Case Report We present the case of a 39-year-old female with a significant medical history of uterine carcinoma treated 10 years prior. The patient presented with a solitary, asymptomatic, pink nodular lesion on the anterior aspect of the foot, which had been present for four years. The patient reported no history of trauma to the site. Dermatoscopic examination revealed non-specific vascular patterns without pathognomonic features for malignancy. Given the persistence of the lesion and the patient's history, an excisional biopsy was performed. Histopathological examination reported sections of skin showing a melanocytic proliferation Melan A positive,composed of epitheloid cells of Spitz type, within which a well defined area of nodular growth (approximately 0.5 mm in diameter) is identifiable.This area shows features of severe cytologic atypia with a marked increase in mitotic activity (mitotic count 4 per mm2). Immunohistochemistry for p16 shows weaker nuclear positivity in the melanocytic elements of the above described area.There is no evidence of endovascular or perineural neoplastic invasion.The surgical excision margins are free of tumor.These findings appear compatible with malignant amelanotic melanoma.

Conclusion

Discussion This case underscores the inherent challenges in identifying amelanotic melanoma, particularly when the clinical morphology is stable over a prolonged period. The four-year history of a seemingly benign pink nodule highlights the "masquerader" nature of AM. While the patient’s history of previous malignancy warrants clinical vigilance, it can also lead to diagnostic bias, where practitioners might assume a metastatic origin or, conversely, overlook a new primary lesion. This case reaffirms that any persistent, non-healing, or clinically equivocal nodule—regardless of the duration or the lack of classic dermoscopic features—requires histopathological examination to rule out malignancy.

Conclusion Amelanotic melanoma should remain a primary differential diagnosis for any persistent erythematous lesion on the extremities. Clinicians must maintain a low threshold for biopsy in cases of long-standing lesions where dermoscopic findings are non-specific, emphasizing that clinical stability does not exclude the possibility of malignancy.

EA DV CONGRESS
VIENNA
30 SEP - 3 OCT 2026

Abstract N°: 1344

Cutaneous adenosquamous carcinoma: a case series highlighting aggressive behavior and response to immunotherapy

Javier Lorenz Dolz*[1], andrea diez santandreu[1], fatima mayo martinez[1], ruggero moro[1], Víctor Traves[1], celia requena caballero[1], onofre sanmartin jimenez[1]

[1] Fundación Instituto Valenciano de Oncología (IVO), Valencia, Spain

Introduction

Cutaneous squamous cell carcinoma (cSCC) is the second most common malignant skin tumor. While most cases follow an indolent course, a subset exhibits high-risk features associated with recurrence and nodal involvement.

Cutaneous adenosquamous carcinoma (ASC) is a rare variant of cSCC characterized by biphasic squamous and glandular differentiation, with frequent deep infiltration, stromal desmoplasia, and perineural invasion. It is associated with a more aggressive clinical course and a high rate of local recurrence.

The aim of this study was to describe the clinical and histopathological features of cutaneous ASC and its relevance as a high-risk subtype of cSCC.

Materials and Methods

We conducted a retrospective descriptive case series including patients with histopathologically confirmed cutaneous ASC diagnosed between 2010 and 2025. Clinical, demographic, histopathological, treatment, and outcome data were collected.

Histopathological evaluation focused on established high-risk features of cSCC, including type and grade of differentiation, stromal desmoplasia, perineural invasion, and tumor depth. Diagnosis was confirmed by hematoxylin–eosin staining and immunohistochemistry.

Results

Five patients were included, all male, with a median age of 73 years. Tumors were mainly located in the head and neck region, with a mean disease duration of 4.6 months. High-risk histopathological features were present in four cases, including desmoplasia and perineural invasion.

At diagnosis, three patients were staged as T3, three had nodal involvement, and one presented distant metastasis.

Treatment included surgery, radiotherapy, anti-EGFR therapy, and anti-PD-1 immunotherapy. Only one patient achieved a durable complete response, while disease progression occurred in the remaining four cases.

Conclusions

Cutaneous ASC represents a high-risk variant of cSCC, with aggressive behavior, early nodal involvement, and poor outcomes despite multimodal treatment. Anti-PD-1 immunotherapy showed limited effectiveness. Further

studies are needed to better characterize this entity and optimize management strategies.

EA DV CONGRESS
VIENNA
30 SEP - 3 OCT 2026

Abstract N°: 1364

Incidence of Paraneoplastic syndromes after a primary diagnosis of skin cancer: an original investigation

Rashwan Alameddine*[1], Umer Nadir[2], Allison Roecker[1], Sara Zoghi[1], Hannah Riva[3], Esmeralda Rodgers[1], Stanislav Tolkachjov[4]

[1] Texas A&M University Naresh K. Vashisht College of Medicine, Bryan, United States

[2] Division of Dermatology, Baylor University Medical Center,, Dallas, United States

[3] Department of General Surgery , HCA Medical City, Plano, United States

[4] Epiphany Dermatology. University of Texas at Southwestern. Baylor University Medical Center., Texas A&M University Naresh K. Vashisht College of Medicine, Lewisville, United States

Introduction

The incidence of skin cancers across the United States continues to rise across all subtypes, including nonmelanoma skin cancers, melanoma, and Merkel cell carcinoma (MCC). Coinciding with this trend, recognition of paraneoplastic syndromes (PNS) has similarly increased. Despite growing clinical relevance, no comprehensive study has examined the incidence and distribution of PNS across all skin cancer subtypes.

Materials and Methods

A systematic literature search was conducted across Ovid MEDLINE, Ovid Embase, Wiley Cochrane CENTRAL, and Clarivate Web of Science Core Collection from January 2026 to February 2026. Search terms included skin cancers, cutaneous basal cell carcinoma (BCC), cutaneous squamous cell carcinoma (SCC), melanoma, Merkel cell carcinoma, and paraneoplastic syndromes. Animal studies, non-English manuscripts, and studies lacking an abstract or full text were excluded. Studies indicating PNS diagnosis prior to skin cancer detection or after chemotherapy initiation were also excluded. Two independent reviewers screened titles, abstracts, and full texts, with a third serving as tiebreaker.

Results

A total of 211 articles encompassing 788 participants were included. Among participants, 52.4% were male, 41.2% were female, and the mean age was 58.5 years. Melanoma was the most prevalent primary diagnosis (n=581, 73.7%), followed by MCC (n=99, 12.6%), SCC (n=59, 7.5%), and BCC (n=7, 0.9%). Sixty-two distinct PNS were identified across all participants, with onset after diagnosis ranged: 0.7–228 months (melanoma), 12–60 months (MCC), 4 months–120 months (SCC), and 60 months (BCC); before diagnosis: 1 month–96 months (melanoma), 12–24 months (MCC), 3 months (SCC), and 8 months (BCC), respectively. Among melanoma cases, melanoma-associated retinopathy was the most common PNS (n=448, 77.1%), followed by vitelliform retinopathy (4.8%) and dermatomyositis (3.1%). In MCC, Lambert-Eaton Myasthenic Syndrome was predominant (n=32, 32.3%), followed by paraneoplastic cerebellar degeneration (21.2%) and paraneoplastic encephalomyelitis (8.1%). For SCC, hypercalcemia of malignancy was most prevalent (n=42, 71.2%), followed by paraneoplastic leukemoid reaction (10.2%) and Bazex syndrome (5.1%). BCC demonstrated the fewest associations, with pure red cell aplasia most frequently observed (n=3, 42.9%).

Figure 1a. Melanoma associated paraneoplasms

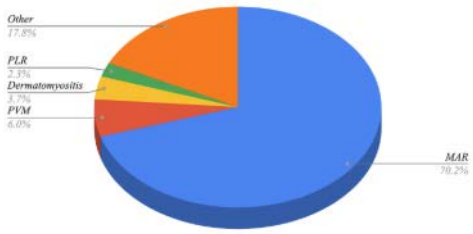

Figure 1b. Squamous cell carcinoma associated paraneoplasms

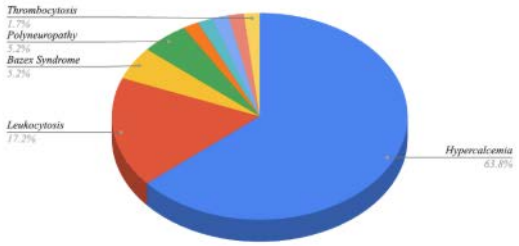

Figure 1c. Merkel cell carcinoma associated paraneoplasms

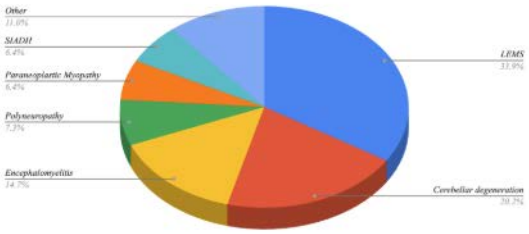

Figure 1d. Basal cell carcinoma associated paraneoplasms

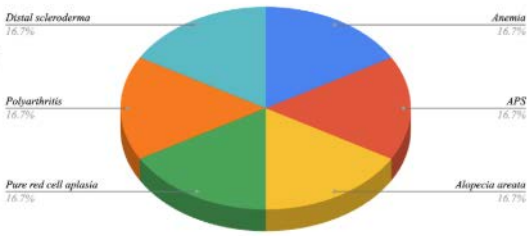

Figure 1. Proportional distribution of reported paraneoplastic syndromes by skin cancer subtype: (a) Melanoma, (b) Squamous cell carcinoma, (c) Merkel cell carcinoma, and (d) Basal cell carcinoma.

Abbreviations: MAR, Melanoma-associated retinopathy; PVM, paraneoplastic vitelliform maculopathy; DM, dermatomyositis; PLR, paraneoplastic leukemoid reaction; LEMS, Lambert-Eaton myasthenic syndrome; SIADH, syndrome of inappropriate antidiuretic hormone secretion; APS, antiphospholipid syndrome.

Conclusions

This systematic review identified 62 distinct paraneoplastic syndromes across 788 participants with a primary skin cancer diagnosis, underscoring the clinical and immunologic complexity of these malignancies. Heightened vigilance is warranted among dermatologists and oncologists when patients present with unexplained systemic manifestations following skin cancer diagnosis. Targeted autoantibody panels and thorough laboratory evaluation should be incorporated into the workup of suspected PNS. While tumor excision may lead to symptom remission, not all syndromes resolve due to irreversible immune and tissue damage, emphasizing the importance of continued surveillance. Future research should prioritize prospective designs, standardized diagnostic criteria, and larger cohorts across all skin cancer subtypes to better characterize incidence, prognosis, and therapeutic outcomes.

EA DV CONGRESS
VIENNA
30 SEP - 3 OCT 2026

Abstract N°: 1381

Pharmacological inhibition of FARP1 suppresses melanoma metastasis through the Rac1 signaling pathway

Wenbin Zhou*[1, 2, 3, 4, 5], Tianhao Wu[1, 2, 3, 4, 5], Shanghong Li[1, 2, 3, 4, 5], Xinxian Gong[1, 2, 3, 4, 5], Meng Zhang[1, 2, 3, 4, 5], Xiaowei Liang[1, 2, 3, 4, 5], Juan Su[1, 2, 3, 4, 5], Hong Liu[1, 2, 3, 4, 5], Xiang Chen[1, 2, 3, 4, 5], Xinwei Kuang[1, 2, 3, 4, 5]

[1] Department of Dermatology, Xiangya Hospital, Central South University, Changsha, China
[2] National Engineering Research Center of Personalized Diagnostic and Therapeutic Technology, Changsha, China
[3] Hunan Key Laboratory of Skin Cancer and Psoriasis, Changsha, China
[4] FuRong Laboratory, Changsha, China
[5] National Clinical Research Center for Geriatric Disease, Changsha, China

Introduction
Metastasis remains the primary determinant of melanoma-related mortality, yet the molecular drivers underlying this process remain incompletely characterized. Cytoskeletal remodeling and aberrant cell motility — hallmarks of metastatic progression — are critically governed by the Rho-GEF family of signal transduction proteins; however, the specific contributions of individual members to melanoma metastasis have not been systematically evaluated. Through integrated multi-omics screening, FARP1 emerged as a key Rho-GEF member specifically enriched in metastatic melanoma subpopulations, representing a compelling yet underexplored pharmacological target. Developing small-molecule inhibitors against FARP1 therefore offers a promising strategy to impede melanoma dissemination.

Materials and Methods
A signature scoring system based on the Rho-GEF family was developed for systematic screening, integrating bulk transcriptomic differential expression analysis, survival analysis, and single-cell transcriptomic profiling of metastatic subpopulations. Findings were validated using clinical tissue microarrays (TMAs). FARP1 knockdown melanoma cell models were generated to assess effects on cell migration and invasion *in vitro*, with a nude mouse tail-vein injection pulmonary metastasis model employed to confirm *in vivo* function. A structure-based virtual screening strategy, combined with surface plasmon resonance (SPR) and biochemical validation, was applied to identify small-molecule inhibitors targeting FARP1. Anti-metastatic efficacy was systematically evaluated *in vitro* using invasion assays and *in vivo* with both a footpad-injection lymph node metastasis model and a pulmonary metastasis model using human melanoma xenografts in severely immunodeficient mice.

Results
Multi-omics and TMA analyses confirmed that FARP1 is progressively upregulated from primary to metastatic melanoma, is specifically enriched in metastatic melanoma single-cell subpopulations, and correlates with adverse prognosis. Genetic depletion of FARP1 suppressed melanoma invasion without significantly affecting cell proliferation, acting by specifically downregulating Rac1-GTP levels. Through virtual screening, a natural small-molecule inhibitor (designated as Compound P) was identified to directly bind to the FARP1 protein (Kd = 19.4 μM). Treatment with Compound P successfully inhibited FARP1-mediated Rac1 activation, thereby drastically impairing melanoma cell invasion *in vitro*. Furthermore, *in vivo* systemic administration of Compound P profoundly blocked both lymph node and pulmonary metastasis in human melanoma xenograft models, with no significant systemic toxicity observed.

Conclusions
This study systematically identifies FARP1 as a central driver of melanoma metastasis, demonstrating its potential

as both a prognostic biomarker and a novel therapeutic target. Pharmacological blockade of FARP1 with a targeted small molecule effectively impedes melanoma metastasis by uncoupling the Rac1 signaling axis. These findings establish FARP1 as a highly druggable vulnerability in melanoma, laying a solid foundation for developing FARP1-targeted agents as novel anti-metastatic therapeutics with promising potential for clinical translation.

EA DV CONGRESS
VIENNA
30 SEP - 3 OCT 2026

Abstract N°: 1387

Malignant Transformation of Giant Congenital Melanocytic Nevus to Malignant Peripheral Nerve Sheath Tumor: A Case Report with Clinical Management Insights

Wei Tan*[1], nanhui wu[1], Zhuo Chen[2], Yeqiang Liu[1]

[1] Department of Pathology, Shanghai Skin Disease Hospital, School of Medicine, Tongji University, Shanghai, China

[2] Department of Dermatology, Shanghai Children's Medical Center, School of Medicine, Shanghai Jiao Tong University, Shanghai, China

Introduction

Giant congenital melanocytic nevus (GCMN) is a rare neurocristopathy associated with an elevated risk of malignant transformation, predominantly to melanoma. Malignant peripheral nerve sheath tumor (MPNST) arising from GCMN is extremely rare, with limited literature describing its clinical course and optimal management. Herein, we report a case of MPNST developing in a 49-year-old male with a long-standing GCMN on the right elbow, characterized by recurrent local lesions, systemic metastasis, and keloid diathesis. This case highlights the unique clinical manifestations of GCMN malignant transformation to MPNST and provides practical insights into the diagnosis and comprehensive treatment of this rare, aggressive tumor.

Case Presentation

A 49-year-old male presented with a 2-year history of recurrent masses on the right elbow. The patient had a congenital melanocytic nevus on the right elbow since birth, which was not regularly monitored. In March 2024, a 2×1×1 cm nodule appeared on the nevus, which was surgically removed without pathological examination. In October 2024, the lesion recurred at the same site, growing to 2×2×2 cm. Due to persistent foreign body sensation, the patient repeatedly massaged, squeezed, and scratched the lesion, leading to gradual enlargement to 3.5×3×2 cm. Wide local excision was performed, and histopathology revealed a mesenchymal malignant tumor. Immunohistochemistry (IHC) showed S-100 (+), SOX10 (+), Ki-67 (20% positive), CD99 (focal positive), Nkx2.2 (partial positive), while SMA, Desmin, EMA, HMB45, and MITF were negative. To exclude clear cell sarcoma, FISH testing for EWSR1 was performed and found to be negative. Combined with the clinical history and pathological features, the tumor was diagnosed as MPNST arising from GCMN, with positive surgical margins.

Postoperatively, the patient received 8 cycles of chemotherapy with doxorubicin 130 mg + ifosfamide 4.8 g (d1-4), followed by 1 cycle of PLD 40 mg (d1) + PLD 45 mg (d2) + ifosfamide 4.8 g (d1-4). Re-examination MRI showed reduction of the local tumor, but with possible invasion of the ulnar olecranon. PET-CT revealed multiple nodules and masses in the posterior medial muscle group of the right elbow with increased glucose metabolism (indicating active tumor) and multiple bilateral pulmonary nodules suggestive of metastatic lesions. To completely eliminate the lesion, right elbow lesion resection and upper arm amputation were performed. Postoperatively, the patient recovered well and was discharged with arrangements for regular follow-up.

Conclusion

This rare case describes MPNST arising from GCMN, characterized by recurrent local lesions, and early systemic metastasis. The IHC profile (S-100 and SOX10 positive, melanocytic markers negative) confirms the diagnosis of

MPNST and excludes melanocytic malignancies, while EWSR1 negativity rules out clear cell sarcoma. The clinical course emphasizes the importance of long-term monitoring of GCMN, timely pathological examination of recurrent lesions, and comprehensive treatment strategies including surgery and chemotherapy. Radical resection may be necessary for locally advanced or recurrent disease to improve disease control. Further clinical case accumulation is needed to optimize the diagnosis and treatment of this rare malignant transformation pathway.

EADV CONGRESS
VIENNA
30 SEP - 3 OCT 2026

Abstract N°: 1403

Cutaneous Leukemic Infiltration Mimicking Drug-Induced Dermatosis in CLL

Ilke Ekin Arıcan*[1], Akin Aktas[1], Esra Ucaryilmaz[2]

[1] Department of Dermatology and Venereology, Ankara Bilkent City Hospital, Ankara, Turkey, Ankara, Türkiye
[2] Department of Pathology,Ankara Bilkent City Hospital, Ankara, Turkey, Ankara, Türkiye

Introduction

Cutaneous manifestations in patients with hematological malignancies may arise from drug reactions, inflammatory dermatoses, or direct malignant infiltration. Distinguishing between these entities can be challenging, particularly in the setting of newly initiated systemic therapies, and has important implications for patient management.

Case Presentation

A 72-year-old female with a known diagnosis of chronic lymphocytic leukemia (CLL) was started on acalabrutinib therapy. Within one week of treatment initiation, she developed multiple, rapidly appearing, painful nodular lesions measuring approximately 1–1.5 cm in diameter. Some of the lesions showed erythematous to ecchymotic discoloration. The lesions were scattered over the upper extremities, trunk, and lower extremities, particularly involving the pretibial areas, and were associated with marked tenderness on palpation.

Given the acute onset, distribution, and severity of pain, drug-induced Sweet syndrome, erythema nodosum, and other neutrophilic dermatoses were considered in the differential diagnosis, along with drug-related panniculitis . There was no prior history of similar lesions. An excisional biopsy was performed from a nodular lesion on the upper extremity.

Histopathological examination demonstrated dense dermal infiltration by small lymphoid cells consistent with leukemic infiltration of the skin, confirming cutaneous involvement of CLL.

Conclusion

Cutaneous leukemic infiltration may closely mimic drug-induced or inflammatory dermatoses in patients with CLL, particularly in the setting of newly initiated targeted therapies. The temporal association with treatment initiation and the presence of painful nodular lesions may lead to an initial suspicion of neutrophilic dermatoses or drug-related reactions, potentially delaying the correct diagnosis. This case emphasizes the need for maintaining a broad differential diagnosis in patients with hematological malignancies presenting with atypical or rapidly evolving skin lesions. Early skin biopsy remains essential for accurate diagnosis, preventing misinterpretation, and ensuring timely and appropriate management.

EA DV CONGRESS
VIENNA
30 SEP - 3 OCT 2026

Abstract N°: 1404

Secondary and tertiary amino groups in metformin as risk factor for drug-related photocarcinogenicity and basal cell carcinoma development

Simona Kordeva*[1], Konstantin Tchernev Jr[2], Georgi Tchernev[1, 2]

[1] Medical Institute of Ministry of Interior - Department of Dermatology and Venereology, Sofia, Bulgaria
[2] Onkoderma- Clinic for Dermatology, Venereology and Dermatologic Surgery, Sofia, Bulgaria

Introduction

The metformin related phototoxicity might be linked to the availability of secondary and tertiary amine in its structure. Both of these amines could be the reason for 1) exogenous NDMA formation during the manufacturing process outside the human body and 2) endogenous formation of nitrosamines in the stomach together with the intake of nitrite-rich food. The newly defined photocarcinogenicity could be formulated as drug-related nitroso photocarcinogenicity/ drug-related nitrosogenesis of skin cancer and drug- and dietary-related endogenously nitrosogenesis of skin cancer.

The potential or actual contamination of widely distributed medications with nitrosamines is currently a serious problem. Medications, such as ranitidine, metformin, rifampicin, hydrochlorothiazide, ACE inhibitors, Sartans, used as monotherapy or in a combination with other drug classes, practically contain secondary/tertiary amino groups within their chemical structure. Upon ingestion, secondary or tertiary amino groups within the chemical structure of certain drug may undergo nitrosation in the presence of nitrite-rich food, resulting in the formation of nitrosamines. Following systemic absorption, these compounds may circulate and accumulate in the skin, where, upon exposure to UV radiation, they can undergo photodecomposition. The resulting reactive intermediates may induce DNA damage, thereby contributing to the development of skin cancer.

The dilemma with the ″increased availability″ of amino groups within polymedication concerns the subsequent development not only of single, but also of multiple skin tumors, sometimes even - in a combination with other tumor types.

The development, in particular, of keratinocyte tumors approximately after the same period of time within administering certain type of drugs, such as sartans, hydrochlorothiazide and ACE inhibitors, should not be taken as surprising and has been described repeatedly over the past 7 years.

Data on these types of tumors have been officially published not only in a number of large-scale European and American retrospective analyses, but also in the form of dozens of case studies with a retrospective/prospective nature.

Case Presentation

We describe the first case in the world literature of a patient who developed a basal cell carcinoma of the chin (Figure) after taking metformin (containing both secondary and tertiary amine functional group within its structure).



Figure: Large ulcerated tumor lesion on the right lower facial area, at the level of the mandible, with 4-5cm with elevated and uneven borders formed by some pigmented and translucent nodules with teleangiectasia typical of BCC, with a deep ulceration in the middle with adherence to the deeper structures.

Conclusion

The role of exogenous and endogenous nitrosamine formation as a possible key factor in the tumor development is discussed.

EADV CONGRESS
VIENNA
30 SEP - 3 OCT 2026

Abstract N°: 1409

Can Subcutaneous Nodular Lesions on the Face Be a Sign of Acute Myeloid Leukemia?: A Case of Cutaneous Myeloid Sarcoma

Aslıhan Özel*[1], Nilay Duman[1], Gürsel Kavlak[2], Mine Hekimgil[3], Ajda Güneş[2], Taner Akalın[3]

[1] Ege University Faculty of Medicine, Department of Dermatology and Venereology, İzmir, Türkiye
[2] Ege University Faculty of Medicine, Department of Internal Medicine, İzmir, Türkiye
[3] Ege University Faculty of Medicine, Department of Medical Pathology, İzmir, Türkiye

Introduction

Myeloid sarcoma is a rare form of extramedullary leukemic involvement. It most commonly occurs concurrently with acute myeloid leukemia (AML) or during the course of the disease; however, it may also be associated with other myeloproliferative and myelodysplastic disorders. It may manifest as papules, nodules, plaques, or tumor-like lesions. In this report, we present a case of a patient who was admitted to the dermatology outpatient clinic with subcutaneous nodular lesions on the face who was diagnosed with acute myeloid leukemia after bone marrow biopsy.

Case Presentation

A 52-year-old female patient presented to the dermatology outpatient clinic in July 2025 with complaints of facial swelling and nodularity. Her medical history included surgery for a well-differentiated small intestinal neuroendocrine tumor, lymph node metastasis, liver metastasis of neuroendocrine carcinoma, and prior surgery for moderately differentiated colon adenocarcinoma. Dermatological examination revealed firm, greenish subcutaneous nodular lesions located on the bilateral malar regions, nasal dorsum, and frontal area .Dermoscopic examination showed a polymorphic vascular pattern consisting of dotted and linear-curved vessels on a pink structureless background.Upon application of pressure with the dermoscope, a yellowish and greenish hue of the lesions became more apparent.
Considering the patient's systemic disease history and dermatological findings, a punch biopsy was obtained from a subcutaneous nodular lesion in the left zygomatic region with preliminary diagnoses of leukemia cutis, extramedullary hematopoiesis, granulomatous dermatitis, sarcoidosis, panniculitis, and B-cell lymphoproliferative disorders. Histopathological and immunohistochemical findings were consistent with myeloid sarcoma. Concurrently, a bone marrow aspiration biopsy performed due to the development of leukocytosis confirmed the diagnosis of acute myeloid leukemia.

Conclusion

Although myeloid sarcoma is a rare malignancy, it should be considered in the differential diagnosis when rapidly progressive papules, plaques, nodules, or tumoral masses occur, particularly at atypical sites. Cutaneous findings may represent an indicator of an underlying or previously undiagnosed hematologic malignancy. Therefore, dermatological and dermoscopic evaluation, together with timely histopathological examination, are important for early diagnosis.

EADV CONGRESS
VIENNA
30 SEP - 3 OCT 2026

Abstract N°: 1422

AN UNUSUAL PRESENTATION OF PRIMARY CUTANEOUS ANAPLASTIC LARGE CELL LYMPHOMA ON THE NOSE: A CASE REPORT WITH TZANCK SMEAR FINDINGS

Duygu Özçelik*[1], Alperen Külhan[1], Esra Uçaryılmaz Özhamam[2], Esra Kıratlı Nalbant[1]

[1] Ankara Bilkent City Hospital, Dermatology, Ankara, Türkiye
[2] Ankara Bilkent City Hospital, Pathology, Ankara, Türkiye

Introduction

Primary cutaneous anaplastic large cell lymphoma (pcALCL) is a rare CD30-positive cutaneous T-cell lymphoproliferative disorder that typically presents as a solitary or localized nodulo-ulcerative lesion. Nasal involvement is extremely uncommon, and the clinicopathological diagnosis may be particularly challenging in rapidly progressive destructive lesions. In addition, the cytological features of pcALCL on Tzanck smear have not been well documented.

Herein, we report a rare case of nasal pcALCL in which Tzanck smear findings contributed to the diagnostic suspicion and subsequent clinicopathological confirmation.

Case Presentation

A 41-year-old woman was admitted to the otorhinolaryngology clinic of our hospital with a non-healing right nasal alar lesion developing two months after nasal piercing. An initial debridement biopsy suggested deep fungal infection, and systemic amphotericin B with multiple antibiotics was initiated, but the lesion progressed rapidly, prompting multidisciplinary evaluation and referral to our department for further evaluation. Her personal and family histories were unremarkable. Physical and dermatological examination revealed cervical lymphadenopathy and a tumor-like lesion with a partially hemorrhagic and verrucous surface, almost completely covering the right side of the nose. Routine laboratory investigations were normal except for elevated ESR (76 mm/h) and CRP (172 mg/L) with negative serological and autoimmune markers. Magnetic resonance imaging demonstrated an extensive contrast-enhancing soft tissue lesion involving the nasal alae and adjacent structures.

Based on the clinical presentation, the differential diagnosis included NK/T-cell lymphoma, anaplastic T-cell lymphoma, atypical mycobacterial infection, ANCA-associated vasculitis, and cutaneous leishmaniasis. A Tzanck smear obtained from the biopsy material using the impression technique revealed atypical malignant cells characterized by one or more prominent nucleoli, giant nuclei with irregular nuclear contours, and an increased nuclear-to-cytoplasmic ratio, favoring a diagnosis of lymphoma. Because the Tzanck smear findings were inconsistent with the previous biopsy report, the pathology department was informed of the cytological suspicion for malignancy. Careful reassessment of the specimen, followed by immunohistochemical evaluation, demonstrated widespread infiltration of atypical cells in the dermis. These cells showed a heterogeneous staining pattern for CD45 and CD3, with diffuse positivity for CD30, CD8, TIA-1, and granzyme and a high Ki-67 index (~80%). In light of the clinicopathological correlation, the patient was diagnosed with primary cutaneous anaplastic large cell lymphoma. The patient was referred to oncology and initiated chemotherapy but discontinued treatment after one cycle and was lost to follow-up by choice.

Conclusion

Primary cutaneous anaplastic large cell lymphoma (pcALCL) is a rare subtype of primary cutaneous T-cell lymphoma characterized by the clonal proliferation of CD30-positive large atypical T cells. In the present case, despite an initial suspicion of fungal infection and a clinical impression of NK/T-cell lymphoma, the final diagnosis of nasal pcALCL was established by immunohistochemistry, with Tzanck smear providing an important early clue. Nasal involvement is remarkably rare, with only about six cases reported in the literature, and this appears to be the first case in which Tzanck smear findings have been described.

EA DV CONGRESS
VIENNA
30 SEP - 3 OCT 2026

Abstract N°: 1423

Metastatic melanoma to the central nervous system associated with a giant congenital melanocytic nevus: an unusual presentation in adulthood

Katherine López-Soto*[1], Lenin Vladimir Sandoval-Luna[2], Daniel Alvarez-Sandoval[3], José Eduardo Samayoa-Palma[4]

[1] National Autonomous University of Mexico, CDMX, Mexico

[2] Department of Neurosurgery, Farallón Hospital, Acapulco, Mexico

[3] Department of neurosurgery, Vicente Guerrero Regional General Hospital, IMSS, Acapulco, Mexico

[4] Department of Pathology, Vicente Guerrero Regional General Hospital, IMSS, Acapulco, Mexico

Introduction

Giant congenital melanocytic nevi (GCMN) are rare melanocytic lesions, occurring in approximately 1 in 500,000 newborns, characterized by a size greater than 20 cm or covering an area larger than 120 cm^2 (1,2). Their clinical significance lies in the increased risk of transformation into cutaneous melanoma (5–15%). However, most melanomas arising in patients with GCMN do not originate within the nevus itself but rather occur extracutaneously, involving visceral organs or, more notably, the central nervous system (CNS), where they may present as leptomeningeal melanocytosis, parenchymal involvement, or other CNS abnormalities. These complications typically follow an aggressive course, most commonly manifesting in early childhood (3). We report an exceptional case of metastatic melanoma to the CNS associated with GCMN in an adult patient.

Case Presentation

A 45-year-old woman from a rural community, with a past medical history of HBP diagnosed 5 years ago, migraine diagnosed in 2023 under neurological follow-up (treatment unspecified), a thyroid nodule under evaluation, and a hysterectomy performed in 2019 due to cysts.The current illness began in January 2023, with a mild headache of five months' duration. On June 1, 2023, she developed an episode of holocranial headache rated 8/10 in intensity, accompanied by photopsia, stiffness, and vertigo, for which she was evaluated in the neurology outpatient clinic and diagnosed with migraine, receiving unspecified pharmacological treatment without improvement.

On June 14, 2023, she experienced a new episode of severe headache (10/10) associated with vertigo and presented to the emergency department. Neurological examination was unremarkable. A contrast-enhanced cranial computed tomography (CT) scan with 3D reconstruction revealed an extra-axial parieto-occipital intracranial lesion with dural attachment and cytotoxic cerebral edema (Figure 1b-c), suggestive of meningioma. She was scheduled for surgery by the neurosurgery team.

During surgery, a melanocytic lesion with hypertrichosis was noted in the lower dorsal region, extending to both gluteal areas and anteriorly along both flanks to the abdomen (Figure 1a), with multiple satellite nevi, consistent with a giant congenital melanocytic nevus. A left parieto-occipital craniectomy was performed with resection of a hyperpigmented, oval, indurated lesion measuring 3.0 cm in diameter, easily dissectable from the brain parenchyma and attached to the adjacent dura mater, with a blackish and reddish-gray appearance (Figure 1d-e). Histopathological examination confirmed metastatic malignant melanoma (Figure 2).

The patient was referred to medical oncology, where computed tomography of the abdomen and pelvis revealed nodular lesions in the right basal region suggestive of tumor activity. Multiple biopsies of the nevi were performed, all negative for malignancy. A diagnosis of metastatic melanoma of unknown primary was established.

She received adjuvant therapy with nivolumab 200 mg iv every two weeks for six months; however, she was subsequently lost to follow-up.

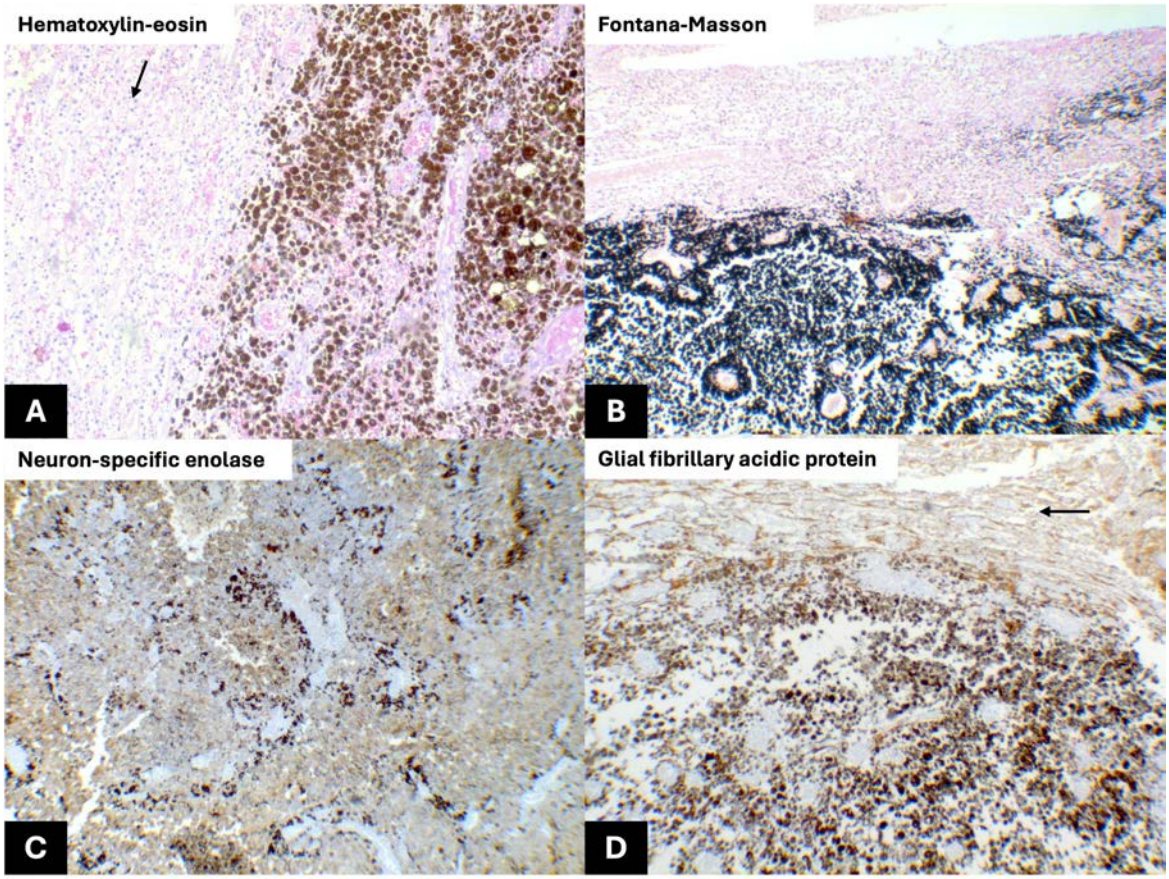

Figure 2. A. Area of neuroglial tissue (arrow) in contact with sheets of uniform melanocytes containing granular intracytoplasmic pigment (hematoxylin–eosin, 40×), B. Melanocytes containing melanin highlighted by Fontana–Masson; neuroglial tissue is observed in the upper portion (hematoxylin–eosin, 40×), C. Sheets of melanocytes with scattered granular positivity on immunohistochemistry (neuron-specific enolase, 40×), D. Neuroglial tissue (arrow) and melanocytes positive on immunohistochemistry (glial fibrillary acidic protein, 40×).

Conclusion

Metastatic melanoma to the CNS in GCMN is highly aggressive and associated with a poor prognosis. Risk correlates with lesion size (up to 15% if >40 cm), posterior axial location, and the presence of multiple satellite nevi (3). Although melanoma usually develops in childhood and neurological symptoms appear before 2 years of age, our case presented atypically in adulthood, likely influenced by limited access to healthcare. Diagnosis requires a high index of suspicion in patients with GCMN presenting with nonspecific neurological symptoms, supported by imaging, preferably MRI. Early neurosurgical intervention may allow confirmation of the diagnosis through histopathological examination. Notably, in up to 24% of cases, the primary tumor cannot be identified (4,5). There is no curative treatment, and the median survival is approximately 4.8 months (1). Early multidisciplinary follow-up is essential.

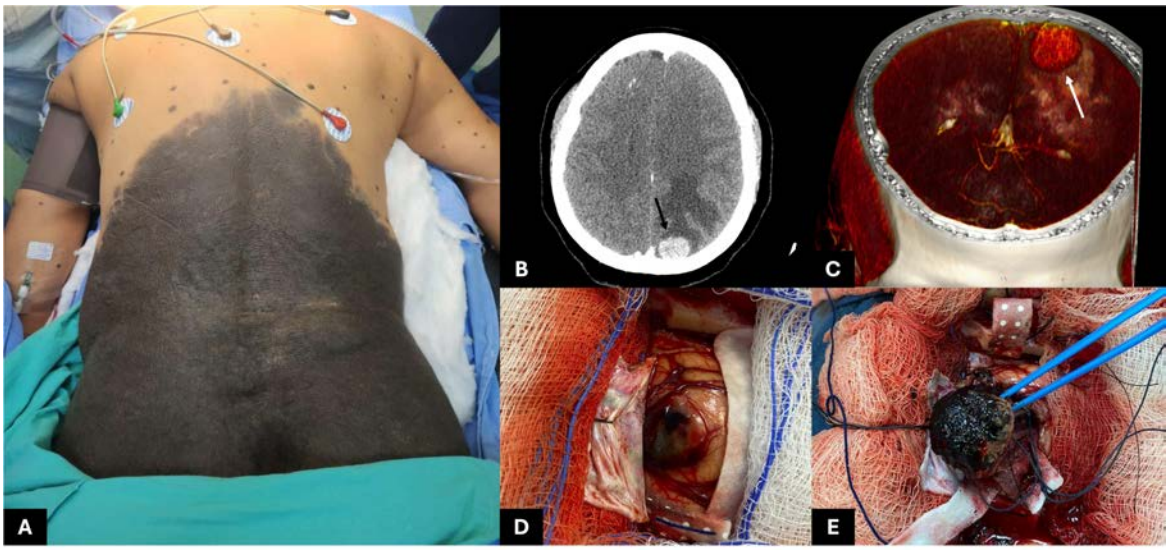

Figure 1. A. Melanocytic lesion located in the dorsal region, extending to both gluteal areas and the lateral aspects of the trunk, with associated hypertrichosis and multiple satellite nevi. B. Axial contrast TC showing an unique intracranial, extraaxial lesion (arrow), with homogeneous contrast enhancement, a dural attachment and associated cytotoxic edema in the left posterior parietal lobe, 3mm lateral to the superior sagittal sinus. C. Oblique anterosuperior view of a 3D model of the lesion (arrow) D. intraoperative image showing a cortical eruption of the tumor sound by healthy brain parenchyma. E. intraoperative complete tumor removal showing a 3cm wide rounded blackish and reddish-gray appearance tumor.

EADV CONGRESS
VIENNA
30 SEP - 3 OCT 2026

Abstract N°: 1440

Use of Adjuvant Immunotherapy and Overall Survival in Stage III Merkel Cell Carcinoma

Hue Tran*[1], Frank Jing[1], Duc Le[1], Raslina Shrestha[1], Jerry D.Brewer[2], Deepti Behl[3], Clark Otley[4], Svetomir N. Markovic[5], Giang Nguyen[1]

[1] Department of Dermatology, Mayo Clinic, Rochester, United States

[2] Division of Micrographic Surgery and Dermatologic Oncology, Department of Dermatology, Mayo Clinic, Rochester, United States

[3] 3 Department of Oncology, Mayo Clinic, Rochester, United States

[4] Division of Dermatologic Surgery, Department of Dermatology, Mayo Clinic, Rochester, United States

[5] Department of Oncology, Mayo Clinic, Rochester, United States

Introduction

Merkel cell carcinoma (MCC) is a rare and highly aggressive cutaneous malignancy with a substantial risk of recurrence and disease-specific mortality. Approximately one-third of patients present with regional nodal involvement at diagnosis. While immune checkpoint inhibitors have transformed the management of advanced MCC, their role in the adjuvant setting remains incompletely defined. Recent prospective data suggest improvements in disease-free survival, but overall survival (OS) outcomes remain immature, and real-world evidence is limited.

Materials and Methods

We conducted a retrospective cohort study using the National Cancer Database, including adults (≥18 years) with stage III cutaneous MCC diagnosed between 2017 and 2022 who underwent definitive surgery and lymph node dissection. Adjuvant immunotherapy (AIT) was defined as receipt of immunotherapy within 90 days of surgery, applying a landmark approach to mitigate immortal time bias. Multivariable logistic regression was used to identify factors associated with AIT receipt. Overall survival was evaluated from the landmark using Kaplan-Meier methods and Cox proportional hazards models in a 1:1 propensity score-matched cohort, with additional adjustment for residual imbalances.

Results

A total of 1,286 patients were included, of whom 122 (9.5%) received AIT. Utilization of AIT increased over time, from 3.7% in 2017 to 14.5% in 2022. Patients receiving AIT were younger and more likely to have adverse pathological features, including higher T stage and positive surgical margins. In multivariable analysis, younger age, T3-4 disease, and positive margins were independently associated with AIT use. After propensity score matching (122 pairs), 2-year OS was 70.9% in the AIT group versus 65.3% in the non-AIT group, without a statistically significant difference. In adjusted Cox models, AIT was not associated with improved OS (adjusted hazard ratio 0.90, 95% CI 0.57-1.44).

Conclusions

In this national cohort of resected stage III MCC, use of adjuvant immunotherapy remains limited but is increasing over time and appears to be preferentially administered to patients with higher-risk pathological features, consistent with a risk-adapted approach in clinical practice. In adjusted analyses, AIT was not associated with improved early overall survival, although point estimates numerically favored treatment. Given the retrospective design, potential for residual confounding, and limited follow-up, these findings should be interpreted with caution and do not exclude a possible delayed survival benefit. Further prospective studies with longer follow-up

are needed to better define the impact of AIT on survival outcomes.

EADV CONGRESS
VIENNA
30 SEP - 3 OCT 2026

Abstract N°: 1442

Hyperthermic Isolated Limb Perfusion for In-Transit Melanoma: A Multi-Site Tertiary-Center Experience

Miguel Aristizabal Torres*[1], Roy Rogers[2], Thais Pincelli[1]

[1] Mayo Clinic Florida, Jacksonville, United States
[2] Mayo Clinic Arizona, Scottsdale, United States

Introduction
In-transit melanoma represents a challenging subset of advanced limb melanoma for which regional therapies remain essential. Hyperthermic isolated limb perfusion (HILP) enables delivery of high-dose regional chemotherapy while minimizing systemic toxicity. However, outcome data after HILP remain scarce, particularly multi-institutional analyses within standardized oncologic systems.

Materials and Methods
A retrospective review was performed of all patients who underwent HILP for in-transit melanoma at Mayo Clinic Florida, Rochester, and Arizona between 2000 and 2025. Demographics, operative parameters, and outcomes were abstracted from institutional records.

Clinical response was assessed at first post-procedure follow-up (20-24 weeks) and classified as complete response (CR: disappearance of all lesions), partial response (PR: ≥50 % reduction in number or size of lesions), stable disease (SD: <50 % decrease or <25 % increase), or progressive disease (PD: ≥25 % increase or new lesions). Regional toxicity was graded using the Wieberdink scale (I–V). Limb preservation and recurrence were recorded for all patients.

Results
Twenty-two patients were identified (median age 69 years, range 44–82; 59% male). At initial follow-up, responses were CR 8 (36.4%), PR 3 (13.6%), SD 4 (18.2%), and PD 7 (31.8%), yielding an ORR of 50.0%.

Toxicity was predominantly mild to moderate: Wieberdink I–II in 68%, III in 27%, and IV–V in 5%. Limb preservation was achieved in 21 of 22 patients (95.5%). Local or in-transit recurrence occurred in 9 patients (40.9%) during follow-up. No treatment-related deaths were documented.

Conclusions
HILP provided meaningful regional disease control with a 50% objective response rate and high limb-preservation rate in this multi-institutional series. Most toxicities were low-grade and manageable. These findings support HILP as a safe, durable, limb-preserving treatment option for selected patients with in-transit melanoma. Prospective, standardized follow-up will be valuable to define long-term outcomes and predictors of response.

EADV CONGRESS
VIENNA
30 SEP - 3 OCT 2026

Abstract N°: 1453

Primary cutaneous marginal zone lymphoma mimicking an epidermoid cyst

İrem Erişir*[1], Burce Can Kuru[1]

[1] Department of Dermatology, University of Health Sciences Türkiye, Sultan 2. Abdulhamid Han Training and Research Hospital, İstanbul, Türkiye

Introduction

Primary cutaneous marginal zone lymphoma is an indolent B-cell lymphoma arising in the skin. Because of its rarity and variable clinical presentation, it may mimic benign cutaneous lesions and can be challenging to diagnose clinically.

Case Presentation

A 71-year-old man presented with a 2-month history of an erythematous swelling on the midline of the back. Physical examination revealed an erythematous, inflamed nodule in the interscapular region. With a preliminary diagnosis of an infected epidermoid cyst, superficial soft-tissue ultrasonography was performed and was reported as suggestive of an epidermoid cyst. The lesion was totally excised. Histopathological examination showed lymphoid proliferation with Bcl-2 positivity and Bcl-6 and CD10 negativity, consistent with primary cutaneous marginal zone lymphoma. Lactate dehydrogenase was 204 U/L, and PET-CT showed no systemic involvement.

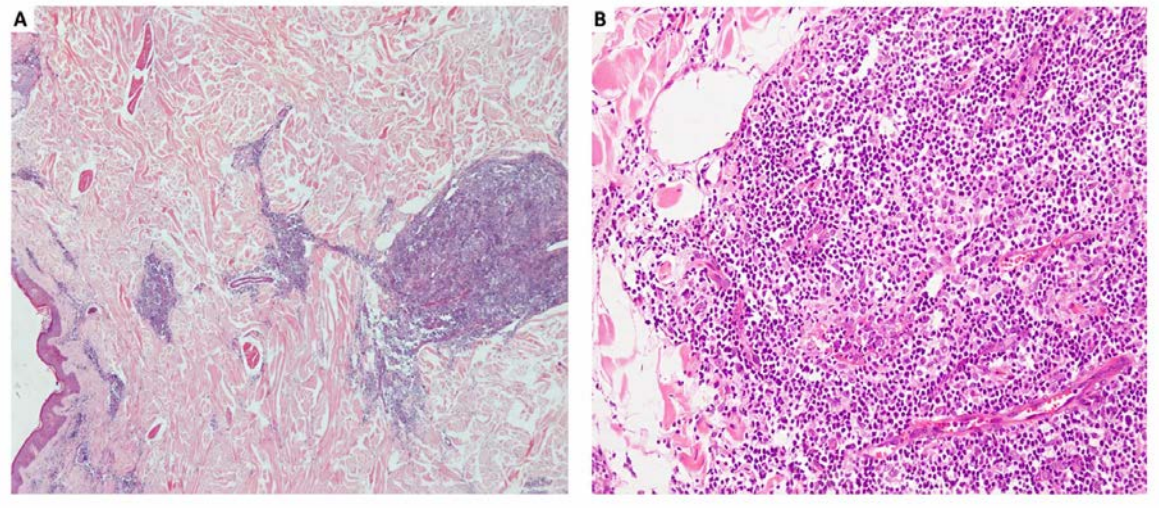

Panel A: Low-power view showing nodular dermal lymphoid infiltrates. Panel B: High-power view showing a dense infiltrate of small- to medium-sized atypical lymphoid cells.

Conclusion

This case highlights that cutaneous lymphomas should be considered in the differential diagnosis of nonspecific

erythematous nodules, even when clinical and ultrasonographic findings suggest an epidermoid cyst.

EADV CONGRESS
VIENNA
30 SEP - 3 OCT 2026

Abstract N°: 1465

Extraocular Sebaceous Carcinoma: A Regional Experience and Comprehensive Characterization

Victor Onecha Vallejo*[1], Juan José García Santos[2], Patricia Bodas Gallego[3], Beatriz Sanjurjo Lamela[4], Estela Gomez Calvo[3]

[1] Hospital Río Carrión, Palencia, Spain
[2] Hospital Virgen de La Concha, Zamora, Spain
[3] Sacyl Hospital de León, León, Spain
[4] Centro de Salud Zamora Norte, Zamora, Spain

Introduction
Sebaceous carcinoma is a malignant tumor characterized by sebaceous differentiation. It represents the most aggressive end of the spectrum of sebaceous neoplasms, which range from benign ectopic sebaceous glands to sebaceous carcinoma. This neoplasm is rare, accounting for approximately 0.2% to 4–6% of cutaneous malignancies, with an estimated incidence of 1–2 cases per 1,000,000 inhabitants. It typically occurs in elderly, fair-skinned patients, with no significant sex predilection. Two main variants are recognized: the ocular form, which accounts for approximately 75% of cases, and the extraocular variant. Diagnostic delay is common due to the difficulty of clinical and dermoscopic recognition. Sebaceous carcinoma may be associated with genetic syndromes such as Muir–Torre syndrome and MUTYH-associated polyposis

Materials and Methods
Cases of extraocular sebaceous carcinoma were identified from the earliest available records to the present. Epidemiological, histological, clinical, and prognostic data were collected for all cases.

Results
A total of 40 cases of extraocular sebaceous carcinoma were identified, with the first case recorded in 1995. No sex predilection was observed, and the mean age at diagnosis was 83.5 years. Most patients presented with multiple comorbidities. Tumors were high-grade in 85% of cases and were most frequently located on the scalp (n=12) and cheek (n=10). Surgical treatment was performed in all patients, including two conventional excisions and the remainder treated with Mohs micrographic surgery; one patient required concomitant radiochemotherapy. Sentinel lymph node biopsy was performed in two cases. The mean follow-up period was 25.8 months. A mortality rate of 50% was observed, with deaths attributable to either intercurrent malignancies (colon and bladder carcinoma) or disease progression of sebaceous carcinoma (two cases each).

Conclusions
This series comprises elderly patients with no sex predilection and predominantly high-grade tumors. The main treatment objective is complete surgical excision followed by clinical surveillance. No standardized treatment protocol exists, and management is tailored to each patient. Mortality in this cohort is increased primarily due to non-tumor-related factors, including advanced age and comorbidities, with relatively short follow-up periods. Microsatellite instability testing appears to be sensitive but lacks specificity. Further studies are required, given the rarity of this entity, to better define therapeutic strategies and the role of adjuvant treatment in these patients

EADV CONGRESS
VIENNA
30 SEP - 3 OCT 2026

Abstract N°: 1517

Keratoacanthoma on a tattoo.

Valeria Vasilieva*[1], Irina Smirnova[1], Roman Fadeev[1], Tatiana Shmidt[1], Polina Ptashnikova[1]

[1] Saint-Petersburg State University, Saint-Petersburg, Russian Federation

Introduction

Keratoacanthoma (KA) is a rapidly growing epithelial neoplasm with clinical and histological similarities to well-differentiated squamous cell carcinoma (SCC). In recent years, an increasing number of KA and SCC cases have been reported at sites of injections, laser treatments, and tattoos, particularly those involving red pigment. Red tattoo pigment contains organic components, namely azo pigments, which are chemically unstable and prone to photodegradation as well as thermal or enzymatic cleavage, leading to the formation of aromatic amines and other carcinogenic compounds.
In addition, red pigment may contain inorganic substances, such as mercury, cadmium sulfide, iron oxide, and trace metal impurities, which can act as photocatalysts, potentially contributing to neoplastic transformation.

Case Presentation

A 37-year-old man presented with a complaint of an asymptomatic red nodule on the skin of his left forearm. The lesion developed approximately two months prior, shortly after receiving a tattoo with red pigment. On examination, a solitary, dome-shaped nodule with a central crater-like depression filled with keratinous material was observed. The lesion was well demarcated and showed no signs of perifocal infiltration.
An excisional biopsy was performed. Histological examination revealed pronounced papillomatosis, diffuse hyperkeratosis with crater formation containing keratinous and parakeratotic material, marked acanthosis, mild atypia of basal keratinocytes, and intraepithelial lymphocytic infiltration. The dermis demonstrated inflammatory infiltration and deposits of red pigment.
Conclusion: Keratoacanthoma / well-differentiated squamous cell carcinoma (G1, pT1) of the forearm skin. The lesion was excised with clear margins. A differential diagnosis between KA and well-differentiated SCC was made, taking into account the lesion’s symmetry, limited growth, and minimal cytological atypia.
Radical surgical excision was performed due to the inability to reliably exclude SCC. Subsequently, close follow-up and photoprotection are recommended. Laser tattoo removal should be postponed until complete exclusion of malignant activity, given the potential risk of carcinogen release during pigment photodegradation.

Conclusion

This case highlights the potential role of the chemical composition of red tattoo pigment in the pathogenesis of KA or SCC, due to its ability to undergo photodegradation and generate carcinogenic metabolites. A high index of oncological suspicion, early biopsy, and radical excision of rapidly growing neoplasms arising in tattooed skin are essential. Caution regarding laser tattoo removal, as well as awareness of potential risks for patients and the tattoo industry, is warranted.

EA DV CONGRESS
VIENNA
30 SEP - 3 OCT 2026

Abstract N°: 1521

Giant Scalp Melanoma Misdiagnosed as Seborrheic Dermatitis: A Case of Diagnostic Delay and Fulminant Fatal Course

Yagiz Ustundag*[1], Ozlem Ozbagcivan[1], Yasemin Cakir[2]

[1] Dokuz Eylul University Faculty of Medicine, Department of Dermatology and Venereology, Izmir, Türkiye

[2] Dokuz Eylul University Faculty of Medicine, Department of Pathology, Izmir, Türkiye

Introduction

Scalp melanomas account for approximately 5% of all melanomas but are responsible for nearly 10% of melanoma-related deaths. This disproportionate mortality is attributed to delayed diagnosis due to the anatomical location, which limits routine examination, and frequent misdiagnosis as benign dermatoses. Additional contributing factors include rich vascularization of the region, increased Breslow thickness at diagnosis, neurotropism, and difficulty in achieving adequate surgical margins. Consequently, scalp melanomas are referred to as "invisible killers" in the literature. We report a rare case of a giant scalp melanoma with delayed diagnosis, resulting in rapid clinical deterioration and fatal outcome.

Case Presentation

An 82-year-old woman presented with a 1-week history of facial erythema, fever, and headache, along with a longstanding black scalp lesion. Examination revealed erythema and edema of the left malar region consistent with erysipelas. A large infiltrative frontoparietotemporal scalp lesion composed of black, gray, and violaceous papules, nodules, and tumoriform masses with scale, crusting, and satellite lesions was observed. Left cervical lymphadenopathy was present. In detailed history, the lesions initially appeared as crusted plaques 1 year earlier. Five months prior, she had been diagnosed with seborrheic dermatitis at an external center and treated with topical corticosteroids without response, followed by progressive disease. Her past medical history included hypertension. Family history was notable for lung cancer in a sister and liver cancer in a brother.

Dermoscopy showed irregular black, gray, and brown structureless areas with scale and crusts, white shiny lines, focal ulceration, and peripheral pink-red structureless areas with white shiny streaks (Figure 1). Laboratory findings revealed elevated CRP (11.8 mg/L), leukocytosis (16.9 × 10^9/L) with neutrophilia, and markedly increased lactate dehydrogenase (LDH, 1394 U/L). Liver and renal function tests were within normal limits. Oral amoxicillin–clavulanic acid was initiated for erysipelas.

Skin biopsy from frontal, parietal, and postauricular regions revealed atypical melanocytic proliferation. Immunohistochemistry was positive for S100, HMB45, and Melan-A (Figure 1). Excisional biopsy of a satellite lesion confirmed malignant melanoma. PET-CT demonstrated extensive hypermetabolic scalp lesions, bilateral cervical lymph node involvement, pleural effusion, and hepatic, splenic, periportal, and paraaortic metastases. Brain MRI showed no intracranial involvement.

During follow-up, the patient developed jaundice, right upper quadrant pain, and nausea. Laboratory evaluation revealed rapidly worsening hepatic dysfunction with a marked increase in LDH (4605 U/L), consistent with visceral crisis due to extensive liver metastases.

Given rapidly progressive metastatic disease, combination immunotherapy with ipilimumab and nivolumab was initiated. Despite treatment, the patient developed acute hepatic and renal failure with hyperkalemia and rapidly deteriorated, dying four weeks after diagnosis of melanoma.

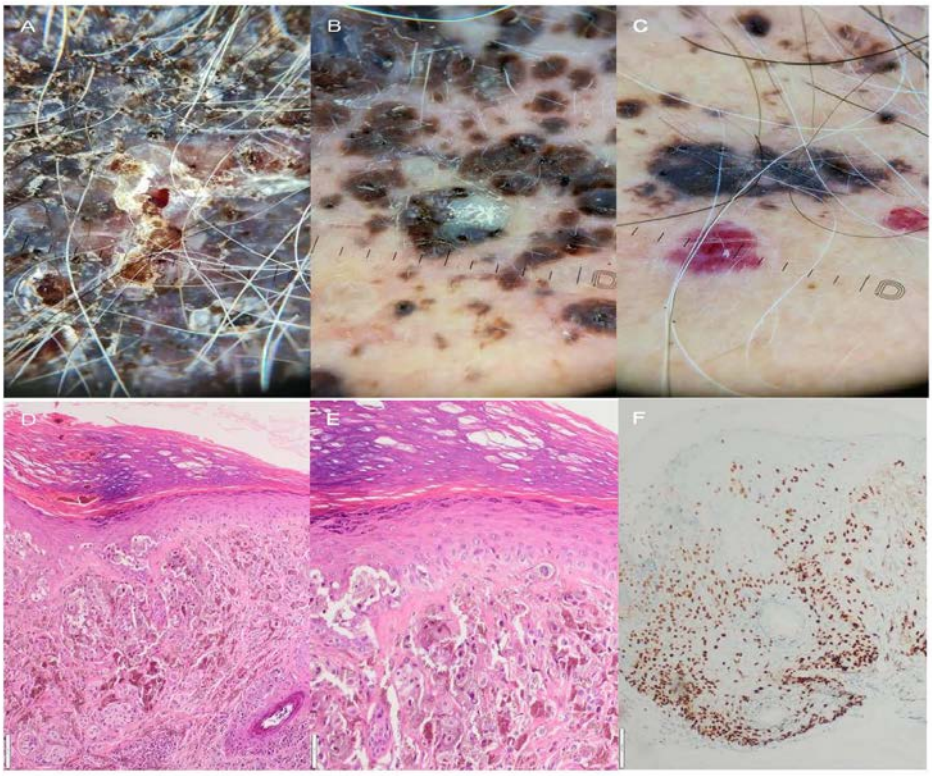

Figure 1. Dermoscopic and histopathological features of the lesion. (A–C) Dermoscopic examination revealed structureless black, gray and brown areas covered by scales and crusts, white shiny lines and structures, and focal ulceration. In the peripheral regions of the lesion, pink-red round-to-oval structureless areas with overlying white shiny streaks were observed. (D, E) Histopathological examination demonstrated melanoma composed of pleomorphic cells with an accompanying intraepidermal component (H&E, ×200 and ×400, respectively). (F) SOX10 immunohistochemical staining showed nuclear positivity in melanoma cells (×200).

Conclusion

Giant scalp melanomas are exceedingly rare, with limited cases reported (Table 1). They are defined by size >10 cm or confluent infiltrative growth and are associated with a high risk of metastatic dissemination. Reported cases have been managed with surgery and systemic therapies. In the present case, an exceptionally aggressive course led to death within four weeks of diagnosis, precluding molecular profiling and immunotherapy, underscoring the importance of early recognition. In conclusion, giant scalp melanomas pose major diagnostic and therapeutic challenges. Their intrinsic aggressiveness and frequent misdiagnosis as benign dermatoses contribute to high mortality. Melanoma should be considered in atypical, refractory, or rapidly progressive scalp lesions, and prompt histopathological confirmation is essential, as delay may result in a fulminant fatal outcome.

Case	Age/sex	Metastatic disease	Treatment
Ching A et al, 2012	70/M	No	Surgical excision and lymph node dissection
Panajotovic L et al, 2007	57/M	No	Surgical excision
González-González A et al, 2026	72/M	No	BRAF/MEK inhibitors
Current case, 2026	82/W	Yes	Ipilimumab and nivolumab (1 cycle) – death

Table 1. Reported cases of giant scalp melanomas

EA DV CONGRESS
VIENNA
30 SEP - 3 OCT 2026

Abstract N°: 1530

Nipple Adenoma: A rare benign lesion mimicking malignancy

Juana Sanguinetti*[1], Lía Salomé Abeledo[1], Maria Walker[1], Carla Trila[1], Corina Busso[1]

[1] Hospital Universitario Austral, Buenos Aires, Argentina

Introduction

Nipple adenoma is a rare benign lesion arising from the lactiferous ducts of the nipple–areolar complex. Clinically, it is often mistaken for malignant conditions, particularly Paget's disease or breast carcinoma, making histopathological evaluation essential for an accurate diagnosis.

It typically affects women in midlife, with a reported median age of around 56 years. Patients usually present with a palpable nipple nodule, frequently associated with surface changes such as erosion or ulceration, as well as serous or bloody discharge, crusting, or pruritus. Symptoms are often present for several months, and this clinical picture commonly raises suspicion of malignancy.

Initial evaluation includes physical examination, imaging, and sometimes cytology, although cytological findings may be misleading, showing atypical features despite the benign nature of the lesion. Imaging, particularly ultrasonography, has limited sensitivity. Therefore, the diagnosis ultimately relies on histopathological examination.

Histologically, nipple adenoma shows a ductal proliferation closely related to the nipple epithelium, with preservation of the myoepithelial layer. Different architectural patterns have been described, including adenosis, large duct, papillary, and pseudoinfiltrative forms, the latter of which may simulate invasive carcinoma. This overlap makes the differential diagnosis challenging and highlights the importance of careful evaluation.

Case Presentation

A 45-year-old woman with no significant past medical history presented to the Dermatology Department in October 2025 with an asymptomatic lesion on the right nipple, with a one-year history.

Physical examination revealed a 2 cm pink nodular lesion with firm-elastic consistency on the right nipple. A partial biopsy was performed, revealing a dermal adnexal lesion with apocrine differentiation, consistent with nipple adenoma.

Subsequent mammography showed no pathological findings. Complete surgical excision of the lesion was performed, achieving clear margins.

Conclusion

Nipple adenoma is an uncommon benign lesion that can closely mimic malignancy both clinically and histologically, which may lead to diagnostic uncertainty. For this reason, correlation between clinical, imaging, and histopathological findings is essential.

Once correctly diagnosed, management is straightforward, as complete surgical excision is usually curative. More conservative approaches are often sufficient, helping to avoid unnecessary aggressive procedures.

Overall, the prognosis is excellent, with a very low risk of recurrence after complete excision and no clear association with invasive carcinoma. Awareness of this entity is important to ensure appropriate diagnosis and management.

EA DV CONGRESS
VIENNA
30 SEP - 3 OCT 2026

Abstract N°: 1531

Tryptophan checkpoint enzyme G facilitates immune evasion through the epigenetic silencing of CCL5

Dingan Luo[1, 2, 3, 4, 5], Fang Li*[1, 2, 3, 4, 5], Yi He[1, 2, 3, 4, 5], Wenbin Zhou[1, 2, 3, 4, 5], Yunle Kuang[1, 2, 3, 4, 5], Lin Liang[1, 2, 3, 4, 5], Jing Zhang[1, 2, 3, 4, 5], Juan Su[1, 2, 3, 4, 5], Hong Liu[1, 2, 3, 4, 5], Xiang Chen[1, 2, 3, 4, 5], Xinwei Kuang[1, 2, 3, 4, 5]

[1] Department of Dermatology, Xiangya Hospital, Central South University, Changsha, China
[2] FuRong Laboratory, Changsha, China
[3] National Engineering Research Center of Personalized Diagnostic and Therapeutic Technology, Changsha, China
[4] Hunan Key Laboratory of Skin Cancer and Psoriasis, Changsha, China
[5] National Clinical Research Center for Geriatric Disease, Xiangya Hospital, Central South University, Changsha, China

Introduction
Metabolic reprogramming is a hallmark of malignancy, driving tumor initiation, progression, and therapeutic resistance. Within this metabolic landscape, amino acid pathways serve as pivotal regulators of tumor cell fitness and survival. Tryptophan (TRP) metabolism, in particular, has garnered significant attention for its multifaceted role in orchestrating immune evasion and reshaping the tumor microenvironment (TME). In melanoma, while TRP metabolism is known to promote malignancy, the precise molecular mechanisms by which its downstream rate-limiting enzyme, G, facilitates immune suppression remain poorly understood.

Materials and Methods
We employed an integrative approach combining multi-omics profiling, dietary TRP intervention models, and conditional knockdown systems of enzyme G to elucidate its role in melanoma pathogenesis. The functional impact on $CD8^+$ T cells was evaluated using single-cell RNA sequencing (scRNA-seq), flow cytometry, and *in vitro* co-culture assays. To dissect the regulatory axis, we utilized bulk RNA-seq, enzyme-linked immunosorbent assay (ELISA), and CUT&Tag to investigate the enzyme G-mediated regulation of CCL5 expression. Furthermore, we identified small-molecule inhibitors of enzyme G through structure-based virtual screening, surface plasmon resonance (SPR), and enzymatic activity assays, validating their therapeutic efficacy in tumor-bearing mice and clinical cohorts.

Results
Dietary restriction of TRP or genetic silencing of enzyme G significantly inhibited melanoma growth. We observed that enzyme G is aberrantly overexpressed in melanoma, and its depletion profoundly altered the TME by enhancing $CD8^+$ T cell activation. Mechanistically, enzyme G maintains NAD^+ homeostasis through the kynurenine pathway (KP), which subsequently activates the deacetylase SIRT1. Activated SIRT1 mediates the deacetylation of the CCL5 promoter, leading to its epigenetic silencing and disrupting the CCL5-CCR5 axis, which is essential for cytotoxic activity of $CD8^+$ T cells. We identified the clinical drug eltrombopag (ELT) as a potent and specific inhibitor of enzyme G. ELT demonstrated robust anti-tumor activity in an enzyme G-dependent manner and exhibited a strong synergistic effect when combined with anti-PD-1 therapy. Clinically, a combined molecular signature of high enzyme G and low CCL5 expression (enzyme G^{hi}/$CCL5^{lo}$) emerged as a robust biomarker for predicting resistance to immunotherapy and poor prognosis.

Conclusions
This study identifies the enzyme G/NAD^+/SIRT1 signaling axis as a critical epigenetic regulator of CCL5-mediated

anti-tumor immunity. By uncovering the potential of ELT as an inhibitor of enzyme G to sensitize tumors to anti-PD-1 therapy, our findings provide a novel mechanistic framework and promising translational strategies for precision combination immunotherapy in melanoma.

EA DV CONGRESS
VIENNA
30 SEP - 3 OCT 2026

Abstract N°: 1533

Secondary amino groups in ACE inhibitors/ Calcium Channel Blockers, Antiarrhythmics and Anticoagulants as donors for drug related phototoxicity/ carcinogenicity: the completely new role of the Nutritional nitrosogenesis as substantial additional cofactor for skin carcinogenesis

Georgi Tchernev[1, 2], Simona Kordeva*[1], Valentina Broshtilova-Nikolova[3], Konstantin Tchernev Jr[2]

[1] Medical Institute of Ministry of Interior - Department of Dermatology and Venereology, Sofia, Bulgaria

[2] Onkoderma- Clinic for Dermatology, Venereology and Dermatologic Surgery, Sofia, Bulgaria

[3] Sofia University Saint Kliment Ohridski, Faculty of Medicine - Department of Internal Diseases, Pharmacology and Clinical Pharmacology, Pediatrics, Epidemiology, Infectious Diseases, and Skin Diseases, Sofia, Bulgaria

Introduction

Drug-mediated phototoxicity and photocarcinogenicity remain incompletely understood, with one of the principal challenges being the apparently sporadic nature of these reactions. Their sporadic occurrence appears to depend on environmental factors, including 1) the concomitant intake of drugs containing secondary or tertiary amino groups with nitrite-rich foods under gastric conditions, with dietary patterns varying across populations; and 2) the exogenous formation of nitrosamines during the manufacturing process of medications containing such functional groups.

These processes can lead to the formation of nitrosamines, which are recognized as established photocarcinogens.

Materials and Methods

The subsequent resorption of the nitroso compounds may lead to increased concentrations in the bloodstream, with two possible outcomes:

1) The nitrosamines may undergo metabolic activation in the liver through enzymatic alpha-hydroxylation with cytochrome P450, resulting in dealkylated primary nitrosamine. This product is unstable and subsequently decomposes to form a diazoniumion - a DNA alkylating agent. The resulting DNA damage can lead to carcinogenesis.

2) Within the established bioavailability of nitroso compounds in peripheral blood, and when they are not metabolically activated in the liver, nitrosamines may exert genotoxic and phototoxic effects, when deposited on skin and following photodecomposition.

Upon reaching the skin, these compounds may undergo photodecomposition under ultraviolet radiation, leading to the release of nitric oxide and other procarcinogenic mediators capable of inducing DNA damage in keratinocytes and melanocytes. Consequently, malignant transformation may be initiated even in the absence of exogenous nitrosamine contamination in the administered medications. In this context, drugs from heterogenous classes may function as indirect sources of photocarcinogenic compounds within the skin.

Results

We present another case of keratinocyte cancer (basal cell carcinoma) (Figure a) that developed relatively shortly after combined intake of four drugs (apixaban, flecainide, amlodipine, and perindopril), each containing a

secondary amino group in its structure - serving as a potential precursor for the generation of photocarcinogens in the stomach. The defect has been treated via nasal tip rotation flap as dermatosurgical approach (Figure b).



Figure a,b: A nodular tumorous lesion protruding, with irregular borders and visible telangiectasias, located on the apex nasi (a). The defect was reconstructed via nasal tip rotation flap with the secondary defect closed with single interrupted sutures (b).

Conclusions

The role of endogenous gastric related Nitrosogenesis during the intake of potentially /completely uncontaminated drugs - particularly those containing secondary amino groups - in relation to nitroso-photocacinogenesis and subsequent development of skin cancer is considered. This perspective introduces a novel conceptual framework: even in the absence of exogenous nitrosamine contamination, endogenous nitrosamine formation prior to hepatic metabolism may represent a critical, previously underrecognized step in the pathway of nitrosocarcinogenesis.

EADV CONGRESS
VIENNA
30 SEP - 3 OCT 2026

Abstract N°: 1537

Polypharmacy and skin cancer: a new vision for skin cancer pathogenesis - photocarcinogenicity-mediated due to nitrosamine formation during telmisartan/tamsulosin intake

Georgi Tchernev[1, 2], Simona Kordeva*[1], Konstantin Tchernev Jr[2], James Patterson[3]

[1] Medical Institute of Ministry of Interior - Department of Dermatology and Venereology, Sofia, Bulgaria

[2] Onkoderma- Clinic for Dermatology, Venereology and Dermatologic Surgery, Sofia, Bulgaria

[3] University of Virginia - Department of Pathology, Charlottesville, United States

Introduction

Nitrosamines are mutagens, genotoxic substances, and mediators of phototoxicity/carcinogenicity, whose long-term daily usage, in the context of polypharmacy, can result in the parallel appearance of heterogeneous forms of skin cancer: keratinocytic and melanocytic.

Nitroso formation in certain drug classes with nitrosamines is proving to be more than a serious problem. The process is known also as Drug-related Nitrosogenesis. This problem is fueled on the one hand by the fact that nitrosamines are 1) photocarcinogens (known for decades), but on the other hand, they are also 2) mutagens/carcinogens, genotoxic substances (according to the FDA classification). The phototoxic effect according to current data is not calculated by the tests provided by the regulators (at least so far), which in practice leads to a miscalculation of the total, cumulative carcinogenic effect in the context of the intake of a contaminated mono or polymedication. The tests could be seen as either largely static, according to some clinical observations-even as categorically insufficient in terms of defining the concept of carcinogenicity in real-world settings (such as the intake of carcinogens with drugs, for example). These tests are determing a carcinogenic effect after metabolic activation in the liver and not the photocarcinogenic effect after photodecomposition on human skin.

Materials and Methods

Concepts such as phototoxicity and photocarcinogenicity appear to be inextricably linked, but unfortunately relatively little is known about their pathogenetic significance concerning skin cancer – including epithelial cancers but not only. Some questions remain as to: Why does a drug cause a phototoxic reaction in one patient but not in another? Is it determined by the body's contact with photocarcinogens present in certain batches of a drug but not in others? Which factors determine the occurrence of photocarcinogens in the body? What are the sources of photocarcinogens, e.g. foods, medicines, or cosmetic products? Which are more dangerous: nitrosamines in medicines or the products resulting from their metabolism? Is a particular nitrosamine metabolized differently depending on how it comes into contact with the human body, e.g. via the skin/skin microbiome, gut flora/ gut microbiome, or liver? Can certain nitrosamines be deposited in the skin without being metabolized and cause phototoxic and/or genotoxic reactions?

These questions can now be addressed within the emerging concept of nitrosogenesis of skin cancer, but not only: Even when medications are considered to be completely nitrosamine-free, they may, under gastric conditions and in the presence of nitrite-rich foods, undergo ntirosation , prior to hepatic metabolism.

Polymedication may further contribute to increased blood concentrations of certain (nitroso) compounds, mainly due to drug-drug interactions involving inhibition of cytochrome P450 (CYP) enzymes in the liver, which can

enhance their systemic bioavailability.

Once these compounds reach peripheral tissues, particularly the skin, they may undergo photodecomposition under UV light, leading to the generation of nitric oxide (NO) and reactive oxygen species (ROS). These processes may contribute to DNA damage and, consequently, to the development or progression of skin cancer.

Results

We present a patient with multiple actinic keratoses and an epithelial skin tumor in the scalp area (Figure a-d) that developed during therapy with Tamsulosin and Telmisartan, each containing a secondary amine within its chemical structure. These medications can also contain completely formed exogenously Nitrosamines/ NDSRIs.



Figure a-d: Solitary, round nodular tumor on the vertex of the scalp with a centrally located hyperkeratotic zone extending beyond the lesion's border and altering the shape at that point. On the contralateral side, a separate nodular growth with a regular shape, defined borders, and a pink, raised, pearly edge is noted. The surrounding skin is severely sun damaged (a,b). Intraoperative view (c,d): An elliptical excision of a tumor on the forehead resulted in aprimary wound defect, with the marked lesion on the [capillitium], visible in the background. The wound defects on both the [capillitium] (upper lesion) and the forehead (lower lesion) were closed using single interrupted sutures.

Conclusions

We comment on the role of drug-mediated Photo-Nitrosocarcinogenesis/Oncopharmacogenesis in the background of potential/actual exo- and endogenous carcinogen contamination and formation. Successful surgical treatment by modified advancement flap and cryotherapy was performed.

EADV CONGRESS
VIENNA
30 SEP - 3 OCT 2026

Abstract N°: 1541

Secondary cutaneous plasmacytomas in multiple myeloma: A marker of disease progression and poor prognosis

Laila Zineb Chbihi Moukit*[1], Layla Bendaoud[1], Mariem Aboudourib[1], Ouafa Hocar[1], Said Amal[1]

[1] Department of Dermatology-Venerology, Mohammed VI University Hospital, Biosciences and Health Laboratory, Cadi Ayyad University, Marrakech, Morocco

Introduction

Cutaneous involvement in multiple myeloma is an uncommon manifestation, usually occurring in advanced stages. It may arise from hematogenous dissemination or infiltration of plasma cells from underlying bone lesions, resulting in secondary cutaneous plasmacytomas. These lesions often reflect aggressive disease which is associated with poor prognosis.

Case Presentation

A 65-year-old woman with medical history of type 2 diabetes mellitus, hypertension and a breast cancer treated 10 years earlier, currently in remission, had been diagnosed with multiple myeloma three years prior, initially presenting with bone pain and anemia. Laboratory evaluation revealed an IgA lambda monoclonal gammopathy, and bone marrow examination showed 40% plasma cell infiltration.

Despite multiple lines of chemotherapy, disease progression was observed. One month prior to admission, the patient developed multiple rapidly enlarging, painful, erythematous nodules involving the left upper limb, overlying an area of acquired lymphedema.

Histopathological examination of two skin lesions showed a dense dermal infiltrate of atypical plasma cells expressing CD138, with monoclonality for lambda light chain, consistent with secondary cutaneous plasmacytomas.

The patient was treated with dexamethasone, leading to a transient regression of the lesions. Treatment discontinuation due to systemic infection was followed by rapid relapse.

Throughout the remainder of her hospitalization, the patient remained severely ill and unable to tolerate further steroids or cancer therapy. She was transitioned to comfort care.



Erythematous nodules involving the left upper limb, arising in an area of acquired lymphedema.

Conclusion

Secondary cutaneous plasmacytomas represent a rare but well-recognized manifestation of advanced multiple myeloma and are indicative of aggressive disease with unfavorable outcome. Their recognition is essential, as they often signify systemic progression and the need for therapeutic reassessment.

EADV CONGRESS
VIENNA
30 SEP - 3 OCT 2026

Abstract N°: 1549

carcinoid-associated cutaneous scleroderma: a clinicopathological marker of advanced ileal neuroendocrine tumors

María Valentina Oliver Hernandez*[1], Valeria Ojeda Silva[2], Andres Soto[3], Carlos Alberto Ojeda[2]

[1] Fundación Universitaria Sanitas. Bogotá, Colombia., Hospital Universitario la Samaritana, Bogotá, Colombia
[2] Hospital Universitario la Samaritana, Bogota, Colombia
[3] Universidad Nacional de Colombia, Bogotá, Colombia

Introduction

Within the spectrum of scleroderma-like disorders, cutaneous fibrosis of paraneoplastic origin represents a pathophysiologically autonomous entity, independent of the immunological mechanisms that define idiopathic systemic sclerosis. Carcinoid-associated scleroderma offers a compelling illustration of this distinction: cutaneous fibrosis does not arise from a dysregulated immune response, but from the direct effect of vasoactive mediators — serotonin, substance P, and neurokinin A — secreted by neuroendocrine tumors of ileal origin. The presence of hepatic metastases constitutes a pathophysiological prerequisite: it is the saturation of first-pass hepatic metabolism that allows these mediators to reach the systemic circulation in concentrations sufficient to induce dermal remodeling and fibroblast activation, independent of any immunological mechanism. The resulting clinical picture faithfully reproduces idiopathic systemic sclerosis in its cutaneous and histological expression, yet lacks its serological markers and follows a radically different pathogenic logic. This dissociation between the cutaneous phenotype and serology does not represent a diagnostic void, but rather the key that directs investigation toward a non-autoimmune underlying cause. Since cutaneous fibrosis may precede the systemic manifestations of the tumor, the skin represents its first detectable expression, placing the dermatologist in a frontline diagnostic position.

Case Presentation

A 72-year-old male presented with progressive sclerodermoid cutaneous changes of the lower limbs, in the setting of stage IV well-differentiated neuroendocrine tumor of the distal ileum, synchronous hepatic metastases, and active carcinoid syndrome. The clinical course had been marked by carcinoid heart disease requiring bioprosthetic tricuspid and pulmonary valve replacement, evidence of the simultaneous action of profibrotic mediators across multiple target organs. Diffuse brown-violaceous hyperpigmentation and dermal induration of the lower limbs were documented, without sclerodactyly or Raynaud phenomenon; the serological workup revealed no systemic sclerosis-specific autoantibodies. Facial examination showed persistent erythema with telangiectasias. Doppler ultrasound ruled out significant vascular disease. Skin biopsy demonstrated tufted capillary proliferation, lymphohistiocytic infiltrate, erythrocyte extravasation, and hemosiderin deposition. Clinicopathological correlation supported the diagnosis of paraneoplastic cutaneous scleroderma in the setting of active carcinoid syndrome.

Conclusion

The coexistence of cutaneous scleroderma and carcinoid heart disease does not constitute a clinical coincidence, but rather the expression of convergent fibrotic pathways driven by the same tumor-derived vasoactive microenvironment, which explains their association with advanced stages of disease. Hepatic metastases do not represent an incidental finding: they constitute the necessary condition for the systemic mediator burden to reach

the threshold required to induce dermal fibrosis. The described phenotype — lower limb predominance without acral distribution, absence of Raynaud phenomenon, visceral fibrosis restricted to the endocardium, and seronegativity — allows differentiation from idiopathic systemic sclerosis. Of particular clinical significance, sclerodermoid changes in a seronegative patient should not be interpreted as atypical autoimmunity, but should prompt systematic investigation for an underlying neuroendocrine malignancy. The skin may represent the first detectable manifestation of the tumor — and the dermatologist, the first to recognize it.

EADV CONGRESS
VIENNA
30 SEP - 3 OCT 2026

Abstract N°: 1551

Atypical vascular lesions after breast cancer radiotherapy: clinicopathologic features

Bugra Burc Dagtas*[1], Cem Leblebici[2], Ayse Esra Koku Aksu[3]

[1] Department of Dermatology, Faculty of Medicine, Istanbul Medeniyet University., Istanbul, Türkiye
[2] Department of Pathology, Istanbul Training and Reseach Hospital, Istanbul, Türkiye
[3] Department of Dermatology, Istanbul Training and Reseach Hospital Istanbul, Türkiye, Istanbul, Türkiye

Introduction
Atypical vascular lesions (AVLs) are rare benign vascular proliferations arising in previously irradiated skin, most commonly after breast cancer treatment. They may clinically and histologically mimic radiation-associated angiosarcoma (RAAS), necessitating accurate clinicopathologic evaluation.

Materials and Methods
We retrospectively analyzed 10 female patients diagnosed with AVL following breast cancer treatment between 2013 and 2025. All patients had received surgery, chemotherapy, and radiotherapy. Clinical data, including latency, lesion characteristics, treatment, and follow-up, were collected. Histopathological and immunohistochemical evaluation (CD31, D2-40, c-myc, Ki-67) was performed in all cases.

Results
The median age was 53 years (range 34–63). The median latency from radiotherapy to lesion onset was 52.5 months (range 20–175), and the median lesion duration was 5 months. All lesions developed within irradiated fields. Lesions were solitary in 4 patients, multiple (≥10) in 5, and triple in 1.

All patients underwent complete surgical excision with histologically negative margins. No recurrences or malignant progression were observed during a median follow-up of 3.5 years (range 0.5–12).

Histologically, 8 cases were lymphatic subtype, one demonstrated mixed subtypes, and one was vascular subtype. CD31 was positive in all cases. D2-40 was positive in lymphatic and mixed subtypes and negative in vascular subtype. No c-myc overexpression was detected. Ki-67 indices ranged from 1% to 7%.

Conclusions
AVLs are benign post-radiotherapy vascular proliferations with a heterogeneous histopathologic spectrum. The absence of c-myc overexpression and low Ki-67 indices support their distinction from RAAS. Complete excision with negative margins and long-term follow-up are essential for optimal management.

EADV CONGRESS
VIENNA
30 SEP - 3 OCT 2026

Abstract N°: 1554

atypical acral cd8+ mycosis fungoides: the diagnostic challenge of the dorsal hand and foot variant

María Valentina Oliver Hernandez*[1], Alejandra Sáenz Peñas[1], María Ariza[2], Elkin PEÑARANDA[3]

[1] Fundación Universitaria Sanitas. Bogotá, Colombia., Bogota, Colombia

[2] Fundación Universitaria Sanitas., Bogotá, Colombia

[3] Clinica Nogales, Fundación Universitaria Sanitas, Bogotá, Colombia

Introduction

Mycosis fungoides (MF) is the most common primary cutaneous T-cell lymphoma, typically involving sun-protected areas. Acral variants are rare and include mycosis fungoides palmaris et plantaris. Recently, involvement of dorsal acral surfaces has been described as a distinct and underrecognized presentation. These lesions may clinically mimic inflammatory or autoimmune dermatoses, posing significant diagnostic challenges.

Case Presentation

A patient presented with a one-year history of asymptomatic papules over the metacarpophalangeal and interphalangeal joints, progressing into plaques involving the dorsal hands, feet, and ankles. Lesions showed fine atrophy with a cigarette paper–like appearance. Gottron-like papules raised suspicion of dermatomyositis; however, there were no nail changes, muscle weakness, or creatine phosphokinase elevation, and autoimmune serology was negative.

Skin biopsy revealed a T-cell lymphoid infiltrate suggestive of MF with a CD8+ immunophenotype. Given the atypical morphology and localized distribution, a second biopsy was performed, confirming MF by demonstrating epidermotropism with atypical lymphocytes. Immunohistochemistry showed CD2, CD3, and CD5 positivity with CD8 predominance. A diagnosis of CD8+ acral MF involving dorsal surfaces was established, and topical corticosteroids were initiated.

Conclusion

Dorsal acral MF represents a rare and likely underrecognized variant characterized by involvement of the dorsal hands and feet. Unlike palmar and plantar forms, this presentation frequently affects the knuckles and may closely resemble dermatomyositis or chronic eczema, leading to diagnostic delay.

The CD8+ immunophenotype observed in this case is uncommon in MF but has been associated with indolent behavior in early-stage disease. The strictly localized distribution in mechanically exposed areas supports the hypothesis of chronic antigenic stimulation contributing to localized clonal T-cell expansion.

MF should be considered in the differential diagnosis of acral dermatoses with dermatomyositis-like features. Accurate diagnosis relies on clinicopathological correlation and may require repeated biopsy. Recognition of CD8+ dorsal acral MF expands the clinical spectrum of early-stage disease and helps avoid misdiagnosis.

EA DV CONGRESS
VIENNA
30 SEP - 3 OCT 2026

Abstract N°: 1557

A Turning Point in Melanoma Mortality: National Declines Following Immunotherapy Mask Persistent U.S. Disparities, 1999–2024

Abdullah Almeziny*[1]

[1] College of Medicine, Imam Mohammad Ibn Saud Islamic University, Riyadh, Saudi Arabia, Riyadah, Saudi Arabia

Introduction
Malignant melanoma remains one of the most lethal skin cancers, with rising incidence but evolving mortality patterns. While the introduction of immune checkpoint inhibitors has transformed outcomes, whether these advances have translated into equitable population-level survival gains remains unclear.

Materials and Methods
We conducted a nationwide population-based analysis of melanoma mortality in the United States from 1999 to 2024 using CDC WONDER data. Deaths were identified using ICD-10 code C43. Age-adjusted mortality rates (AAMRs) per 100,000 population were calculated using the 2000 U.S. standard population and stratified by sex, age, race/ethnicity, region, state, and urbanization. Temporal trends were analyzed using Joinpoint regression to identify significant changes and estimate annual percent changes (APCs).

Results
A total of 247,909 melanoma-related deaths were identified. Mortality demonstrated a clear inflection point, with a gradual increase from 1999–2013, followed by a **sharp decline from 2013–2017**, and subsequent stabilization through 2024. The average AAMR was 2.8 per 100,000.

Men experienced more than double the mortality of women (4.1 vs 1.8 per 100,000), and individuals aged ≥65 years accounted for the majority of deaths. Non-Hispanic White populations bore the highest mortality burden; however, disparities persisted across racial and ethnic groups. Geographic inequalities were pronounced, with higher mortality in the West and South and in nonmetropolitan compared with metropolitan regions. State-level variation remained substantial, with consistently elevated mortality in Idaho and Oklahoma.

Importantly, the post-2013 decline coincided with the widespread adoption of immune checkpoint inhibitors and targeted therapies, suggesting a **population-level therapeutic effect**. However, this survival benefit was unevenly distributed, with persistent disparities across demographic and geographic subgroups.

Conclusions
Melanoma mortality in the United States has entered a **new therapeutic era**, marked by significant declines following the introduction of modern systemic therapies. However, these gains remain **inequitably distributed**, with enduring disparities by sex, age, geography, and race/ethnicity.

The stabilization of mortality after 2017 highlights the **limits of treatment innovation alone** and underscores the urgent need for **equitable access to advanced therapies, improved early detection, and targeted public health interventions**. Addressing these gaps is essential to sustain progress and achieve meaningful reductions in melanoma mortality at the population level.

EA DV CONGRESS
VIENNA
30 SEP - 3 OCT 2026

Abstract N°: 1574

Primary Cutaneous Follicle Center Lymphoma of the Scalp during Anti–TNF alpha therapy

Dorsaf Elinkichari*[1], Marie Donzel[2], Stephane Dalle[1]

[1] Dermatology Department, Centre Hospitalier Lyon Sud, HCL, Lyon, France
[2] Pathology Department, Centre Hospitalier Lyon Sud, HCL, Lyon, France

Introduction

Primary cutaneous lymphomas (PCL) are a heterogeneous group of extranodal non-Hodgkin lymphomas. Approximately, 25% of PCL are B-cell derived and are classified into 3 major entities: Primary cutaneous follicle center lymphoma (PCFCL), primary cutaneous diffuse large B-cell lymphoma, leg type (PCDLBCL, LT), and primary cutaneous marginal zone lymphoma (PCMZL). Epstein–Barr virus (EBV)-positive mucocutaneous ulcer (EBVMCU) is a recently described EBV-positive lymphoproliferative disorder that affects the skin and mucosa.
We report a PCFCL occurring under anti-TNF alpha therapy for Crohn's disease.

Case Presentation

A 35-year-old man with a history of Crohn's disease, receiving adalimumab therapy for the past 7 years, presented with a 6-month history of a progressively enlarging alopecic patch of the scalp. The lesion was initially identified by his hairdresser and subsequently showed progressive enlargement, and became painful upon minimal contact. His general condition remained preserved, with no associated fever or weight loss. Physical examination demonstrated an inflammatory erythemato-violaceous plaque located on the vertex, measuring approximately 7–8 × 9–10 cm, with overlying yellow crusts. Palpation revealed firm, fixed, and tender nodules. No regional lymphadenopathy was observed. Mycological examination, including direct microscopy and fungal culture, yielded negative results. A scalp biopsy was performed, with neutrophilic dermatosis of the scalp, and kerion considered as the main diagnostic hypotheses. Histopathological examination concluded to a cutaneous localization of a B-cell lymphoma rich in large cells, with germinal center phenotype. Serum protein electrophoresis and peripheral blood immunophenotyping were within normal limits. Serological testing for Lyme disease and Epstein–Barr virus was negative. FDG PET/CT was unremarkable, except for hypermetabolic activity confined to the scalp lesion. The diagnosis of a primary cutaneous follicle center lymphoma (PCFCL) of scalp was retained. The patient underwent radiotherapy at a total dose of 30–36 Gy delivered in 15–18 fractions to the involved field, resulting in regression of the lesion. Residual cicatricial alopecia persisted at the site of the previously infiltrated plaque.

Conclusion

PCFCL is commonly presenting as a solitary purple to pink papule or as multiple papules, plaques or nodules with a rim of peripheral erythema occurring on the forehead, neck and upper back in middle-aged adults. While grouped lesions may be observed, multifocal disease is less common, as are rare presentations, including rhinophyma and scarring alopecia. Our case is particular as the lymphoma appeared in a patient treated with adalimumab. To our knowledge, 55 cases of cutaneous lymphomas have been reported after anti-TNF alpha agent exposure. Mycosis fungoides / Sezary syndrome were identified in 35 cases (64%). Most patients were treated with anti-TNF alpha for psoriasis. Consistently, in patients without an initial biopsy, the possibility of pre-existing cutaneous T cell lymphoma with psoriasiform presentation should be considered. Regarding PCFCL, only one patient is reported in the present literature, treated with radiotherapy with complete remission, with anti-TNF

alpha resumed without recurrence at 9 years of follow-up.

Cutaneous lymphomas do occur in patients receiving anti-TNF alpha therapy. However, a causal relationship has not been formally established. These cases may reflect coincidence or initial misdiagnosis, particularly in psoriasiform T-cell lymphomas. We report the second case of PCFCL occurring under anti-TNF alpha therapy.

EADV CONGRESS
VIENNA
30 SEP - 3 OCT 2026

Abstract N°: 1600

Photoprotection and Skin Cancer Among Fishing Professionals in a Tropical Coastal Population: A Cross-Sectional Study

Lillian Rodrigues de Freitas[1], Laura Paes Moraes[1], Liana Moura De Almeida[1], Áurea Maria Salomão Simão[2], Diogo Pazzini Bomfim*[3], Julia Laluce Cardoso[3]

[1] Hospital Escola Álvaro Alvim, Faculdade de Medicina de Campos, Campos dos Goytacazes, Brazil
[2] Mayo Clinic, Rochester, United States
[3] Derma Focus Cursos LTDA, São Paulo, Brazil

Introduction

Skin cancer is the most prevalent malignancy in Brazil, with ultraviolet (UV) radiation exposure being the primary risk factor. Certain occupations, such as fishing, involve prolonged sun exposure and are associated with an increased risk of developing skin cancer. This study aimed to characterize the practices and epidemiological profile to identify risk factors for skin cancer among fishermen in a tropical coastal population.

Materials and Methods

We conducted a cross-sectional analysis between September 2024 and April 2025, following ethical standards. Data were collected through structured questionnaires administered to fishermen. Associations among variables were analyzed using the chi-square test.

Results

A total of 103 fishermen were included (43% male, 57% female), and they were predominantly older than 55 years-old (47.6%). Participants had an overall low educational levels (68% with incomplete primary education). The most common occupational activities were artisanal fishing (33%) and professional fishing (31%). Fitzpatrick skin phototypes II–IV were the most prevalent. Daily sun exposure exceeding 8 hours was reported by 50% of the participants, with 52% reporting more than 30 years of occupational sun exposure. A history of sunburn was reported by 70%. Photodamage was observed in 89% of participants, predominantly solar melanosis (68.1%). Suspicious lesions suggestive of skin cancer were identified in 13.2%, and 9% reported a previous diagnosis of skin cancer, primarily basal cell carcinoma on the face. Although 90% recognized the importance of photoprotection, adherence to preventive measures was suboptimal. Among users, 31.3% used hats, 17.2% used both sunscreen and hats, 10% combined sunscreen with UV-protective clothing, and 17.2% used sunscreen alone. Among non-users, the main barriers were lack of interest (45%), lack of knowledge (19%), and financial constraints (19%). Regarding dermatological care, 63% had never consulted a dermatologist, mainly because they did not consider it necessary. No significant association was found between photoprotective measures and sex (OR = 0.802; 95% CI: 0.357–1.782; p = 0.687). Notably, all participants (100%) with a prior history of skin cancer presented photodamage.

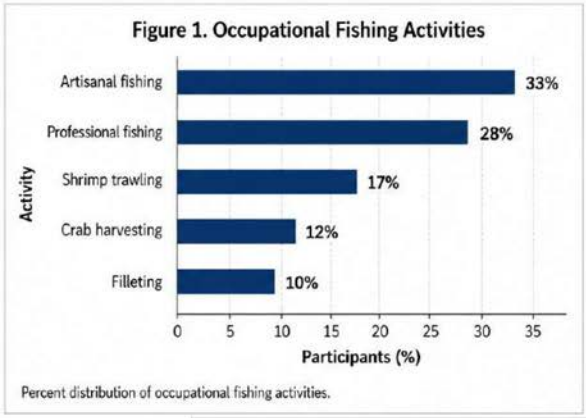

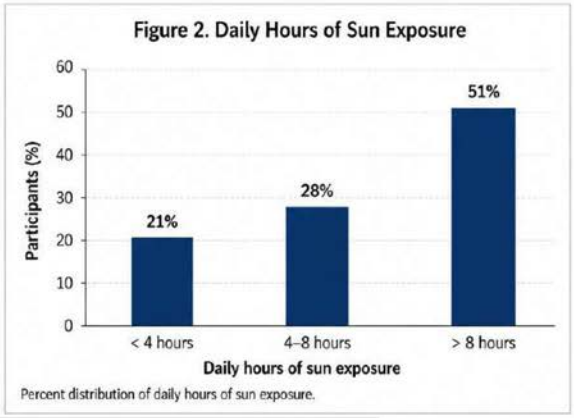

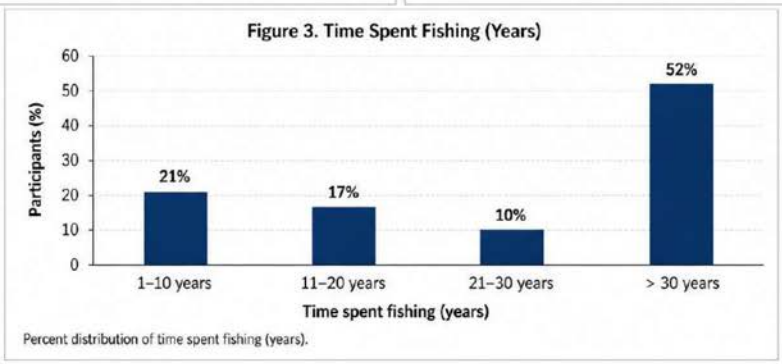

Occupational characteristics and sun exposure among fishing professionals. (A) Distribution of occupational fishing activities. (B) Daily hours of sun exposure. (C) Duration of occupational fishing (years). Values are presented as percentages.

Conclusions

The high prevalence of photodamage (89%) among fishermen highlights the strong association between chronic sun exposure and its cumulative effects. Despite good awareness of photoprotection, adherence to preventive practices remains insufficient, mainly due to informational and socioeconomic barriers. These findings underscore the need for targeted educational strategies and public health interventions to improve prevention and early detection of skin cancer,

particularly in underserved high-risk populations.

EADV CONGRESS
VIENNA
30 SEP - 3 OCT 2026

Abstract N°: 1607

Anti-epileptic-induced T-cell Pseudolymphoma with Complex Peripheral TCR Rearrangements: A Diagnostic Pitfall

Alihan Baylan*[1], Hande Ermis Akkus[1], Alp Can Erkiner[1], Nesimi Buyukbabani[2], Asude Kara Polat[1], Savaş Yaylı[1]

[1] Koç University School of Medicine, Department of Dermatology, Istanbul, Turkey, Istanbul, Türkiye
[2] Koc University Hospital, Department of Pathology, Istanbul, Türkiye

Introduction

Cutaneous pseudolymphomas (CPL) are benign lymphocytic infiltrates simulating cutaneous lymphomas. This mimicry is challenging in cases with scattered CD30 positivity and complex molecular findings. Aromatic antiepileptic agents (carbamazepine, lamotrigine) are common triggers for drug-induced CPL (D-CPL), often presenting as "pseudo-mycosis fungoides" or simulating other cutaneous T-cell lymphomas (CTCL). This requires a multidisciplinary approach for accurate diagnosis. We present a unique T-cell pseudolymphomatous infiltrate containing scattered CD30-positive cells with complex peripheral T-cell receptor (TCR) rearrangements, highlighting the importance of clinico-pathological correlation.

Case Presentation

A patient with a long-standing history of epilepsy presented with a 15-day history of a pruritic, poorly demarcated erythematous patch–plaque located on the inner aspect of the upper arm. The clinical history revealed long-term antiepileptic therapy with carbamazepine and lamotrigine, prescribed since childhood. Notably, a previous skin biopsy performed two years earlier—while the patient was on the same antiepileptic regimen—for suspected mycosis fungoides (MF) had demonstrated findings consistent with subacute spongiotic dermatitis. Although the previous pathology slides were unavailable for re-evaluation, the original report described findings consistent with subacute spongiotic dermatitis and notably made no mention of a dense pseudolymphomatous infiltrate or lymphocytic atypia.

Current histopathological examination revealed a dense superficial dermal perivascular lymphoid infiltrate. The infiltrate was notably polymorphic, composed predominantly of atypical T lymphocytes with prominent nucleoli and increased mitotic figures, accompanied by a significant number of eosinophils. The epidermis was spared, showing no evidence of epidermotropism, and immunohistochemical analysis demonstrated a CD3+/CD4+ dominant infiltrate containing scattered large, activated cells expressing CD30, which accounted for approximately 20% of the total cell population. Peripheral blood analysis showed 6% eosinophilia.

Flow cytometry demonstrated a normal CD4/CD8 ratio of 1.7. Within the total lymphocyte population, the proportions of aberrant subsets were recorded as: CD3+CD4+CD7- at 8.3% (82/mm3), CD3+CD4+CD26- at 5.3% (209/mm3), and CD3+CD4+CD7-CD26- at 8.9% (67/mm3), remaining significantly below the diagnostic thresholds for systemic involvement. These values confirmed that the circulating atypical cells represented a reactive expansion rather than a malignant process. TCR gene rearrangement analysis performed on peripheral blood demonstrated oligoclonality in the TCR-beta locus and a monoclonal rearrangement on a polyclonal background in the TCR-gamma locus.

Conclusion

This case illustrates a notable diagnostic pitfall where reactive drug-induced infiltrates mimic lymphoproliferative

processes. While clinical features favored a lymphomatoid drug reaction—supported by intense eosinophilic infiltrate and temporal drug relationship—the scattered CD30+ cells and complex TCR rearrangements necessitated careful exclusion of CD30+ disorders. Although primary cutaneous anaplastic large-cell lymphoma was unlikely due to low CD30 expression, the lack of epidermotropism helped distinguish the lesions from Type B lymphomatoid papulosis. Integrated flow cytometry confirmed that atypical cells represented a reactive expansion rather than a high-burden malignant clone. Aromatic antiepileptics are "great mimickers" of lymphoma. Our findings highlight that TCR rearrangements in reactive states should be interpreted with caution as they can represent pseudoclonality rather than definitive malignancy. This case reinforces that holistic integration of clinical history, histology, and molecular data is essential to avoid overtreatment. Lesions are currently controlled with topical corticosteroids, with planned clinical follow-up.

EA DV CONGRESS
VIENNA
30 SEP - 3 OCT 2026

Abstract N°: 1621

Seasonal Variation in Skin cancer presentation in primary care clinic in Sydney, NSW, Australia

Marjia Johns*[1], Yagiz Aksoy[2], Gilberto Moreno[1]

[1] The Skin & Cancer Foundation Australia, Westmead, Australia
[2] The University of Sydney, Camperdown, Australia

Introduction

Seasonal variation in both melanoma and non-melanoma skin cancer presentation has been noted in the literature, with the vast majority showing increased incidence of skin cancer in the summer months. The majority of this literature shows Northern Hemisphere trends, with less noted on trends in the Southern Hemisphere. This is the first study to compares data from a primary care skin clinic in Sydney over a decade, examining seasonal variation on skin cancer presentation, and the impact of COVID 19.

Materials and Methods

A retrospective was performed based on a histopathological data taken from a primary care clinic in the western suburbs of Sydney, NSW between March 2016 to March 2026. Inclusion criteria were basal cell carcinoma (BCC), squamous cell carcinoma (SCC) and melanoma. Multiple complementary analytical approaches were performed, including cosinor harmonic regression, negative binomial models, mixed-effects models, time series decomposition, and Bayesian inference. Analyses incorporated sensitivity testing to distinguish biological seasonalilty from operational influences (e.g. clinic closures, “holiday effect), and to evaluate the impact of COVID 19.

Results

9778 skin cancers were included over a nine-year period, which included BCC; (n=5,290; 54.1%), SCC; (n=4,041; 41.3%), and melanoma (n=447; 4.6%). Seasonal differences were statistically significant, however clinically negligible. Conversely, there was a demonstrated reduction in presentations at the onset of COVID-19, with sustained reduction in presentations through to 2024.

No clinically significant seasonal variation in skin cancer presentations was found, in direct contrast with literature from the northern hemisphere. This may reflect Australia’s milder climate and relatively high annual ultraviolet index, effective public health messaging and the accessibility of primary care services. Deficits in presentations throughout the year appear operation-dependent as opposed to biological seasonality. The significant and sustained impact of COVID-19 on skin cancer presentation raises concerns regarding the ongoing impact of delayed diagnoses of skin cancer in the Australian population.

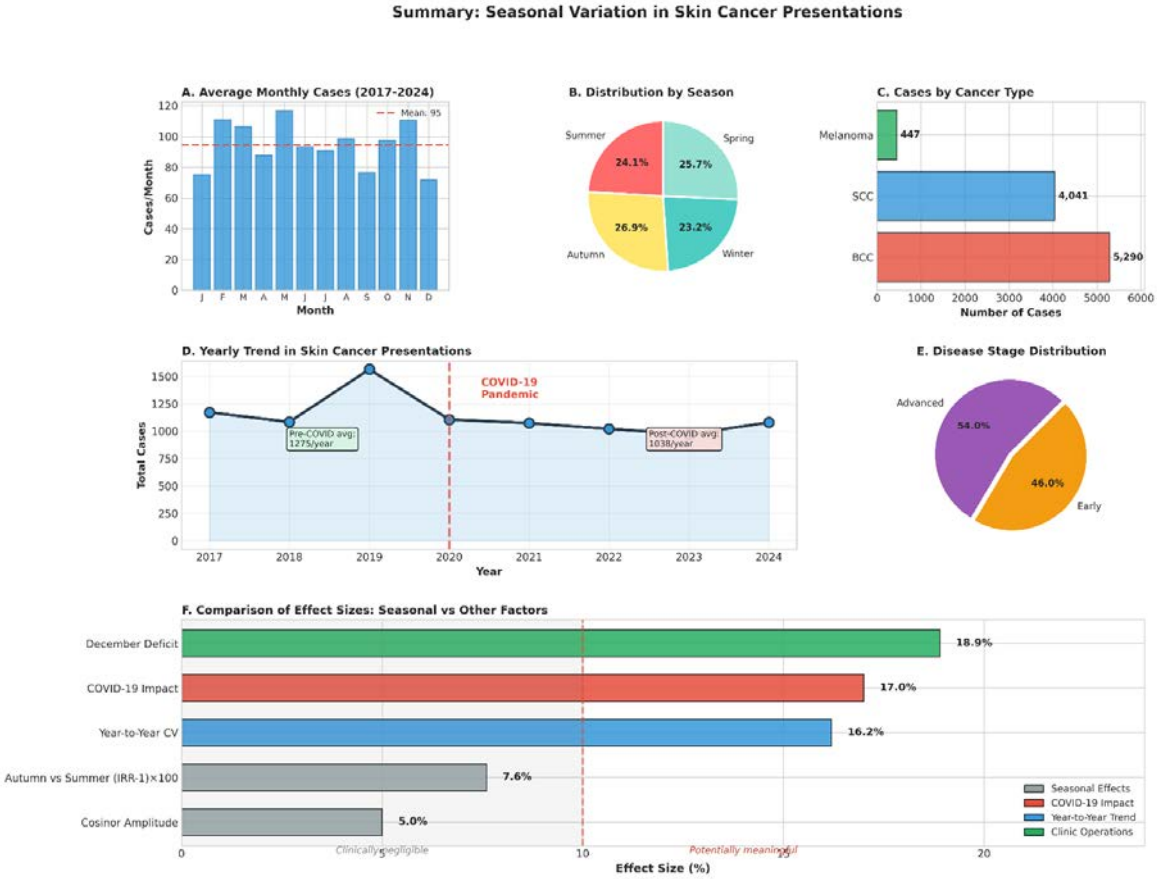

Summary dashboard of key findings. Upper panels: monthly distribution, seasonal breakdown, and cancer type composition. Middle: yearly trends and key statistics. Lower panel: effect size comparison showing seasonal effects (5.0-7.6%) are smaller than COVID-19 impact (17.0%), year-to-year variation (16.2%), and December closure effect (18.9%). Dashed line indicates 10% clinical meaningfulness threshold.

Conclusions

No clinically significant seasonal variation in skin cancer presentation was found in a large primary care skin cancer cohort in metropolitan Sydney, however, COVID-19 exerts a substantial and sustained impact. Vigilance regarding the long-term consequences of pandemic-related healthcare disruptions is warranted.

EADV CONGRESS
VIENNA
30 SEP - 3 OCT 2026

Abstract N°: 1624

Treating the Symptom or the Clone? High-Priority Paraneoplastic Vasculitis in Binet B Chronic Lymphocytic Leukemia with Unmutated IGHV

Juan Sebastian Orozco Carrillo*[1], Beatriz Soto Cala[1], Margarita Tamayo[1], Santiago Bernal[1], Leonardo Bohorquez[2]

[1] Pontificial Xaverian University, San Ignacio University Hospital, Bogotá DC, Colombia

[2] San Ignacio University Hospital, Bogotá DC, Colombia

Introduction

Paraneoplastic vasculitis and Sjogren syndrome represent rare manifestations of hematologic malignancies, particularly chronic lymphocytic leukemia (CLL). The coexistence of ANCA positivity, leukocytoclastic vasculitis (LCV), neutrophilic panniculitis and new-onset Sjogren syndrome in a patient with a prior hematologic neoplasm is unusual and poses diagnostic and therapeutic challenges.

Case Presentation

We present the case of a 62-year-old woman with a 5-year history of chronic lymphocytic leukemia/small lymphocytic lymphoma (CLL/SLL) Binet stage B, Rai stage I, CLL-IPI score of 2, with unmutated IGHV status. under watchful waiting by hematology, with a 3-year history of recurrent generalized purpuric lesions predominantly affecting the lower extremities, associated with edema, pruritus, and intermittent fever, as well as a neuropathic pain in limbs. Furthermore, eight months prior to consulting, she starts with sicca symptoms.

Physical examination revealed palpable purpura, nodules, and erythematous-violaceous plaques predominantly in limbs. Laboratory workup revealed positive anti-PR3 ANCA, positive anti-Ro and elevated rheumatoid factor. Imaging studies revealed multiple lymphadenopathies, which remained stable in both size and number compared with prior studies, without evidence of compressive or obstructive involvement of adjacent organs. Skin biopsy confirmed leukocytoclastic vasculitis with neutrophilic lobular panniculitis. Minor salivary gland biopsy revealed morphological findings consistent with focal lymphocytic sialadenitis.

A multidisciplinary panel including rheumatology, hematology–oncology, and dermatology determined that her oncologic condition was controlled, with no current indication for disease-specific oncologic therapy. Given systemic involvement (cutaneous, pulmonary nodules, and neuropathy), a diagnosis of ANCA-associated vasculitis likely of paraneoplastic origin was established, as well as a concomitant Sjögren syndrome. Previous treatment with azathioprine was ineffective. Rituximab was recommended as first-line therapy, but due to administrative barriers within a financially strained healthcare system, cyclophosphamide combined with a short course of prednisolone was initiated given their greater accessibility.

Conclusion

This case highlights that in Binet B/Rai I CLL, severe paraneoplastic manifestations—such as ANCA-associated vasculitis and Sjögren syndrome—can precede clinical progression of the malignancy.
In patients with a high-risk biological profile, such as unmutated IGHV, immune dysregulation may pose a more immediate threat than tumor burden itself. Therefore, the therapeutic priority should shift toward aggressive immunosuppression to prevent irreversible organ damage, even when criteria for onco-specific treatment are not yet met. A multidisciplinary 'Watch & Treat' strategy is essential to balance paraneoplastic control with hematological surveillance

EA DV CONGRESS
VIENNA
30 SEP - 3 OCT 2026

Abstract N°: 1634

ABO/Rh blood group distribution in patients with basal cell carcinoma: a cross-sectional study in Colombia

David Alejandro Caviedes-Cómbita[1], Jennipher Andrea Blanco Gomez[1], Eunhye Lee[1], Karen Andrea Roa-Salas[1], Valentina Fernández-Castro[1], Jesus Daniel Fierro Lozada[1], David Castillo-Molina*[1]

[1] Fundación para la Investigación en Dermatología, Bogotá, Colombia

Introduction

Basal cell carcinoma (BCC) is the most common neoplasm worldwide, mainly linked to chronic ultraviolet exposure and skin phenotype. However, individual risk variability suggests additional factors, including the ABO blood group system. ABO antigens, expressed on epithelial cells, are involved in adhesion and immune surveillance. Evidence suggests non-O blood groups may have a slightly lower BCC risk than group O. We aim to describe the distribution of ABO/Rh blood types among patients with BCC at a dermatological center in Bogota.

Materials and Methods

We conducted a descriptive cross-sectional study in a dermatological centre in Colombia, between January 2017 and December 2023. Variables included were age, Fitzpatrick phototyping scale, tumour location and tumour subtype. Data and statistical analysis were performed using R software (version 4.3.3) and categorical variables were expressed as absolute and relative frequencies. The clinical and histopathological variables were systematically collected and organized in Microsoft Excel.

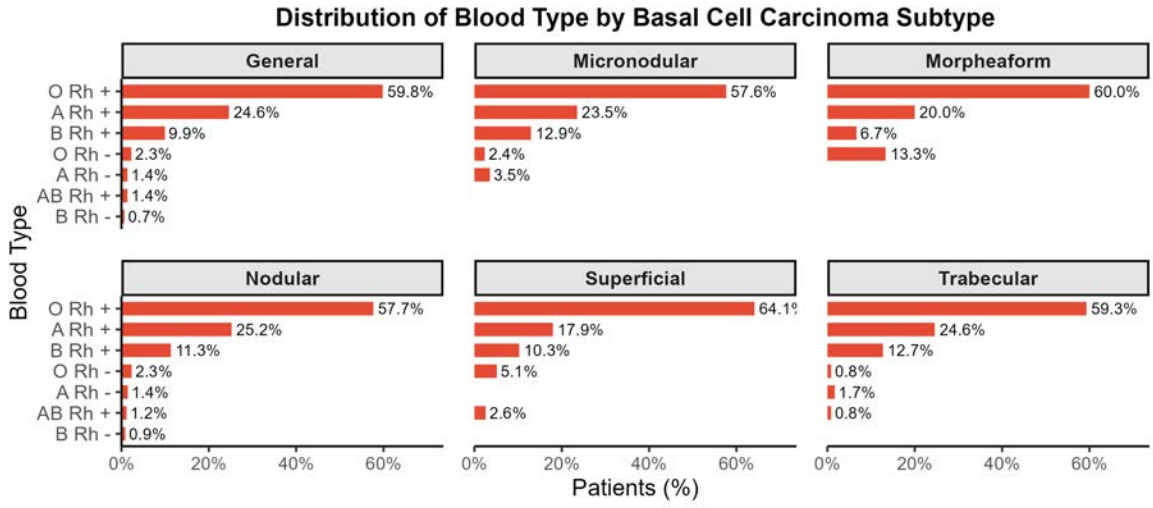

Figure 1. Distribution of blood type frequency among patients with basal cell carcinoma according to cancer subtype in a dermatology centre in Bogotá, Colombia, 2017-2023.

Results

Out of 443 patients, 58.2% were female, with an average age of 70 years and phototype III was the most prevalent with 45.8% (Table 1). Regarding tumor location, high-risk areas were the most frequent at 67.5% and the nodular

subtype of BCC was the most common, accounting for 77.9% of the histological variants analysed. Regarding blood type frequencies (Figure 1), the majority of BCC patients were Rh-positive group O (59.8%), Rh-positive group A (24.6%), Rh-positive group B (9.9%) and Rh-positive group AB (1.4%). The superficial subtype had the highest prevalence of the O Rh+ blood type (64.1%). The morpheaform subtype featured the highest proportion of O Rh- patients (13.3%) compared to the other subtypes. The micronodular subtype showed a slightly higher frequency of B Rh+ patients (12.9%) compared to the overall group (9.9%).

Table 2. Blood type according to with basal cell skin cancer risk area in a dermatology center in Colombia, 2017-2023

Blood type	Tumour location, n(%)			
	High risk area N=299	Medium risk area N=71	Low risk area N=33	Unknown N=40
O, Rh +	184 (61.5%)	35 (49.3%)	22 (66.7%)	24 (60.0%)
O, Rh -	8 (2.7%)	1 (1.4%)	1 (3.0%)	0 (0%)
A, Rh +	73 (24.4%)	21 (29.6%)	6 (18.2%)	9 (22.5%)
A, Rh -	4 (1.3%)	1 (1.4%)	1 (3.0%)	0 (0%)
B, Rh +	26 (8.7%)	11 (15.5%)	2 (6.1%)	5 (12.5%)
B, Rh -	1 (0.3%)	1 (1.4%)	0 (0%)	1 (2.5%)
AB, Rh +	3 (1.0%)	1 (1.4%)	1 (3.0%)	1 (2.5%)
AB, Rh -	0 (0%)	0 (0%)	0 (0%)	0 (0%)

Rh: rhesus factor

Conclusions

Our study identified a high frequency of BCC in elderly patients with phototype III, consistent with reports in Colombia epidemiology. Additionally, we found a higher frequency in high-risk areas and in individuals with Rh-positive group O blood type, which also represented the majority of cases across all histological subtypes. The observed distribution is consistent with the known blood type demographics of the Colombian population and these findings do suggest that the ABO/Rh system may exhibit that the non-O groups have lower risk for all the histological subtypes. However, given the descriptive design of the study and the absence of a control group, it is not possible to establish whether this is a risk factor or a protective factor. Additional analytical studies with control groups are needed to determine whether blood type acts as a predictive biomarker for susceptibility to specific BCC subtypes and tumor behavior.

Table 1. Characteristics of patients with basal cell skin cancer in a dermatology center in Colombia, 2017-2023

Variable	N= 443
Age in years, mean(SD), [Min, Max]	70.0 (13.2) [20.0, 97.0]
Sex, n(%)	
Female	258 (58.2%)
Male	185 (41.8%)
Fitzpatrick phototyping scale, n(%)	
1	4 (0.9%)
2	18 (4.1%)
3	203 (45.8%)
4	56 (12.6%)
5	2 (0.5%)
Unknown	160(36.1%)
Tumour location, n(%)	
High risk area	299(67.5%)
Medium risk area	71(16.0%)
Low risk area	33(7.4%)
Unknown	40 (9.0%)
Tumour subtype, n(%)	
Nodular	345 (77.9%)
Trabecular	118 (26.6%)
Superficial	39 (8.8%)
Morpheaform	15 (3.4%)
Micronodular	85 (19.2%)

SD: standard deviation

EADV CONGRESS
VIENNA
30 SEP - 3 OCT 2026

Abstract N°: 1654

Monthly intra-lesional Rituximab for cutaneous B-cell lymphoma

Emily Avitan-Hersh*[1, 2]

[1] Rambam Health Care Campus, Technion Israel Institute of Technology, Haifa, Israel
[2] Skin Cancer Research lab, Technion institute of Technology, Haifa, Israel, Haifa, Israel

Introduction

Primary cutaneous marginal zone lymphoma (PCMZL) and primary cutaneous follicle center lymphoma (PCFCL) are rare B-cell lymphomas. Treatment options include surgical excision, irradiation, intralesional or intravenous rituximab. Protocols for intralesional rituximab vary; the standard regimen typically involves administration three times per week during each cycle, with repeated cycles as needed. The objective of this study was to evaluate the efficacy of monthly intralesional rituximab for primary cutaneous B-cell lymphomas.

Materials and Methods

A retrospective study on on seven patients with PCMZL or PCFCL who received once monthly intralesional rituximab.

Results

We treated five females with PCFCL and two male patients with PCMZL. Four lesions were located on the face. All but one patient had failed previous treatments (irradiation/excision). Two patients experienced side effects to prior intralesional steroids, and the remaining failed.

Patients were treated with 2-4 monthly injections of intralesional rituximab, after which six patients achieved complete remission, and in one patients marked improvement was recorded. The maximum dose per cycle was 30 mg. In three patients intralesional steroids were added during the third cycle if the lesion persisted. Local recurrence adjacent to the injected area occurred in two patients, and resolved following 2–3 additional cycles. Side effects included pain, erythema, weakness and flu-like symptoms, which resolved with the use of premedication at subsequent visits.

Conclusions

Monthly intralesional rituximab is a well-tolerated and effective treatment for PCMZL or PCFCL . Co-administration of intralesional steroids is recommended for persistent lesions. Premedication is advised to minimize flu-like symptoms following injection.

EA CONGRESS
VIENNA
30 SEP - 3 OCT 2026

Abstract N°: 1654

Malignant Transformation of a Miescher Nevus: An Exceptional Case with Dermoscopic Correlation

Ceylan Avcı[1], Elif Kazaz Özmen*[1], Sevgi Akarsu[1], Yasemin Çakır[1], Banu Lebe[2]

[1] Dokuz Eylül University Hospital, İzmir, Türkiye
[2] Acıbadem Kent Hospital, izmir, Türkiye

Introduction

Miescher nevi represent a distinct subtype of intradermal nevus that predominantly occurs on the face, particularly in the malar region. Clinically, they present as dome-shaped skin-colored to light-brown nodules, often containing terminal hairs, and tend to become more prominent with age (Greco et al., 2020).

Cutaneous melanoma is the most aggressive form of skin cancer and may arise either de novo or from a pre-existing nevus. Approximately 20–30% of melanomas are nevus-associated. (Bevona et al., 2003; Cymerman et al.).

Importantly, nevus-associated melanomas most commonly arise from junctional or compound nevi, whereas melanoma developing within a purely intradermal nevus is considered exceptionally rare. Previously reported cases have predominantly described melanoma arising at the periphery of intradermal nevi, rather than originating directly within them (Ledić Drvar et al., 2023). However, rare reports have documented melanoma developing entirely within intradermal nevi without a junctional component (Benisch et al., 1980; Hashiro et al., 1998).

Herein, we present a rare case of invasive melanoma arising within a long-standing Miescher-type intradermal nevus on the right malar region of a 66-year-old woman.

Case Presentation

A 66-year-old woman presented with recent changes in a long-standing nevus on the right malar region. The lesion had been present for approximately 50 years and had remained stable until three months before admission, when progressive darkening at the inferior pole was noted. The patient denied bleeding or ulceration and reported the presence of terminal hairs since the initial appearance of the lesion.

Her medical history was significant for diabetes mellitus and hypertension, with no history of immunosuppression. There was no personal or family history of melanoma. She had not regularly used sunscreen, and her Fitzpatrick skin type was III.

Dermatological examination revealed a skin-colored nodular lesion with focal dark brown pigmentation and terminal hairs. No regional lymphadenopathy was detected. Dermoscopic evaluation demonstrated an atypical blotch in the inferior portion of the lesion, with a milky-red, structureless area, polymorphic vessels, and shiny white streaks around, raising suspicion of malignant transformation (Figure 1). The clinical differential diagnosis included intradermal melanocytic nevus and malignant melanoma.

The lesion had been excised at an external center and was subsequently re-evaluated at our institution. Histopathological examination confirmed superficial spreading melanoma with a Breslow thickness of 1.5 mm (Clark level III) and a mitotic rate of 5/mm^2, without ulceration or evidence of lymphovascular or perineural invasion (Figure 2). The melanoma arose in association with a pre-existing intradermal nevus, and surgical

margins were clear.

Sentinel lymph node biopsy following lymphoscintigraphy revealed no metastatic involvement. A subsequent wide local excision showed no residual tumour. According to the AJCC 8th edition, the patient was classified as stage IB melanoma(Gershenwald et al., 2017).

No adjuvant therapy was indicated. To rule out the metastasis of a primary melanoma from another location, the patient was screened with computed tomography, showing no evidence of any primary or metastatic melanoma.

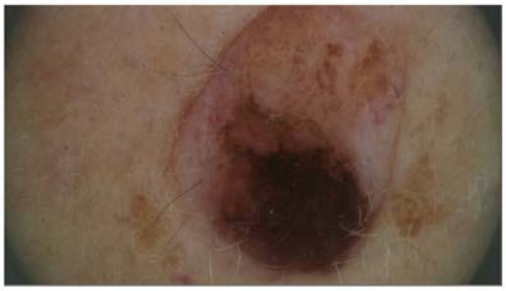

Figure 1: atypical blotch in the inferior portion of the lesion, with a milky-red, structureless area, polymorphic vessels, and shiny white streaks around

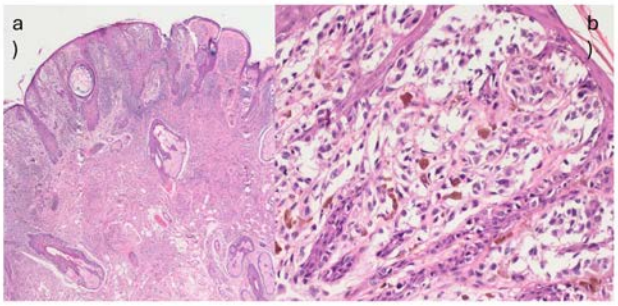

Figure 2: a) Melanoma area with an intraepidermal component at the surface, with nevoid cells observed in the deep dermis (hematoxylin-eosin, x100). b) Melanoma cells exhibiting pleomorphism andpigmentation in the epidermis and papillary dermis (hematoxylin-eosin, x400).

Conclusion

Melanoma arising within a purely intradermal (Miescher-type) nevus represents an exceptionally rare event. This case underscores that even long-standing, clinically benign-appearing intradermal nevi can undergo malignant transformation. In our patient, the recent asymmetric darkening of the lesion served as a crucial warning sign. Importantly, following careful clinical and dermoscopic assessment of lesions with recent or rapidly evolving changes, prompt biopsy should be performed in cases of suspicion and not delayed.

EA DV CONGRESS
VIENNA
30 SEP - 3 OCT 2026

Abstract N°: 1659

Treating cheilitis actinica with topical tirbanibulin improves quality of life

Roland Aschoff*[1], Nadia Günther[1], Anna Büchner[1], Frank Friedrich Gellrich[1], Stefan Beissert[1], Sarah Hobelsberger[1]

[1] Department of Dermatology, University Hospital Carl Gustav Carus, TU Dresden, Dresden, Germany

Introduction
Actinic cheilitis (AC) is a chronic inflammatory, UV-induced condition of the lips with a high risk of progression to invasive squamous cell carcinoma. In addition, the redness and crusting of the lips lead to a reduced quality of life for patients. To date, there are no approved topical treatments. This study examined the efficacy and impact on quality of life of Tirbanibulin as a topical treatment for AC.

Materials and Methods
Twenty patients with AC were treated with topical tirbanibulin once daily for five consecutive days. All patients completed the study per protocol. The follow-up included clinical visits at seven, 14 and 56 days after the beginning of the treatment.

The oral health DLQI was assessed to measure patients' subjective impairment caused by the disease and by treatment with Tirbanibulin. Eleven questions were rated on a five-point scale regarding limitations in quality of life in daily activities related to the lips, particularly during eating, speaking, and appearance, as well as anxiety caused by the skin condition, ranging from 0 (no limitation) to 4 (severe limitation).

Furthermore, study participants reported itching and burning of the lips in the study subject self-assessment (SSSA) on a scale from 0 (none) to 3 (severe).

The local skin reaction was determined by the investigator using the local skin reaction score (LSRS), which rated erythema, crusting, vesicles/pustules, erosions/ulcerations, swelling, and scaling on a scale from 0 (none) to 3 (severe).

The healing rate was determined using optical coherence tomography (OCT).

Results
Even before treatment, patients felt that their quality of life was impaired by AC. The oral health DLQI score was 6.75. In particular, patients were concerned about their lips and their appearance, and reported pain when eating hot or cold foods.

The SSSA was also elevated to 0.7 prior to treatment with Tirbanibulin, and objectively, the LSRS showed increased values with a score of 5.95.

Treatment with Tirbanibulin resulted in only a slight increase in the oral health DLQI to 7.1 after 7 days. The SSSA also increased only slightly to 0.75, and the LSRS to 7.05, indicating minimal impairment of patients by Tirbanibulin therapy. There were no severe or systemic adverse events and no treatment discontinuations.

On day 56, patients reported little to no impairment of quality of life due to AC or the adverse effects of

Tirbanibulin. The oral health DLQI decreased significantly to 2.9 (p=0.040). The SSSA and LSRS dropped to 0.4 and 2.1, respectively.

Complete healing on day 56 was demonstrated in 60% of patients upon OCT. Among the patients with partial remission, the reduction in area of AC was >75% in two patients, 50 - 75% in five patients and <50% in one patient.

Conclusions

When treating AC, the choice of therapy should take into account not only the potential progression of AC to invasive squamous cell carcinoma but also the patients' quality of life.

AC itself already impairs the quality of life of affected patients. Treatment with Tirbanibulin results in a significant improvement in quality of life with only minor, transient side effects. This treatment also results in a high healing rate.

Thus, Tirbanibulin seems to be a suitable treatment for AC with minimal impairment of quality of life.

EADV CONGRESS
VIENNA
30 SEP - 3 OCT 2026

Abstract N°: 1663

Mogamulizumab Dose Interval Extension to Every Four Weeks in Mycosis Fungoides and Sézary Syndrome: A Real-World Multicenter Experience

José Luis Alejo Fernández Baillo*[1], Carlos Calvo Asin[1], Elena Porres Lopez[1], Paula Hernández Madrid[1], Antonia Rodriguez Izquierdo[1], Concepción Postigo Llorente[1], Keila Mitsunaga[1], Pablo Luis Ortiz-Romero[1], Daniel Falkenhain Lopez[1]

[1] Hospital Universitario 12 de octubre, Madrid, Spain

Introduction

Mogamulizumab (MOGA), an anti-CCR4 monoclonal antibody, is approved for relapsed/refractory mycosis fungoides (MF) and Sézary syndrome (SS) at a standard dose of 1 mg/kg, administered weekly during the first cycle and every two weeks thereafter. In clinical practice, dose interval extension to 1 mg/kg every four weeks (4w posology) is increasingly attempted in patients achieving deep responses or experiencing difficulty tolerating the standard schedule, with the aim of improving tolerability and reducing treatment burden while maintaining disease control. However, real-world data on the feasibility, efficacy outcomes, and safety profile of this strategy remain scarce.

Materials and Methods

Retrospective, descriptive, unicentre cohort study. Patients with MF or SS receiving MOGA at a 4-week interval were identified. Demographic data, disease characteristics, prior therapies, response at the time of monthly posology initiation (MPI), progression-free survival (PFS), time to next treatment (TTNT) and adverse events—including mogamulizumab-associated rash (MAR)—were collected and analysed.

Results

Thirteen patients were included, the majority with advanced-stage disease and heavily pretreated with multiple prior systemic therapies. At the time of monthly posology initiation, most patients had already received MOGA for a prolonged period and had achieved deep responses, with high rates of complete or partial response in both skin and blood compartments. Overall response was maintained in the vast majority of patients after the interval was extended, with no significant loss of disease control observed.

Progression-free survival after the switch to the 4-week schedule was sustained over a clinically meaningful period. Most treatment discontinuations were not related to disease progression but to other causes, including response consolidation or adverse events.

MAR was the most relevant adverse event identified in this cohort, occurring in a substantial proportion of patients. Importantly, the extension of the dosing interval was used as an active strategy to improve MAR control, and most patients achieved improvement or resolution of this toxicity without requiring permanent treatment withdrawal.

Conclusions

Extending MOGA dosing to every four weeks represents a dual-purpose strategy in MF/SS: a de-escalation approach in patients with deep responses, and a clinically meaningful tool for managing MAR without requiring treatment discontinuation. In this cohort, interval extension was employed not only to reduce treatment burden in

responders, but also as an active intervention to improve MAR control in patients with difficult-to-manage cutaneous toxicity. Crucially, this strategy allowed disease response to be maintained — with a median PFS of 42 weeks after interval extension — while achieving MAR improvement in the majority of affected patients (CR or PR in over 85%), thus avoiding the need to permanently discontinue MOGA. These findings suggest that dose interval extension may offer a clinically viable alternative to treatment withdrawal in patients experiencing MAR, preserving the therapeutic benefit of MOGA. Prospective studies with larger cohorts are needed to validate these results, define optimal candidate selection criteria, and establish evidence-based guidelines for dose de-escalation in this setting.

EA DV CONGRESS
VIENNA
30 SEP - 3 OCT 2026

Abstract N°: 1665

Proliferating trichilemmal tumor of the thigh: an unusual presentation of a rare adnexal neoplasm

João Luís Fernandes*[1], Jorge Lindo[1], Teresa Lemos[1], José Carlos Cardoso[1], Joana Calvão[1]

[1] Department of Dermatology, ULS de Coimbra, Coimbra, Portugal

Introduction

Proliferating trichilemmal tumors are rare adnexal neoplasms, typically benign, originating from the outer root sheath of the hair follicle. They predominantly occur in sun-exposed, hair-bearing areas, with more than 90% of cases arising on the scalp of elderly women, and may clinically and histologically mimic other cutaneous tumors, particularly squamous cell carcinoma. Occurrence in non-scalp locations is uncommon and may pose diagnostic challenges and carry prognostic implications, as these atypical presentations have been associated with a higher risk of aggressive or malignant behavior.

Case Presentation

We report the case of a 63-year-old man with Fitzpatrick skin phototype VI who presented with a long-standing nodule on the left thigh, reportedly present since childhood, with significant enlargement over the previous five years. The lesion was asymptomatic but associated with intermittent discharge of seropurulent material upon compression. There was no history of local trauma or similar lesions elsewhere. Physical examination revealed a 3 × 3.5 cm firm, duro-elastic, skin-colored to brownish nodule located on the distal third of the anterior left thigh. The surface was slightly lobulated, with a focal 3 × 3 mm area of granulation tissue and active discharge of brownish seropurulent material. A rim of peripheral reactive hyperpigmentation was also noted. Dermoscopic examination showed a nonspecific pattern, with white fibrotic streaks on a brownish background and no distinctive vascular structures. An incisional biopsy was performed, and samples were sent for histopathological and microbiological evaluation. Histopathology revealed an intradermal cystic lesion lined by stratified squamous epithelium with abrupt trichilemmal keratinization, characterized by compact orthokeratosis without an intervening granular layer. Focal acanthosis with intraluminal papillary projections, associated fibrosis, inflammatory infiltrate, and focal calcifications were also observed. These features were consistent with a proliferating trichilemmal tumor, with no evidence of malignant transformation or significant cytological atypia. Microbiological cultures of both the exudate and tissue specimen were positive for *Pseudomonas aeruginosa*. The patient was treated with a 20-day course of levofloxacin, followed by complete surgical excision of the lesion, which confirmed the diagnosis and excluded malignant transformation throughout the entire lesion.

Conclusion

This case expands the clinicopathological spectrum of proliferating trichilemmal tumors by illustrating an uncommon extra-scalp presentation complicated by secondary infection, a combination that may obscure the clinical picture and mimic more aggressive and/or infectious entities. It highlights the diagnostic limitations of clinical and dermoscopic assessment in such contexts and reinforces the pivotal role of histopathology. Although generally benign, complete surgical excision is recommended due to the potential for local aggressiveness and to enable comprehensive pathological evaluation for definitive diagnosis, as incisional biopsy may be inconclusive. This approach further enables the exclusion of malignant transformation, a rare yet well-documented event. Recognition of atypical presentations is therefore essential to avoid misdiagnosis and to ensure appropriate management and follow-up.

EADV Congress 2026, VIENNA
30 SEPTEMBER - 03 OCTOBER 2026
POWERED BY M-ANAGE.COM

EA DV CONGRESS
VIENNA
30 SEP - 3 OCT 2026

Abstract N°: 1666

Analysis of the Clinical and Pathological Characteristics of Single-center Cutaneous Squamous Cell Carcinoma and Construction of a Prognostic Risk Model

Bingjie Li*[1], Zhaowei Chu[1], Songmei Geng[1]

[1] the Second Hospital Affiliated to Xi'an Jiaotong University, Xi'an, Shaanxi Province, China

Introduction

Cutaneous Squamous Cell Carcinoma (cSCC) is a malignant skin tumor that originates from the keratinocytes of the epidermis and is one of the more common types of malignant skin tumors. There remain certain limitations in accurately predicting the risk of postoperative recurrence and metastasis in cSCC patients. This study aims to investigate the role of clinical and histopathological features in predicting postoperative recurrence and metastasis risk by conducting an in-depth analysis of the clinical pathological characteristics and prognosis of cSCC patients from a single center, thereby providing a scientific basis for clinical treatment.

Materials and Methods

This study conducted a retrospective analysis of patients who visited our department from June 2018 to June 2024 and were diagnosed with cutaneous squamous cell carcinoma (cSCC) through histopathological examination under a microscope. The clinical and pathological data of these patients were collected, and their prognostic outcomes were followed up.

The Kaplan-Meier method was employed for univariate survival analysis of the included factors. Cox regression analysis was used to identify independent risk factors associated with postoperative prognosis. Based on the included risk factors, which encompassed patient individual differences, clinical characteristics and pathological features of the lesions. Five machine learning methods were utilized to construct postoperative recurrence/metastasis risk models for cSCC patients.

The predictive performance of the models was evaluated using receiver operating characteristic (ROC) curves and decision curves to select the optimal model. Finally, SHAP (SHapley Additive exPlanations) analysis was conducted based on the optimal model to quantify the contribution of each risk factor to the model's predictive outcomes.

Results

1. 1. 507 patients were ultimately included. Through univariate and multivariate analyses, the results showed that the clarity of the lesion margin (P=0.001), whether it is a recurrent lesion after surgery (P=0.003), presence of ulceration (P=0.002), lesion growth rate (P=0.022), whether the tumor is secondary to chronic inflammation or scar (P=0.046), and tumor differentiation degree (P=0.029) were significantly associated with the postoperative recurrence and metastasis of cutaneous squamous cell carcinoma patients from a statistical perspective.
2. 2. According to the SHAP heatmap of the constructed model, Clark level, lesion growth rate, lesion margin, presence of ulceration, tumor diameter, whether it is a recurrent lesion after surgery, and the location, are all important risk factors affecting prognosis. Among them, the Clark level of the tumor has the highest weight in the model.

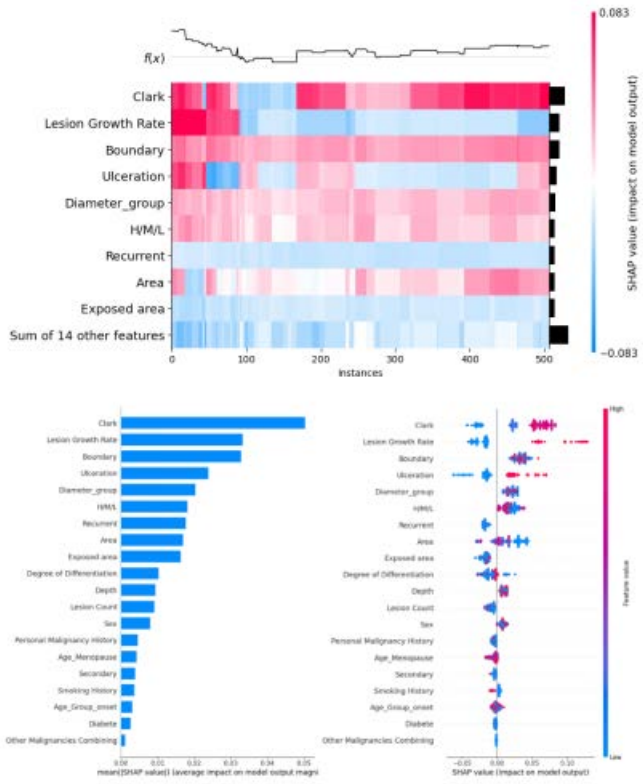

Figure. SHAP Heatmap Visualization of the RFC Model

Conclusions

The depth of tumor invasion was identified as a key factor affecting the postoperative prognosis of cSCC patients.The growth rate of the lesion, lesion boundary, ulceration, tumor diameter, whether it is a recurrent lesion, the location, and the degree of differentiation were also identified as important risk factors that significantly influence prognosis.

EA DV CONGRESS
VIENNA
30 SEP - 3 OCT 2026

Abstract N°: 1710

C-POST study of adjuvant cemiplimab for high-risk cutaneous squamous cell carcinoma: disease-free survival analyses per high-risk criteria and per start time after radiotherapy

Danny Rischin[1], Sandro Porceddu[2], Fiona Day[3], Daniel Brungs[4], Hayden Christie[5], James Jackson[6], Brian Stein[7], Annette Lim[1], Yungpo Su[8], Gerard Adams[9], Samantha Bowyer[10], Zulfiquer Otty[11], Naoya Yamazaki[12], Paolo Bossi[13], Amarnath Challapalli[14], Rahul Ladwa[15], Axel Hauschild[16], Debra McIntyre[17], Jean-Francois Pouliot*[17], Frank Seebach[17], Suk-Young Yoo[17], Priscila Goncalves[17], Matthew Fury[17]

[1] Department of Medical Oncology, Peter MacCallum Cancer Centre, Melbourne, Australia
[2] Department of Radiation Oncology, Peter MacCallum Cancer Centre, Melbourne, Australia
[3] Department of Medical Oncology, Calvary Mater Newcastle, Waratah, Australia
[4] Illawarra Cancer Care Centre, Wollongong Hospital, Wollongong, Australia
[5] Cancer Care Centre Hervey Bay, Urraween, Australia
[6] Radiation Oncology Centers, Gold Coast, Australia
[7] Adelaide Cancer Centre, Adelaide, Australia
[8] Head and Neck Medical Oncology, Nebraska Cancer Specialists, Omaha, NE, United States
[9] Radiation Oncology, Genesis Cancer Care, Bundaberg, Australia
[10] Department of Medical Oncology, Sir Charles Gairdner Hospital, Perth, Australia
[11] Townsville Cancer Centre, Townsville University Hospital, Townsville, Australia
[12] National Cancer Center Hospital, Tokyo, Japan
[13] Department of Biomedical Sciences, Humanitas University, Milan, Italy
[14] Bristol Cancer Institute, University Hospitals Bristol & Weston NHS Foundation Trust, Bristol, United Kingdom
[15] Princess Alexandra Hospital, Woolloongabba, Australia
[16] Department of Dermatology, University Hospital (UKSH), Kiel, Germany
[17] Regeneron Pharmaceuticals, Inc., Tarrytown, NY, United States

Introduction

C-POST, a phase 3 trial (NCT03969004) in patients with high-risk cutaneous squamous cell carcinoma (CSCC) after surgery and radiotherapy (RT), demonstrated superior disease-free survival (DFS) for adjuvant cemiplimab (cemi) vs placebo (pbo) (HR, 0.32; *P*<0.0001); treatment discontinuation due to adverse events occurred in 9.8% vs 1.5% of patients (Rischin, et al. *N Engl J Med.* 2025). With approximately 6 months of additional follow-up, we present exploratory analyses of DFS per high-risk criteria and per the interval between completion of adjuvant RT and study randomisation (2-6 wk vs >6 wk). These additional analyses provide key data to understand the importance of risk factors and the impact of time post RT.

Materials and Methods

Patients were randomised 1:1 (N=415) to adjuvant cemi or pbo (350 mg cemi or pbo Q3W for 12 wk, then 700 mg cemi or pbo Q6W for 36 wk). All patients had nodal high-risk disease (with extracapsular extension [ECE] and ≥1 node ≥20 mm or ≥3 nodes regardless of ECE) and/or non-nodal high-risk disease (in-transit metastases, perineural invasion, T4 lesions or recurrent CSCC with ≥1 other feature). Tumours could meet ≥1 high-risk criteria. Randomisation occurred within 2-11 wk after completion of RT. Data cutoff was April 7, 2025.

Results

Among 415 patients (209/206 cemi/pbo) randomised, the DFS HR was 0.35 (95% CI, 0.23-0.55) at a median follow-up of 30 months. The most common high-risk criterion was nodal ECE, present in 48.4% of patients (201/415). DFS was improved with cemi vs pbo across all high-risk features, including both nodal and non-nodal criteria (**Table 1**). A consistent benefit was observed regardless of whether the interval between adjuvant RT completion and study randomisation was 2-6 wk (DFS events, 17/117 [14.5%] vs 37/112 [33.0%]; HR, 0.39; 95% CI, 0.22-0.70) or >6 wk (DFS events, 12/91 [13.2%] vs 31/93 [33.3%]; HR, 0.36; 95% CI, 0.19-0.71).

Conclusions

In this phase 3 study, adjuvant cemi demonstrated a DFS benefit vs pbo across all high-risk features and regardless of the interval between adjuvant RT completion and randomisation.

Table 1. DFS with cemi vs pbo: analyses per high-risk criteria

Criteria[a]	Met high risk criteria, n/N (%)	DFS events in cemi arm, n/N (%)	DFS events in pbo arm, n/N (%)	DFS HR (95% CI)
Nodal high risk				
ECE with ≥1 node ≥20 mm	201/415 (48.4)	14/105 (13.3)	27/96 (28.1)	0.44 (0.23-0.84)
≥3 nodes	71/415 (17.1)	7/34 (20.6)	18/37 (48.6)	0.34 (0.13-0.92)
Non-nodal high risk				
In-transit metastases	41/415 (9.9)	2/20 (10.0)	9/21 (42.9)	0.07 (0.01-0.58)
T4 lesion	33/415 (8.0)	6/17 (35.3)	5/16 (31.3)	0.58 (0.16-2.11)
Perineural invasion	64/415 (15.4)	3/32 (9.4)	8/32 (25.0)	0.27 (0.07-1.04)
Recurrent CSCC with ≥1 additional high-risk criteria	105/415 (25.3)	9/55 (16.4)	22/50 (44.0)	0.19 (0.08-0.45)

[a]Tumours could meet ≥1 high-risk criteria.

EA DV CONGRESS
VIENNA
30 SEP - 3 OCT 2026

Abstract N°: 1717

Cutaneous chemical carcinogenesis: Multicentric Mycosis fungoides type D'emblee after henna dye

Simona Kordeva*[1], Konstantin Tchernev Jr[2], Georgi Tchernev[1, 2]

[1] Medical Institute of Ministry of Interior - Department of Dermatology and Venereology, Sofia, Bulgaria
[2] Onkoderma- Clinic for Dermatology, Venereology and Dermatologic Surgery, Sofia, Bulgaria

Introduction
Mycosis fungoides is a cutaneous T-cell lymphoma, arising from peripheral epidermotropic T-cells that express a CD4+ immunophenotype, with a high CD4/CD8 ratio. Initially manifesting as patches, the condition progresses into infiltrated plaques and can eventually lead to tumor formations. Double positive immunophenotypes, although rare, could be considered as potential predictors for better survival rates.

Materials and Methods
Environmental exposure to radiation and chemicals, along with other risk factors, may be potentially linked to the development of Mycosis fungoides.

Henna dye is currently used as a "natural" hair dye and serves as an alternative to conventional hair dyes for many consumers. The number of health concerns, along with the desire for a "chemical-free" lifestyle, compels consumers to seek more "natural" alternatives like henna dye over traditional chemical-based hair dye options. However, since it is not strongly regulated or regulated at all, we cannot be sure what ingredients or impurities are present in these mass-produced products.

Results
We present a 74-year-old female with potentially henna-induced Multicentric Mycosis Fungoides type tumor d'emblee, staged T3N0M0B1 lA (Figure a-d). Immunohistochemistry and flow cytometry revealed a double positive immunophenotype CD4+/CD8+. Throughout her routine follow-ups, two biopsies were conducted to confirm the diagnosis, with several changes of the therapeutic regimen, all resulting in disease progression. On her latest follow-up, we recommended initiating therapy with methotrexate.



Figure a-d: Well-defined erythematous-squamous plaques, measuring 4-5 cm in diameter, located on

trunk, upper and lower limbs, capillitium, and face areas (a-d). Additionally, tumor formations with smooth surfaces are observed in the head and chin regions (c,d). Multiple yellowish-brownish crusts were also noted on the capillitium (c).

Conclusions

The presentation will primarily focus on emerging and new hypotheses in the dermatological field, including: 1) the significance of double immunophenotypes as prognostic indicators, and 2) the potential chemical contamination of henna with different carcinogens / mutagens and its subsequent role in MF development and progression.

EADV CONGRESS
VIENNA
30 SEP - 3 OCT 2026

Abstract N°: 1732

Cutaneous lymphangitic carcinomatosis: the initial clinical manifestation of metastatic lung adenocarcinoma

Lei Alcazaren*[1]

[1] James Paget Hospital, Norfolk, United Kingdom

Introduction

Cutaneous lymphangitic carcinomatosis is a rare manifestation of cutaneous metastasis, accounting for 5% of cases and is characterised by tumour embolisation within dermal lymphatic vessels. It may be the initial clinical sign of an occult malignancy and is a marker of advanced disease associated with poor prognosis. It can present as erythematous mimicking inflammatory conditions, or violaceous plaques and can be mistaken for vascular malignancies.

Case Presentation

We report a case of a 77-year-old female presenting to the GP with a 4-week history of an indurated, violaceous skin lesion progressively spreading across her left supraclavicular region. She was referred to dermatology for further assessment.

She had a 60-pack year history with multiple comorbidities. 3 months prior to her presentation to the GP for the skin lesion, she sustained a low impact right humeral fracture and developed right upper limb deep vein thrombosis.

Initial dermatology examination suggested angiosarcoma. A skin biopsy was performed which showed tumour emboli within the dermal lymphatics, in keeping with cutaneous lymphangitic carcinomatosis. Immunohistochemistry showed the tumour cells were positive for cytokeratin, CK7, and TTF1.

Whole body CT scan revealed a nodular lesion in the left supraclavicular region, suspicious for cutaneous malignancy. It also showed widespread lymph node metastasis with diffuse septal thickening in the lungs which raised suspicion for metastatic disease, but no primary mass was detected.

Despite immunohistochemical findings, the absence of a primary tumour on imaging was consistent with an occult malignancy and she was diagnosed with cancer of unknown primary after initial workup.

Given her comorbidities and frailty, the patient was referred to the palliative team for supportive care and pain management for the skin lesion.

A repeat CT scan was performed 3 months later during a hospital admission and showed progressive thoracic involvement. Coupled with the immunohistochemistry, it was in keeping with metastatic lung adenocarcinoma.

She passed away 5 months after her initial presentation for her skin lesion.

Conclusion

Cutaneous lymphangitic carcinomatosis is a rare form of cutaneous metastasis and is a marker of advanced disease associated with poor prognosis.

Despite its malignant nature, it can be misdiagnosed for other inflammatory conditions resulting in inappropriate treatment and delays in investigations. It may also resemble vascular malignancies such as angiosarcoma, yet its appearance masks its true metastatic nature. It represents a diagnostic pitfall owing to its deceptive presentation and can result in delayed recognition of metastatic disease.

A low threshold for malignancy should be considered for patients presenting with a new skin lesion with significant risk factors. This patient had a significant smoking history and previous fragility fracture, increasing suspicion for malignancy which prompted skin biopsy and whole-body imaging.

This skin manifestation may suggest recurrence, but it may also precede the diagnosis of a primary cancer, as seen in this case. Cutaneous lesions may be the first manifestation of an occult malignancy, highlighting the pivotal role of early dermatological assessment and skin biopsy. Skin biopsy is a minimally invasive procedure yet has a high diagnostic yield. Both histological examination and immunohistochemistry can confirm metastatic disease, as well as suggest a primary site.

Timely recognition of cutaneous lymphangitic carcinomatosis allows early involvement of palliative care, shifting the focus to improving quality of life through proactive pain control and psychological support.

EADV CONGRESS
VIENNA
30 SEP - 3 OCT 2026

Abstract N°: 1739

Thymoma-Associated Multiorgan Autoimmunity: when immune surveillance fails

João Luís Fernandes*[1], Jorge Lindo[1], Teresa Lemos[1], Maria Manuel Xavier[1], José Carlos Cardoso[1], João Teixeira[1]

[1] Department of Dermatology, ULS de Coimbra, Coimbra, Portugal

Introduction

The thymus is responsible for T-cell maturation and the elimination of autoreactive cells. In thymomas, this function is impaired, allowing the survival of autoreactive T lymphocytes. Thymoma-associated multiorgan autoimmunity (TAMA), a term proposed in 2007 by Wadhera et al., describes a paraneoplastic condition in the context of thymoma that presents with cutaneous, intestinal, and/or hepatic manifestations, sharing clinical and histological features with graft-versus-host disease. Cutaneous manifestations are among the most frequent presentations and may precede or parallel systemic involvement, often posing a significant diagnostic challenge.

Case Presentation

We report a 55-year-old man with a history of metastatic thymoma who presented to the emergency department with a one-month history of generalized pruritic dermatosis. On physical examination, he exhibited erythroderma (BSA 90%) characterized by confluent erythema with diffuse ichthyosiform scaling, more pronounced on the trunk and face. In acral regions, a lichenoid papular component was evident. Two incisional biopsies were performed and daily topical treatment with 2% salicylic petrolatum plus betamethasone valerate 1 mg/g ointment was initiated. Ten days later, there was partial improvement of the ichthyosiform component on the trunk and lower limbs, but progressive worsening of scaling on the face and upper limbs, eventually involving the entire skin surface. Histopathological examination revealed confluent parakeratosis, moderate acanthosis, extensive epidermal infiltration by cytotoxic CD8+ T lymphocytes, and numerous apoptotic keratinocytes, consistent with thymoma-associated multisystem autoimmunity. Given the unfavorable evolution, acitretin 10 mg/day was added to the previously instituted therapy. After two weeks, the patient was readmitted to the emergency department with multiorgan failure and subsequently died.

Conclusion

This case highlights the importance of considering TAMA, a rare entity with only a limited number of cases reported in the literature, in the differential diagnosis of erythroderma in patients with a history of thymoma. Its clinical heterogeneity and overlap with graft-versus-host disease–like features may hinder prompt recognition. Early diagnosis and the institution of multidisciplinary, individualized therapy may help reduce associated morbidity and improve quality of life, despite the poor overall prognosis.

EA DV CONGRESS
VIENNA
30 SEP - 3 OCT 2026

Abstract N°: 1743

Association between glucagon-like peptide-1 receptor agonists and development of cutaneous malignancies in diabetics mellitus

Akshay Pulavarty[1], Robert Adler*[2], Michael Kozlov[2], Jessica Feig[2], Nayoung Lee[1], Maressa Criscito[1], John Carucci[1], Mary Stevenson[1]

[1] The Ronald O. Perelman Department of Dermatology, New York University Grossman School of Medicine,, New York, United States
[2] SUNY Downstate College of Medicine, Brooklyn, United States

Introduction

Glucagon-like peptide-1 receptor agonists (GLP-1RAs) are increasingly prescribed for type 2 diabetes and obesity. While emerging evidence suggests GLP-1RAs may influence cancer risk, their association with skin cancers remains unclear.[1] Studies show mixed findings–some suggest protection against basal cell carcinoma (BCC), while others report no association with skin cancers.[1,2] Given rising GLP-1RA use and the burden of cutaneous malignancies, clarifying this relationship has important clinical implications. Using the TriNetX database, a global federated health research network with data from 115 healthcare organizations, we conducted a retrospective cohort study to evaluate the association between GLP-1RA exposure and development of BCC, cutaneous squamous cell carcinoma (cSCC), and melanoma in a population of insulin-dependent diabetics.

Materials and Methods

Adult patients with type 2 diabetes on combination GLP-1RA and long-acting insulin (GLP+INS) were matched against patients on only insulin (INS) via strict propensity-score matching for demographics, comorbidities, and medications. Outcomes included 3-year relative risk (RR) of developing BCC, cSCC, and melanoma, with corresponding Cox proportional hazard models to estimate hazard ratios (HRs) and 95% confidence intervals via log-rank testing.

Results

After propensity-score matching, the GLP+INS and INS groups included 288,702 patients each. All covariates had standard differences <0.10, confirming balanced cohorts. Mean follow-up was comparable: 813.7 ± 356.3 days (GLP+INS) versus 784.1 ± 395.8 days (INS). Among matched cohorts including ~280,000 patients, 1,818 versus 1,766 patients developed BCC in GLP+INS versus INS groups (3-year risk 0.006 both groups). For cSCC, 1,306 (GLP+INS) versus 1,505 (INS) patients were affected (3-year risk 0.005 both groups). Melanoma developed in 666 (GLP+INS) versus 588 (INS) patients (3-year risk 0.002 both groups). Kaplan-Meier hazard ratios (HRs) for BCC, cSCC, and melanoma were HR 0.93 (95% CI 0.93-1.06, log-rank p=0.843), 0.84 (0.78-0.90, p<0.001), and 1.09 (0.98-1.22, p=0.123), respectively.

Conclusions

Overall, we demonstrate via a robust, controlled analysis of insulin-dependent diabetics that the additional use of GLP-1RA does not increase the risk of developing cutaneous malignancies. This is consistent with prior studies that demonstrated no increased risk of GLP-1RA on melanoma and NMSC risk when compared to sulfonylureas and a possible benefit to BCC risk.[1,3] A prior TriNetX study similarly demonstrated a protective effect of GLP-1RA against melanoma in obese patients.[4] Interestingly, we demonstrate that the risk of cSCC is lower in the GLP+INS group suggesting a slight protective role of GLP-1RA, a finding not yet established in the literature and of unclear clinical significance. The mechanistic role by which GLP-1RA reduces skin cancer risk is unclear but may be related to modulation of systemic inflammatory mediators (independent of glycemic control and weight loss), similar to its emerging benefits in managing inflammatory skin diseases.[5] Limitations to this analysis include use of ICD-10 billing and medication codes, limited outcome windows (3-year), and generalizability of a insulin-dependent diabetic cohort.

In sum, we show that GLP-1RA is not associated with increased 3-year risk of melanoma or NMSC in insulin-dependent diabetics, with a possible protective benefit on cSCC.

EA DV CONGRESS
VIENNA
30 SEP - 3 OCT 2026

Abstract N°: 1780

Subungual metastasis of testicular choriocarcinoma

María Fernanda Cruz Quiñones*[1], Mariana De La Vega[2], Karla Delgado Moreno[3], Lucía Berlanga Delgado[4], Wendoline Almeida Vega[5], Ma. Teresa Vega Gonzalez[6]

[1] General Practitioner, Mexico City, Mexico
[2] Dermatology, Mexico City, Mexico
[3] Dermatology, Leon, Guanajuato, Mexico
[4] Dermatology, Monterrey, Mexico
[5] Dermatology, Los Mochis, Sinaloa, Mexico
[6] Department of Dermatology, Instituto Nacional de Cancerología, Mexico city, Mexico

Introduction

Testicular choriocarcinoma is a non-seminomatous germ cell tumor that typically arises from germ cells. These tumors are usually highly vascularized, which may explain the presence of hemorrhagic lesions at metastatic sites.

Cutaneous metastases result from the infiltration of skin by proliferating cells originating from a distant malignant tumor. In testicular cancer, cutaneous metastases are rare and are associated with a poor prognosis, with mortality reaching up to 70%.

Case Presentation

A 30-year-old male, with a history of maternal aunt diagnosed with breast cancer (alive) and a maternal uncle deceased due to pancreatic cancer, was diagnosed with a non-seminomatous germ cell testicular tumor with metastases to the lungs and cervical lymph nodes since June 2024, clinical stage (TxN3M1aS3) IIIC.
The patient was underwent treatment with Etoposide and Cisplatin. After the first chemotherapy cycle, he developed a subungual neoformation on the fourth finger of the right hand, which grew rapidly over a period of 4 months.

Physical examination revealed a dermatosis localized to the subungual region of the right fourth finger, presenting as an exophytic lesion measuring 2.0 × 1.0 × 0.5 cm. The lesion caused nail plate deformation and exhibited a bluish-black to violaceous hue, irregular borders, and an anfractuous surface partially covered with crusts and hemorrhagic remnants. The texture was friable. Dermoscopy revealed areas of ulceration and hemorrhagic crusts. Additionally, first and third nail plates of the right hand had a bluish-black to violet coloration.

An incisional biopsy of the neoformation was performed. Histopathology revealed: syncytiotrophoblastic cells with cellular pleomorphism. Immunohistochemistry yielded the following results: hCG positive, SALL4 positive, PLAP negative, CD31 negative, Actin negative. Based on these findings, the diagnosis of metastasis from testicular choriocarcinoma was made.

Surgical treatment with distal phalanx amputation was indicated; however, the patient experienced complications due to disease progression in the lungs and was referred to palliative care for pain management

Conclusion

In the presented case, we observed an atypical presentation of testicular choriocarcinoma metastasis, both in location and morphology, as there are no previously reported cases of ungual involvement. Choriocarcinoma metastases are uncommon and may represent a significant diagnostic challenge.

In oncology patients, any lesion including those located periungually or subungually should raise suspicion of tumor metastasis, warranting an appropriate diagnostic approach.

EADV CONGRESS
VIENNA
30 SEP - 3 OCT 2026

Abstract N°: 1795

Acral Lentiginous Amelanotic Melanoma with Chondroid Differentiation: Clinical and Histopathological Features of a Case Mimicking Clear Cell Sarcoma

Ilhame Jegoual*[1], Layla Bendaoud[1], Mariem Aboudourib[1], Ouafa Hocar[1], Said Amal[1]

[1] Dermatology Department, Arrazi Hospital, Mohammed VI University Hospital, Biosciences Research Laboratory, FMPM, Cadi Ayyad University, Marrakesh, Morocco

Introduction

Melanoma with chondroid differentiation is a rare histological variant that may simulate mesenchymal tumors, particularly clear cell sarcoma, with which it shares morphological and immunohistochemical similarities. The distinction between these entities relies on a combined analysis of histological, immunohistochemical, and molecular features, representing a significant diagnostic challenge.

Case Presentation

We report the case of a 56-year-old patient with a history of a puncture injury caused by a manipulated plant thorn, complicated by the progressive development of a proliferative ulcer evolving over 6 months.

Clinical examination revealed a rounded, proliferative ulcer located on the left heel, with a fibrinous base and well-defined hyperkeratotic borders, measuring 6 cm in its diameter. The lesion was painless, non-bleeding on palpation, with peripheral hypoesthesia and no palpable lymphadenopathy.

Dermoscopy showed irregular linear vessels, a few hairpin vessels, structureless whitish areas, hemorrhagic crusts, red globules, and oval nests.

Two biopsies demonstrated a widely ulcerated malignant tumor composed of spindle and epithelioid cells with areas of osteochondroid differentiation. Tumor cells expressed S100, SOX10, and SOX9, with no expression of Melan-A or HMB45, raising the differential diagnosis of melanoma versus sarcoma. BRAF mutation analysis was negative.

Staging investigations, including brain and thoraco-abdomino-pelvic CT scans, revealed no evidence of metastatic disease. Ankle CT showed a locally infiltrative tumor without bone involvement. PET scan demonstrated a hypermetabolic lesion in the left heel without other hypermetabolic areas.

Wide surgical excision with 2 cm margins was performed. Histopathological and immunohistochemical examination of the surgical specimen supported a melanocytic proliferation with focal chondroid differentiation and calcifications, with a Breslow thickness of 9 mm.

Conclusion

Our case highlights the clinical and histological diagnostic overlap between these two entities and underscores the importance of molecular biology in establishing an accurate diagnosis, which is essential for appropriate management.

EADV CONGRESS
VIENNA
30 SEP - 3 OCT 2026

Abstract N°: 1810

Blastic plasmacytoid dendritic dell neoplasm: A multicenter case series

María Nazaret Olmos García*[1], Noelia Izquierdo Herce[1], Adriana Marcela Quintero Duarte[2], Andrés Palacios Abufón[3], Elisabeth Vanrell Büse[1], Antoni Nadal Nadal[4], Verónica Fernández Tapia[4], Daniela Mendizábal Cajal[4], Daniel Vírseda González[3], Carles Saus Sarrias[1], Fernando Terrasa Sagristá[4], Juan Gabriel Garcías Ladaria[1]

[1] Hospital Universitario Son Espases, Palma de Mallorca, Spain

[2] Hospital Universitario Son Espases, Palma, Spain

[3] Hospital Can Misses, Ibiza, Spain

[4] Hospital Universitario Son Llàtzer, Palma de Mallorca, Spain

Introduction

Blastic plasmacytoid dendritic cell neoplasm (BPDCN) is a rare and aggressive hematologic malignancy, frequently involving the skin as the initial manifestation and commonly progressing to systemic disease. Its estimated incidence is 0.04 cases per 100,000 inhabitants, and prognosis remains poor, particularly in elderly patients.

Materials and Methods

A retrospective search was conducted to identify patients diagnosed with BPDCN across multiple hospitals in a spanish region. Clinical records were reviewed to collect data on epidemiological characteristics, clinical presentation, laboratory findings, histopathology and immunophenotype, systemic involvement, treatment strategies, and outcomes.

Results

Six patients were identified from 2021 to the present. The mean age at diagnosis was 79.1 years (range 70–85). Cutaneous involvement was the initial manifestation in all cases, most frequently presenting as disseminated erythematous or violaceous papules, nodules, or plaques. The trunk and scalp were the most commonly affected sites, while lower limb involvement was uncommon. Pruritus, asthenia, fever, and constitutional symptoms were frequent.

Laboratory abnormalities mainly consisted of cytopenias, including anemia, leukopenia or leukocytosis, and thrombocytopenia. Bone marrow involvement was detected in most patients, and central nervous system involvement was also documented in 2 patients. Histopathological examination showed dense dermal infiltrates sparing the epidermis, with a Grenz zone. Immunophenotyping consistently demonstrated expression of CD4, CD56, and CD123, with negativity for B-, T-, and myeloid-lineage markers.

Treatment strategies were heterogeneous and largely determined by patient fitness, comorbidities, and drug availability, including tagraxofusp, hypomethylating agents combined with venetoclax, conventional chemotherapy, radiotherapy, and palliative care. Median overall survival was 5 months.

Conclusions

Compared with previously published data, this series is characterized by a markedly older patient population, a higher frequency of disseminated cutaneous disease, and predominant involvement of the trunk and scalp, with less frequent lower limb involvement. Bone marrow infiltration was more common, while rates of central nervous system involvement were similar. Overall survival was poor, likely reflecting advanced age, frailty, and limited therapeutic options. These findings highlight the importance of recognizing BPDCN in elderly patients with widespread cutaneous lesions and emphasize the role of early dermatologic diagnosis and multidisciplinary management.

EADV CONGRESS
VIENNA
30 SEP - 3 OCT 2026

Abstract N°: 1811

Primary cutaneous lymphomas: clinical patterns, diagnostic pitfalls, and outcomes across the disease spectrum

Joana Calvão*[1, 2], Maria Lourenço[2], Francisco Martins[1], Ines Sampaio Dantas Coutinho[1, 2], Emmanuella Guenova[3, 4], Margarida Gonçalo[1, 2]

[1] Dermatology Department, Coimbra University Hospital, Coimbra Local Health Unit, Coimbra, Portugal

[2] Faculty of Medicine, University of Coimbra, Coimbra, Portugal

[3] Department of Translational Immunodermatology, Kepler University Hospital, Johannes Kepler University, Linz, Austria

[4] Clinical Research Institute for Inflammation Medicine, Johannes Kepler University, Linz, Austria

Introduction

Primary cutaneous lymphomas (PCL) are a rare and heterogeneous group of extranodal lymphomas with widely variable clinical presentation, diagnostic complexity, and outcomes. Real-world data addressing the full spectrum of PCL, particularly diagnostic burden and factors associated with diagnostic delay, remain limited. In this study, we aimed to characterize the epidemiologic distribution, clinical phenotype, diagnostic burden, treatment patterns, and outcomes of primary cutaneous T-cell and B-cell lymphomas.

Materials and Methods

We performed a retrospective study of patients with PCL diagnosed at a tertiary referral centre between 2010 and 2025. Cases were identified through the dermatopathology database and included if a diagnosis of primary cutaneous T-cell or B-cell lymphoma was established by integrated clinicopathologic correlation, with multidisciplinary review in uncertain cases. Patients with secondary cutaneous lymphomas, inconclusive diagnoses, or insufficient clinicopathologic data were excluded. Demographic, clinicopathologic, diagnostic, treatment, and outcome data were collected, including lesion morphology, local and systemic symptoms, time to diagnosis, number of biopsies needed for diagnosis, first-line treatment, progression, extracutaneous dissemination, and disease-specific death. Exploratory univariable and multivariable analyses were performed to identify factors associated with diagnostic delay and adverse outcome.

Results

The study included 265 patients, of whom 206 (77.7%) had cutaneous T-cell lymphomas and 59 (22.3%) cutaneous B-cell lymphomas; mycosis fungoides (MF) was the most frequent subtype (54.3%). Diagnostic burden varied substantially across subtypes, with longer diagnostic intervals and/or a more frequent need for multiple biopsies in MF, Sézary syndrome and primary cutaneous marginal zone lymphoma, whereas diffuse large B-cell lymphoma, leg type, showed the shortest time to diagnosis. Diagnostic delay was longer in cutaneous T-cell than in cutaneous B-cell lymphomas (median 18.6 vs 11.7 months, $p=0.003$). In exploratory analyses, nodular lesions were associated with shorter time to diagnosis than non-nodular presentations (5.9 vs 23.4 months, $p<0.001$), whereas an initial inflammatory rather than neoplastic differential diagnosis was associated with longer delay (29.3 vs 11.2 months, $p<0.001$); psoriasis was the differential diagnosis most strongly associated with prolonged delay. In multivariable analysis, psoriasis in the differential diagnosis and nodular morphology remained independently associated with longer and shorter time to diagnosis, respectively. Treatment patterns and outcomes broadly reflected biologic behaviour across subtypes. Time to diagnosis was not associated with adverse outcome,

whereas systemic involvement was the only independent prognostic factor.

Conclusions

This real-world cohort provides a broad characterization of the full spectrum of PCL and highlights substantial variation in diagnostic burden across subtypes. Diagnostic delay was strongly influenced by lesion morphology and the initial differential diagnosis considered by the clinician. These findings refine current understanding of diagnostic burden in PCL and support multidisciplinary approaches to improve recognition and diagnostic pathways across these challenging entities.

EA DV CONGRESS
VIENNA
30 SEP - 3 OCT 2026

Abstract N°: 1813

CemiplimAb-rwlc Survivorship and Epidemiology (CASE): A prospective, non-interventional study of the safety and effectiveness of cemiplimab in immunocompromised/immunosuppressed patients with advanced cutaneous squamous cell carcinoma at 2 years' follow-up

Soo Park[1], Guilherme Rabinowits[2], Michael Kelley[3], Emily S Ruiz[4], Francis Worden[5], Debra McIntyre[6], Ruben Quek[6], Joy Wang[6], Sarah Nia*[6], Jean-Francois Pouliot[6]

[1] University of California San Diego, La Jolla, CA, United States
[2] Miami Cancer Institute/Baptist Health South Florida, Miami, FL, United States
[3] Durham VA Medical Center and Duke University School of Medicine, Durham, NC, United States
[4] Brigham and Women's Hospital, Boston, MA, United States
[5] University of Michigan, Ann Arbor, MI, United States
[6] Regeneron Pharmaceuticals, Inc., Tarrytown, NY, United States

Introduction
Cemiplimab is a programmed cell death-1 (PD-1) inhibitor approved in patients with locally advanced or metastatic cutaneous squamous cell carcinoma (CSCC) who are not candidates for curative surgery or radiation. Cemiplimab is also approved for the adjuvant treatment of adult patients with CSCC at high risk of recurrence after surgery and radiation. Despite high prevalence of CSCC, immunocompromised or immunosuppressed (IC/IS) patients have been excluded from registration studies due to potentially reduced treatment efficacy. Here, we present the safety and effectiveness of cemiplimab in IC/IS patients with advanced CSCC from a non-interventional study in the real-world setting, at 2 years' follow-up.

Materials and Methods
CASE is a phase 4, multicentre, prospective, non-interventional study evaluating the effectiveness and safety of cemiplimab in patients with advanced CSCC (NCT03836105). Data were collected from 65 United States academic and community oncology centres.

Results
As of 24 March 2025, 254 patients with advanced CSCC had received ≥1 dose of intravenous cemiplimab 350 mg every 3 weeks. Of these, 42 (16.5%) patients were IC/IS. Most IC/IS patients were white (90.5%), male (76.2%), ≥65 years of age (88.1%), and had locally advanced disease (57.1%). The IC/IS patients were divided into 3 categories: with haematologic malignancies (45% - chronic lymphocytic leukaemia, myeloproliferative disorders or other leukaemia), immunosuppressed (33% - immune disorders or human immunodeficiency virus infection) and organ transplant recipients (21% - kidney, liver or pancreas). Median duration of exposure was 43.9 weeks. Objective response rate was achieved in 45.2% of patients, with 23.8% having a complete response. Median progression-free survival was similar in IC/IS vs non-IC/IS patients, at 14.6 and 15.7 months, respectively. Treatment-related immune-related adverse events occurred in 31.0% of patients and treatment-related serious adverse events occurred in 7.1% of patients. The proportion of IC/IS patients experiencing adverse events was similar to that of the non-IC/IS population. Among the 9 transplant patients, 7 had stable transplant status and 2 had rejection episodes leading to treatment-related allograft loss.

Conclusions

This analysis suggests that the safety and efficacy of cemiplimab in IC/IS patients with advanced CSCC are similar to those observed in non-IC/IS patients in this real-world study.

EADV CONGRESS
VIENNA
30 SEP - 3 OCT 2026

Abstract N°: 1816

Synchronous Primary Cutaneous Follicle Center Lymphoma and Lung Adenocarcinoma with Dual Response to Chemotherapy

Valentina Celeste Pini Gueli*[1], Denise Chavit Emerson[1], Pedro Barbosa[1], Berenice Fouces[1], Corina Busso[1]

[1] Hospital Universitario Austral, Pilar, Buenos Aires, Argentina

Introduction

Primary cutaneous follicle center B-cell lymphoma (PCFCL) is the most frequent subtype of primary cutaneous B-cell lymphoma, accounting for approximately 60% of cases and about 12% of all primary cutaneous lymphomas. It typically occurs between the fifth and sixth decades of life and shows a slight male predominance. Although the prognosis is generally favorable with a 5-year survival rate approaching 95%, recurrence occurs in 30 to 50% of the cases.

First-line treatment options include local radiotherapy, surgical excision, and systemic rituximab. In selected cases, systemic chemotherapy or a watch-and-wait strategy may be considered. Second-line therapies include intralesional treatments such as rituximab, corticosteroids, or interferon alfa, whereas regimens such as R-CHOP or CHOP are generally reserved for refractory or multifocal disease.

We report the case of synchronous malignancies in which a primary cutaneous B-cell lymphoma achieved complete response following carboplatin and paclitaxel chemotherapy administered for an incidentally diagnosed lung adenocarcinoma.

Case Presentation

A 73-year-old male patient with a history of atrial fibrillation, hypertension, dyslipidemia, asthma, and chronic obstructive pulmonary disease presented with a 2-year history of a cutaneous lesion. Physical examination revealed an erythematous, tender, infiltrated plaque with a pseudovesicular surface located on the right lower lateral thoracic region.

The patient had a prior biopsy, reported as primary cutaneous follicle center B-cell lymphoma. He was referred to the Hematology Department for staging and evaluation of systemic involvement. Bone marrow aspiration and biopsy showed no evidence of neoplastic infiltration.

As part of the staging workup, imaging studies including PET scan demonstrated hypermetabolic dermal thickening in the right thoracic wall measuring approximately 10 mm, as well as increased metabolic activity in a spiculated solid pulmonary nodule in the left apical region, with associated hypermetabolic lymphadenopathy involving the left hilum, mediastinum, and supraclavicular regions.

Biopsy of the pulmonary lesion confirmed lung adenocarcinoma, staged as IIIC, with no targetable alterations on next-generation sequencing and negative programmed death-ligand 1 expression. Based on these findings, combined chemotherapy with carboplatin and paclitaxel for the lung cancer and radiotherapy for the PCFCL were planned, however radiotherapy was not performed because of limited access.

After 11 cycles of chemotherapy, a follow-up PET imaging demonstrated persistence of the hypermetabolic pulmonary nodule in the apical segment of the left upper lobe, without significant interval change. In contrast, regressive anatomo-metabolic changes were observed in the previously identified cervicothoracic

lymphadenopathy, consistent with treatment response. Marked reduction in both thickness and metabolic activity of dermal lesion in the right thoracic wall was also observed.

On physical examination, a notable regression of the cutaneous lymphoma was documented. Collectively, these findings were consistent with a partial remission of the lung adenocarcinoma and a complete response of the cutaneous involvement to chemotherapy.

Conclusion

This case illustrates a rare presentation of synchronous malignancies and highlights an unexpected complete response of primary cutaneous follicle center lymphoma to systemic chemotherapy administered for lung adenocarcinoma. This observation suggests that systemic treatment directed at a synchronous solid tumour may also induce regression of cutaneous lymphomas in selected circumstances.

EA DV CONGRESS
VIENNA
30 SEP - 3 OCT 2026

Abstract N°: 1842

Analysis of second primary cutaneous squamous cell carcinoma (CSCC) tumours reported during the C-POST trial, a randomized phase 3 study of adjuvant cemiplimab vs placebo (pbo) for high-risk CSCC

Danny Rischin[1], Sandro Porceddu[2], Fiona Day[3], Daniel Brungs[4], Hayden Christie[5], James Jackson[6], Brian Stein[7], Yungpo Su[8], Rahul Ladwa[9], Gerard Adams[10], Samantha Bowyer[11], Zulfiquer Otty[12], Paolo Bossi[13], Amarnath Challapalli[14], Axel Hauschild[15], Annette Lim[1], Frank Seebach[16], Suk-Young Yoo[16], Priscila Goncalves*[16], Matthew Fury[16]

[1] Department of Medical Oncology, Peter MacCallum Cancer Centre, Melbourne, Australia
[2] Department of Radiation Oncology, Peter MacCallum Cancer Centre, Melbourne, Australia
[3] Department of Medical Oncology, Calvary Mater Newcastle, Waratah, Australia
[4] Illawarra Cancer Care Centre, Wollongong Hospital, Wollongong, Australia
[5] Cancer Care Centre Hervey Bay, Urraween, Australia
[6] Radiation Oncology Centers, Gold Coast, Australia
[7] Adelaide Cancer Centre, Adelaide, Australia
[8] Head and Neck Medical Oncology, Nebraska Cancer Specialists, Omaha, NE, United States
[9] Princess Alexandra Hospital, Woolloongabba, Australia
[10] Radiation Oncology, Genesis Cancer Care, Bundaberg, Australia
[11] Department of Medical Oncology, Sir Charles Gairdner Hospital, Perth, Australia
[12] Townsville Cancer Centre, Townsville University Hospital, Townsville, Australia
[13] Department of Biomedical Sciences, Humanitas University, Milan, Italy
[14] Bristol Cancer Institute, University Hospitals Bristol & Weston NHS Foundation Trust, Bristol, United Kingdom
[15] Department of Dermatology, University Hospital (UKSH), Kiel, Germany
[16] Regeneron Pharmaceuticals, Inc., Tarrytown, NY, United States

Introduction

Cemiplimab was recently approved for the adjuvant treatment of adult patients (pts) with CSCC at high risk of recurrence after surgery and radiation. The approval was based on the results from the primary analysis of the phase 3 C-POST trial (NCT03969004) that demonstrated an improved disease-free survival (DFS) with cemiplimab vs pbo (HR 0.32) in pts with high-risk CSCC. We report results of CSCC second primary tumors (SPTs) that arose during the study period.

Materials and Methods

A secondary objective of C-POST was to compare the effect of adjuvant cemiplimab vs pbo on the cumulative incidence of SPTs. SPTs were defined as invasive CSCC lesions in the skin unrelated to the index high-risk CSCC. SPTs were managed by local modality therapy as part of routine clinical practice and were not DFS events per protocol. Pts could have multiple SPTs during the study.

Results

From Jun 2019 to Aug 2024, 415 pts were enrolled (209 cemiplimab; 206 pbo). There were 191 SPTs occurring in

68 pts during the study period (on-treatment plus follow-up; **Table**). Although the number of pts with ≥1 SPT was similar in each arm (n=31 cemiplimab; n=37 pbo), the total number of SPTs and the annualized SPT rate were lower in the cemiplimab arm (68 SPTs; 0.63 [95% CI: 0.36–1.11]) vs the pbo arm (123 SPTs; 1.20 [0.59–2.44]). In a post-hoc analysis in which first SPTs were counted as DFS events, efficacy still favoured cemiplimab (HR 0.43; 95% CI: 0.30–0.60).

Conclusions

Cemiplimab may be associated with a lower incidence and rate of SPTs in a subset of pts with high-risk CSCC. The robust efficacy signal with cemiplimab vs pbo is maintained in a post-hoc analysis in which first SPTs were included as DFS events.

Table

	Cemiplimab (n=209)	Pbo (n=206)
Total SPTs, n	68	123
Total pt-years followed	412.4	331.0
SPT rate		
Unadjusted†	0.2	0.4
Adjusted annualized (95% CI)‡	0.63 (0.36–1.11)	1.20 (0.59–2.44)
Pts with ≥1 SPT, n (%)	31 (15)	37 (18)
Pts by number of SPTs, n (%)		
1	17 (8)	25 (12)
2	6 (3)	4 (2)
3	2 (1)	1 (<1)
4	1 (<1)	2 (1)
5	4 (2)	0
6	0	1 (<1)
7	0	2 (1)
9	1 (<1)	0
16	0	1 (<1)
43	0	1 (<1)

† Total SPTs during study period divided by total pt-years followed.

‡ Via negative binomial model: response variable: total SPTs during study period; covariates: treatment arm, location of resected high-risk tumour, geographic region; offset variable: log-transformed standardised observation duration.

EADV CONGRESS
VIENNA
30 SEP - 3 OCT 2026

Abstract N°: 1853

Synchronous Primary Cutaneous Melanomas Mimicking Cutaneous Metastasis: Diagnostic and Therapeutic Challenges

Crinela Kelemen-Radu*[1], Iulia Dobocan[2], Loredana Ungureanu[1, 2]

[1] "Iuliu Hatieganu" University of Medicine and Pharmacy from Cluj-Napoca, Cluj-Napoca, Romania

[2] Dermatology Department, County Emergency Hospital Cluj-Napoca, Cluj-Napoca, Romania

Introduction

Cutaneous melanoma is an aggressive malignancy characterized by unpredictable evolution and high metastatic potential. The differential diagnosis between multiple primary melanomas and cutaneous metastases can be challenging, with significant implications for staging and therapeutic management. We present a case highlighting these diagnostic difficulties.

Case Presentation

A 38-year-old patient presented with a pigmented lesion located on the right anterior thoracic wall, clinically suspicious for melanoma. Dermatological and dermoscopic examination revealed an asymmetric lesion with irregular borders, polychromia, a central blue-white veil, regression structures, and an atypical peripheral pigment network. A second pigmented lesion was identified in the right scapular region and was initially suspected to represent a distant cutaneous metastasis. Soft tissue ultrasound revealed hypoechoic nodular lesions, along with a suspicious right axillary lymph node in the given clinical context. Both lesions were surgically excised. Histopathological examination demonstrated melanomas in the vertical growth phase. The pectoral lesion arose on a pre-existing nevus and showed an initial Breslow thickness of 1 mm, ulceration, and a mitotic rate of 2/mm2, later revised to 2.3 mm with adjacent microsatellitosis. The scapular lesion had a Breslow thickness of 1 mm and was also associated with microsatellitosis, without clear evidence of arising on a pre-existing nevus. For accurate staging and exclusion of distant metastases, brain MRI with contrast and whole-body PET-CT were performed, both showing no evidence of metastatic disease. Accordingly, the tumors were classified as stage IIIC (pectoral lesion) and stage IIIB (scapular lesion), confirming the diagnosis of synchronous primary melanomas rather than cutaneous metastasis. In the presence of a BRAF V600E mutation, targeted therapy with BRAF/MEK inhibitors was initiated. A CT scan of the chest, abdomen, and pelvis performed at three months after treatment initiation showed no evidence of disease progression or secondary metastases.

Conclusion

This case underscores the importance of comprehensive clinical, imaging, and histopathological evaluation in distinguishing between cutaneous metastases and multiple primary melanomas. Microsatellitosis plays a key role in staging and prognosis. A multidisciplinary approach and personalized targeted therapy are essential for optimal patient management in advanced melanoma.

EA DV CONGRESS
VIENNA
30 SEP - 3 OCT 2026

Abstract N°: 1862

Diffuse Large B-Cell Lymphoma with Early Extranodal Relapse and Cutaneous Involvement

Denise Chavit Emerson*[1], Valentina Pini Gueli[2], Carla Trila[1], Pedro Barbosa[1], Corina Busso[1]

[1] Hospital Universitario Austral, Buenos Aires, Argentina
[2] Hospital Universitario Austral, Buenos aires, Argentina

Introduction

Diffuse large B-cell lymphoma (DLBCL) is the most common subtype among non-Hodgkin lymphomas (NHL) and it is characterized by an aggressive clinical course. It typically presents with a rapidly enlarging tumor mass that may affect one or multiple lymph nodes, as well as extranodal locations. Extranodal involvement occurs in roughly 30% of cases, with the gastrointestinal tract and skin being the most frequently affected organs.

We present the case of a patient with early extranodal cutaneous involvement secondary to diffuse large B-cell lymphoma.

Case Presentation

A 66-year-old male patient with a history of Non-Hodgkin lymphoma diagnosed in 2012, relapsed in 2024, subsequently underwent autologous hematopoietic stem cell transplantation (ASCT) in January 2025.

The patient was referred to dermatology for assessment of asymptomatic cutaneous lesions on the lower extremities that had been present for three months. Physical examination revealed multiple violaceous nodular tumors located on the pretibial region, lateral and posterior aspect of the left thigh, and left inguinal area, without mucosal involvement. A large, non-tender, non-mobile lymph node was palpated in the left inguinal region.

The differential diagnoses included Kaposi sarcoma, cutaneous involvement of B-cell lymphoma, angiosarcoma and bacillary angiomatosis.

Skin biopsy showed a diffuse non-epidermotropic dermal infiltrate composed of large pleomorphic lymphoid cells with immunoblastic and centroblastic morphology. Immunohistochemistry demonstrated positivity for CD20, BCL2, BCL6, and MUM1 (>30%), with CD10 negativity, consistent with secondary cutaneous involvement by DLBCL.

Further studies included regional ultrasound, which demonstrated multiple lymphadenopathies (the largest measuring 17 mm) with inflammatory changes in adjacent fat planes. A PET scan revealed multiple hypermetabolic nodules involving the skin and soft tissues, along with supra and infradiaphragmatic hypermetabolic lymphadenopathies, predominantly on the left side, suggestive of systemic relapse.

Given the diagnosis of early relapse (within six months after ASCT), extranodal involvement, and high tumor burden, treatment with epcoritamab, a CD3×CD20 bispecific antibody, was initiated. Fourteen days later the patient developed severe acute hepatopathy and acute respiratory failure, ultimately resulting in death.

Conclusion

Secondary cutaneous involvement may be a manifestation of early extranodal relapse in DLBCL and indicates highly aggressive disease with poor prognosis. This case illustrates that early biopsy of suspicious skin lesions is essential for timely diagnosis.

EA DV CONGRESS
VIENNA
30 SEP - 3 OCT 2026

Abstract N°: 1874

Artificial Intelligence Augmented Skin Cancer Detection and Risk Stratification in LMICs: A Scoping Review of Clinical Integration, Diagnostic Accuracy, and Real-World Implementation

Mohd Faizan Siddiqui*[1], Mouna Azaroual[2]

[1] International Medical Faculty, Osh State University, osh, Kyrgyzstan

[2] CHU Mohammad VI, Marrakesh, Marrakesh, Morocco

Introduction

Skin cancer is a leading type of malignancy in the world, and the increasing incidence of the disease is putting an increasing burden on the dermatology services. Artificial intelligence (AI) and specifically deep learning-based image analysis have demonstrated potential in early detection, but have not been implemented in practice in clinical settings. To map and synthesize the existing evidence about AI-assisted skin cancer detection, with a focus on diagnostic performance, clinical integration, and implementation issues.

Materials and Methods

This scoping review was based on PRISMA-ScR. A systematic search of publications published in 2015-2026 was carried out in PubMed, Scopus, and Web of Science. A total of 1,126 records were found in the search. Following the deletion of 312 duplicates, 814 titles and abstracts were filtered, and 96 articles subjected to a full-text review. The final analysis was done with 28 studies based on predefined inclusion and exclusion criteria. Qualified studies evaluated AI-based models to detect, classify or stratify the risk of melanoma and non-melanoma skin cancers. Data extraction involved study design, type of algorithm, data characteristics, validation measures and diagnostic performance measures (sensitivity, specificity, AUC).

Results

28 studies that were included showed that AI models and especially convolutional neural networks were highly accurate in diagnosis, and the reported AUC values were 0.85 to 0.98. A number of studies demonstrated similar performance to that of dermatologists in controlled conditions. The incorporation of AI enhanced the triage of lesions, early detection of melanoma, and workflow. Tools with mobile and dermoscopy increased care accessibility. Nevertheless, there were shortcomings such as bias in data sets, underrepresentation of darker types of skin, no external validation data, and limited prospective clinical trials. Concerns of regulatory, ethical, and interpretability also curtailed the general adoption.

Conclusions

AI can greatly change the way skin cancer is identified, and field of dermatology specially in Low and Middle income countries. Although there is good diagnostic performance, methodological and ethical issues limit its use in practice. Standardized validation, variety of datasets, and clinically-integrated, prospective studies should be prioritized in future research studies to allow safe and justifiable adoption.

EADV CONGRESS
VIENNA
30 SEP - 3 OCT 2026

Abstract N°: 1893

Melanoma arising in an intradermal nevus in a transplant recipient

Natalija Zivotic[1], Tamara Jemcov[2], Visnja Lezaic[3], Zorka Milovanovic[4], Danijela Dobrosavljevic Vukojevic*[1]

[1] Clinic of Dermatovenereology UKCS, Faculty of Medicine, University of Belgrade, Belgrade, Serbia

[2] Clinic of Nephrology, KBC Zemun, Faculty of Medicine, University of Belgrade, Clinic of Nephrology UKCS, Faculty of Medicine, University of Belgrade, Belgrade, Serbia

[3] Clinic of Nephrology UKCS, Faculty of Medicine, University of Belgrade, Belgrade, Serbia

[4] Institute of Oncology and Radiology, Belgrade, Belgrade, Serbia

Introduction

After ten years of the first appointment, we performed check-up of the examined kidney transplanted patients and search in database. We present a case of melanoma arising in intradermal melanocytic naevus (IMN) in a kidney transplanted patient.

Case Presentation

A 51-year-old woman presented for dermatological evaluation eight years after kidney transplantation from a living donor. She was receiving long term immunosuppressive therapy (tacrolimus, mycophenolatemofetil, prednisone) and had excellent graft function. Clinical examination revealed a nodular lesion in the right preauricular region measuring 25 mm in diameter and 8 mm in elevation. It was present as an IMN, unchanged for 30 years, slowly enlarging and changing in appearance over the previous year. The lesion had a rough surface, partially covered with a hemorrhagic crust. Dermoscopy revealed asymmetry, melanocytic pigment and regression, hemorrhagic crust and marked polychromia.

Complete surgical excision was performed. Histopathological analysis demonstrated a nevoid type melanoma arising within an intradermal nevus, with superficial ulceration. Pigmentation involved approximately two thirds of the lesion. Mitotic activity was 3 per 10 high power fields, accompanied by a brisk lymphocytic infiltrate. No satellite foci or lymphovascular invasion were identified.

Five months after excision, metastases were detected in regional lymph nodes, the salivary gland, and striated muscles. The disease progressed rapidly, and the patient died within one year of diagnosis in 2016. At that time, no systemic therapy in our country was approved for melanoma patients.

Conclusion

By the end of 2025, only 16 cases of melanoma arising in an intradermal nevus had been reported.

Dermatoscopic documentation is available in a very few cases. This is the first dermatoscopy of melanoma in a transplanted patient. In transplant recipients, *de novo* melanoma occurs on the face in approximately 50% of cases, but development within an intradermal nevus has not been previously described. Chronic immunosuppression and reduced immune surveillance may have contributed to tumor development. This case underscores the importance of regular skin examination in transplant recipients.

EA DV CONGRESS
VIENNA
30 SEP - 3 OCT 2026

Abstract N°: 1896

Pembrolizumab-Induced Inverse Psoriasiform Eruption In Melanoma: An Uncommon Immune-Related Cutaneous Adverse Event

Lina Marcela López González*[1], Rafael Montealegre Alvarado[1], Valeria Duque Clavijo[1], Liseth Losada Rodriguez[1]

[1] Universidad FUCS, Hospital Infantil de San José, Bogotá, Colombia

Introduction

Immune checkpoint inhibitors, such as pembrolizumab, have revolutionized the treatment of advanced melanoma by blocking the PD-1/PD-L1 axis and enhancing antitumor immune responses[1]. However, they are associated with cutaneous adverse events in up to 30–40% of patients, with psoriasiform eruptions being an increasingly recognized manifestation[2]. Immunotherapy-induced psoriasis may occur de novo or as an exacerbation, with an average latency of approximately 8 weeks[1]. The inverse subtype is uncommon, accounting for nearly 5% of psoriasis cases associated with checkpoint inhibitors, and is often misdiagnosed as infectious intertrigo, delaying diagnosis[3]. Reports of pembrolizumab-induced inverse psoriasiform eruptions remain scarce in the literature[4].

Case Presentation

A 33-year-old female with invasive superficial spreading melanoma (T4a N1a M0, stage IIIC) located on the left thigh, treated with surgical excision and left inguinal lymph node dissection, was receiving adjuvant treatment with pembrolizumab 200 mg IV every 3 weeks. After the third cycle of immunotherapy, she developed erythematous plaques with fine adherent whitish scale and intense pruritus, predominantly affecting intertriginous areas. Initial treatment with topical calcineurin inhibitors showed no clinical improvement. Due to the clinical features and oncologic context, a skin biopsy from the left axilla and groin were performed, revealing epidermal psoriasiform acanthosis, hyperkeratosis with parakeratosis, and intracorneal neutrophilic aggregates, without evidence of fungal structures, compatible with a psoriasiform eruption (Figure 1).

Based on these findings, treatment with a medium-potency topical corticosteroid combined with a vitamin D analogue was initiated, achieving approximately 80% resolution of the lesions within two weeks, along with significant improvement in pruritus.

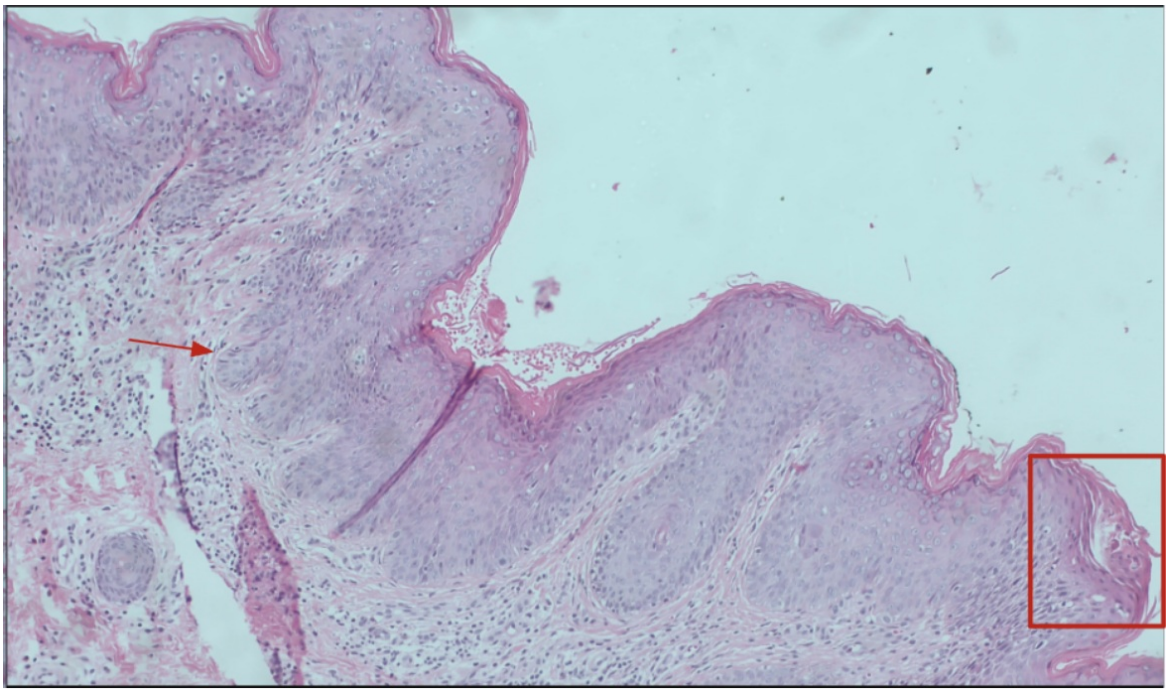

Figure 1. Histopathological examination of skin biopsy (H&E stain, medium magnification). Hyperkeratosis with focal parakeratosis and mild reduction of the granular layer are observed. Red arrow: epidermis with psoriasiform hyperplasia and elongation of rete ridges. Red box: lymphocytic exocytosis and intracorneal neutrophilic aggregates consistent with microabscesses. No evidence of fungal structures. Findings are consistent with psoriasiform dermatitis.

Conclusion

Psoriasis induced by PD-1 inhibitors represents a relevant immune-mediated adverse event, likely related to activation of Th1/Th17 pathways[1]. Although uncommon, the inverse subtype should be considered in patients receiving immunotherapy who present with refractory intertriginous dermatoses, particularly when unresponsive to antifungal treatment[3]. It is essential to recognize and report these cutaneous adverse events, as they significantly impact patients' quality of life and may lead to discontinuation of adjuvant oncologic therapy. This interruption carries a potential risk of disease progression and, consequently, increased mortality.

This case highlights the importance of early clinical recognition and histopathological confirmation to avoid diagnostic delays. Furthermore, it demonstrates that conventional topical therapies, such as corticosteroids and vitamin D analogues, can be highly effective, allowing continuation of life-prolonging oncologic treatment.

EADV CONGRESS
VIENNA
30 SEP - 3 OCT 2026

Abstract N°: 1917

Who detects melanoma first? Insights from a prospective clinical investigation

Filippos Giannopoulos*[1]

[1] Department of Dermatology and Venerology, Sahlgrenska University Hospital, Gothenburg, Sweden

Introduction

Early detection of melanoma is essential for favourable outcomes. Both patients and healthcare professionals contribute to identifying suspicious lesions, but the balance between patient-initiated and healthcare-initiated detection differs across clinical contexts.

Prospective data on how melanomas are first suspected in routine clinical practice remain limited. An ongoing clinical investigation with blinded parallel assessment using an artificial intelligence (AI)-based decision support system provides an opportunity to explore detection pathways in a real-world setting.

The aim of this sub-analysis was to investigate who first suspected melanoma in the initial cases included in this prospective clinical investigation.

Materials and Methods

This is an exploratory sub-analysis of an ongoing prospective, non-randomized, parallel, double-blinded clinical investigation.

Patients ≥18 years with clinically suspected primary melanoma scheduled for surgical excision are consecutively included. Dermoscopic images are analyzed by an AI-based decision support system in parallel, while investigators remain blinded to the AI output. Histopathology serves as the reference standard.

At inclusion, a structured electronic case report form captures the question: “Who first discovered the suspected melanoma?”.

For this analysis, the first 50 patients (53 lesions) were evaluated. Lesions diagnosed as melanoma or melanoma in situ were included. Detection was categorized as patient-related (patient or relative) or healthcare-related (dermatologist, general practitioner, or other healthcare personnel). Descriptive statistics were used.

Results

Among the first 50 patients, 17 melanomas (including melanoma in situ) were identified.

Of these, 8/17 (47%) were first detected by patients or relatives, while 9/17 (53%) were first identified within the healthcare system. Patients accounted for the largest single category (7 cases), while dermatologists and general practitioners identified 4 cases each.

Invasive melanomas were predominantly detected by patients, whereas melanoma in situ lesions were more frequently identified during healthcare encounters.

Benign lesions, including dysplastic nevi, were more frequently detected during healthcare encounters, particularly by dermatologists.

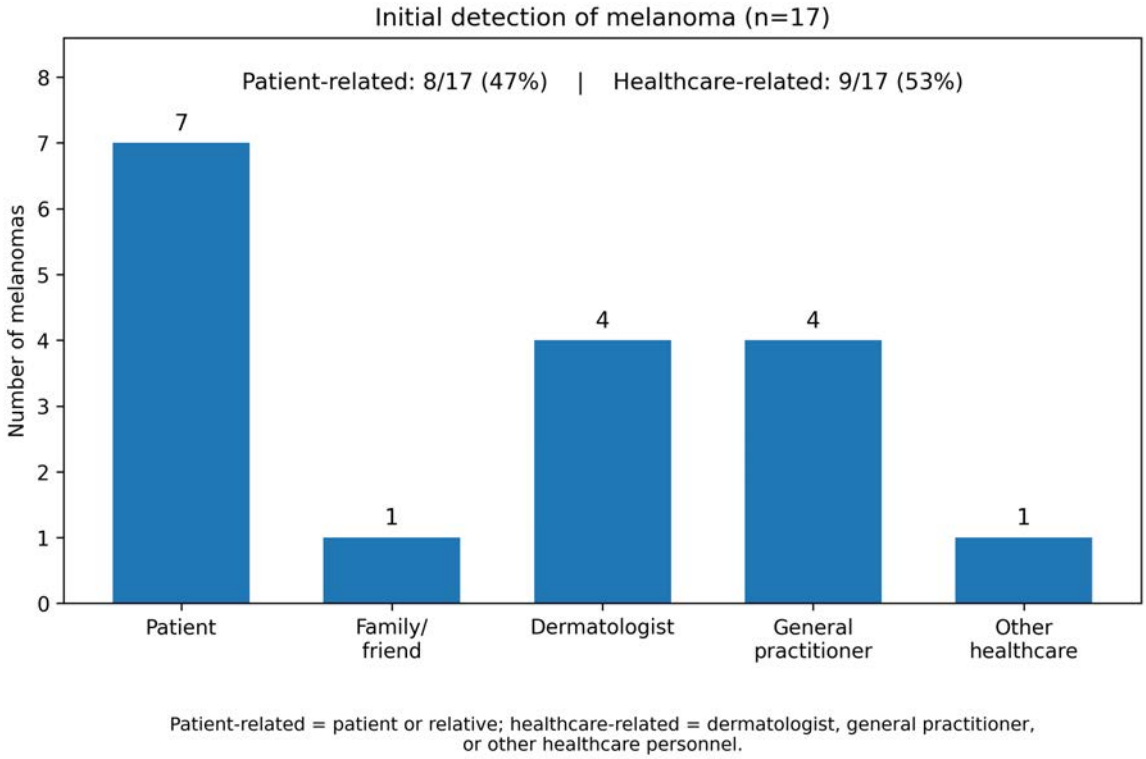

Figure 1. Initial detection of melanoma by melanoma type. The stacked bars show the distribution of detection categories for melanoma in situ (n=10) and invasive melanoma (n=7). Patient-related detection predominated in invasive melanomas, while melanoma in situ lesions were more frequently identified during healthcare encounters.

Conclusions

In this exploratory prospective analysis, melanoma detection was nearly equally distributed between patient-initiated and healthcare-initiated pathways.

These findings suggest that detection is not driven by a single pathway but reflects complementary contributions from patient awareness and clinical evaluation, particularly for lesions that may not initially raise concern.

Further analyses in the full cohort are warranted to better understand detection patterns and their relationship to tumor characteristics and outcomes.

EA DV CONGRESS
VIENNA
30 SEP - 3 OCT 2026

Abstract N°: 1929

Melanoma development and progression during polypharmacy and the additional intake of metformin and sitagliptin: links to nitroso photocarcinogenesis and oncopharmacogenesis

Georgi Tchernev[1, 2], Konstantin Tchernev Jr[2], Valentina Broshtilova-Nikolova[3], Simona Kordeva*[1]

[1] Medical Institute of Ministry of Interior - Department of Dermatology and Venereology, Sofia, Bulgaria

[2] Onkoderma- Clinic for Dermatology, Venereology and Dermatologic Surgery, Sofia, Bulgaria

[3] Sofia University Saint Kliment Ohridski, Faculty of Medicine - Department of Internal Diseases, Pharmacology and Clinical Pharmacology, Pediatrics, Epidemiology, Infectious Diseases, and Skin Diseases, Sofia, Bulgaria

Introduction

The photocarcinogenic or genotoxic, mutagenic effect of certain nitrosamines such as nitrosomorpholine, for example, is even- just as an information availability in the scientific space,an extremely worrying fact .Nitrosamines could appear in the body due drug contamination in medication, sensitive to form these photocarcinogenic substances. Medication containing secondary and tertiary amino groups is capable to nitroso creation in and outside the human body.

External nitrosamine formation and endogenously nitroso formation differs from each other. External nitrosogenesis occurs during manufacturing process while the endogenously nitroso genesis requires acidic conditions, nitrite-rich food and secondary/tertiary amino groups in medication. After resorption in the human body and before metabolization/activation in the liver, nitroso medication could deposit on skin. Subsequent UV irradiation may lead to photodecomposition and NO release, ROS interaction and DNA damage. The complex aspect of the nitrosogenesis of skin cancer seems to be dependent from many factors like drug and food intake which determine the intake of photocarcinogens.

Currently, even if a medication is completely free of nitrosamine contamination, when ingested and under acidic gastric conditions can undergo nitrosation.

Materials and Methods

The overlapping mutational patterns of nitrosamine-induced mutations in humans in general (RAS and p53), with those responsible for the manifestation of melanoma and keratinocytic cancers (again, the same genes) , are one piece of albeit indirect evidence that nitrosamines could safely be considered a pathogenetic cofactor for skin cancer, regardless of their phototoxicity. The different mutation pattern in skin cancer genome might be linked to the influence of different nitroso compounds/ NDSRIs in different drugs.

Distinguishing the mutagenic from the carcinogenic organotoxic action of nitrosamines is also important (but also problematic) because of the fact that not every mutation is equivalent to a carcinogenic action, and that not every carcinogen could be classified as a mutagen.

Different nitrosamines have different effects: from mutagenic, to mutagenic-carcinogenic, genotoxic, or purely carcinogenic-to the complete absence of each of these. Nitrosamines have also been identified as genotoxic chemicals, while also being described as possible potent human and animal carcinogens. Some nitrosamines are also potent mutagens.

Results

We present 3 cases of patients with melanomas of the skin that developed and progressed in the context of intake of secondary/tertiary amino groups:

(1) Patient 1's regimen during the years included bisoprolol (secondary), nebivolol (secondary), candesartan /hydrochlorothiazide (secondary), amlodipine (secondary), and clopidogrel (tertiary), and esomeprazole (tertiary) [Figure a,b];

(2) Patient 2's included amiodarone (tertiary), apixaban, furosemide (secondary), spironolacton, and pantoprazole (tertiary) [Figure c,d]; and

(3) Patient's 3 regimen included sitagliptin (secondary)/metformin (secondary and tertiary), glimepiride (secondary), and gliclazide (tertiary) [Figure e,f].

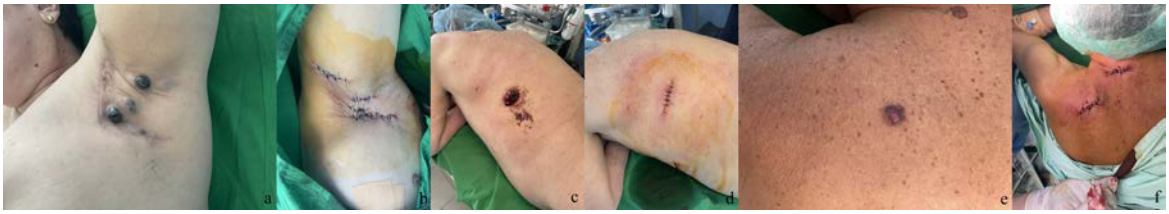

Figure a-f: Patient 1 (a,b): Two well-defined dark nodules and multiple small slightly raisedpigmented lesions in the left axillary region (a). Surgical removal with multiple elliptical excisions of the lesions followed by closure of the remaining defects with single interrupted sutures (b). Patient 2 (c,d): Polypoid melanoma measuring 2 cm by 1.8 cm, with spontaneous bleeding and surface ulceration (c). The melanoma is removed with an elliptical excision (d) and the remaining defect is closed by single interrupted sutures. Patient 3 (e,f): Nevus with irregular borders and uneven pigmentation centrally in the back area at the level of C7 (e). Nodular melanoma at the level of Th12, 4 cm to the left, with uneven borders, inhomogeneous pigmentation, and measured 1.5 cm in size (e). The primary defects were closed with single interrupted sutures (f).

Conclusions

We comment on the possible relevance of endogenous Nitroso formation in the drugs mentioned above in relation to melanoma pathogenesis.

EADV CONGRESS
VIENNA
30 SEP - 3 OCT 2026

Abstract N°: 1939

Dermatofibrosarcoma Protuberans of the Neck: A Diagnostic and Therapeutic Challenge

Ouissal Laadime*[1], Mariem Aboudourib[1], houda azour[1], Bendaoud Layla[1], ouafa hocar[1], Amal Said[1]

[1] Department of Dermatology and Venereology, Arrazi Hospital, Mohammed VI University Hospital Center, Marrakech, Morocco

Introduction

Dermatofibrosarcoma protuberans (DFSP) is a rare cutaneous tumor characterized by slow growth but a high tendency for local recurrence. Diagnosis is often delayed due to its variable clinical presentation and frequently non-conclusive initial biopsies.

Case Presentation

We report the case of a 34-year-old woman with no relevant medical history, presenting with a 5-year history of an infiltrated erythematous plaque on the right lateral aspect of the neck, associated with nodular components, measuring 12 × 7 cm. The lesion evolved in an afebrile context with preserved general health.

Three initial biopsies were inconclusive. Bacteriological and mycological studies, as well as GeneXpert testing, were negative. The most recent biopsy revealed a dermal and subcutaneous mesenchymal proliferation of moderate density. Immunohistochemical analysis showed diffuse CD34 positivity, low proliferative activity (Ki-67 ≈ 4%), and negative S100 expression, consistent with dermatofibrosarcoma protuberans.

Staging workup showed no evidence of metastasis. Given the large size and challenging cervical location, management was complex. Neoadjuvant therapy with imatinib (400 mg/day) was initiated, followed by planned surgical excision.

Conclusion

DFSP should be suspected in any persistent infiltrated cutaneous lesion. A multimodal approach combining histopathology, immunohistochemistry, and targeted therapy may optimize surgical management in complex cases.

EADV CONGRESS
VIENNA
30 SEP - 3 OCT 2026

Abstract N°: 1944

FLASH radiotherapy for non-melanoma skin cancer: preclinical evaluation of skin toxicity and optimization of fractionation strategies.

Dorien De Ridder*[1], Inès Dufait[2], Racell Nabha[2], Gaelle Leemans[1], Lisa Kerkhove[2], Mark De Ridder[2], Jan Gutermuth[1], Thierry Gevaert[2]

[1] Department of Dermatology, UZ Brussel, VUB, Brussels, Belgium

[2] Department of Radiotherapy, UZ Brussel, VUB, Brussels, Belgium

Introduction

Non-melanoma skin cancer (NMSC), including squamous cell and basal cell carcinoma, is highly prevalent. In patients unsuitable for surgery, radiotherapy (RT) is a key treatment option, with skin toxicity and cosmetic outcome driving clinical decision-making. FLASH-RT, delivering ultra-high dose rates, has demonstrated reduced normal tissue toxicity while preserving tumour control in preclinical models. However, optimal fractionation and long-term skin effects remain undefined, limiting translation into clinical practice.

This study aims to define clinically relevant FLASH-RT fractionation strategies for NMSC by integrating radiobiological modelling with preclinical *in vivo* assessment of skin toxicity.

Materials and Methods

A two-step translational approach was applied. First, an *in silico* model incorporating uncertainty in α/β ratios and a FLASH-modifying factor compared therapeutic ratios between conventional RT and FLASH-RT for a single-fraction (1×20 Gy) and a moderately hypofractionated regimen (10×4 Gy), using Monte Carlo simulations.

Second, a preclinical large-animal study was initiated in Göttingen minipigs. Animals receive kV, MV, and FLASH irradiation across clinically relevant dose schedules and field sizes (Figure 1). Acute (<3 months) and chronic (up to 24 months) skin toxicity are assessed longitudinally using standardized scoring, imaging, and histopathology.

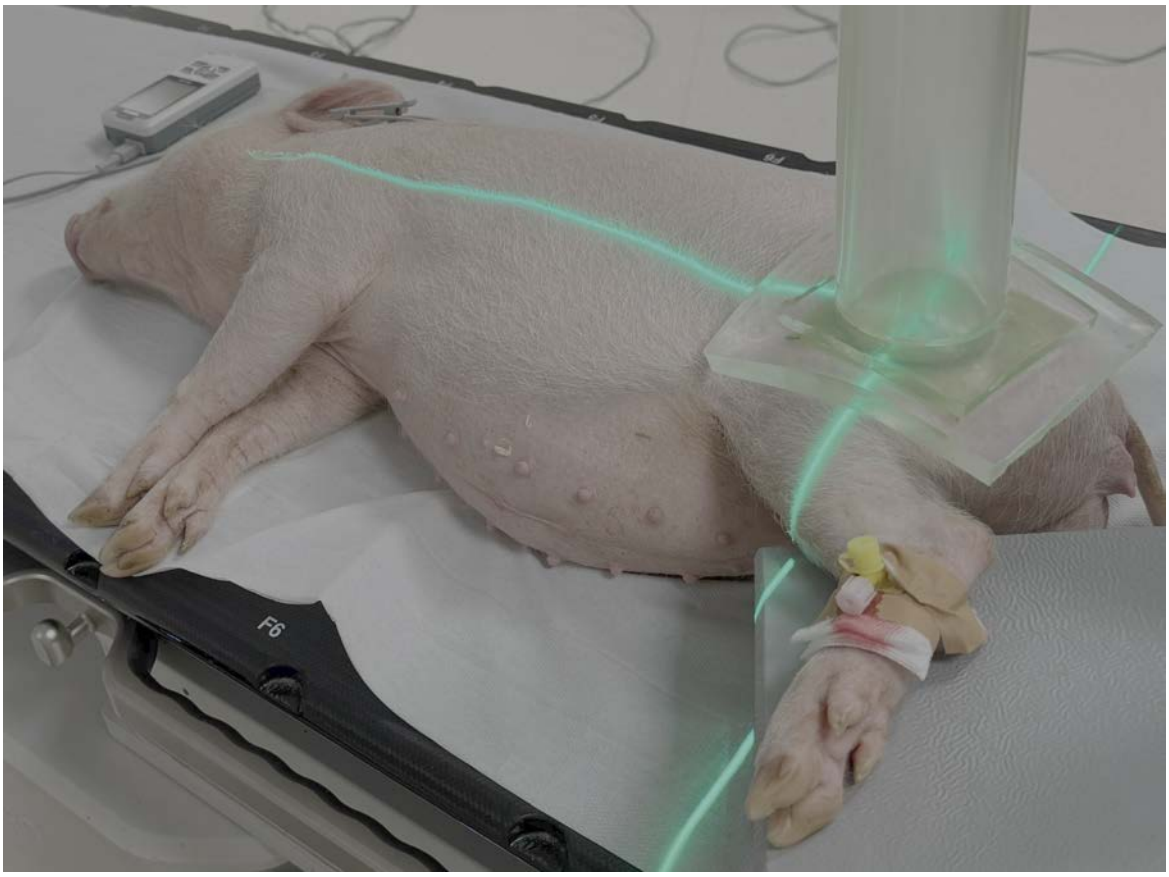

Figure 1: FLASH irradiation of a Göttingen minipig using 9 MeV electrons and a 5 cm cone collimator.

Results

Radiobiological modelling showed preserved tumour effects with FLASH and consistently reduced normal tissue biologically effective doses (BED), resulting in improved therapeutic ratios. Table 1 demonstrates reduced acute and late normal tissue BED across both regimens, while tumour BED remained unchanged.

FLASH using a moderately hypofractionated regimen (10×4 Gy) showed narrower distributions and greater robustness, with more consistent therapeutic ratios across Monte Carlo simulations, as illustrated in Figures 2A and 2B. Single-fraction FLASH (1×20 Gy) produced the largest increase in therapeutic ratio but with greater variability, particularly for late toxicity, as reflected by broader distributions in Figure 2B.

Overall, single-fraction FLASH maximized relative gain, whereas the moderately hypofractionated regimen provided a more stable balance between efficacy and skin tolerance. These findings are particularly relevant for NMSC, where treatment selection is often driven by expected cosmetic outcome rather than tumour control alone.

The preclinical study is ongoing and will validate these findings *in vivo* by assessing clinically relevant skin toxicity endpoints, including erythema, desquamation, fibrosis, and radionecrosis. Preliminary results, including *in vivo* confocal microscopy and transcriptomic analyses, will be presented.

	Conventional 1×20 Gy			FLASH 1×20 Gy		
	Mean	**SD**	**Range**	**Mean**	**SD**	**Range**
BED_T	60.4	3.6	53.4 – 70.0	60.4	3.7	52.8 – 70.6
BED_{NT_acute}	64.8	4.5	53.8 – 77.0	52.6	3.7	43.0 – 64.3
BED_{NT_late}	156.4	20.9	120.1 – 219.6	135.9	18.1	102.8 – 193.7
	Conventional 10×4 Gy			**FLASH 10×4 Gy**		
BED_T	56.2	1.4	53.4 – 60.0	56.2	1.5	53.1 – 60.2
BED_{NT_acute}	57.9	1.8	53.5 – 62.8	53.0	1.5	49.2 – 57.7
BED_{NT_late}	94.6	8.4	80.0 – 119.9	86.4	7.2	73.1 – 109.5

Table 1: BED_T, BED_{NT_acute} and BED_{NT_late} for FLASH and conventional irradiation for two different treatment regimens. *Abbreviations:* BED_T, BED_{NT_acute}, BED_{NT_late}: Biologically Effective Dose for Tumour, Normal Tissue Acute and Late Effects, respectively.

Conclusions

FLASH-RT has the potential to improve the therapeutic ratio in NMSC by reducing skin toxicity, with direct implications for cosmetic outcome and long-term skin integrity. A moderately hypofractionated regimen (10 fractions) appears to provide the most robust balance between efficacy and safety and may represent a clinically applicable strategy for patients with squamous or basal cell carcinoma in whom surgery is not feasible. Ongoing large-animal data will guide clinical translation and support future phase I/II trials in dermatologic oncology.

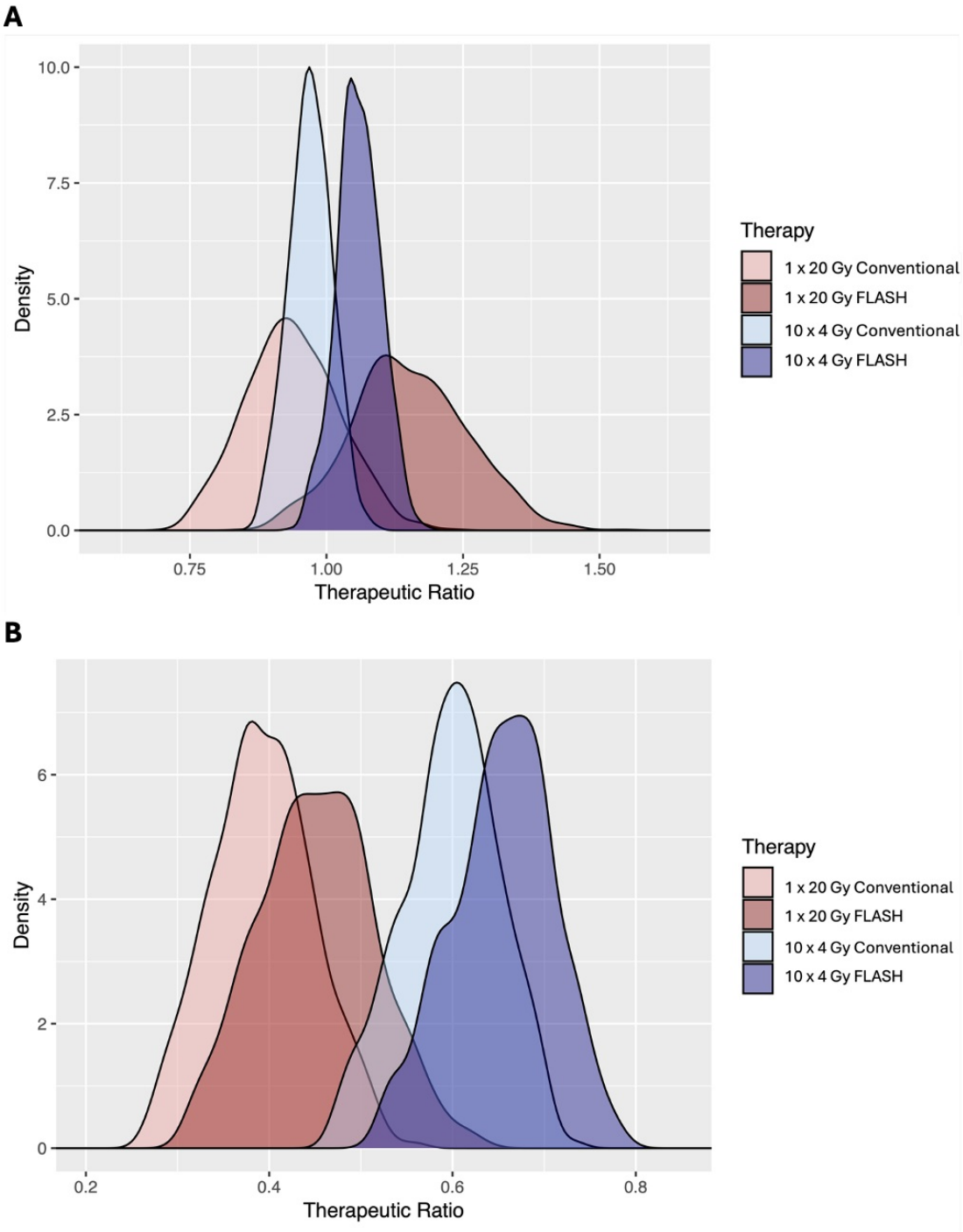

Figure 2: Therapeutic ratios: (A) Tumour control versus acute toxicity; (B) Tumour control versus late toxicity

EA DV CONGRESS
VIENNA
30 SEP - 3 OCT 2026

Abstract N°: 1948

Pyogenic granuloma-like sebaceous adenocarcinoma (PGLSA), an atypical case report.

Eduardo Josué Marín González*[1], Eduardo Marín Hernández[1], Verónica Bautista Piña[2]

[1] Instituto Mexicano del Seguro Social (IMSS), Mexico City, Mexico
[2] Fundación de Cáncer de Mama (FUCAM), Mexico City, Mexico

Introduction

Sebaceous adenocarcinoma (SA) is an infrequent but aggressive malignant neoplasm, with a higher incidence in males >60 years of age and of White ethnicity; data from Latin America are unknown. We present the case of a male in his eighth decade of life who presents with a rapidly growing, highly vascularized lesion that clinically resembled a pyogenic granuloma.

The primary location is the upper eyelid, accounting for 38.5% of all cases; extraocular presentation manifests in the head and neck in 42% of cases, the trunk in 15%, and the extremities in 6.5%. It typically presents as a firm, painless, slow-growing pink, brown, or yellow papule; the lesion morphology may vary with thickening, ulceration, or nodule formation.

The diagnostic cornerstone is histopathologic examination, evidencing pleomorphic basophilic cells with vacuolated cytoplasm, prominent nuclei, and mitotic figures. Immunohistochemistry demonstrates adipophilin granules, the most sensitive and reliable marker; epithelial membrane antigen, present in all SA cases. The androgen receptor shows diffuse nuclear positivity in SA with a sensitivity of 66% and a specificity of 92%. Pagetoid spread, found in up to 80% of palpebral cases, has implications for surgical margins.

Given the strong association with Muir-Torre syndrome (MTS), mutations in DNA mismatch repair proteins MLH1, MSH2, and MSH6 should be assessed; loss of expression of one or more genes is common, with a strong association with gastrointestinal neoplasms, primarily colorectal.

Surgery constitutes the therapeutic mainstay; Mohs micrographic surgery or complete circumferential peripheral and deep margin assessment are the preferred techniques, as they are associated with lower recurrence rates and greater overall survival.

Case Presentation

A 78-year-old male with obesity, hypertension, and diabetes of 15 years' duration, well-controlled, presented to the dermatology clinic with a dermatosis of one month's duration, with easy bleeding upon minimal trauma. Physical examination revealed a trilobulated neoformation with a central ulcer covered by a hematic crust at the left pectoral level. Based on these clinical findings, a diagnosis of pyogenic granuloma was proposed; shave excision and electrofulguration of the base were performed, with the specimen sent to pathology for examination, which reported sebaceous adenocarcinoma. During follow-up, a second lesion was intentionally sought and identified at the chin, with a vascularized papular appearance; excision reported sebaceous adenocarcinoma. With the diagnosis of sebaceous adenocarcinoma at two sites, the patient was referred to oncology, who performed margin widening of the thoracic lesion with no evidence of residual lesion on histopathologic report. During follow-up by the colorectal surgery service, no intestinal neoplastic lesions were identified. To date, no recurrences or new lesions have been documented.

Conclusion

SA represents 0.2 to 4.6% of all cutaneous malignant neoplasms. With a higher incidence in advanced age and primarily affecting Caucasian males, reports in our setting are scarce, and therefore precise epidemiological data are lacking. The significance of this report lies in the unusual clinical presentation, the clinical course, and the dual presentation of sebaceous adenocarcinoma in a patient without association such as MTS. In dermatologic literature, pyogenic granuloma-like appearance has been reported in drug reactions, renal tumor metastases, and Kaposi sarcoma, but not in primary SA with this terminology.

EADV CONGRESS
VIENNA
30 SEP - 3 OCT 2026

Abstract N°: 2011

Vulvar lentiginosis and the importance of differential diagnosis with melanoma: a case report

Mariana Menezes de Mauro*[1], Ingrid Palloma Vieira de Melo[2], Hudson Rezende[2], Betina Werner[3], Grace Lopes[4], Lucas Rodrigues Cardoso[5], Túlio Tozzi Fedrigo[4]

[1] Universidade São Francisco, Bragança Paulista, Brazil
[2] Centro Universitário Lusíada, Santos, Brazil
[3] Universidade Federal do Paraná, Curitiba, Brazil
[4] Universidade Paranaense (UNIPAR), Umuarama, Brazil
[5] Pontifícia Universidade Católica do Paraná, Curitiba, Brazil

Introduction

Vulvar pigmented lesions are relatively common and may raise clinical concern due to their resemblance to melanoma. Vulvar lentiginosis, also known as vulvar melanosis, is a benign condition characterized by brownish macules with a stable course and no malignant potential. However, its clinical similarity to melanoma often leads to diagnostic uncertainty, requiring careful evaluation. This report highlights the importance of accurate diagnosis to avoid unnecessary interventions.

Case Presentation

A 35-year-old woman was referred for evaluation of asymptomatic hyperpigmented lesions on the external genitalia, initially identified during a routine gynecological examination approximately 12 months earlier. The patient reported **a** slow, progressive increase in the number and size of the lesions, without associated symptoms or relevant personal or family history.

Dermatological examination revealed multiple well-defined, symmetric brownish macules on the labia majora and minora, predominantly measuring 1–2 mm, along with larger lesions measuring approximately 1.5 cm on the labia minora. Dermoscopy demonstrated a homogeneous pigmented pattern without structures suggestive of melanocytic proliferation or malignancy.

An incisional biopsy was performed, and histopathological examination confirmed vulvar lentiginosis, characterized by basal layer hyperpigmentation without cytological atypia or melanocytic nesting. The patient was managed conservatively with periodic follow-up and remained clinically stable, with no indication for treatment.

Conclusion

Vulvar lentiginosis is a benign condition that may clinically mimic melanoma, posing a diagnostic challenge. Dermoscopy and histopathological examination are essential for accurate diagnosis. Recognition of this entity is crucial to avoid unnecessary invasive procedures and to provide appropriate patient reassurance.

EADV CONGRESS
VIENNA
30 SEP - 3 OCT 2026

Abstract N°: 2025

Skin Bacteriome and Mycobiome in Mycosis Fungoides: Associations with Pruritus, Clinical Presentation, and PUVA Therapy

Magdalena Łyko*[1], Anita Brzoza[2], Joanna Maj[1], Łukasz Łacznański[2], Alina Jankowska Konsur[1]

[1] University Centre of General Dermatology and Oncodermatology, Wroclaw Medical University, Wroclaw, Poland
[2] Laboratory of Genomics and Bioinformatics, Hirszfeld Institute of Immunology and Experimental Therapy, Polish Academy of Sciences, Wrocław, Poland, Wroclaw, Poland

Introduction
Mycosis fungoides (MF), the most common cutaneous T-cell lymphoma subtype, is characterised by clonal T-cell infiltration of the skin. While bacterial dysbiosis has been reported in MF, integrated assessment of both the bacteriome and mycobiome, their associations with clinical features, and their response to phototherapy remain unexplored. This study aimed to characterise the skin bacteriome and mycobiome in MF and to evaluate the impact of psoralen plus ultraviolet A (PUVA) therapy.

Materials and Methods
Twenty-six patients with MF and 18 healthy controls were enrolled. Skin swabs from lesional and non-lesional sites were collected before and after PUVA therapy. Bacterial 16S rRNA (V3–V4) and fungal ITS1 amplicon sequencing was performed on an Illumina MiSeq platform. Alpha and beta diversity, differential abundance (ANCOM-BC2), and correlations between mycobiome diversity and pruritus severity (Numeric Rating Scale) were analysed using QIIME2 and R.

Results
The skin bacteriome was globally altered in MF, with significant compositional differences between both lesional and non-lesional patient skin and controls, consistent depletion of *Fusicatenibacter saccharivorans*, and progressive dysbiosis at advanced disease stages. The mycobiome exhibited an inverse pattern: compositional differences between lesional and non-lesional skin—driven by depletion of *Toxicocladosporium chlamydosporum* in lesional areas—but no divergence from controls. Fungal alpha diversity was strongly and positively correlated with pruritus severity in pre-treatment lesional skin (Shannon R = 0.816, $p = 0.007$); all correlations were abolished following PUVA. PUVA therapy induced kingdom-specific effects: partial bacteriome normalisation and resolution of the intra-patient mycobiome gradient.

Conclusions
Mycosis fungoides was associated with distinct, kingdom-specific alterations in the cutaneous microbiome, with broader bacteriome differences relative to controls and more localised mycobiome differences between lesional and non-lesional skin. The observed association between fungal alpha diversity and pruritus severity, and its absence after PUVA therapy, suggests a potential relationship between the skin mycobiome and symptom burden. These findings should be considered exploratory and warrant validation in larger longitudinal studies.

EA DV CONGRESS
VIENNA
30 SEP - 3 OCT 2026

Abstract N°: 2026

Major visceral dissemination in classical Kaposi sarcoma: a “pseudo-epidemic” profile

Maroua Berdjane*[1], mira chikhaoui[1], Baya Moussaoui[1], Houria Sahel[1]

[1] Dermatology Department, Bab El Oued University Hospital, Algiers, Algeria

Introduction

Classic Kaposi sarcoma (KS) is an angioproliferative disorder typically affecting elderly patients from Mediterranean regions. It usually follows an indolent course limited to the skin, with visceral involvement being rare (<10%). We report an unusual case mimicking an epidemic (HIV-related) profile, with triple dissemination involving skin, mucosa, and internal organs.



Involvement of the hard palate and the face

Case Presentation

A 74-year-old Algerian man, HIV-seronegative, presented with a one-year history of diffuse papulo-nodular angiomatous lesions involving the face, trunk, and limbs, associated with hard palate involvement and right blepharo-conjunctivitis. The subsequent onset of dry cough, melena, and refractory anemia prompted staging investigations. Laboratory tests revealed hemoglobin at 8 g/dL.Chest CT scan showed peribronchovascular nodules. Bronchoscopy revealed violaceous macular lesions of the upper trachea. Upper gastrointestinal endoscopy identified reddish-purple gastric lesions. Histopathological examination of cutaneous and gastric biopsies confirmed KS, with positive HHV-8 immunostaining.Given the extensive visceral involvement, systemic chemotherapy with paclitaxel was initiated, leading to partial clinical improvement after the first cycle.
This case highlights the heterogeneity of classic Kaposi sarcoma. While the disease is usually cutaneous and indolent in elderly Mediterranean patients, our case exhibited an aggressive “pseudo-epidemic” phenotype with rapid cutaneo-mucosal and visceral dissemination.Hard palate involvement should be considered a marker of severe disease, warranting systematic screening for deep organ involvement. In this patient, respiratory and gastrointestinal symptoms revealed tracheopulmonary and gastric disease, consistent with stage IV KS.Such visceral dissemination in an immunocompetent elderly patient underscores the role of immunosenescence, which may facilitate uncontrolled replication of HHV-8 and progression to disseminated disease.Liposomal doxorubicin

is the standard treatment for visceral KS; however, due to unavailability, paclitaxel was used as an alternative.

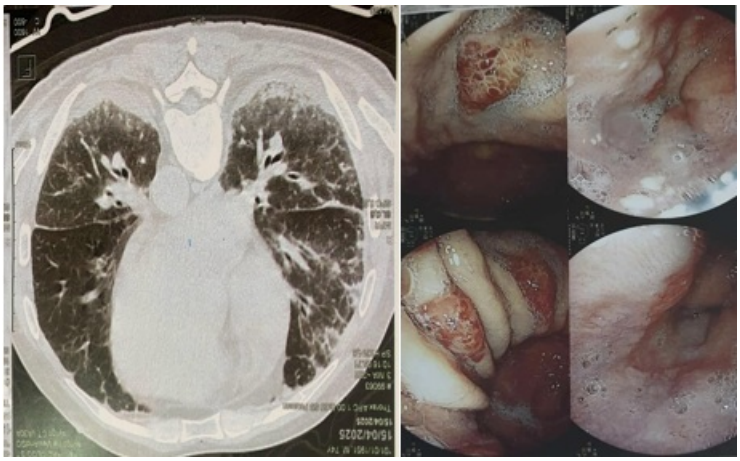

Pulmonary and gastrointestinal involvement

Conclusion

Although classically indolent and skin-limited, classic Kaposi sarcoma can rarely evolve into aggressive disseminated forms with visceral involvement in elderly patients. This justifies systematic evaluation and early therapeutic management.

EA DV CONGRESS
VIENNA
30 SEP - 3 OCT 2026

Abstract N°: 2033

Facial and periocular primary cutaneous diffuse large B-cell lymphoma with systemic progression and immunophenotypic shift at relapse: a case report

Erandy Alicia Salcedo Elguea*[1], NANCY GABRIELA MÉNDEZ VIZCARRA[2], Pablo Garcia Chavez[1]

[1] ISSSTE General Hospital, Juarez City, Mexico

[2] Dermatos Skin Clinic, Juarez City, Mexico

Introduction

Primary cutaneous B-cell lymphomas (PCBCLs) are rare extranodal lymphomas, representing approximately 25–30% of all primary cutaneous lymphomas, with an estimated incidence of 3.1 cases per million person-years. Among these, primary cutaneous diffuse large B-cell lymphoma (PCDLBCL) is the most aggressive subtype, with a 5-year overall survival of 20–50%. Facial and periorbital involvement is exceedingly rare, and immunophenotypic divergence between initial and relapse biopsies has rarely been documented.

Case Presentation

A 78-year-old woman with a history of breast cancer (30 years prior), arterial hypertension, and hypothyroidism presented with a 1-year history of an asymptomatic violaceous macule on the left cheek, progressively enlarging to involve the lower eyelid, retroauricular region, and ipsilateral neck. Physical examination revealed a localized dermatosis affecting the left hemiface and lateral neck, involving the cheek, jawline, lower eyelid with extension toward the outer canthus, characterized by multiple erythematoviolaceous, indurated plaques ranging from 2 to 12 cm in greatest diameter, consistent with deep dermal infiltration (Fig. 1A–B). Perilesional telangiectasias and ecchymotic discoloration of the periorbital skin were noted. No regional lymphadenopathy or systemic signs were identified. Dermoscopy revealed homogeneous erythematoviolaceous areas with whitish septa and branching serpentine vessels, raising suspicion for a cutaneous lymphoproliferative process (Fig. 1C).

Skin biopsy (2023) confirmed DLBCL (Fig. 1D). Immunohistochemistry (IHC) showed a CD10−/BCL6+/MUM1− profile, consistent with a GCB immunophenotype per the Hans algorithm; BCL2 and Ki-67 were not performed. PET/CT confirmed skin-confined disease. Given cardiac contraindication to anthracyclines, the patient received rituximab combined with cyclophosphamide, vincristine, and prednisone (8 cycles), achieving complete remission.

Eighteen months later, new lesions developed on the left lower eyelid. Physical examination revealed a focal erythematoviolaceous, indurated plaque on the left lower eyelid with perilesional ecchymotic discoloration and prominent branching telangiectasias on the adjacent cheek, in the same anatomical distribution as the primary lesion. Dermoscopy of the relapse lesion revealed comma-shaped vessels on a white structureless background and a homogeneous erythematoviolaceous area with preserved follicular openings, a pattern distinctly different from the serpentine vessels and erythematoviolaceous areas with whitish septa observed in 2023.

Repeat biopsy (2025) revealed DLBCL recurrence with a predominance of centroblasts and immunoblasts. IHC showed marked phenotypic evolution: CD20 95% (+++), BCL6 90% (+++), and de novo MUM1 75% (+++), representing a shift from GCB to non-GCB immunophenotype (CD10−/BCL6+/MUM1+) per the Hans algorithm — potentially compatible with PCDLBCL leg type, a possibility that could not be confirmed without BCL2 and Ki-67. PET/CT (2025) now demonstrated a subcentimeter left hilar lymph node (SUVmax 5.4) and a 1.3 × 1.0 cm hepatic segment V lesion (SUVmax 8.3), representing systemic progression.

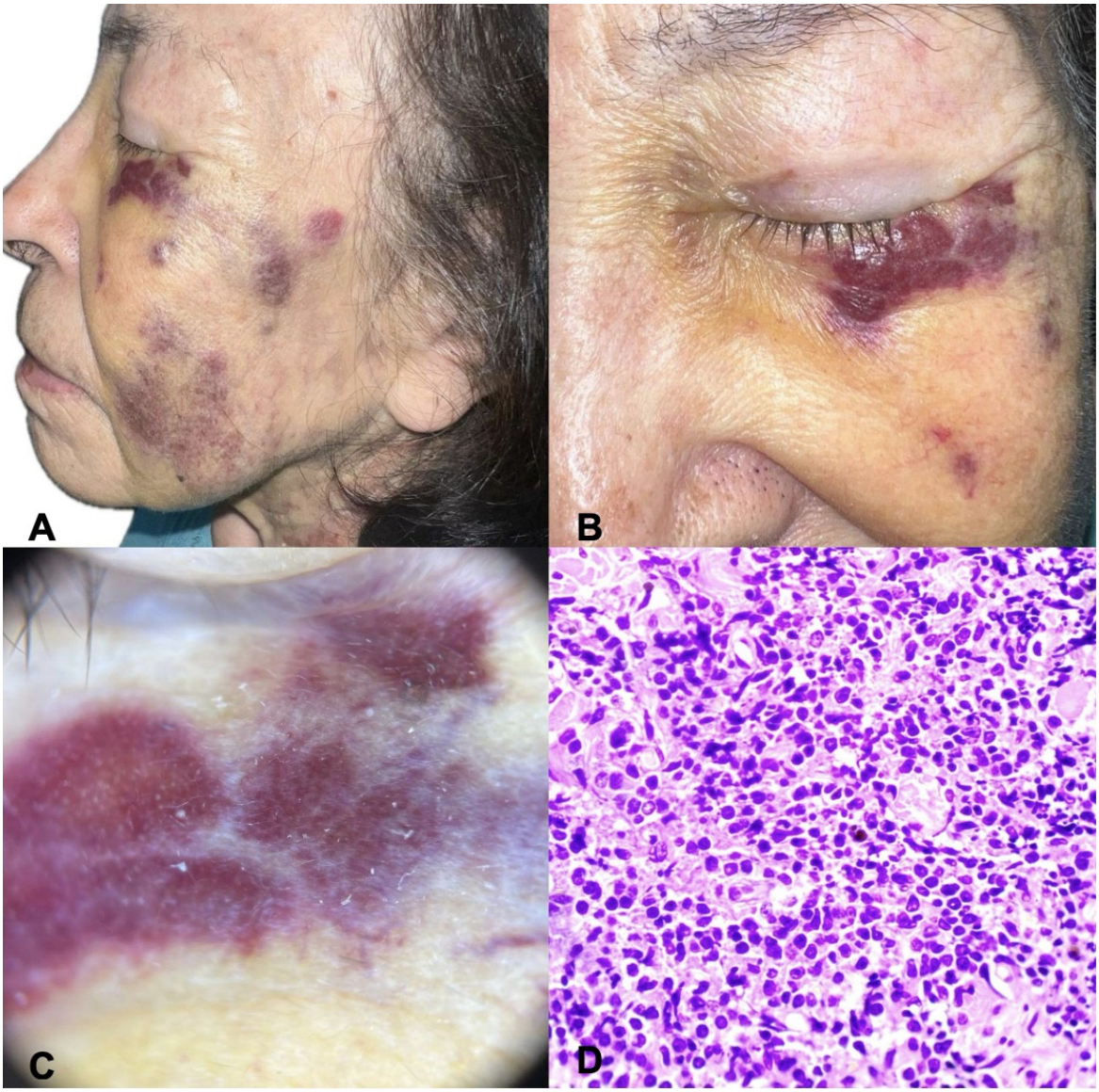

Initial presentation (2023). (A) Erythematoviolaceous indurated plaques with satellite lesions and perilesional telangiectasias on the left cheek and jawline. (B) Indurated erythematoviolaceous plaque on the left lower eyelid with ecchymotic discoloration and extension toward the outter canthus. (C) Dermoscopy: homogeneous erythematoviolaceous areas with whitish septa and serpentine vessels. (D) Skin biopsy (H&E ×400): diffuse infiltrate of large atypical B-lymphocytes with prominent nucleoli and atypical mitoses, consistent with DLBCL.

Conclusion

This case illustrates three key learning points: (1) PCDLBCL may present at atypical facial and periorbital sites, and progressive indurated facial plaques in elderly patients warrant early biopsy regardless of anatomical location; (2) immunophenotypic shifts between diagnosis and relapse — including BCL6 upregulation and de novo MUM1 expression — may reflect clonal evolution under therapeutic pressure, and a complete IHC panel (including BCL2 and Ki-67) is essential at both initial diagnosis and relapse; (3) full PET/CT restaging is indispensable at relapse even when the clinical presentation appears locally confined, as systemic progression may occur silently and fundamentally alters prognosis and management.

EADV CONGRESS
VIENNA
30 SEP - 3 OCT 2026

Abstract N°: 2040

Implementing a See-and-Treat dermatology service: treatment outcomes for cutaneous squamous cell carcinoma.

Anthoula Efstathiadou*[1], Kellen Beck-Sander[1], Jonathan Sutton[1], Annabel Morton[1], Myrto Kastrisiou[1], Roshni Simmonds[2], Charles Mitchell[1]

[1] Dermatology Department, Portsmouth Hospitals University NHS Trust Dermatology Centre, St Mary's Community Health Campus, Milton Rd, Portsmouth, UK, PO3 6AD, Portsmouth, United Kingdom
[2] Pharmacy and Biomedical Science, University of Portsmouth, School of Medicine, St Michael's Building, White Swan Road, Portsmouth, UK, PO1 2UP, Portsmouth, United Kingdom

Introduction
Cutaneous malignancies are of the few malignancies where same-day diagnosis and treatment is feasible, however whether rapid intervention improves patient outcomes remains unclear. Our aim was to review if a same-day diagnosis and treatment approach of possible cutaneous squamous cell carcinoma (cSCC) cases has any effect on early-stage diagnosis compare to standard practice.

Materials and Methods
Our department introduced 'See-and-Treat' (S&T) clinics (same-day review and excision of suspected cutaneous cancers) in January 2023. 98 'same day' and 324 'different day' cases of cSSC were retrospectively identified and compared for histopathological staging and cancer grading, as per the 2020 BAD cSCC management guidelines.

Results
Both risk classification approaches demonstrated the same effect; pathological staging was lower in 'same day' compared to 'different day' cases (4% vs 10% diagnosed as pT3, p-value=0.1805), as was the cancer grading (5% vs 9% graded as very high risk, p-value=0.2612).

Conclusions
Our findings are of interest to other dermatology services considering the introduction of aS&T approach, as its overall benefits for patients and the department are important factors to consider when providing this type of service.

EADV CONGRESS
VIENNA
30 SEP - 3 OCT 2026

Abstract N°: 2046

Actinic Keratosis as a Dynamic Premalignant Spectrum: Insights into Progression Toward Cutaneous Squamous Cell Carcinoma

Diana Dirzu*[1], Mihaela Cojocaru[1], Georgiana Marin[1], Roxana Diaconu[1], Daciana Elena Branisteanu[1]

[1] Dermatology Unit, Railway Clinical Hospital, Iasi, Romania, Iasi, Romania

Introduction
Actinic keratosis (AK) is a premalignant cutaneous lesion induced by chronic ultraviolet radiation exposure, characterized by atypical keratinocyte proliferation and a variable risk of progression to cutaneous squamous cell carcinoma (cSCC). Early identification of clinical and dermatoscopic signs suggestive of malignant transformation is essential for timely therapeutic intervention.

Materials and Methods
This presentation aims to provide a comprehensive clinical, dermatoscopic and histopathological analysis of AK, with emphasis on intraepidermal progression patterns and early indicators of transition to invasive cSCC.
A descriptive analysis of AK was performed, integrating clinical presentation, dermatoscopic features and histopathological correlates. Particular attention was given to grading severity, identifying high-risk features for malignant transformation, and reviewing current diagnostic and therapeutic approaches.

Results
AK predominantly affects elderly patients with fair phototypes and a history of cumulative sun exposure. Clinically, lesions range from subtle erythematous scaly macules to infiltrated hyperkeratotic plaques. Dermatoscopically, severity correlates with features such as erythematous pseudonetwork, “strawberry” pattern, and structureless white areas with keratotic follicular plugs. Progression to cSCC may occur without sequential transition through all histological grades. Warning signs of malignant transformation include rapid lesion growth, induration, persistent ulceration, spontaneous bleeding, and vascular pattern changes. Management is individualized based on lesion number, severity, and localization, and includes lesion-directed therapies, field-directed topical treatments, photodynamic therapy and excisional biopsy in suspicious cases.

Conclusions
AK represents a premalignant condition with unpredictable evolution toward invasive cSCC. Careful clinical and dermatoscopic monitoring enables early detection of invasive transformation and prompt initiation of appropriate treatment. Preventive strategies, particularly photoprotection remain essential in reducing both incidence and progression.

EA DV CONGRESS
VIENNA
30 SEP - 3 OCT 2026

Abstract N°: 2053

Beyond chemotherapy in Kaposi sarcoma: real-world evidence for immunotherapy and pomalidomide from a multicentre cohort

Stefania Kokkali[1], Ioannis-Alexios Koumprentziotis[2], Vaia Mentesidou[3], Eleni-Panagiota Chamalidou[4], Michaella Plaka[2], Anna Boulouta[5], Konstantinos Lallas[6], Panagiotis Papanastasopoulos[7], Evdoxia Panou[2], Angeliki Befon[2], Anastasios Kyriazoglou[5], Alexander Stratigos[2], Vasiliki Nikolaou*[2]

[1] Hippokratio General Hospital of Athens, Oncology Unit, 2nd Department of Medicine, Athens, Greece

[2] 1st Department of Dermatology and Venereology, Andreas Sygros Hospital, National and Kapodistrian University of Athens, Medical School of Athens, Athens, Greece

[3] Department of Medical Oncology, Papageorgiou Hospital, Aristotle University of Thessaloniki, School of Health Sciences, Faculty of Medicine, Salonica, Greece

[4] First Propaedeutic Department of Internal Medicine, Aristotle University of Thessaloniki, AHEPA University Hospital, Thessaloniki, Greece

[5] Attikon University Hospital, 2nd Propaedeutic Department of Medicine, Athens, Greece

[6] Department of Medical Oncology, Papageorgiou Hospital, Aristotle University of Thessaloniki, Thessaloniki, Greece

[7] Olympion General Clinic, Patras, Greece

Introduction

Kaposi sarcoma (KS) is an angioproliferative neoplasm driven by human herpesvirus-8 (HHV-8), encompassing distinct clinical subtypes including classic (sporadic) and AIDS-related disease. Pegylated liposomal doxorubicin (LD) has long been established as the standard systemic treatment; however, the optimal management of relapsed or refractory disease remains insufficiently defined. Herein, we present a multicentre retrospective analysis of systemic therapies in patients with classic and AIDS-related KS.

Materials and Methods

This retrospective multicentre study included adult patients with histologically confirmed KS treated with systemic therapies between January 2010 and December 2024 across five tertiary referral centres in Greece. Information on patient demographics, systemic treatments, treatment sequences, response outcomes, adverse events (AEs), and survival status was collected.

Results

A total of 139 patients with KS (94 cKS, 45 AIDS-related KS) were included. Male predominance was observed in both groups (77.7% vs 93.3%, p=0.018). Patients with cKS were older (median [IQR] 75.5 [68.5–82] vs 41.5 [31–51] years, p<0.001). Systemic involvement at diagnosis was uncommon (10.8%), while lymph node involvement was more frequent in AIDS-related KS (20% vs 5.3%, p=0.019). LD was used as first-line therapy in 94.7% of cKS patients and all AIDS-related KS patients (with HAART). The overall response rate (ORR) was 96.2%, with higher complete response (CR) rates in AIDS-related KS (64.4% vs 46.1%, p=0.04). No progressive disease (PD) was observed, while 3.7% had stable disease (SD). LD rechallenge was performed in 60 patients, achieving CR in 35%, with consistent activity across treatment lines. Median time to retreatment was 8, 9, 19.5, and 10 months in first-,

second-, third-, and fourth-line settings, respectively. Ten cKS patients were treated with pomalidomide across multiple treatment lines with an ORR of 40%, with one patient achieving CR, three partial response (PR), two (SD) and one suffering from (PD). Regarding immunotherapy, all five patients that received pembrolizumab, at a dose of 200 mg infused every three weeks, responded to treatment with three of them achieving CR. Other treatments utilized for cKS included interferon (n=8), vinblastine (n=1) bleomycin (n=2), paclitaxel (n=5) achieving PR in all cases but one SD and one PD due to interferon. At last follow-up, 73.3% of AIDS-related KS patients were alive without disease compared with 31.9% of patients with cKS ($p < 0.00001$). In total, 11 (7.9%) patients died during follow-up, either due to disease related or other causes, all belonging in the cKS subgroup.

Conclusions

LD remains the standard first-line therapy for cKS, with effective rechallenge in relapsing disease. In patients with limited response duration or contraindications to further anthracyclines, alternative therapeutic classes may be prioritized. The current findings highlight the urgent need for prospective, comparative studies to define the optimal sequencing of available agents and improve long-term outcomes and quality of life for patients with cKS.

EADV CONGRESS
VIENNA
30 SEP - 3 OCT 2026

Abstract N°: 2055

"Primary Cutaneous Diffuse Large B-Cell Lymphoma, Leg Type: An Aggressive Masquerader with a Lethal Course"

Mona Sharma*[1]

[1] ESIPGIMSR NEW DELHI, DELHI, India

Introduction

Primary cutaneous diffuse large B-cell lymphoma, leg type (PCDLBCL-LT) is a rare, aggressive primary cutaneous lymphoma with poor prognosis and variable clinical presentation, often posing diagnostic challenges.

Case Presentation

A 54-year-old male with diabetes and hypertension presented with multiple asymptomatic papulonodular lesions over the left leg for 1.5 months. Examination revealed non-tender nodules with scaling, crusting, and satellite lesions. Systemic evaluation was unremarkable. Differentials included cutaneous metastasis, angiosarcoma, and deep fungal infection. Histopathology showed a dense dermal infiltrate of atypical lymphoid cells extending into subcutis without epidermotropism. Immunohistochemistry was positive for CD20, CD79a, PAX5, and LCA, confirming B-cell lineage, consistent with PCDLBCL-LT. FDG-PET showed no systemic involvement.

Management and Outcome:

The patient was treated with R-CHOP chemotherapy, showing initial clinical improvement; however, he succumbed to sepsis after four cycles.

Conclusion

PCDLBCL-LT accounts for a minority of primary cutaneous lymphomas but is the most aggressive subtype. Diagnosis relies on clinicopathological and immunohistochemical correlation. Management is extrapolated from systemic diffuse large B-cell lymphoma, with R-CHOP as standard therapy.

Conclusion:

This case underscores the aggressive course and diagnostic complexity of PCDLBCL-LT. Early recognition and prompt treatment are crucial, though outcomes remain guarded.

EADV CONGRESS
VIENNA
30 SEP - 3 OCT 2026

Abstract N°: 2060

Erysipeloid Cutaneous Carcinomatous Lymphangitis: A Misleading Form of Breast Cancer Cutaneous Metastasis

Wijdane tebbaai*[1], BENDAOUD LEYLA[1], ABOUDOURIB MERIEME[1], HOCAR OUAFA[1], AMAL SAID[1]

[1] Department of Dermatology, Arrazi Hospital, Mohammed VI University Hospital, Marrakech Research Laboratory in Biosciences, Marrakech, Morocco

Introduction

Cutaneous carcinomatous lymphangitis is a rare manifestation of cutaneous metastases, characterized by the invasion of dermal lymphatic vessels by tumor emboli. It occurs most frequently in advanced breast carcinomas and may clinically mimic infectious dermohypodermitis such as erysipelas, leading to diagnostic delay. Its identification is essential because it reflects neoplastic progression and is associated with a poor prognosis.

Case Presentation

A 56-year-old woman with a 10-year history of hormone receptor-positive, HER2-negative invasive ductal carcinoma of the left breast, previously treated with radiochemotherapy and hormone therapy, presented with an extensive inflammatory plaque involving the entire left upper limb, associated with painful edema, induration, and peau d'orange appearance. Despite well-conducted empiric antibiotic therapy, no clinical improvement was observed. The patient also developed suppurative nodular lesions over a scarred area of the left breast evolving for several months. Laboratory investigations showed a marked inflammatory syndrome with elevated CRP and ESR (>140 mm) contrasting with low procalcitonin levels, suggesting a non-infectious process. Severe normocytic normochromic anemia, hyperferritinemia, and markedly elevated tumor markers (CA 15-3, CA 19-9, and CEA) were also noted. Doppler ultrasonography demonstrated diffuse soft tissue infiltration without abscess formation, associated with pathological axillary lymphadenopathy and no evidence of deep venous thrombosis. Skin biopsy revealed massive dermal infiltration by a poorly differentiated carcinomatous proliferation arranged in glandular structures, cords, tubules, and trabeculae, confirming cutaneous metastatic involvement from breast carcinoma.
Cutaneous carcinomatous lymphangitis (carcinoma erysipeloides) is a rare form of cutaneous metastasis caused by tumor spread through dermal lymphatic vessels, leading to lymphatic obstruction and a misleading pseudo-infectious inflammatory presentation. Breast cancer is one of the most frequent underlying malignancies.
Clinically, it typically presents as an erythematous, warm, infiltrated, and painful plaque associated with edema and peau d'orange, closely mimicking erysipelas or cellulitis, particularly in patients with post-therapeutic lymphedema. This resemblance frequently leads to diagnostic delay and inappropriate antibiotic treatment.
Several studies have highlighted the polymorphic nature of cutaneous metastatic lesions and their ability to imitate common inflammatory dermatoses. Persistent erysipeloid lesions unresponsive to antibiotics, especially in patients with a history of breast carcinoma, should therefore raise suspicion for metastatic disease. Biological findings may be misleading, as elevated CRP and ESR can mimic infection; however, low procalcitonin levels, absence of microbiological documentation, and evidence of tumor progression constitute important diagnostic clues. Imaging usually demonstrates diffuse soft tissue infiltration without abscess formation, sometimes associated with pathological lymphadenopathy.
Definitive diagnosis relies on histopathological examination, showing dermal carcinomatous infiltration and/or lymphatic tumor emboli. Prognostically, cutaneous carcinomatous lymphangitis generally reflects advanced metastatic disease and is associated with poor outcomes, with reported median survival of only a few months after diagnosis.

Early recognition and prompt skin biopsy are therefore essential to avoid diagnostic delay and allow rapid oncologic reassessment.



Conclusion

Cutaneous carcinomatous lymphangitis is an important dermatological warning sign and should be suspected in

any persistent or atypical erysipeloid dermatitis occurring in a patient with a history of breast carcinoma. Early skin biopsy is essential to avoid diagnostic and therapeutic delays. This entity generally reflects advanced neoplastic progression and requires prompt oncological reassessment.

EADV CONGRESS
VIENNA
30 SEP - 3 OCT 2026

Abstract N°: 2071

Features of high-risk cutaneous squamous cell carcinoma in solid organ transplant recipients and their association with the disease latency period

Kendall Trieglaff*[1], Rachel Tao[1], Nicole Boswell[1], Brandon Calley[1], Melanie Clark[1]

[1] Medical College of Wisconsin, Milwaukee, United States

Introduction

Cutaneous squamous cell carcinoma (cSCC) is the most common skin cancer in solid organ transplant (SOT) recipients. SOT recipients are uniquely susceptible to cSCC due to prolonged exposure to immunosuppressive medications and failure of the suppressed immune system to target malignant cells. High-risk cutaneous squamous cell carcinoma (hr-cSCC) is of significant clinical concern due to increased risk of local recurrence, metastasis, and mortality. Due to these risks, it is important to better understand high-risk features and their association with the disease latency period from SOT to development of hr-cSCC in the adult population.

Materials and Methods

An Institutional Review Board approved retrospective chart review was conducted on patients identified with hr-cSCC from Mohs Micrographic Surgery logs, biopsy logs, and hospital tumor board records screened from 1/1/2007 - 4/18/2023. Inclusion criteria were patients older than 18 years of age, American Joint Committee on Cancer – 8 criteria for T3-T4 staging and/or BWH criteria for T2b-T3 staging. Patients were excluded if they were younger than 18 years of age, did not meet high risk criteria, lacked pathology records, or had absent clinical follow up. From this cohort, SOT recipients were identified.

The primary aim for the statistical analysis was to identify patient demographics and tumor features in relation to the disease latency period (date of transplant to date of tissue diagnosis of hr-cSCC). Univariate linear regression analysis included demographic information, tumor characteristics, and immunosuppressive medication exposure. Multivariable linear regression analysis was performed on variables found to be significant on univariate analysis.

Results

Within a cohort of 160 adult patients with hr-cSCC, 24 SOT patients were identified representing 30 hr-cSCCs. There were seventeen kidney, three heart, two lung, and four liver transplant patients. Two patients received more than one organ transplant. The average age at transplant was 51 years old and the average age at hr-cSCC diagnosis was 65 years old. The average disease latency period was 13.8 years. During the latency period, patients were exposed to the following immunosuppressive medications reported as percentages: tacrolimus (88%), prednisone (88%), azathioprine (25%), everolimus (17%), cyclosporine (13%), and sirolimus (8.3%).

On univariate linear regression analysis, SOT recipient variable immunosuppressant exposure was not associated with a change in the latency period. Significant variables on univariate analysis were further studied on multivariable linear regression analysis and included: number of transplants, depth of the tumor >6mm/beyond subcutaneous fat, and metastasis to lymph nodes at time of diagnosis. With all other variables being held constant in multivariable linear regression analysis, the depth of the tumor >6mm/beyond subcutaneous fat was significantly associated with a shorter latency period by 14 years (p-value

0.02). The number of transplants and metastasis to lymph nodes at the time of diagnosis was not associated with a significant change in the latency period.

After receiving Mohs surgery, the SOT group experienced four instances of local recurrence, two instances of lymph node metastasis, and one instance of distant metastasis. Six patients were deceased at time of chart review, and two deaths were related to the patients' hr-cSCC.

Table 1: Demographics, Transplant Organ, and Immunosuppressant Type During Latency Period in SOT Recipients with hr-cSCC

Demographics	
White/Caucasian, number (%)	24 (100)
Mean Age at Transplant, years	51
Mean Age at HR-CSCC Diagnosis, years	65
Mean Latency Period from SOT to HR-SCC Diagnosis, years	13.8
Transplant Organ, number (%)	
Kidney	17 (71)
Heart	3 (13)
Lung	2 (8.3)
Liver	4 (17)
>/= 2 Organs Transplanted	2 (8.3)
Immunosuppressant Type During Latency Period, number (%)	
Tacrolimus	21 (88)
Prednisone	21 (88)
Azathioprine	6 (25)
Everolimus	4 (17)
Cyclosporine	3 (13)
Sirolimus	2 (8.3)

Percentages based on SOT recipients with hr-cSCC (n=24)

Conclusions

In a cohort of hr-cSCC patients who were also SOT recipients, depth of the tumor >6mm/beyond subcutaneous fat was significantly associated with a shorter disease latency period. Intrinsic tumor biology related to acute immunosuppression post-transplant may play a more significant role in the latency period than demographic factors and specific immunosuppressant exposure. This data suggests that certain high-risk features may present sooner after SOT, potentially underscoring the importance of close surveillance post-transplantation in this high-risk population.

EADV CONGRESS
VIENNA
30 SEP - 3 OCT 2026

Abstract N°: 2073

Eccrine poroma in the hand: A challenge in the differential diagnosis of acral lesions

Veronica Martinez Garcia*[1], Dolores Maribel Arellano Vivero[1], Lucia Achell Nava[1], Claudia Jessica Espinoza Hernandez[2]

[1] Centro Medico Nacional "20 de Noviembre" ISSSTE, Mexico City, Mexico
[2] Hospital General "Dr Manuel Gea González", Mexico City, Mexico

Introduction

Eccrine poroma is a benign adnexal tumour derived from the acrosyringium. It typically presents as a solitary pigmented or non-pigmented lesion, clinically appearing as a sessile, skin-coloured, red, or pink nodule. The classical locations described are the soles and lateral aspects of the feet; however, lesions have also been reported on the head, neck, scalp, external auditory canal, chest, abdomen, proximal extremities, and hands. These tumours are usually smaller than 3 cm in diameter and may also occur in a pigmented form, with a predilection for non-acral sites. Histologically, eccrine poromas are well-circumscribed tumours composed of cords and broad bands of uniform basaloid cells extending from the undersurface of the epidermis into the dermis.

Case Presentation

A 53-year-old male mechanic with no significant past medical history was evaluated for a localized dermatosis involving the left palm, consisting of a 1-cm pigmented, dome-shaped neoformation of dark brown colour. Dermoscopic examination revealed a pigmented, dome-shaped lesion with pinpoint vessels in its central portion. The patient reported a 5-year history of the lesion, without pain or other associated symptoms; however, he described recurrent trauma to the area with occasional bleeding. An excisional biopsy was performed, revealing an epithelial tumour confined to the epidermis and superficial dermis. The stroma showed thin collagen bundles with interstitial oedema and capillary proliferation. Surgical margins were free of tumour.

Conclusion

Eccrine poromas arising in atypical locations may represent a diagnostic challenge. Clinically, these tumours may present as pigmented or non-pigmented lesions; however, the presence of pinpoint vessels and a keratotic surface is uncommon. Based solely on clinical examination, the main differential diagnoses in this case included irritated seborrhoeic keratosis and verruca vulgaris. This case highlights the importance of careful clinical evaluation, detailed history taking, and clinicopathological correlation, particularly in the diagnosis of rare adnexal tumours. Furthermore, the pigmented variant accounts for approximately 17% of all eccrine poromas, which may contribute to underdiagnosis or misdiagnosis. Although eccrine poromas are benign neoplasms, up to 18% may undergo malignant transformation into eccrine porocarcinoma, emphasizing the importance of early diagnosis and treatment.

EADV CONGRESS
VIENNA
30 SEP - 3 OCT 2026

Abstract N°: 2074

Rhinophyma Associated Cutaneous Angiosarcoma Mimicking Squamous Cell Carcinoma: The Added Value of High-Frequency Ultrasonography in a Diagnostic Pitfall

Alperen Ozmen*[1], Ozlem Ozbagcivan[1]

[1] Dokuz Eylul University Hospital, Department of Dermatology and Venereology, Izmir, Türkiye

Introduction

Cutaneous angiosarcoma (CAS) is a rare, aggressive vascular malignancy with a dismal 5-year survival rate ranging from 10% to 35%. Chronic lymphedema is a well-established predisposing condition (Stewart-Treves syndrome), likely through impaired immune surveillance, tissue hypoxia, and sustained angiogenic stimulation within an edematous microenvironment. Rhinophyma is characterized by progressive sebaceous gland hyperplasia, fibrosis, and disruption of local lymphatic drainage. However, only a few cases of CAS arising in association with rhinophyma have been reported, making this an underrecognized diagnostic pitfall. We present a rare case of rhinophyma-associated CAS clinically mimicking SCC and highlight the added diagnostic value of HFUS beyond dermoscopic evaluation in pre-biopsy assessment.

Case Presentation

A 77-year-old male was referred to our clinic by the Plastic Surgery department with a pre-diagnosis of SCC on a background of rhinophyma, scheduled for total excision and reconstruction. The patient reported a 4-year history of a nasal mass that had become friable and hemorrhagic over the last two months. Physical examination revealed a large, livid-erythematous ulcerated nodule on the left alar wing, causing rightward deviation of the nose, superimposed on a phymatous base. Firm infiltration extending into the left malar region suggested impaired lymphatic drainage.

Dermoscopic evaluation showed yellow follicular plugs (consistent with rhinophyma), along with purple-red structureless areas with a bluish hue, shiny white structures producing a rainbow-like appearance, and complex polymorphic vascular patterns. Based on the clinical and dermoscopic findings suggestive of CAS, 20 MHz High-Frequency Ultrasonography (HFUS) was performed to further characterize the lesion and assess tumor depth. HFUS revealed a poorly demarcated, nodular lesion involving the dermis and extending into the hypodermis. The internal structure exhibited significant echogenic irregularities and inhomogeneity, while the periphery displayed a distinct hyperechogenic environment. Color Doppler imaging demonstrated intense low resistence arterial and venous internal vascularization within the lesion. Visualization of these deeper vascular structures beyond the penetration depth of dermoscopy strongly supported the diagnosis of CAS. An incisional biopsy subsequently confirmed the diagnosis.

Conclusion

Hemorrhage, ulceration or atypical livid discoloration within rhinophymatous tissue should raise suspicion for vascular malignancy, particularly because CAS may clinically mimic SCC, BCC, or amelanotic melanoma. Dermoscopy and HFUS appear to provide complementary diagnostic

information in this setting. Dermoscopy facilitates visualization of superficial vascular architecture and epidermal microstructures down to the level of the papillary dermis, whereas HFUS enables assessment of lesion depth, echogenicity, and vascular density within deeper dermal and subcutaneous compartments. Incorporation of HFUS into dermatologic oncology practice by dermatologists may improve pre-biopsy diagnostic accuracy in clinically ambiguous tumors.

EA DV CONGRESS
VIENNA
30 SEP - 3 OCT 2026

Abstract N°: 2081

Double-Negative (CD4-/CD8-) Folliculotropic Mycosis Fungoides with Negative TCR Clonality: A Diagnostic Challenge in Advanced Cutaneous Disease

Juan Ochoa-Bermudez[1], Sofia Martinez-Guerrero*[1], Natalia Nempeque-Benitez[2], Hector Jimenez[3], Elkin Peñaranda[3]

[1] Fundación Universitaria Sanitas., Bogotá, Colombia

[2] Universidad del Rosario, Bogotá, Colombia

[3] Centros Médicos Colsanitas., Bogotá, Colombia

Introduction

Mycosis fungoides (MF), the most common form of primary cutaneous T-cell lymphoma, typically exhibits a CD4+ phenotype. Double-negative (CD4-/CD8-) variants are rare and may pose significant diagnostic challenges, particularly in cases with inconclusive molecular studies. We report a case of advanced MF with a double-negative immunophenotype and negative T-cell receptor (TCR) clonality, emphasizing the importance of clinicopathological correlation.

Case Presentation

A 72-year-old woman presented with a 7-year history of generalized xeroderma and a 5-year progression to pruritic, scaling plaques refractory to multiple treatments, including topical corticosteroids, antibiotics, oral antihistamines, and narrowband UVB phototherapy. Her medical history included type 2 diabetes mellitus, rheumatoid arthritis, hypertension, dyslipidemia, venous insufficiency, and obesity.

Physical examination revealed extensive involvement of approximately 90% of the body surface area, characterized by erythematous-violaceous plaques, retiform hyperpigmented macules, and infiltrated tumors with well-defined borders, some exhibiting surface erosion. Lesions were symmetrically distributed over photoprotected areas, including the trunk, arms, and thighs, without clinically evident nodal or extracutaneous involvement. The modified Severity-Weighted Assessment Tool (mSWAT) score was 50 .

Laboratory evaluation showed no significant hematologic abnormalities. Flow cytometry revealed normal T- and B-cell populations, and TCR clonality studies were negative . Imaging studies demonstrated bilateral axillary lymphadenopathy without mediastinal or visceral involvement.

Initial skin biopsies suggested spongiotic and interface dermatitis; however, subsequent biopsies revealed epidermotropism of atypical lymphocytes with cerebriform nuclei, a dense dermal lymphoid infiltrate with folliculotropism, and >25% large atypical cells. Immunohistochemistry demonstrated positivity for CD2, CD3, and GATA3, with reduced expression of CD5 and CD7, and absence of CD4 and CD8 expression, consistent with a double-negative T-cell phenotype. CD30 was negative .

Multidisciplinary evaluation confirmed the diagnosis of advanced-stage MF with folliculotropic features. The disease was staged as IB (T2N0M0B1). Treatment with PUVA phototherapy combined with oral methoxsalen was initiated.

Conclusion

This case highlights a rare presentation of double-negative MF with negative TCR clonality, underscoring the

diagnostic complexity of atypical immunophenotypes. Despite inconclusive molecular findings, integration of clinical, histopathological, and immunophenotypic data enabled accurate diagnosis. Recognition of such variants is essential to avoid diagnostic delay and initiate appropriate management in advanced cutaneous lymphoma.

EADV CONGRESS
VIENNA
30 SEP - 3 OCT 2026

Abstract N°: 2090

Digital Papillary Adenocarcinoma of the Finger: A Deceptively Benign-Appearing Lesion Requiring Terminalisation

Sophie Stretch*[1], Parmis Vafapour[2], Samina Imran[2], Al-Achraf Khoriati[3], Thiagarajah Balamurugan[2]

[1] Glan Clwyd Hospital, Rhyl, United Kingdom
[2] Ashford and St Peter's NHS Foundation Trust, Chertsey, United Kingdom
[3] Royal Surrey NHS Foundation Trust, Guildford, United Kingdom

Introduction

Digital papillary adenocarcinoma (DPAc) is a rare malignant adnexal tumour of eccrine sweat gland origin, most commonly affecting the distal digits of middle-aged men. Despite often appearing clinically indolent, it carries significant risk of local recurrence and distant metastasis. We present a case of DPAc in a Caucasian man in his early 40s initially misdiagnosed as a benign giant cell tumour.

Case Presentation

The patient presented with a five-year history of a slowly enlarging, non-tender swelling on the ulnar border of the distal phalanx of the right index finger. He was otherwise fit and well, with no history of malignancy or immunosuppression. Ultrasound, X-ray, and MRI demonstrated a well-circumscribed vascular lesion without bony invasion or tendon involvement, favouring a benign diagnosis including giant cell tumour of tendon sheath or glomus tumour. Owing to the prolonged history and reassuring imaging appearances, the lesion was booked for non-urgent excision.

Excision in September 2024 revealed a superficial multinodular tumour. Histopathological examination demonstrated spiradenoma-like architecture transitioning into hypercellular epithelial nests and basaloid nodules with increased mitotic activity and architectural heterogeneity. Immunohistochemistry showed high MIB-1 proliferative activity with positivity for carcinoembryonic antigen (CEA) and epithelial membrane antigen (EMA), supporting eccrine differentiation. The tumour extended to the resection margin, and specialist dermatopathology review confirmed digital papillary adenocarcinoma.

The case was reviewed at the regional skin cancer multidisciplinary team meeting with tertiary centre input. Staging PET-CT and MRI brain demonstrated no metastatic disease. Given the positive margins and recognised risk of recurrence, the patient underwent terminalisation of the right index finger in January 2025 with resection of the distal and part of the middle phalanx. Histology confirmed complete excision with clear margins. He recovered well post-operatively and remains under ongoing dermatology surveillance with annual chest radiography.

Conclusion

This case highlights the diagnostic difficulty of DPAc and reinforces the importance of histopathological evaluation in apparently benign digital lesions. It also demonstrates that DPAc may follow a prolonged indolent course with reassuring radiological appearances, contributing to delayed diagnosis. Early multidisciplinary involvement is essential in guiding management of this rare malignancy, for which evidence-based treatment and surveillance protocols remain limited.

EADV Congress 2026, VIENNA
30 SEPTEMBER - 03 OCTOBER 2026
POWERED BY M-ANAGE.COM

EADV CONGRESS
VIENNA
30 SEP - 3 OCT 2026

Abstract N°: 2098

Retreatment with Total Skin Electron Beam Therapy in Cutaneous T-Cell Lymphomas: A Case Series

Laura Giménez Cuenca*[1], Alba Nácher Albiach[1], Amparo González Sanchís[1], Mariam Ibáñez Company[1], María Carmen García Mora[1], Carmen Cristina Amorós Pérez[1], Paola Antonini Bolumburu[1], Karla Patricia Javier González[1], María Josefa Lis Chulvi[1], María Esther Roselló Sastre[1], Daniel Blaya Imbernón[1], Malena Finello[1], Elena Pérez Zafrilla[1], Angel Gonzalez[1], Nadia Giner Cerdà[1], Dolla Logunova[1], Esther Díez Recio[1], Jorge Magdaleno[1]

[1] Consorcio Hospital General Universitario de Valencia, Valencia, Spain

Introduction
Total skin electron beam therapy (TSEBT) is effective in cutaneous T-cell lymphomas (CTCL), although relapses are frequent. Retreatment raises questions regarding its safety and efficacy. The aim of this study was to describe our real-world clinical experience.

Materials and Methods
We conducted a retrospective descriptive study of a series of four patients diagnosed with CTCL who had previously been treated with TSEBT and subsequently received a second course of total skin electron beam therapy at a tertiary referral center.

Clinical variables, interval between treatments, response, indication for retreatment, duration of response, and cumulative toxicity were collected.

Results
Four patients with CTCL who relapsed after an initial response to TSEBT were included. Retreatment with TSEBT was administered using radiation regimens adapted according to individual patient characteristics.

Clinical response was observed in most patients after retreatment, with significant improvement of cutaneous lesions.

Regarding safety, treatment was generally well tolerated, and adverse events were mainly mild and cutaneous.

Conclusions
Retreatment with TSEBT in patients with CTCL appears to be an effective and safe therapeutic option, capable of inducing new clinical responses after relapse. These findings reinforce the role of TSEBT not only as an initial treatment, but also as a reusable therapeutic tool within the sequential management of CTCL.

EADV CONGRESS
VIENNA
30 SEP - 3 OCT 2026

Abstract N°: 2103

Lymphomatoid Papulosis Type A/D in a Child – Diagnostic Challenges and Clinical Course

Zuzanna Pawlak*[1, 2], Wojciech Baran[1, 2]

[1] University Centre of General Dermatology and Oncodermatology, Wroclaw Medical University, Department of Dermatology, Wrocław, Poland
[2] Univeristy Hospital Wroclaw, Department of Dermatology, Wrocław, Poland

Introduction

Lymphomatoid papulosis (LyP) is a rare primary cutaneous CD30+ T-cell lymphoproliferative disorder characterized by a chronic, recurrent, yet typically benign clinical course. It predominantly affects adults, while paediatric cases are uncommon and may pose significant diagnostic challenges.

Case Presentation

We present the case of a 6.5-year-old boy with an unremarkable past medical history, who developed his first skin lesions in July 2022, after vacation in Italy. Initially, solitary necrotic, pruritic lesion surrounded by erythema was observed, raising suspicion of an infectious aetiology, including cutaneous anthrax. Extensive microbiological diagnostics, including bacterial and viral testing, were negative.

In the following months, the lesions became disseminated, presenting as recurrent erythematous papules with central necrosis, spontaneously resolving within several weeks and leaving scars. Imaging studies showed no evidence of systemic involvement or significant lymphadenopathy.

Histopathological examination revealed a dermal infiltrate composed of atypical CD30+ T lymphocytes. Based on clinicopathological correlation and immunophenotyping, a diagnosis of lymphomatoid papulosis was established —initially type A, and subsequently revised to type D with a cytotoxic (CD8+) phenotype upon further evaluation.

The patient remains under close dermatological and oncological follow-up without systemic treatment. Currently, recurrent but less severe skin lesions are observed.

Conclusion

This case highlights the diagnostic difficulties of LyP in paediatric patients, particularly in the early stages when the clinical presentation may mimic infectious or inflammatory dermatoses. Accurate diagnosis requires careful correlation of clinical, histopathological, and immunohistochemical findings. Type D LyP, which is rarely reported in children, may further raise concern for more aggressive lymphoproliferative disorders.
LyP should be considered in the differential diagnosis of recurrent necrotic skin lesions in children. Despite its generally benign course, long-term follow-up is essential due to the potential risk of associated or subsequent lymphoid malignancies.

EA DV CONGRESS
VIENNA
30 SEP - 3 OCT 2026

Abstract N°: 2110

First-Line ECP Plus Interferon-α in Sézary Syndrome: Survival Outcomes and Exploratory Prognostic Factors

Antonio Di Guardo*[1], Maria Pina Accetturi[1], Cristina Cristofoletti[1], Lorena Silvestri[1], Alessandra Frezzolini[1], Enrico Scala[1], Alessandro Monopoli[1], Maria Grazia Narducci[1]

[1] IDI-IRCCS, Istituto Dermopatico dell'Immacolata, "Sapienza" University of Rome, Rome, Italy

Introduction

Sézary syndrome (SS) is a rare, aggressive type of cutaneous T-cell lymphoma, characterized by the presence of malignant T lymphocytes, namely Sézary cells, in the peripheral blood and associated with an unfavorable prognosis. Clinically, patients typically present with erythroderma, diffuse skin involvement, alopecia, nail changes, and lymphadenopathy (Willemze R, et al. *Blood*. 2005; Scarisbrick JJ, et al.*J Clin Oncol.* 2015). Current treatment strategies for advanced SS include both skin-directed and systemic therapies, among which extracorporeal photopheresis (ECP), alone or in combination with biological response modifiers such as interferon-α (IFN-α), represents a widely adopted first-line option. However, outcomes remain heterogeneous, and clinically useful prognostic markers of durable benefit are still lacking.

Aims: To evaluate overall survival (OS) in a real-world cohort of patients with SS treated with first-line ECP plus IFN-α at a tertiary dermatology referral center in Italy, and to explore whether blood clonality and Sézary cell immunophenotypic features may be associated with significantly different survival outcomes.

Materials and Methods

We conducted a retrospective single-center survival analysis of 72 patients with SS treated in first line with ECP plus IFN-α between 2000 and 2023. OS was estimated using the Kaplan–Meier method. Time to next treatment was also explored as an additional real-world indicator of treatment durability. To investigate potential prognostic factors associated with divergent outcomes, patients were stratified into two groups according to OS. Variables related to circulating tumor burden, SS cells immunophenotype and hematological parameters were collected at diagnosis and during follow-up (F-UP). Tumor burden was assessed by blood clonality by flow cytometry (FACS) using TCR Vβ rearrangement repertoire kit (Beckman Coulter, Fullerton, CA) in combination with anti- CD3 and anti-CD4 antibodies. Alternatively, SS cells were identified based on their $CD3^{+}CD4^{+}CD49d^{-}CD26^{-}CD7^{-}$ immunophenotypic profile (Scala E, et al. *Haematologica*. 2010).

Results

Kaplan–Meier analysis of the overall cohort showed a median OS of 59 months, with a 5-year survival rate of 44.9% (Figure 1). Time to next treatment was explored as an additional real-world measure of treatment durability and clinical benefit over time. To better characterize this prognostic variability, patients were stratified according to extreme survival outcomes, identifying 13 long survivors (OS >80 months) and 13 poor survivors (OS <30 months). Comparative analyses of these subgroups are ongoing taking into consideration the blood tumor burden at the diagnosis and F-UP, expressed either as the percentage of TCR Vb+ T lymphocytes within total patient'CD4+ T cells or as the absolute number of SS cells recognized by their CD3+CD4+CD49d−CD26−CD7− expression pattern.

This exploratory approach aims to identify candidate biological markers potentially associated with durable

response and prolonged survival in a real-world setting.

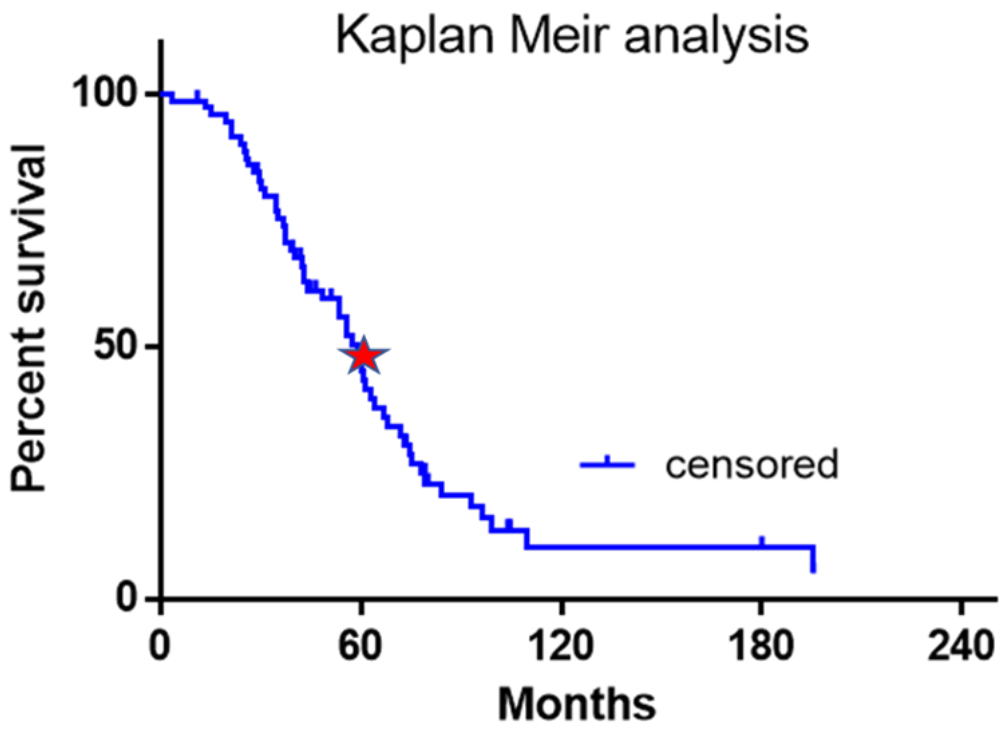

Figure 1. Retrospective survival analysis performed using the Kaplan–Meier estimator in a cohort of 72 patients with Sézary syndrome treated at IDI-IRCCS, Rome, with first-line ECP plus IFN-α between 2000 and 2023, showing a median overall survival of 59 months and a 5-year survival rate (60 months, marked with an X) of 44.9%.

Conclusions

In our real-world experience, first-line ECP combined with IFN-α was associated with meaningful long-term survival in patients with SS. Notably, the 5-year OS observed in our cohort appears to lie at the upper end of the range reported in previous studies (Gao C, et al. *Blood*. 2019; Ling YL, et al. *J Dermatolog Treat.* 2020), possibly reflecting the added value of management in a tertiary referral center, where earlier diagnostic recognition and timely treatment initiation may improve patient outcomes.

These findings further support the ongoing role of immunomodulatory therapy as a durable long-term strategy in the treatment of SS. The identification of long- and short-surviving subgroups also underscores the marked heterogeneity of the disease and supports the investigation of blood clonality and Sézary cell immunophenotype as candidate prognostic tools.

EADV CONGRESS
VIENNA
30 SEP - 3 OCT 2026

Abstract N°: 2113

Primary cutaneous non-Merkel neuroendocrine carcinoma: a diagnostic challenge

Carlo Gerbino*[1], Guido Valente[1], Rossana Tiberio[1]

[1] Dermatology Unit, S. Andrea Hospital, ASL Vercelli, Vercelli, Italy

Introduction

Cutaneous carcinomas with neuroendocrine differentiation are rare and heterogeneous neoplasms. Beyond Merkel cell carcinoma, these entities are poorly characterized and may pose significant diagnostic challenges, particularly in advanced and neglected presentations. We hereby report a case of a primary cutaneous giant, long-standing, poorly differentiated carcinoma with non-Merkel neuroendocrine differentiation, highlighting clinical and immunohistochemical features.

Case Presentation

An 83-year-old male was referred for evaluation of a progressively enlarging cutaneous lesion of at least one year’s duration. Due to severe anxiety and depression, the patient had not sought medical attention, resulting in marked tumor progression. Clinical examination revealed a large ulcerated and exophytic tumor on the left shoulder, measuring approximately 6–8 cm in diameter, with necrosis, hemorrhagic crusting, and malodorous exudate. Multiple perilesional nodules suggestive of in-transit metastases and ipsilateral lymphadenopathy were observed. A biopsy was performed at the tumor margin.

Histopathological examination showed a poorly differentiated carcinoma with extensive ulceration and necrosis. Immunohistochemistry demonstrated positivity for synaptophysin, β-catenin, cytokeratin 7, and Ber-EP4, with negativity for cytokeratin 20, thyroid transcription factor-1, S100, p63, cytokeratin 5/6, epithelial membrane antigen, and CDX2. The immunophenotype supported a diagnosis of poorly differentiated primary cutaneous carcinoma with neuroendocrine differentiation not consistent with Merkel cell carcinoma. Staging with positron emission tomography and total-body computed tomography excluded an extracutaneous primary neuroendocrine tumor, showing only ipsilateral axillary lymphadenopathy without focal lesions in major organs. Multiple osseous lesions consistent with metastases were detected, involving the left iliac wing, sacrum, lumbar (L3), thoracic and cervical vertebrae, and ribs. Given the patient’s poor performance status (ECOG 3) and the extent of cutaneous and systemic disease, a palliative approach was adopted. The patient died three months after diagnosis, with subsequent development of pulmonary metastases.



Figure 1- Large, ulcerated and exophytic neuroendocrine carcinoma of the left shoulder

Conclusion

This case underscores the aggressive behavior and diagnostic complexity of primary cutaneous non-Merkel neuroendocrine carcinomas. Comprehensive clinicopathological correlation, supported by advanced imaging, is essential to exclude metastatic disease from an extracutaneous primary. Delayed presentation may result in disseminated disease and limited therapeutic options, highlighting the importance of early recognition.

EADV CONGRESS
VIENNA
30 SEP - 3 OCT 2026

Abstract N°: 2119

Low-Dose versus Standard-Dose Total Skin Electron Beam Therapy in Mycosis Fungoides: Cutaneous Response and Tolerability

Gülfiye Selin İzgi*[1], Emine Kamer[2], İlgen Ertam Sağduyu[1], Ayda Acar[1], Tuğçe Bozkurt[2], Günsel Öztürk[1], Yavuz Anacak[2]

[1] Ege University, Faculty of Medicine, Department of Dermatology, Izmir, Türkiye
[2] Ege University, Faculty of Medicine, Department of Radiation Oncology, Izmir, Türkiye

Introduction
Mycosis fungoides (MF) is the most common subtype of cutaneous T-cell lymphoma and may progress to advanced stages with widespread cutaneous involvement adversely affecting prognosis and quality of life. While skin-directed therapies such as topical corticosteroids, phototherapy (PUVA/NB-UVB), and topical chemotherapy constitute the mainstay of early-stage treatment, total skin electron beam therapy (TSEI) remains an important option for patients with widespread disease refractory to conventional treatments. This study aimed to compare clinical response rates, dermatologic toxicity profiles, and long-term outcomes of standard-dose TSEI (SD-TSEI) versus low-dose TSEI (LD-TSEI), with a focus on skin-related endpoints and tolerability.

Materials and Methods
Forty-seven histopathologically confirmed MF patients who received TSEI at our center between 2011 and 2025 were retrospectively reviewed. All patients had been evaluated and followed up at the dermatology clinic prior to TSEI. Clinical staging followed the ISCL/EORTC TNMB classification. Cutaneous response was assessed at baseline, during treatment, and at follow-up by dermatologic examination and physician global assessment. TSEI was delivered using the modified Stanford technique with six fields and dual gantry angles at daily fractions of 1–1.2 Gy. From 2011 to 2016, 19 patients received SD-TSEI (36 Gy); from 2017 to 2025, 28 patients received LD-TSEI (12 Gy). In the low-dose group, 12 patients received a second course and 3 a third course due to relapse or progression. Mean age was 57 years (31–88) with male predominance (34 males [72.3%], 13 females [27.7%]). By TNMB staging: 2 (4.3%) stage I, 22 (46.8%) stage II, 14 (29.8%) stage III, and 9 (19.1%) stage IV.

Results
Patients carried a substantial treatment burden prior to TSEI, with a mean time from diagnosis to TSEI of 4.9 years (0–22 years). In the SD-TSEI group, 15 patients (78.9%) achieved complete cutaneous response (CCR) and 4 (21.1%) partial cutaneous response (PCR), yielding an overall response rate (ORR) of 100%. In the LD-TSEI group, 20 (71.4%) achieved CCR and 8 (28.6%) PCR, with 100% ORR. CCR rates were numerically higher in the SD group but not statistically significant ($p > 0.05$). Mean time to cutaneous relapse was 14.8 months (SD-TSEI) versus 11.6 months (LD-TSEI). Five-year disease-free survival rates were 42.1% versus 72.2% ($p > 0.05$) and overall survival rates 50.1% versus 75% ($p > 0.05$). Regarding toxicity, 18 SD-TSEI patients (94.7%) developed mild-to-moderate erythema (CTCAE grade 1–2) and 1 (5.3%) severe erythema (grade 3). In addition to erythema, the SD group exhibited prominent xerosis in 14 patients (73.7%), widespread desquamation in 7 patients (36.8%), and transient alopecia in 2 patients (10.5%); these findings frequently necessitated intensive dermatologic care. This included multiple daily emollient applications, topical corticosteroids for localized areas, wet-wrap therapy for extensive desquamation, and topical antibacterial treatment in cases with suspected secondary infection. Leukopenia developed in 1 patient (5.3%). In contrast, only mild-to-moderate erythema was observed in the LD-TSEI group,

with no grade ≥3 toxicity or systemic adverse events. No treatment-limiting events occurred.

Conclusions

TSEI is an effective skin-directed treatment across all stages of MF. From a dermatologic perspective, low-dose TSEI (12 Gy) in repeatable courses offers a balanced approach between efficacy and cutaneous tolerability. Although SD-TSEI provides higher CCR rates, it is associated with significant toxicities including xerosis, desquamation, and alopecia, potentially affecting quality of life and retreatment feasibility. LD-TSEI, with comparable long-term survival, emerges as a practical and well-tolerated treatment strategy preserving skin integrity; notably, no cumulative cutaneous toxicity was observed with repeated courses. At our center, this approach is preferred for disease control with fewer adverse effects.

EADV CONGRESS
VIENNA
30 SEP - 3 OCT 2026

Abstract N°: 2140

Superficial CD34-positive fibroblastic tumor of low malignant potential: diagnostic challenges in the differential diagnosis with dermatofibrosarcoma protuberans

Javier de Quadros Malagón*[1], Rocío Muñoz Martínez[1], María Dolores Caro Gutiérrez[1], Araceli Sánchez Gilo[1], José Javier Mateos Rico[1], Cristina Marcos Rodríguez[1], Mario Porto Souto[1], Francisco Javier Vicente Martín[1]

[1] Hospital Universitario Rey Juan Carlos, Móstoles, Spain

Introduction

Superficial CD34-positive fibroblastic tumors comprise a heterogeneous group of mesenchymal neoplasms with overlapping histologic and immunophenotypic features, making accurate classification challenging, particularly in distinguishing them from dermatofibrosarcoma protuberans (DFSP).

Case Presentation

We report the case of a 91-year-old patient with a 15-year history of a lesion located on the lateral aspect of the right hand. Clinically, the lesion presented as a skin-colored, mobile, multilobulated subcutaneous mass that had exhibited slow and indolent growth despite a recent increase in size. An initial biopsy revealed a collagenized myofibroblastic proliferation suggestive of fibromatosis.

Histopathologic examination of the excision specimen demonstrated a relatively well-circumscribed dermal spindle cell proliferation arranged in intersecting fascicles, with focal areas showing a poorly defined storiform pattern. Tumor cells displayed eosinophilic cytoplasm, mild nuclear pleomorphism, occasional multinucleation, and scattered foamy histiocytes, without necrosis or significant mitotic activity. Immunohistochemically, the tumor showed diffuse CD34 positivity, with scattered CD68-positive cells, and was negative for Factor XIIIa, β-catenin, EMA, desmin, smooth muscle actin, SOX10, STAT6, MUC4, cytokeratins, and melanocytic markers.

Although the morphologic and immunophenotypic profile prompted consideration of DFSP in the differential diagnosis, the prolonged clinical course, slow growth, relative circumscription, and absence of overt infiltrative features were atypical for that entity. Molecular analysis by next-generation sequencing for detection of the COL1A1–PDGFB fusion was inconclusive due to insufficient sample quality. Taken together, the findings support the diagnosis of a superficial CD34-positive fibroblastic tumor with low malignant potential.

Conclusion

This case highlights the diagnostic complexity within the spectrum of CD34-positive fibroblastic tumors and underscores the limited specificity of CD34 expression, which may be observed in multiple fibroblastic and fibrohistiocytic entities. It also emphasizes the importance of integrating clinical, morphologic, immunohistochemical, and molecular findings to achieve accurate classification, which is essential for appropriate surgical management and prognostic assessment.

EA DV CONGRESS
VIENNA
30 SEP - 3 OCT 2026

Abstract N°: 2145

Autonomous AI triage in urgent skin cancer pathways: real-world safety, diagnostic performance and system impact in 8,391 patients

Lucy Thomas*[1], Chrystalla Macedo[2], Louise Fearfield[2]

[1] Chelsea & Westminster Hospital NHS Foundation Trust, Imperial College London, London, United Kingdom
[2] Chelsea & Westminster Hospital NHS Foundation Trust, London, United Kingdom

Introduction

Urgent suspected skin cancer (USSC) referrals in the UK have tripled since 2009 and continue to rise annually, while conversion rates remain low (~6%)[1]. This mismatch drives pathway inefficiency, delays care for routine dermatology patients, including those with complex inflammatory disease and contributes to diagnostic delay of skin cancers presenting outside urgent pathways. Workforce pressures are significant, with ~25% of UK dermatologist posts unfilled[2]. While teledermatology improves access, it has not fully met demand. Artificial intelligence as a medical device (AIaMD) has demonstrated diagnostic performance comparable to dermatologists; however, evidence for fully autonomous deployment within real-world cancer pathways remains limited[3,4]. To our knowledge, this represents the first large-scale dataset from a prospective real-world deployment of autonomous AIaMD within a cancer pathway.

Materials and Methods

Following pilot validation with teledermatologist (TD) second reads, a CE-marked Class III autonomous AIaMD was implemented across two hospital sites (December 2024; July 2025). Standardised clinical and dermoscopic images were acquired using smartphone dermoscopy. The AI system applies sequential validation (dermoscopic confirmation, image quality assessment) followed by hierarchical classification prioritising higher-risk diagnoses. Cases classified as benign were discharged autonomously with safety-netting advice, without clinician review. High-risk cases were triaged to TD assessment. Outcomes were prospectively evaluated over 16 months, using histopathology as the reference standard for malignant lesions. Outcomes were compared with face-to-face (F2F), TD-only, and AI-assisted TD pathways to evaluate diagnostic performance and system-level impact.

Results

A total of 8,391 patients (94% of USSC referrals) were managed via the autonomous pathway (Site 1: 5,787; Site 2: 2,604) and consent for autonomous decision making was high (86%). Autonomous AIaMD discharge was 37% (site 1) and 32% (site 2) with an actual discharge rate after exclusions of 31% and 25% respectively, with TD discharging an additional 24% and 25%. Comparative clinical outcomes and resource utilisation are summarised in *Table 1*. Autonomous AIaMD reduced routine follow-up versus standard TD (12% vs 27%) and biopsy rates versus conventional F2F care (26–29% vs 43%), indicating improved diagnostic efficiency and reduced downstream resource use. All skin types were represented with Fitzpatrick type V/VI also being routed for TD review. False negatives were rare (n=6, five basal cell carcinomas [BCC] and one melanoma in situ), identified through post-market surveillance, with no adverse outcomes identified within available follow-up. For context, in a national dataset including both sites with ground truth for benign cases, sensitivity for malignancy exceeded 97% (invasive melanoma, 98.3% [95% CI, 97.3–99.0]; squamous cell carcinoma, 98.4% [95% CI, 97.8–98.8]; BCC, 98.1% [95% CI,

97.7–98.5]), with a specificity of 72.1% (95% CI, 71.7-72.6%). Estimated clinician time savings versus F2F pathways were 2,851 hours, compared with 4,601 hours for traditional F2F pathways representing an approximate 62% gain in clinical capacity. This equates to 8,553 additional F2F patient appointments (assuming 20-minute consultations) over 16 months.

	F2F	TD	AI assisted TD (TD second read)		Autonomous AI triage with TD	
	Site 1	Site 1	Site 1	Site 2	Site 1	Site 2
Total number of patients	200	20,000	10,042	2,009	5,787	2,604
Direct discharge rate	43%	37%	46% (AI 26%, TD 20%)	45% (AI 24% TD 21%)	55% (AI 31%, TD 24%)	50% (AI 25%, TD 25%)
Urgent F2F clinic	100%	6%	5%	9%	6%	7%
Routine follow-up required	13%	27%	21%	14%	12%	12%
Biopsy rate (urgent & routine)	43%	27%	26%	32%	26%	29%
Mean clinician time per case (minutes)	20	12	9	9	9	9

Table 1 Comparative clinical outcomes and resource utilisation across urgent suspected skin cancer pathway models. Abbreviations: F2F, face-to-face clinician review; TD, teledermatologist review; AI, artificial intelligence; AIaMD, artificial intelligence as a medical device; AI assisted TD (TD second read), AIaMD triage with teledermatologist review of all cases; Autonomous AI triage with TD, Autonomous AIaMD triage and discharge of benign lesions with teledermatologist review of cases deemed not benign or excluded from AIaMD assessment.

Conclusions

Autonomous AIaMD can be safely integrated into real-world USSC pathways, enabling immediate discharge of approximately one-quarter of patients without clinician input while maintaining high sensitivity for malignancy. This approach improves diagnostic efficiency, reduces unnecessary clinic utilisation and biopsy rates, and preserves specialist capacity for higher-risk and complex disease. At scale, autonomous AI offers a credible, scalable solution to rising demand and workforce constraints in dermatology. Further evaluation of long-term outcomes, cost-effectiveness, and patient acceptability will support wider adoption.

EA DV CONGRESS
VIENNA
30 SEP - 3 OCT 2026

Abstract N°: 2163

A Challenging Case of Adult-Onset Langerhans Cell Histiocytosis Misdiagnosed as Hidradenitis Suppurativa

Ozge Zorlu[1], Sevil Karabag[2], Umut Gunal*[1], Ozge Erturk[1], Seval Akpınar[3]

[1] Department of Dermatology and Venereology, Faculty of Medicine, Tekirdag Namık Kemal University, TEKIRDAG, Türkiye

[2] Department of Medical Pathology, Faculty of Medicine, Tekirdag Namık Kemal University, TEKIRDAG, Türkiye

[3] Department of Hematology, Faculty of Medicine, Tekirdag Namık Kemal University, TEKIRDAG, Türkiye

Introduction

Langerhans cell histiocytosis (LCH) is a rare neoplastic disorder characterized by the clonal proliferation of immature myeloid precursor cells that phenotypically resemble epidermal Langerhans cells. The role of BRAF V600E mutations and MAPK pathway activation in its pathogenesis has solidified the view of LCH as a myeloid neoplasm rather than a reactive inflammatory process. The disease exhibits significant clinical heterogeneity, ranging from single-system involvement to life-threatening multisystem disease. While more prevalent in children, adult-onset LCH is exceptionally rare, with an incidence of 1–2 cases per million. Following the skeletal system, the skin and mucosa are the second most frequently involved sites and often serve as the initial clinical manifestation. Histopathologically, characteristic features include immunopositivity for CD1a, S100, and Langerin (CD207), as well as the presence of cytoplasmic Birbeck granules observed under the electron microscope. We herein report a rare case of adult-onset LCH that was initially misdiagnosed as hidradenitis suppurativa (HS), posing a significant diagnostic challenge.

Case Presentation

A 55-year-old female presented with a six-month history of pruritic and suppurative lesions involving the scalp, axillae, inguinal regions, and inframammary folds. Her medical history was significant for a diagnosis of HS eight years prior, which had been treated with systemic and topical antibiotics and acitretin (25 mg/day) for nine months, resulting in transient partial remission. Due to worsening symptoms, the patient recently sought a gynecological evaluation, which revealed an eroded, mass-like lesion on the right vulvar fourchette. To differentiate the atypical presentation from HS, a punch biopsy was performed from the vulvar lesion. Histopathological examination demonstrated a dense histiocytic proliferation filling the papillary dermis. Immunohistochemical (IHC) analysis showed diffuse positivity for S100 and CD1a, confirming the diagnosis of LCH.Upon referral to our dermatology clinic, a detailed physical examination revealed yellowish adherent scales on the vertex and parieto-occipital scalp. Erythematous eroded plaques with focal yellow crusting and petechiae were observed in the bilateral axillae, shoulders, inframammary regions, mid-back, groins, and vulva. Notably, pathognomonic HS features—such as abscesses, nodules, or sinus tracts—were absent. A skin biopsy specimen obtained from the right inguinal region in recent months, which had been originally reported as "compatible with HS," was retrospectively re-evaluated at our institution. Histopathological re-examination confirmed that this specimen was also consistent with LCH. Further systemic staging identified a mass in the buccal mucosa; biopsy results were consistent with LCH. Molecular analysis detected a likely pathogenic BRAF V487 variant. The patient's background included hypothyroidism and hypereosinophilic syndrome associated with a PDGFRα mutation, for which she was undergoing treatment with imatinib. Laboratory investigations revealed eosinophilia along with elevated levels of C-reactive protein, alkaline phosphatase, gamma-glutamyl transferase, and ferritin. The patient is currently under multidisciplinary follow-up by the dermatology and hematology departments for systemic

involvement staging and treatment planning.

Conclusion

LCH is frequently regarded as the 'great imitator' due to its propensity to mimic common inflammatory conditions such as seborrheic dermatitis, intertrigo, or lichenoid eruptions, often leading to significant diagnostic delays in adults. This case highlights a rare presentation of LCH as a clinical simulator of HS. The differential diagnosis of treatment-refractory suppurative lesions should maintain a high index of clinical suspicion for LCH, necessitating early histopathological and immunohistochemical evaluation to ensure an accurate diagnosis and prevent inappropriate long-term systemic interventions.

EA DV CONGRESS
VIENNA
30 SEP - 3 OCT 2026

Abstract N°: 2170

Cutaneous Manifestations of Mantle Cell Lymphoma: A Diagnostic Challenge with Major Prognostic Implications

KHALDI HANANE FADOUA*[1], Mahi Ilhem[1], DAHMANI Boumediene[1], Assia zenagui[1], Abuhammad Ahmad[1], Benhamed Nardjes[1]

[1] Department of Dermatology and Venereology, CHU Tlemcen, Tlemcen, Algeria

Introduction

Mantle cell lymphoma (MCL) is a rare and aggressive subtype of B-cell non-Hodgkin lymphoma. While extranodal involvement is frequent, cutaneous localization remains exceptional, representing only 0.3% of cutaneous malignant lymphomas. Such presentation often signifies a disseminated form of the disease and carries a poor prognosis. We report an original observation where skin lesions served as the key to the etiopathogenic diagnosis of MCL.

Case Presentation

An 81-year-old female patient with a medical history of heart disease, diabetes, and hypertension presented with asymptomatic, confluent, and highly infiltrated violaceous papulonodular lesions on the forehead, evolving over several months. A skin biopsy revealed an orthokeratotic hyperkeratotic squamous epithelium overlying a dermis containing a monomorphic malignant neoplastic lymphoid proliferation. This proliferation consisted of small regular lymphocytes without epidermotropism.Immunohistochemical analysis demonstrated diffuse and intense CD20 positivity, along with bcl2 expression. Both CD10 and CD5 were negative, while Cyclin D1 showed moderate diffuse positivity. Based on the 2024 WHO classification, a diagnosis of B-cell Mantle Cell Lymphoma was established. Extension workup identified bilateral cervical lymphadenopathy without organomegaly or other detectable nodal involvement. Following a multidisciplinary consultative meeting (RCP), a chemotherapy regimen adapted for geriatric care was initiated. The clinical course was marked by a complete response by the fifth cycle, characterized by the total regression of skin nodules and disappearance of lymphadenopathy, confirmed by CT imaging.

MCL typically affects elderly patients in a disseminated pattern involving the bone marrow, spleen, and gastrointestinal tract. Its cutaneous expression is rare, with only approximately thirty cases reported in the literature. Molecularly, MCL is defined by the t(11;14)(q13;q32) translocation, leading to Cyclin D1 overexpression. The semiological diversity of lesions—ranging from nodules to infiltrated plaques—can mimic granulomatous diseases like sarcoidosis, complicating the clinical diagnosis. In this case, histological and immunohistochemical analysis was the pivotal tool to rectify the initial orientation. Although our patient’s current response is satisfactory, the prognosis remains guarded due to high relapse rates.

Conclusion

Cutaneous involvement in MCL is rare and often misleading. However, these lesions can be the primary clinical indicator of the disease. Given its severity, rapid diagnostic processing and early multidisciplinary management are essential

EADV Congress 2026, VIENNA
30 SEPTEMBER - 03 OCTOBER 2026
POWERED BY M-ANAGE.COM

EA DV CONGRESS
VIENNA
30 SEP - 3 OCT 2026

Abstract N°: 2179

Complex Evolution: Nora's Tumor Masquerading as a Pyogenic Granuloma Following Ungual Surgery.

KHALDI HANANE FADOUA*[1, 2], Aboubakr Kamila[1, 2], Mahi Ilhem[1, 2], DAHMANI Boumediene[1, 2], Benhamed Nardjes[2]

[1] Department of Dermatology and Venereology, CHU Tlemcen, Tlemcen, Algeria
[2] Faculty of Medicine, Dr. Benzerdjeb Benaouda, Tlemcen, Faculty of Medicine, Dr. Benzerdjeb Benaouda, Tlemcen, Tlemcen, Algeria

Introduction

Nora's tumor, formally known as **Bizarre Parosteal Osteochondromatous Proliferation (BPOP)**, is a rare, benign, yet locally aggressive osteocartilaginous lesion. While its exact etiology remains a subject of debate, a prevailing hypothesis suggests an exuberant reactive process following trauma or surgical intervention. We report an original case of Nora's tumor arising after the surgical management of an ingrown toenail, highlighting the diagnostic challenges and the critical need to differentiate it from malignant lesions.

Case Presentation

A 17-year-old female patient (L.D.), with no significant medical history, underwent complete surgical excision for an ingrown hallux nail. One week post-operation, a 2 cm nodular, firm, and multinodular tumor developed at the surgical site, exhibiting contact bleeding. An initial excision and histopathological examination concluded a diagnosis of **pyogenic granuloma** (botriomycoma).However, an immediate clinical recurrence occurred within one week. A CT scan of the foot was performed, revealing a 14×9 mm osseous neoformation grafted onto the distal phalanx (P3), notably lacking cortico-medullary continuity. A subsequent surgical exploration with dual sampling confirmed a superficial reactive pyogenic granuloma overlying a deep osteocartilaginous proliferation. Histological features, including a basophilic matrix and "bizarre" chondrocytes, authenticated the diagnosis of Nora's tumor.

BPOP, first described by Nora in 1983, is a rare entity whose pathogenesis appears closely linked to aberrant healing processes post-trauma or surgery. This case is exemplary due to its presentation under the "mask" of a pyogenic granuloma, where a superficial inflammatory reaction obscured the underlying bone proliferation.The primary challenge of Nora's tumor lies in its polymorphism. While the cytological "bizarre" nature of the chondrocytes can mimic chondrosarcoma, the **absence of cortico-medullary continuity** on imaging (CT/MRI) is the pathognomonic criterion that distinguishes it from a classic osteochondroma. This distinction is vital to prevent unnecessary radical amputations. Nevertheless, the local aggressiveness of BPOP—with recurrence rates reaching up to 55%—necessitates rigorous monobloc excision with decortication of the cortical base.

3.

Conclusion

Nora's tumor following ungual surgery is a rare entity that frequently simulates malignancy. Clinical awareness is essential to avoid over-treatment. Management relies on meticulous local excision to mitigate the risk of recurrence, which remains the primary challenge of this pathology.

EADV Congress 2026, VIENNA
30 SEPTEMBER - 03 OCTOBER 2026
POWERED BY M-ANAGE.COM

EA CONGRESS
VIENNA
30 SEP - 3 OCT 2026

Abstract N°: 2186

Circulating CD21-/lo B Cells and BAFF/BAFF-R Signaling as Candidate Biomarkers of Response to Immune Checkpoint Inhibitors in Metastatic Melanoma

Lorenzo Homann*[1], Lacin Cevhertas[2], Mirjam Fässler[3], Fiamma Berner[3], Manal Bel Imam[2], Cezmi Akdis[2], Mübeccel Akdis[2], Lukas Flatz[1, 3], Willem van de Veen[2]

[1] Universitäts-Hautklinik Tübingen, Tübingen, Germany

[2] Universität Zürich, Zürich, Switzerland

[3] Institute of Immunobiology, Kantonsspital St Gallen, Sankt Gallen, Switzerland

Introduction

Immune checkpoint inhibitors (ICIs) have substantially improved outcomes in metastatic melanoma; however, a considerable proportion of patients fails to benefit. While the therapeutic effects of ICIs are mainly attributed to T-cell reactivation, increasing evidence highlights a contributory role of B cells in anti-tumor immunity. In this study, we investigated whether circulating B-cell subsets and BAFF/BAFF-receptor signaling are linked to clinical response in patients receiving ICI therapy (anti-PD-1 and/or anti-CTLA-4).

Materials and Methods

Patients with metastatic melanoma receiving anti-PD-1 and/or anti-CTLA-4 therapy were prospectively enrolled, and a balanced cohort of 24 patients (12 responders, 12 non-responders) with longitudinal sampling before treatment (T1), after 3 weeks (T2), and after 9–12 weeks (T3) was analyzed. Peripheral blood mononuclear cells (PBMCs) and serum samples were isolated and cryopreserved; 10 healthy donors served as controls. Treatment response was assessed by CT imaging according to RECIST 1.1, with confirmatory scans to exclude pseudoprogression, and immune-related adverse events were graded per CTCAE v4.03. Serum BAFF and APRIL levels were quantified by ELISA. Immunophenotyping of PBMCs was performed using multicolor flow cytometry to define B cell subsets, including $CD21^{-}$/lo populations. All samples were processed under standardized conditions with blinded analysis and randomized batch allocation. Statistical analyses included log-transformation of variables, parametric or nonparametric group comparisons, repeated-measures analyses, correlation testing (Pearson or Spearman), and ROC curve analysis to evaluate predictive performance.

Results

Patients who responded to therapy showed higher frequencies of class-switched memory B cells ($CD27^{+}IgM^{-}IgD^{-}$) both at baseline and throughout treatment. In contrast, non-responders exhibited an expansion of $CD21^{-}$/lo B cells, particularly within IgG^{+} and IgA^{+} compartments. Elevated serum BAFF levels were observed in non-responders at T1 and T2 and were inversely associated with BAFF-R expression on B cells, whereas APRIL levels did not differ between groups. Responders displayed higher BAFF-R expression at early time points, followed by a decline during therapy. Receiver operating characteristic analyses demonstrated that BAFF levels discriminated responders from non-responders at baseline and early during treatment (AUC ~ 0.8), but not at later time points.

Conclusions

Overall, our data indicate that both the composition of circulating B-cell subsets and the BAFF/BAFF-R signaling axis are associated with response to ICI therapy. Increased $CD21^{-}$/lo B cells and elevated BAFF levels characterize non-response, whereas a prominent class-switched memory B-cell compartment combined with lower BAFF levels is linked to favorable outcomes. These findings support a potential role for B-cell–related parameters as biomarkers for immune monitoring; validation in a larger, independent international confirmation cohort is currently ongoing.

EA DV CONGRESS
VIENNA
30 SEP - 3 OCT 2026

Abstract N°: 2215

Fulminant Merkel Cell Carcinoma with a Pseudocellulitic Presentation and Rapid Fatal Progression

EDUARDA LUISA ROCHA CORTI*[1], Carolina Lourenço dos Santos Landini Freitas[1], Carolina Siqueira Varotto Martins[1], MARIA BEATRIZ LIRA DO O ESPOSITO[1], Camila Gouvea Facure[1], JOÃO GARCIA DA ROCHA NETO[1, 1], CÉLIA ALVEZ[1], Juliana Arêas de Souza Lima Beltrame Ferreira[1], Clovis Antonio Lopes Pinto[1], Glaucos Ricardo Paraluppi[1], Mariana Careta[1]

[1] Jundiaí, Jundiaí, Brazil

Introduction

Merkel Cell Carcinoma is a rare and highly aggressive neuroendocrine cutaneous malignancy characterized by rapid tumor growth, early lymphatic dissemination, and high mortality rates. Although it predominantly affects elderly fair-skinned individuals in photoexposed areas, atypical clinical presentations may mimic inflammatory or infectious dermatoses, delaying diagnosis and contributing to advanced-stage disease.

Case Presentation

A 76-year-old Brazilian woman, Fitzpatrick skin phototype II, with a medical history of systemic arterial hypertension and chronic venous insufficiency, and no previous dermatological diseases, initially presented with erythematous papules on the left lower limb, interpreted as an inflammatory reaction secondary to an insect bite, with transient spontaneous improvement. Subsequently, the lesion recurred in the same limb as an erythematous plaque resembling cellulitis, followed by rapid clinical progression, progressive tumor enlargement, and local pain. Dermatological examination revealed an erythematous-violaceous tumor on the anterior aspect of the left leg, covered by a central honey-colored crust and associated necrotic areas. Multiple erythematous satellite nodules were observed on the anterior and posterior aspects of the limb, associated with extensive indurated edema extending from the ankle to the thigh root and palpable left inguinal lymphadenopathy.

The patient was hospitalized for diagnostic investigation and empirical systemic antibiotic therapy. The diagnosis of Merkel cell carcinoma was confirmed by histopathology and immunohistochemistry, demonstrating a typical neuroendocrine profile, with CK20 positivity and a high Ki-67 proliferative index. An inconclusive result for Merkel cell polyomavirus does not exclude the diagnosis, considering that a significant proportion of cases are associated with ultraviolet radiation-induced mutations and high mutational burden. Computed tomography revealed extensive inguinal, pelvic, and retroperitoneal lymph node involvement, consistent with advanced metastatic disease (cT3N3M1a – stage IV).

Currently, immune checkpoint inhibitors targeting the PD-1/PD-L1 axis represent the standard systemic treatment for advanced disease, with superior response rates and survival outcomes compared with conventional chemotherapy. However, limited access to immunotherapy remains a major therapeutic challenge in several healthcare settings. Due to the unavailability of this therapeutic modality, systemic treatment with carboplatin and etoposide was proposed. Nevertheless, owing to the extremely aggressive behavior and rapid tumor progression, the patient died before systemic therapy could be initiated.

Conclusion

This case highlights the fulminant behavior of Merkel cell carcinoma and emphasizes the importance of early recognition of atypical clinical presentations, particularly those mimicking infectious or inflammatory conditions such as cellulitis. Prompt diagnosis associated with timely therapeutic definition is essential in an attempt to

achieve disease control. Furthermore, this report underscores the prognostic impact of early access to immunotherapy in patients with advanced metastatic disease.

EADV CONGRESS
VIENNA
30 SEP - 3 OCT 2026

Abstract N°: 2229

Solitary fibrofolliculoma of the lower lip mimicking a pyogenic granuloma: a diagnostic pitfall

Fatima Zahra Hammoud*[1], Chourouq Mustapha Eid[1], Fatima Zahra Sassine[1], Najoua Ammar[1], Mariame Meziane[1], Nadia Ismaili[1], Syrine Hamada[1], Laila Benzekri[1]

[1] Department of Dermatology, Mohamed V University of Rabat, Ibn Sina University Hospital, Rabat, Morocco

Introduction
Fibrofolliculoma is a benign follicular hamartoma most commonly associated with Birt–Hogg–Dubé syndrome, an hereditary autosomal dominant disorder that results from germline mutations on chromosome 17p11.2 of the folliculin (FLCN), where it typically presents as multiple lesions. In contrast, solitary fibrofolliculoma is rare and often underrecognized due to its nonspecific clinical features and unusual locations. Histopathological examination remains essential for diagnosis. We report a case arising on the lower lip, clinically mimicking a vascular lesion.

Case Presentation
A 27-year-old man presented with a solitary, progressively enlarging lesion of the lower lip evolving over one year. The lesion was asymptomatic but prone to recurrent bleeding following minor trauma. Clinical examination revealed a well-demarcated, dome-shaped, erythematous and friable nodule measuring approximately 1 cm. Dermoscopic evaluation was non-specific

Given its vascular appearance, a pyogenic granuloma was initially suspected. A nodular basal cell carcinoma was also considered, along with benign follicular adnexal tumors such as perifollicular fibroma, trichofolliculoma, trichoepithelioma, trichilemmoma and trichodiscoma, as well as angiofibroma and basaloid follicular hamartoma.

No additional mucocutaneous lesions or systemic features suggestive of Birt–Hogg–Dubé syndrome were identified.

Complete surgical excision was performed. Histopathological analysis revealed a well-circumscribed lesion centered on a dilated follicular infundibulum, from which thin anastomosing epithelial strands extended into a fibrous perifollicular stroma. The stroma was composed of dense collagen with fibroblasts, consistent with a fibroepithelial hamartoma of follicular origin. These findings confirmed the diagnosis of fibrofolliculoma. No cytological atypia or features suggestive of basal cell carcinoma were observed.

Conclusion
Solitary fibrofolliculoma is an uncommon benign adnexal tumor that may clinically mimic vascular or malignant lesions, particularly in atypical locations such as the lip. This case highlights the importance of systematic histopathological examination in any atypical or bleeding facial lesion. Furthermore, recognition of fibrofolliculoma should prompt evaluation for Birt–Hogg–Dubé syndrome, even in apparently isolated cases. Surgical excision remains both diagnostic and curative, with an excellent prognosis.

EADV CONGRESS
VIENNA
30 SEP - 3 OCT 2026

Abstract N°: 2237

Subcutaneous Nodules Revealing a Pulmonary Adenocarcinoma

Mansouri Rayane*[1], kaghouche lilia[1], Safa Djebbas[1], Amel Gherfi[1], esma bouhila[1], khadidja bouarroudj[1], Tarek Mansoul[1], RIADH BOUSSAID[1], Ahmed Samaouel Chehad[1]

[1] Department of Dermatology, CHU Benbadis, Constantine, Algeria, constantine, Algeria

Introduction

Cutaneous metastases of solid tumors can be revealing of the primary tumor. They appear as papules or subcutaneous nodules of firm consistency, single or multiple.
Histology and immunohistochemistry are essential tools to confirm the tumoral nature of the nodules and guide towards the localization of the primary focus.

Case Presentation

It is about an 84-year-old patient, with a history of smoking, who consulted for the appearance for 7 months of multiple subcutaneous nodules of a few centimeters in diameter, of firm consistency, sensitive to palpation, involving the upper limb, thigh, buttock, and abdominal wall.
A deep skin biopsy was performed, showing a malignant dermo-hypodermic tumoral proliferation, organized in lobules and cords, associated with foci of necrosis. The tumoral cells are epithelioid, large, with moderately abundant eosinophilic cytoplasm, presenting large, irregular, nucleolated nuclei, with a high mitotic index. The tumoral stroma is fibrous and desmoplastic, suggesting a secondary metastatic origin.
The immunohistochemical study showed intense and diffuse positivity of pancytokeratin and CK7, moderate nuclear positivity of TTF-1, and negativity of the other markers. This profile being in favor of a poorly differentiated adenocarcinoma, compatible with a pulmonary origin.
The thoraco-abdomino-pelvic CT scan showed, at the thoracic level, multiple bilateral pulmonary masses and nodules of peripheral localization with upper lobar predominance and presence of wormlike calcifications in some places. The largest lesion was located at the apical segment of the left lower lobe, measuring 77 × 32 mm.
The diagnosis of cutaneous metastases revealing a poorly differentiated pulmonary adenocarcinoma was made, and the patient was referred to the oncology department for appropriate treatment.

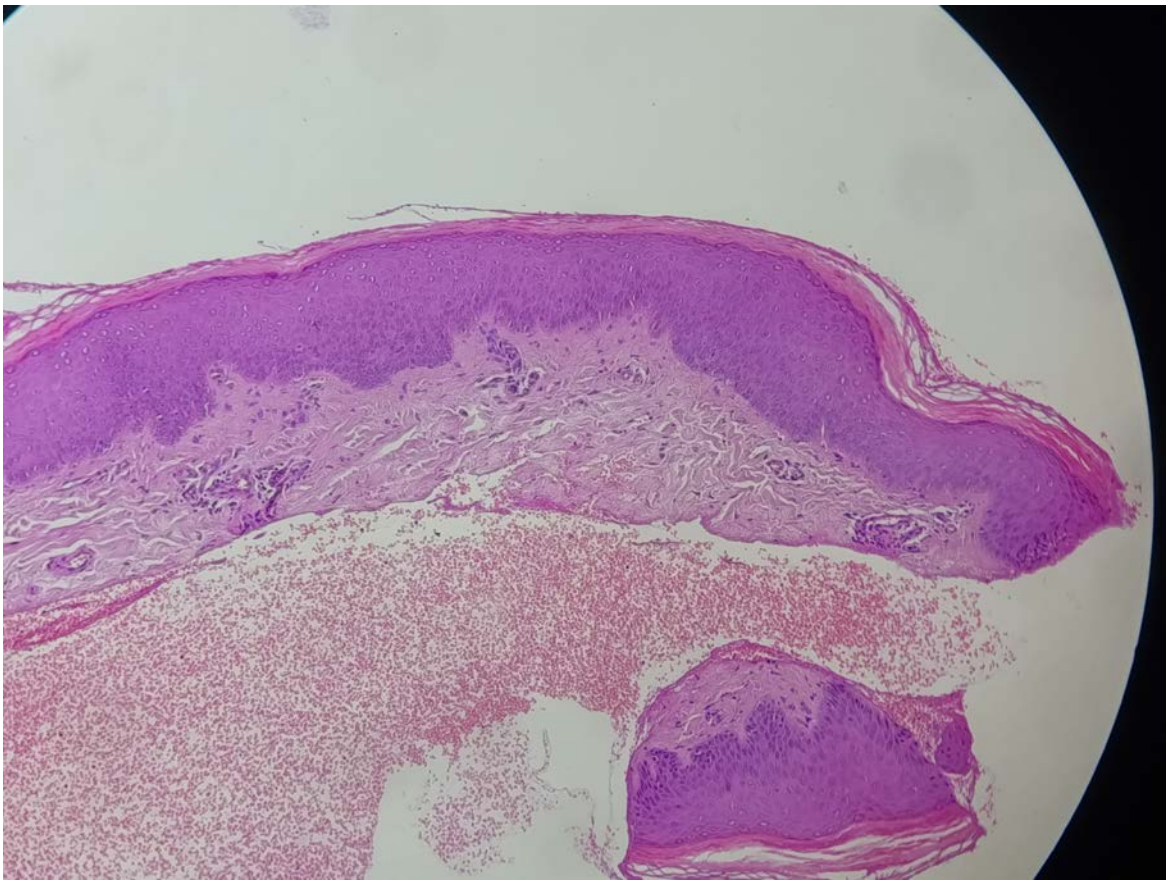

Infiltration in sheets, clusters of atypical cells, with anisokaryosis, hyperchromatism, and frequent mitoses. The architecture is infiltrative and destructive, invading the deep dermis and hypodermis

Conclusion

Discussion

Pulmonary cutaneous metastases are rare and can sometimes precede the diagnosis of lung cancer. Their atypical clinical presentation or disseminated character can represent a real diagnostic challenge. The histological examination most often allows the diagnosis to be guided. In our case, the anatomopathological examination of the nodules showed a malignant epithelioid proliferation with a high mitotic index and tumoral necrosis. The immunohistochemical profile with positive pancytokeratin, CK7, and TTF-1, associated with the negativity of digestive and melanocytic markers, made it possible to identify the pulmonary origin, illustrating the central role of histology and immunohistochemistry in determining the primary focus.

Conclusion

Our case illustrates that cutaneous lesions can be revealing of visceral neoplasms, hence the necessity to think about it.

EADV CONGRESS
VIENNA
30 SEP - 3 OCT 2026

Abstract N°: 2254

Melanoma in patients aged ≥80 years: clinical features, management patterns and outcomes in real-world practice

Sara De Benito Mendieta*[1], Reyes Gamo Villegas[1], Alejandra Méndez Valdés[1], Irene Alonso Rodríguez[1], María Castellanos González[1], Gemma Jumilla Martínez[1], Cristina Nistreanu[1], Jose Luis López Estebaranz[1]

[1] Hospital Universitario Fundación Alcorcón, Alcorcón, Spain

Introduction

The incidence of cutaneous melanoma is increasing worldwide, particularly in elderly populations. Patients aged ≥80 years represent a growing subgroup with distinct clinicopathological features and management patterns, yet they remain underrepresented in clinical studies.

Materials and Methods

We conducted a retrospective observational study including patients aged ≥80 years diagnosed with cutaneous melanoma at a tertiary hospital between June 1998 and February 2025. Demographic, clinicopathological, management and outcome data were collected from medical records. Survival analyses were performed using the Kaplan–Meier method.

Results

A total of 167 melanomas were included, representing 12.6% of all melanomas diagnosed at our institution. Median age at diagnosis was 84.5 years, with a slight male predominance. Chronic sun damage was documented in 59.9% of patients. Melanoma in situ accounted for 41.0% of cases, while 59.0% were invasive.

Lentigo maligna was the most frequent subtype overall. Among invasive melanomas, lentigo maligna melanoma, superficial spreading melanoma and nodular melanoma predominated. The most common anatomical location was the head and neck (55.1%), followed by the trunk (27.5%) and acral sites (7.8%).

Among invasive melanomas, Breslow thickness showed a heterogeneous distribution, with 37.2% ≤0.8 mm and 25.8% >4 mm. Ulceration was present in 29% of cases. Most patients were diagnosed at early stages (stage I–II: 84.8%).

Management was predominantly surgical, with sentinel lymph node biopsy performed in 55.4% of eligible patients. Systemic therapies were rarely used.

Median follow-up was 23.4 months. Disease progression occurred in 16.2% of patients. Overall mortality was high (52.7%), but melanoma-specific mortality was lower (10.8%). Five-year overall survival was 36.2%, whereas melanoma-specific survival reached 77.4%. Survival differences across age groups were significant for overall survival but not for melanoma-specific survival.

Conclusions

Melanoma in patients aged ≥80 years represents a growing and clinically relevant subgroup. It is characterised by a predominance of head and neck involvement and subtypes associated with chronic sun damage. Despite a high overall mortality, most deaths are not melanoma-related. Management is mainly surgical, highlighting the need for individualized treatment strategies in this population.

EADV CONGRESS
VIENNA
30 SEP - 3 OCT 2026

Abstract N°: 2256

Prognostic Factors for Metastasis and Recurrence in Cutaneous Squamous Cell Carcinoma: Experience from Tertiary Center

Sofia El haitamy*[1], Sara Elloudi[1], IKRAME BEJJA[1], Saadia Boughaleb[1], Zakia Douhi[1], Meryem Soughi[1], Hanane Baybay[1], Fatima Zohra Mernissi[1]

[1] Department of Dermatology, University Hospital Hassan II, Fez, Morocco

Introduction
Cutaneous squamous cell carcinoma (cSCC) is typically associated with a favorable prognosis. However, a subset of tumors displays aggressive behavior, leading to local recurrence, metastasis, and disease-related mortality. Identifying clinicopathological features and outcomes in these populations is essential to optimize risk stratification and management.

Materials and Methods
We conducted a retrospective study of 276 patients with invasive cSCC treated at a single tertiary referral center. Inclusion criteria were histopathologically confirmed invasive cSCC, excluding in situ and mucosal/anogenital cases. Data on demographics, tumor characteristics, and outcomes were analyzed. Univariate and multivariate logistic regression analyses were performed to identify independent prognostic factors.

Results
The mean age was 66.9 years, with a male predominance (53.3%). Chronic sun exposure was reported in 68.8% of cases, while 26.8% of tumors arose from scars or chronic wounds. The cohort exhibited a high rate of metastasis (33.3%) and a local recurrence rate of 10.8%. Univariate analysis identified precancerous origin (p=0.031), tumor size >2 cm (p<0.001), and Breslow thickness >2 mm (p=0.024) as significant risk factors for metastasis. In multivariate analysis, locoregional invasion beyond subcutaneous fat was the strongest independent predictor for both metastasis (OR=7.22; 95% CI 3.95–13.19; p<0.001) and local recurrence (OR=7.35; 95% CI 3.08–17.57; p<0.001). Poor differentiation was also an independent predictor of metastasis (OR=3.96; p=0.002).

Conclusions
These results highlight the urgent need for early detection, prompt referral, and aggressive multimodal treatment in deeply invasive tumors to reduce the high metastatic risk and morbidity observed in this setting.

EA DV CONGRESS
VIENNA
30 SEP - 3 OCT 2026

Abstract N°: 2259

Extramammary Paget Disease Presenting as Chronic Inguinal Plaques

Bouchra Idrissi Rhenimi*[1], Fadwa El Aissoug[1], Geraldine Titeca[1]

[1] Clinique notre dame de grace - gosselies, Gosselies, Belgium

Introduction

Extramammary Paget disease (EMPD) is a rare intraepithelial adenocarcinoma usually involving apocrine gland-bearing areas. Because of its nonspecific clinical presentation, EMPD is frequently misdiagnosed as inflammatory or infectious dermatoses, resulting in significant diagnostic delay. We report a case of inguinal EMPD initially managed as chronic genital eczema and fungal intertrigo.

Case Presentation

A 61-year-old man presented with a 1.5-year history of persistent pruritic inguinal and genital lesions. Initial clinical suspicion included tinea cruris, lichen simplex, and inflammatory dermatosis. Multiple topical treatments, including antifungal agents and corticosteroids, resulted in no significant improvement.

Clinical examination revealed chronic erythematous lichenified plaques involving the inguinal folds and genital region with focal erosive changes and maceration. Due to persistence of symptoms and resistance to conventional therapies, a punch biopsy was performed.

Histopathological examination demonstrated pagetoid intraepidermal infiltration by atypical oval cells with pale cytoplasm containing secretory material. PAS staining highlighted intraepidermal glandular cytoplasmic content. Immunohistochemistry showed tumor cell positivity for CK7 and weak c-erbB2 expression, while p63, CK20, CDX2, and NKX3.1 were negative. These findings supported the diagnosis of primary extramammary Paget disease.



Well-demarcated erythematous infiltrated plaques involving the inguinal folds, scrotal region, and perineal area, associated with lichenification, whitish hyperkeratosis, focal erosions, and maceration

Conclusion

This case highlights the diagnostic challenge of extramammary Paget disease, which may clinically mimic chronic inflammatory or infectious genital dermatoses. Persistent pruritic inguinal lesions refractory to standard treatments should prompt histopathological evaluation. Early recognition of EMPD is essential to avoid delayed diagnosis and optimize patient management.

EADV CONGRESS
VIENNA
30 SEP - 3 OCT 2026

Abstract N°: 2260

Erythroderma with epidermotropism mimicking mycosis fungoides in a patient with lung adenocarcinoma

Maryam Benssied*[1], YOUSSEF ZEMMEZ[1], JAWAD EL AZHARI[1], MOHAMED EL AMRAOUI[1], RACHID FRIKH[1], NAOUFAL HJIRA[1]

[1] Department of Dermatology, Military Hospital of Instruction Mohammed V, RABAT, Morocco

Introduction

Erythroderma may represent a major diagnostic challenge, particularly when clinicopathological findings suggest cutaneous T-cell lymphoma in the setting of an underlying solid malignancy. Distinguishing between true cutaneous lymphoma and reactive lymphoid dermatoses remains difficult in certain atypical presentations.

Case Presentation

A 77-year-old chronic smoker presented with a 3-month history of progressive pruritic erythroderma associated with burning sensation and weight loss, without prior dermatologic disease or recent drug exposure.

Clinical examination revealed diffuse erythematous scaly plaques involving approximately 60–70% of body surface area, sparing the face, palms, and soles, progressively evolving toward generalized erythroderma.

Initial skin biopsy with immunohistochemistry demonstrated an epidermotropic lymphoid infiltrate suggestive of mycosis fungoides. However, further systemic work-up unexpectedly revealed a localized TTF-1 positive lung adenocarcinoma.

A second skin biopsy performed after topical corticosteroid therapy showed non-specific inflammatory changes without evidence of cutaneous T-cell lymphoma. Staging investigations confirmed localized disease without metastasis.

Progressive and complete regression of the cutaneous manifestations was observed following tumor-directed radiotherapy.

Conclusion

This observation highlights a major diagnostic pitfall in erythrodermic presentations. The discordance between histopathological findings and clinical evolution strongly suggests a paraneoplastic lymphoid dermatosis mimicking mycosis fungoides rather than a true cutaneous T-cell lymphoma.

This case emphasizes the importance of repeated clinicopathological correlation and disease evolution in the interpretation of epidermotropic lymphoid infiltrates.

EADV CONGRESS
VIENNA
30 SEP - 3 OCT 2026

Abstract N°: 2264

The value of regional ultrasonography in melanoma surveillance

Nadja Højgaard Pedersen*[1], Marie Weitemeyer[1], Caroline Gjørup[1], Eva Ellebæk[2], Inge Svane[2], Simon Thomsen[3], Lisbet Hölmich[1], Neel Helvind[1]

[1] Department of Plastic Surgery, Copenhagen University Hospital: Herlev and Gentofte, Herlev, Denmark., Department of Dermato-Venereology & Wound Healing Centre, Copenhagen University Hospital - Bispebjerg and Frederiksberg, Copenhagen, Denmark, Copenhagen, Denmark

[2] Department of Oncology, Copenhagen University Hospital: Herlev and Gentofte, Herlev, Denmark., Herlev, Denmark

[3] Department of Dermato-Venereology & Wound Healing Centre, Copenhagen University Hospital - Bispebjerg and Frederiksberg, Copenhagen, Denmark, Department of Biomedical Sciences, University of Copenhagen, Copenhagen, Denmark, Copenhagen, Denmark

Introduction
Patients with sentinel lymph node micrometastases undergoing melanoma surveillance are routinely monitored with regional lymph node ultrasonography (US) to facilitate early detection of regional recurrence. However, evidence regarding the diagnostic yield and diagnostic value of these routine US evaluations remains sparse. To date, no systematic investigation has been conducted within a population-based cohort enrolled in a stage-specific surveillance program. The aim of this study was to determine the yield and diagnostic value of routine regional US scans in patients followed in the Danish stage-specific surveillance program.

Materials and Methods
The present study was a nationwide, population-based cohort study with retrospective analysis of prospectively collected surveillance data from the Danish Melanoma Database (DMD) and the Danish Pathology Registry (Patobank). We included adult Danish patients, registered in the DMD with a first-time diagnosis of stage IIIA–IIID cutaneous melanoma from 2018 to 2024. Main outcomes were diagnostic yield, diagnostic value (sensitivity, specificity, negative, and positive predictive values (NPV, PPV)), and number-needed-to-scan (NNS) of routine regional US in melanoma surveillance.

Results
We included 1,369 patients from the DMD (median age 64 years [IQR 51.5-74.0 years]). Median surveillance time was 45 months. Patient age increased progressively across stage III subgroups, ranging from a median of 56.5 years in stage IIIA to 73.0 years in stage IIID ($p < 0.001$). A total of 2,973 US scans were performed in 867 patients with stage III melanoma during the surveillance period. Recurrence was suspected in 128 scans and confirmed with histopathology in 21 cases, corresponding to a recurrence yield of 0.7 % (95 % CI: 0.4-1.1). The false positive rate was 3.7 % (95 % CI: 3.0-4.4), the false negative rate was 61.1 % (95 % CI: 46.9-73.8), while the sensitivity and specificity were 38.9 % (95 % CI: 26.2-53.1) and 96.3 % (95 % CI: 95.6-97.0) respectively. PPV was 16.4 % (95 % CI: 10.7-24.2), NPV was 98.8 % (95 % CI:98.4-99.2), and NNS was 141.6 scans to detect one true recurrence.

Conclusions

In this nationwide, population-based cohort study, the diagnostic yield, sensitivity, and PPV were low, while false positive rate, false negative rate, and NNS were considerable. These findings suggest that routine regional US is superfluous in melanoma surveillance when patients also undergo PET-CT scanning and may constitute a risk of overtreatment due to false positive findings.

EA DV CONGRESS
VIENNA
30 SEP - 3 OCT 2026

Abstract N°: 2276

Prognostic value of neutrophil-to-lymphocyte ratio in mycosis fungoides: a retrospective single-centre study

Miguel Limeres de la Rosa*[1], Andrea Isabel Rodriguez-Sanna[1], Francisco Vilchez-Marquez[1], Amanda Núñez García[1], Salvador Arias-Santiago[1]

[1] Hospital Universitario Virgen de las Nieves, Granada, Spain

Introduction

Mycosis Fungoides (MF) accounts for up to 50% of all primary cutaneous lymphomas, representing 60-72% of all cutaneous T-cell lymphomas. A higher neutrophil-to-lymphocyte ratio (NLR) at baseline correlates with poor prognosis in numerous malignancies. However, this relation is still not clear for MF. The aim of this study was to evaluate the prognostic value of baseline NLR in patients with MF and to assess its association with disease stage, progression and time to progression.

Materials and Methods

This retrospective, single-centre study included patients with a confirmed diagnosis of MF between January 2008 and February 2026. Clinical and laboratory data, including disease stage and NLR, were collected at baseline. Staging was performed according to standard clinical criteria at the time of diagnosis.

Patients were followed longitudinally to assess clinical outcomes. Disease progression and time to progression were recorded. Progression was defined based on worsening of clinical stage or an increase in disease burden according to established criteria. Overall survival and time to death were also documented when applicable.

Results

The study included 32 patients, with 59.38% (19/32) being male and 40.63% (13/32) being female. At the time of diagnosis, the mean age of patients was 64.25 years (SD = 14.47). Most patients (87.50%, 28/32) presented with early-stage disease (IA, IB or IIA), while 12.50% (4/32) had advanced-stage disease (IIB, III or IV). Mean baseline mSWAT score was 9.21 (SD = 6.55). Mean lactate dehydrogenase (LDH) at diagnosis was 220.87 (SD = 8.17), and mean baseline NLR was 2.20 (SD = 1.17). Disease progression occurred in 15.6% (5/32) of patients, with a mean time to progression of 30.80 months (SD = 1.17). Overall mortality was 12.5% (4/32), with a mean time to death of 19.50 months (SD = 7.78).

An NLR cut-off value of 2 was established based on the mean of our cohort, resulting in two equally sized groups: 50% of patients with NLR < 2 and 50% with NLR > 2. No statistically significant differences were observed between the groups regarding age or sex. Similarly, no significant differences were found in disease stage distribution. Among patients with NLR < 2, 81.25% (13/16) had early-stage disease and 18.75% (3/16) had advanced-stage disease. In the NLR > 2 group, 93.75% (15/16) had early-stage disease and 6.25% (1/16) had advanced-stage disease. Although differences in baseline mSWAT scores were not statistically significant, patients with NLR < 2 had a lower mean mSWAT (8.50) compared to those with NLR > 2 (10.17). No differences in progression rates were observed between the two groups (18.75% vs 12.50%). However, a statistically significant difference was found in the time to progression: patients with NLR < 2 had a longer time to progression (48.33 months) when compared with those with NLR > 2 (4.50 months, p = 0.04). Due to the limited number of events, no conclusions

could be drawn regarding the association between NLR and mortality.

Conclusions

Baseline NLR may represent a useful prognostic biomarker in patients with MF. Although no association was observed with disease stage or progression rates, a higher NLR was significantly associated with a shorter time to progression. These findings suggest that NLR could help identify patients at higher risk of early disease progression, warranting closer monitoring.

EA DV CONGRESS
VIENNA
30 SEP - 3 OCT 2026

Abstract N°: 2283

When the face raises doubt: An atypical presentation of mycosis fungoides

Hind Majdoul*[1], Fouzia Hali[1], Soumiya Chiheb[1]

[1] Dermatology and Venereology Department, Ibn Rochd University Hospital, Casablanca, Morocco

Introduction

Mycosis fungoides (MF) is an indolent cutaneous T-cell lymphoma. In its folliculotropic form, isolated facial involvement is particularly rare and perplexing. This atypical presentation poses major diagnostic challenges, both clinically and histologically. Early recognition is crucial, but treatment remains complex due to its unpredictable evolution.

This case report perfectly illustrates the complexity of this entity, as evidenced by the long journey of our patient.

Case Presentation

A 47-year-old patient with a history of occupational exposure to hydrocarbons presented with non-pruritic facial and neck lesions and progressive loss of beard, eyelashes, and eyebrows, evolving over the past 6 months. Clinical examination revealed two infiltrated, hyperpigmented, and depilated papulo-nodular plaques: the largest on the left temporo-malar region, extending to the nasolabial fold, labial commissure, and part of the upper lip; and the other in the right peri-orbital area, resulting in striking facial asymmetry. Also noted was a non-infiltrated occipital alopecic plaque, as well as the absence of eyelashes and eyebrows. The rest of the examination revealed bilateral, mobile, and painless cervical lymphadenopathy. The diagnosis of cutaneous lymphoma was initially suspected but only confirmed after several skin biopsies at different stages of the disease's natural evolution. Histological ambiguity even led to a clonality study, which confirmed the malignant nature and CD4+ phenotype of the lymphoproliferation, without being able to definitively classify it. The staging workup concluded to stage IIB. Initial treatment included topical and systemic corticosteroids along with methotrexate before switching to interferon alpha. After multiple failures, polychemotherapy was initiated, starting with the GEMOX regimen, followed by a more aggressive CHOEP regimen, resulting in a favorable clinical outcome.

Conclusion

The folliculotropic variant of mycosis fungoides (MF) is a common form of MF, characterized by erythematous, sometimes confluent, follicular papules associated with depilation, alopecia, comedones, cysts, or acneiform plaques, or more rarely, true tumorous lesions. However, isolated facial involvement is an unusual manifestation that is rarely reported in the literature, requiring heightened vigilance from both dermatologists and histopathologists. Clinically, it can mimic other inflammatory or infectious facial dermatoses, often delaying the diagnosis due to the absence of typical lymphoma signs. Histologically, lymphocytic infiltrates may be subtle, poorly or inadequately characterized, making biopsy interpretation more difficult. In terms of treatment, resistance in facial localizations is often very challenging. Although topical treatments like corticosteroids may offer some initial relief, systemic management is frequently necessary, with options such as retinoids, methotrexate, or phototherapy. Chemotherapy remains reserved for aggressive, advanced, or resistant forms. Biological therapies also offer promising perspectives for refractory cases. Achieving sustained remission can be difficult, and the prognosis remains uncertain, dependent on both clinical evolution and therapeutic response.

EADV Congress 2026, VIENNA
30 SEPTEMBER - 03 OCTOBER 2026
POWERED BY M-ANAGE.COM

EADV CONGRESS
VIENNA
30 SEP - 3 OCT 2026

Abstract N°: 2295

Primary Cutaneous Diffuse Large B-cell Lymphoma, Leg Type: A Rare Case of Aggressive Bilateral Leg Tumours

Bai Han Ooi*[1], Pei Ling Low[2], Ruhana Amirah Abdul Halim[3], Khairunnisa Muhammad Zuhaidi[3], Hock Leng Lee[1]

[1] Dermatology Unit, Hospital Taiping, Taiping, Malaysia
[2] Hematology Unit, Hospital Taiping, Taiping, Malaysia
[3] Histopathology Unit, Hospital Taiping, Taiping, Malaysia

Introduction

Primary cutaneous diffuse large B-cell lymphoma, leg type (PCDLBCL-LT) is a rare entity of haematological malignancies which accounts for about 1%-3% of all cutaneous lymphomas. It occurs predominantly in elderly women, presenting with rapidly growing tumours on one or both legs and extracutaneous dissemination. Given its rarity and aggressive behaviour, this case report aims to highlight the clinical and pathological features of the disease, enabling timely diagnosis and prompt treatment.

Case Presentation

We report a 57-year-old lady with underlying hypertension and dyslipidemia, who presented with bilateral huge nodular plaques at the right ankle and left lower leg with overlying crusted ulcers. The lesions persisted for 2 years, during which she was under orthopaedic care for a chronic non-healing wound for which she received multiple antimicrobials. Possible differentials include deep fungal infection, cutaneous tuberculosis, mycetoma and cutaneous malignancies. A skin biopsy and tissue cultures were sent. Empirically, she was commenced on trimethoprim-sulfamethoxazole therapy. However, due to lack of response, she was subsequently switched to itraconazole 200mg twice daily. Her skin biopsy then revealed medium to large neoplastic lymphoid cells with round nuclei and mitotic figures. Immunohistochemical stain showed positivity to CD20, MUM-1 and BCL-2 alongside a negative BCL-6 and CD10 stain. Consistent with activated B-cell phenotype of DLBCL, the distinct immunophenotypic pattern of PCDLBCL-LT suggests an aggressive nature of the tumour which carries a grave prognosis. Her computed tomographic(CT) scan showed extracutaneous manifestation of bilateral external iliac, inguinal and left cervical lymphadenopathy. She received one cycle of rituximab, cyclophosphamide, doxorubicin, vincristine, and prednisone (R-CHOP), five cycles of rituximab, cyclophosphamide, etoposide, vincristine, and prednisone (R-CEOP) followed by one cycle of fractionated cyclophosphamide, vincristine, adriamycin, and dexamethasone (hyper-CVAD) part B chemotherapy, under haematology care. Her leg tumours were deemed refractory to previous chemotherapy, showing signs of expansion and new surrounding lesions. She was then given another three cycles of rituximab, ifosfamide, carboplatin and etoposide (R-ICE) as part of the salvage chemotherapy regime. She is now due for positron emission tomography (PET) and CT scan as an end-of-therapy assessment.

Conclusion

Compared with other cutaneous B-cell lymphomas, PCDLBCL-LT carries a poorer prognosis, with frequent relapses and extracutaneous dissemination. In this case, the distribution and multiplicity of the lesions represent adverse

prognostic factors. Early recognition of its characteristic clinical features is essential to enable timely diagnosis and prompt treatment initiation, which may improve disease outcomes. Emerging therapies, including bispecific T-cell engager (BiTE) therapy, radiotherapy, haematopoietic stem cell transplantation, and novel targeted agents, may further enhance treatment efficacy in the future.

EA DV CONGRESS
VIENNA
30 SEP - 3 OCT 2026

Abstract N°: 2304

Teledermatology for Skin Lesion Assessment in the Department of Dermatology, NHS Grampian, Scotland

Alexandra Bonsall*[1], Michelle McNeil[1], Julie McIntosh[1]

[1] NHS Grampian, Aberdeen, United Kingdom

Introduction

The Department of Dermatology in NHS Grampian, Scotland, UK, covers a population of over 500,000 people living in an area spanning approximately 3000 square miles. We accept referrals for skin lesion assessment on a Routine, Urgent and Urgent Suspected Cancer basis. GPs are encouraged to include current images of the lesion with their referral, with the Department providing advice at point of vetting where possible. Despite that, once seen in clinic many lesions referred as USC are benign, and some lesions referred routinely are melanoma or SCC. By November 2025, 1,125 patients on our Routine New Lesion waiting list had waited more than 52 weeks, and there was a risk that patients with melanoma or non-melanoma skin cancer could be within this group.

Materials and Methods

After considering options, we devised a local pathway similar to others in use across the UK, in which patients on this waiting list were appointed to community hubs, for images to be taken of their lesion by trained Healthcare Support Workers. From there, the patients were appointed to teledermatology clinics, for remote review of their images by Consultant Dermatologists. From those clinics, letters were sent to patients and their GP with relevant diagnosis and treatment or management advice, and patients were outcomed to: discharge with advice having been given; a minor surgery appointment; or requiring face to face clinic review.

Results

Between December 2025 and April 2026, 690 patients were assessed over this pathway. Of those patients, data from 455 patients assessed by one clinician was reviewed. 268 (59%) of 455 patients were managed remotely with advice. 92 (20%) of patients required a minor surgery appointment. 92 (20%) required f2f review, and 1 (<1%) were referred for other investigation, which was an ultrasound scan of a neck lump. The main reason for face to face review was the patients having originally been referred for assessment of multiple lesions. A further review of 25 of the 92 patients appointed for minor surgery, indicated that 23 (92%) of the 25 patients were discharged following their procedure.

Conclusions

The data indicates that the majority of patients on a lesion waiting list can be managed efficiently using teledermatology. We plan to extend use of this teledermatology pathway for all patients referred for lesion assessment, unless there is a clear clinical or social reason at the vetting stage for them to require a direct face to face, or minor surgical appointment. By doing this we hope to better manage our lesion waiting lists overall, and expedite review and treatment for patients with skin cancer.

EADV CONGRESS
VIENNA
30 SEP - 3 OCT 2026

Abstract N°: 2312

A rare presentation of 2 diseases of different pathogenesis: A diagnostic and therapeutic challenge

Sarah Akram Kamal Hussein Orabi*[1]

[1] Cairo University, Dermatology Department, Cairo, Egypt

Introduction

As both clinical and dermatopathological findings in MF occasionally closely imitate other dermatoses, correct diagnosis may be a challenge both for clinicians as well as dermatopathologists (Wobser et al. 2015). If sarcoidosis and lymphoma occur in association, lymphoma almost invariably develops subsequent to sarcoidosis after disease-free intervals of a number of years (Brincker 1989). This association between MF and sarcoidosis is relatively rare with few reported cases and is even rarer if sarcoidosis onset follows MF.

Case Presentation

A 30-year-old female patient presented to the cutaneous lymphoma unit, Dermatology Department with slowly progressive scaly hypo and hyperpigmented skin patches of 15 years duration that started on the face and extended to become generalized for which active treatment was never prescribed. The condition was associated with multiple asymptomatic skin swellings on the head and both elbows of 2 months duration. The patient also complained of scaly scalp with diffuse hair loss. The patient also had fever and arthralgia. The patient is wheelchaired suffering from post-polio paralysis of both legs since she was a child. No medications were taken prior to the onset of the skin lesions and family history was irrelevant. On examination, there was generalized hypo and hyperpigmented scaly dusky erythematous skin patches with atrophy and telangiectasia(poikiloderma)together with multiple firm nontender skin nodules on both sides of the patient's forehead, inner aspects of both arms as well as both elbows ranging from few mm to 2 cm. The scalp was scaly with diffuse non-cicatricial alopecia(Figure 1). A written informed consent was taken from the patient. Investigations were done and routine laboratory tests were normal(complete blood count, liver and kidney functions, serum vitamin D). However, the 24-hour urinary calcium was elevated; 376.5 mg/24h(reference range: 100-300 mg/24h). Also, the angiotensin converting enzyme (ACE) was elevated;69 U/L(reference range: 8-52 U/L). Blood culture revealed no growth of organisms. Chest X-ray, transthoracic echocardiography, and abdominopelvic ultrasound were all normal. The high-resolution computed tomography(CT) scan of the chest was unremarkable apart from bilateral axillary lymphadenopathy for which lymph node ultrasound was done. The lymph nodes ultrasound showed reactive cervical and axillary lymph node enlargement.

he first biopsy demonstrated acanthotic epidermis with no spongiosis. Infiltration of atypical, haloed lymphocytes along the dermoepidermal junction and some infiltrated up in the dermis forming epidermoptropism. The lymphocytes showed hyperchromasia, polymorphism and angulation of their shapes. The papillary dermis showed patchy band lymphocytic infiltration, wiry fibroplasia of the papillary dermis together with telangiectasia and scattered melanophages. The deeper part of the dermis and subcutaneous fat demonstrated discrete granulomas with surrounding fibrosis and minimal lymphocytic infiltrate. The granulomas were non caseating and formed of epithelioid histiocytes and giant cells. No foreign bodies were noted within the granulomas. The second biopsy demonstrated acanthotic epidermis with epidermotropism of atypical, haloed lymphocytes. The dermis demonstrated patchy band lymphocytic infiltrate of small to medium sized lymphocytes, together with telangiectasia and scattered melanophages.

Based on the clinical and pathologic findings this case was diagnosed with sarcoidosis associated with MF plaque stage.



Clinical presentation of the patient A, B: Sarcoidosis presenting as multiple firm nontender skin nodules on both sides of the patient's forehead, inner aspects of both arms as well as both elbows ranging from few mm to 2 cm;

Conclusion

MF could be associated with sarcoidosis unpredictably through the course of disease although their association is relatively rare. Our case report should alert the dermatologists about possibility of occurrence of two distinct skin diseases with different underling pathogeneses.

EADV CONGRESS
VIENNA
30 SEP - 3 OCT 2026

Abstract N°: 2323

Atypical lower limb presentation of primary cutaneous CD4+ small/medium T-cell lymphoproliferative disorder: diagnostic and management challenges

Fredo Da Silva*[1], Sian McGarel[1], Rory Barry[1], Sarah Fleming[1], Michael O'Connell[1], Fergus MacSweeney[1]

[1] University Hospital Waterford, Waterford, Ireland

Introduction

Primary cutaneous CD4+ small/medium T-cell lymphoproliferative disorder (PCSM-TCLPD) is a rare, indolent cutaneous T-cell proliferation that typically presents as a solitary, asymptomatic purple to erythematous nodule, plaque, or tumour localised to the head, neck, and upper trunk. However, its clinical presentation is broad, with reports of multiple lesions, atypical locations, symptomatic cases, and reports in children. Diagnosis is confirmed by histology and immunohistochemistry. Its treatment usually involves intralesional steroids, surgical excision and, in many cases, spontaneous resolution after biopsy. In rare cases, radiotherapy or chemotherapy may be necessary. We highlight the diagnostic and therapeutic challenges of an atypical presentation of this rare lymphoproliferative condition localised below the knees.

Case Presentation

We present the case of a 51-year-old male with a 2-year history of multifocal violaceous maculopapular lesions on the right medial foot, together with a large, diffuse macular lesion on the left medial calf. In addition, these were associated with intermittent stinging pain, pruritus, and scaling, but no B-symptoms were detected. Baseline blood investigations were unremarkable. Initial suspicion favoured an inflammatory or vascular process, and the patient was treated with topical steroids, but without benefit.

Histological features showed a dense upper- to mid-dermal lymphoid infiltrate of small- to medium-sized atypical T-cell lymphocytes. The infiltrate extended into adnexal structures, and there was focal epidermotropism. The atypical T cells showed an immunophenotype of CD3 positivity with preserved CD5 and CD7 expression, and a predominance of CD4 over CD8. They expressed PD-1 and partial BCL-6 positivity but were negative for CD10. The Ki-67 proliferation index was low, estimated at <10%. Monoclonal T-cell receptor beta and gamma chain gene rearrangements were detected. PET/CT scan and bone marrow biopsy excluded systemic involvement.

This case illustrates a less typical, mixed-pattern manifestation of PCSM-TCLPD localised to an unusual site, which may mimic vascular or inflammatory dermatoses and potentially delay clinical diagnosis. Due to the bilateral distribution and extent of disease, surgical excision was unsuitable. Local radiotherapy was not recommended after discussion with Oncology due to the large field of involvement, raising some management difficulties. Gradual and symptomatic resolution was achieved after 32 sessions of psoralen plus ultraviolet A (PUVA) therapy, which was well tolerated, with the patient remaining asymptomatic at 6-month follow-up. Evidence supporting PUVA therapy in PCSM-TCLPD remains limited.

Conclusion

Atypical PCSM-TCLPD without systemic involvement may present in unusual anatomical distributions. When disease extent is a limitation, PUVA may represent a feasible therapeutic alternative, although further research is needed to optimise management strategies, improving our understanding of this rare condition.

EADV CONGRESS
VIENNA
30 SEP - 3 OCT 2026

Abstract N°: 2324

A Case of Amelanotic Subungual Melanoma

Imane Chraiki*[1], Bendaoud Layla[1], Mariem Aboudourib[1], Ouafa Hocar[2], Said Amal[1]

[1] Dermatology-Venereology Department, Mohamed VI University Hospital, Marrakesh, Morocco
[2] Dermatology-Venereology Department, Mohamed VI Hospital, Marrakesh, Morocco

Introduction

Subungual melanoma is a rare melanocytic tumor that represents a true diagnostic challenge, both clinically and histologically. It accounts for 1.8% to 8.1% of cutaneous malignant melanomas.
We report the case of a patient with amelanotic subungual melanoma.

Case Presentation

A 64-year-old woman with Fitzpatrick skin phototype III presented with nail dystrophy and recurrent friability of the fourth left fingernail evolving over one year, with no history of trauma. The course was marked by the appearance of a bleeding exophytic mass.

Clinical examination revealed an ulcerated, exophytic nodule arising from the nail bed, without associated pigmentation or palpable lymphadenopathy. Dermoscopic evaluation showed a milky-red background, central ulceration, irregular linear and hairpin vessels, and a 1 mm peripheral pigmentation.

Skin biopsy revealed an ulcerated malignant cellular proliferation infiltrating the reticular dermis, with immunohistochemical findings consistent with malignant melanoma. The staging evaluation revealed no evidence of metastasis.

Histopathological examination of the amputated specimen demonstrated an amelanotic acral lentiginous melanoma, nodular subtype, ulcerated and infiltrating the hypodermis, with Clark level V and a Breslow depth of 11 mm. No bone involvement was identified. Sentinel lymph node biopsy was negative.

The tumor was classified as stage IIC, and the patient was referred for specialized oncologic management.

Conclusion

Amelanotic subungual melanoma is rare and may mimic other benign and malignant conditions. The presence of isolated nail dystrophy should prompt thorough evaluation and requires regular follow-up.

EADV CONGRESS
VIENNA
30 SEP - 3 OCT 2026

Abstract N°: 2328

The association between occult metastasis size and mortality in stage IIIA melanoma: A nationwide population-based registry study

Rasmus Mikiver[1, 2], Michelle Marjanovic[3, 4], Kari Nielsen[5, 6, 7, 8], Karolin Isaksson[5, 9, 10], Magdalena Claeson*[3, 4]

[1] Department of Biomedical and Clinical Sciences, Linköping University, Regional Cancer Center Southeast Sweden and Department of Clinical and Experimental Medicine, Linköping, Sweden

[2] Regional Cancer Center Southeast Sweden and Department of Clinical and Experimental Medicine, Linköping University, Linköping, Sweden

[3] Department of Dermatology and Venereology, Institute of Clinical Sciences, Sahlgrenska Academy, University of Gothenburg, Department of Dermatology and Venereology, Sahlgrenska University Hospital, Region Västra Götaland, Gothenburg, Sweden

[4] Department of Dermatology and Venereology, Sahlgrenska University Hospital, Gothenburg, Region Västra Götaland, Gothenburg, Sweden

[5] Lund University Cancer Center, LUCC, Lund University, Lund, Sweden

[6] Department of Dermatology, Skåne University Hospital, Lund, Sweden

[7] Department of Clinical Sciences Lund, Faculty of Medicine, Lund University, Lund, Sweden

[8] Lund University Skin Cancer Research Group, Dermatology, Department of Clinical Sciences Lund University, Lund, Sweden

[9] Department of Clinical Sciences, Surgery, Lund University, Lund, Sweden

[10] Department of Surgery, Skåne University Hospital, Kristianstad, Sweden

Introduction

Sentinel lymph node (SLN) status forms the basis of staging in cutaneous melanoma, but key aspects of nodal disease are still not fully represented in classifications. Currently, the melanoma staging system incorporates the number of involved lymph nodes and whether metastases are detected clinically or in the sentinel lymph node, but does not include the size of the occult metastases. Stage IIIA melanoma is classified as T1–T2a tumours with clinically occult nodal metastasis (N1a–N2a). Patients with stage IIIA melanoma have favourable survival outcomes (5-year survival in Sweden: 87%), despite nodal involvement. Prior studies from specialized institutions have shown that the SLN burden may further refine prognostic stratification in stage IIIA. This study aimed to evaluate whether, in population-based registry data as well, the size of the occult lymph node metastasis is associated with melanoma mortality.

Materials and Methods

Data were collected from a cohort of adults with a diagnosis of stage II-III melanoma from the Swedish Melanoma Register (SweMR), between January 1, 2001, and December 31, 2018, who were all pathologically staged with SLN biopsy. Information on occult metastasis size was consistently recorded in the SweMR from 2013. The data item was defined as the maximum diameter of the largest occult metastatic deposit in the SLN, as measured by the pathologist. In this study, occult metastasis size was categorized into two groups (≤1.0 vs >1.0 mm) to stabilize models with few cases. Cox proportional hazards models were used to estimate hazard ratios (HRs) with 95% confidence intervals (CIs) for the association with melanoma-specific mortality. A multivariable model was adjusted for age, sex, thickness, and the presence of ulceration.

Results

In the SweMR cohort of N=5,815 melanoma patients, information on the occult metastasis size were available for 217 stage IIIA patients. Among those, 11 (5.1%) had died from melanoma during follow-up, while 206 were either alive at 2018-12-31 or had died from other causes. Larger occult metastasis size (>1.0 mm versus ≤1.0) was associated with an increased risk of melanoma-specific mortality (HR 9.34, 95% CI 1.18-73.68) in the fully adjusted model.

Conclusions

In nationwide, population-based melanoma registry data from Sweden, the occult metastasis size in stage IIIA patients was strongly and independently associated with melanoma-specific mortality. These findings may have important future implications for risk stratification, as well as for individualized treatment and surveillance strategies. However, the estimates lacked precision and larger studies are warranted.

EADV CONGRESS
VIENNA
30 SEP - 3 OCT 2026

Abstract N°: 2340

Giant ulcerated gluteal Merkel cell carcinoma mimicking soft tissue sarcoma

salma larabi*[1]

[1] Department of dermatology, Ibn Sina University Hospital ,Rabat , Morocco, rabat, Morocco

Introduction
Merkel cell carcinoma (MCC) is a rare and highly aggressive cutaneous neuroendocrine carcinoma, typically occurring in elderly patients on sun-exposed areas. Atypical localizations may lead to diagnostic delay. We report a case of MCC arising in an unusual gluteal location presenting as a giant ulcerated tumor.

Case Presentation
A 60-year-old man, a former farmer and chronic smoker, with a history of inguinal hernia repair, presented with a right gluteal tumor evolving over six months. The lesion initially appeared as a painful papule, complicated by secondary ulceration after local manipulation. Several courses of antibiotic therapy were ineffective, while the tumor rapidly increased in size.

Clinical examination revealed a large ulcerated, exophytic, and hemorrhagic mass of the right buttock, measuring approximately 15 cm, with irregular borders, an indurated base, and contact bleeding. Ecchymotic lesions were also observed on the ipsilateral thigh.

Thoraco-abdomino-pelvic CT scan showed a large heterogeneously enhancing tumor arising from the right gluteal subcutaneous tissue (121 × 111 × 59 mm), with bilateral inguinal lymphadenopathy, more prominent on the right side, and no distant metastases. According to the TNM classification , the disease was staged as cT3 N2 M0 (stage III).

Differential diagnoses included angiosarcoma, soft tissue sarcoma, amelanotic melanoma, infiltrating squamous cell carcinoma, and cutaneous metastases.

Histopathological examination of a skin biopsy revealed a malignant neuroendocrine tumor. Immunohistochemistry showed positivity for cytokeratins (CK20), chromogranin A, and synaptophysin, and negativity for TTF-1, confirming Merkel cell carcinoma.

Conclusion
Merkel cell carcinoma is an aggressive cutaneous malignancy associated with Merkel cell polyomavirus and ultraviolet exposure. Although classically located on sun-exposed skin, it may arise in atypical sites such as the gluteal region, contributing to delayed diagnosis.

Clinically, MCC can closely mimic other rapidly growing malignant tumors, particularly soft tissue sarcomas, when presenting as large ulcerated and hemorrhagic masses. Imaging is essential for staging and assessment of lymph node involvement, which are major prognostic factors, but histopathology with immunohistochemistry remains decisive for diagnosis by demonstrating neuroendocrine differentiation (CK20, chromogranin A, synaptophysin).

Given its aggressive behavior and poor prognosis, early recognition is critical. Management relies on surgical

excision when feasible, radiotherapy, and immune checkpoint inhibitors in advanced disease. This case highlights the need to consider MCC in the differential diagnosis of rapidly evolving ulcerated tumors, even in atypical locations, and emphasizes the importance of early biopsy to avoid diagnostic delay and improve outcomes.

EADV CONGRESS
VIENNA
30 SEP - 3 OCT 2026

Abstract N°: 2350

Cutaneous Adenoid Cystic Carcinoma of the Forearm Mimicking Pilomatricoma: A Diagnostic Pitfall

salma larabi*[1]

[1] Department of dermatology, Ibn Sina University Hospital ,Rabat , Morocco, rabat, Morocco

Introduction

Cutaneous adenoid cystic carcinoma (CACC) is an exceptionally rare malignant adnexal tumor, with only isolated cases reported in the literature. It most commonly arises from secretory glands such as salivary, lacrimal, ceruminous, or genital glands, while primary cutaneous involvement remains uncommon.

When present in the skin, CACC predominantly affects the head and neck region, whereas localization on the extremities is exceptional. Although generally slow-growing, this tumor is characterized by a marked propensity for perineural invasion, contributing to its locally aggressive behavior.

Clinically, CACC often presents as a nonspecific cutaneous nodule, frequently leading to misdiagnosis as benign adnexal tumors and delayed diagnosis.

We report an additional rare case of CACC arising on the forearm, initially misdiagnosed as pilomatricoma.

Case Presentation

We report the case of a 65-year-old man with a history of chronic smoking and no significant medical comorbidities.

He presented with a solitary lesion on the left forearm, evolving over one year. Initially asymptomatic, the lesion later became pruritic and progressively increased in size.

Clinical examination revealed a well-circumscribed, firm, non-tender subcutaneous nodule measuring 2 cm in diameter. Dermoscopic examination was non-contributory.

Based on its clinical appearance and consistency, a diagnosis of pilomatricoma was initially suspected.

An excisional biopsy was performed.

Histopathological examination revealed a dermal and subcutaneous tumor composed of basaloid cells arranged in a cribriform pattern with characteristic “Swiss cheese” pseudocystic spaces filled with mucin. Focal perineural invasion was identified, without lymphovascular invasion.

Immunohistochemistry showed tumor positivity for CK7, smooth muscle actin (SMA), CD117, EMA, CK5/6, and SOX10, supporting the diagnosis of adenoid cystic carcinoma.

Conclusion

Cutaneous adenoid cystic carcinoma is a rare malignant adnexal tumor that may clinically mimic benign subcutaneous lesions, particularly pilomatricoma, epidermoid cysts, or other adnexal tumors, especially when located in atypical sites such as the extremities.

This diagnostic pitfall is reinforced by its indolent and well-circumscribed clinical appearance, in contrast with its histological aggressiveness, characterized notably by frequent perineural invasion and a significant risk of local recurrence. This discrepancy underscores the importance of considering malignant adnexal tumors in the differential diagnosis of any persistent or atypical subcutaneous nodule.

Definitive diagnosis relies on histopathological examination, which remains essential to avoid misdiagnosis and delayed management. Immunohistochemistry, including expression of CK7, CK5/6, CD117, EMA, SOX10, and SMA, further supports the diagnosis and helps exclude morphologic mimickers such as basaloid carcinoma or trichoblastoma.

Management is based on wide local excision with clear margins, ideally up to 2 cm when anatomically feasible. Given the infiltrative nature and risk of late local recurrence, long-term follow-up is mandatory.

EADV CONGRESS
VIENNA
30 SEP - 3 OCT 2026

Abstract N°: 2354

PRAME Expression as a Prognostic Biomarker in Merkel Cell Carcinoma: A Multicenter Retrospective Study

Estrella Cobos Bonilla*[1], Ana María Montaña Ramírez[2], Rosa Rendón García[2], Carmen María Alfonso Rosa[2], Gonzalo Alonso Fernández de Gatta[2], francisco rivas ruiz[1], Antonio Archidona Arranz[1], Rafael Fúnez Liebana[1], Juan José Ríos Martín[2], Jesús Machuca Aguado[2]

[1] Costa del Sol Hospital, Marbella, Spain
[2] Virgen Macarena Hospital, Sevilla, Spain

Introduction
Merkel cell carcinoma (MCC) is a highly aggressive primary cutaneous neuroendocrine neoplasm. Although it is a rare tumor, its incidence has increased in recent years. In this context, PRAME (Preferentially Expressed Antigen in Melanoma), poliomavirus infection and P53 immunostainings have recently been proposed as a potential prognostic marker in this type of carcinoma. Given the high morbidity and mortality associated with MCC, the identification of new prognostic factors could have a significant impact on clinical decision-making and on optimizing the management of these patients.

Objectives:

- To assess PRAME, poliomavirus and P53 expression in MCC
- To evaluate their prognostic value and association with survival

Materials and Methods
A retrospective multicenter observational study was conducted in two tertiary hospitals in Spain. Patients with histologically confirmed MCC and complete clinical and pathological data were included. PRAME positivity was defined as staining in >50% of tumor cells, evaluated by two pathologists. Statistical analyses included chi-square/Fisher tests, t-test or Mann–Whitney, Cohen's Kappa, and Kaplan–Meier survival analysis with Log-Rank testing ($p < 0.05$).

Results
Out of 77 patients, 65 were included. The mean age was 76.1 years, and tumors were most commonly located in the head and neck region. Nine patients were immunosuppressed. Thirty patients developed nodal metastases, ten had distant metastases, and fifteen experienced recurrence. Lymphovascular invasion was observed in 13 cases, and the mean tumor size was 22 mm. PRAME expression was positive in 35.4% of primary tumors.

Immunohistochemistry for polyomavirus was evaluable in only 34 samples, being positive in 19 cases (55.9%). P53 could be assessed in 37 cases and was mutated in 67.6%.

A significant association was found between PRAME positivity in primary tumors and nodal metastases (65.2% vs 35.7%; $p = 0.043$). The association with overall metastasis showed a non-significant trend.

In disease-free survival analysis ($n = 53$; 15 events), PRAME-positive tumors were associated with significantly shorter survival (115.85 vs 214.41 months; HR 3.07; $p = 0.017$). However, no statistically significant differences were observed in overall survival ($n = 63$; 20 events; $p = 0.323$).

Although polyomavirus infection and p53 mutation did not show statistically significant associations ($p > 0.05$), there appears to be a trend toward reduced survival in patients who are polyomavirus-negative and harbor p53 mutations.

Conclusions

This study presents the largest series of MCC with immunohistochemical analysis of PRAME, poliomavirus and P53.

PRAME expression was significantly associated with the presence of nodal metastases, recurrences, and shorter disease-free survival. Therefore, we propose that positive PRAME immunohistochemical expression could serve as an additional prognostic marker in MCC, with potential impact on follow-up strategies and treatment of these patients.

Despite the absence of statistically significant associations for polyomavirus infection and p53 mutation ($p > 0.05$), a tendency toward poorer survival was observed among patients who were polyomavirus-negative and had p53 mutations.

EA DV CONGRESS
VIENNA
30 SEP - 3 OCT 2026

Abstract N°: 2357

Acral Lentiginous Melanoma Arising Over a Calcaneal Spur

Mohammad Azouagh*[1], Feryel Amri[1], Mariem Tabka[1], Aida Khadhar[2], Asmahane Souissi[1], ines chelly[2], Mourad Mokni[1]

[1] Dermatology department, La Rabta Hospital, Tunis, Tunisia
[2] Anatomopathology department, La Rabta Hospital, Tunis, Tunisia

Introduction

Cutaneous melanoma accounts for approximately 4% of skin tumours but is responsible for more than 75% of skin cancer–related mortality. Although uncommon overall, acral lentiginous melanoma (ALM) is the most frequent melanoma subtype in Tunisia, typically affecting the palms, soles, and nail apparatus. We report an original case of ALM occurring on the heel in association with a calcaneal spur, suggesting a potential contributory role of chronic local trauma.

Case Presentation

A 74-year-old woman had been followed for nine months for a left calcaneal spur, treated with repeated local corticosteroid injections. Six months prior to presentation, she noticed the gradual appearance of a pigmented macule on the ipsilateral heel. Detailed history revealed that the plantar surface had been free of lesions before the diagnosis of the calcaneal spur and the initiation of injections. Initially considered to be a haematoma, the lesion progressively increased in size and changed in pigmentation, prompting specialist consultation.

Clinical examination revealed an asymmetric 3 cm macule with irregular borders and heterogeneous pigmentation. Dermoscopic evaluation showed polymorphous pigmentation with structureless areas, eccentric pseudopods, and a parallel ridge pattern, highly suggestive of ALM. Histological examination confirmed the diagnosis, with a Breslow thickness of 3 mm and Clark level III. Staging investigations showed no evidence of metastasis. The tumour was classified as stage IIA, and wide surgical excision with 2 cm margins combined with sentinel lymph node biopsy was planned.

Conclusion

ALM differs from other melanoma subtypes by its lack of association with ultraviolet exposure, its predilection for acral sites, and its distinct molecular profile, characterised by a higher frequency of *KIT* mutations compared with *BRAF* mutations.

The role of trauma in the development of ALM remains controversial. However, several series, particularly from Asian populations, have reported an increased frequency of acral melanomas arising in areas subjected to repeated trauma or chronic mechanical stress. In the present case, the temporal association between the onset of the calcaneal spur, repeated local injections, and the development of melanoma on a previously unaffected area suggests a possible facilitating role of chronic microtrauma, although a direct causal relationship cannot be established.

Beyond diagnostic delay—often related to initial misinterpretation of the lesion as a benign post-traumatic change—some studies suggest that trauma may represent an independent adverse prognostic factor in acral melanoma, particularly at early stages, as illustrated by our observation.

This case highlights the potential occurrence of plantar acral lentiginous melanoma in the context of chronic trauma related to a calcaneal spur. It underscores the need for heightened clinical vigilance when evaluating any new pigmented lesion arising in areas exposed to repeated microtrauma, in order to minimise diagnostic delay and improve patient prognosis.

EA DV CONGRESS
VIENNA
30 SEP - 3 OCT 2026

Abstract N°: 2372

Intravascular T-Cell Lymphoma presenting with diffuse telangiectasias: A rare and aggressive Case

MOHAND AIT SI ALI*[1], Dalya Fodil[1], Aissa Bachiri[2]

[1] Dermatology department, Central Military Hospital, Algiers, Algeria
[2] Hematology department , Central Military Hospital, Algiers, Algeria

Introduction

Intravascular lymphoma (IVL) is a rare subtype of diffuse non-Hodgkin lymphoma characterized by the proliferation of large lymphoid cells confined to the lumina of small blood vessels, including arterioles, venules, and capillaries. The cutaneous involvement presents as diffuse telangiectasias. The majority of cases exhibit a B-cell phenotype; however, rare instances of T-cell lineage have been reported, along with exceptionally uncommon variants. We describe an unusual case of IVL with a T-cell phenotype.

Case Presentation

A 47-year-old woman presented with an erythematous telangiectatic plaque that had appeared ten months earlier, associated with subcutaneous nodules on the anterior aspect of the left thigh. Her general condition was impaired, with fever and diffuse myalgia.

Within a few weeks, the clinical course was marked by the development of profuse, arborizing telangiectasias involving the trunk and the proximal thighs, with preservation of skin elasticity. An initial histopathological examination of a nodule revealed a mild, non specific pericapillary inflammatory infiltrate associated with both septal and lobular panniculitis. Given the rapid clinical progression, with extension of telangiectatic lesions to nearly the entire trunk and proximal limbs, repeat skin biopsies were obtained from indurated areas.

Histological examination demonstrated a proliferation of large atypical lymphoid cells confined to the lumina of small blood vessels.

Immunohistochemical analysis showed that the atypical cells were positive for CD3 and CD45, negative for CD20, and exhibited a high Ki-67 proliferation index, supporting the diagnosis of intravascular lymphoma of T-cell phenotype. Staging investigations, including hematological assessment, were unremarkable. The patient was treated with six cycles of first line poly-chemotherapy, resulting in complete remission of the cutaneous lesions. However, six months later, relapse occurred, with recurrence of skin lesions accompanied by pulmonary and cerebral involvement, leading to global motor deficit and dysphagia. Despite treatment with four cycles of second line poly-chemotherapy and the initiation of parenteral nutrition, the clinical outcome was fatal.



Arborizing telangiectasias involving the trunk.

Conclusion

This case underscores the rarity and marked aggressiveness of intravascular lymphoma of T cell phenotype, as well as the heterogeneity of its clinical and histopathological features. The presence of acquired diffuse telangiectasias strongly suggets the diagnosis. Although not currently recognized as a distinct entity in the WHO classification, its unique characteristics support consideration as a separate clinicopathological entity

EADV CONGRESS
VIENNA
30 SEP - 3 OCT 2026

Abstract N°: 2378

Real-world study of adjuvant immunotherapy for melanoma in people aged over 65 years

Pedro Naranjo Álamo*[1], Elena Castro Gonzalez[1], Ana Rebolledo Ruiz[1], Maria Luisa Suarez Rizkallal[1], Javier Sanchez Gutierrez[1], Irene Castaño Gonzalez[1]

[1] Universitary Hospital of Gran Canaria Doctor Negrin, Las Palmas of Gran Canaria, Spain

Introduction
Adjuvant immunotherapy (IT) in resected melanoma has improved recurrence-free survival (RFS) in patients, but it causes immune-related adverse effects (iRAEs) that could influence the decision to administer it to older patients. Our aims are to describe the incidence and severity of iRAEs, as well as data on RFS in people aged 65 and over receiving adjuvant IT. As a secondary end point, to compare findings by age group (65–75 years versus over 75 years) and against those aged under 65, and to analyse the relationship between iRAEs and RFS.

Materials and Methods
Retrospective observational study that included patients with stage IIB–IV (M1a) melanoma treated with adjuvant immunotherapy from October 2018 up to October 2025. Demographic variables (age, sex), medical history (history, tumour histological data, stage, treatment received, iRAEs, etc.) and dates relevant to the calculation of RFS were collected and analysed using Kaplan-Meier and Cox regression. The Charlson Comorbidity Index (CCI) was used as a measure of patient comorbidity.

Results
Of 79 patients, 34 (43%) were over 65 years of age. The mean age was 72.4 ± 6.7 years, with a CCI of 3.6 ± 1.1. The most common histological subtype was superficial invasion (38.2%), and the mean Breslow thickness was 4.97 ± 2.87 mm. Ulceration was present in 68.1%, lymphovascular invasion (LVI) in 29.4%, and satellite lesions or metastases in transit in 29.4%. BRAF was mutated in 29.4% of patients.
Most patients were in stage IIIC (58.8%) and 85.3% received pembrolizumab. 11.8% discontinued treatment due to disease progression, whilst 8.8% did so due to adverse effects. 64.7% experienced iRAEs, with grade 3 iRAEs in 5.9% of patients; there were no grade 4–5 iRAEs.
No statistically significant differences were observed in the univariate analysis between age groups (65–75 vs. over 75) in the incidence and severity of iRAEs or in RFS. When comparing those over and under 65 years of age, statistically significant differences were observed in the CCI ($p < 0.01$) with no differences in RFS. The presence of iRAEs was associated with a 60% lower risk of progression in the multivariate Cox model, independent of age, Breslow thickness and ulceration.

Conclusions
Adjuvant IT demonstrated a comparable safety and efficacy profile across age groups. The occurrence of iRAEs was associated with better RFS, supporting its potential prognostic value in real-world clinical practice.

POWERED BY M-ANAGE.COM

EADV CONGRESS
VIENNA
30 SEP - 3 OCT 2026

Abstract N°: 2390

Familial Melanoma: tumor spectrum and clinical outcomes in carriers of germline POT1 variants

Paula Aguilera*[1], Celia Badenas[2], Esther Darder[3], Josep Malvehy[1], Cristina Carrera[1], Joan Bunet[3], Susana Puig[4], Miriam Potrony[5]

[1] Dermatology Department. Hospital Clinic de Barcelona, Universitat de Barcelona, Barcelona, Spain
[2] Biochemistry and Molecular Genetics department. Hospital Clinic de Barcelona, Universitat de Barcelona, Barcelona, Spain
[3] Institut Català d'oncologia, Girona, Spain
[4] Institut d'Investigacions Biomèdiques August Pi i Sunyer. IDIBAPS, Universitat de Barcelona, Barcelona, Spain
[5] Biochemistry and Molecular Genetics department. Hospital Clinic de Barcelona, Barcelona, Spain

Introduction
Germline alterations in ***POT1***, a gene encoding a critical component of the shelterin complex involved in telomere protection, have been increasingly recognized as a cause of inherited cancer susceptibility. Carriers appear to have a predisposition to multiple tumor types, although the breadth of associated malignancies and long-term outcomes are not yet fully established. A deeper clinical understanding is required to better define individual risk and guide surveillance recommendations.

Materials and Methods
We performed a retrospective observational study including 23 individuals carrying germline ***POT1*** variants from five unrelated families. Clinical data, including tumor types, age at diagnosis, and survival outcomes, were obtained through medical record review. Descriptive analyses were conducted to assess tumor distribution and disease evolution.

Results
A total of 23 carriers of pathogenic or likely pathogenic ***POT1*** variants were included: c.233T>C (p.Ile78Thr) (n=3), c.1030G>T (p.Glu344Ter) (n=3), c.255G>A (r.125_255del) (n=2), c.1792G>A (r.1791_1792insAGTA, p.Asp598SerfsTer22) (n=14), and one variant of uncertain significance with suspected pathogenicity, c.670G>A (p.Asp224Asn) (n=1). Thirteen individuals (56.5%) developed at least one malignancy, with melanoma being the most frequent (n=9). Additional tumors included papillary thyroid carcinoma, squamous cell carcinoma, soft tissue sarcoma, angiosarcoma, and osteosarcoma (one case each). Four patients presented with multiple primary melanomas. The mean age at first cancer diagnosis was 43.4 years (range: 17–66), while the mean age at last follow-up or death was 49 years (range: 19–73). Six patients (46.2%) died from cancer, with a mean cancer-specific survival of 3.7 years.

Conclusions
Our findings further support the role of germline ***POT1*** variants in inherited cancer predisposition, revealing a broad and heterogeneous tumor spectrum alongside a substantial impact on survival. These results emphasize the need for tailored and proactive surveillance strategies in affected families.

EA DV CONGRESS
VIENNA
30 SEP - 3 OCT 2026

Abstract N°: 2395

Effect of Extended Longitudinal Dermoscopic Comparison on Melanoma Detection and Overdiagnosis in a High-Risk Cohort.

Louise Shield*[1], Geeta Belgi[1]

[1] University Hospital Southampton NHS Foundation Trust, Southampton, United Kingdom

Introduction
Melanoma overdiagnosis is typically inferred when increased detection is not accompanied by improvements in clinically meaningful outcomes. In high-risk cohorts undergoing total body mapping and serial digital dermoscopy (TBM & SDD) diagnostic thresholds may be influenced by how longitudinal change is assessed. In 2025, we modified our protocol to increase sensitivity to dermoscopic change by comparing lesions with the earliest available image rather than the most recent (approximately 6 months prior) image. This enabled evaluation of whether increased detection reflects overdiagnosis or improved case-finding.

Materials and Methods
We conducted a retrospective analysis of a high-risk cohort undergoing TBM & SDD monitoring from 2019 to 2025. Over 6 years, 274 patients underwent 1166 visits. From 2019–2024, lesions were compared with dermoscopic images from approximately 6 months prior; in 2025, comparison was made with the earliest available image. Outcomes included melanoma diagnoses, melanocytic excisions, and diagnostic yield, defined as melanoma relative to non-melanoma melanocytic lesions and melanoma relative to dysplastic lesions (dysplastic naevi and severely dysplastic naevi). Breslow thickness was analysed annually. Proportions were compared using Fisher's exact test, with odds ratios (OR) and 95% confidence intervals (CI).

Results
A total of 39 melanomas were diagnosed in 2019–2024 compared with 50 in 2025, alongside an increase in melanocytic lesion excisions. The melanoma to non melanoma melanocytic ratio increased from 0.21 (39/187) to 0.31 (50/161), demonstrating a non-significant trend ($p=0.0979$; $OR\approx1.49$, 95% CI ~0.93–2.38). In contrast, the melanoma to dysplastic lesion ratio increased significantly from 0.24 (39/164) to 0.43 (50/115) ($p=0.0146$; $OR\approx1.83$, 95% CI ~1.13–2.96), indicating improved diagnostic yield relative to dysplastic lesions. Mean Breslow thickness showed no consistent downward trend across years (2019–2024 range 0.30–0.70 mm; mean 0.465 mm) and remained comparable in 2025 (0.39 mm).

Conclusions
Increasing sensitivity to longitudinal dermoscopic change was associated with higher melanoma detection and excision rates, with a significant improvement in melanoma yield relative to dysplastic lesions and a non-significant trend toward higher yield overall. The absence of a reduction in Breslow thickness suggests that increased detection was not limited to thinner or potentially less clinically significant melanomas.

These findings support improved detection efficiency rather than overdiagnosis in this high-risk cohort and highlight the value of combining diagnostic yield metrics with tumour thickness when evaluating melanoma surveillance strategies.

EA DV CONGRESS
VIENNA
30 SEP - 3 OCT 2026

Abstract N°: 2407

Metastatic melanoma of unknown primary: Insights from a Single-Center Experience

Daniel Vírseda González*[1], Blanca Sánchez Lafuente[2], Marta Serra Torres[1], Diego Iglesias Riera[3], Catalina Torres Sánchez[1], Azahara Agudo García[1], Mercedes Hergueta Díaz[1], Andrés Palacios Abufón[1]

[1] Department of Dermatology, Hospital Can Misses, Eivissa, Spain
[2] Department of Oncology, Hospital Clínico Universitario Virgen de la Arrixaca, Murcia, Spain
[3] Department of Oncology, Hospital Can Misses, Eivissa, Spain

Introduction

The management and prognosis of advanced melanoma of unknown primary (MUP) have historically raised uncertainties when compared to advanced melanoma with a known primary site (MKP). To contribute further evidence, we aim to describe the experience of our centre in the management and clinical outcomes of patients with advanced MUP.

Materials and Methods

We conducted a retrospective, single-centre descriptive study including patients diagnosed with MUP between 2020 and 2026. Inclusion criteria required an initial presentation of metastatic melanoma (nodal, subcutaneous, or visceral) without identification of a primary melanocytic lesion. Patients meeting any of Das Gupta's exclusion criteria were excluded. Data collected included clinical presentation, BRAF mutation status, first-line treatment, subsequent therapies, and clinical outcomes. Statistical analyses was performed using SPSS.

Results

Eight patients with MUP were identified (5 males, 3 females), which represented 11% of advanced melanoma identified at our centre. Diagnostic work-up included whole-body imaging, ophthalmologic examination, genitoanal examination, and gynecologic evaluation in female patients. Seven patients presented with nodal metastases, three of whom also had concurrent visceral and subcutaneous involvement, while one patient had exclusively visceral metastasis. According to staging, 2 patients were classified as stage IIIB and 6 as stage IV. Five patients harboured a BRAF V600E mutation.

Among stage IV patients, all received first-line systemic therapy except one, who was managed with best supportive care due to poor performance status. Stage IIIB patients underwent complete lymph node dissection followed by adjuvant immunotherapy. The median follow-up time was 15 months.

In stage IV patients, 3 cases (all BRAF V600E-mutated) showed response to first-line treatment, with 2 complete responses and 1 partial response. The remaining 2 patients (both BRAF wild-type) exhibited primary resistance to immunotherapy. All stage IIIB patients completed one year of adjuvant pembrolizumab without progression during treatment. Objective response rate (defined as patients with complete or partial remission as best overall response) was of 62,5%.

During follow-up, 5 patients experienced disease progression after first-line treatment, with a median progression-free survival of 16 months. Median overall survival of the cohort was 24 months. At the last follow-up, 3 patients had died due to disease progression. Two patients remain in complete response on first-line therapy, 2 are receiving second-line treatment, and 1 is under best supportive care after progression to first-line treatment.

Compared to previously published series, our cohort showed a slightly higher rate of BRAF-mutated tumours,

supporting a likely cutaneous origin. Reported outcomes in advanced MUP cohorts are heterogeneous, with median overall survival ranging from 27 to 50 months and progression-free survival from 6 to 17 months, as well as an objective response rate between 45% and 60%. Importantly, prior studies have not demonstrated consistent or significant differences in outcomes between advanced MUP and advanced MKP. Unfortunately, due to the limited sample size, comparative analysis with our MKP cohort was not feasible.

Conclusions

We present a single-centre cohort of advanced MUP. Advanced MUP represent a considerable proportion of advanced melanoma (11%). Consistent with previous reports, a high frequency of BRAF V600E mutations supports a cutaneous origin hypothesis. Objective response rate was of 62,5%, with a median progression-free survival of 16 months, and a median overall survival of the cohort was 24 months. Management strategies and clinical outcomes appear comparable to those observed in patients with advanced MKP, without proven differences in overall survival and progression-free survival.

EADV CONGRESS
VIENNA
30 SEP - 3 OCT 2026

Abstract N°: 2423

Factors associated with positive surgical margins in high-risk nonmelanoma skin cancers treated with conventional excision

Fabiola Silva*[1], Alisson Oliveira[1], Larissa Caminha[1]

[1] Federal University of Bahia/Brazil, Salvador/BA, Brazil

Introduction

Conventional excision remains widely used for high-risk nonmelanoma skin cancers (NMSC), particularly in settings with limited access to Mohs micrographic surgery.

Objective: To evaluate the prevalence of positive surgical margins and identify clinicopathological factors associated with incomplete excision in high-risk NMSC treated with conventional excision.

Materials and Methods

We conducted a retrospective study based on medical record review of patients who underwent conventional excision of BCC or cSCC between January 2023 and November 2025 at the Department of Dermatology, Federal University of Bahia, Brazil. Clinicopathological variables were analyzed according to margin status. Associations were assessed using chi-square or Fisher's exact tests. Binary logistic regression was performed for BCC to identify independent predictors of positive margins.

Results

A total of 220 tumors were analyzed, including 169 BCCs and 51 cSCCs. Positive margins were identified in 44 tumors (20.0%), with no significant difference between BCC and cSCC (p=0.904). Most tumors were located on the nose or ear (53.6%). In BCC, binary logistic regression showed that tumors located on the nose or ear had approximately threefold higher odds of positive margins than tumors in other facial or cervical sites (OR, 2.91; 95% CI, 1.25–7.42; p=0.018). High-risk histological subtypes were also independently associated with positive margins (OR, 3.02; 95% CI, 1.34–6.82; p=0.007). Across all histological risk categories, tumors located on the nose or ear showed higher predicted probabilities of positive surgical margins (Figure 1). In cSCC, nose or ear location was also associated with positive margins (OR, 4.31; p=0.048), whereas histological grade was not (p=0.81). Residual tumor was identified in 15.9% of re-excisions.

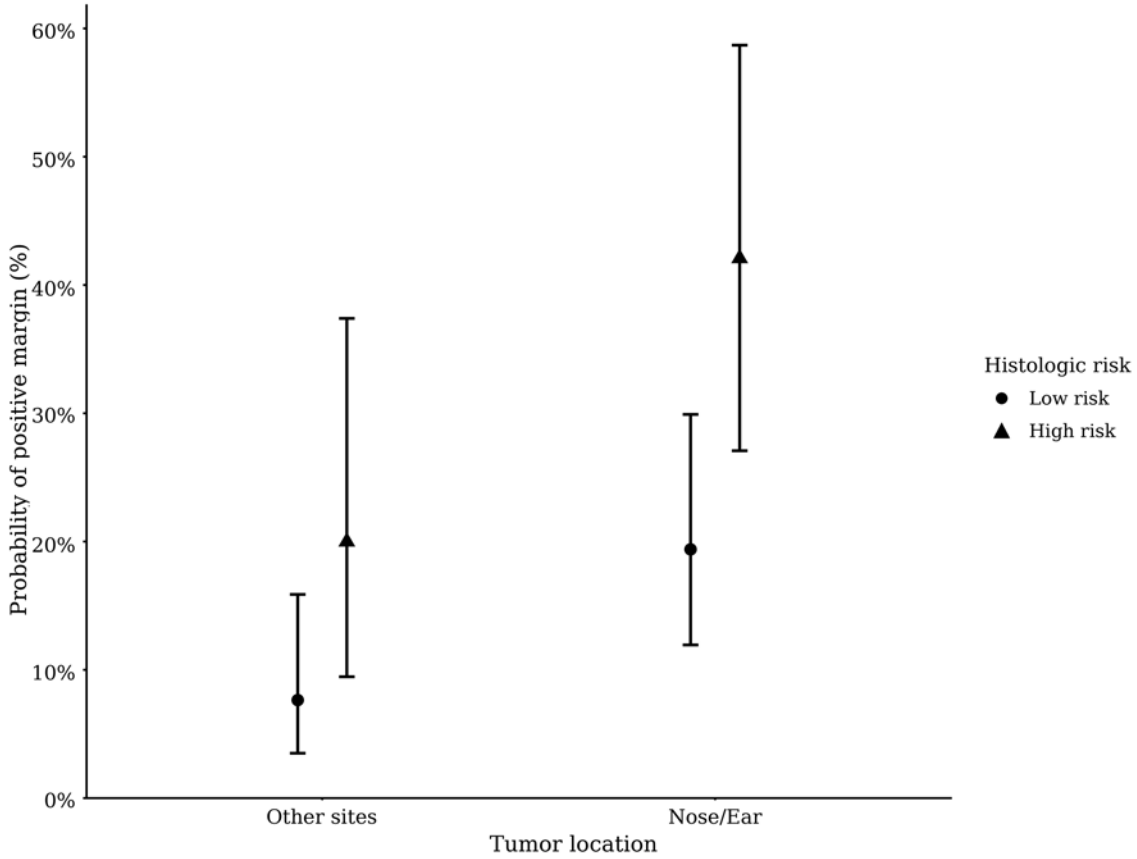

Predicted probability of positive surgical margins in basal cell carcinoma according to tumor location and histological risk group. Error bars indicate 95% confidence intervals.

Conclusions

Conventional excision of high-risk NMSC was associated with a substantial rate of positive surgical margins. Nose or ear location was the main factor associated with incomplete excision in both BCC and cSCC, while high-risk histological subtype was an additional independent predictor in BCC. These findings support the need for careful surgical planning and conservative reconstructive strategies until histological clearance is confirmed.

EA DV CONGRESS
VIENNA
30 SEP - 3 OCT 2026

Abstract N°: 2424

Rapidly Progressive Systemic T-Cell Lymphoma Initially Mimicking Tumor Stage Mycosis Fungoides

Handan Merve Erol Mart[1], Sevgi Özensel Özel*[1], Bengü Nisa Akay[1], Gülşah Kaygusuz[2], Hatice Sanli[1]

[1] Ankara University, Department of Dermatology and Venereology, Ankara, Türkiye

[2] Ankara University, Department of Pathology, Ankara, Türkiye

Introduction

Primary gastrointestinal T-cell lymphomas are exceptionally rare and may rarely involve the skin. Their clinical and histopathological overlap with primary cutaneous T-cell lymphomas may create significant diagnostic challenges. We report a rapidly progressive systemic T-cell lymphoma with gastric, pancreatic, and cutaneous involvement initially mimicking tumor-stage mycosis fungoides (MF).

Case Presentation

A 72-year-old man presented with infiltrated plaques with focal ulceration and necrosis on the lower extremities, horseshoe-shaped polycyclic lesions, and widespread nodular and tumoral lesions that initially appeared on the left pretibial region and rapidly disseminated throughout the body within two months. Dermoscopic examination demonstrated polymorphic vessels, ulceration, and scaling on an orange-pink background, while some lesions additionally exhibited prominent white lines and a rainbow pattern. Clinically, differential diagnoses initially included cutaneous T-cell lymphoma, particularly tumor-stage MF, primary cutaneous diffuse large B-cell lymphoma, leg type (PCDLBCL-LT), and cutaneous metastasis of a solid organ malignancy.

Laboratory investigations demonstrated elevated lactate dehydrogenase (415 U/L) and beta-2 microglobulin (5.39 mg/L) levels. Because of the rapidly progressive ulceronecrotic cutaneous lesions, malignant syphilis was also considered in the differential diagnosis; however, VDRL testing was negative.

Histopathological examination of skin biopsy specimens revealed atypical lymphoid infiltration extending into the subcutaneous adipose tissue. Immunohistochemical (IHC) analysis demonstrated CD3 and partial CD4 positivity with loss of CD7 expression, and epidermotropism. Although epidermotropism and CD7 loss initially suggested tumor-stage MF, the abrupt onset, rapidly progressive course, and systemic deterioration were atypical for conventional MF progression.

Imaging studies revealed dilatation of the intrahepatic bile ducts and main pancreatic duct, together with a soft tissue mass at the level of the ampulla of Vater, without evidence of lymphadenopathy. Upper gastrointestinal endoscopy demonstrated ulcerative lesions within the gastric corpus, and biopsy specimens were obtained. IHC evaluation of the gastric biopsy revealed loss of CD3 and CD5 expression with an approximately 90% Ki-67 proliferation index. These findings suggested a highly proliferative T-cell lymphoproliferative neoplasm, and aggressive T-cell lymphoma was considered the leading diagnosis.

During follow-up, the patient developed jaundice, abdominal pain, elevated amylase and lipase levels and acute pancreatitis. Definitive subclassification could not be achieved because of the patient’s rapidly progressive clinical deterioration and death before completion of advanced molecular and hematopathological studies.

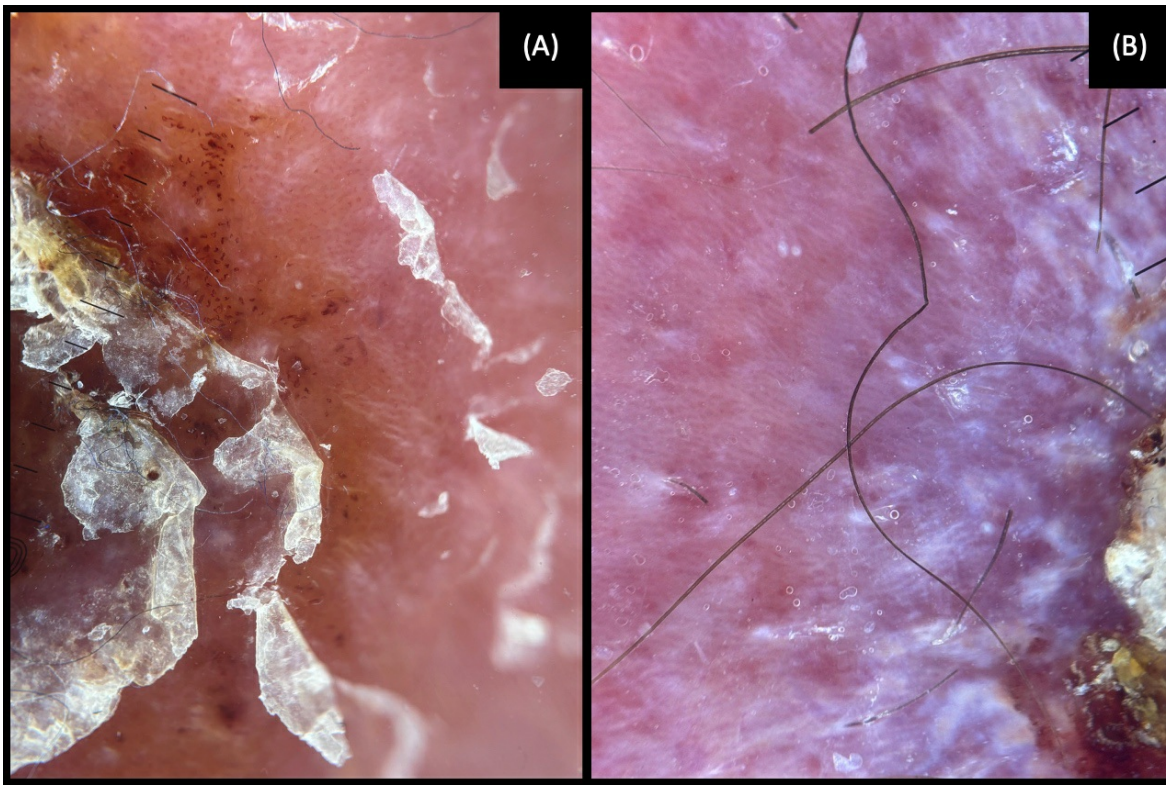

Figure 1. Dermoscopic features of the lesions. (A) Dermoscopy demonstrating ulceration, scales, and polymorphic vascular structures on an orange-pink background. (B) Dermoscopic image of another lesion showing prominent white lines and rainbow pattern-like areas.

Conclusion

Primary gastric non-Hodgkin lymphomas account for approximately 1%–7% of all gastric malignancies, whereas primary gastric T-cell lymphomas are exceptionally rare. Although cutaneous involvement in T-lymphoblastic lymphoma has been reported in approximately 4.3% of cases, primary gastrointestinal involvement is exceedingly uncommon. In contrast, peripheral intestinal T-cell lymphomas may exhibit a broad spectrum of cutaneous manifestations, including macules, papules, purpura, and ulcerative lesions, with skin biopsies demonstrating variable T-cell immunophenotypes.

This case is notable for the rapid onset of aggressive tumoral cutaneous lesions without a preceding patch/plaque stage. Such atypical presentations should prompt early evaluation for aggressive systemic T-cell lymphoma, particularly in the setting of rapid clinical deterioration. Our case further demonstrates that systemic T-cell lymphomas with cutaneous involvement may both clinically and histopathologically mimic tumor-stage MF, representing a significant diagnostic pitfall.



Figure 2. Clinical presentation of the cutaneous lesions. (A) Widespread infiltrated plaques, nodules, and tumoral lesions involving the bilateral lower extremities, with focal ulceration and necrosis. (B) Close-up view of a necrotic tumoral lesion with central black eschar formation on the lateral aspect of the knee. (C) Horseshoe-shaped polycyclic erythematous plaque on the right leg.

EADV CONGRESS
VIENNA
30 SEP - 3 OCT 2026

Abstract N°: 2430

Dynamic Diagnostics in Rare Melanoma: The Role and Limits of Imaging

Paola Negovetic*[1], Klara Gaćina[1], Marija Buljan[1, 2]

[1] University Hospital Centre Sestre milosrdnice, Zagreb, Croatia

[2] University of Zagreb, School of dental medicine, Zagreb, Croatia

Introduction

Melanoma of the glans penis is a rare and clinically challenging entity, often associated with delayed diagnosis and an unfavorable prognosis. In such cases, diagnostics play a central role, not only in establishing the diagnosis, but also in guiding treatment and monitoring disease progression. The combination of histopathology, molecular analysis, and modern imaging techniques such as PET/CT is essential, yet not without limitations.

Case Presentation

We present a patient with melanoma of the glans penis with microsatellitosis (stage IIIB), who underwent partial penile amputation following diagnostic biopsy. Histopathology confirmed superficial spreading melanoma without ulceration, while resection margins were initially inconclusive. Molecular analysis revealed BRAF V600 negativity and the presence of a KIT gene alteration, significantly influencing further therapeutic considerations.

Baseline whole-body PET/CT demonstrated no evidence of disease dissemination. The patient was subsequently discussed in a multidisciplinary team for melanoma and other cutaneous tumors, and adjuvant immunotherapy with nivolumab was initiated. Regular interval imaging using PET/CT every three months represented the cornerstone of disease monitoring.

Despite initially negative imaging, follow-up PET/CT revealed hematogenous dissemination with suspected involvement of mediastinal lymph nodes, pulmonary lesions, and possible osseous and celiac lymph node metastases. Importantly, these findings highlighted the sensitivity of PET/CT in detecting early metastatic spread even in clinically asymptomatic patients.

Therapeutic strategy was adjusted to combined immunotherapy with nivolumab and ipilimumab. However, treatment was complicated by immune-related adverse events, including diarrhea and suspected immune-mediated arthritis, that required corticosteroid therapy and temporary treatment delays.

Subsequent PET/CT evaluation demonstrated a partial response, followed by a stable finding of small, metabolically inactive pulmonary and skeletal lesions of uncertain etiology. At this stage, a key diagnostic dilemma emerged: were these residual metastases, treatment-related changes, or incidental benign findings? Repeated imaging remained inconclusive, emphasizing the limits of radiological specificity, especially in the context of immunotherapy.

Throughout the disease course, diagnostic emphasis remained on integrating imaging findings with clinical status, treatment history, and molecular characteristics. Comprehensive genomic profiling further supported individualized management.

Conclusion

This case illustrates how complex and dynamic diagnostics can be in rare melanoma presentations. While PET/CT is highly sensitive in detecting early metastatic spread, interpretation challenges remain in distinguishing active disease from treatment-related or benign findings. Continuous multidisciplinary evaluation is essential to optimize diagnostic accuracy and guide therapeutic decisions in complex cases.

EADV CONGRESS
VIENNA
30 SEP - 3 OCT 2026

Abstract N°: 2437

Pigmented Basal Cell Carcinoma in an Atypical Location

Claudio Lelis Souza[1], Julia Coffler*[2], Ana Laura Ritter[1], Guilherme Gonçalves Nascimento[3], Brian Vicente[3], Julia Nakano[3]

[1] unifenas, alfenas, Brazil
[2] EMESCAM, Vitória, Brazil
[3] FMABC, Santo Andre, Brazil

Introduction

Basal Cell Carcinoma (BCC) is the most common skin cancer worldwide, characterized by slow growth and low metastatic potential. It predominantly affects chronically sun-exposed areas, especially the upper third of the face, scalp, ears, neck, and neckline. Periungual involvement is extremely uncommon and may represent a diagnostic challenge, particularly in the pigmented subtype, which can clinically mimic melanoma. Reports of pigmented BCC arising in unusual anatomical sites are scarce in the literature and are relevant due to the potential for delayed diagnosis and inappropriate management.

Case Presentation

A 62-year-old female patient presented to the Dermatology Outpatient Clinic complaining of chronic nail thickening, which impaired the use of closed shoes. She reported longstanding ungual alterations for several years, although she was unable to define the exact duration. Dermatological examination revealed marked subungual hyperkeratosis affecting almost all toenails, more pronounced on the right hallux. Careful examination identified a pearly tumoral lesion located in the periungual region of the right hallux, measuring approximately 1.3 cm in diameter, with telangiectasias, irregular borders, and pigmented dark areas. The patient reported progressive growth over approximately three years. Due to the pigmentation pattern and irregular contours, the initial diagnostic hypothesis was subungual melanoma. However, the indolent clinical evolution and prolonged course were less suggestive of an aggressive melanocytic neoplasm. An incisional biopsy using a 4mm punch was performed. Histopathological examination demonstrated nests of basaloid cells with peripheral palisading associated with melanin deposition, confirming the diagnosis of pigmented basal cell carcinoma. Complete surgical excision was subsequently performed, followed by healing by secondary intention, with satisfactory postoperative evolution and no evidence of recurrence during follow-up.

Conclusion

Pigmented basal cell carcinoma occurring in the periungual region is an exceedingly rare presentation and represents an important diagnostic pitfall due to its clinical resemblance to melanoma. This case highlights the importance of considering BCC in the differential diagnosis of chronic pigmented periungual lesions, even in non-sun-exposed and unusual anatomical sites. Early recognition and histopathological confirmation are essential to avoid delayed diagnosis and ensure adequate treatment. Furthermore, this report reinforces the relevance of documenting atypical presentations of common skin cancers, especially those capable of simulating more aggressive malignancies such as melanoma.

EADV CONGRESS
VIENNA
30 SEP - 3 OCT 2026

Abstract N°: 2468

Unmasking Hidden Malignant Cutaneous Lesions Following Treatment of Extensive Pityriasis Rubra Pilaris: A Case Report

Ana Lígia Scotti Alérico*[1], Sandra e Dinato[1], Paulo Ricardo Criado[1], Bruna Marques Bilia[1], Renata Rodrigues[1], Julia Carneiro da Cunha[1]

[1] Centro Universitário Lusíada - UNILUS, Santos, Brazil

Introduction

Pityriasis rubra pilaris (PRP) is a rare chronic papulosquamous disorder characterized by follicular hyperkeratosis, palmoplantar keratoderma, and well-demarcated erythematous plaques that may progress to erythroderma. Severe inflammatory dermatoses such as PRP may obscure underlying cutaneous lesions, which become clinically evident only after disease control.

Case Presentation

The report is on the case of a 71-year-old male with a naturalist lifestyle, who reported not having bathed for the previous 11 years, presenting a two-month history of pruritic skin lesions. Initially, the lesions involved the face and trunk, with subsequent progression to generalized involvement. The condition evolved with thick hyperkeratotic lesions on the palms and soles, associated with painful fissures and impaired ambulation. His medical history included schizophrenia treated with clozapine and aripiprazole.

Dermatological examination revealed 70% of body surface area (BSA) with diffuse scaling, erythematous papules and plaques, marked palmoplantar keratoderma with fissures, nail dystrophy, and scalp involvement. Histopathological examination demonstrated acanthosis, parakeratosis, mild hyperkeratosis, spongiosis, and a superficial perivascular lymphocytic infiltrate. Based on clinicopathological data correlation, a diagnosis of PRP was established.

Treatment with risankizumab resulted in marked clinical improvement, with the resolution of erythema, scaling, and keratoderma. As the inflammatory process subsided and the previously affected skin became cleared of lesions, multiple basal cell carcinomas that had been concealed by the crusts were identified across different body areas.

Conclusion

This case highlights the potential of PRP to act as a masking dermatosis, obscuring underlying skin neoplasms. Disease control may reveal previously undetectable lesions, emphasizing the importance of careful skin examination during and after treatment. Clinicians should be aware of this phenomenon to avoid delayed diagnosis of cutaneous malignancies.

EADV CONGRESS
VIENNA
30 SEP - 3 OCT 2026

Abstract N°: 2468

Menopausal status significantly influences immune related adverse events upon checkpoint inhibitor therapy in skin cancer

Florentine Tonko*[1], Sarah Preis[1], Lisa Wein[2], Tilo Biedermann[1], Lucie Heinzerling[2], Oana-Diana Persa[1]

[1] Technical University of Munich, TUM School of Medicine and Health, Department of Dermatology and Allergy, Munich, Germany

[2] Department of Dermatology and Allergy, University Hospital, LMU Munich, Munich, Germany

Introduction

Immune checkpoint inhibitors (ICIs) are associated with immune-related adverse events (irAEs) that can affect any organ system. These events can lead to significant morbidity and may necessitate treatment interruption or permanent discontinuation. Although sex-specific differences in the irAE profile have been described, the role of menopausal status as a biologically relevant factor in women remains insufficiently understood. The aim of this study was to investigate the organ-specific irAE profile, severity, clinical management, and outcome in premenopausal versus postmenopausal women with cutaneous malignancies receiving ICI therapy.

Materials and Methods

Data were extracted from the SERIO registry, a multicenter real-world database. Women with melanoma, squamous cell carcinoma, or Merkel cell carcinoma were stratified into premenopausal (n=85) and postmenopausal (n=357) subgroups. IrAE spectrum was analyzed at the event level using cluster bootstrap resampling; adjusted odds ratios were estimated using generalized estimating equations (GEE) adjusted for ICI type.

Results

Overall irAE frequency, severity, and time to first irAE did not differ significantly between groups. Colitis was significantly more frequent among postmenopausal women (21.2% vs. 10.9%, $p<0.001$; adj OR 0.28, $p=0.003$), while hepatitis predominated in premenopausal women (16.7% vs. 11.7%, $p=0.024$; adj OR 1.90, $p=0.045$). Thyroiditis was numerically more frequent in premenopausal women but did not reach significance after adjustment. Postmenopausal women received corticosteroid therapy more frequently (67.2% vs. 57.3%, $p=0.049$), though this did not remain significant after adjustment. Premenopausal women showed a significantly higher rate of complete irAE resolution (66.7% vs. 52.6%, $p=0.015$).

Conclusions

Menopausal status shapes the organ-specific irAE profile of women receiving ICIs in ways not captured by biological sex alone, with divergent patterns of hepatic and gastrointestinal toxicity. These findings support routine documentation of menopausal status in immunotherapy registries and suggest that individualized monitoring strategies may improve early irAE detection and management.

EA DV CONGRESS
VIENNA
30 SEP - 3 OCT 2026

Abstract N°: 2472

Carcinoma en Cuirasse: The Primary Clinical Indicator of an Undiagnosed Breast Malignancy

Marija Malinić*[1], Margita Mijuskovic[1], Emilija Manojlović-Gačić[2], Dubravka Zivanovic[1, 3]

[1] Clinic of Dermatology and Venereology, University Clinical Center of Serbia, Belgrade, Serbia
[2] Institute of Pathology, University of Belgrade – Faculty of Medicine, Belgrade, Serbia
[3] University of Belgrade – Faculty of Medicine, Belgrade, Serbia

Introduction

Carcinoma en cuirasse (CeC) is a rare and aggressive scirrhous variant of cutaneous metastasis, occurring as the primary presenting sign of malignancy in approximately 0.8% of breast cancer cases. The term, introduced by Velpeau in 1838, is derived from the French word for a cuirassier's breastplate, characterizing the diffuse, sclerodermoid encasement of the torso that mimics a rigid, armor-like shield. Due to its unique spread through the dermal lymphatics, CeC frequently mimics inflammatory or sclerotic skin conditions, presenting a significant diagnostic challenge.

Case Presentation

A 47-year-old Caucasian female with an unremarkable medical history presented with a 15-month history of progressive, extremely firm, erythematous plaques on the anterior trunk. The lesions were largely confluent, covering the abdomen and pubic region, resulting in a rigid, diffuse induration of the skin with an armor-like firmness on palpation. Laboratory evaluation showed significantly elevated tumor markers: CA 125 was nearly double the reference range, while CYFRA 21-1 showed an extreme elevation of over ten times the normal limit. Notably, CT imaging of the thorax, abdomen, and pelvis showed no evidence of visceral metastases or an identifiable primary mass, indicating an isolated cutaneous disease burden. Histopathological analysis revealed that the dermis and subcutis were densely infiltrated by atypical oval tumor cells arranged in a solitary, characteristic single-file infiltration pattern. The immunohistochemical profile – specifically panCK+, CK7+, and GATA3+ in the absence of CK20, TRPS1, and hematolymphoid markers (LCA, CD68/163) was highly suggestive of skin metastasis originating from the breast. Following the skin biopsy findings, targeted breast imaging and an oncology board evaluation were performed; the patient subsequently initiated a multimodal regimen including an aromatase inhibitor, an LHRH agonist, and a CDK4/6 inhibitor, combined with oophorectomy.

Conclusion

The clinical recognition of CeC is paramount, as it may be the initial indicator of occult breast malignancy. The pathognomonic "armor-like" rigidity of the skin and single-file infiltration on histopathology are hallmark diagnostic clues that differentiate CeC from primary sclerotic skin conditions. Importantly, the absence of visceral involvement despite extensive cutaneous spread emphasizes the unique locoregional biology and predominant lymphogenous tropism of this metastatic variant. This case highlights the utility of a specific IHC signature in identifying the site of origin, particularly when the primary malignancy is not detected during initial systemic CT evaluation.

The recognition of cutaneous metastases is crucial, as they may serve as the sole clinical indicator of an undiagnosed primary malignancy. This case illustrates the importance of a multidisciplinary approach in identifying such rare presentations and ensuring the prompt initiation of appropriate systemic oncological

therapy.

EADV CONGRESS
VIENNA
30 SEP - 3 OCT 2026

Abstract N°: 2480

Survival outcomes in melanoma of unknown primary versus known primary: impact of first-line treatment in a real-world retrospective cohort

Daniel Javier Sánchez Báez*[1], Miguel Quetglas Valenzuela[1], Asier Viciana Tarife[1], EVA FAGUNDO GONZALEZ[1], Rosa Nieves Rodríguez Rodríguez[2]

[1] Dermatology Department - Hospital Universitario de Canarias, San Cristóbal de La Laguna, Spain
[2] Pathology Department - Hospital Universitario de Canarias, San Cristóbal de La Laguna, Spain

Introduction
Melanoma of unknown primary (MUP) is a rare subtype of metastatic melanoma in which no cutaneous or mucosal primary tumor is identified. Its prognosis compared with melanoma of known primary (MKP) remains incompletely defined, and it is unclear whether MUP biology influences response to immunotherapy or targeted therapies.

Materials and Methods
We conducted a retrospective study including all metastatic melanoma cases discussed at our institution's Skin Tumor Board between 2016 and 2024. Demographic (age, sex), clinical (MUP vs MKP, AJCC 8th edition stage), therapeutic (progression-free survival [PFS], overall survival [OS], treatments, adverse events), and histopathological (BRAF status) variables were collected. Survival was analyzed using Kaplan–Meier estimates and Cox regression. Stratified analyses were performed according to clinical variables and type of first-line therapy (immunotherapy vs BRAF/MEK inhibitors).

Results
A total of 107 patients were included: 91 MKP (85%) and 16 MUP (15%). Baseline characteristics were comparable between groups, including age (62.7±15.2 vs ~62±13 years), BRAF mutation rate (38.9% vs ~40%), and stage distribution (IV vs ≤III). In univariate analysis, MUP showed a numerically higher risk of adverse outcomes, although differences were not statistically significant: OS HR 1.56 (95% CI 0.69–3.52; p=0.286) and PFS HR 1.93 (95% CI 0.89–4.17; p=0.095). After adjustment for age and stage, no significant differences were observed (OS HR 1.23; p=0.637; PFS HR 1.56; p=0.280). Extended models including BRAF status and ≥2 treatments yielded consistent results (OS HR 0.95; p=0.918; PFS HR 1.87; p=0.170). In treatment-based subanalyses, among patients receiving first-line immunotherapy (n=69), no differences were observed between MUP and MKP (OS HR 1.21; p=0.733; PFS HR 1.49; p=0.418). In contrast, among those treated with BRAF/MEK inhibitors (n=20), MUP was associated with worse outcomes (OS HR 5.21; p=0.025; PFS HR 6.92; p=0.013), although this subgroup included only 3 MUP patients. Overall, the trend toward worse PFS in MUP was attenuated in patients treated with immunotherapy and appeared more pronounced in those receiving targeted therapy.

Conclusions
MUP has been associated with a more immunogenic tumor microenvironment and, in several studies, similar or improved survival compared with MKP. In our cohort, no survival advantage was observed, although the trend toward worse PFS was attenuated in patients receiving immunotherapy. By contrast, poorer outcomes in patients

treated with BRAF/MEK inhibitors may reflect both confounding by indication and potential biological mechanisms, including MAPK pathway reactivation, compensatory PI3K/AKT signaling, and tumor microenvironment barriers that may limit drug efficacy. Meta-analytic data suggest a possible survival benefit for MUP, although results remain heterogeneous; our findings do not confirm this advantage but are consistent with the exploratory nature of the analysis.

MUP represents a rare form of metastatic melanoma. No significant differences in OS or PFS were observed compared with MKP. The trend toward worse PFS in MUP was attenuated in patients treated with immunotherapy and appeared more pronounced in those receiving targeted therapy, warranting further investigation in larger cohorts.

EA DV CONGRESS
VIENNA
30 SEP - 3 OCT 2026

Abstract N°: 2490

Effect of a Proactive Skin Care Regimen on EGFR-TKI–Induced Skin Toxicities in Advanced Lung Cancer: A Randomized Controlled Pilot Study

Danang Tri Wahyudi*[1], Agassi Suseno Sutarjo[1], Fadhli Aulia Mughni[1], Aida Hoemardani[1], Inadia Putri Chairista[1], Nuril Ilmi[1], Raissa Putri Raspati[1], Arif Riswahyudi Hanafi[2], Muhamad Alfin Hanif[2], Mariska Pangaribuan[2], Wily Ariawan[2], Samir Salah[3], Delphine Kerob[3]

[1] Dharmais National cancer Hospital, Department of Dermatology, Venereology, and Aesthetics, Jakarta, Indonesia

[2] Dharmais National Cancer Hospital, Department of Pulmonology and Respiratory, Jakarta, Indonesia

[3] La Roche-Posay Laboratoire Dermatologique, Levallois-Perret, France

Introduction

EGFR tyrosine kinase inhibitor (EGFR-TKI) therapy frequently induces cutaneous adverse events—most notably papulopustular rash, paronychia, xerosis, and pruritus—that may impair quality of life, treatment adherence, and in severe cases precipitate dose reduction or discontinuation. Proactive skin care, through maintenance of hydration and barrier function, represents a promising adjunctive strategy. This pilot study evaluated the effectiveness of a proactive skin care regimen in preventing EGFR-TKI—induced skin toxicities, preserving skin barrier function, and improving quality of life in patients with advanced lung cancer over 12 weeks.

Materials and Methods

This was a 12-week prospective, randomized, single-blind, controlled pilot study enrolling 30 patients with advanced EGFR-mutated lung cancer receiving EGFR-TKI therapy (afatinib, erlotinib, or gefitinib), randomized to intervention (N=16; moisturizer, cleanser, anti-irritation cream, and sunscreen) or control (N=14; standard care). Skin toxicity severity across four domains—papulopustular rash, paronychia, xerosis, and pruritus—was graded using CTCAE. Reactive treatment was provided as clinically indicated, including systemic doxycycline, topical corticosteroids (clobetasol), topical antibiotics (fucidic acid), antihistamines (cetirizine), and emollients. Skin barrier function was assessed by transepidermal water loss (TEWL) and stratum corneum hydration (SCH) at the forehead, hand, and back. Quality of life was measured using DLQI.

Results

Baseline characteristics were well balanced between groups (all $p>0.05$). Given the pilot design and limited statistical power, skin toxicity and treatment data are presented as exploratory findings. Overall skin toxicity incidence was comparable between groups at all-time points (all $p>0.05$). However, consistent numerical trends suggested milder profiles in the intervention group: Grade ≥2 toxicities at week 9 occurred in 12.5% of intervention versus 57.1% of control patients. Notably, Grade 3 toxicities—including severe papulopustular rash and severe paronychia—were absent in the intervention group throughout the study, while occurring in the control group at week 6 (14.3%) and 9 (7.1%). At week 3, only 1/16 (6.25%) intervention patients required pharmacological management (doxycycline monotherapy) compared to 5/14 (35.71%) in the control group, who received more complex multi-agent regimens combining doxycycline, clobetasol, fucidic acid, and cetirizine ($p=0.255$). At week 12, any-grade toxicity was present in 81.25% versus 85.71% of patients ($p=0.160$). SCH was significantly higher in the intervention group at the back (week 3: $p=0.026$; week 12: $p=0.042$) and forehead (week 3: $p=0.018$; week 12: $p=0.028$). TEWL changes from baseline were not significantly different between groups. DLQI was significantly better in the intervention group at week 12, with median 0 (range 0–6) versus 2 (range 0–16) in

controls (p=0.013).

Conclusions

This pilot study provides exploratory evidence that a proactive skin care regimen significantly improves skin hydration and quality of life in patients receiving EGFR-TKI therapy. Numerical trends suggest attenuation of toxicity severity—particularly prevention of Grade 3 papulopustular rash and paronychia—and reduced early pharmacological intervention including systemic doxycycline, though not statistically confirmed given limited power. Larger randomized studies are warranted to establish proactive skin care as a standard adjunct in oncology practice.

EADV CONGRESS
VIENNA
30 SEP - 3 OCT 2026

Abstract N°: 2515

Merkel Cell Carcinoma of the Skin Mimicking Pyogenic Granuloma

Claudia Bravo Contreras*[1], Fátima Yadira Urbano[2], Roberto Rosas Hernández[1]

[1] Instituto Mexicano del Seguro Social (IMSS), Hospital General Regional no. 66, Ciudad Juárez, Chihuahua, Mexico
[2] Sierra Alta Medical City (Hospital privado y centro médico de alta especialidad)., Chihuahua, Chihuahua, Mexico

Introduction

Merkel cell carcinoma is a rare and aggressive cutaneous neuroendocrine tumor.[1] Risk factors include advanced age[1] (mean age at diagnosis greater than 75 years),[2] male sex, exposure to ultraviolet radiation, fair skin, and immunosuppression.[1] Most cases develop in sun-exposed skin, with 42.6% occurring in the head and neck region, followed by upper limbs, lower limbs, and trunk.[2] Its carcinogenesis is based either on the integration of the Merkel cell polyomavirus or on ultraviolet mutagenesis, both of which lead to high immunogenicity either through the expression of viral proteins or neoantigens.[3] Epidemiological data on this condition remain limited due to its rarity.[4] In a retrospective cohort study conducted in Mexico, a predominance of females was observed, with the extremities being the most commonly affecting sites, differing from findings reported in the international literature.[4]



Fig 1. Cupuliform nodular lesion measuring 1.5 x 1 cm in diameter on the left cheek. Dermoscopy shows a polymorphous vascular pattern on a milky-red background.

Case Presentation

A 64-year-old female patient, with no relevant medical history, presented with a violaceous, dome-shaped nodule on the left cheek, with a smooth surface and soft consistency, that had been present for 6 months (Fig. 1). A shave biopsy was performed, with an initial diagnostic impression of pyogenic granuloma. Histopathological examination (Fig. 2) confirmed the diagnosis of Merkel cell carcinoma of the skin. An organized malignant epithelial neoplasm was observed, composed of solid sheets of cells, nests, and papillary structures embedded in a loose desmoplastic stroma, with extensive tumor necrosis interspersed with hemosiderophages and recent hemorrhage. Numerous atypical mitoses were also found. Immunohistochemical analysis showed negative CK20 and P40 staining, with 80% positivity for synaptophysin (Fig. 3). The patient was referred to Surgical Oncology for sentinel lymph node biopsy, which was negative. Given the high rate of local recurrence, adjuvant radiotherapy was indicated.

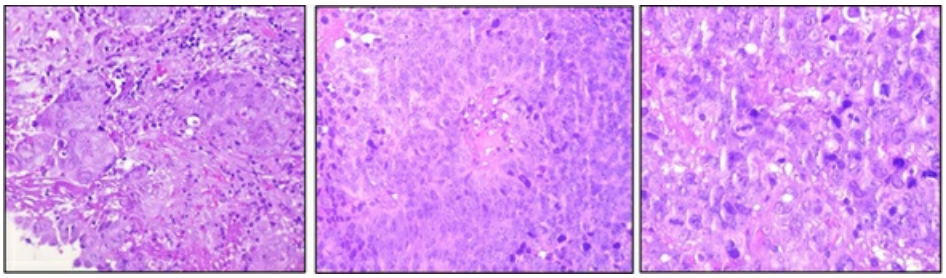

Fig 2. Dermal Merkel cell carcinoma (haematoxylin–eosin staining). Atypical cells with vesicular nuclei with dotted nucleoli and abundant eosinophilic cytoplasm, show areas with nuclear molding and contain numerous atypical mitoses.

Conclusion

Common clinical diagnoses are BCC, EC, amelanotic melanoma, and adnexal tumor. Due to the violaceous, sometimes hemorrhagic, appearance, the differential diagnosis also includes pyogenic granuloma, abscesses, angiosarcoma, and lymphoma.[5] Given its aggressive nature, Merkel cell carcinoma should be considered in differential diagnosis of rapidly growing cutaneous lesions. Tumor stage, advanced age, male sex, and viral status are associated with prognosis. The approximate 5-year survival rate is 62.8% for stage I disease, 34.8%–54.6% for stage II, 26.8%–40.3% for stage III, and 13.5% for stage IV.[2] A punctate paranuclear staining pattern for CK20 is highly suggestive of the diagnosis.[2] Furthermore, CK20-negative and Merkel cell polyomavirus-negative carcinomas appear to exhibit more aggressive behavior.[5] Positive staining for neuroendocrine markers such as chromogranin, synaptophysin, somatostatin, calcitonin, and vasoactive intestinal peptide supports the diagnosis.[5] A high index of suspicion should be maintained even in atypical clinical settings to avoid missed diagnoses. Rapidly growing skin lesions warrant histopathological examination regardless of their benign appearance. Timely recognition has a significant impact on prognosis.

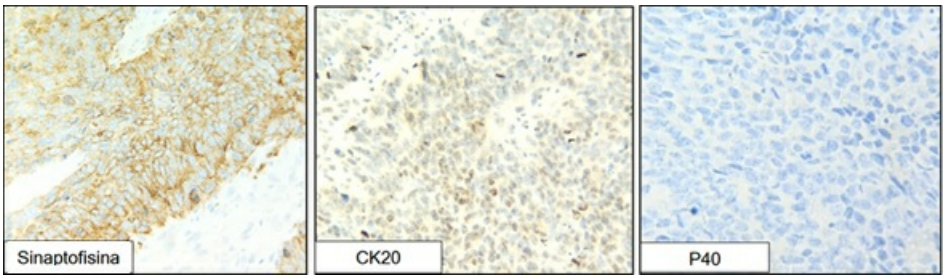

Fig 3. Synaptophysin: polyclonal, cytoplasmic immunolocalization: Positive in around 80% with moderate intensity.

EA DV CONGRESS
VIENNA
30 SEP - 3 OCT 2026

Abstract N°: 2526

Cutaneous localization of acute myeloid leukemia mimicking a neutrophilic dermatosis: a case report

Theophile Dugast*[1], Caroline-Jade Clerc[2], Jeremy Gottlieb[2], Karine Boye[2], Ingrid Kupfer-Bessaguet[2]

[1] CHU de Poitiers, Poitiers, France
[2] CH de Niort, Niort, France

Introduction

Acute myeloid leukemia (AML) is a hematological malignancy characterized by the proliferation of immature myeloid cells in the bone marrow. Cutaneous involvement, known as leukemia cutis, occurs when these leukemic cells infiltrate the skin. We report a rare case of leukemia cutis masquerading as a neutrophilic dermatosis, highlighting the diagnostic challenges in patients with myeloid malignancies.

Case Presentation

A 74-year-old female patient with a history of AML secondary to chronic myelomonocytic leukemia (CMML) presented with sudden, intermittent night sweats and a painful, infiltrated, erythematous lesion, 4 cm in diameter, on the lateral aspect of the right thigh. Biological tests revealed a systemic inflammatory response, and a CT scan showed dermo-hypodermal infiltration without abscess formation.

Despite broad-spectrum antibiotic therapy, the lesion rapidly progressed to a necrotic state. Given the clinical appearance and the underlying AML, a neutrophilic dermatosis (Sweet syndrome) was initially suspected. One week later, a similar lesion appeared on the contralateral thigh. Skin biopsies were performed, revealing a monotonous infiltration of blast cells invading the dermis and hypodermis. Immunohistochemistry (IHC) was positive for myeloperoxidase (MPO), CD68, and CD15, confirming the diagnosis of leukemia cutis. The absolute neutrophil count, initially stable at 14 G/L, rose to 44 G/L one month after the onset of skin lesions, signaling an extracutaneous hematological relapse.

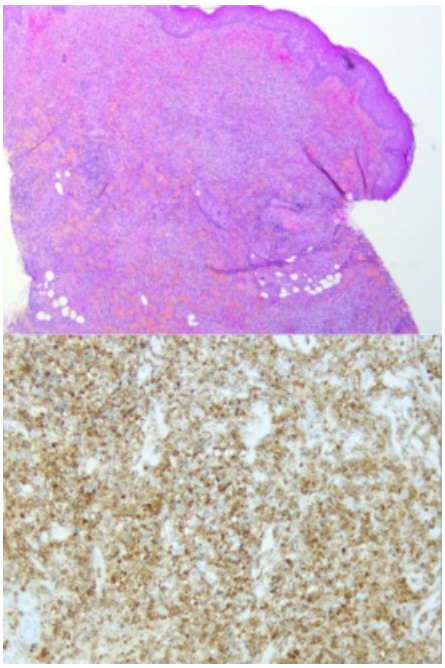

A. Histological section of a skin biopsy showing a dense dermo-hypodermal infiltrate of blastic cells (Hematoxylin Eosin Saffron - x5) B. Skin biopsy section showing positive immunohistochemical staining with the anti-myeloperoxidase antibody (MPO - x20)

Conclusion

Leukemia cutis may present with various clinical morphologies, including multiple papules, plaques, or nodules, and more rarely, as necrotic extensive plaques or tumoral masses. Histologically, it is characterized by a dense dermo-hypodermal infiltration of monotonous blast cells. These cells typically express myeloid markers (MPO, CD33) and/or monocytic markers (CD15, CD68, and lysozyme).

While the incidence of Sweet syndrome in AML patients is approximately 1%, some cases may be misdiagnosed in the absence of IHC. Furthermore, cutaneous involvement can be the first manifestation of AML relapse. This case emphasizes the importance of distinguishing leukemia cutis from histiocytoid Sweet syndrome, which typically displays a more polymorphous cellular infiltration and less intense IHC staining. As observed in our patient, the appearance of these specific skin lesions is often highly correlated with systemic disease progression or relapse.

In the context of AML, the appearance of skin lesions suggestive of neutrophilic dermatosis should prompt an immediate skin biopsy with IHC. Differentiating specific leukemia cutis from reactive neutrophilic dermatosis is essential, as the former indicates a poor prognosis and requires urgent systemic treatment adjustment.

EA DV CONGRESS
VIENNA
30 SEP - 3 OCT 2026

Abstract N°: 2537

Malignant transformation of linear porokeratosis into squamous cell carcinoma: a case report

Mariana Müller Angulski*[1], Anna Luiza Glus de Souza[1], Sofia Feres Tetto[1], Marcela Sarú Campos[1], Bianca Sanderson Chiaratti[1], Isadora Ceccatto Ortellado[1], Yasmim Mirindiba Ribeiro[1], Camila Cristina Wojcik Mannes[1], Gabriela de Queiroz Peixoto[1], Felipe Binder Coelho[1], Luiza Martins Affornali[1], Manuela Romero Macedo[1], Anber Tanaka[1]

[1] Faculdade Evangélica Mackenzie do Paraná, Curitiba, Brazil

Introduction

Porokeratosis is a disorder of keratinization characterized by circular or annular cutaneous lesions with a hyperkeratotic border known histologically as the cornoid lamella. It is frequently associated with chronic sun exposure, with ultraviolet radiation being a significant extrinsic contributing factor. Porokeratosis is considered a premalignant condition, particularly associated with the development of squamous cell carcinoma (SCC) and, less frequently, basal cell carcinoma. Among the clinical variants of porokeratosis, the linear subtype is not only one of the rarest but also carries a significantly high risk of malignant transformation. SCC is a malignant neoplasm arising from epidermal keratinocytes with potential dermal invasion. It is more prevalent in photoexposed areas and commonly affects fair-skinned individuals over 60 years of age. The gold standard for diagnosis is histopathological examination.

Case Presentation

A 79-year-old male with a history of well-controlled systemic arterial hypertension, diabetes mellitus, and previous cerebrovascular accident presented with skin lesions. The patient denied drug allergies and had a social history of alcohol and tobacco use, both discontinued 10 years prior to evaluation. The patient was initially evaluated in 2023, with complaints of hyperpigmented and scaly lesions on the dorsum of the right hand and the right abdominal region, with long-standing history. The patient denied pruritus or pain, reporting only episodes of bleeding after manipulation. Physical examination revealed an ulcerated erythematous plaque with hemorrhagic crusts, measuring approximately 2.5 cm on the dorsum of the right hand. Additionally, linear, confluent hyperpigmented plaques with a serpiginous pattern, central atrophies areas and verrucous appearance, and raised keratotic border were observed, affecting the right upper limb and right trunk, not crossing the midline. Given the location in a sun-exposed area and the clinical findings, linear porokeratosis was considered, and a skin biopsy was indicated. A 4 mm punch biopsy was performed on an ulcerated lesion on the dorsum of the right hand without complications. The patient was lost to follow-up and returned approximately two years later. The initial biopsy result showed squamous cell carcinoma in situ. At reevaluation, the patient presented with persistence of the lesions, reporting bleeding upon manipulation, without pain or pruritus. The lesion on the dorsum of the hand had progressed to an ulcerated and exudative plaque with hyperkeratotic borders, while the remaining lesions showed no changes. A new biopsy was performed, reinforcing the diagnostic hypothesis of squamous cell carcinoma arising from preexisting linear porokeratosis. The histopathological examination confirmed the diagnosis of well-differentiated squamous cell carcinoma. Surgical excision of the lesion was performed, with complete removal of the lesion. Due to the extent of the resected area, a skin graft was performed. The procedure was completed without complications.

Conclusion

This case highlights the malignant potential of linear porokeratosis, a rare variant associated with an increased risk of progression to squamous cell carcinoma. Chronic sun exposure and delayed follow-up may have contributed to lesion progression in this patient. Early recognition of suspicious lesions, histopathological confirmation, and long-term dermatological surveillance are essential for prompt diagnosis and treatment, aiming to reduce morbidity and improve patient outcomes.

EA DV CONGRESS
VIENNA
30 SEP - 3 OCT 2026

Abstract N°: 2542

Extramammary Paget's Disease of the Scalp with an Underlying Atypical Meningioma

Alexia-Roberta Baia*[1], Sabina Tăpălagă[1], Simona Senila[2]

[1] Iuliu Hatieganu University of Medicine and Pharmacy, Cluj Napoca, Cluj-Napoca, Romania

[2] County Emergency Hospital Cluj-Napoca, Iuliu Hatieganu University of Medicine and Pharmacy Cluj Napoca, Cluj-Napoca, Romania

Introduction

Extramammary Paget’s disease (EMPD) is an uncommon intraepithelial adenocarcinoma typically arising in apocrine gland-bearing regions, most frequently involving the anogenital and axillary areas. Ectopic EMPD occurring on the scalp is exceptionally rare and remains diagnostically challenging because of its nonspecific clinical presentation and frequent resemblance to chronic inflammatory dermatoses. Fewer than ten scalp cases have been documented in the English-language literature. We report an unusual case of extensive ectopic EMPD of the scalp associated with an underlying intraosseous atypical meningioma, a previously unreported association.

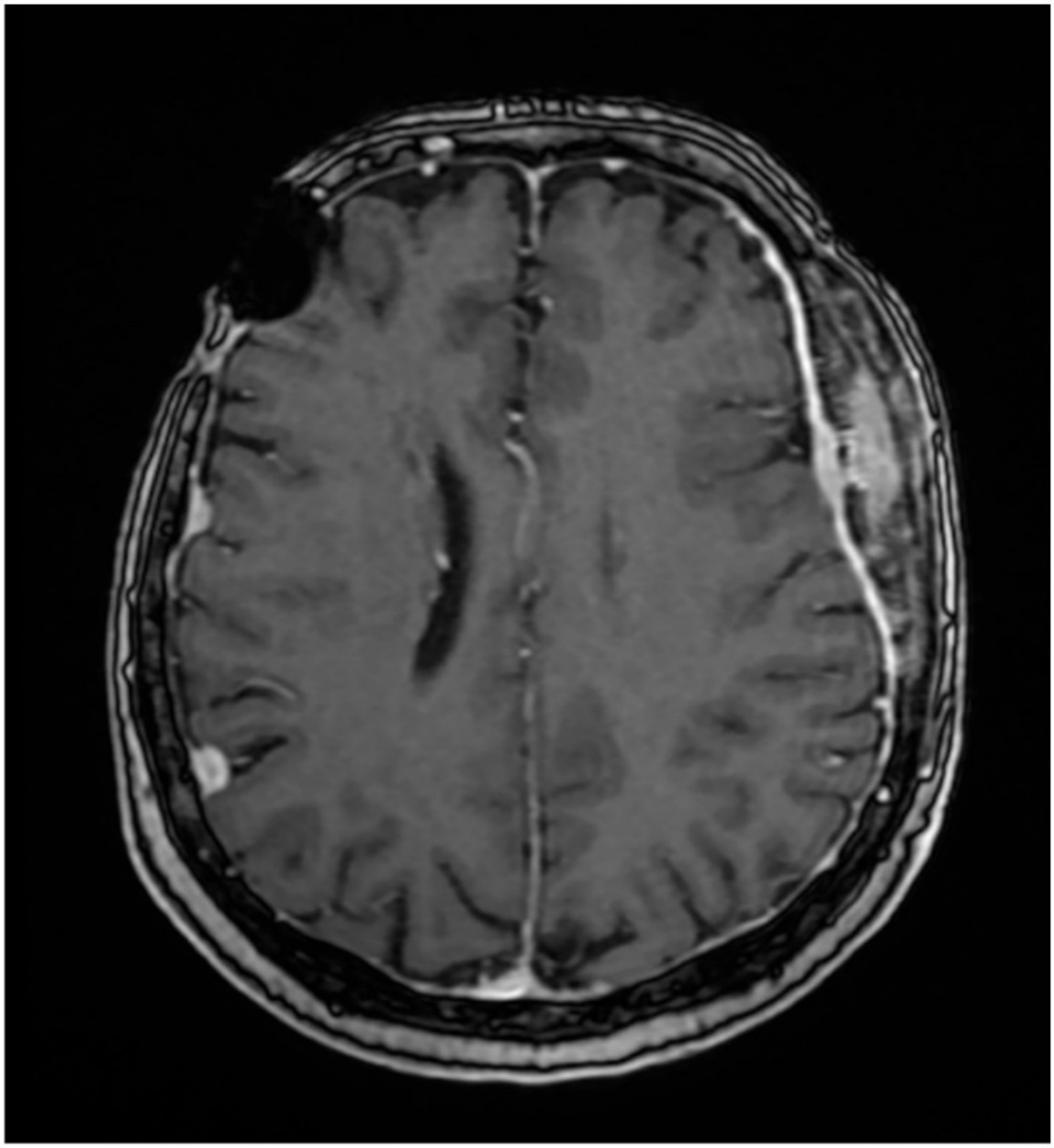

multiple right-sided meningiomas (frontal, temporal, and parietal), a left temporal meningioma, and a fronto-temporo-parietal intraosseous meningioma. Solomon C, Apostu AP, Trufin II, Halmagyi SR, Rogojan L, Șenilă SC, Ungureanu L. Extramammary Paget's Disease of the Scalp with an Underlying Atypical Meningioma-A Case Report and Review of the Literature. Life (Basel). 2025 Jul 3;15(7):1064. doi: 10.3390/life15071064. PMID: 40724566; PMCID: PMC12298491.

Case Presentation

70-year-old woman presented with a slowly progressive, mildly pruritic scalp lesion persisting for approximately ten years. The lesion had been repeatedly treated as eczema and infectious dermatosis with topical corticosteroids, antibiotics, and antifungal agents, without clinical response. Dermatological examination revealed a large 15 cm erythematous, shiny, atrophic plaque involving the left fronto-parieto-temporal scalp, extending beneath preserved white hair, with central alopecia, erosions, crusting, and yellow-white scaling. No lymphadenopathy or neurological deficits were identified. Her medical history was notable for multiple meningiomas, including previous surgical excision of a right frontal meningioma.

Magnetic resonance imaging demonstrated a fronto-temporo-parietal intraosseous lesion characterized by osteolysis, contrast enhancement, extracranial soft tissue extension, meningeal thickening, and adjacent tissue edema, in association with stable multiple intracranial meningiomas. Skin ultrasonography suggested soft tissue infiltration related to meningiomatosis. Laboratory investigations were non-contributory except for elevated antinuclear antibodies (ANA 1:2560), while ENA and anti-desmoglein antibodies were negative. Mycological studies were negative.

Histopathological examination revealed epidermal ulceration with intraepidermal proliferation of atypical discohesive pagetoid cells involving the epidermis and adnexal structures without dermal invasion. Immunohistochemical profiling demonstrated diffuse positivity for CK7, GATA3, HER2, and androgen receptor, while CK20, p63, CK5/6, estrogen receptor, and progesterone receptor were negative, supporting the diagnosis of ectopic EMPD. Comprehensive systemic screening, including mammography and gynecologic evaluation, excluded an associated internal malignancy.

The intraosseous lesion underwent neurosurgical resection followed by cranioplasty using titanium mesh and autologous periosteal grafting. Histopathological analysis confirmed grade II atypical meningioma. Considering the extent and anatomical complexity of the cutaneous lesion, radiotherapy was selected as the therapeutic approach for EMPD. Following completion of 25 photon irradiation sessions, the patient demonstrated significant clinical improvement with near-complete resolution of erythema and scaling, leaving only minimal residual edema.

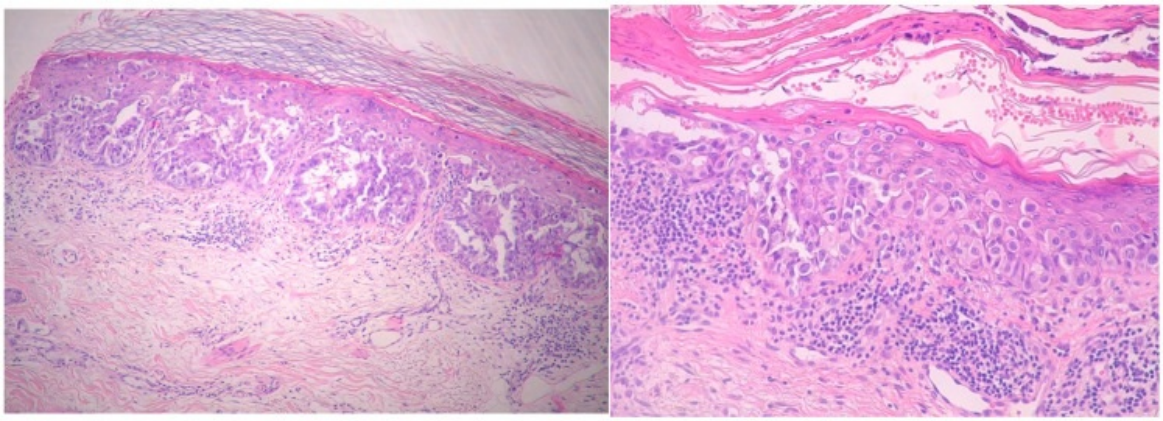

Histopathological picture. Large cells with clear cytoplasm and atypical nuclei, arranged on their own or in nests in the epidermis (Paget cells), spread partially to the adnexa, but with no dermal infiltration (hematoxylin and eosin, original magnification, ×10 ×20). Solomon C, Apostu AP, Trufin II, Halmagyi SR, Rogojan L, Șenilă SC, Ungureanu L. Extramammary Paget's Disease of the Scalp with an Underlying Atypical Meningioma-A Case Report and Review of the Literature. Life (Basel). 2025 Jul 3;15(7):1064. doi: 10.3390/life15071064. PMID: 40724566; PMCID: PMC12298491.

Conclusion

We describe an exceptionally rare presentation of ectopic scalp EMPD associated with intraosseous atypical meningioma, representing both the 10th reported scalp case and the largest lesion described to date. This previously unreported

association expands the spectrum of neoplastic conditions linked to EMPD and underscores the importance of thorough multidisciplinary evaluation. The prolonged diagnostic delay observed in this case highlights the necessity of considering EMPD in persistent atypical scalp lesions refractory to conventional therapy. Histopathological and immunohistochemical assessment remain indispensable for definitive diagnosis. Early recognition and comprehensive oncologic screening are essential to optimize management and improve patient outcomes in this rare and diagnostically demanding entity.

EA DV CONGRESS
VIENNA
30 SEP - 3 OCT 2026

Abstract N°: 2544

Pilomatrical carcinoma of the nasal ala mimicking basosquamous carcinoma: a rare and aggressive adnexal neoplasm.

Carolina Lourenço dos Santos Landini Freitas*[1], JOÃO GARCIA DA ROCHA NETO[1], EDUARDA LUISA ROCHA CORTI[1], Camila Gouvea Facure[1], Carolina Siqueira Varotto Martins[1], MARIA BEATRIZ LIRA DO O ESPOSITO[1], Glaucos Ricardo Paraluppi[1], Juliana Arêas de Souza Lima Beltrame Ferreira[1], Célia Antonia Xavier de Moraes Alves[1], Clovis Antonio Lopes Pinto[1], Mariana Careta[1]

[1] Faculdade de Medicina de Jundiaí, Jundiaí, SP, Brazil

Introduction

Pilomatrical carcinoma is an exceptionally rare malignant adnexal neoplasm originating from hair matrix cells and regarded as the malignant counterpart of pilomatricoma. First described by Lopansri and Mihm in 1980, fewer than 150 cases have been reported in the literature, emphasizing the rarity of this entity and the limited understanding of its biological behavior, prognostic factors, and optimal therapeutic management. The tumor predominantly affects elderly male patients and usually arises in photoexposed areas, especially the head and neck region. Although uncommon, pilomatrical carcinoma demonstrates locally aggressive behavior characterized by infiltrative growth, tissue destruction, high local recurrence rates, and occasional metastatic potential involving lymph nodes, lungs, and bones. Histopathological diagnosis may be particularly challenging because of overlapping morphologic features with basal cell carcinoma, basosquamous carcinoma, squamous cell carcinoma, and sebaceous carcinoma. Consequently, immunohistochemical evaluation and clinicopathological correlation are frequently essential for definitive diagnosis and adequate therapeutic planning.

Case Presentation

A 70-year-old male with a medical history of systemic hypertension and benign prostatic hyperplasia, receiving daily enalapril and doxazosin, presented with a rapidly enlarging lesion on the right nasal ala evolving over approximately four months. The patient reported progressive exophytic growth associated with recurrent spontaneous bleeding episodes and increasing local friability. Physical examination demonstrated an exophytic tumor involving the right nasal ala, covered by hemorrhagic crust and friable tissue. The patient also had a previous history of cutaneous squamous cell carcinoma on the left arm one year earlier, in addition to a significant family history of skin cancer involving his mother and sister. Initial evaluation by a surgeon led to excision of the lesion. Histopathological analysis revealed a basaloid-pattern carcinoma with focal squamous differentiation and ulceration extending to the deep reticular dermis. No vascular, lymphatic, or perineural invasion was identified; however, both lateral and deep surgical margins were compromised. Due to the unusual histological findings, complementary immunohistochemical investigation was recommended to better differentiate between basosquamous carcinoma and sebaceous carcinoma.

Immunohistochemical examination demonstrated a malignant neoplasm composed of basaloid cells with both intraepithelial and invasive dermal components. Numerous foci of squamous differentiation and cystic areas with follicular differentiation were observed. The basaloid component predominated and exhibited marked cytological atypia, elevated mitotic activity, and focal comedonecrosis. Tumor cells showed positivity for p63, high molecular weight cytokeratins (34BE12), LEF-1, and CDX2. In addition, the Ki-67 proliferative index reached approximately 45%, supporting a highly proliferative neoplasm. The overall morphological and immunohistochemical profile favored the diagnosis of pilomatrical carcinoma. Based on these findings, surgical margin enlargement was

indicated for adequate oncological control and reduction of recurrence risk.

Conclusion

This case highlights the diagnostic complexity and aggressive biological behavior of pilomatrical carcinoma, particularly when presenting histopathological overlap with other non-melanoma skin cancers in anatomically sensitive areas such as the nasal ala. Recognition of characteristic histopathological and immunohistochemical findings is essential to avoid misdiagnosis and ensure appropriate treatment. Reporting additional cases is important to improve understanding of the clinical course, histopathological spectrum, prognostic factors, and therapeutic strategies for this rare malignant adnexal tumor.

EA DV CONGRESS
VIENNA
30 SEP - 3 OCT 2026

Abstract N°: 2560

Comparison of the Efficacy of Topical 0.05% Clobetasol Propionate and Topical 0.1% Tacrolimus in the Treatment of Early-Stage Mycosis Fungoides

Aslı Aksu[1], Aysegul Oz*[1], Hazel Kaya[1], Pınar Çetinkaya[1], Birgül Kurt[1], Ilknur Altunay[1]

[1] University of Health Sciences, Şişli Hamidiye Etfal Training and Research Hospital, Department of Dermatology, Istanbul, Türkiye

Introduction

Mycosis fungoides (MF) is the most common form of primary cutaneous T-cell lymphoma, typically managed with skin-directed therapies in early-stage disease. While topical corticosteroids like clobetasol propionate are standard first-line treatments due to their high efficacy, their long-term use is often limited by adverse effects such as skin atrophy and telangiectasia. Topical calcineurin inhibitors (TCIs), such as tacrolimus, inhibit the calcineurin-NFAT signaling pathway involved in MF pathogenesis, offering a biological rationale for their use. The National Comprehensive Cancer Network (NCCN) guidelines acknowledge TCIs as a steroid-sparing option for selected early-stage lesions. However, direct comparative evidence between TCIs and potent corticosteroids remains scarce. This study aimed to compare the clinical efficacy, safety, and relapse rates of topical 0.1% tacrolimus ointment versus 0.05% clobetasol propionate ointment in patients with stage IA–IB MF.

Materials and Methods

A retrospective review was conducted at a tertiary care hospital's Dermato-Oncology clinic between November 2019 and April 2025. Adult patients (≥18 years) receiving skin-directed topical therapy with either 0.1% tacrolimus ointment or 0.05% clobetasol propionate ointment as monotherapy for at least 16 weeks were included. Clinical response was evaluated using standard oncology criteria: complete clinical response (CCR) was defined as 100% clearance; partial response (PR) as ≥50% improvement; and stable disease (SD) as <50% improvement or no change. Relapse was defined as the reappearance of lesions after achieving CCR. All patients were followed for a minimum of two years. Statistical analyses were performed using IBM SPSS Statistics version 26.0. Comparisons between groups utilized the Mann–Whitney U test for continuous variables and Pearson's chi-square or Fisher's exact test for categorical variables, with $p < 0.05$ considered statistically significant.

Results

A total of 40 patients with stage IA–IB MF were included, with 20 patients in each treatment group. In both groups, 70% of patients were classified as stage IA and 30% as stage IB; all had patch-stage disease and B0 blood status. There were no significant differences in baseline characteristics between the groups ($p > 0.05$) (Table 1). In the clobetasol group, 95% achieved CCR and 5% achieved PR, whereas in the tacrolimus group, 60% achieved CCR, 20% achieved PR, and 20% had stable disease (SD) ($p = 0.009$ for CCR; $p = 0.037$ for SD). The median time to CCR was 2 months for clobetasol and 3.5 months for tacrolimus ($p = 0.520$). Among patients achieving CCR, relapse was significantly higher in the clobetasol group (63.2%) compared to the tacrolimus group (25%) ($p = 0.042$). The median remission duration was 6 months for clobetasol and 5 months for tacrolimus ($p = 0.885$). In the tacrolimus group, one patient discontinued treatment due to local irritation and three due to insufficient clinical response; no treatment discontinuations occurred in the clobetasol propionate group (Table 2).

Table 1. Demographic and clinical characteristics of the patients

	0.1% Tacrolimus Group (n=20)	0.05% Clobetasol Propionate Group (n=20)	*p*
Age [median (min-max), years]	55.5 (25-78)	62 (35-77)	0.203
Sex (n, %) Male Female	 12 (60%) 8 (40%)	 11 (55%) 9 (45%)	0.752
Stage (n, %) IA IB	 14 (70%) 6 (30%)	 14 (70%) 6 (30%)	1.000
Disease duration [median (min-max), years]	11.5 (3-30)	7 (3-24)	0.271
Prior Treatments (n, %) dbUVB Topical steroids Topical bexarotene Naïve	 17 (85%) 2 (10%) 1 (5%) -	 17 (85%) - - 3 (15%)	0.845

Data are presented as median (minimum-maximum) for continuous variables and n (%) for categorical variables.
For variables with limited observations, median (minimum–maximum) values are shown.
The Mann–Whitney U test was used for continuous variables. Pearson's chi-square test or Fisher's exact test was used for categorical variables, as appropriate.
*Clinical staging was defined according to the TNMB classification based on Olsen et al.[10]

Table 2. Comparison of clinical response, relapse rates, and treatment discontinuation in tacrolimus and clobetasol propionate groups

	0.1% Tacrolimus Group (n=20)	0.05% Clobetasol Propionate Group (n=20)	*p*
Clinical Response (n, %) CCR PR SD	 12 (60%) 4 (20%) 4 (20%)	 19 (95%) 1 (5%) -	 0.009* 0.157 0.037*
Time to achieve CCR [median (min-max), months]	3.5 (1-12)	2 (1-6)	0.520
Time to achieve PR [median(min-max), months]	1 (1-3)	[a]NA	
Relapse** (n, %)	3 (25%)	12 (63.2%)	0.042*
Duration of Remission/ Time Until Relapse [median (min-max), months]	5 (4-18)	6 (2-21)	0.885
Irritation (n, %)	1 (5%)	0	0.317
Discontinuation of Treatment (n, %) • Due to Irritation (n, %) • Due to Inadequate Response (n, %)	4 (20%) 1 (5%) 3 (15%)	0 0 0	0.037* 0.317 0.075

Data are presented as median (minimum–maximum), as appropriate, for continuous variables, and n (%) for categorical variables.
**Relapse rates were evaluated only in patients who achieved a clinical complete response (CCR).
Comparisons were performed using the Mann–Whitney U test for continuous variables and Pearson's chi-square test or Fisher's exact test for categorical variables, as appropriate. CCR: clinical complete response; PR: partial response; SD: stable disease; IQR: interquartile range; NA: not applicable.
*$p < 0.05$ was considered statistically significant. [a]only one PR observed

Table 1. Demographic and clinical characteristics of the patients Table 2. Comparison of clinical response, relapse rates, and treatment discontinuation in tacrolimus and clobetasol propionate groups.

Conclusions

Topical 0.1% tacrolimus represents an effective and well-tolerated therapy for selected patients with early-stage MF. Although clobetasol propionate was associated with higher initial CCR rates, tacrolimus demonstrated fewer relapses during follow-up, suggesting more sustained disease control. Although concerns have been raised regarding a potential association between TCIs and lymphoma, current evidence suggests that the absolute risk is low and likely confounded, particularly in atopic dermatitis populations. These findings support the use of topical tacrolimus as a valuable steroid-sparing option, particularly for patients requiring long-term maintenance or those with concerns regarding corticosteroid-induced adverse effects.

EA DV CONGRESS
VIENNA
30 SEP - 3 OCT 2026

Abstract N°: 2581

Eruptive Meyerson nevi following melanoma excision: coincidence or immune-mediated response?

Klara Gaćina*[1], Paola Negovetic[1], Dragana Marušić[1], Sanja Spoljar[1]

[1] Sestre milosrdnice University Hospital Center, Department of Dermatology and Venereology, Zagreb, Croatia

Introduction

Meyerson nevus (Meyerson phenomenon) is characterized by an eczematous halo surrounding a pre-existing melanocytic nevus and is considered a benign inflammatory reaction. However, it may represent a diagnostic challenge, particularly in patients with a history of melanoma, as clinical and dermoscopic features can mimic malignancy. Emerging evidence suggests that immune dysregulation may play a role in the development of eruptive or multiple Meyerson nevi. The aim of this report is to present a patient with a recent history of melanoma who developed multiple Meyerson nevi in a short time period, exploring a possible post-melanoma immune-mediated trigger.

Case Presentation

A 63-year-old male patient underwent surgical excision of cutaneous melanoma located on the left abdomen in June 2024, with a Breslow thickness of 1.68 mm and regression up to 1.1 mm. During routine follow-up in February 2026, a complete dermatological examination and digital dermoscopy were performed. Clinical examination revealed two coin-sized nummular erythematous lesions on the right lateral abdomen. The lesions showed an eczematous appearance with an erythematous rim and center, and a relatively paler pink zone in between. Digital dermoscopy findings were consistent with Meyerson nevus. Routine postoperative ultrasonographic follow-up and laboratory findings were unremarkable. Topical therapy with a combination of betamethasone and gentamicin was initiated. At one-month follow-up, repeat digital dermoscopy demonstrated clinical and dermoscopic improvement of the lesions. At the same visit, the patient reported pruritus in the area of a nevus on the left lateral trunk. Clinical examination and digital dermoscopy raised suspicion of an additional Meyerson nevus, and the same topical therapy (betamethasone/gentamicin) was prescribed. At the next follow-up examination, regression was observed and no new Meyerson nevi were detected.

Conclusion

Meyerson nevus represents a benign inflammatory reaction but may pose a diagnostic dilemma, particularly in patients with a history of melanoma. The occurrence of multiple lesions within a short period, as observed in this case, may further increase clinical concern. This case highlights the importance of careful clinical and dermoscopic evaluation in melanoma follow-up, as well as the usefulness of digital dermoscopy in monitoring lesion evolution and avoiding unnecessary surgical procedures. Beyond a purely coincidental finding, a potential immunological link may be considered. Meyerson phenomenon is believed to involve a localized T-cell–mediated inflammatory response, possibly associated with increased expression of adhesion molecules and immune activation in the skin. In patients with prior melanoma, such reactions may reflect a broader state of immune dysregulation or heightened cutaneous immune surveillance. Recognition of this phenomenon is crucial to avoid misinterpretation as melanoma recurrence or new primary lesions. Digital dermoscopy plays a key role in monitoring and supports conservative management. Further observations are needed to clarify whether eruptive or multiple Meyerson nevi could represent a marker of post-melanoma immune activity rather than a coincidental finding.

EADV Congress 2026, VIENNA
30 SEPTEMBER - 03 OCTOBER 2026
POWERED BY M-ANAGE.COM

EA DV CONGRESS
VIENNA
30 SEP - 3 OCT 2026

Abstract N°: 2586

Nails as a Diagnostic Clue: Multiple Onychopapillomas in BAP1 Tumor Predisposition Syndrome

Marija Buljan*[1], Dragana Marušić[2]

[1] Sestre Milosrdnice University Hospital Centre, Department of Dermatology and Venereology, Zagreb, Croatia, School of Dental Medicine, Department of Dermatology and Venereology, Zagreb, Croatia

[2] General Hospital Karlovac, Karlovac, Croatia

Introduction

BRCA1-associated protein 1 tumor predisposition syndrome (BAP1-TPDS) is a rare autosomal dominant cancer susceptibility syndrome caused by germline pathogenic variants in the BAP1 gene. It is associated with an increased risk of several malignancies, including uveal melanoma, cutaneous melanoma, mesothelioma, renal cell carcinoma, and basal cell carcinoma. In recent years, nail unit
abnormalities, particularly multiple onychopapillomas, have emerged as a potentially characteristic yet still underrecognised phenotypic manifestation of the syndrome.

Case Presentation

We report a 64-year-old female patient with genetically confirmed BAP1-TPDS who developed progressive nail changes clinically consistent with multiple onychopapillomas during routine dermatologic follow-up. Examination revealed longitudinal erythronychias affecting multiple fingernails on both hands, associated with distal subungual hyperkeratosis and subtle distal fissuring of the nail plate. Clinically similar changes were also evident in the toenails. The lesions were asymptomatic but demonstrated gradual progression over time, with an increasing number of involved nails and greater clinical prominence.

The patient had no history of visceral malignancy during follow-up. Her personal history was notable for multiple BAP1-inactivated melanocytic tumors (BIMTs), five of which were excised in 2017 from the right lumbar, right superior gluteal, right inferior gluteal, left femoral, and right scapular regions, including a BAP1-negative melanoma on the trunk. Her family history was highly suggestive of hereditary cancer predisposition, including BAP1-negative melanoma and urinary bladder carcinoma in her father, as well as pleural mesothelioma, lung carcinoma, gastrointestinal carcinoma, and multiple BIMTs among second-degree relatives.

Onychopapilloma is a benign neoplasm of the distal nail matrix and/or nail bed that typically presents as a solitary lesion. In contrast, multiple onychopapillomas are exceedingly uncommon and should raise suspicion for an underlying hereditary syndrome. Only a limited number of cases describing multiple onychopapillomas in patients with BAP1-TPDS have been reported to date. Importantly, a recent cohort study by Luchini et al. (2024) involving 47 individuals with germline BAP1 mutations identified nail abnormalities in 87.2% of patients, while findings consistent with onychopapillomas were observed in 83.0%, with polydactylous involvement present in 97.4% of affected individuals. These observations strongly support nail involvement as a frequent and potentially highly characteristic manifestation of BAP1-TPDS.

Conclusion

Multiple onychopapillomas may represent an important and underrecognised phenotypic marker of BAP1-TPDS. Their identification in patients with a suggestive personal or family history should prompt consideration of genetic evaluation for BAP1 mutations. Early recognition of this clinical feature may facilitate timely diagnosis, implementation of targeted oncologic surveillance, and screening of at risk relatives. Greater awareness among dermatologists and dermoscopy specialists is essential, as nail findings may precede the development of internal malignancies and provide a valuable opportunity for early detection of this hereditary cancer syndrome and surveillance in affected individuals and their families. Given the paucity of published reports, increasing recognition of multiple onychopapillomas may substantially expand the phenotypic spectrum and facilitate earlier identification of BAP1-TPDS.

EADV CONGRESS
VIENNA
30 SEP - 3 OCT 2026

Abstract N°: 2586

Viral Oncogenesis and Cutaneous Malignancy Outcomes in Solid Organ Transplant Recipients: A Systematic Review

Kim Tran*[1], Kimia Ameri[2], Sofia Maruschak-Love[1], Sherilyn Wen[3], Eunice Chow[4], Ilya Mukovozov, MD, PhD, FRCPC, DABD, FAAD[5]

[1] Faculty of Medicine and Dentistry, University of Alberta, Edmonton, Canada
[2] Faculty of Medicine, University of British Columbia, Vancouver, Canada
[3] Faculty of Medicine, University of Toronto, Toronto, Canada
[4] Division of Dermatology, Department of Medicine, University of Alberta, Edmonton, Canada
[5] Division of Dermatology, Department of Medicine, Women's College Hospital, University of Toronto, Toronto, Canada

Introduction
Solid organ transplant recipients (SOTRs) experience a substantially increased risk of cutaneous malignancy, particularly keratinocyte carcinomas due to long-term immunosuppression. Beyond ultraviolet (UV) radiation, viral oncogenesis is an important risk factor in cutaneous carcinogenesis in this population. Oncogenic viruses such as human papillomaviruses (HPV), human herpesviruses (HHV), Epstein-Barr virus (EBV) and Merkel cell polyomavirus (MCPyV) have been implicated in tumor initiation, progression, and aggressiveness. However, existing evidence is heterogeneous and the contribution of viral infection to cutaneous malignancy incidence, recurrence, metastasis, and mortality in SOTRs remains unclear. This systematic review aims to synthesize and evaluate available evidence to inform prevention, screening, and management strategies.

Materials and Methods
Medline, EMBASE, and Web of Science were systematically searched for original studies, including case-control and cohort designs published up to February 2026. In total, 1654 articles were screened via 4 reviewers, and 117 studies were included in the final analysis. Eligible exposures included HPV, HHV, cytomegalovirus (CMV), EBV, MCPyV and cutaneous malignancies.

Results
Demographic reporting was heterogenous across studies with some describing entire transplant cohorts and others focusing on cancer-specific subgroups. Patient ages ranged from 15 months to 85 years with most cohorts reporting median ages in the sixth to seventh decade. Kidney transplantation was the most common (78.9%), followed by liver (13.2%), heart (2.8%), mixed (0.95%) and lung (0.92%); while 3.2% of patients had an unspecified transplant type. 83.3% of SOTRs were on immunosuppression, most commonly calcineurin inhibitor-based triple therapy (tacrolimus or cyclosporine with an antimetabolite and corticosteroids). Following diagnosis of cutaneous malignancy, immunosuppression was either modified via dose reduction, discontinuation, or conversion to mTOR inhibitors (i.e., sirolimus or everolimus).

Time to onset of cutaneous malignancy varied by virus: HHV-8 associated cancers developed approximately within 1-2 years post-transplant, EBV-associated malignancies ranged from several months to decades, MCPyV-related tumors appeared within 5 years up to decades, CMV-associated cases occurred within 4-22 months, and HPV-associated lesions' appearance ranged from 1 year to decades.

HHV-8 demonstrated a strong association with Kaposi sarcoma (KS) often with extracutaneous involvement. EBV

was identified in a small subset of cases but was associated with rare, aggressive malignancies including cutaneous T-cell lymphoproliferative disorders and B-cell lymphomas. MCPyV was detected in only 7-33% of Merkel cell carcinoma (MCC) cases in SOTRs, suggesting that MCC in transplant recipients is disproportionately driven by the UV-dependent, virus-negative pathway. HPV on the other hand was highly associated with anogenital and cutaneous squamous cell carcinoma (SCC). β-HPV infection, particularly high viral diversity and load of species 1 types (e.g., HPV5, 8, 20), was associated with a 1.7-2.8-fold increased risk of cutaneous SCC in SOTRs, though the role of β-HPV remains likely that of a co-factor alongside UV exposure and immunosuppression. CMV may also contribute to tumor initiation in KS.

Conclusions

Viral oncogenesis contributes to skin cancer in SOTRs in a heterogeneous, context-dependent manner. HPV is implicated in anogenital and cutaneous SCC, with β-HPV acting primarily as a co-factor alongside UV exposure and chronic immunosuppression. The most consistent virus–tumor association is HHV-8 in KS, while MCPyV and EBV account for a smaller, variable subset of cases. Overall, viral infections appear to modify rather than independently determine cutaneous malignancy risk. Further prospective studies are needed to clarify causality and inform risk-adapted prevention and management strategies.

EADV CONGRESS
VIENNA
30 SEP - 3 OCT 2026

Abstract N°: 2608

Efficacy and Safety of Tirbanibulin 1% Ointment for Actinic Keratosis At 1-Year Follow-Up: A Real-Life Extension Study

Federica Li Pomi*[1], Mario Vaccaro[2], Michelangelo Rottura[2], Natasha Irrera[2], Francesco BORGIA[2]

[1] University of Palermo, Palermo, Italy

[2] University of Messina, Messina, Italy

Introduction

Tirbanibulin 1% ointment has demonstrated short-term efficacy and excellent tolerability in the treatment of actinic keratosis (AK) on the face and scalp. However, data on long-term efficacy are still lacking.

Materials and Methods

This prospective, single-center, 12-month extension study included patients with facial and scalp AKs previously treated with tirbanibulin 1% ointment once daily for 5 consecutive days. Long-term analysis was restricted to lesions that had achieved complete clinical clearance at the 2-month follow-up. At 12 months, the treated areas were reassessed clinically and dermoscopically. High-resolution images obtained at baseline, 2 months, and 12 months were compared lesion by lesion to distinguish sustained clearance, recurrence at the same anatomical site, and the development of new AKs within the treated field.

Results

Thirty-seven patients were reassessed at 12 months. Of the 228 AKs treated at baseline, 116 lesions had achieved complete clearance at 2 months and were therefore eligible for long-term evaluation. At 1 year, 70/116 lesions (60.3%) remained free of recurrence, whereas 46/116 (39.7%) relapsed. Sustained clearance was observed in 35/51 grade 1 lesions (68.6%), 32/57 grade 2 lesions (56.1%), and 3/8 grade 3 lesions (37.5%). In addition, 35 new AKs developed within the previously treated field. No delayed local or systemic adverse events and no progression to invasive cSCC were observed during follow-up. Patient-reported satisfaction was high, and 94% of patients stated they would be willing to repeat the treatment.

Conclusions

Tirbanibulin was associated with sustained lesion clearance at one year, particularly in lower-grade AKs. While recurrence remains relatively common—especially in thicker lesions—the treatment was well tolerated and associated with no delayed adverse effects. Its short application regimen and excellent safety profile support tirbanibulin’s role in the long-term management of field cancerization.

EADV CONGRESS
VIENNA
30 SEP - 3 OCT 2026

Abstract N°: 2613

Association of Cutaneous and Systemic Comorbidities in Patients with Mycosis Fungoides: A Case–Control Study

Ayşe Çal*[1], İlknur Kıvanç Altunay[1], Aslı Aksu[1]

[1] Department of Dermatology, Şişli Hamidiye Etfal Training and Research Hospital, University of Health Sciences, ıstanbul, Türkiye

Introduction
Mycosis fungoides (MF), the most common subtype of cutaneous T-cell lymphoma, is characterized by chronic inflammation, immune dysregulation, and epidermotropism. These mechanisms may predispose patients to various comorbid conditions; however, data regarding their distribution and association remain limited and inconsistent.To evaluate the relationship between MF and cutaneous as well as systemic comorbidities in comparison with an age- and sex-matched healthy control group.

Materials and Methods
This prospective case–control study included 80 patients with biopsy-proven MF and 80 healthy controls matched for age and sex. Demographic data, disease characteristics, treatment status, and comorbidities were recorded. All participants underwent a full dermatological examination. Statistical analyses were performed using SPSS v31. Categorical variables were compared using chi-square or Fisher's exact test, and continuous variables using independent samples t-test. Multivariate analysis was conducted with binary logistic regression to identify independent associations. A p-value <0.05 was considered statistically significant.

Results
The mean age was 51.77±15.19 years in the MF group and 53.85±15.63 years in controls (p=0.408), with equal sex distribution. Most patients were in early stages (IA–IB).

Systemic comorbidities did not differ significantly between groups. However, seborrheic dermatitis (OR≈2.3) and epidermoid cysts (OR≈7.5) were significantly more frequent in MF patients, whereas androgenetic alopecia was more common in controls (OR≈2.0). In univariate analysis, hemangiomas were increased in MF but lost significance in multivariate analysis.

Treatment subgroup analysis showed higher rates of striae and acanthosis nigricans in untreated patients, while tinea corporis was more frequent in those receiving phototherapy. No cases of striae or acanthosis nigricans were observed in the acitretin group.

Conclusions
While systemic comorbidities were not significantly increased, certain cutaneous conditions were more prevalent in MF patients. These findings suggest a possible role of chronic inflammation and follicular dysfunction in the development of specific skin comorbidities. Larger, multicenter studies are needed to clarify these associations.

EADV CONGRESS
VIENNA
30 SEP - 3 OCT 2026

Abstract N°: 2614

Necrolytic Migratory Erythema in a Context of Severe Malnutrition

Ouissam BENMESSAOUD*[1], Tarek Mansoul[1], RIADH BOUSSAID[1], Amel GHERFI[1], Asma BOUHILA[1], Khadidja BOUARROUDJ[1], Lilia KAGHOUCHE[1], Safa DJEBBAS[1], Ahmed Samaouel Chehad[1]

[1] Department of Dermatology, University of Constantine, Constantine, Algeria

Introduction

Necrolytic migratory erythema (NME) is a rare dermatosis most often paraneoplastic, occurring as part of glucagonoma syndrome.
It typically presents as a dark-red migratory erythema, frequently erosive, with centrifugal progression predominantly involving the extremities, skin folds, and perioral and perigenital regions.
Cases occurring in the absence of this secreting tumor, grouped under the term pseudoglucagonoma syndrome, have also been described, leading to diagnostic challenges.
We report a rare case of NME in a patient with a history of colon cancer and severe malnutrition.
This observation illustrates an unusual nutritional deficiency-related form of NME and highlights the importance of broadening etiological hypotheses beyond glucagonoma.

Case Presentation

We report the case of a 62-year-old woman followed for colonic adenocarcinoma, surgically treated in 2024 by partial colectomy with anastomosis, who was admitted to our department for a diffuse cutaneous eruption evolving for one year.
Clinical examination revealed weight loss with a body mass index of 21.5 kg/m^2 and diffuse polycyclic erythematous-squamous lesions bordered by a desquamative collarette, sparing the palms and soles.
Histopathological examination showed an atrophic epidermis with parakeratosis, apoptotic keratinocytes, and inflammatory infiltrate at the dermoepidermal junction.
Laboratory investigations demonstrated normal fasting blood glucose, HbA1c, and plasma glucagon levels, whereas the remaining workup revealed severe malnutrition, including hypoalbuminemia at 23 g/L, hypochromic microcytic anemia with low serum iron levels, and hypocholesterolemia.
Radiological assessment (thoraco-abdomino-pelvic CT scan), tumor markers, and lower gastrointestinal endoscopy were unremarkable.
Parenteral nutrition led to improvement of the skin lesions.
In the absence of evidence supporting glucagonoma, the diagnosis of NME within the setting of pseudoglucagonoma syndrome was retained

Conclusion

The presence of NME requires investigation for a neuroendocrine tumor such as glucagonoma, particularly in the presence of the classic triad of NME, diabetes mellitus, and weight loss. Exceptionally, as in our case, NME may occur in the absence of a neuroendocrine tumor and may be associated with malabsorption states, hepatic disorders, or nutritional deficiencies. Its pathophysiology remains poorly understood and may involve deficiencies in amino acids, zinc, or essential fatty acids.
This case highlights the importance of considering pseudoglucagonoma syndrome in patients presenting with NME, particularly in the setting of malnutrition, in order to guide appropriate management.

EADV Congress 2026, VIENNA
30 SEPTEMBER - 03 OCTOBER 2026
POWERED BY M-ANAGE.COM

EA DV CONGRESS
VIENNA
30 SEP - 3 OCT 2026

Abstract N°: 2616

Clinicopathological spectrum of primary cutaneous lymphomas: a 10-year single-center study in a North African cohort

kenza Allali*[1], Bendaoud Layla[1], Mariem Aboudourib[1], Amal Said[1], Ouafa Hocar[1], Sanaa Soufi[2], fakhri anas[2]

[1] Department of Dermatology, Mohammed VI University Hospital, Cadi Ayyad University, Marrakech, Morocco, Marrakech, Morocco

[2] Department of Pathology, Mohammed VI University Hospital, Cadi Ayyad University, Marrakech, Morocco, Marrakech, Morocco

Introduction

Primary cutaneous lymphomas (PCL) encompass a heterogeneous group of extranodal lymphomas with highly variable clinical presentations, often mimicking benign inflammatory dermatoses and contributing to delayed diagnosis. Despite their clinical relevance, data from North African populations remain scarce.**Objective:**To characterize the clinicopathological landscape of primary cutaneous lymphomas in a North African cohort, emphasizing diagnostic delay, clinical mimickers, and distinctive subtype distribution.

Materials and Methods

We conducted a retrospective descriptive study including all histologically confirmed cases of primary cutaneous lymphomas diagnosed over a 10-year period in a single-center setting. Secondary lymphomas and incomplete records were excluded. Diagnoses were established through systematic clinicopathological correlation, integrating histopathological examination and immunohistochemistry, and classified according to WHO-EORTC criteria.

Results

Thirty-four patients were included (mean age: 55 years; male-to-female ratio: 1.4). An increase in the number of diagnosed cases was observed during the last four years. The mean diagnostic delay was 15.7 months.

Clinically, pruritus was reported in 54% of cases. Lesions were predominantly erythematous-squamous plaques, followed by nodular and tumoral forms, with preferential involvement of photo-protected areas. Diagnostic confusion with inflammatory dermatoses was observed in 26% of cases, particularly in early-stage mycosis fungoides.

Cutaneous T-cell lymphomas accounted for 80% of cases, predominantly mycosis fungoides (62%), including three transformed forms and one pagetoid variant. B-cell lymphomas represented 20% of cases and were exclusively diffuse large B-cell lymphomas.

Histopathological examination showed epidermotropism in 90% of mycosis fungoides cases, with Pautrier microabscesses in 25%. Immunohistochemistry confirmed typical phenotypes with a high proliferative index in large B-cell lymphomas.

Lymph node involvement was confirmed in 5 out of 6 biopsied patients, consistent with advanced-stage disease at diagnosis.

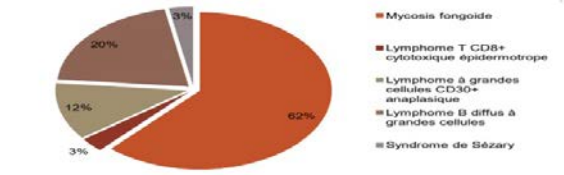

Prévalence des sous types de LC

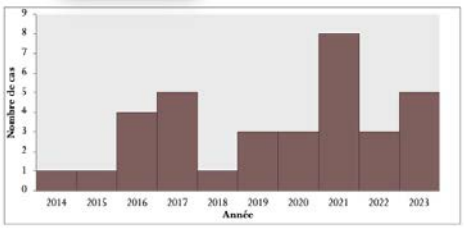

Incidence annuelle des LCP

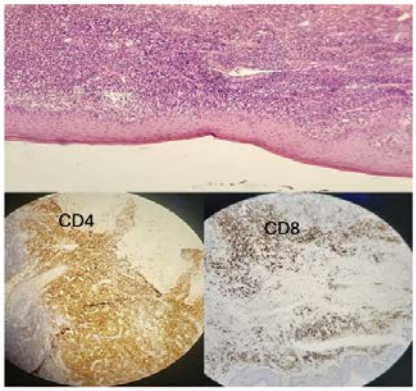

Coupes histologiques + IHC d'un cas de Mycosis fongoide suivi au service de dermatologie

Conclusions

This study highlights the predominance of cutaneous T-cell lymphomas, particularly mycosis fungoides, and underscores the marked clinicopathological heterogeneity of primary cutaneous lymphomas. Prolonged diagnostic delay, frequent clinical misdiagnosis with inflammatory dermatoses, and a high rate of advanced-stage presentation represent key challenges in our cohort. The exclusive occurrence of diffuse large B-cell lymphoma among B-cell subtypes and the increasing number of diagnoses over time suggest distinctive epidemiological features. These findings emphasize the need for earlier recognition and strengthened clinicopathological collaboration to improve patient management.

EA DV CONGRESS
VIENNA
30 SEP - 3 OCT 2026

Abstract N°: 2617

The impact of a SmartPhone applicatiOn for skin cancer risk assessmenT on the healthcare system (SPOT-study): A randomized controlled trial

Anna Smak Gregoor*[1], Tobias Sangers[1], Carin Uyl-de Groot[2], Eveline Heijnsdijk[3], Tamar Nijsten[1], Marlies Wakkee[1]

[1] Erasmus MC Cancer institute, Rotterdam, Netherlands

[2] School of Health Policy and Management, Erasmus University, Rotterdam, Netherlands

[3] Department of Public Health, Erasmus University Medical Center, Rotterdam, Netherlands

Introduction

Artificial intelligence (AI)-based mobile health (mHealth) smartphone apps for skin cancer detection are increasingly available to the general population. Although conventional population-based skin cancer screening is currently not recommended due to concerns regarding (cost)-effectiveness and overdiagnosis, it remains unclear whether the introduction of AI might change this paradigm. Therefore, we conducted a randomized controlled trial (RCT) to investigate the impact of implementing an AI-based mHealth app on skin cancer detection and healthcare consumption for benign skin lesions.

Materials and Methods

The SPOT study is an investigator-initiated and -designed, unblinded, RCT. Participants were recruited via a Dutch non-profit health insurance in the region in and around Rotterdam, the Netherlands, between August and December 2021. Participants were randomly assigned (3:2) to either free access to an AI-based mHealth app for skin cancer risk detection or care-as-usual (i.e. visiting their general practitioner). The three co-primary endpoints were the differences at 12-months follow-up in the intention-to-treat population in 1) the incidence of histologically verified skin cancers, 2) insurance claims for benign skin lesions, and 3) insurance claims for malignant and premalignant skin lesions. Secondary endpoints included differences in melanoma characteristics (T-stage and Breslow thickness), the proportion of surgical interventions, overall use of dermatological care, and associated costs.

Results

Of the 240,819 adults invited, a total of 19,009 people participated in this study. Within the group of study participants, the skin cancer incidence was higher among the intervention group compared to the control group at 12 months follow-up (2.7% (n = 305) vs. 2.3% (n = 171); risk difference (RD) 0.4% (95% confidence interval (CI) -0.1 - 0.9), p = 0.10), though this difference was not statistically significant (Table 1). However, participants in the intervention group had significantly more claims for benign skin lesions (3.9% (n = 443) vs. 2.6% (n = 198), RD 1.3% (95% CI 0.7 - 1.7), p < 0.001). No statistically significant difference was found in claims for malignant and premalignant skin lesions (6.9% (n = 791) vs. 6.3% (n = 478), RD 0.6% (95% CI -0.2 - 1.3), p = 0.23). Notably, the incidence of claims for malignant and premalignant skin lesions combined was 2.8-fold higher among the 19,009 study participants compared to those who did not participate in the study, suggesting an important effect of activation bias. Regarding the secondary outcomes, we found no difference in melanoma Breslow thickness (median 0.5 mm, interquartile range [IQR] 0.3 - 0.7 vs. 0.7 mm, IQR 0.4 - 0.9; p = 0.59) or T-stage. Those in the intervention group underwent more surgical interventions, had an overall larger care consumption and higher mean costs per participant (€63 (95% CI €58 - €67), vs. €47 (€41 - €52); p < 0.001) compared to controls.

Table 1. Number of histologically confirmed melanomas, cutaneous squamous cell carcinomas and basal cell carcinomas within the control and intervention group at 12 months follow-up.

	Control group (N = 7,536)	**Intervention group** (N = 11,473)	**Risk Difference (95% CI)**	**p-value**
Melanoma	23	30		
Patients with a melanoma	23 (0.31%)	30 (0.26%)	-0.05% (-0.21 - 0.12)	0.68
Median Breslow thickness (IQR) - mm	0.7 [0.4-0.9]	0.5 [0.3-0.7]		0.59
Melanoma TNM stage*				0.38
pTis	11 (47.8%)	8 (26.7%)		
pT1a & pT1b	10 (43.5%)	17 (56.7%)		
pT2a & pT2b	2 (8.7%)	2 (6.7%)		
pT3a & pT3b	0 (0%)	1 (3.3%)		
pT4a & pT4b	0 (0%)	2 (6.7%)		
cSCC – no.	22	61		
Patients with a cSCC – no. (%)	22 (0.29%)	55 (0.48%)	0.19% (0 - 0.37)	0.06
BCC – no.	196	292		
Patients with a BCC– no. (%)	135 (1.79%)	228 (1.99%)	0.2% (-0.21 - 0.6)	0.36
Total – no. †	244	383		
Patients with any type of skin cancer – no. (%)†	171 (2.27%)	305 (2.66%)	0.39% (-0.07 - 0.85)	0.10

Data are n or n (%) unless otherwise indicated. Differences between groups were compared Wilcoxon's rank sum test for medians, $\chi 2$ for categorical variables containing at least 10 observations within a cell and Fisher's exact test for categorical variables containing less than 10 observations within a cell. IQR = interquartile range, mm = millimetre, CI = confidence interval, cSCC = cutaneous squamous cell carcinoma, BCC = Basal cell carcinoma. Percentages may not sum to 100 because of rounding. * Staging reported according to the American Joint Committee on Cancer eighth edition (AJCC8). † Only including melanoma, cSCC and BCC.

Conclusions

In the first 12 months of this study, access to an AI-based mHealth app for skin cancer risk detection showed a modest trend toward a higher rate of skin cancer detection compared to care-as-usual. However, it also resulted in significantly more dermatological care for benign skin lesions.

EA DV CONGRESS
VIENNA
30 SEP - 3 OCT 2026

Abstract N°: 2623

Neoadjuvant Capecitabine in Advanced Cutaneous Squamous Cell Carcinoma of the Head and Neck

Savanah Haidar*[1], Alex Mlynarek[2], Philippe Lefrancois[2], Osama Roshdy[2], Manish Khanna[2], Geneviève Fortier-Riberdy[1], Keith Richardson[2], Livia Florianova[2], Marc Pusztaszeri[2], Derin Caglar[2], Nader Sadeghi[2], Michael Hier[2], Khalil Sultanem[2], Christina Tsien[2], Nathaniel Bouganim[2], Khashayar Esfahani[2], Marco Mascarella[2]

[1] University of Montreal, Montreal, Canada

[2] McGill University, Montreal, Canada

Introduction

The incidence of cutaneous squamous cell carcinoma of the head and neck (SCCHN) has increased, including among patients with high-risk disease. Delays in access to and initiation of care are associated with disease progression and worse outcomes. Neoadjuvant approaches have therefore gained interest as a strategy to reduce tumor burden in patients with advanced disease. Capecitabine has previously shown effective antitumor activity with low toxicity. To our knowledge, this is the first study to evaluate the efficacy and tolerability of neoadjuvant capecitabine (NC) in patients with advanced cSCCHN awaiting surgery.

Materials and Methods

This prospective case series was conducted at 2 academic centers in Montreal, Canada, and included 15 consecutive patients with advanced SCCHN who were awaiting surgery. Two cycles of neoadjuvant capecitabine (NC) (1000 mg, twice daily, on days 1–14, followed by a 1-week rest period) were administered according to the Capecitabine Prior to Tumor Resection in Entoncology (CAPTURE) protocol, with surgical resection performed within 1 to 2 weeks after treatment completion. Main outcomes and measures included clinical tumor response and clinical to pathologic stage migration, defined as the comparison of initial clinical stage with the postsurgical pathologic stage.

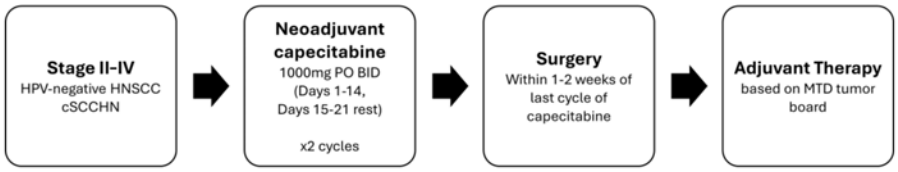

Figure. Flow Diagram of the Proposed Protocol for the Capecitabine Prior to Tumor Resection in Entoncology (CAPTURE) Trial

Results

The mean (SD) age of the cohort was 77 (8.1) years; 6 patients (40%) were female, and 9 patients (60%) were male. Clinical tumor regression was observed in 10 of 15 patients (67%). Among those who underwent resection, 5 (42%) achieved a complete pathologic response. Two patients avoided surgery due to complete treatment response and opted to receive radiotherapy. Nonresponse occurred for 5 patients, including 1 patient who experienced progression to metastatic disease. No grade 3 or higher capecitabine-related toxic effects were reported.

Table 1. Patient Characteristics.

Sex	Age, y	Subsite	Clinical stage	Tumor size, cm	Tumor depth, mm	Tumor differentiation	PNI	Clinical response to capecitabine	Pathologic stage	Surgical treatment post-capecitabine	Clinical pathologic stage migration	Pathologic response, modified Ryan score	Adjuvant therapy	Adverse events	CCI score	Follow-up	Immuno-suppression status
M	60-69	Scalp	cT4N0	20	14.0	Poorly	Yes	No change	pT4N0	Craniectomy with lat	None	3	None	None	8	6 mo	Kidney Transplant
M	70-79	Scalp	cT3N0	8.2	6.0	Well	No	No change	pT3N0	Scalpectomy with lat dorsi	None	3	None	ECA bleed	5	6 mo	No
M	70-79	Scalp	cT4N3b	5.5	12.0	Poorly	Yes	Increased tumor	pT4N3b	WLE of the skin with lat dorsi	None	3	Cemiplimab	None	7	5 mo	Kidney Transplant
M	70-79	Ear	cT3N0	5.7	6.0	Moderately	No	Tumor reduction	pT1N0	Lateral temple bone resection with MSAP	Downstage	1	None	None	4	4 mo	No
M	60-69	Lip	cT2N0	3.0	1.5	Well	No	Tumor reduction	pT1N0	WLE of the lip with mucosal advancement	Downstage	0	None	None	5	1 mo	No
M	80-89	Parotid	cT3N0	4.5	7.0	Moderate-to-poorly	Yes	No change	pT3N0	WLE of parotid with submental flap	None	3	None	None	5	1 mo	No
F	80-89	Nose	cT4N0	2.0	10.0	Moderately	N/A	Tumor reduction	N/A	None	N/A	N/A	None	None	5	—	No
M	60-69	Lip	cT3N0	4.1	6.0	Well	No	Tumor reduction	pT2N0	WLE of the lip with mucosal advancement	Downstage	2	None	None	4	2 wks	No
F	80-89	Scalp	cT4N0	7.0	13.0	Moderately	N/A	Increased tumor	N/A	None	N/A	N/A	Cemiplimab	None	6	N/A	No
F	70-79	Nose	cT3N0	4.2	9.0	Well	N/A	Tumor reduction	N/A	None	N/A	N/A	None	None	7	N/A	No
M	70-79	Parotid	cTXN1	N/A	N/A	Moderately	Yes	Tumor reduction	pT0N1	Parotidectomy	None	0	XRT	None	5	18 mo	No
M	70-79	Lip	cT2N0	3.0	4.0	Well-to-moderately	No	Tumor reduction	pT0N0	WLE of the lip with mucosal advancement	Downstage	0	None	None	5	20 mo	No
F	80-89	Lip	cT2N0	2.8	3.0	Well-to-moderately	No	Tumor reduction	pT0N0	WLE of the lip with mucosal advancement	Downstage	0	None	None	5	18 mo	No
F	90-99	Parotid	cTXN1	N/A	NA	Well-to-moderately	No	Tumor reduction	pTXN0	Parotidectomy	Downstage	0	None	None	8	21 mo	No
F	80-89	Parotid	cT1N1	1.8	6.0	Poorly	No	Tumor reduction	pT0N1	WLE, parotidectomy and neck dissection with local flap	Downstage	2	None	None	7	21 mo	No

Abbreviations: CCI, comprehensive complication index; ECA, external carotid artery: F, female; M, male; MSAP, medial sural artery perforator; NA, not applicable; PNI, perineural invasion: WLE, wide local excision; XRT, radiotherapy.

As described by Mascarella et al. SCCHN indicates cutaneous squamous cell carcinoma of the head and neck; HNSCC, head and neck squamous cell carcinoma; MTD, multidisciplinary.

Conclusions

This case series found that NC demonstrated significant tumor regression and pathologic response without severe treatment-related toxic effects. NC may be an effective treatment option for providing disease control and tumor downstaging in patients with advanced SCCHN.

EADV Congress 2026, VIENNA
30 SEPTEMBER - 03 OCTOBER 2026
POWERED BY M-ANAGE.COM

EA DV CONGRESS
VIENNA
30 SEP - 3 OCT 2026

Abstract N°: 2629

Eruptive Halo Nevus Phenomenon Associated with Gastrointestinal Melanoma

Ouissam BENMESSAOUD*[1], Tarek Mansoul[1], RIADH BOUSSAID[1], Amel GHERFI[1], Asma BOUHILA[1], Khadidja BOUARROUDJ[1], Lilia KAGHOUCHE[1], Safa DJEBBAS[1], Ahmed Samaouel Chehad[1]

[1] Department of Dermatology, University of Constantine, Constantine, Algeria

Introduction

Halo nevus, also known as Sutton's phenomenon, is characterized by the development of a circular achromic halo surrounding one or several pigmented nevi and corresponds to an autoimmune destruction of melanocytes.
This regression phenomenon, usually observed in young adults, may occur in isolation, be associated with the onset of vitiligo, or more rarely be associated with melanoma, thus warranting a thorough examination of all pigmented lesions.
We report an original rare case involving eruptive halo nevus phenomenon associated with gastrointestinal melanoma.

Case Presentation

A 46-year-old woman with a history of anemia, underwent surgery for intestinal obstruction syndrome.
Investigations revealed a gastrointestinal melanoma confirmed by histopathology and immunohistochemistry, without satellite lymph node involvement and with no identifiable primary cutaneous or mucosal lesion.
Concomitantly, the patient developed multiple depigmented halos surrounding several pre-existing nevi, consistent with Sutton's phenomenon.
A complete dermatological and ophthalmological examination revealed no suspicious lesions except for three halo nevi displaying atypical clinical and dermoscopic features.
Skin biopsy of these lesions showed no atypical melanocytic proliferation.
Staging investigations including cerebral and thoraco-abdomino-pelvic CT scans as well as ultrasonography of lymph node areas showed no evidence of secondary metastatic localizations.
Based on these findings, the patient was classified as having stage IV melanoma, and immunotherapy with pembrolizumab was initiated.

Conclusion

Halo nevus reflects a cytotoxic cell-mediated immune response directed against melanocytes.
In adults, their occurrence represents a warning sign that may reveal melanoma. Indeed, Sutton nevi appearing in adulthood are associated with a 1% risk of developing primary cutaneous melanoma within one year following the diagnosis of Sutton. Furthermore, several reports have described regressing melanomas presenting clinically as Sutton nevi, particularly in elderly patients.
In cases of recently appearing Sutton nevi without a clear triggering factor, dermoscopic examination of halo nevi as well as a complete evaluation for melanoma should be performed. From a pathophysiological perspective, the association between halo nevus and melanoma may be explained by molecular mimicry, epitope spreading, or "bystander" activation.
In our patient, the halo nevus lesions appeared concomitantly with the discovery of gastrointestinal melanoma and should have represented an early warning sign prompting investigation for melanoma even before the onset of digestive symptoms.Eruptive halo phenomenon in adults should not be underestimated. It requires a complete dermatological examination and appropriate investigations to rule out associated melanoma.

EADV Congress 2026, VIENNA
30 SEPTEMBER - 03 OCTOBER 2026
POWERED BY M-ANAGE.COM

EA DV CONGRESS
VIENNA
30 SEP - 3 OCT 2026

Abstract N°: 2634

Cutaneous lymphoproliferative disorders after COVID-19 vaccination: signal or coincidence

Corrado Zengarini*[1, 2], Alberto Corrà[3], Tullio Brunetti[1, 2], Alessio Natale[1, 2], Michelangelo La Placa[1, 2], Alba Guglielmo[4], Bianca Maria Piraccini[5], Alessandro Pileri[1, 2], Martina Mussi[1, 2]

[1] Department of Medical and Surgical Sciences, University of Bologna, Bologna, Italy

[2] Dermatology Unit, IRCCS Azienda Ospedaliero-Universitaria di Bologna, Dermatology Unit, IRCCS Azienda Ospedaliero-Universitaria di Bologna, Bologna, Italy

[3] Dermatology Unit, Ospedale San Bortolo, Vicenza, Italy

[4] University of Ferrara, Ferrara, Italy

[5] Ambulatorio Piraccini, Bologna, Italy

Introduction

Primary cutaneous lymphoproliferative disorders (PCLPs) encompass a heterogeneous spectrum ranging from reactive conditions to true cutaneous lymphomas, predominantly of T-cell origin. Following the global rollout of SARS-CoV-2 vaccines, several cases of new-onset or relapsed cutaneous lymphomas (CLs) and lymphoproliferative disorders (LPDs) have been reported in temporal association with vaccination and, although rare, these observations have raised questions regarding potential immunological mechanism. Vaccine-induced immune activation may act as a trigger or unmask subclinical lymphoproliferative conditions, similarly to what has been described for other immune-mediated diseases.

Materials and Methods

A systematic review was conducted according to PRISMA guidelines. PubMed/MEDLINE, Scopus, and Web of Science databases were searched up to March 2024 using predefined keywords related to cutaneous lymphomas, lymphoproliferative disorders, and COVID-19 vaccination. Eligible studies included case reports and case series describing histologically confirmed CLs or LPDs occurring after SARS-CoV-2 vaccination. Data on demographics, clinical presentation, histopathology, vaccine type, latency to onset, treatment, and outcomes were extracted and analyzed.

Results

Fifteen studies comprising 35 cases met inclusion criteria: among these, 18 cases (51.4%) were classified as cutaneous lymphomas, while 17 (48.6%) were non-neoplastic lymphoproliferative disorders. The most frequent subtype was lymphomatoid papulosis (n=9), followed by Sézary syndrome (n=3) and mycosis fungoides (n=1). The remaining cases included a variety of CD30-positive and other rare entities. Among LPDs, cutaneous lymphoid hyperplasia, lymphomatoid reactions, and primary cutaneous CD4+ small/medium T-cell lymphoproliferative disorder were the most represented.

Most patients (80%) received the BNT162b2 (Pfizer-BioNTech) vaccine, reflecting global vaccination trends. In new-onset cases, latency ranged from 3 to 42 days, with a clustering within the first two weeks post-vaccination. Clinically, most cases followed an indolent course, with favorable outcomes and frequent spontaneous regression or response to standard therapies.

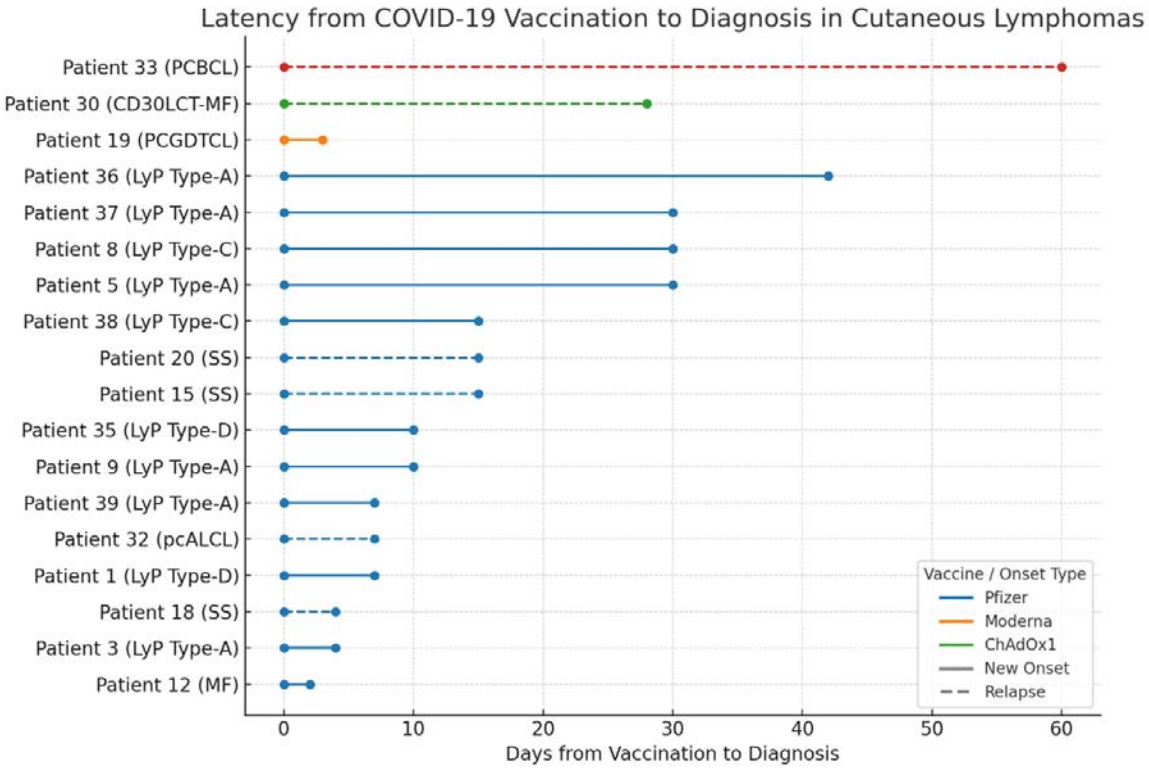

Latency from SARS-CoV-2 vaccination to diagnosis of cutaneous lymphomas. Each line represents the time interval (in days) between vaccine administration and clinical diagnosis for individual patients. Solid lines indicate new-onset cases, while dashed lines represent relapses of previously diagnosed disease. Colors correspond to vaccine type: blue (BNT162b2, Pfizer-BioNTech), orange (mRNA-1273, Moderna), and green (ChAdOx1 nCoV-19/AZD1222). Most cases cluster within the first 14 days following vaccination.

Conclusions

The predominance of indolent, CD30-positive lymphoproliferative disorders and the short latency observed in many cases may initially suggest the hypothesis of some kind of vaccine-induced immune activation acting as a triggering or unmasking factor in predisposed individuals. However these findings could be more consistent with a model of transient immune amplification rather than true lymphomagenesis.

Given the rarity, the lack of a clear connection and generally benign clinical course of these events, they do not alter the favorable risk–benefit profile of SARS-CoV-2 vaccination. Studies integrating clinical, molecular, and epidemiological may be needed to better clarify host susceptibility and underlying mechanisms.

EADV CONGRESS
VIENNA
30 SEP - 3 OCT 2026

Abstract N°: 2641

Successful Immunocryosurgery of New-Onset Eyelid Basal Cell Carcinoma in a Patient Treated With Cemiplimab for Squamous Cell Carcinoma

Joanna Zalewska-Gryszko[1], Piotr Janicki*[1], Iwona Czarnecka[1], Monika Słowińska[1], Anna Kozera[1], Nina Wiśniewska[1], Agnieszka Terlikowska-Brzósko[1], Karol Pniewski[1], Witold Owczarek[1]

[1] Dermatology Clinic, Military Institute of Medicine – National Research Institute, Warsaw, Poland

Introduction

Immunocryosurgery (ICS) is a minimally invasive combination treatment for non-melanoma skin cancer (NMSC) that integrates topical immune stimulation with local tumor destruction. Developed in 2004, it has been most extensively studied in basal cell carcinoma (BCC). ICS offers a tissue-sparing, outpatient alternative for patients who are poor surgical candidates or for whom surgery would be mutilating or technically complex. In the standard protocol, patients apply imiquimod 5% cream daily for 5 weeks, with a single cryosurgery session (liquid nitrogen, two freeze–thaw cycles of 10–20 s) performed around day 14 while imiquimod treatment is continued.

Case Presentation

We report the case of a 51-year-old man who developed new-onset nodular BCC of the lower left eyelid during treatment with cemiplimab for periocular and conjunctival squamous cell carcinoma (SCC). The patient had no history of chronic diseases or prior skin cancers and was not taking any regular medications. His family history was unremarkable. The only notable risk factor was active tobacco use. Between December 2024 and May 2026, he received 21 cycles of cemiplimab, with remission of the SCC confirmed radiologically by MRI. During one of the follow-up visits in June 2025 (after 6 cycles of immunotherapy), a new nodular lesion of the left lower eyelid was identified. Dermoscopic features were suggestive of BCC, and the diagnosis was confirmed histopathologically. ICS was initiated according to the protocol described by Gaitanis et al., resulting in complete clinical remission, which has been maintained during 11 months of follow-up. The decision to initiate ICS was made jointly with the patient after careful consideration of various therapeutic options, including potentially mutilating surgical excision.

Conclusion

This case is noteworthy because cemiplimab has demonstrated efficacy in the treatment of both SCC and BCC, yet a new BCC developed despite ongoing immunotherapy. Cemiplimab is a fully human IgG4 monoclonal antibody targeting the programmed death-1 (PD-1) receptor, blocking its interaction with PD-L1 and PD-L2 ligands, thereby enhancing cytotoxic T-cell–mediated antitumor responses. Initially approved for advanced SCC in patients ineligible for curative surgery or radiation, cemiplimab has also shown activity in BCC as a second-line treatment after hedgehog inhibitor failure or intolerance. Multiple phase II trials and real-world studies report objective response rates (ORR) of 42–51% in both locally advanced and metastatic SCC, compared with 31% in locally advanced BCC and 22–24% in metastatic BCC. This case underscores the heterogeneous responses of different NMSC subtypes to immune checkpoint inhibition and supports the need for individualized, multimodal treatment strategies.

Furthermore, this case highlights ICS as a simple, widely available, and cost-effective treatment option for BCC, particularly in anatomically and functionally challenging locations such as the eyelid, where surgical excision may

result in significant functional impairment, unsatisfactory cosmetic outcomes, and potential vision loss.

EADV CONGRESS
VIENNA
30 SEP - 3 OCT 2026

Abstract N°: 2646

Atrophic Dermatofibrosarcoma Protuberans: a rare and underrecognized variant

Laura Rodríguez Suárez*[1], Sofia Martinez-Guerrero[1], Karen Villa-Méndez[2], Diana Duarte-Navas[2]

[1] Fundación Universitaria Sanitas, Bogotá, Colombia

[2] Centros Médicos Colsanitas, Bogotá, Colombia

Introduction

Dermatofibrosarcoma protuberans (DFSP) is a rare locally aggressive mesenchymal tumor, representing approximately 1.8% of all soft tissue sarcomas. The atrophic variant is a rare subtype, accounting for only 1.7% of all DFSP cases. While classical DFSP usually presents as an indurated protuberant plaque or nodule, atrophic DFSP is characterized by a slow-growing, centrally depressed plaque. Due to its atypical clinical presentation and indolent nature, this entity represents a significant diagnostic challenge and is frequently misdiagnosed as morphea, anetoderma, or atrophic scar. Early identification is critical to minimize local aggression and high recurrence rates associated with delayed diagnosis.

Case Presentation

A 35 year-old male patient presented with a 5-year history of an asymptomatic 8mm erythematous-violaceous atrophic area, located in the left pectoral region. Palpation of the lesion identified a firm, mobile nodule within the atrophic area. Dermoscopic evaluation revealed a multicomponent pattern including a pigmented network on a pink background. A skin biopsy was performed, which reported an unencapsulated spindle cell proliferation arranged in a storiform pattern, involving both the dermis and hypodermis. The lesion was composed of cells with moderate cytoplasm and elongated ovoid nuclei, exhibiting mild pleomorphism and low mitotic activity. There is evidence of trapped residual skin adnexa and the characteristic “honeycomb” pattern of infiltration is evident in the subcutaneous adipose tissue. Immunohistochemistry revealed strong positivity for CD34 and negativity for Factor XIIIa, smooth muscle actin (SMA), CD68, and S100, confirming the diagnosis of DFSP, atrophic variant.

Conclusion

Atrophic DFSP is a rare clinical variant that is frequently misidentified due to its non-protuberant appearance While dermoscopy serves as a valuable, non-invasive supportive tool for identifying characteristic patterns such as pigmented networks and vascular structures, histopathology remains the gold standard for confirmation. This case emphasizes the value of clinic–dermoscopic–histopathologic correlation for accurate diagnosis and highlights the need to consider atrophic DFSP in persistent atrophic plaques with subtle dermoscopic vascular–pigment patterns, prompting early biopsy despite a benign clinical appearance.

EADV CONGRESS
VIENNA
30 SEP - 3 OCT 2026

Abstract N°: 2659

Squamous Cell Carcinoma Arising in Long-Standing Hidradenitis Suppurativa: A Case Report

Hajar Haj Khlifa*[1], El Fetoiki Fatimazahra[1], Soumiya Chiheb[1]

[1] CHU Ibn Rochd, Casablanca, Morocco

Introduction

Hidradenitis suppurativa (HS), also known as Verneuil's disease, is a chronic inflammatory disorder of the folliculopilosebaceous unit characterized by recurrent nodules, abscesses, sinus tract formation, and scarring, mainly affecting intertriginous areas. Malignant transformation into squamous cell carcinoma (SCC) is a rare but severe complication, typically occurring in long-standing and severe disease. SCC arising in HS is often aggressive and associated with delayed diagnosis and poor prognosis. We report a case of SCC developing in chronic gluteal hidradenitis suppurativa

Case Presentation

A 60-year-old man presented with an ulcerative and proliferative lesion of the right buttock evolving for three years in the context of hidradenitis suppurativa diagnosed seven years earlier. His medical history included heavy smoking (47 pack-years), chronic cannabis uses for 43 years, alcohol dependence with abstinence for seven years, and treated pulmonary tuberculosis five years prior. The clinical presentation was associated with weight loss without fever.

Physical examination revealed a conscious and hemodynamically stable patient with Fitzpatrick skin phototype III–IV. Dermatological examination of the right gluteal region showed multiple ulcerative exophytic nodular lesions covered with fibrinous deposits, including one fistulized lesion with purulent discharge. The lesions had irregular elevated borders resting on an indurated base, with focal pigmentation and peripheral erythema, and were locally warm and painful on palpation, involving most of the right buttock. A polylobulated erythematous-violaceous dermoepidermal nodule overlying an indurated subcutaneous plaque measuring approximately 5 cm was also noted, presence of open and closed comedones on the face, trunk, and retroauricular area.

Multiple bilateral inguinal lymphadenopathies of variable sizes were detected. Skin biopsy revealed histological features consistent with squamous cell carcinoma. Ultrasound showed necrotic right inguinal lymph node conglomerates. Magnetic resonance imaging demonstrated an ulcerative tumoral process involving the right gluteal soft tissues with ipsilateral inguinal lymphadenopathies. Proctological examination was normal. Thoraco-abdomino-pelvic computed tomography revealed locoregional tumor extension with necrotic ipsilateral inguinal lymphadenopathies and additional subcentimetric iliac lymph nodes. Bilateral pulmonary micronodules were considered likely sequellar.

Following multidisciplinary tumor board discussion, neoadjuvant chemotherapy based on 5-fluorouracil and cisplatin was initiated, with surgical management planned subsequently

Conclusion

Malignant transformation of hidradenitis suppurativa into squamous cell carcinoma is uncommon but represents a life-threatening complication, particularly in long-standing gluteal disease. Chronic inflammation and delayed diagnosis contribute to aggressive tumor behavior and regional metastatic spread. This case highlights the importance of close clinical monitoring of chronic HS lesions and early histopathological assessment of suspicious or non-healing lesions to ensure timely diagnosis and appropriate multidisciplinary management.

EADV Congress 2026, VIENNA
30 SEPTEMBER - 03 OCTOBER 2026
POWERED BY M-ANAGE.COM

EADV CONGRESS
VIENNA
30 SEP - 3 OCT 2026

Abstract N°: 2676

Melanoma Risk in Multiple Sclerosis and the Impact of Disease-Modifying Therapy

Robert Adler*[1], EVE LOWENSTEIN[1], Marc Cohen[1]

[1] SUNY Downstate College of Medicine, Brooklyn, United States

Introduction

Multiple sclerosis (MS) is a chronic immune-mediated disease frequently treated with disease-modifying therapies (DMTs) that alter immune surveillance. Given the role of immune regulation in melanoma pathogenesis, concerns persist regarding melanoma risk in MS and with DMT exposure. We sought to evaluate melanoma incidence in patients with MS and assess the impact of DMT use on melanoma risk in a large real-world population.

Materials and Methods

Two retrospective cohort analyses were conducted using the TriNetX US Collaborative Network. MS patients were identified using ICD-10 code G35 with ≥2 diagnoses separated by one year. In the primary analysis, MS patients were compared with neurologic controls with ≥2 procedural encounters without MS. In the secondary analysis, MS patients treated with ≥2 prescriptions for DMTs were compared with untreated MS patients. DMTs included monoclonal antibodies, sphingosine-1-phosphate modulators, and other immunomodulatory agents. Propensity score matching (1:1) balanced demographics, comorbidities, medications, procedures, and laboratory variables. The primary outcome was melanoma (ICD-10 C43/D03), assessed from 1 to 10 years after index. Kaplan-Meier and Cox proportional hazards models were used.

Results

After matching, 134,428 patients remained in each cohort in the primary analysis. Melanoma occurred in 425 MS patients and 348 controls, with no significant difference in risk (HR 0.93; 95% CI 0.81-1.07; p=0.323). In the secondary analysis (52,687 per group), melanoma occurred in 213 treated and 122 untreated patients, with no significant difference (HR 1.20; 95% CI 0.96-1.50; p=0.110).

Conclusions

MS and DMT use were not associated with increased melanoma risk in this large real-world cohort. These findings support the overall safety of DMTs regarding melanoma risk, though continued surveillance is warranted.

EA DV CONGRESS
VIENNA
30 SEP - 3 OCT 2026

Abstract N°: 2677

PCTCL-NOS: A CRUCIAL DIAGNOSIS FOR AGGRESSIVE AND ATYPICAL CUTANEOUS LYMPHOMAS

Soumia Reziga*[1], mahmoudi naziha[1], khelil amel[1]

[1] University Hospital Centre of Oran, Oran, Algeria

Introduction

Primary cutaneous T-cell lymphoma, not otherwise specified (PCTCL-NOS), is a rare entity representing only 2% of cutaneous T-cell lymphomas. Recently consolidated as a distinct entity in the 5th edition of the WHO classification, it is characterized by extreme aggressiveness. The objective of this work is to illustrate, through a clinical case, the complexities of the diagnosis of exclusion and the therapeutic challenges of this pathology with a dismal prognosis.

Case Presentation

Materials and Methods

We report the observation of a 36-year-old patient who presented with a polymorphic and pruritic eruption evolving over 3 months. The diagnostic workup was based on a comprehensive clinical examination, a skin biopsy with morphological study, and a broad immunohistochemical panel (CD3, CD4, CD8, CD30, BCL2, BCL6, CD79, Ki67). Systemic staging was performed using computed tomography (CT-TAP), lymph node biopsies, and bone marrow biopsy (BMB).

Results

Clinical examination revealed a diffuse presentation involving more than 20 lesions, including macules, infiltrated plaques, and disseminated ulcerated nodules. Histopathological analysis showed a dense infiltrate of large pleomorphic cells, limited to the basal layer of the epidermis and diffuse within the dermis. Immunohistochemical study demonstrated a **CD3+, CD4+, and BCL2+** phenotype, with weak **CD8 positivity**. The strict negativity for **CD30, BCL6, and CD79** markers allowed for the exclusion of CD30+ lymphoproliferative disorders and B-cell lymphomas. The **Ki67** proliferation index was particularly high(65%), confirming strong tumor activity.

Staging confirmed cervical and inguinal lymph node involvement (histologically proven), without bone marrow infiltration (negative BMB). The case was staged as T3bN2M0 according to the WHO-ISCL classification. As no therapeutic consensus has yet been established, polychemotherapy remains the most common treatment for this type of lymphoma based on reported cases. The patient was referred to hematology to initiate the CHOP polychemotherapy regimen.

Discussion

PCTCL-NOS remains a diagnosis of exclusion. It can only be established after ruling out better-defined entities, notably large-cell transformed mycosis fungoides or aggressive cytotoxic T-cell lymphoma. The variability of clinical presentations reported in the literature (single or multifocal lesions, ulcerated or not) makes clinicopathological correlation indispensable. Biologically, aberrant immunophenotyping and the loss of certain T-cell markers are characteristic. The prognosis is extremely guarded, with a 5-year survival rate often below 20%, particularly in disseminated forms such as that of our patient. In the absence of an international therapeutic consensus, polychemotherapy (CHOP regimen) remains the standard approach, although stem cell transplantation is sometimes considered. As a recently classified distinct entity, this pathology is the subject of ongoing studies and case reports aiming to better define its characteristics.

Conclusion

PCTCL-NOS is a rare and formidable entity, marked by a poor prognosis, especially in multifocal forms. This pathology warrants better recognition and must be imperatively considered in any aggressive cutaneous presentation that does not meet the criteria for classic categories of cutaneous lymphomas.

EA DV CONGRESS
VIENNA
30 SEP - 3 OCT 2026

Abstract N°: 2687

Primary Cutaneous Lymphomas: A 30-Case Hospital-Based Study from a Maghrebian Center

Maroua Berdjane*[1], mira chikhaoui[1], Baya Moussaoui[1], Houria Sahel[1]

[1] Dermatology Department, Bab El Oued University Hospital, Algiers, Algeria

Introduction
Primary cutaneous lymphomas (PCLs) are a heterogeneous and rare group of non-Hodgkin lymphomas. Although their incidence is lowestimated at 0.96 per 100,000 inhabitants in France .heir often indolent clinical course results in a relatively high prevalence due to prolonged follow-up requirements. The aim of our study was to establish the epidemiological and clinical profile of patients diagnosed with PCL and hospitalized in our department.

Materials and Methods
We conducted a prospective study between 2009 and 2025 including patients hospitalized for primary cutaneous lymphoma. Diagnosis was established based on clinical and histopathological findings. Data were collected using a standardized questionnaire

Results
Thirty patients with primary cutaneous lymphomas were included (23 men, 7 women; mean age 53.5 years). The mean diagnostic delay was 49.4 months. T-cell lymphomas were predominant (86.7%) compared to B-cell lymphomas (13.3%). Clinically, infiltrated plaques were the most frequent presentation (53.3%), followed by ulcerations (16.7%) and tumors (10%). Pruritus was reported in 43.3% of cases. The most common sites were proximal limbs (63.3%), trunk (46.7%), and head and neck (30%).Histologically, mycosis fungoides was the main subtype (80%), including folliculotropic and granulomatous variants. B-cell lymphomas accounted for 13.3% of cases. The most frequent comorbidities were cardiovascular diseases (43.3%), followed by non-dermatological malignancies (36.7%).Outcomes showed partial response in 33.3% and complete response in 20%. Disease progression occurred in 10%, transformation in 6.7%, and death in 3.3%. Loss to follow-up was noted in 16.7%.Overall, clinical and histological features are similar to European series, while diagnostic delay and follow-up characteristics are closer to Maghrebian data.

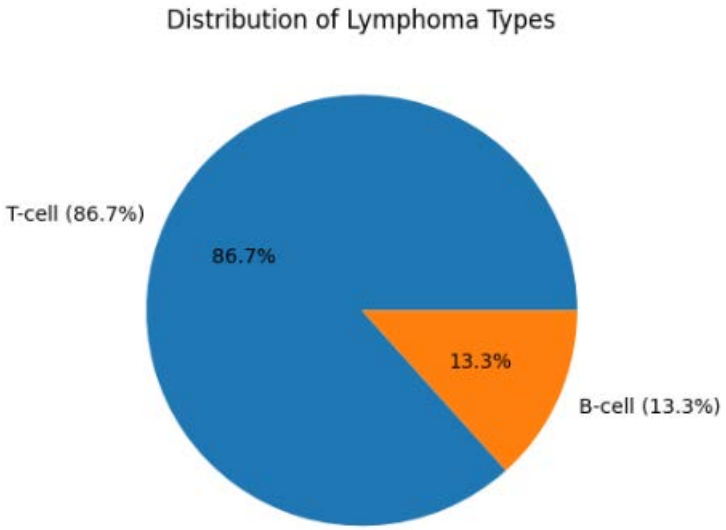

T-cell lymphomas largely predominated (86.7%) compared to B-cell lymphomas (13.3%)

Conclusions

Our findings highlight an epidemiological and clinical profile of primary cutaneous lymphomas that shares similarities with European series in terms of age and therapeutic response, yet remains marked by specific Maghrebian features, including male predominance, diagnostic delay, and follow-up challenges.These results emphasize the need for earlier diagnosis and improved patient monitoring to enhance prognosis and quality of life in our setting.

EADV CONGRESS
VIENNA
30 SEP - 3 OCT 2026

Abstract N°: 2688

A Rare Variant of Mycosis Fungoides presenting as Porokeratosis-like lesions in a Chinese man: A Case Report and Review of Literature

Xin Yi Lee*[1], Cheryl Ma[2], Kong Bing Tan[2], Lester Juay[2], Adeline Mei Yen Yong[2]

[1] Yong Loo Lin School of Medicine, Singapore, Singapore
[2] National University Hospital, Singapore, Singapore

Introduction

Mycosis Fungoides (MF), the most common subtype of cutaneous T cell lymphoma (CTCL), is a recognised clinical masquerader. It can mimic a wide variety of dermatoses, rendering it a diagnostically challenging condition. Porokeratosis-like MF is extremely rare, with only five cases documented in literature to date. We describe a rare case of porokeratosis-like MF in a Chinese patient. To our knowledge, such a presentation has not previously been documented in Asian patients.

Case Presentation

A 64-year-old Chinese male with no significant medical history presented with persistent annular brown scaly papules over the abdomen and thighs. These sharply demarcated papules had atrophic centres with elevated borders, which were clinically suggestive of porokeratosis. Punch biopsy performed revealed atypical band-like lymphoid infiltrate in the superficial dermis with epidermotropism. Immunohistochemical staining revealed a pattern consistent with MF (CD2+, CD3+, CD5+, CD30- with CD7 loss and dual CD4 and CD8 positivity). The patient was diagnosed with MF and subsequently treated with topical steroids. In this patient, the absence of a cornoid lamella on both dermoscopy and histopathology, together with distribution involving sun-protected skin, were discriminating features from true porokeratosis.

Conclusion

We describe a rare case of mycosis fungoides resembling porokeratosis, in which the absence of cornoid lamella and atypical distribution were important diagnostic clues. This case expands the limited literature surrounding this diagnostically challenging presentation of CTCL and highlights its potential to mimic porokeratosis, even in Asian patients. It also underscores the importance of a lowered threshold to biopsy in patients with chronic, treatment-resistant annular scaly eruptions in atypical distributions, even when the clinical picture favours porokeratosis.

EADV CONGRESS
VIENNA
30 SEP - 3 OCT 2026

Abstract N°: 2689

Surgical excision versus topical 5% 5-fluorouracil and photodynamic therapy in the treatment of Bowen's disease: long-term results of a multicenter randomized controlled trial

Myrthe Moermans*[1, 2], Shima Ahmady[1, 2], Patty Nelemans[3], Aimee Arits[4], Janneke Kessels[5], J.P.A. van Pelt[6], Nicole Kelleners-Smeets[1, 2], Klara Mosterd[1, 2]

[1] Department of Dermatology, Maastricht University Medical Center+, Maastricht, Netherlands
[2] Grow Research Institute for Oncology and Reproduction, Maastricht University, Maastricht, Netherlands
[3] Department of Epidemiology, Maastricht University, Maastricht, Netherlands
[4] Department of Dermatology, Catharina Hospital, Eindhoven, Netherlands
[5] Department of Dermatology, Zuyderland Medical Center, Heerlen, Netherlands
[6] Department of Dermatology, VieCuri Medical Center, Venlo, Netherlands

Introduction
Evidence on the long-term efficacy with head-to-head comparison of different treatments for Bowen's disease (BD) is lacking. The aim of this study is to compare the long-term efficacy of 5-fluorouracil and methylaminolevulinate photodynamic therapy (MAL-PDT) versus surgical excision (SE) in BD.

Materials and Methods
In this multicenter, non-inferiority randomized controlled trial, 250 patients with BD were invited for long-term follow-up, 3-5 years post-treatment. Patients had been randomly assigned to 5FU, MAL-PDT, or SE in a 1:1:1-ratio. The primary outcome was the cumulative probability of tumor-free survival 4 years post-treatment with treatment failures confirmed histopathologically. A secondary endpoint was the risk of cutaneous squamous cell carcinoma (cSCC).

Results
During the first year of follow-up, treatment failure was observed in 27 patients. During long-term follow-up, only one additional patient developed a recurrence, 5 years after MAL-PDT. The 4-year cumulative probability of tumor-free survival was 97.5% for SE (95% confidence interval (CI) 90.4-99.4), 86.2% for 5FU (95% CI 76.4-92.1), and 82.7% for MAL-PDT (95% CI 72.6-89.4). No patient developed a cSCC in the treated area.

Conclusions
During long-term follow-up, the additional risk of recurrence of BD after 5FU and SE, and the risk of developing a cSCC from a treated BD were negligible. Treatment with 5FU remains non-inferior to SE, whereas non-inferiority of MAL-PDT could not be concluded.

EA DV CONGRESS
VIENNA
30 SEP - 3 OCT 2026

Abstract N°: 2701

DESMOPLASTIC MELANOMA ON A GIANT AND SEGMENTAL NEVUS SPILUS

Camila Anderlini*[1], Eliana Gisel Astronave[1], Sofía Zanitti Manzone[1], Marco Mazzotta[1], Valente Enrique[1]

[1] Hospital Privado Universitario de Cordoba, Cordoba, Argentina

Introduction

Desmoplastic melanoma is a rare melanoma subtype, accounting for approximately 0.4–4% of all melanomas, with biological behavior distinct from conventional melanoma. Clinically, it often presents as a non-pigmented indurated papule or plaque with poorly defined borders, frequently mimicking scar tissue, which makes diagnosis challenging and may delay treatment.

Melanoma arising within a nevus spilus is exceptionally uncommon, with fewer than 45 cases reported in the literature.

We present a rare case of pure desmoplastic melanoma developing within a segmental nevus spilus in a young patient.

Case Presentation

A 38-year-old male patient, without personal or family history of skin cancer, consulted our Dermatology service for androgenetic alopecia.

During the examination, a pigmented macular lesion that cointaned darker papules on the inside was observed in in the left dorsolumbar region that extended to the left homolateral abdomen. Clinically, it was consistent with a segmental nevus spilus (48cmx 20cm), which presented an erythematous, indurated, palpation-adherent tumor on top, currently asymptomatic and approximately 7 years old. Dermoscopy revealed no melanocytic lesion criteria, showing a whitish color throughout its extension and a pseudoreticular pattern on the periphery

In the medical history, the patient mentioned the history of an incisional punch biopsy performed outside our hospital on the nevus spilus, which he did not bring during the first consult, with the subsequent appearance of the tumor lesion in the area. This lesion was slightly itchy, presenting slow growth over time and initially interpreted as a keloid scar in the other clinic and consequently treated with intralesional corticosteroids without clinical improvement.

We decided to perform a lozenge excisional biopsy of the tumor, considering dermatofibrosarcoma protuberans, atypical dermatofibroma, and amelanotic melanoma as possible differential diagnoses.

Histopathology revealed a proliferation of fusiform neoplastic cells without pigment, with vesicular macronuclei and prominent nucleoli. These cells were scattered and surrounded by thick collagen bundles, occupying the reticular dermis. Immunohistochemical staining was slightly positive for Melan-A, strongly positive for SOX-10, and S-100, and negative for CD34 and CD68, with a Ki-67 of 5%. This established the diagnosis of desmoplastic melanoma, pure variant, without ulceration, perineural invasion, or lymphovascular invasion, with a Breslow thickness of 8.5 mm and Clark level IV, with 1mm2 mitosis, and mild TIL. Laboratory tests and imaging studies for patient staging were requested that showed normal results.

Later, sentinel lymph node biopsy was performed, in which five positive lymph nodes were found, three on the left and two on the right armpit, which were removed and examined, revealing tumor invasion, classifying the melanoma as Stage IIIC. Following this, the decision was made to initiate immunotherapy treatment with nivolumab, with a good result and follow up.



Erythematous, indurated, palpation-adherent tumor on top of the nevus spillus.

Conclusion

This case highlights the importance of a thorough full-body skin examination.

Although the malignant transformation potential of nevus spilus is low, periodic clinical and digital dermoscopic follow-up may be advisable, particularly in large or segmental lesions. An increased risk seems to exist when the nevus spillus is congenital or acquired in infancy, of macular type, and larger than 4 cm (especially giant and zosteriform variants). Once a melanoma develops, it has a similar prognosis and management as compared with other melanomas.

On top, desmoplastic melanoma remains a major clinical and histopathological diagnostic challenge due to its nonspecific presentation and scar-like appearance.

Early recognition is essential given its locally aggressive behavior and potential for advanced disease.

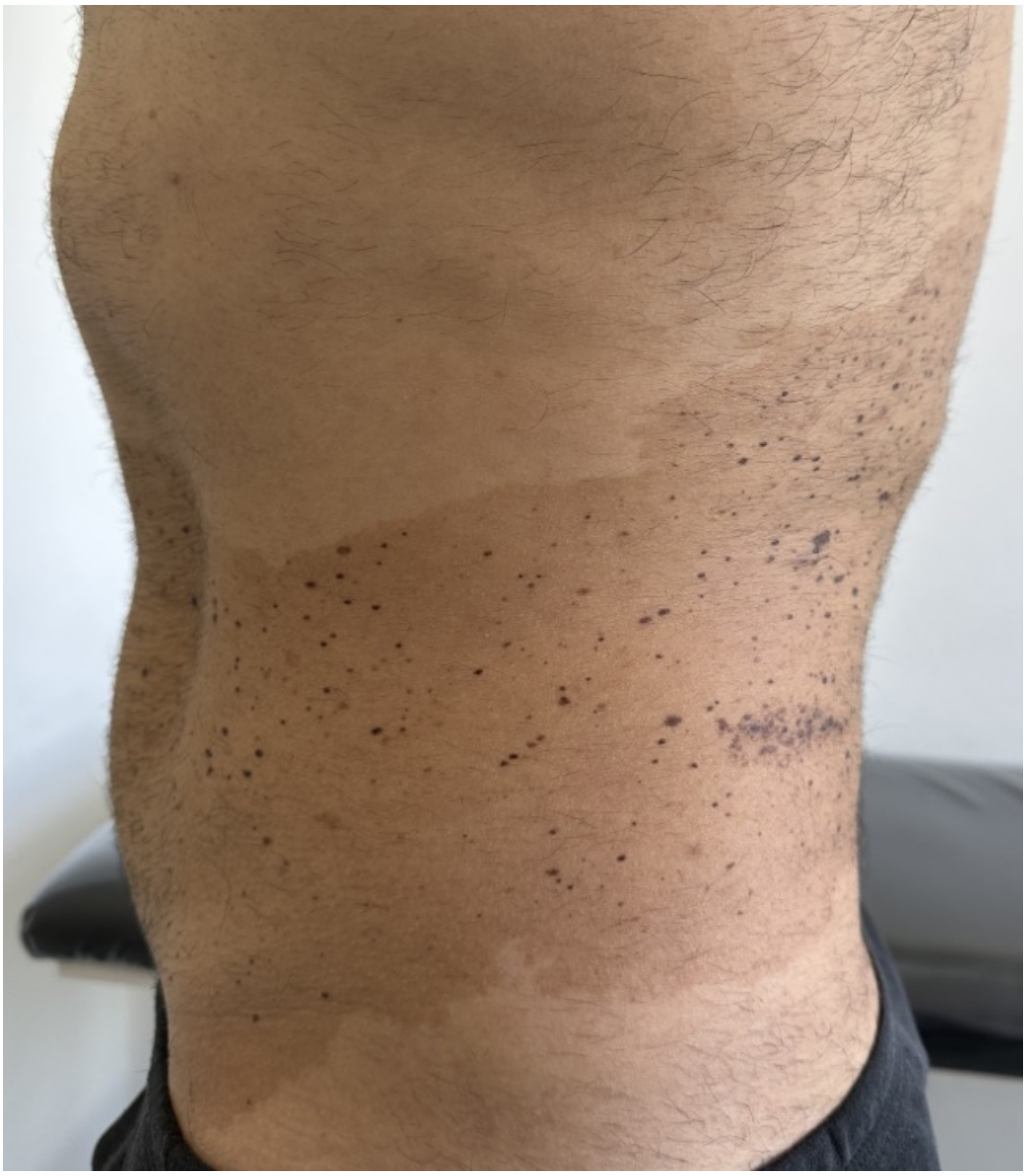

Segmental nevus spilus (48cm long x 20cm high).

EA DV CONGRESS
VIENNA
30 SEP - 3 OCT 2026

Abstract N°: 2709

Micrographic Surgery of High-Risk Cutaneous Squamous Cell Carcinoma Using the "Three-Dimensional Histology–Muffin Technique" and Reconstruction with an O to H Flap

Muhammed Ali Mergen[1], Ersin Çiftçi[1], Peyker Temiz[2], Tubanur Cetinarslan[1], Aylin Türel Ermertcan*[1], Bengu Gerceker Turk[3]

[1] Manisa Celal Bayar University, Department of Dermatology and Venereology, Manisa, Türkiye
[2] Manisa Celal Bayar University, Department of Pathology, Manisa, Türkiye
[3] Private practice, İzmir, Türkiye

Introduction

Cutaneous squamous cell carcinoma (cSCC), particularly when located in the head and neck region, is considered a high-risk malignant tumor due to its increased risk of recurrence and metastasis. Complete evaluation of surgical margins constitutes the most critical step in treatment. Muffin Technique Micrographic Surgery (MTMS) is a highly practical paraffin block–based method that enables evaluation of all lateral and deep surgical margins within a single cassette.

Case Presentation

A 78-year-old female patient presented with a progressively enlarging mass on the forehead that had been growing for approximately one year. Dermatological examination revealed a 2×2 cm nodular lesion with a central hemorrhagic crust located in the frontal region. Dermoscopic examination demonstrated a central keratin plug, hemorrhagic foci, white structureless areas, and a polymorphous vascular pattern. The lesion was clinically considered suggestive of keratoacanthoma or cSCC and was evaluated as high-risk; therefore, mapping and excision using MTMS, a three-dimensional histology method, was planned.

In the first stage, tumor borders were marked dermoscopically and the tumor tissue was excised. In the second stage, the tumor-free surgical bed was excised. Deep incisions were made at the 12 and 6 o'clock positions of the block-excised tumor bed, while the 3 and 9 o'clock positions were identified by additional incisions. The 12 and 3 o'clock positions were marked with correction fluid and the specimen was placed into a cassette. The specimen was then sent to the pathology laboratory for histopathological evaluation. While awaiting the pathology results, the surgical defect was managed with dressings. Histopathological examination revealed moderately differentiated cSCC. Complete negativity of all surgical margins was confirmed. Following confirmation of tumor-free margins, the defect was reconstructed the next day using an O to H flap. No recurrence was observed during the three-month follow-up period.

Conclusion

Compared with conventional histopathological examination following standard excision methods, in which only a limited portion of the surgical margins can be evaluated, MTMS enables comprehensive assessment of all lateral and deep surgical margins in a holistic manner. The two-stage excision approach combines tissue-sparing surgery with complete surgical margin assessment, while the delayed reconstruction strategy allows safe repair after confirmation of negative margins. With these advantages, MTMS represents a rational surgical approach that optimizes both oncological safety and cosmetic outcomes, particularly in high-risk cSCCs located in the head and

neck region. In centers with limited access to Mohs Micrographic Surgery, MTMS may serve as a feasible, cost-effective, and efficient alternative, as it does not require specialized technicians or equipment.

EADV CONGRESS
VIENNA
30 SEP - 3 OCT 2026

Abstract N°: 2720

Primary Epithelioid Angiosarcoma of the Scalp: Diagnostic and Therapeutic Challenges

Hiba Et-Taghy*[1], ikram lahmouch[1], Zaineb Kettani[1], Narjess Errachdy[1], Najoua Ammar[1], syrine Hamada[1], Meriem Meziane[1], Nadia Ismaili[1], Laila Benzekri[1]

[1] Department of Dermatology, CHU Ibn Sina, Rabat, Morocco

Introduction

Angiosarcoma is a rare endothelial malignancy accounting for approximately 1% of all soft tissue sarcomas and up to 2% of all sarcomas. Cutaneous angiosarcoma most often affects elderly patients and commonly involves the scalp and face, where it may present as a bruise-like, violaceous, infiltrated plaque or as a rapidly enlarging hemorrhagic tumor. Because of its nonspecific clinical appearance and aggressive biology, early diagnosis is essential to improve outcome.

Case Presentation

An 85-year-old woman presented with a painful, progressively enlarging scalp tumor of three months' duration. The lesion initially appeared as pinkish raised plaques over the left temporal region and extended to the occipital scalp, evolving into a purplish, indurated, hypertrophic, and easily bleeding plaque with well-defined margins, measuring 15 × 13 cm (Fig1). No lymphadenopathy or systemic symptoms such as fever, weight loss, abdominal pain, or other masses were noted. Dermoscopic examination showed an erythematous background with red to bluish lacunae well delimited by whitish septa, hemorrhagic areas, and vascular structures arranged as dots and linear-tortuous vessels. Histopathology revealed a dermal malignant epithelioid proliferation with marked cytonuclear atypia and focal tumor necrosis, without vascular emboli or perineural invasion. Immunohistochemistry was positive for ERG and CD31, confirming epithelioid angiosarcoma. Brain MRI demonstrated soft tissue swelling over the parietal and temporal regions without intracranial extension. Thoraco-abdomino-pelvic CT scan showed no secondary lesions. Laboratory testing revealed inflammatory syndrome and mild anemia, while coagulation studies were unremarkable. Given the patient's poor general condition, severe aortic stenosis, and extensive scalp involvement, a multidisciplinary discussion favored multimodal treatment with radiotherapy and systemic chemotherapy rather than upfront radical excision. Despite management, the patient died within one year of diagnosis, underscoring the aggressive course and poor prognosis of scalp angiosarcoma.



Figure 1 : Clinical presentation of the scalp angiosarcoma. An extensive 15 × 13 cm purplish, indurated, and hypertrophic plaque with well-defined margins and focal hemorrhagic crusting, prominently involving the occipital and left temporal scalp.

Conclusion

Primary cutaneous epithelioid angiosarcoma of the scalp is an aggressive malignancy with a high risk of early local recurrence and distant metastasis. Its diagnosis relies on a high index of suspicion, especially in elderly patients with a rapidly progressive violaceous scalp lesion. Early histological confirmation and prompt multidisciplinary management are crucial to optimize outcomes.

EA DV CONGRESS
VIENNA
30 SEP - 3 OCT 2026

Abstract N°: 2730

Novel Pathogenic Germline BRIP1 Variant Associated with Atypical Non-Photoexposed Cutaneous Squamous Cell Carcinoma and Metachronous Rectal Adenocarcinoma.

Stefany Velasco*[1], Laura Umaña[2], Manuela Rojas[3], Ligia Mendez[4]

[1] Universidad del Quindío, Armenia, Colombia

[2] Universidad Militar Nueva Granada, Hospital Militar Central, Bogotá, Colombia

[3] Universidad Nacional de Colombia, Bogotá, Colombia

[4] Hospital Militar Central, Bogotá, Colombia

Introduction

Cutaneous squamous cell carcinoma (cSCC) typically arises from ultraviolet (UV) radiation-induced mutagenesis. Its development in non-photoexposed sites suggests alternative etiologies(1).The *BRIP1* gene (BRCA1 Interacting Protein C-terminal helicase 1) participates in DNA double-strand break repair through homologous recombination. While germline loss-of-function variants in *BRIP1* are well-documented risk factors for breast and ovarian malignancies(2), their implications in cutaneous oncogenesis remain poorly characterized. We present the case of a 47-year-old male carrying a novel pathogenic germline variant in *BRIP1* (c.674dup) who presented with cSCC on the dorsal aspect of the toe alongside a metachronous rectal adenocarcinoma. This case represents the first documentation of this syndromic phenotype in Latin America.

Case Presentation

A 47-year-old male presented with a 10-month history of a recalcitrant erythematous plaque (1.5×1.5 cm) on the dorsal aspect of the second digit of the right foot. Incisional biopsy revealed a well-differentiated cSCC. In February 2020, wide local excision with 6-mm safety margins and total skin graft reconstruction was performed. Histopathology confirmed an infiltrating, well-differentiated, large-cell cSCC (1.7 cm diameter, 2 mm Breslow thickness, reticular dermis invasion) with negative margins.

Concurrently, evaluation for occasional hematochezia via colonoscopy revealed a 4 cm exophytic mass in the mid-rectum. Biopsy confirmed a moderately differentiated infiltrating rectal adenocarcinoma (staged mrT2 N1 M0, Stage IIIA). The patient completed total neoadjuvant therapy (TNT) consisting of pelvic chemoradiotherapy (5040 cGy) followed by six cycles of CAPOX. He achieved a clinical complete response (mrTRG1) and entered a strict "Watch and Wait" surveillance protocol, remaining in complete oncological remission at week 247 of follow-up (February 2025).

Given the atypical, non-photoexposed cSCC presentation, the metachronous colorectal malignancy, and a significant paternal family history of gastrointestinal cancers (table 1), multi-gene germline panel testing was performed in January 2021. The analysis identified a novel, heterozygous pathogenic germline variant in the *BRIP1* gene: c.674dup (p.Asn225Lysfs∗10, transcript NM_032043.2). This frameshift mutation induces a premature stop codon, disrupting the helicase C-terminal domain and resulting in a non-functional protein.

Family Member	Cancer / Clinical Diagnosis	Age at Diagnosis
Patient	Colorectal, cSCC	47
Father	Gastric, Prostate	76
Paternal Grandmother*	Gastric, skin cancer	80
Paternal Uncle 1*	Gastric	35
Paternal Aunt 1*	Gastric	30
Paternal Aunt 2*	Gastric	50
Paternal Aunt 3*	Gastric	70
Maternal Aunt 1	Breast, Invasive	40
Maternal Aunt 2*	Gastric	60

Deceased due to cancer*

Table 1. Family and personal cancer history.

Conclusion

The presentation of an aggressive, infiltrating cSCC in a non-photoexposed site strongly implicates an alternative mechanism of genomic instability driven by germline DNA damage response deficiencies. *BRIP1* encodes a DEAH-box helicase that interacts with BRCA1, playing a pivotal role in double-strand break repair.(3) Emerging oncological data support a molecular link between *BRIP1* dysfunction and squamous cell carcinoma lineages; genetic variations in *BRIP1* microRNA-binding sites are associated with cSCC susceptibility, and loss of heterozygosity in *BRIP1* has been documented in squamous cell carcinoma of the head and neck (SCCHN)(4).

The identified germline variant (c.674dup) disrupts baseline DNA repair within keratinocytes, rendering them susceptible to malignant transformation independent of photochemical triggers. The syndromic nature of this case is highlighted by the metachronous rectal adenocarcinoma. To date, only two cases of germline *BRIP1*-associated colorectal cancer have been documented typically presenting a distinct molecular profile (*KRAS/NRAS/BRAF* wild-type, microsatellite stable, with somatic *TP53* and *APC* co-mutations)(5). In conclusion, this case suggests germline *BRIP1* variants drive non-UV cSCC within a metachronous rectal adenocarcinoma phenotype. Significant paternal cancer clustering underscores a hereditary component, necessitating targeted cascade genetic testing for at-risk family members.

EA DV CONGRESS
VIENNA
30 SEP - 3 OCT 2026

Abstract N°: 2734

LATE CUTANEOUS METASTASIS OF BILATERAL BREAST CANCER AFTER PROLONGED REMISSION

Fatima Zahra Sassine*[1], Chourouq Mustapha Eid[1], Kenza Benothmane[1], Yasmine Zekraoui[1], Sandra Aloui[2]

[1] Ibn Sina University Hospital, Dermatology Derpartment, Rabat, Morocco

[2] Hopital Henri Duffaut, Dermatology Department, Avignon, France

Introduction

Cutaneous metastases (CMs) account for 2% of all skin malignancies, and nearly 70% of CMs in women originate from breast cancer. They occur in 0.6% to 10.4% of patients with solid tumors and typically appear 2 to 3 years after the initial diagnosis, although late recurrences are well documented. CMs may be the first sign of recurrent disease, with 75% of patients also harboring visceral metastases at the time of diagnosis. Clinically, they most commonly present as firm, painless, erythematous nodules on the anterior chest wall. Dermoscopy has emerged as a valuable non-invasive tool, revealing characteristic vascular patterns, particularly serpentine vessels in up to 88% of non-pigmented cutaneous metastases. Prompt recognition is critical, as CMs carry significant prognostic implications, with a median overall survival of approximately 22 months.

Case Presentation

A 45-year-old woman with a 12-year history of breast carcinoma, initially left-sided then bilateral, with two prior episodes of recurrence, and in complete clinical remission for 4 years, presented with a recently appeared erythematous nodule on the right breast.

On clinical examination, the lesion was a firm, well-circumscribed, erythematous nodule. Dermoscopic evaluation revealed an erythematous background traversed by multiple telangiectatic and linear irregular vessels, consistent with a polymorphous atypical vascular pattern. This pattern is recognized as the most common dermoscopic finding in non-pigmented cutaneous metastases, with linear irregular (serpentine) vessels being the predominant subtype (77% of cases), frequently associated with arborizing vessels (53%). Breast cancer metastases specifically may also display blue (41.5%) and red (34.3%) colors with irregular vessels on dermoscopy.

Given the significant oncologic history and the suspicious dermoscopic features, an urgent skin biopsy was performed. Histopathological examination confirmed a cutaneous metastasis of breast carcinoma.

A comprehensive restaging workup was initiated, and the case was referred to a multidisciplinary tumor board for therapeutic decision-making.

Conclusion

This case highlights several key clinical messages. First, cutaneous metastases can occur years after apparent complete remission, underscoring the need for prolonged clinical surveillance in

breast cancer patients. Second, dermoscopy is a reliable non-invasive diagnostic aid: the presence of polymorphous vascular structures, particularly linear irregular vessels, within a cutaneous nodule in a patient with a known cancer history should raise immediate suspicion for cutaneous metastasis. Third, any suspicious skin lesion in a patient with a history of breast cancer warrants prompt biopsy, as early detection of CMs may influence staging, treatment strategy, and ultimately patient outcomes.

EADV CONGRESS
VIENNA
30 SEP - 3 OCT 2026

Abstract N°: 2735

Primary Cutaneous Follicle Center Lymphoma Initially Mimicking Marginal Zone Lymphoma: Diagnostic Value of Repeated Biopsy and Optimized Bcl-6 Staining.

Gamze Titiz Acur*[1], Yavuz Selim Pilis[1], Meltem Cebeci[1], Vildan Manav[1], Cem Leblebici[2], Ayşe Esra Koku Aksu[1]

[1] [1] Department of Dermatology and Venereology, Istanbul Training and Research Hospital, Istanbul, Türkiye, [2] Department of Pathology, Istanbul Training and Research Hospital, Istanbul, Türkiye, istanbul, Türkiye

[2] [2] Department of Pathology, Istanbul Training and Research Hospital, Istanbul, Türkiye, istanbul, Türkiye

Introduction

Distinguishing primary cutaneous follicle center lymphoma (PCFCL) from other cutaneous B-cell lymphomas may be challenging in limited biopsy specimens. We report a diagnostically difficult PCFCL requiring repeated biopsy and optimized immunohistochemistry for definitive classification.

Case Presentation

A 56-year-old male with no known systemic diseases presented with an asymptomatic mass on his anterior chest. The lesion had appeared approximately 6 years prior but exhibited rapid growth over the past two months. Dermatologic examination revealed an asymptomatic, 3 cm erythematous to violaceous, pseudo-keloidal nodule with a shiny surface and palpable induration on the left inferior clavicle. Dermoscopy displayed structureless areas and telangiectasia.

A 6 mm punch biopsy initially suggested a B-cell lymphoproliferative lesion. Initial microscopic evaluation showed a diffuse infiltrate of small-to-medium-sized lymphoid cells with sparse large cells, favoring a marginal zone lymphoma. Initial immunohistochemistry was technically negative for Bcl-6 and CD10. Due to diagnostic uncertainty, a wider incisional biopsy was performed. The subsequent biopsy demonstrated CD20(+), PAX5(+), sparse CD10(+), and low Ki-67 proliferative activity.

Repeated Bcl-6 immunostaining on the wider biopsy specimen revealed diffuse positivity, identifying the initial negativity as a technical false-negative. Crucially, Bcl-2 was negative, and the morphologic findings were consistently compatible with follicle center differentiation, redirecting the diagnosis toward PCFCL. High-grade lymphoma features were absent.

Laboratory investigations were largely unremarkable, with normal kidney and liver function tests, mild lymphopenia, and a CRP level of 14. A PET-CT scan showed no systemic uptake or internal organ involvement. Following a multidisciplinary approach, the patient was referred to the hematology and radiation oncology departments, and localized radiotherapy was planned.

Discussion

This case illustrates that technical false-negative immunostaining and limited tissue sampling may significantly delay accurate subclassification of cutaneous B-cell lymphomas.

Conclusion

Persistent solitary nodules with nondiagnostic initial pathology should prompt wider repeat biopsy and reassessment of key immunohistochemical markers to avoid misclassification of cutaneous B-cell lymphomas.

References:

1. Willemze R, Cerroni L, Kempf W, et al. The 2018 update of the WHO-EORTC classification for primary cutaneous lymphomas. Blood. 2019;133(16):1703-1714.
2. Senff NJ, Noordijk EM, Kim YH, et al. European Organization for Research and Treatment of Cancer and International Society for Cutaneous Lymphoma consensus recommendations for the management of cutaneous B-cell lymphomas. Blood. 2008;112(5):1600-1609.
3. Wilcox RA. Cutaneous B-cell lymphomas: 2019 update on diagnosis, risk stratification, and management. Am J Hematol. 2018;93(11):1427-1430.

EA DV CONGRESS
VIENNA
30 SEP - 3 OCT 2026

Abstract N°: 2742

Generalized eruptive keratoacanthomas of Grzybowski in a patient with end-stage renal disease

Aleix de Vargas-Machuca*[1], Kristin Technau[1], Paul Schmidle[1], Christoph Schempp[1], Cristina Has[1]

[1] University Medical Center Freiburg - Department of Dermatology and Venereology, Freiburg im Breisgau, Germany

Introduction

Generalized eruptive keratoacanthomas of Grzybowski (GEKA) are a rare disorder characterized by the rapid development of numerous keratotic papules and nodules accompanied by severe pruritus. The pathogenesis remains incompletely understood, with trauma, immune dysregulation, HPV, drugs and systemic comorbidities proposed as contributing factors.

Case Presentation

A 40-year-old woman with type 1 diabetes and dialysis-dependent end-stage renal disease presented with severe chronic pruritus (NRS 9/10) and a two-month history of rapidly progressive disseminated hyperkeratotic papules and nodules predominantly affecting the trunk and extremities.

Histopathological examination demonstrated epidermis-derived keratinizing squamous proliferation with central horn plugs and mixed inflammatory infiltrates, consistent with eruptive keratoacanthomas. HPV was not detected from available tissue testing. Clinicopathological findings were consistent with generalized eruptive keratoacanthomas of Grzybowski.

Topical corticosteroids, topical calcineurin inhibitors and moisturizers showed no significant improvement. Systemic treatment with acitretin 20 mg/day resulted in marked reduction of hyperkeratotic lesions after four months. However, severe pruritus persisted and new lesions continued to develop predominantly in areas of scratching, consistent with active Koebnerization.

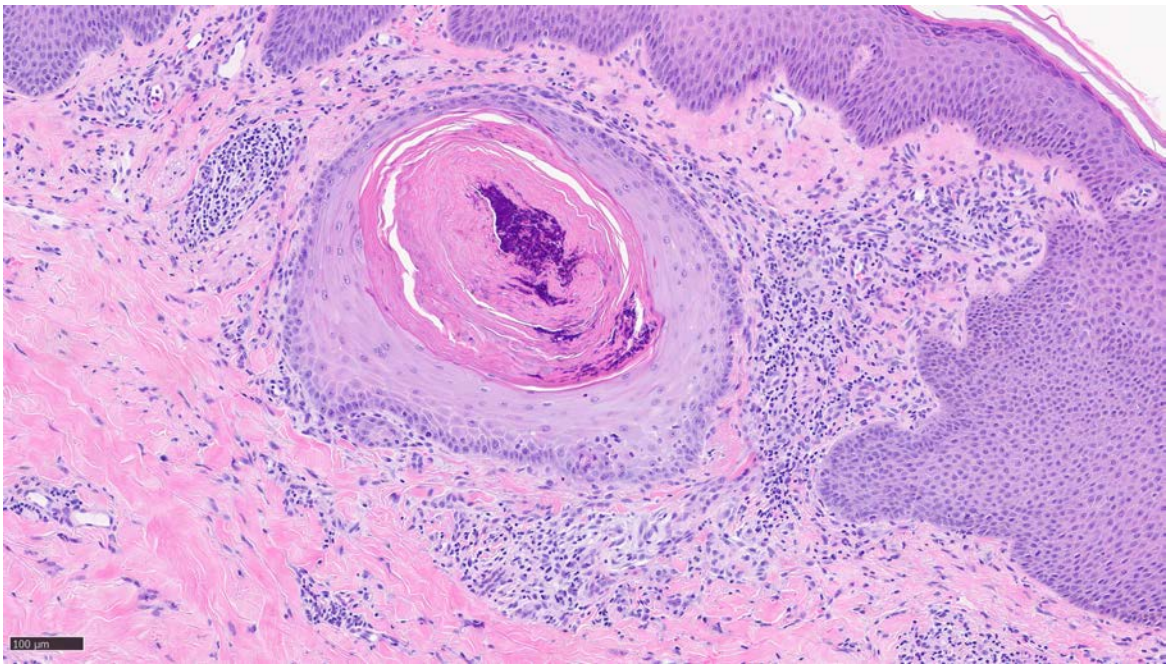

Figure 1: Histopathology showing crateriform keratinizing squamous proliferation with central horn plug and inflammatory infiltrate, consistent with eruptive keratoacanthoma (H&E stain).

Conclusion

This case supports a pathogenic model in which chronic pruritus and repetitive mechanical trauma may contribute to eruptive keratinocytic proliferation in GEKA. In the context of end-stage renal disease, uremic pruritus may represent an important driver of disease activity. Early recognition of Koebnerization may have therapeutic implications by emphasizing the need to target both keratinocytic proliferation and itch control.

EADV CONGRESS
VIENNA
30 SEP - 3 OCT 2026

Abstract N°: 2752

Brentuximab vedotin-induced pustular eruption in transformed mycosis fungoides: a diagnostic challenge

Eglė Janušonytė*[1], Ophélie Marchal[1], Sébastien Menzinger[1], Gürkan Kaya[1], Begonia Cortés[1]

[1] Department of Dermatoveneorology, Geneva University Hospitals, Geneva, Switzerland

Introduction

Brentuximab vedotin is a monoclonal antibody targeting CD30+ cells conjugated to the tubulin toxin monomethyl auristatin E. It was approved for the treatment of CD30+ cutaneous T-cell lymphoma (CTCL), including mycosis fungoides (MF) with large-cell transformation.

Although a nonspecific maculopapular rash was noted in 11% of patients treated with brentuximab vedotin during clinical trials, only a few case reports of severe cutaneous adverse reaction have been described. Distinguishing it from the patient's underlying CTCL skin disease can be challenging.

We report a case that expands the phenotypic spectrum of brentuximab vedotin-associated cutaneous toxicity in transformed MF.

Case Presentation

A 39-year-old man known for plaque MF presented with new tumoral lesions of the face, consistent with large-cell transformed CD30+ MF. These lesions appeared after multiple prior treatment lines, including mogamulizumab most recently. Brentuximab vedotin was initiated in December 2025, with an excellent early response and near-complete regression after two infusions.

Seven days after the second infusion, he developed a highly pruritic generalized papulovesicular eruption involving the face, trunk and limbs, with fever (38.5°) and bilateral cervical and preauricular lymphadenopathy.

Histopathology showed subcorneal and intraepidermal neutrophilic pustules, spongiosis, basal vacuolar degeneration with keratinocyte necrosis, and a mixed dermal infiltrate rich in histiocytes, overall favoring a drug eruption with pustular and interstitial granulomatous features. The infiltrate contained small, non-atypical lymphocytes, without epidermotropsim, and immunohistochemical findings did not support involvement by the mycosis fungoides. Laboratory investigations revealed eosinophilia (0.83 G/l), neutrophilia (17.55 G/l), and elevated alanine aminotransferase (83 U/L). Atypical lymphocytes were also detected on peripheral smear. Brentuximab vedotin was discontinued, and the clinical course was favorable. He was treated with topical steroids.

Allergological investigations revealed negative lymphocyte transformation testing for brentuximab vedotin, with interpretation limited by the degree of immunosuppression. Patch tests were negative. Intradermal testing elicited a positive reaction to brentuximab vedotin at 48 hours at the maximum tested concentration (0.05 mg/mL).

Conclusion

This case illustrates a severe cutaneous adverse reaction in the context of brentuximab vedotin therapy for transformed MF. A DRESS syndrome could not be fully excluded, with a RegiSCAR score of 3 (possible DRESS), supported by fever, eosinophilia, leukocytosis, and atypical lymphocytes on peripheral smear. Prior mogamulizumab exposure has been associated with earlier onset of brentuximab vedotin-related rash, a pattern also seen in our patient, who developed the eruption 38 days after initiation (reported median of 43 days). Severe skin reactions to brentuximab vedotin are exceptional but must be recognized, as they can be mistaken for a flare of the tumoral disease.

EADV CONGRESS
VIENNA
30 SEP - 3 OCT 2026

Abstract N°: 2754

Concurrent management of xeroderma pigmentosum due to POLH mutation with multiple skin cancers and ultra–high-risk multiple myeloma

Heike Hulla*[1], Carsten Weishaupt[1]

[1] University Hospital Münster – Department of Dermatology, Münster, Germany

Introduction

Xeroderma pigmentosum (XP) is a rare autosomal recessive DNA repair disorder characterized by defective nucleotide excision repair or translesion synthesis, resulting in extreme ultraviolet sensitivity and early-onset cutaneous malignancies. XP variant (XP-V), caused by mutations in the POLH gene encoding DNA polymerase eta, is associated with impaired translesion synthesis and a high burden of UV-induced skin cancers. Management is further complicated in patients with concomitant systemic malignancies.

Case Presentation

A 50-year-old patient was diagnosed with Xeroderma pigmentosum variant in July 2025, presenting at an advanced stage with multiple cutaneous malignancies, including several basal cell carcinomas (BCC), among them a locally destructive nasal/paranasal lesion (figure A), a melanoma in situ, and an invasive melanoma (Breslow thickness 0.4 mm). Family history revealed an effected brother. Molecular genetic testing confirmed a homozygous POLH mutation, consistent with XP-V.

Concomitantly, symptomatic kappa light chain Multiple myeloma (R-ISS II) with ultra–high-risk cytogenetics (t(14;16), 1q gain, del(13q)) and extensive osteolytic disease was diagnosed. Systemic therapy with Daratumumab, Bortezomib, Lenalidomide, and Dexamethasone was initiated. Radiotherapy was largely avoided due to the underlying DNA repair defect. However, due to a osteolysis of the tenth thoracic vertebral body (T10) with posterior wall involvement, stabilizing radiotherapy was considered unavoidable and was performed in October 2025 (39Gy).

Due to advanced BCC, treatment with the Hedgehog pathway inhibitor Sonidegib was started and maintained. A marked clinical response of the infiltrative nasal tumor was observed after 12 weeks of treatment. However, upon follow-up, a new lesion developed on the left side of the nose (figure B). Diagnostic biopsy revealed a cutaneous squamous cell carcinoma (cSCC).

Following interdisciplinary tumor board evaluation, combination therapy with the PD-1 inhibitor Cemiplimab was initiated in parallel with ongoing hedgehog inhibitor and hematooncological treatment of multiple myeloma. The treatment with daratumumab, dexamethasone, and lenalidomide had to be administered at a reduced dose due to myelosuppression with recurrent infections; otherwise, the combination therapy showed good tolerability and resulted in a marked clinical response of the cSCC as well as ongoing response of the BCC (figure C). Within the short observation period of five months, there was no sign of any tumor in the irradiated skin on the back.

Conclusion

This case highlights the aggressive tumor phenotype associated with XP-V due to POLH mutation and underscores the complexity of managing multiple malignancies in this context. Combined Hedgehog inhibition and immune checkpoint blockade may represent a promising strategy in advanced keratinocyte carcinomas in XP patients. Interdisciplinary management is essential to balance efficacy, toxicity, and disease-specific constraints in the absence of established guidelines.

EA DV CONGRESS
VIENNA
30 SEP - 3 OCT 2026

Abstract N°: 2755

Acral Lentiginous Melanoma In-Situ in England: Insights from National Registry Data

Suhani Sharma*[1], Birgitta van Bodegraven[2, 3], Ava Lee[1, 3, 4], Zoe Venables[1, 3, 4]

[1] Norwich Medical School, Norwich, United Kingdom

[2] British Association of Dermatologists, London, United Kingdom

[3] National Disease Registration Service, Data and Analytics, NHS England, London, United Kingdom

[4] Norfolk & Norwich University Hospital, Norwich, United Kingdom

Introduction

Acral lentiginous melanoma in situ (ALMIS) is an uncommon melanoma subtype arising on glabrous acral skin and the nail apparatus, with poorly characterised epidemiology. International literature suggests acral lentiginous melanoma represents a small proportion of melanoma cases overall, with variation across populations and a tendency to present at older ages. Robust population-level data are essential to understanding disease pathogenesis, demographic patterns, and potential inequities in diagnosis. We explored national registry data to describe the incidence and demographic profile of ALMIS in England and to highlight limitations relevant to interpretation.

Materials and Methods

Publicly available data were extracted from the National Disease Registration Service (NDRS) “Get Data Out” platform for diagnoses registered between 2013–2022. Cases recorded as ‘melanoma in situ’ with tumour subtype coded as ‘acral lentiginous melanoma in situ’ were identified using ICD-10 and ICD-O3 codes. They were analysed descriptively by annual counts, incidence, age, gender, ethnicity, and deprivation quintiles. The one-way chi-squared test compared overall sex distribution (male vs female case counts).

Results

A total of 375 cases were registered. ALMIS accounted for 0.59% of all melanoma in situ cases (n = 63,803) over the study period. Annual counts ranged from 21–55, peaking in 2018 (n=55), falling in 2020 (n=24), and rising again by 2022 (n=46) without a consistent linear trend. Incidence ranged 0.04–0.10 per 100,000 person-years (crude) and 0.04–0.10 per 100,000 person-years (age-gender-standardised). Cases occurred predominantly in individuals aged ≥50 years, with highest counts at ages 60–79 years. Overall, females represented a significantly higher proportion of cases than males (66.9% vs 33.1%; $\chi^2(1)=43.01$, $p<0.001$). Ethnicity was unknown in 40/375 cases (10.7%). Among recorded cases, White ethnicity was most common (75.2%, n=282), followed by Black (8.0%, n=30), Asian excluding Chinese (4.5%, n=17), Other (1.3%, n=5), and Mixed (0.3%, n=1). Cases were observed across deprivation quintiles. Distribution across deprivation quintiles is shown in Table 1.

For the most recent cohort with 5-year follow-up available (2014–2016 diagnoses), 5-year Kaplan–Meier survival was 86.1% (95% confidence intervals (CI) 78-91.4) and 5 year net survival was 94.3% (CI 85.9-102.7).

Deprivation Quintile	Description	n	%
Q1	Most deprived	54	14.4%
Q2		74	19.7%
Q3		85	22.7%
Q4		78	20.8%
Q5	Least deprived	84	22.4%

[Table 1. Distribution of ALMIS cases by deprivation quintile (England, 2013–2022)]

Conclusions

In England, ALMIS remains exceptionally rare, although this limits detailed epidemiological interpretations. Demographic patterns, including female predominance and relatively equal distribution across deprivation quintiles, must be interpreted cautiously due to small numbers. Incomplete ethnicity recording limits detailed assessment by ethnic groups. These findings emphasise the importance of large, population-level datasets to enable robust evaluation of epidemiological patterns and meaningful study of variations in rare melanoma subtypes such as ALMIS.

EADV CONGRESS
VIENNA
30 SEP - 3 OCT 2026

Abstract N°: 2757

Zosteriform Cutaneous Metastases of Pulmonary Adenocarcinoma – A Case Report

Jelena Vukovic*[1], Dubravka Zivanovic[1, 2], Aleksandra Pucanovic[3], Andjela Kovcic[1], Svetlana Popadic[1, 2]

[1] Polyclinic Imedic, Belgrade, Serbia

[2] University of Belgrade - Faculty of Medicine, Department of Dermatology and Venereology, Belgrade, Serbia

[3] Department of Dermatology and Venereology, Clinical Hospital Center Zemun, Belgrade, Serbia

Introduction

Adenocarcinoma is the most common histological subtype of lung cancer and remains one of the leading causes of mortality among adults worldwide. Cutaneous metastases from pulmonary adenocarcinoma are uncommon, with a reported incidence ranging from 1% to 12%. The most frequently affected sites include the chest, abdomen, head, and neck. Clinically, they most often present as solitary or multiple papules and nodules, while less common manifestations include plaque-like lesions, erysipelas-like eruptions, and zosteriform lesions. Cutaneous metastases usually develop late in the course of the disease and are associated with a poor prognosis and reduced survival. We present a case of cutaneous metastases from pulmonary adenocarcinoma with a zosteriform distribution.

Case Presentation

An 82-year-old woman with stage III lung adenocarcinoma presented at our clinic with an asymptomatic dermatomal eruption on the left side of the neck and upper chest. Lesions had been present for four months and had been treated with topical corticosteroids and antibiotics without improvement. Clinical examination revealed erythematous, indurated plaques with vesiculopapules and pustules on the lateral neck and upper chest, along the distribution of the left C4-C5 dermatome area. Histopathological findings confirmed adenocarcinoma metastases infiltrating the dermis.

Conclusion

The pathogenesis of cutaneous lung cancer metastases is yet to be fully understood. The most commonly suggested mechanism is retrograde lymphovascular invasion, while poor differentiation and upper lobe location of primary tumors increase the risk. Zosteriform cutaneous metastases are a rare clinical presentation, with a limited number of cases reported in the literature. This case highlights the importance of considering cutaneous metastases in the differential diagnosis of herpes zoster-like eruptions, particularly in patients with a history of internal malignancy.

EADV CONGRESS
VIENNA
30 SEP - 3 OCT 2026

Abstract N°: 2761

Radiation-Induced Basal Cell Carcinoma: A Case Series

Joanna Choma*[1], Robert Kijowski[1], Ewelina Mazur[1]

[1] The Department of Dermatology, University of Rzeszów, Rzeszów, Poland

Introduction

Radiation-induced basal cell carcinoma (BCC) is a secondary malignancy developing within or at the margins of a previously irradiated field. These malignancies are characterized by long latency period estimated at 20-45 years. 3.3-fold increased BCC risk after exposure to radiation was previously reported. Young age at irradiation constitutes one of the main risk factors. These tumours are characterized by multifocality and pose diagnostic challenges due to similar clinical and dermoscopic features to chronic radiation-induced dermatitis.

Materials and Methods

We conducted a retrospective analysis of patients diagnosed with radiation-induced BCC at the Department of Dermatology, University of Rzeszów over a period of 10 years (2016 to 2026). All lesions underwent surgical excision with histopathological confirmation. Patients with molecularly confirmed Gorlin-Goltz syndrome and Xeroderma pigmentosum were excluded from the study.

Results

Six patients, 4 females and 2 males with radiation-induced basal cell carcinoma were included. The mean latency between radiotherapy and first BCC diagnosis was 27 years (range 16-35). The majority of patients were irradiated as children or young adults; youngest age at irradiation was 2 years. Primary malignancies treated with radiotherapy included Hodgkin lymphoma in 3 cases, Wilms tumor in 1 case, ependymoma in 1 case and breast cancer in 1 case. Multiple lesions were observed in 5 out of 6 patients. Total number of BCC lesions ranged from 1 to 25 per patient - all developed within the irradiation field, mostly on the trunk. Dermoscopic features of BCCs were frequently superimposed on a chronic radiation-induced dermatitis (CRD) background characterized by structureless white areas, polarization-dependent white lines, brown dots and globules, branching vessels.

Conclusions

Radiation-Induced Basal Cell Carcinoma is a significant challenge as oncological treatment efficacy and patient survival improve. The prolonged latency period and tendency to develop multiple lesions require lifelong dermatological monitoring of irradiated patients. Dermoscopic differentiation between early BCC and CRD remains challenging and requires systematic evaluation in the context of prior radiation exposure.

EADV CONGRESS
VIENNA
30 SEP - 3 OCT 2026

Abstract N°: 2763

The Economic and Clinical Imperative of Early Melanoma Detection: A Comparative Analysis of Treatment Costs and Survival Outcomes

Afshin Sadeghiyan[1], Gulcin Canbeyli[1], Pooya Khanmohammad Beigi*[1]

[1] MARI, Los Angeles, United States

Introduction
Dermatological malignancies represent a significant public health challenge in the United States, with nearly 6 million individuals treated annually. Disease staging at initial presentation remains the primary determinant of clinical prognosis and health system resource utilization. This study aims to quantify the survival and economic impact of stage-specific melanoma detection while identifying socioeconomic barriers to early diagnosis for underserved populations.

Materials and Methods
This analysis synthesizes longitudinal epidemiological data from the Centers for Disease Control and Prevention (CDC, 2025) and the American Cancer Society (ACS, 2026), alongside a retrospective cohort analysis of 67,000 cases from the New York State Cancer Registry. We performed a comparative analysis of five-year survival rates and cumulative treatment expenditures across Stages I through IV.

Results
Clinical outcomes are characterized by a 99% five-year survival rate for localized disease versus 35% for distant metastasis. Economic expenditures escalate by a factor of 22 for advanced cases, representing a 2,200% cost increase ($4,649 vs. $159,808). Early detection yields a projected marginal cost saving of $100,000 to $155,000 per patient. Notably, wait times for Medicaid patients were found to be 2.3 times longer than for privately insured patients, directly correlating with advanced-stage presentation.

Conclusions
Early identification represents the single most effective clinical and economic lever in modern dermato-oncology. Shifting diagnostic patterns through dermatology-enhanced targeted screenings is essential to dismantle entrenched survival disparities and mitigate the catastrophic financial burden on the public health system. A paradigm shift toward proactive, low-barrier screening models—such as dermatology facilitators—is not merely a clinical recommendation but a fiscal necessity for sustainable healthcare delivery in the 21st century. By prioritizing early-stage detection, health systems can achieve a superior return on investment while significantly reducing mortality in the most vulnerable patient demographics.

POWERED BY M-ANAGE.COM

EA DV CONGRESS
VIENNA
30 SEP - 3 OCT 2026

Abstract N°: 2764

Inverted Follicular Keratosis: A Case Report

Houda El ABBADE*[1], Meryem soughi[1], rihame al heyasat[1], IKRAM BEJJA[1], Saadia Boughaleb[1], ZAKIA DOUHI[1], Sara Elloudi[1], HANANE Baybay[1], Fatimazahra Mernissi[1]

[1] UHC HASSAN II, FEZ, Morocco

Introduction

Inverted follicular keratosis is a benign cutaneous tumor arising from the infundibular portion of the hair follicle, above the level of the sebaceous duct opening. It was first described by Helwig in 1954. Since then, several cases have been reported in the dermatological and pathological literature . We report a new case.

Case Presentation

A 57-year-old male patient with no significant past medical history presented with a raised lesion on the forehead evolving over eight months , with progressive increase in size. The patient reported no pain or bleeding on contact.

Dermatological examination revealed a well-demarcated hyperkeratotic plaque with irregular borders, measuring approximately 2 cm in its greatest diameter. The lesion had a sessile triangular base, was non-infiltrated, and was located along the midline of the frontal hairline on otherwise normal-appearing skin (figure a) . Dermoscopic examination showed scaling without visible vascular structures (figure b) .

The initial differential diagnoses included epidermized pyogenic granuloma, cutaneous horn, granulation tissue, fibroma, and benign adnexal tumor.

The patient underwent complete excisional biopsy. No recurrence was observed after a 12-month follow-up.

Histopathological examination demonstrated an endophytic epidermal proliferation covered by orthokeratotic hyperkeratosis. The lesion consisted of anastomosing lobules composed of uniform keratinocytes. The underlying dermis was fibrotic with mild inflammatory infiltrate. Surgical margins were clear.
These findings were consistent with inverted follicular keratosis.



Figure a : a well-demarcated hyperkeratotic plaque with irregular borders ,located along the midline of the frontal hairline Figure b : scaling without visible vascular structures

Conclusion

Inverted follicular keratosis is a benign follicular tumor. This case highlights both the rarity of this entity and the diagnostic challenges it may pose clinically and histologically. Diagnosis relies on histopathological examination, and treatment is primarily surgical.

EADV CONGRESS
VIENNA
30 SEP - 3 OCT 2026

Abstract N°: 2768

Melanotan II Augments the Therapeutic Efficacy of c-Met Inhibitor in Suppressing B16-F10 Melanoma

Chieh-Shan Wu*[1, 1], Ming-Hong Tai[2], Wen-Ho Chuo[3]

[1] Department of Dermatology, Pingtung Veterans General Hospital, Pingtung County, Taiwan

[2] Institute of Biomedical Science, National Sun Yat-Sen University, Kaohsiung City, Taiwan

[3] Department of Pharmacy, Tajen University, Pingtung Verterans General Hospital, Pingtung Verterans General Hospital, Pingtung County, Taiwan

Introduction

Melanoma is refractory to conventional cancer therapies and associated with a high risk of mortality. Cabozantinib acts as a potent multi-tyrosine kinase inhibitor (TKI) in melanoma by targeting VEGFR/cMET/AXL/RET pathways. However, the response rate of advanced melanoma patients to TKI Cabozantinib remains poor, underscoring the demand of novel therapeutic strategies. Melanotan II (MT II), a synthetic analog of alpha-melanocyte stimulating hormone (α-MSH), has been applied in humans for tanning purposes. Our previous study indicates topical MT II application effectively attenuated the oncogenic behaviors *in vitro* and progression of B16-F10 melanoma *in vivo*. RNA sequence analysis reveals that MT II upregulates the expression of c-Met, one of the targeting pathways by carbozantinib, in B16-F10 melanoma cells.

Case Presentation

Thus, we investigated whether MT II supply enhanced the anti-neoplastic potential of Cabozantinib in B16-F10 melanoma. It was found that that MT II significantly enhanced the tumor-suppressive effects of cabozantinib by inhibiting the proliferation and colonies formation of B16-F10 cells. Moreover, MT II diminished the pro-invasive and epithelial mesenchymal transition (EMT)-promoting functions of cabozantinib in B16-F10 cells. In mice bearing established B16-F10 melanoma, combination therapy using both MT II and cabozantinib significantly reduced the tumor burden. Notably, histological analysis showed that MT II reversed the cabozantinib-mediated EMT whereas cabozantinib abrogated the MT II–induced c-Met upregulation.

Conclusion

These findings advocate the potential of MT II and carbozantinib combinatory therapy for melanoma suppression in the future.

EA DV CONGRESS
VIENNA
30 SEP - 3 OCT 2026

Abstract N°: 2785

Cutaneous Presentation of Extranodal NK/T-cell Lymphoma with Concurrent Testicular Involvement

Çınar Yıldız*[1], Nazan Ozsan[2], Ece Gökyayla[1], İlgen Ertam[1]

[1] Ege University Department of Dermatology and Venereology, İzmir, Türkiye
[2] Ege University Department of Pathology, İzmir, Türkiye

Introduction

Extranodal natural killer/T-cell lymphoma, nasal type (ENKTL) is a rare and aggressive Epstein–Barr virus (EBV)-associated malignancy that most commonly involves the nasal cavity; extranasal presentations are less frequently reported, with the skin being one of the more common extranasal sites of involvement.[1] We report a patient whose clinical manifestations initially presented with cutaneous lesions and who was subsequently found to have concurrent testicular involvement.

Case Presentation

A 58-year-old man was referred to our dermatology clinic with progressive cutaneous patches and plaques, a cellulitis-like lesion and bilateral testicular enlargement. The cutaneous lesions had initially appeared on the chest approximately nine months prior to admission and gradually extended to involve the extremities. Approximately six months later, a cellulitis-like lesion developed on the medial aspect of the left leg (Figure 1 and Figure 2) in association with bilateral testicular enlargement noticed by the patient. Scrotal ultrasonography demonstrated bilateral, poorly defined hypoechoic testicular lesions suggestive of an infiltrative process. Peripheral blood smear and routine laboratory parameters were unremarkable, except for an elevated serum beta-2 microglobulin level (2882 µg/L; reference range, 800–2400 µg/L). A right orchiectomy had previously been performed at an external centre, and the specimen was submitted to our pathology department for consultation. After admission to our clinic, two additional skin biopsies were obtained. Histopathological examination of both skin and testicular specimens revealed a diffuse pleomorphic lymphoid infiltrate, with focal angiocentric features. On immunohistochemistry, the neoplastic cells were strongly positive for CD2, CD56, TIA-1, granzyme B, and EBER (in situ hybridisation). The proliferation index (Ki-67) was approximately 90%. The neoplastic cells were negative for CD3, CD4, CD8, CD20, CD138, TdT, CD30, CD10, and Bcl-6, supporting a diagnosis of extranodal NK/T-cell lymphoma (Figure 3). Whole-body 18F-fluorodeoxyglucose positron emission tomography/computed tomography (FDG PET/CT) revealed hypermetabolic foci in the left testis and at multiple cutaneous sites, with no evidence of upper aerodigestive tract or nodal involvement.

While the majority of testicular lymphomas are diffuse large B-cell lymphomas[2], secondary involvement by ENKTL has only rarely been reported and tends to follow an aggressive clinical course.[3] Sequential progression from cutaneous to testicular disease has previously been described[4]; in our patient, the precise chronological sequence between cutaneous and testicular involvement could not be defined with certainty, although the cutaneous lesions clearly preceded the recognition of testicular disease. PET/CT was helpful in delineating the extranasal distribution of the disease and in excluding upper aerodigestive tract involvement, in keeping with previous reports.[5] Following diagnosis, the patient was commenced on chemotherapy with the dexamethasone, methotrexate, ifosfamide, L-asparaginase and etoposide (SMILE) regimen, which is widely employed in this entity.[6]

Conclusion

In summary, cutaneous manifestations of ENKTL may present as subcutaneous nodules, cellulitis-like lesions and ulcerated plaques, and dermatologists may be among the first physicians to encounter such patients.[1] Early clinical recognition of these presentations, together with prompt histopathological evaluation, is therefore important, as it may help unmask underlying systemic involvement before further disease progression.

EADV CONGRESS
VIENNA
30 SEP - 3 OCT 2026

Abstract N°: 2786

Cutaneous extramedullary relapse of IgA-kappa multiple myeloma mimicking cutaneous metastases

Jorge Valdespino-Valdes*[1], Alejandra Brown-Herrera[1], Mariana Elizondo-Alatorre[1], Sonia Chavez-Alvarez[1], Otoniel Gonzalez[2], Rodolfo Franco-Marquez[2], Jorge Ocampo-Candiani[1]

[1] Dermatology Service, Hospital Universitario "Dr. José E. González", Monterrey, Mexico
[2] Pathology Department, Hospital Universitario "Dr. José E. González", Monterrey, Mexico

Introduction

Disease-specific cutaneous involvement in multiple myeloma is rare and usually reflects extramedullary dissemination with aggressive biological behavior. It may present as erythematous to violaceous papules, plaques or nodules, requiring clinicopathologic correlation for diagnosis. In patients with concomitant solid malignancies, distinguishing cutaneous myeloma involvement from cutaneous metastases is particularly challenging.

Case Presentation

A 79-year-old man with IgA-kappa multiple myeloma diagnosed in 2021, last treated with carfilzomib in January 2026, presented with a three-month history of disseminated cutaneous lesions. Recent serum protein electrophoresis showed only a minimal monoclonal peak. He also had metastatic ampullary adenocarcinoma, previously treated with pancreatico-duodenectomy followed by adjuvant gemcitabine and capecitabine, discontinued after three cycles due to febrile neutropenia and severe thrombocytopenia. After hepatic metastatic progression, capecitabine monotherapy was restarted in February 2026.

Examination revealed a bilateral, asymmetric, polymorphic dermatosis involving the left lower limb, the dorsum of both feet and the left plantar surface. The lesions consisted of multiple indurated, smooth-surfaced, erythematous-violaceous nodules, some mildly pruritic. Dermoscopy showed polymorphous vessels. Main differential diagnoses included cutaneous extramedullary involvement by multiple myeloma or cutaneous metastases from ampullary adenocarcinoma.

Skin biopsy revealed a dermal infiltrate of predominantly monomorphic population of large atypical cells with eccentric nuclei, visible nucleoli and basophilic cytoplasm, resembling plasma cells or immunoblasts. Focal areas showed marked nuclear pleomorphism, numerous mitotic figures, consistent with high-grade cytologic features. Immunohistochemistry showed diffuse CD138 positivity and negative EBER-ISH. Kappa/lambda light-chain studies demonstrated a kappa predominance over lambda in a 4:1 ratio, concordant with the original IgA-kappa multiple myeloma phenotype (Figure 1). These findings confirmed cutaneous extramedullary relapse of multiple myeloma rather than cutaneous involvement by ampullary adenocarcinoma.

At latest follow-up, the patient was undergoing the second of three planned 21-day cycles of daratumumab, bortezomib and dexamethasone, and had completed seven of ten planned sessions of local radiotherapy to the affected lower limb.

The central diagnostic challenge was not only to identify plasma cell lineage, but to determine whether the infiltrate was reactive or clonal. CD138 confirmed plasma cell differentiation, whereas concordant kappa light-chain restriction established monoclonality. This distinction is essential because plasma cell-rich infiltrates may occur in carcinomas, inflammatory processes and infections. High-grade plasmablastic/immunoblast-like morphology supported aggressive extramedullary disease, while EBER-ISH negativity helped exclude Epstein-Barr virus-associated plasmablastic lymphoma.

A relevant feature was the discordance between minimal monoclonal protein on serum electrophoresis and biopsy-proven cutaneous extramedullary relapse, suggesting that conventional immunoprotein markers may underestimate disease burden in extramedullary or oligosecretory relapse.

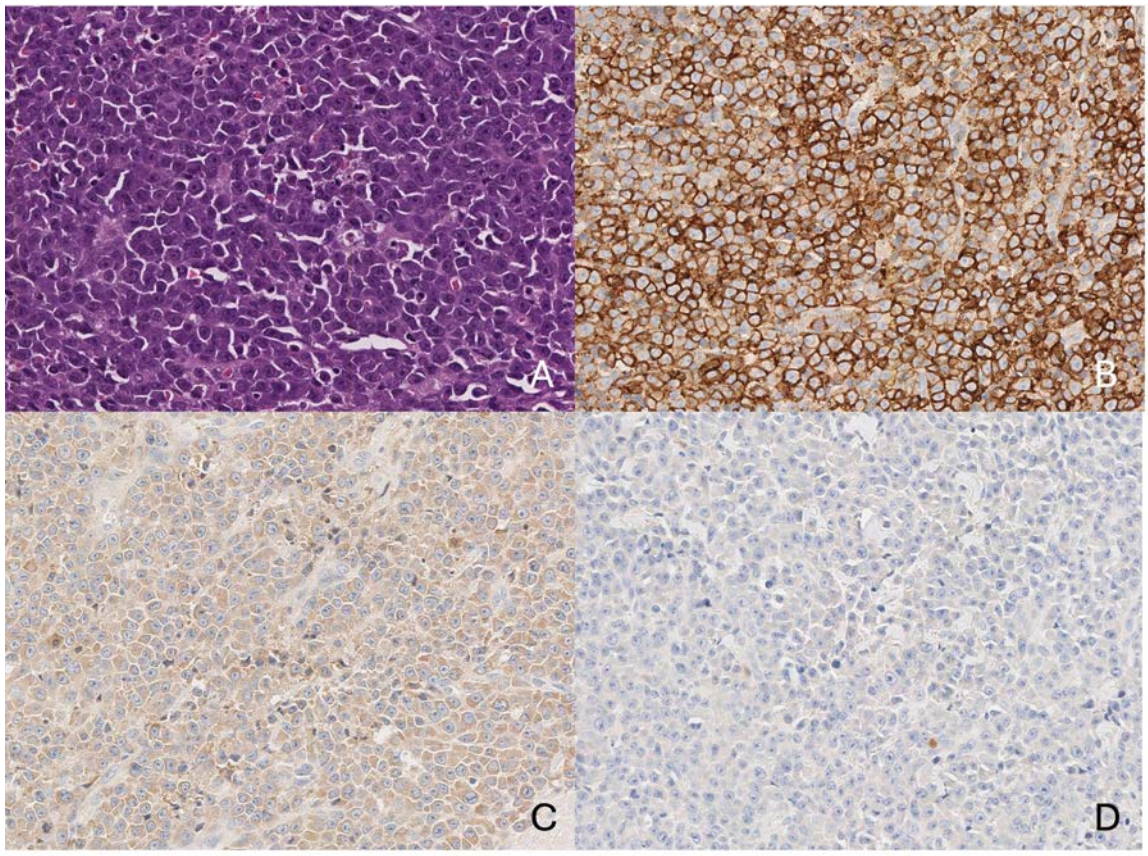

Figure 1. A) A monomorphic population of large atypicals cells can be observed, with an eccentric nucleus, visible nucleolus, and basophilic cytoplasm, giving the appearance of a plasma cell (H&E, x20). B) Immunohistochemical marker CD13 was broadly positive in a membranous pattern in the neoplastic cells. (IHC CD138, x20). C and D) Immunohistochemical markers for light chains (kappa and lambda), which were broadly positive with a kappa-to-lambda ratio of 4:1. The staining pattern is granular cytoplasmic in the neoplastic cells. (IHC CD138, x20).

Conclusion

New erythematous-violaceous nodules in patients with multiple myeloma should raise suspicion for cutaneous extramedullary relapse, even without overt serologic progression. Skin biopsy with immunohistochemistry and light-chain restriction is essential to distinguish cutaneous myeloma involvement from metastatic solid tumors or treatment-related eruptions.

EADV CONGRESS
VIENNA
30 SEP - 3 OCT 2026

Abstract N°: 2787

Vesiculobullous folliculotropic mycosis fungoides with large cell transformation: a polymorphous presentation with an aggressive disease course

Hui Kai Koh*[1], Derek Lim[1], Hui Yi Chia[1], Suat Hoon Tan[1], Wei Sheng Chong[1]

[1] National Skin Centre, Singapore, Singapore

Introduction

Introduction: Mycosis fungoides (MF) is renowned for its polymorphous clinicopathological presentations. Among its rarer variants, vesiculobullous MF is exceptionally uncommon; rarer still is its concurrent manifestation with folliculotropism, conventional plaque-stage disease, and large cell transformation within the same patient, representing an unusual and diagnostically challenging constellation.

Case Presentation: A 72-year-old Indian woman presented with a four-month history of pruritic eruption with associated anorexia and weight loss. Examination revealed psoriasiform scaly plaques on the chest and abdomen with superimposed tense vesicles and bullae, alongside digitate plaques along the flanks. Three biopsies were performed. One showed subcorneal pustules, bulla and folliculotropism associated with an atypical lymphoid infiltrate, whilst another biopsy showed plaque stage mycosis fungoides. The third biopsy showed mycosis fungoides with large cell transformation. Imaging revealed generalised lymphadenopathy; cervical node excision confirmed mature T-cell lymphoma. PET-CT demonstrated multifocal FDG-avid lymphadenopathy above and below the diaphragm with extensive cutaneous uptake. Stage IVA (T2N3M0) folliculotropic MF with large cell transformation and nodal involvement was diagnosed. The patient was referred for systemic evaluation and therapy.

Conclusion: The coexistence of vesiculobullous change, folliculotropism, and large cell transformation in this case represents an unusual and diagnostically challenging constellation. Vesiculobullous MF likely results from coalescing Pautrier microabscesses and lymphocyte-mediated disruption of keratinocyte adhesion within a Th2-skewed cytokine milieu. Vesiculobullous MF carries a poor prognosis, with reported mortality approaching 50% within one year of bullae appearance. Folliculotropism and large cell transformation are independent predictors of treatment resistance and reduced survival. This case highlights that a polymorphous presentation should prompt expeditious histopathological workup, as recognition of these convergent features is critical for accurate staging and timely therapeutic intervention. The aggressive course seen in this patient also expands the spectrum of aggressive cutaneous T cell lymphomas, including mycosis fungoides.

EA DV CONGRESS
VIENNA
30 SEP - 3 OCT 2026

Abstract N°: 2791

Cutaneous Metastasis of Neuroblastoma in a 5-Month-Old Infant: A Diagnostic Challenge for Dermatologists

Carlos Manuel Martorell Moreau*[1], Luis Javier Del Pozo Hernando[1], Laura Moreno Hernández[1], Carmen María Ruiz Gámez[2], Carlos Saus Sarria[3], Samuel Navarro Noguera[2], Ana Martín Santiago[1]

[1] Department of Dermatology. Son Espases University Hospital, Palma, Spain
[2] Department of Pediatrics. Son Espases University Hospital, Palma, Spain
[3] Department of Pathology. Son Espases University Hospital, Palma, Spain

Introduction

Neuroblastoma is the most common extracranial solid tumor of infancy. It most frequently originates in the adrenal medulla or paraspinal ganglia, and can present as a mass in the abdomen, chest, neck, or pelvis. Cutaneous metastases are a rare but well-recognized manifestation, occurring in approximately 1% of cases and predominantly in neonates and young infants. When present, subcutaneous nodules may constitute the initial and sometimes the only visible sign of underlying malignancy.

Case Presentation

An otherwise healthy 5-month-old infant presented with multiple asymptomatic subcutaneous nodules that had been appearing progressively since the age of 2 months. He was born after an uneventful pregnancy and delivery, with normal developmental milestones. The first and largest lesion arose in the hypogastric region, followed by smaller nodules over the trunk and extremities. Physical examination revealed bluish, soft, non-tender subcutaneous nodules of varying size. Ultrasound showed multiple anechoic nodules without internal Doppler signal. Skin biopsy established the diagnosis, demonstrating diffuse dermal infiltration by small round blue cells with neuropil and immunohistochemical positivity for CD56, NSE, and synaptophysin, consistent with metastatic neuroblastoma.

Laboratory workup confirmed elevated urinary catecholamines. Abdominal imaging revealed a retroperitoneal para-aortic mass with hepatic, muscular, and cutaneous metastases. Bone marrow assessment was non-diagnostic. Molecular studies showed absence of MYCN amplification. Integrating clinical, imaging, histological, and molecular data, a final diagnosis of stage M neuroblastoma (INRGSS)was established. The patient was treated with carboplatin–etoposide chemotherapy, achieving marked reduction of the primary tumor and metastatic burden after four cycles.

Cutaneous metastases in neuroblastoma may fall within the spectrum of the so-called "blueberry muffin baby", a descriptive term for neonates and young infants presenting with multiple bluish, subcutaneous nodules distributed across the body. This pattern is not exclusive to neuroblastoma and encompasses a broad differential diagnosis, including extramedullary erythropoiesis secondary to congenital infections, leukemia cutis, histiocytosis, metastatic rhabdomyosarcoma, rhabdoid tumor, and others. The initial workup should include complete perinatal history, infectious serology, full blood count with peripheral smear, and imaging. If a neoplastic etiology is suspected, skin biopsy is mandatory, as histology ultimately guides all further investigation and clinical management. In neuroblastoma, staging must incorporate MIBG scintigraphy, bone marrow assessment, and molecular studies, with MYCN amplification status representing one of the most important prognostic markers. Its absence is associated with a substantially more favorable clinical course. Cutaneous involvement in an infant

under 12 months without MYCN amplification is usually consistent with MS-stage neuroblastoma, a subgroup with comparatively favorable prognosis, often requiring only observation or minimal treatment due to high rates of spontaneous remission. However, the presence of muscular metastases in our case placed the patient beyond the MS-stage criteria, warranting classification as stage M disseminated disease and guiding the decision to initiate chemotherapy despite the patient's young age and favorable molecular profile.

Conclusion

Neuroblastoma should be included in the differential diagnosis of any young infant presenting with subcutaneous nodules. Skin lesions may precede or occur simultaneously with the identification of a primary tumor, making early biopsy and prompt multidisciplinary evaluation essential. As dermatologists are often the first specialists to evaluate these patients, awareness of this presentation is key to ensuring timely diagnosis and improved outcomes.

EADV CONGRESS
VIENNA
30 SEP - 3 OCT 2026

Abstract N°: 2804

Carcinoma En Cuirasse Mimicking Post-Radiotherapy Sclerodermoid Change In Metastatic Breast Carcinoma

Ibrahim Akcay*[1], Ece Okumuslar Tozman[1], Banu Yaman[2], Nilay Duman[1]

[1] Department of Dermatology and Venereology, Ege University Faculty of Medicine, İzmir, Türkiye
[2] Department of Medical Pathology, Ege University Faculty of Medicine, İzmir, Türkiye

Introduction

Carcinoma en cuirasse (CeC) is a rare form of cutaneous metastatic carcinoma characterized by diffuse sclerodermoid induration resulting from dermal tumor infiltration and progressive stromal fibrosis. It accounts for approximately 3–6% of cutaneous metastases associated with breast carcinoma. Because of its infiltrative fibrosing nature, CeC may be mistaken for inflammatory or post-treatment fibrosing skin changes, creating diagnostic difficulties.

Case Presentation

A 58-year-old woman with metastatic breast carcinoma diagnosed in 2024 developed progressive painful erythematous and indurated lesions involving the right breast, axilla, anterior chest wall, back, and right upper extremity despite multiple systemic treatments and radiotherapy. Physical examination revealed diffuse edema, skin thickening, ulceration, and extensive sclerodermoid induration over the involved areas.

Imaging studies demonstrated diffuse cutaneous and subcutaneous edema involving the right breast, axilla, chest wall, and right upper extremity together with marked skin thickening and infiltrative soft tissue involvement. The progressive sclerodermoid induration initially raised concern for post-radiotherapy fibrosis and inflammatory skin changes.

Punch biopsy specimens obtained from indurated cutaneous lesions demonstrated dense stromal fibrosis with interstitial infiltration of atypical tumor cells arranged in characteristic linear single-file patterns, consistent with carcinoma en cuirasse. Immunohistochemical examination showed SOX10 positivity in tumor cells, whereas estrogen receptor, progesterone receptor, GATA3, and HER2 expression were not detected in the cutaneous biopsy specimen. PAS-Alcian Blue staining demonstrated focal positivity.

Overall clinicopathological findings were consistent with cutaneous metastatic breast carcinoma presenting as carcinoma en cuirasse with extensive fibrosing stromal reaction.

Conclusion

Carcinoma en cuirasse is an uncommon but distinctive presentation of cutaneous metastatic breast carcinoma and may clinically resemble inflammatory or post-treatment fibrosing dermatoses. Recognition of its characteristic sclerodermoid appearance together with the histopathological single-file infiltration pattern is essential for accurate diagnosis. This case highlights the aggressive fibrosing nature of carcinoma en cuirasse and emphasizes the importance of clinicopathological correlation in distinguishing metastatic disease from treatment-related skin changes.

EADV Congress 2026, VIENNA
30 SEPTEMBER - 03 OCTOBER 2026
POWERED BY M-ANAGE.COM

EA DV CONGRESS
VIENNA
30 SEP - 3 OCT 2026

Abstract N°: 2812

Dermatofibrosarcoma protuberans of the left lumbar region: a deceptive tumor revealed after 10 years of evolution

Najat Chebbawi*[1, 1], soukaina benhammou[1], Fatima zahra Benhayoune[1], Bouchra Baghad[1], Hanane Rachadi[1], Mounia Diouri[1], Soumiya Chiheb[1]

[1] University Hospital Center Ibn Rochd, Casablanca, Morocco

Introduction

DFSP is a rare cutaneous fibroblastic tumor of intermediate malignancy, characterized by slow but infiltrative growth and a high risk of local recurrence. It most commonly arises on the trunk and may mimic benign soft tissue lesions, leading to delayed diagnosis.We report the case of a 40-year-old patient presenting with a left lumbar mass, highlighting a rare presentation of dermatofibrosarcoma protuberans (DFSP).

Case Presentation

We report the case of a 40-year-old woman living in Casablanca (Casablanca), originally from Taliwine (Taliwine), with no significant medical history, presenting with a progressively enlarging subcutaneous mass of the left lumbar region evolving over 10 years. The lesion initially appeared as a small subcentimetric nodule, with slow growth over several years, followed by accelerated enlargement over the last two years and the onset of local pain, while the general condition remained preserved. Clinical examination revealed a 7 cm left lumbar subcutaneous mass, mobile relative to deep planes, with a vascularized surface, without necrosis or ulceration, mildly tender on palpation, and no lymphadenopathy or systemic abnormalities.
Dermatofibrosarcoma protuberans (DFSP) is a rare cutaneous sarcoma of intermediate malignancy, accounting for a small proportion of soft tissue tumors. It is characterized by a locally aggressive behavior with infiltrative growth along fascial planes, despite a low metastatic potential. The tumor most commonly affects young to middle-aged adults and typically arises on the trunk, proximal extremities, and less frequently in atypical or deeper subcutaneous locations, which may contribute to diagnostic delay.

Clinically, DFSP often presents as a slow-growing, firm, painless plaque or nodule that may remain stable for years before entering a phase of more rapid enlargement. This indolent initial evolution, as observed in our patient over approximately eight years, is a major reason for late diagnosis. In many cases, the lesion may be misinterpreted as a benign soft tissue tumor such as a lipoma, epidermoid cyst, or other benign fibroblastic lesions, especially in the absence of alarming clinical signs in early stages.

In our case, the left lumbar localization, although classical for DFSP, may allow deep and clinically silent extension into subcutaneous and muscular planes. The recent rapid growth with onset of pain likely reflects increased tumor activity and deeper infiltration. Imaging is useful for assessing tumor extent, but remains non-specific and cannot reliably differentiate DFSP from other soft tissue tumors, making histopathological confirmation essential. DFSP is characterized histologically by a storiform proliferation of spindle cells with a “honeycomb” infiltration of fat and strong CD34 positivity. Treatment relies on wide local excision or Mohs surgery to ensure clear margins, with radiotherapy considered in selected cases, and long-term follow-up is required due to the risk of late local recurrence.



enlarging subcutaneous mass of the left lumbar region

Conclusion

Overall, this case highlights the diagnostic challenge posed by DFSP due to its slow evolution, misleading benign appearance, and deep localization, emphasizing the need for a high index of suspicion in any long-standing subcutaneous mass of the trunk.

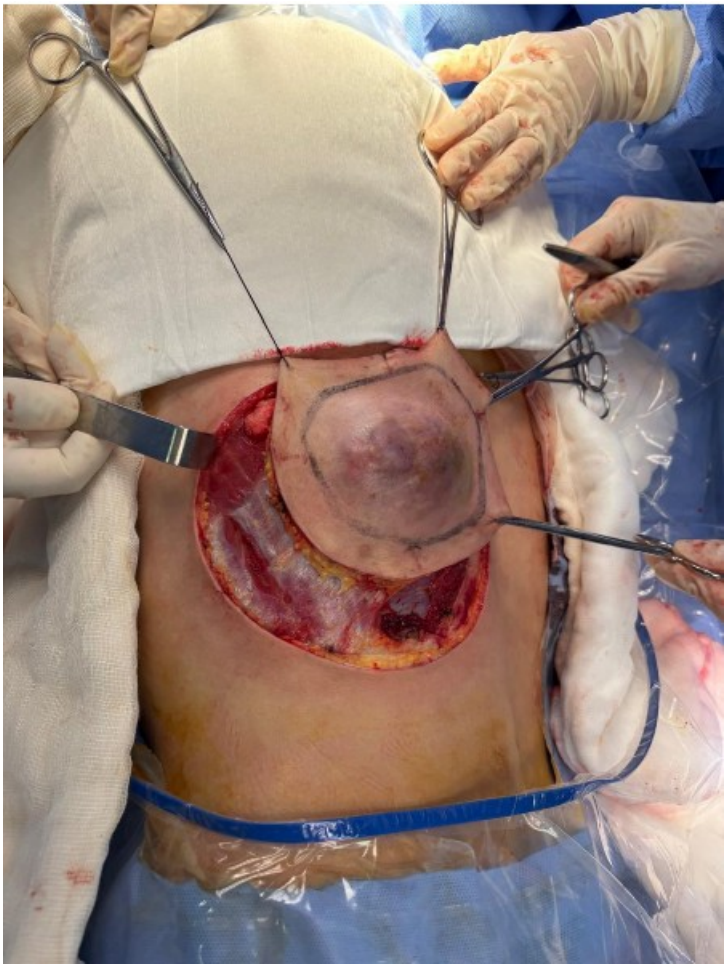

Excision of the lesion with 2 cm lateral margins.

EADV CONGRESS
VIENNA
30 SEP - 3 OCT 2026

Abstract N°: 2817

Atypical Classic Kaposi Sarcoma with Extensive Lymphadenopathy and Penile Localization in an HIV-negative Patient

Ana-Maria Țuțu*[1], Dan Mircioi[1], Kimberley Noel Pallourios[1], Mihaela Mănăilă[1], Andra Miu[1], Andra Dinu[1], Razvan Theodor Andrei[1, 2], Gabriela Turcu[1, 2]

[1] Colentina Clinical Hospital, Bucharest, Romania

[2] Carol Davila University of Medicine and Pharmacy, Bucharest, Romania

Introduction

Kaposi Sarcoma (KS) is a vascular neoplasm associated with human herpesvirus 8, including four clinical variants. The classic (sporadic) form typically affects elderly men of Mediterranean or Eastern European origin and usually follows an indolent course, with lesions predominantly confined to the lower extremities. Extracutaneous involvement and extensive lymphadenopathy are uncommon in this subtype. Although no universally accepted staging system exists for Kaposi sarcoma, current European guidelines propose the classification of patients into three clinical categories based on disease presentation and extent of involvement: localized non-aggressive, locally aggressive, and disseminated Kaposi sarcoma. In the classic form, imaging investigations are recommended according to symptoms and clinical findings rather than as part of routine evaluation.

Case Presentation

A 65-year-old European heterosexual male, HIV-negative, with no significant personal or family medical history, presented with few asymptomatic erythematous-violaceous papules and nodules on the right thigh, evolving over several months. The cutaneous lesions were associated with an exophytic tumor located on the glans penis.

We performed skin biopsy from a thigh lesion, which established the diagnosis of nodular-stage Kaposi sarcoma. Laboratory investigations showed no abnormal findings and particularly no clue to hematologic or immunologic disease. Computed tomography revealed iodophilic nodular cutaneous thickenings in the right thigh, accompanied by adjacent subcutaneous edema. Additionally, multiple enlarged lymph nodes were identified in the abdominal, pelvic, and supraclavicular regions. No pleuropulmonary, hepatic, or osseous involvement was detected.

Conclusion

This case highlights an atypical presentation of classic Kaposi sarcoma in an HIV-negative, immunocompetent patient, marked by extensive lymph node involvement, which is uncommon for this variant. The associated exophytic penile lesion represents a rare localization in classic disease. The discordance between the clinical presentation and disease course, which corresponded to a localized and non-aggressive form of classic Kaposi sarcoma, and the marked nodal dissemination identified on imaging studies suggests an atypical biological behavior. This finding highlights the importance of comprehensive systemic evaluation in selected cases.

EADV CONGRESS
VIENNA
30 SEP - 3 OCT 2026

Abstract N°: 2827

Frequency of antihypertensive use and subtypes of basal cell carcinoma: a descriptive study at a dermatology center in Colombia

Mariana Bracho-Romero[1], Jesus Daniel Fierro Lozada[2], Natalia Briceño-Patiño[1], David Castillo-Molina*[2]

[1] Universidad del Rosario, Bogotá, Colombia

[2] Fundación para la Investigación en Dermatología, Bogotá, Colombia

Introduction

Arterial hypertension and basal cell carcinoma (BCC) share more than a rising incidence. Long term antihypertensive management may have implications for the development and/or behavior of the tumor. Our objective is to describe the frequency of antihypertensive use in patients with BCC and according to histological subtype.

Materials and Methods

A descriptive study was conducted at a dermatology center in Colombia between 2015 and 2024. Data were obtained from medical records of patients with a confirmed diagnosis of BCC. Variables included sex, age, histological subtype of BCC, and the antihypertensive drugs families used. A univariate and bivariate analysis was performed. Variables were expressed as absolute and relative frequencies. Data was collected and analyzed in Microsoft Excel.

Results

Of 258 patients, 59.7% (n=154) were women. The most frequent age range was between 60 and 80 years. The median age was 69 years. Regarding histological subtypes, nodular was the most frequent (56.0%, n=205), followed by micronodular (20.5, n=75), trabecular (6.2%, n=63), and superficial (5.8%, n=15). A total of 59.3% (n=153) of patients were not using antihypertensives. Of the remaining patients 21.3% (n=55) were on monotherapy, 13.1% (n=34) on dual therapy, and 4.6% (n=12) were using more than two agents. Among patients on antihypertensive therapy, the most prevalent BCC subtype was nodular (82.9%, n=87), followed by micronodular (7.6%, n=8) and trabecular (4.8%, n=5). Within patients taking antihypertensives with the nodular subtype, the most frequent drug families were ARBs (63.2%, n=55), followed by calcium channel blockers (29.8%, n=26) and thiazides and beta-blockers (16.1%, n=14 each). ARBs were the most prevalent group in the micronodular and trabecular subtypes (40.4%, n=21 and 44.4%, n=8, respectively).

	BCC Subtype (n)				
Antihypertensive	Nodular	Trabecular	Superficial	Morpheaphorm	Micronodular
Thiazide diuretics	14	2	2	0	5
ACE inhibitors	12	2	0	0	5
Angiotension II receptor blockers	55	8	3	0	21
Beta-blockers	14	3	0	0	6
Calcium channel blockers	26	2	0	0	13
Loop diuretics	4	1	0	0	1
Alpha-blockers	2	0	0	0	1

Distribution of antihypertensive drug classes among patients with basal cell carcinoma, stratified by histological subtype. BCC: basal cell carcinoma

Conclusions

The data obtained regarding age group, median age, and histological subtype were consistent with those described in the literature. A female predominance was observed, which contrasts with other findings at the global level. Recent studies describe that the frequency reverses with age, being higher in premenopausal women and in older men. We found that the antihypertensives most frequently used by our population are not consistent with the available evidence, which suggests that antihypertensives that interfere with the renin-angiotensin-aldosterone axis may have a protective effect against BCC development, while thiazides and calcium channel blockers are associated with its occurrence. The literature reports that the risk of BCC in thiazide users is typically observed when used in combination therapy with other antihypertensives. We consider it necessary to study whether the use of these drugs has any influence on histological behavior, given that the distribution of subtypes could vary between users and non-users of antihypertensive agents. Regarding the more aggressive subtypes, it is important to conduct studies with larger samples that allow associations between the different drug families and the clinical course of the tumor to be identified. These results represent a starting point for the design of analytical studies in the Latin American population that would make it possible to establish whether the use or type of antihypertensive modifies the risk or histological behavior of BCC, since in this population skin phototypes and hypertension management differ from North American and European cohorts, from which the largest body of available evidence originates.

EA DV CONGRESS
VIENNA
30 SEP - 3 OCT 2026

Abstract N°: 2833

Epidemiologic Analysis of Associations of Geographic Residency and Socioeconomic Risk Factors with Cutaneous Merkel Cell Carcinoma Outcomes

Raj Fadadu*[1], Shang I Brian Jiang[1]

[1] University of California, San Diego (UCSD) Department of Dermatology, San Diego, United States

Introduction

Rural and urban residency status affects skin cancer risk through multiple mechanisms, including differences in environmental exposures and access to health care services. Prior studies on Merkel cell carcinoma (MCC) incidence and mortality and associations with geographic residency and other social determinants of health, such as sex, ethnicity, and insurance status, are limited in number and reported varying findings. We used a large, nationwide cancer research database to investigate the relationships between socioeconomic risk factors and outcomes related to MCC, particularly those related to surgery and staging.

Materials and Methods

We performed an epidemiologic cross-sectional study using data from the National Cancer Database (NCD). Data were collected from over 1,500 healthcare facilities in the United States that are accredited by the Commission on Cancer; it is a robust repository that contains clinical information (e.g., diagnosis, staging, and management) about MCC cases as well as the associated social and demographic information for each patient. Cases of pathology-confirmed cutaneous MCC recorded from 2004 - 2021 in the NCD were analyzed in this study. Patients diagnosed as AJCC Stage IV were excluded because surgery is not the initial treatment modality for these cases. For primary statistical analyses, we used multivariable logistic and linear regressions to assess associations between geographic residency (categorized as urban or rural) and several MCC-related clinical outcomes. Covariates included in analyses were age, sex, ethnicity, zip-code level income quartile, and insurance status. Significance was set at $p<0.05$ (JMP software v.19).

Results

A total of 20,795 cutaneous MCC cases were analyzed (**Table 1**). The mean age was 74.3 years (SD = 10.6 years; range = 21-90), and 13,093 (63%) participants were male and 7,702 (37%) were female. Only 325 (1.5%) participants lived in a rural area. For each increase in MCC grade category (from well differentiated to undifferentiated), there is 1.41 (95% CI: 1.03, 1.95) times the odds of a patient being from a rural area. Patients with positive regional lymph nodes were more likely to live in rural vs. urban areas: OR = 1.14 (95% CI: 1.12, 1.17). Female sex, compared to male sex, was associated with significantly lower odds of MCC lymphovascular invasion [OR = 0.95 (95% CI: 0.91, 1.0)] and higher odds of survival >90 days after surgery [OR = 1.12 (95% CI: 1.01, 1.26)]. Patients with private insurance had higher AJCC clinical staging for MCC though decreased time from diagnosis to surgery [3.0 days (95% CI: 0.72, 5.2)] and higher odds of survival >90 days after surgery: OR = 2.14 (95% CI: 1.38, 3.31). Black patients had higher AJCC clinical staging, higher odds of positive regional lymph nodes, and longer time from diagnosis to surgery than White patients.

Conclusions

In this large, nationwide cross-sectional study on MCC, several social determinants of health, such as rural residency, male sex, Black ethnicity, and public insurance, were associated with more severe clinical presentation with greater risk factors and worse surgical outcomes. These results demonstrate that socioeconomic factors should be integrated into public health and clinical interventions aiming to improve MCC morbidity and mortality as well as promote equitable cutaneous oncology outcomes.

Table 1. Study participants' information on demographics and clinical staging of Merkel cell carcinoma (N = 20,795).

Demographic or Clinical Variable	N (%) or Mean (Standard Deviation)
Age	74.3 years (10.6 years)
Sex	
Male	13,093 (63%)
Female	7,702 (37%)
Geographic Residency	
Urban	19,604 (93.5%)
Rural	325 (1.5%)
Unknown	866 (4.2%)
Median Household Income Quartile	
One	2076 (10%)
Two	3825 (18%)
Three	5052 (24%)
Four	6968 (34%)
Unknown	2874 (14%)
Insurance	
Public	15930 (77%)
Private	4460 (21%)
Uninsured	119 (0.57%)
Unknown	286 (1.4%)
Race	
White	20065 (96%)
Black	271 (1.3%)
Asian	152 (0.73%)
Pacific Islander	15 (0.072%)
Other	121 (0.58%)
Unknown	171 (0.82%)
AJCC Staging	
0	77 (0.37%)
1	9425 (45%)
2	3765 (18%)
3	7528 (36%)
Lymphovascular Invasion	
Present	3988 (19%)
Not Present	6876 (33%)
Unknown/Indeterminate	9931 (48%)
Regional Lymph Nodes	
Positive	6640 (32%)
Negative	7917 (38%)
Unknown	6238 (30%)

Table 1. Study participants' information on demographics and clinical staging of Merkel cell carcinoma (N = 20,795).

EADV CONGRESS
VIENNA
30 SEP - 3 OCT 2026

Abstract N°: 2834

Difuse large B cell lymphoma with secondary cutaneous involvement with exuberant skin lesions

Lais dos Santos*[1], Camila Rebel[1], Doménica Cerón Chimarro[1], Mayara Araújo Brilhante[1], Paula Figueiredo de Marsillac[1], David Souza[1], Ana VARGAS[1], Alexandre Gripp[1], Maria de Fátima Guimarães Scotellaro Alves[1]

[1] Universidade do Estado do Rio de Janeiro, Rio de Janeiro, Brazil

Introduction

Diffuse large B-cell lymphoma is the most common type of non-Hodgkin lymphoma, presenting diverse morphological patterns and heterogeneous clinical manifestations. Extranodal involvement is common, with the most common sites being the gastrointestinal tract and skin. Cutaneous involvement can be primary or secondary; primary involvement occurs when the disease is restricted to the skin, without involvement of other sites, usually presenting a better clinical course. In contrast, secondary skin involvement has a worse prognosis, being a sign of disease dissemination. Skin involvement can be due to hematogenous dissemination of neoplastic cells or by direct extension to the skin. Clinically, the patient may present with papules, nodules, plaques, or ulcers, frequently affecting the head, neck, and extremities. Diffuse large B-cell lymphomas show positive immunohistochemical staining for CD20, CD3, CD5, CD10, CD45, BCL-2, BCL-6, MUM-1, and CD30.

Case Presentation

A 66-year-old female patient presented with a history of cervical lymphadenopathy that began approximately 2 years prior, accompanied by unmeasured weight loss, asthenia, and night sweats. This progressed to dysphagia for both solids and liquids, as well as lymphadenopathy in the axillary and inguinal lymph nodes, and subsequently pleural effusion. One year after the onset of lymphadenopathy, nodules appeared on her lower limbs and abdomen, leading to a suspected diagnosis of sporotrichosis. Treatment with itraconazole was unsuccessful. Subsequently, the lesions became ulcerated. During hospitalization for further investigation, a skin biopsy revealed dermal lymphocytic infiltrate with atypical lymphocytes. Immunohistochemistry was positive for CD20, CD79, CD10, MUM-1, BCL2, and BCL6, and weakly positive for CD30. Diagnosed in conjunction with hematology as diffuse B-cell lymphoma with cutaneous involvement and disseminated lymphadenomegaly, evidenced on physical examination and imaging studies. Due to manifestations in other sites, the cutaneous lesions represent secondary skin involvement by diffuse B-cell lymphoma, with systemic diagnosis made from skin biopsy

Conclusion

This case illustrates secondary cutaneous involvement by diffuse large B-cell lymphoma with exuberant lesions. Extranodal involvement in non-Hodgkin lymphomas is not uncommon, with the skin being the second most frequent site. This case highlights the importance of dermatology in the diagnosis of systemic diseases, considering that the lymphoma diagnosis was made from a skin biopsy.

EA DV CONGRESS
VIENNA
30 SEP - 3 OCT 2026

Abstract N°: 2847

Cutaneous B-cell lymphoproliferative process following topical imiquimod treatment

Isabel Mateos Candelario*[1], Alberto Sáez Vicente[1], Cristina Rubio Flores[1], Luis Feito Sancho[1], Iolanda Prats Caelles[1], Jaime Mejías Bielsa[2]

[1] Servicio de Dermatología, Hospital Universitario Infanta Sofía, San Sebastián de los Reyes, Spain
[2] Servicio de Anatomía Patológica, Hospital Universitario Infanta Sofía, San Sebastián de los Reyes, Spain

Introduction

Imiquimod is a topical immunomodulatory agent widely used in dermatology for the treatment of superficial basal cell carcinoma, actinic keratosis, and intraepithelial neoplasms such as Bowen disease. Its mechanism of action is based on the activation of innate and adaptive immunity through Toll-like receptor 7 stimulation, leading to the release of proinflammatory cytokines and enhancement of cell-mediated immune responses. Although imiquimod is generally considered a safe and well-tolerated treatment, several inflammatory and immune-mediated adverse reactions have occasionally been reported. Rarely, the development of lymphoproliferative disorders temporally associated with topical imiquimod use has been described in the literature, mainly in the form of isolated case reports. We present a case of a cutaneous B-cell lymphoproliferative process arising after treatment with topical imiquimod.

Case Presentation

A 95-year-old woman with no relevant past medical history was followed in the Dermatology Department for multiple non-melanoma skin cancers previously treated surgically with histologically clear margins. In May 2025, she was referred for evaluation of persistent lesions located on the right nasal ala and the left temporal region. Skin biopsies revealed a multicentric superficial basal cell carcinoma on the right nasal ala and Bowen disease on the left temporal region. Topical treatment with 5% imiquimod cream was initiated for both lesions according to standard therapeutic protocols.

In November 2025, the patient presented with the rapid onset of multiple semi-solid infiltrated nodular lesions on the left frontal region, corresponding to areas previously treated with imiquimod. The treatment had been discontinued two weeks earlier because of marked local inflammatory reaction. Clinical examination demonstrated several erythematous-violaceous infiltrated nodules with rapid growth and firm consistency. Histopathological examination revealed a dense dermal infiltrate composed predominantly of B lymphocytes, raising suspicion of a systemic lymphoproliferative syndrome. Immunohistochemical studies supported the diagnosis of a B-cell lymphoproliferative process. A subsequent extension work-up, including systemic evaluation, showed no extracutaneous involvement. The lesions were therefore finally characterized as a primary cutaneous lymphoproliferative process. Interestingly, the lesions regressed spontaneously within six weeks without requiring additional treatment.

Conclusion

This case highlights a rare cutaneous lymphoproliferative process temporally associated with topical imiquimod therapy. Although the pathogenic relationship remains uncertain, the immunostimulatory effects of imiquimod may have contributed to the development of an abnormal lymphoid proliferation in a predisposed patient. The appearance of rapidly growing nodular or infiltrated lesions during or after treatment with imiquimod should prompt early histopathological evaluation in order to exclude malignant or lymphoproliferative conditions.

Awareness of this uncommon adverse event may facilitate earlier recognition and appropriate management.

EA DV CONGRESS
VIENNA
30 SEP - 3 OCT 2026

Abstract N°: 2857

COMPASS LLM: Comparing Patient and Physician Perspectives on Large Language Models (LLMs) usage in Dermato-Oncological care.

Carlos van Werde*[1, 2], Chiara L. Blomen[1, 2], Mareike Rutenkröger[3], Larissa Kölln[1], Inger Fischer[1, 2], Benjamin Deitert[1, 2], Laura Adam[1, 2], Sebastian Henkel[1, 4], Felix Rühl[5], Carmen Roeper[1, 2], Lisa Piepke[1], Alessandra Rünger[1, 2], Glenn Geidel[1, 2], Lina Hildebrandt[1], Nina Booken[1, 2], Stefan W. Schneider[1, 2], Katharina Kaminski[6], Astrid Doppler[6], Julian Kött[1, 2], Christoffer Gebhardt[1, 2]

[1] Department of Dermatology and Venereology, University Medical Center Hamburg-Eppendorf, Hamburg, Germany

[2] Fleur Hiege Center for Skin Cancer Research, University Medical Center Hamburg-Eppendorf, Hamburg, Germany

[3] Institute and Outpatient Clinic for Medical Psychology, University Medical Center Hamburg-Eppendorf, Hamburg, Germany

[4] Bundeswehrkrankenhaus Hamburg, Hamburg, Germany

[5] Krankenhaus Tabea, Hamburg, Germany

[6] Melanom Info Deutschland - MID e.V., Essen, Germany

Introduction

The increasing adoption of large language models (LLMs) in the general population raises the question of whether these technologies are already being used in the dermato-oncological setting. This study aims to systematically assess current usage patterns, acceptance, and concerns regarding LLMs among dermato-oncology physicians and skin cancer patients, to facilitate the responsible implementation of LLM-based applications in dermato-oncology.

Materials and Methods

In a multi-center cross-sectional study, skin cancer patients (target: n=200) and dermato-oncology physicians (target: n=100) are surveyed on LLM usage and attitudes using purpose-designed questionnaires (5-point Likert scales). Additionally, sociodemographic characteristics, preferences in medical decision-making (Control Preferences Scale), and technology affinity (ATI-S) are assessed. The analysis is primarily descriptive; inferential statistical methods are used in an exploratory manner.

Results

Recruitment has been ongoing since 02/2026. Preliminary data from 60 patients (mean age 60 years; 66% male; 59% melanoma) and 50 physicians (51% residents; 67% female) reveal a notable usage discrepancy: 78% of physicians use LLMs at least occasionally in their professional practice, whereas only 25% of patients use LLMs for disease-related information, despite 53% of physicians assuming such use among their patients. Physicians view LLMs primarily as an efficiency tool (98%), while patients see them as a means of accessing health information (50%). Both groups share concerns regarding misinformation (physicians 89%; patients 64%) and inaccuracy (physicians 71%; patients 77%). When LLM output

contradicts physician advice, 91% of patients trust their physician. Shared decision-making is preferred by both groups (physicians 82%; patients 68%).

Conclusions

Preliminary data indicates high physician adoption and acceptance of LLMs alongside more cautious patient usage. Both groups recognize the potential of LLMs but share concerns about information quality. The physician-patient consultation remains the central source of information for patients. These initial findings underscore the need for a critical evaluation of LLMs in dermato-oncology. Future analyses will explore the relationship between preferences for shared decision-making and LLM acceptance in the dermato-oncological context.

EADV CONGRESS
VIENNA
30 SEP - 3 OCT 2026

Abstract N°: 2860

Primary cutaneous B-cell lymphoma in patient with the history of osteosarcoma – case report

Marta Pośpiech*[1], Martyna Kiołbasa[1], Jolanta Smyk[1], Maciej Pastuszczak[1]

[1] Medical University of Silesia, Katowice, Szpital Specjalistyczny w Zabrzu, Zabrze, Poland

Introduction

Approximately 25% of all primary cutaneous lymphomas are B-cell lymphomas. Among primary cutaneous B-cell lymphomas (PCBCL) there are several distinct clinicopathologic entities, each with unique clinical features, immunophenotypic characteristics and molecular traits. The World Health Organization (WHO) classification of mature lymphoid neoplasm recognize indolent PCBCL which are Marginal Zone Lymphoma (MZL), Cutaneous Follicle Centre Lymphoma (CFCL) and lymphoid proliferations and lymphomas associated with immune deficiency and dysregulation. These three entities have a minimal risk of nodal, visceral or blood disease involvement. PCBCL with more aggresive behavior are primary cutaneous diffuse large B-cell lymphoma, leg type (PCDLBCL-LT) and intravascular large B-cell lymphoma (IVLBCL).
These relatively rare cases of PCBCL affect primarily white males and their incidence increases with age. Other risk factors that are mentioned in the literature are: chronic infections like Hepatitis C, Borrelia burgdorferi and EBV infection, autoimmune diseases and previous radio- or chemotherapy.

Case Presentation

A 33 years old patient with the history of reccurent osteosarcoma, treated with chemotherapy in 2007, 2014 and 2018, was admitted to the outpatient clinic due to two rapidly growing reddish nodules on the nose. The firm nodules appeared one month earlier and until the first appointment in the outpatient clinic they reached the diameter of 2 and 3 cm. The nodules were accompanied by slight periorbital edema. The patients did not report any other ailments. Laboratory investigation showed leukocytosis with limfocytosis, increased ferritin and LDH levels. Tests for Borrelia burgdorferi IgG and IgM antibodies were negative. Chest radiograph was clear. Cervical and axillary lymph nodes were assesed in the ultrasound examination as reactively enlarged. The punch biopsy of the nodule was taken. The histopathology report revealed the diagnosis of cutaneous B-cell lymphoma. The patient was reffered to the oncology clinic for futher immunohistochemical staging and futher treatment.

Conclusion

PCBCL are rare entities that require interdisciplinary diagnostic approach. Blood tests, body imaging and biopsy are required to establish a diagnosis. Although the disease is diagnosed mainly in erderly patients, previous chemotherapy may contribute to development of PCBCL in younger population.

EADV CONGRESS
VIENNA
30 SEP - 3 OCT 2026

Abstract N°: 2864

A rare case of Stewart-Treves syndrome

Sara Lupita O'Kelly*[1], Denis Bajramoski[1]

[1] East Kent Hospitals University NHS Foundation Trust, Canterbury, United Kingdom

Case Presentation

A 62-year-old woman with longstanding lymphoedema presented with a 3-month history of violaceous nodules on the left lower leg. Examination revealed a tender 30x28cm verroucous plaque with violaceous haemorrhagic nodules and background lymphoedematous changes. Incisional biopsy demonstrated a spindle cell dermal malignancy positive for CD31 and CD34, consistent with angiosarcoma. Imaging showed locally advanced disease without distant metastases. Following multidisciplinary discussion, she was referred to a tertiary sarcoma centre for consideration of excision with graft repair or amputation. Stewart–Treves syndrome is a rare, aggressive angiosarcoma arising in chronic lymphoedema, requiring prompt recognition and management to improve outcomes and reduce delay.[1,2]

EADV CONGRESS
VIENNA
30 SEP - 3 OCT 2026

Abstract N°: 2866

Primary Cutaneous Anaplastic Large Cell Lymphoma Arising During Pregnancy: An Unusual Clinical Presentation with an Indolent Course

Hanae Boumaaza*[1], Meryem Soughi[1], Hafsa Laouni[1], IKRAME BEJJA[1], Saadia Boughaleb[1], Zakia Douhi[1], Sara Elloudi[1], Hanane Baybay[1], Fatima Zohra Mernissi[1]

[1] Department of Dermatology, Hassan II University Hospital, FEZ, Morocco

Introduction

Primary cutaneous anaplastic large cell lymphoma (pcALCL) is a rare CD30-positive cutaneous T-cell lymphoproliferative disorder, accounting for approximately 9% of cutaneous T-cell lymphomas. It is generally characterized by an indolent clinical course and a favorable prognosis. pcALCL predominantly affects older adults, whereas occurrence in young patients is uncommon. In addition, disease onset during pregnancy is rarely reported and may represent a diagnostic challenge because of its atypical clinical presentation and prolonged evolution. This case underlines the importance of considering pcALCL in the differential diagnosis of chronic nodular lesions in young adults and highlights the pivotal role of dermatologists in establishing an early diagnosis and initiating appropriate management to optimize patient outcomes.

Case Presentation

A 22-year-old woman presented with mildly pruritic erythematous nodular lesions localized to the lower limbs. The lesions had evolved progressively over a period of three years, with initial onset occurring during her first pregnancy. The clinical course was slowly progressive, without associated systemic symptoms such as fever, weight loss, or night sweats. Dermatological examination revealed two erythematous nodules and one erythematous-violaceous plaque with a prominent telangiectatic surface, located on the posterior aspect of the thigh. The largest lesion measured 2.5 cm in diameter. Dermoscopic examination showed a diffuse erythematous background associated with polymorphous vascular structures, predominantly linear and dotted telangiectatic vessels. Diascopy did not reveal any lipoid or granulomatous features. A skin biopsy was performed. Histopathological examination, complemented by immunohistochemical analysis, confirmed the diagnosis of primary cutaneous anaplastic large cell lymphoma. The tumor cells expressed CD30, CD45, CD3, and CD2, with a high proliferative index (Ki-67 estimated at 90%). Systemic staging investigations were unremarkable, supporting the diagnosis of a primary cutaneous form without extracutaneous involvement. Localized radiotherapy was initiated, leading to favorable clinical improvement.

Conclusion

This case illustrates an unusual presentation of pcALCL in a young woman, with disease onset during pregnancy and a prolonged indolent course. Recognition of this entity is essential because pcALCL carries an excellent prognosis when accurately diagnosed and appropriately managed. Clinicopathological correlation remains crucial to distinguish pcALCL from other CD30-positive lymphoproliferative disorders and inflammatory dermatoses. Early recognition by dermatologists is fundamental to ensuring timely treatment and improving patient care.

EADV CONGRESS
VIENNA
30 SEP - 3 OCT 2026

Abstract N°: 2896

Basal cell carcinoma arising in a Marjolin ulcer of the lower eyelid: a rare case report

Zineb Aqasbi Ouahi*[1], Zakia Douhi[1], ikrame bejja[1], Saadia Boughaleb[1], Meryem Soughi[1], Sara Elloudi[1], Hanane Baybay[1], Fatima Zohra Mernissi[1, 1, 1]

[1] Department of Dermatology, Hassan II University Hospital, Fez, Morocco

Introduction
Marjolin's ulcer refers to malignant transformation arising within a chronic scar, most commonly presenting as squamous cell carcinoma (SCC). Basal cell carcinoma (BCC) arising in burn scars is rare, particularly in the periocular region. Chronic forms typically occur after a prolonged latency period and are mainly associated with SCC, whereas earlier presentations are more often linked to BCC. We report a rare case of lower eyelid BCC developing on a burn scar, highlighting the importance of long-term surveillance of chronic scars and early recognition of suspicious lesions.

Case Presentation
A 53-year-old female patient presented with a lesion of the left lower eyelid that had appeared four years after a hot-oil burn injury to the same area. Clinical examination revealed a pigmented ulcerated nodule with an infiltrated base, located on the lower eyelid. The main differential diagnoses included squamous cell carcinoma, melanoma, sebaceous carcinoma, and basal cell carcinoma. Dermoscopy demonstrated arborizing vessels, ovoid nests, blue-gray globules, scales, and structureless white areas, findings consistent with pigmented BCC. The patient underwent surgical excision with flap reconstruction. Histopathological examination confirmed nodular basal cell carcinoma with clear margins. The postoperative course was uneventful, with no evidence of recurrence.

Conclusion
This case illustrates the rare occurrence of basal cell carcinoma arising in a burn scar of the lower eyelid. The intermediate latency period and unusual periocular localization make this presentation exceptional. It emphasizes the need for prolonged surveillance of burn scars and systematic biopsy of any persistent or evolving lesion to ensure early diagnosis and appropriate management.

EA DV CONGRESS
VIENNA
30 SEP - 3 OCT 2026

Abstract N°: 2898

Ablative Fractional CO_2 Resurfacing for Refractory Scalp Field Cancerization and Multifocal Bowen's Disease: Durable Two-Year Remission Following Field-Directed Therapy

Kashika Sareen*[1], Dusan Sajic[2, 3, 4]

[1] University of British Columbia Department of Medicine, Vancouver, Canada

[2] McMaster University, Hamilton, Canada

[3] DermaSkin Institute, Guelph, Canada

[4] Guelph Dermatology Research, Guelph, Canada

Introduction

Actinic keratoses (AKs) arise within chronically ultraviolet-damaged skin and reflect a broader process of field cancerization involving genetically altered keratinocyte populations extending beyond clinically visible lesions. Conventional therapies such as cryotherapy and topical field agents can reduce lesion burden, however recurrence remains common in patients with extensive or biologically active disease. This likely reflects persistence of subclinical dysplastic keratinocytes within adnexal structures and the surrounding cutaneous field, which continue to support carcinogenesis despite repeated superficial treatments. Ablative fractional CO_2 ($AFCO_2$) laser resurfacing offers a mechanistically distinct approach through controlled depth-dependent ablation extending into the superficial dermis, with potential to more comprehensively disrupt the diseased field.

Case Presentation

A 60 year old male with chronic sun exposure and prior cutaneous squamous cell carcinoma presented with longstanding recurrent AKs involving the frontal and vertex scalp. Between 2020 and 2023, serial biopsies demonstrated recurrent AKs including hypertrophic variants despite repeated treatment with cryotherapy, topical fluorouracil, diclofenac sodium, serial shave excisions with electrodessication and curettage, retinoids, antioxidants, and corticosteroids. In December 2023, extensive shave biopsies revealed multifocal Bowen's disease involving multiple scalp regions. Given progressive disease despite prolonged treatment, the patient underwent field-directed $AFCO_2$ laser resurfacing over three sessions between February and May 2024. Treatment utilized high-density, multi-pass ablative settings with energies ranging from approximately 110-140 W and density between 30-60%, adjusted according to regional disease severity. The final session incorporated adjunctive methyl aminolevulinate photodynamic therapy immediately following laser treatment.

Treatment was well tolerated with expected post-procedural erythema, edema, and mild discomfort. Progressive clinical improvement was observed throughout follow-up, with resolution of previously identified lesions and marked reduction in background actinic change. At 4- and 7-month follow-up, treated areas were well healed with minimal residual findings. At long-term assessment in March 2026, approximately two years following $AFCO_2$ resurfacing, there was no clinical evidence of recurrent Bowen's disease. Only a small number of isolated AKs remained and were managed with focal cryotherapy.

Conclusion

This case highlights the limitations of repeated superficial and lesion-directed therapies in advanced field cancerization and supports $AFCO_2$ laser resurfacing as a deeper field-modifying intervention capable of achieving sustained disease control. Unlike conventional topical therapies largely confined to the epidermis, $AFCO_2$ creates microscopic columns of ablation extending into the superficial dermis, enabling disruption of dysplastic keratinocyte reservoirs within both the interfollicular epidermis and adnexal units. In parallel, laser-induced wound healing promotes dermal remodeling and re-epithelialization from adjacent viable keratinocytes, potentially contributing to normalization of the local cutaneous microenvironment. The durable remission observed in this patient suggests that deeper ablative approaches may offer more meaningful long-term control in refractory field cancerization by addressing the underlying biologic field rather than isolated clinical lesions alone.

EADV CONGRESS
VIENNA
30 SEP - 3 OCT 2026

Abstract N°: 2899

The Evaluation of Skin Infiltration in Mycosis Fungoides/Sézary Syndrome Using the High-Frequency Ultrasonography

Hanna Cisoń*[1], Alina Jankowksa-Konsur[1], Rafał Białynicki-Birula[2]

[1] University Centre of General Dermatology and Oncodermatology, Wroclaw Medical University, 50-556 Wroclaw, Poland, Wrocław, Poland

[2] Faculty of Medicine, Wroclaw University of Science and Technology, 50-370 Wroclaw, Poland, Wrocław, Poland

Introduction
High-frequency ultrasonography (HFUS) has gained increasing attention in dermatology as a non-invasive imaging technique capable of visualizing cutaneous structures with high resolution. In cutaneous T-cell lymphomas (CTCL), including mycosis fungoides (MF)/Sézary syndrome (SS), HFUS may provide an objective method for assessing disease activity and monitoring treatment response. This study aimed to evaluate the clinical utility of HFUS in detecting therapy-induced changes in subepidermal low-echogenic band (SLEB) thickness.

Materials and Methods
We conducted a prospective, single-center study between May 2021 and May 2025. Thirty-three patients with histologically confirmed MF (n = 31) or SS (n = 2) underwent HFUS at baseline and after 4–8 weeks of treatment. SLEB thickness was measured before (E1) and after early treatment (E2). Patients received systemic agents, phototherapy, or topical regimens. Statistical analysis included mixed-model ANOVA with repeated measures to assess SLEB changes, and post hoc tests were applied to explore the influence of therapy type, age, and gender.

Results
Among 31 evaluable patients with MF, HFUS revealed a significant reduction in SLEB thickness after treatment (0.90 ± 1.10 mm vs. 0.69 ± 0.89 mm; $F(1,29) = 8.88$, $p = 0.006$, $\eta^2 = 0.23$). The type of early therapy (systemic vs. topical) did not significantly affect outcomes ($p = 0.452$). Age emerged as a relevant factor: patients ≥ 66 years exhibited higher baseline SLEB values and a significant reduction post-treatment ($p < 0.001$), whereas no comparable effect was observed in younger patients. Gender did not significantly influence SLEB changes.

Conclusions
HFUS is a sensitive and clinically applicable imaging tool for monitoring treatment response in MF/SS. Reductions in SLEB thickness were observed across therapeutic modalities and aligned with early clinical improvement. HFUS may serve as a valuable adjunct to standard clinical and histopathological evaluation in the routine management of MF/SS.

EADV CONGRESS
VIENNA
30 SEP - 3 OCT 2026

Abstract N°: 2904

IMPACT OF NEOADJUVANT IMMUNOTHERAPY IN RESECTABLE ADVANCED MELANOMA: A CASE REPORT.

MARIA BEATRIZ LIRA DO O ESPOSITO*[1], Carolina Siqueira Varotto Martins[1], JOÃO GARCIA DA ROCHA NETO[1], Camila Gouvea Facure[1], EDUARDA LUISA ROCHA CORTI[1], Carolina Lourenço dos Santos Landini Freitas[1], Juliana Arêas de Souza Lima Beltrame Ferreira[1], Clovis Antonio Lopes Pinto[1]

[1] Faculdade de Medicina de Jundiaí, Jundiaí, Brazil

Introduction

Advanced cutaneous melanoma presents a high metastatic potential and a poor prognosis. Despite therapeutic advances with adjuvant immunotherapy and targeted therapy, recurrence still occurs in a significant proportion of patients. In this context, neoadjuvant therapy has emerged as a promising strategy, allowing early control of micrometastases, tumor reduction before surgery, and potential improvement in oncological outcomes. Here we present a case of stage 3 cutaneous melanoma, highlighting the value of neoadjuvant therapy and a multidisciplinary approach.

Case Presentation

A 61-year-old male patient presented with a scalp lesion that had been rapidly growing for approximately nine months, associated with the appearance of a left cervical nodule about one month after the skin lesion appeared.
On physical examination, a bluish-gray tumor measuring approximately 4.5 × 4.5 cm was observed in the left occipital region, associated with left cervical lymphadenopathy of approximately 5 cm.
An incisional biopsy guided by dermatoscopy of the skin lesion was performed. The histopathological examination revealed unclassifiable melanoma, Clark level V, Breslow of 8.0 mm, without ulceration, and a mitotic index of 1.25 mitoses/mm^2.
Fine needle aspiration biopsy (FNAB) of the cervical lymph node was consistent with melanoma metastasis.
Neoadjuvant treatment with a PD-1 checkpoint inhibitor was chosen. After six cycles of immunotherapy, PET-CT showed a reduction in hyperuptake of the left posterior parietal lesion and left cervical lymph nodes.
Subsequently, the patient underwent surgical excision of the scalp lesion associated with cervical lymph node dissection, maintaining follow-up with adjuvant targeted therapy. The final histopathological report was compatible with nodular malignant melanoma, Breslow size of 2.3 cm, mitotic index of 4 mitoses/mm^2, ulceration present, and a satellite nodule measuring 6 mm. Postoperative PET-CT showed an absence of hypermetabolic areas suggestive of active neoplastic disease. The patient continues under multidisciplinary follow-up one year after surgery without signs of recurrence.

Conclusion

Patients with stage III cutaneous melanoma have a poor prognosis when treated exclusively with surgery, with a 5-year overall survival rate of less than 50%. Although checkpoint inhibitors and adjuvant targeted therapies have significantly reduced the risk of recurrence, recurrence rates exceeding 30% are still observed in the first two years after surgical treatment.
Neoadjuvant therapy has emerged as a tool to optimize disease control before surgery, promoting early eradication of micrometastases in a more immunosensitive environment, enabling less extensive surgical procedures and reducing the risk of metastatic dissemination. In addition, it allows for the evaluation of tumor response and the identification of prognostic and predictive biomarkers.

Checkpoint inhibitors promote early activation of tumor-specific T lymphocytes while the tumor antigen is still present, providing a more robust and lasting immune response.

A study demonstrated a significant benefit of neoadjuvant pembrolizumab compared to adjuvant therapy alone, with a two-year event-free survival of 72% versus 49%, consolidating the paradigm shift in melanoma treatment.

The case presented shows a significant clinical and metabolic response after neoadjuvant immunotherapy, followed by surgical approach and adjuvant therapy, reinforcing the potential of this strategy in the management of advanced resectable melanoma.

EA DV CONGRESS
VIENNA
30 SEP - 3 OCT 2026

Abstract N°: 2910

Clinicopathologic differences according to anatomical location in acral melanoma: a retrospective single-center study

Elisabetta Magnaterra*[1], Federico Venturi[1], Biagio Scotti[1], Emy Dika[1]

[1] Department of Medical and Surgical Sciences (DIMEC), University of Bologna, Oncologic Dermatology Unit, IRCCS Azienda Ospedaliero-Universitaria di Bologna, 40138 Bologna, Italy., Bologna, Italy

Introduction
Acral melanoma represents a distinct subset of cutaneous melanoma arising on glabrous skin and within the nail unit. Although generally considered a single entity, melanoma arising on acral sites may show significant heterogeneity according to anatomical location. The aim of this study was to investigate the impact of anatomical site on the clinicopathologic features of acral melanoma.

Materials and Methods
We retrospectively analyzed 183 patients with melanoma arising on acral sites diagnosed at a tertiary referral center for skin cancer. Cases were stratified into soles and palms (n=56), dorsum of the hands and feet (n=47), and nail unit melanoma (n=80). Clinical and pathological variables included age at diagnosis, Breslow thickness, histologic subtype, growth phase, cytological pattern, pT stage, and other prognostic variables. Continuous variables were analyzed using non-parametric tests and categorical variables using chi-square tests with multiple-testing correction.

Results
Significant differences emerged across anatomical groups. Patients with dorsum melanoma were younger at diagnosis compared with those with soles/palms and nail unit melanoma (median age 53.0 vs 66.0 and 62.5 years, respectively; $p=0.014$). Breslow thickness also differed significantly, with dorsum lesions showing the lowest median thickness (0.4 mm) compared with soles/palms (1.2 mm) and nail unit melanoma (0.7 mm) ($p<0.001$). Histologic subtype distribution varied markedly according to anatomical location. Superficial spreading melanoma predominated in the dorsum group (83.3%), whereas acral lentiginous melanoma represented the most frequent subtype in soles/palms lesions (61.5%). Nail unit melanoma showed the highest proportion of nodular melanoma (30.2%). Growth phase distribution differed significantly across groups. Radial growth phase lesions were particularly common on the dorsum (80.0%), whereas vertical growth phase predominated in soles/palms (58.3%) and nail unit melanoma (51.7%). Tumor stage distribution also differed significantly according to anatomical location. Dorsum melanomas were predominantly early-stage tumors, with 73.9% classified as T1 lesions. In contrast, soles/palms melanomas demonstrated a greater burden of advanced disease, with 35.2% of cases classified as T3–T4. Nail unit melanoma showed a heterogeneous pattern, characterized by both the highest proportion of melanoma in situ lesions (38.3%) and a substantial representation of advanced tumors. Substage analysis further highlighted these differences, with dorsum melanoma largely composed of pT1a lesions and soles/palms lesions more frequently including ≥pT2 tumors and pT4b stages.

Conclusions
Overall, our findings demonstrate that melanoma arising on acral sites encompasses distinct clinicopathologic phenotypes according to anatomical location. Dorsum lesions appear less aggressive at presentation, with thinner tumors and earlier stages, whereas soles and palms are associated with more advanced disease and predominance

of vertical growth. Nail unit melanoma shows marked heterogeneity, including both early and advanced presentations. These observations suggest that anatomical location may reflect not only differences in diagnostic timing, but also underlying biological heterogeneity within acral melanoma. Improved recognition of these site-specific patterns may contribute to earlier diagnosis, optimized surveillance strategies, and more accurate risk stratification in patients with melanoma arising on acral sites.

EADV CONGRESS
VIENNA
30 SEP - 3 OCT 2026

Abstract N°: 2923

Pattern and Clinical Impact of Immune-Related Adverse Events in Adjuvant Melanoma: A Real-World Study

MARIA LUISA SUAREZ RIZKALLAL*[1], ELENA CASTRO GONZALEZ[1], Pedro Naranjo Álamo[1], Ana Rebolledo Ruiz[1], Javier Sánchez Gutiérrez[1], Irene Castaño González[1]

[1] HUGCDN, Las Palmas de Gran Canaria, Spain

Introduction
Adjuvant immunotherapy has significantly improved outcomes in advanced melanoma. Emerging evidence suggests that immune-related adverse events (irAEs) may be associated with treatment efficacy. This study explores the incidence of irAEs and their potential prognostic value for recurrence-free survival (RFS).

Materials and Methods
We performed a retrospective observational analysis of patients with stage IIB–IV (M1a) melanoma treated with adjuvant immunotherapy between October 2018 and 2025. Data collected included demographic characteristics, tumor features (histology, stage, Breslow thickness, ulceration, BRAF status), treatment details, and irAE characteristics (type, grade according to CTCAE v5, time to onset). RFS was estimated using Kaplan–Meier curves and evaluated with Cox proportional hazards models.

Results
Among 79 patients, 59.5% developed irAEs. Most events were mild to moderate, with 6 grade 3 and 1 grade 4 irAEs, and no treatment-related deaths. Endocrine toxicities were the most common (21.5%), followed by cutaneous (12.7%) and rheumatologic (10.1%), with a median onset of 17.5 weeks. Patients experiencing irAEs showed improved RFS compared to those who did not (p=0.016). This benefit was primarily driven by grade 1–2 irAEs, whereas severe events did not confer the same advantage (p=0.002). In multivariate analysis, absence of irAEs was independently associated with a higher risk of progression (HR=3.05; p=0.008).

Conclusions
The development of mild to moderate irAEs during adjuvant immunotherapy is associated with improved recurrence-free survival in advanced melanoma. Conversely, the absence of irAEs identifies patients at increased risk of progression, supporting their role as a potential predictive biomarker of treatment benefit.

EADV CONGRESS
VIENNA
30 SEP - 3 OCT 2026

Abstract N°: 2927

INVASIVE MELANOMA ARISING ON A PREVIOUS BASAL CELL CARCINOMA SCAR TREATED WITH VISMODEGIB: A CASE REPORT

Asier Viciana Tarife*[1], Miguel Quetglas Valenzuela[1], Daniel Javier Sánchez Báez[1], Carmen Miguelez Sánchez[1], Maria Luísa Santos e Silvia Caldeira Marques[1], Rosa Nieves Rodríguez Rodríguez[1], Isa Gara Guillén Morales[1], Alba García Carceller[1], Ana de Andrés del Rosario[1]

[1] Hospital Universitario de Canarias, San Cristóbal de La Laguna, Spain

Introduction

The development of melanoma arising on a scar from basal cell carcinoma (BCC) previously treated with vismodegib represents a diagnostic challenge that has not been previously described. Although this drug has been associated with an increased risk of cutaneous squamous cell carcinoma (cSCC), there is currently no evidence suggesting an increased risk of melanoma. We report the first documented case of this association.

Case Presentation

A 62-year-old woman with a significant medical history of marginal zone non-Hodgkin lymphoma treated with six cycles of R-bendamustine and currently in complete remission, as well as a large (>10 cm), ulcerated infiltrative basal cell carcinoma located on the frontal scalp, successfully treated with vismodegib 150 mg daily for 8 months, was evaluated during follow-up.

A faint, poorly demarcated macule with regular borders was identified at the superior edge of the scar. Biopsy revealed scar-related changes secondary to treatment with Hedgehog (HH) pathway inhibitors.

Given these findings, close follow-up was established. Ten months after completion of treatment, progressive enlargement of the lesion was observed. The macule became heterochromic and showed rapid growth, reaching approximately 4.5 × 1 × 0.4 cm. Dermoscopy revealed a thickened pigment network in the central area, linear projections, regression structures, and white shiny areas.

A skin biopsy was performed, showing a non-ulcerated superficial spreading melanoma in vertical growth phase with a Breslow thickness of 0.8 mm (pT1b).

According to current scientific evidence, no association has been established between treatment with HH pathway inhibitors and an increased risk of melanoma. The second malignancy most significantly associated with this drug is cutaneous squamous cell carcinoma (cSCC).

A case-control study conducted at Stanford University (55 exposed patients vs. 125 controls) demonstrated that patients treated with vismodegib had a hazard ratio (HR) of 6.37 (95% CI: 3.39–11.96; $p < 0.001$) for the development of non-BCC malignancies. However, no significant increase was observed in other cancer types, including melanoma.

Paradoxically, HH-GLI signaling is active in melanoma and is required for melanoma proliferation, survival, and tumor stem cell self-renewal. Multiple preclinical studies have demonstrated that inhibition of smoothened (SMO), the molecular target of vismodegib, reduces melanoma growth both in vitro and in vivo.

The coexistence of BCC and melanoma may be explained by three mechanisms: (1) colonization of BCC by melanoma, (2) basomelanocytic tumor (dual differentiation from a common progenitor cell), or (3) collision tumor (two independent neoplasms).

The characteristics of the present case support the diagnosis of a collision tumor:

1. Sequential temporal development of melanoma after treatment of the basal cell carcinoma.
2. Presence of two histologically distinct cell populations with different immunohistochemical profiles (atypical melanocytes S-100+/HMB-45+ versus basaloid cells).
3. Absence of intimate admixture between both tumor components.



Pigmented macule with defined borders and multicomponent pattern arising on a previous basal cell carcinoma scar treated with vismodegib

Conclusion

We report the first case described in the literature of melanoma arising on the scar of a previously infiltrative BCC treated with vismodegib. This finding highlights the importance of close dermoscopic surveillance of scarred areas in patients undergoing treatment with HH pathway inhibitors, with histopathological evaluation recommended in the presence of morphological changes or newly appearing pigmented lesions.



Pigmented macule with a multicomponent pattern. Presence of a thickened pigment network in the superolateral area, white shiny areas, linear projections, and a central regression area.

EADV CONGRESS
VIENNA
30 SEP - 3 OCT 2026

Abstract N°: 2931

Behind a keloid: an unexpected mycosis fungoides

assia zenagui*[1], Latifa abdelmoumen[1], I Mahi[1], B dahmani[1], F Dedouche[1], S berrichi[1]

[1] CHU Dr Tidjani Damerdji of Tlemcen, Faculty of Medicine, Tlemcen, Algeria

Introduction

Mycosis fungoides is the most common cutaneous T-cell lymphoma, characterized by marked clinical heterogeneity. While classic forms are well established, certain rare variants may mimic benign dermatoses, significantly delaying diagnosis. Hypertrophic or fibrotic presentations with a keloid-like appearance represent an exceptional and still poorly described entity, posing a real diagnostic challenge. We report a rare case of mycosis fungoides with a keloid-like presentation.

Case Presentation

We report the case of a 45-year-old woman with no significant medical history, presenting with hypertrophic cutaneous lesions of pseudo-keloidal appearance arising with no prior history of trauma. Four lesions were noted, located on bilateral shoulders, the inguinal folds, and the gluteal region.

The patient had had consulted multiple times and received topical corticosteroids as well as monthly intralesional injections of triamcinolone, with transient partial remission followed by recurrences occurring a few months after treatment discontinuation.

Given the persistence and atypical features of the lesions, a skin biopsy was performed. Histopathological examination revealed an atypical lymphocytic infiltrate with epidermotropism, consistent with a diagnosis of mycosis fungoides.
discussion :

Mycosis fungoides is characterized by significant clinical heterogeneity, often mimicking various benign dermatoses, which can lead to prolonged diagnostic delays. So-called 'keloid-like' or hypertrophic presentations of mycosis fungoides are exceptionally rare in the literature. These forms are characterized by marked dermal fibrosis associated with an atypical lymphocytic infiltrate, giving the lesions a firm, indurated appearance that simulates keloids or hypertrophic scars. Our case illustrates a misleading clinical presentation of mycosis fungoides and underscores the importance of rigorous clinico-pathological correlation to prevent diagnostic delay.

Conclusion

Mycosis fungoides may exceptionally present as pseudo-keloidal lesions, posing a significant diagnostic pitfall. This case highlights the importance of considering cutaneous lymphoma in any atypical hypertrophic lesion with an unusual clinical course.

EA DV CONGRESS
VIENNA
30 SEP - 3 OCT 2026

Abstract N°: 2959

Proliferating Trichilemmal Tumors of the scalp : A Comparative Analysis With Squamous Cell Carcinoma

Hiba Essolaymany*[1], Sara Elloudi[1]

[1] CHU HASSAN II, FES, Morocco

Introduction

Proliferating trichilemmal tumors (PTTs) are uncommon adnexal tumors arising from the isthmic portion of the external epithelial sheath of the hair follicle. They are often confused with squamous cell carcinoma (SCC). The lack of distinguishing features reported in the literature prompted us to conduct this study, aiming to establish well-difined criteria for PTT, compared with SCC, its main differential diagnosis.

Materials and Methods

We included all patients admitted to our dermatology department between 2019-2025, who were diagnosed with scalp PTT and SCC through histopathological examination. We conducted a case–control study including two distinct groups. The case group consisted of 30 PTTs and the control group included 30 cases of SCC. Keratoacanthoma and basosquamous carcinoma were excluded. Comparisons between groups were performed using the Chi-square test or Fisher's exact test for categorical variables, and Mann–Whitney U test for continuous variables. A p-value < 0.05 was considered statistically significant. Other outcome measures included sensitivity, specificity, as well as positive predictive value and negative predictive value of the different features identified in each group.

Results

Significant features of PTTs (all $p < 0.05$) included : female sex, personal or family history of trichilemmal cysts, normal hair density, associated trichilemmal cysts on the scalp, recent rapid growth of an old pre-existing trichilemmal cyst, tumor with smooth surface and focal ulceration, violet-red to yellowish-pink color lesion. Dermoscopic structures of PTTs with statistical significance and discriminative ability included: Arborizing vessels, yellow backround, blue-violet hue and milky white clods. Trichilemmal keratinization and presence of calcifications represented the most specific histopathological finding (100%) Rapid growth, size bigger than 5 cm, ulceration and tumor necrosis were highly predictive of malignancy. Significant features of SCC (all $p < 0.05$) included male sex, older age (74,7 +/- 12 years), general condition deterioration, chronic sun exposure with skin actinic damage, severe androgenetic alopecia, slow growth of the tumor over several years, ulcerative exophytic tumor with a purulent surface. Highest specificity dermoscopic features of SCC comprised: milky red areas, glomerular vessels, white circls, keratin plugs and white scales. Unexpectedly , hairpin vessels surrounded by whitish halo are not specific of SCC as they were also observed in 54,5% of PTTs, as well as rosettes and rainbow pattern.

Conclusions

PTT was first recognized in 1966 as an entity that had major capacity to simulate squamous cell

carcinoma. The most descriminative dermoscopic features of PTTs appear to reflect the underlying histopathological findings. The arborizing vessels correspond to the dilation of superficial dermal vessels. Atrophic epidermis, subepidermal fibrosis and calcifications are consistent with shiny white areas. A large area of thrombosis or necrosis in the upper part of the nodule corresponds to the purple hue. The multiple shades of yellow in the background correspond to keratin mass which varies in size due to trichilemmal keratinisation in the dermal lobules. Degree of mitotic activity, atypia, and stroma invasion varies in PTTs, making them indistinguishable from SCC. The criteria for malignancy have been widely discussed in the literature, and based on histological features, these tumors have been classified into three groups: benign, locally aggressive, and malignant. Unlike SCC, very few data have been published regarding PTTs and reported features are based only on few isolated case reports. Our analytic study indicated that some clinical and dermoscopic signs are sufficiently specific to make distinguishing PTTs from SCC easier. Further studies are warranted to support our findings.

EA DV CONGRESS
VIENNA
30 SEP - 3 OCT 2026

Abstract N°: 2967

Behind a keloid: an unexpected mycosis fungoides

assia zenagui*[1], Latifa abdelmoumen[1], ilhem mahi[1], boumedienne dahmani[1, 1], F Dedouche, F Dedouche

[1] CHU Dr Tidjani Damerdji of Tlemcen, Faculty of Medicine, Tlemcen, Algeria

Introduction
Mycosis fungoides is the most common cutaneous T-cell lymphoma, characterized by marked clinical heterogeneity. While classic forms are well established, certain rare variants may mimic benign dermatoses, significantly delaying diagnosis. Hypertrophic or fibrotic presentations with a keloid-like appearance represent an exceptional and still poorly described entity, posing a real diagnostic challenge. We report a rare case of mycosis fungoides with a keloid-like presentation.

Materials and Methods
Case report
We report the case of a 45-year-old woman with no significant medical history, presenting with hypertrophic cutaneous lesions of pseudo-keloidal appearance arising with no prior history of trauma. Four lesions were noted, located on bilateral shoulders, the inguinal folds, and the gluteal region. The patient had had consulted multiple times and received topical corticosteroids as well as monthly intralesional injections of triamcinolone, with transient partial remission followed by recurrences occurring a few months after treatment discontinuation.

Given the persistence and atypical features of the lesions, a skin biopsy was performed. Histopathological examination revealed an atypical lymphocytic infiltrate with epidermotropism, consistent with a diagnosis of mycosis fungoides.

Results
Discussion :

Mycosis fungoides is characterized by significant clinical heterogeneity, often mimicking various benign dermatoses, which can lead to prolonged diagnostic delays. So-called 'keloid-like' or hypertrophic presentations of mycosis fungoides are exceptionally rare in the literature. These forms are characterized by marked dermal fibrosis associated with an atypical lymphocytic infiltrate, giving the lesions a firm, indurated appearance that simulates keloids or hypertrophic scars. Our case illustrates a misleading clinical presentation of mycosis fungoides and underscores the importance of rigorous clinico-pathological correlation to prevent diagnostic delay.

Conclusions
Mycosis fungoides may exceptionally present as pseudo-keloidal lesions, posing a significant diagnostic pitfall. This case highlights the importance of considering cutaneous lymphoma in any atypical hypertrophic lesion with an unusual clinical course.

EADV Congress 2026, VIENNA
30 SEPTEMBER - 03 OCTOBER 2026
POWERED BY M-ANAGE.COM

EA DV CONGRESS
VIENNA
30 SEP - 3 OCT 2026

Abstract N°: 2968

" PREGNANCY – ASSOCIATED MELANOMA : DIAGNOSTIC DELAY AND TARGETED MANAGEMENT OF A BRAF-MUTATED POLYPOID MELANOMA"

Stesi Bani*[1], Artur Bani[2], Andi Bani[3]

[1] Department of Dermatology , University Hospital Centre " Mother Theresa" , University of Medicine of Tirana, Department of Dermatology ,Berat Regional Hospital , Berat , Albania, Private Clinic " Art DermaMed A & S", Tirana, Albania

[2] Department of Dermatology , University Hospital Centre " Mother Theresa" , University of Medicine of Tirana, Department of Dermatology ,Berat Regional Hospital , Berat , Albania, Private Clinic " Art DermaMed A & S", Berat, Albania

[3] Art DermaMed A & S, Private Clinic " Art DermaMed A & S", Berat, Albania

Introduction

Pregnancy-associated melanoma (PAM), defined as melanoma diagnosed during pregnancy or within one year postpartum, represents the most frequently reported malignancy occurring during gestation. Physiological hormonal, vascular, and pigmentary skin changes during pregnancy may obscure early malignant transformation, potentially contributing to diagnostic delay. Although current evidence suggests that pregnancy does not intrinsically worsen melanoma prognosis, delayed diagnosis remains a key determinant of advanced-stage disease at presentation.

Case Presentation

A 37-year-old woman with Fitzpatrick phototype II reported asymmetry and progressive darkening of a pre-existing nevus located on the abdominal region during the sixth month of pregnancy. Dermatological evaluation was not performed until one year postpartum, when the lesion had evolved into a rapidly enlarging and bleeding nodular tumor. Dermoscopic examination revealed peripheral remnants of brown-black dots and globules, prominent milky-red areas, polymorphous vascular structures (dotted and irregular linear vessels), and central ulceration, findings suggestive of an aggressive melanocytic neoplasm. Complete surgical excision was performed.Macroscopic examination demonstrated a nodular exophytic mass measuring 1.2 cm, within a skin excision specimen measuring 2 × 1.5 × 0.5 cm. Histopathological analysis confirmed malignant melanoma of superficial spreading type with polypoid architecture, composed predominantly of epithelioid tumor cells. The tumor exhibited Clark level IV invasion, Breslow thickness of 4.1 mm (pT4b), and ulceration measuring 9 mm, with a high mitotic rate of 10 mitoses/mm^2. Intratumoral lymphocytic infiltrate (TIL) was present but non-brisk, and tumor pigmentation was scarce, consistent with the clinically erythematous appearance. Molecular profiling identified a BRAF V600E mutation, while PD-L1 expression was low (TPS 1–49%). Given the high-risk pathological features and molecular profile, adjuvant targeted therapy with dabrafenib and trametinib was initiated.

Conclusion

Hypomelanotic or polypoid melanomas may clinically mimic benign vascular lesions such as pyogenic granuloma, particularly in the context of pregnancy-related vascular and pigmentary changes. Dermoscopic features including polymorphous vessels and milky-red areas represent critical diagnostic clues that should prompt immediate excision. This case highlights the potential consequences of delayed evaluation of evolving melanocytic lesions

during pregnancy and emphasizes that biopsy and surgical excision under local anesthesia are safe throughout gestation. Early recognition, histopathologic assessment, and molecular profiling are essential to ensure timely diagnosis and enable personalized targeted therapy in mutation-positive melanoma.

EADV CONGRESS
VIENNA
30 SEP - 3 OCT 2026

Abstract N°: 2970

Multiple Prior Cutaneous Squamous Cell Carcinomas Are Associated With Increased Risk of Metastatic Progression in Advanced Cutaneous Squamous Cell Carcinoma

Federico Venturi*[1], Emy Dika[1]

[1] Università di Bologna, Department of Medical and Surgical Sciences, Bologna, Italy

Introduction
Current risk stratification for cutaneous squamous cell carcinoma (cSCC) is primarily based on tumor-specific features, while the role of cumulative tumor burden remains unclear. With this study, we aimed to evaluate whether prior cSCC multiplicity is associated with metastatic progression in patients with advanced cSCC.

Materials and Methods
We conducted a retrospective cohort study including 425 consecutive patients with advanced cSCC diagnosed between 2017 and 2025. Prior tumor burden was defined as the number of histologically confirmed cSCCs within the preceding 10 years and categorized as <10 versus ≥10 lesions. Primary outcomes were nodal, distant, and overall metastasis. Multivariable logistic regression models adjusted for age, sex, tumor thickness, and perineural invasion (PNI) were performed.

Results
Patients with ≥10 prior cSCCs (7.8%) had significantly higher rates of nodal metastasis (21.2% vs 5.4%) and overall metastasis (24.2% vs 5.4%). In multivariable analysis, ≥10 prior cSCCs was independently associated with increased risk of any metastasis (adjusted odds ratio [aOR] 4.58; 95% CI 1.77–11.85; P=0.002) and nodal metastasis (aOR 3.88; 95% CI 1.45–10.38; P=0.007), but not distant metastasis.

Conclusions
High cumulative cSCC burden is independently associated with increased metastatic risk in advanced cSCC.

EA DV CONGRESS
VIENNA
30 SEP - 3 OCT 2026

Abstract N°: 2971

Real-world effectiveness and safety of mogamulizumab in advanced cutaneous T-cell lymphomas: a multicenter study with clinicopathological characterization of mogamulizumab-associated rash

Elena Pérez Zafrilla*[1], Angel Gonzalez Garcia[1], Isabel Jorques Belda[2], Rafael Botella Estrada[2], Maria del Mar Blanes Martinez[3], Victor Gonzalez Delgado[4], Javier Lorenz Dolz[5], Fatima Mayo Martinez[5], Ivan Blay Simon[6], Ana Isabel Zayas Gavila[6], Daniel Blaya Imbernon[1], Malena Finello[1], Laura Gimenez Cuenca[1], Alba Nacher Albiach[1], Nadia Giner Cerda[1], Dolla Logunova[1], Victor Alegre de Miquel[1], Amparo Perez Ferriols[1], Maria Jose Lis Chulvi[1], Mariam Ibañez Company[1], Esther Diez Recio[1], Jorge Magdaleno Tapial[1]

[1] Hospital General Universitario de Valencia, Valencia, Spain
[2] Hospital Universitario y Politécnico La Fe de Valencia, Valencia, Spain
[3] Hospital General Universitario de Alicante, Alicante, Spain
[4] Hospital Clínico Universitario de Valencia, Valencia, Spain
[5] Instituto Valenciano de Oncología, Valencia, Spain
[6] Hospital Universitario Dr. Peset de Valencia, Valencia, Spain

Introduction

Mogamulizumab, an anti-CCR4 monoclonal antibody, is approved for advanced cutaneous T-cell lymphomas (CTCL) after failure of prior therapies. Although clinical trials have demonstrated its efficacy, real-world data remain limited. Mogamulizumab-associated rash (MAR) is a frequent immune-mediated adverse event that may mimic disease progression and has been suggested as a potential biomarker of response.

The aim of this study is to assess the effectiveness and safety of mogamulizumab in advanced CTCL in a real-world setting, and to characterize the clinical and histopathological features of MAR, exploring its association with treatment response.

Materials and Methods

This retrospective multicenter study included patients with mycosis fungoides (MF) or Sézary syndrome (SS) treated with mogamulizumab across hospitals in the Valencian Community (Spain). Demographic and clinical data, prior therapies, treatment duration, and responses (global and by compartments: skin, blood, lymph nodes) were collected. Adverse events were recorded, with particular focus on MAR. Response was assessed according to routine clinical practice. The association between MAR and overall response rate (ORR) was explored.

Results

Twenty patients with advanced CTCL (MF/SS) were included, representing a heavily pretreated population. The overall response rate was high, with the most pronounced responses observed in the blood compartment. MAR occurred in more than half of the patients and showed heterogeneous clinical presentations, including maculopapular, lichenoid, eczematous, and erythrodermic patterns. Histopathological findings were predominantly inflammatory, without significant tumor infiltration, supporting differentiation from disease progression. Most cases were managed with topical or systemic corticosteroids, and in selected patients, mogamulizumab dose adjustment or temporary interruption was required. Patients who developed MAR showed a higher proportion of response compared to those without MAR; however, this association did not reach statistical significance, likely due to the limited sample size.

Conclusions

In this real-world multicenter cohort, mogamulizumab demonstrated substantial effectiveness in advanced CTCL, particularly in blood involvement, with a manageable safety profile. MAR was a frequent and clinically heterogeneous event requiring clinicopathological correlation to avoid misinterpretation as progression. Its potential role as a biomarker of response warrants further investigation.

EA DV CONGRESS
VIENNA
30 SEP - 3 OCT 2026

Abstract N°: 2979

Dermoscopic misleading Seborrheic Keratosis: A case of nodular basal cell carcinoma

Nouha Touhami*[1], Kenza Benothmane[1, 1], Narjess Errachdy[1], Najoua Ammar[1], Syrine Hamada[1], Mariame Meziane[1], Nadia Ismaili[1], Laila Benzekri[1]

[1] Ibn Sina Hospital, rabat, Morocco

Introduction

Basal cell carcinoma is the most common malignant cutaneous tumor and is characterized by marked clinical heterogeneity, which may complicate diagnosis. In its atypical forms, it can clinically mimic benign lesions, particularly Seborrheic keratosis, due to its verrucous, pigmented, or hyperkeratotic appearance.
Several cases in the literature have reported either the coexistence of basal cell carcinoma within seborrheic keratosis or initial misdiagnosis as seborrheic keratosis, highlighting the deceptive nature of these clinically benign-appearing lesions. This overlap may delay diagnosis and appropriate management, emphasizing the need for careful dermoscopic evaluation and histopathological confirmation when uncertainty persists.

We report a case illustrating this diagnostic challenge, in which a lesion initially suggestive of seborrheic keratosis was ultimately confirmed as basal cell carcinoma on histological examination, underscoring the importance of not underestimating atypical pigmented lesions

Case Presentation

A 40-year-old woman presented to our department with a lesion located on the vertex of the scalp. She had first noticed the lesion three years earlier, with progressive enlargement over time. Her medical history was unremarkable.
Clinical examination revealed a well-defined brown nodule measuring 2 × 1 cm on the vertex. Dermoscopic findings were suggestive of a benign Seborrheic keratosis. However, the lesion was surgically excised at the patient’s request.

Histopathological examination showed an ulcerated cutaneous lesion infiltrated by a tumoral proliferation composed of nodules with peripheral palisading and surrounding retraction clefts. Tumor cells were basaloid, with hyperchromatic anisokaryotic nuclei and fine nucleoli. The cytoplasm was scant and basophilic. The stroma exhibited fibro-inflammatory changes.
The tumor extended to the deep surgical margin.
Immunohistochemical analysis demonstrated:

- EMA: negative
- CK7: negative
- Ber-EP4: positive

The final diagnosis was nodular Basal cell carcinoma measuring 1 cm in greatest diameter. The lateral surgical margins were free, with the closest margin measuring 0.1 cm, whereas the deep margin was involved by tumor cells. A wider surgical re-excision was subsequently performed.



Figure : A:Clinical image of seborrheic keratosis. B:Dermoscopy in polarized light C: dermoscopy under Wood’s light

Conclusion

Basal cell carcinoma may present with misleading clinical features and mimic benign lesions such asSeborrheic keratosis. This morphological overlap highlights the limitations of clinical examination alone and underscores the importance of dermoscopy in the assessment of atypical pigmented or verrucous lesions. However, definitive diagnosis relies on histopathological examination. This case emphasizes the need to biopsy any suspicious or evolving lesion to avoid diagnostic delay and ensure prompt and appropriate management.

EA DV CONGRESS
VIENNA
30 SEP - 3 OCT 2026

Abstract N°: 2988

Transforming Melanoma Stratification: Insights from the MEGA Study Integrating Proteomics and AI-Driven Digital Pathology

Leticia Szadai*[1], Diana Fernandez-Coto[2], Jéssica Guedes[3], Nicole Woldmar[3], Henriett Oskolás[3], Matilda Marko-Varga[3], Roger Appelqvist[4], Elisabet Wieslander[3], Krzysztof Pawlowski[5], Lukas Christersson[3], Johan Malm[3], István Németh[1], Marcell Szász[6], Eszter Baltás[1], Rolland Gyulai[1], Jeovanis Gil[3], György Marko-Varga[3]

[1] Department of Dermatology and Allergology, University of Szeged, Szeged, Hungary
[2] Center for Genomic Sciences, National Autonomous University of Mexico, Cuernavaca, Mexico
[3] Department of Translational Medicine, Lund University, Lund, Sweden
[4] Clinical Protein Science & Imaging, Biomedical Centre, Department of Biomedical Engineering, Lund University, Lund, Sweden
[5] Department of Molecular Biology, University of Texas Southwestern Medical Center, Dallas, United States
[6] National Institute of Oncology, Budapest, Hungary

Introduction
Understanding why melanoma remains localized in some patients while rapidly metastasizing in others is a key question in melanoma care. Moreover, melanoma progression and therapeutic resistance are also major clinical challenges despite advances in targeted and immune checkpoint therapies. Current risk stratification relies primarily on clinicopathological parameters, which do not fully capture tumor heterogeneity and biological behavior. There is a growing need for integrative approaches combining molecular and spatial tumor features to improve prognostic accuracy guiding treatment decisions. The ongoing MEGA Study aim to address this gap by integrating large-scale clinical data with quantitative proteomics and AI-powered digital pathology to refine risk stratification and identify molecular drivers of recurrence and metastasis.

Materials and Methods
The MEGA Study includes approximately 1100 melanoma patients followed over a 10-year period, covering AJCC8 stages I–IV. Early-stage recurrence (stages I–II) was analyzed using two-tailed Mann–Whitney tests and multivariable logistic regression models, with model performance assessed by Nagelkerke R^2 and Hosmer–Lemeshow calibration. Quantitative proteomic profiling of formalin-fixed, paraffin-embedded treatment-naïve primary tumors using high-resolution mass spectrometry is currently ongoing. In parallel, AI-powered digital pathology analysis of whole-slide H&E images is being performed using the QuPath platform to enable automated annotation of tumor, stromal, and immune compartments for integrated spatial analysis.

Results
In early-stage melanoma, recurrence was significantly associated with increased Breslow thickness, higher mitotic rate, and elevated Charlson Comorbidity Index ($p<0.0001$, Mann-Whitney test), confirmed as independent predictors ($p<0.001$). Preliminary proteomic data from MEGA Study highlighted proteins and pathways connected to oxidative phosphorylation (OXPHOS), mitochondrial translation, and TCA cycle activation as driving mechanisms of tumor recurrence, suggesting metabolic reprogramming as a hallmark of progression. BRAF V600E–mutant melanomas exhibited increased mitochondrial protein expression and enrichment of oxidative phosphorylation (OXPHOS) pathways compared to wild-type tumors (FDR < 0.02). Recurrent tumors were further characterized by elevated PD-L1 expression and reduced MHC class I and II levels, consistent with an immune-

evasive phenotype. In line with our previous observations, we identified a significant reduction of ATP5IF1 levels in the acrolentiginous melanoma subtype, independent of mitochondrial load ($p<0.0001$, one-way ANOVA). In addition, AI-powered digital pathology annotations in a smaller patient subgroup demonstrated approximately 80% concordance with pathology expert annotations in the segmentation of tumor, stromal, and immune compartments, supporting the feasibility of a spatially resolved multimodal analysis.

Conclusions

The MEGA Study identifies mitochondrial metabolic reprogramming and immune deviation as key features of melanoma progression within a large, longitudinal cohort. While clinicopathological models remain informative, their limitations highlight the need for integrative, biology-driven approaches. Although the proteomic findings are preliminary, this study point out the potential of integrating quantitative proteomics with AI-driven spatial pathology to complement traditional clinicopathological models, offering a more biologically informed approach that may improve melanoma risk stratification and support more personalized treatment decisions.

EADV CONGRESS
VIENNA
30 SEP - 3 OCT 2026

Abstract N°: 2993

In-transit metastasis occurring four years after intermediate-thickness melanoma: a case report

Yasmim Mirindiba Ribeiro*[1], Sofia Feres Tetto[1], Anna Luiza Glus de Souza[1], Fernanda Rothermel Valderrama[1], Bianca Sanderson Chiaratti[1], Isadora Ceccatto Ortellado[1], Mariana Müller Angulski[1], Marcela Sarú Campos[1], Felipe Binder Coelho[1], Luiza Martins Affornali[1], Manuela Romero Macedo[1], Anber Tanaka[1]

[1] Faculdade Evangélica Mackenzie do Paraná, Curitiba, Brazil

Introduction

Cutaneous melanoma is an aggressive malignancy with high metastatic potential and unpredictable recurrence patterns influenced by histopathological features and routes of dissemination. Melanoma commonly spreads through lymphatic pathways before distant dissemination. In-transit metastases are defined as locoregional recurrences occurring in the skin or subcutaneous tissue between the primary tumor and the regional lymph node basin. These lesions are typically observed within the first 2–3 years following treatment of the primary tumor, while later recurrences are less common and may represent a diagnostic challenge.

Case Presentation

A 59-year-old man with a prior history of cutaneous melanoma of the left lower limb — Breslow thickness of 1.8 mm, Clark level IV, ulceration, and mitotic index of 3 mitoses/mm² — initially underwent an excisional biopsy of the primary lesion. Histopathological evaluation confirmed the diagnosis and established the Breslow thickness and other prognostic factors. Subsequently, the patient underwent margin widening surgery and sentinel lymph node biopsy in 2022. Both surgical margins and the sentinel lymph node were negative. No evidence of recurrence was observed during the initial follow-up period. In 2026, four years after primary treatment, the patient presented with a new solitary nodular lesion in the same limb, showing progressive enlargement. The lesion was located in the left popliteal region, approximately 10 cm from the previous surgical scar, and clinical examination revealed an ulcerated nodular lesion measuring approximately 5 cm in diameter. The lesion was initially interpreted as a possible abscess or local infectious process, contributing to a delay in diagnostic suspicion. Due to its persistence and progressive growth, an excisional biopsy was performed. Histopathological examination, with immunohistochemistry, confirmed in-transit melanoma metastasis. Staging investigations revealed suspicious left iliac lymphadenopathy with no confirmed distant metastatic disease. The patient underwent complete surgical resection of the lesion. Given the locoregional metastatic recurrence, systemic therapy with the programmed cell death protein-1 (PD-1) inhibitor nivolumab was initiated.

Conclusion

This case highlights an uncommon presentation of in-transit metastasis in intermediate-thickness melanoma, emphasizing that locoregional recurrence may occur beyond the conventionally expected timeframe. It also illustrates how in-transit metastases may present with nonspecific clinical features, potentially leading to delayed diagnosis. These findings reinforce the importance of prolonged follow-up and early histopathological evaluation of new cutaneous nodules in patients with a history of melanoma.

EA DV CONGRESS
VIENNA
30 SEP - 3 OCT 2026

Abstract N°: 3001

Regressive Keratoacanthoma in a Patient with Vitiligo: A Case Report

Abdennour BENKERRACHE*[1], Nadjet CHIKHBLED[1], Soumia HAMZAOUI[1], Amina SERRADJ[1]

[1] University Hospital Establishment, Oran, Algeria

Introduction

Keratoacanthoma (KA) is a rapidly evolving epithelial tumor arising from the pilosebaceous follicles,occurring predominantly in elderly, fair-skinned individuals on sun-exposed areas.
It is traditionally classified as a benign tumor with spontaneous regression potential,although its nosological relationship with squamous cell carcinoma (SCC) remains a subject of debate in the dermatological literature.

Case Presentation

A 64-year-old fair-skinned male (Patient BM), with a medical history of vitiligo, type 2 diabetes, hypertension, and lumbar disc herniation, presented with multiple cutaneous lesions.
He initially presented with an ulcerated lesion on the lower lip. Histopathological examination was consistent with verrucous squamous cell carcinoma, which was treated by surgical excision with clear margins.
Subsequently, the patient developed a crateriform nodule on the dorsal aspect of the right hand and a tumoral lesion on the left leg, featuring an irregular, hyperkeratotic verrucous surface covered with a yellowish crust.
Histopathological analysis of these lesions favored keratoacanthoma. Notably, these lesions appeared on areas affected by vitiligo.
Three months later, the patient was recalled for the excision of the keratoacanthoma; however, the lesions had completely disappeared spontaneously without any further treatment.

Conclusion

Discussion and Conclusion:

KA predominantly affects individuals over 50 years of age with fair skin, showing a slight male predominance, and typically involves sun-exposed areas such as the face, the back of the hands, and the lower limbs. The contributing roles of ultraviolet radiation, human papillomavirus (HPV), and immunosuppression are well-established risk factors for keratoacanthoma.

The spontaneous regression of KA is a biologically complex phenomenon involving a cell-mediated immune response, particularly cytotoxic CD8+ T lymphocytes via the release of granzyme B, leading to tumor apoptosis and lesion involution.

Histological studies have highlighted a dense peritumoral T-cell infiltrate in regressing KAs, clearly distinct from that found in progressive forms.

In our patient, the coexistence of vitiligo may be of pathophysiological interest. Vitiligo is characterized by persistent activation of cutaneous cytotoxic T lymphocytes and a microenvironment dominated by the IFN-γ/CXCL10 axis. Such local immune hypervigilance could theoretically enhance antitumor surveillance and promote the spontaneous regression of keratoacanthoma . While this hypothesis remains speculative, it is noteworthy given the immune mechanisms involved in the natural involution of KA.

The complete spontaneous regression observed in our case underscores the unique biological behavior of KA, confirming its distinct identity despite sometimes misleading histological similarities to true SCC.

This case illustrates the spontaneous regression capacity of keratoacanthoma, even after incomplete excision. The coexistence of vitiligo raises the hypothesis that cutaneous immune hypervigilance may play a facilitating role in this regressive phenomenon.

EADV CONGRESS
VIENNA
30 SEP - 3 OCT 2026

Abstract N°: 3007

Cutaneous Melanoma Mortality in Brazil: An Epidemiological Analysis from 2000 to 2023.

Luísa Ribeiro Romiti*[1], Lorena Vieira[1], Helio Miot[2], ana maria bertelli[1], Rossana Vasconcelos[1]

[1] University of Santo Amaro, São Paulo, Brazil

[2] Unesp Universidade Estadual Paulista, Botucatu, Brazil

Introduction

Cutaneous melanoma (CM) is a malignant neoplasm of melanocytic lineage responsible for approximately 90% of skin cancer-related deaths. Its metastatic potential and lethality make it a major public health concern. Over recent decades, CM incidence has increased worldwide, due to ultraviolet (UV) radiation exposure, population aging, and greater surveillance and detection. Brazil is a continental multiracial country, favoring the investigation of demographic disparities in disease burden. This study aimed to describe temporal trends in CM mortality in Brazil from 2000 to 2023, according to sex, age group, and race/skin color.

Materials and Methods

This ecological, descriptive, retrospective study used Brazilian secondary data from Brazilian national databases. Deaths from cutaneous melanoma (ICD-10 C43) between 2000 and 2023 were obtained from the Department of Informatics of the Brazilian Unified Health System. Population data were obtained from the Brazilian Institute of Geography and Statistics (IBGE), based on population estimates and projections. Mortality rates (MR) were calculated per 1 million inhabitants and stratified by sex, age group, and race/skin color. Temporal trends were analyzed using Joinpoint regression, with calculation of annual percentage change (APC).

Results

Between 2000 and 2023, 36,328 deaths from CM were recorded in Brazil. MR increased significantly between 2000 and 2017 (APC=2.72%)(Figure 1), followed by stabilization from 2017 to 2023. White individuals accounted for 80.96% of deaths (n=29,417), with the highest MR (13.45 per 1 million)(Figure2). This is consistent with the greater susceptibility of lighter phototypes to UV-induced damage, partly due to lower constitutive photoprotection and differences in melanin composition. Mixed-race individuals (pardos, according to IBGE) represented 12.43% of deaths (n=4,518; MR 2.36), while Black individuals accounted for 2.30% (n=836; MR 2.21). Although MRs were lower, non-White populations showed increasing trends over time. CM in darker-skinned populations is less common but often diagnosed at more advanced stages; in Black individuals, acral lentiginous melanoma is proportionally more frequent and associated with delayed recognition, diagnostic difficulty, and worse prognosis. Indigenous individuals accounted for less than 0.1% of deaths (MR 0.79). The Asian population, despite a relatively high MR (5.35) due to small population size, accounted for only 0.29% of deaths.

Men accounted for 57.25% of deaths (n=20,792), with an MR of 9.04, compared with 6.46 among women (n=15,533), representing a 1.4-fold higher MR in males (Figure 3). MR increased in men between 2000 and 2016 (APC=3.02%), followed by stabilization, while women showed continuous growth throughout the period (APC=2.17%). These findings are multifactorial, reflecting behavioral factors, such as lower healthcare-seeking behavior and delayed diagnosis in males, as well as biological differences. Previous studies suggest that women retain a survival advantage even after adjustment for tumor thickness, age, and anatomic site, supporting the role

of genetic, immune, and hormonal mechanisms.

MR increased progressively with age (Figure 4). Individuals aged 80 years or older presented the highest MR (92.68; n=7,149), followed by those aged 70-79 years (MR 45.52) and 60-69 years (MR 25.35). Individuals younger than 40 years had MR below 5 per 1 million. Worse outcomes in older adults may reflect cumulative sun exposure, delayed detection, and age-related immune dysfunction, including immunosenescence, which may impair antitumor surveillance.

Figure 1 - Trends in the mortality rate of the Brazilian general population by cutaneous melanoma in Brazil between 2000 and 2023

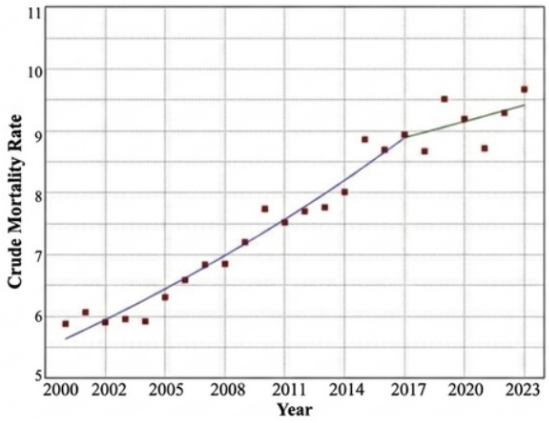

Figure 2 - Trends in the mortality rate of cutaneous melanoma in Brazil between 2000 and 2023 according to self-declared color/race

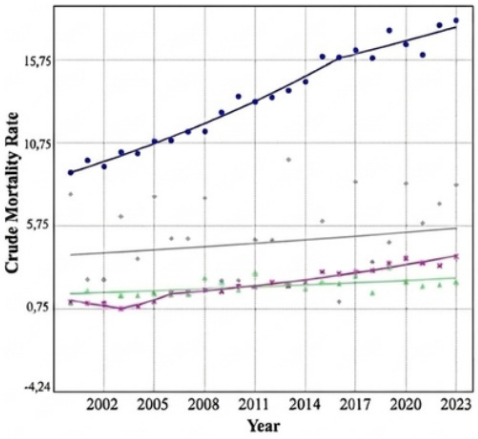

Figure 3 - Trends in the mortality rate of cutaneous melanoma in Brazil between 2000 and 2023 by sex

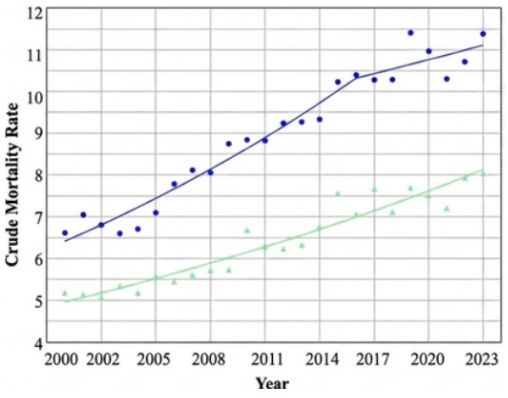

Figure 4 - Trends in the mortality rate of cutaneous melanoma in Brazil between 2000 and 2023 by age group

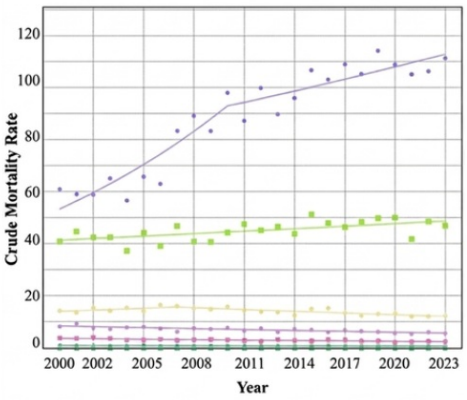

Figure 1 -

Crude mortality rate
2000 to 2017 APC = 2,72*
2017 to 2023 APC = 0,97

Figure 2 -

White – 1 *Jointpoint*
2000 to 2016 APC = 3,62*
2016 to 2023 APC = 1,61
Black – 0 *Jointpoint*
2000 to 2023 APC = 1,92*
Yellow – 0 *Jointpoint*
2000 to 2023 APC = 1,46
Mixed-race – 2 Joinpoints
2000 to 2003 APC = -14,81*
2003 to 2006 APC = 28,04*
2006 to 2023 APC = 5,23*
2006 to 2023 APC = 5,23*

Figure 3 -

Male - 0 Joinpoints
2000 to 2016 APC = 3,02*
2016 to 2023 APC = 1,06
Female - 0 Joinpoints
2000 to 2023 APC = 2,17*

Figure 4 -

10 to 19 - 0 Joinpoints
2000 to 2023 APC = -0,40
20 to 29 - 0 Joinpoints
2000 to 2023 APC = -1,39*
30 to 39 - 0 Joinpoints
2000 to 2023 APC = -1,63*
40 to 49 - 0 Joinpoints
2000 to 2023 APC = -1,62*
50 to 59 - 1 Joinpoint
2000 to 2007 APC = 1,67
2007 to 2023 APC = -1,61*
60 to 69 - 0 Joinpoints
2000 to 2023 APC = 0,13
70 to 79 - 0 Joinpoints
2000 to 2023 APC = 0,71*
80 years or more - 1 Joinpoint
2000 to 2010 APC = 5,69*
2010 to 2023 APC = 1,51

APC (*annual percentage change* - annual percentage change); * (p<0.05); Source: made by the authors

Conclusions

CM mortality in Brazil increased significantly between 2000 and 2017, followed by stabilization until 2023. Higher MRs were observed among White individuals, males, and those over 80 years old. These findings highlight the need for targeted public health strategies focused on prevention, early diagnosis, and improved access to treatment for high-risk populations.

EADV CONGRESS
VIENNA
30 SEP - 3 OCT 2026

Abstract N°: 3018

Proteomic Insights into the Comparative Effectiveness of Cryotherapy and Topical Treatments for Actinic Keratosis

Lauren Faul[1, 2, 3], Ishana Dixit*[1, 3], Ali Azimi[1, 2, 3], Pablo Fernandez-Peñas[1, 2, 3], Zhaoxiang (Simon) Cai[1, 4, 5]

[1] The University of Sydney, Sydney, Australia
[2] Westmead Institute for Medical Research, Westmead, Australia
[3] Westmead Hospital, Westmead, Australia
[4] ProCan®, Westmead, Australia
[5] Children's Medical Research Institute, Westmead, Australia

Introduction
Actinic keratoses (AKs) are common premalignant keratinocytic skin lesions managed with lesion-directed cryotherapy or field-directed topical 5-fluorouracil (5-FU). The comparative molecular responses within treated epidermis are incompletely characterised. We compared pre- and post-treatment tape-striped proteomic changes following cryotherapy versus topical 5-FU.

Materials and Methods
In a comparative observational study, paired tape-striped samples were collected from patients with AK lesions before and after treatment with cryotherapy (n=20) or topical 5-FU (n=13). Proteins were identified and quantified using liquid chromatography–mass spectrometry-based proteomics. Then, paired differential protein abundance was analysed using limma with Benjamini–Hochberg false discovery rate (FDR). Pathway enrichment was assessed using pre-ranked GSEA across GO Biological Process, KEGG, Reactome and Hallmark gene sets; significance was defined as FDR $q<0.25$.

Results
Cryotherapy produced limited single-protein change, with 5/3492 proteins significantly altered (FDR<0.05; 4 upregulated, 1 downregulated), including increased ITIH3, LRG1 and TMPRSS11E, and decreased CYTH1. Despite this, GSEA identified 450 significant gene sets, including enrichment of Lysosome (NES 2.71) and ECM degradation (NES 2.10) with depletion of translation programs (cap-dependent translation initiation, NES −2.53). Topical 5-FU induced broader disruption, with 150/3556 proteins significantly altered (130 upregulated, 20 downregulated), including complement/coagulation and inflammatory proteins (e.g., C1R, CFI, C4BPA, PLG, MPO, ELANE). GSEA identified 683 significant gene sets, including enrichment of complement and coagulation cascades (NES 2.66) and depletion of translation initiation pathways (translation initiation complex formation, NES −3.07).

Conclusions
Tape-strip proteomics demonstrates that both therapies shift the AK surface proteome toward innate immune activation and tissue remodelling with concurrent suppression of ribosome/translation programs. The molecular response is substantially stronger following topical 5-FU, consistent with a pronounced inflammatory field reaction, supporting tape-strip proteomics for mechanistic assessment and biomarker discovery in AK

management.

EADV CONGRESS
VIENNA
30 SEP - 3 OCT 2026

Abstract N°: 3033

Adult disseminated Langerhans cell histiocytosis

Tarek Mansoul*[1], Ibtissem Chelgham[1], Ahmed Samaouel Chehad[1]

[1] Department of Dermatology, Benbadis University Hospital Center, University of Constantine 3, Constantine, Algeria

Introduction

Langerhans cell histiocytosis is defined by a clonal proliferation within tissues of dendritic cells with phenotypic characteristics of Langerhans cells expressing CD1a, CD207, and S100. Clinical manifestations range from single-organ forms that may regress spontaneously to disseminated and potentially life-threatening disease. Cutaneous involvement of Langerhans cell histiocytosis is polymorphic. Lesions may be papular or vesicular, often purpuric, and are predominantly located on the trunk, face, scalp, and intertriginous areas. We report a case of disseminated Langerhans cell histiocytosis with cutaneous, osseous, and endocrine involvement.

Case Presentation

A 51-year-old woman with a 5-year history of type 2 diabetes mellitus treated with metformin, a history of necrotizing external otitis 3 years earlier, presented with erosive lesions partially covered by vegetative plaques in the inguinal folds, as well as erythematous scaly plaques associated with satellite papules involving the submammary and intermammary regions, evolving over the past 2 years.

The remainder of the clinical examination revealed a polyuro-polydipsic syndrome, temporomandibular arthralgia, and knee pain. A skin biopsy demonstrated histopathological findings and an immunohistochemical profile (CD68+, CD1a+) consistent with Langerhans cell histiocytosis.

Bone scintigraphy revealed osteolytic lesions involving both mastoid bones and the left posterior seventh rib, as well as multiple osteosclerotic lesions affecting the femurs and tibias. The water deprivation test was positive, and hypothalamic-pituitary MRI showed absence of the normal posterior pituitary T1 hyperintense signal, confirming central diabetes insipidus.

The patient was treated with prednisone at a dose of 1 mg/kg/day in combination with vinblastine 6 mg/week and vasopressin, resulting in a favorable clinical outcome.

Conclusion

Cutaneous involvement in Langerhans cell histiocytosis is commonly associated with maxillary or craniofacial bone lesions, as observed in our patient. Bone involvement is frequent, accounting for approximately 50% of adult Langerhans cell histiocytosis localizations. Endocrine manifestations are mainly related to hypothalamic-pituitary involvement, most commonly resulting in central diabetes insipidus. The prognosis depends on the number of organs involved and the severity of organ damage.

EADV CONGRESS
VIENNA
30 SEP - 3 OCT 2026

Abstract N°: 3046

Multiple Cutaneous Metastases of Papillary Thyroid Carcinoma: An Atypical Presentation and Marker of Disease Progression

Abdennour BENKERRACHE*[1], Nadjet CHIKHBLED[1], Soumia HAMZAOUI[1], Amina SERRADJ[1]

[1] University Hospital Establishment, Oran, Algeria

Introduction
Papillary thyroid carcinoma (PTC) is the most common form of thyroid cancer.
Distant metastases occur in approximately 4% to 23% of cases, primarily affecting the lungs, bones, and central nervous system.
In contrast, cutaneous metastases are exceptional, occurring in less than 1% of PTC cases.

Case Presentation
We report the case of a 73-year-old woman, BK, whose medical history included a pituitary adenoma, a pancreatic serous cystadenoma, hysterectomy for uterine fibroids, and an atopic background.

She was being followed for papillary thyroid carcinoma treated with total thyroidectomy followed by radioiodine therapy, with known pulmonary metastases.

The patient presented with the progressive appearance of multiple erythematous-violaceous cutaneous nodules located on the abdomen, back, right shoulder, and lower limb, in a context of moderately impaired general condition.

Histopathological and immunohistochemical examination of the skin lesions revealed partial positivity of the tumor cells for thyroglobulin, diffuse nuclear positivity of most cells for TTF-1, and absence of staining for Napsin A.

These findings were consistent with cutaneous metastases from papillary thyroid carcinoma.

Conclusion
Discussion and Conclusion:
Cutaneous metastases from papillary thyroid carcinoma (PTC) are rare. They typically occur in the setting of advanced, often disseminated metastatic disease, as illustrated by our patient’s history of pulmonary metastases.

Clinically, the lesions usually present as firm erythematous or violaceous cutaneous nodules.

The histological appearance in our case corresponded to the morphological features classically described in cutaneous metastases of PTC.

Diffuse nuclear positivity for TTF-1 in most tumor cells, associated with partial thyroglobulin positivity and absence of Napsin A staining, represents an immunohistochemical profile characteristic of a thyroid-origin carcinoma, allowing exclusion of secondary cutaneous involvement from a primary lung tumor.

The abdominal, dorsal, and lower-limb distribution of the cutaneous metastases in our patient is unusual. Most

cases reported in the literature describe preferential involvement of the scalp and cervical regions.

The interval between thyroidectomy and the onset of cutaneous metastases is variable, ranging from a few months to several decades. In our patient, the occurrence of skin lesions after thyroidectomy for metastatic PTC with known pulmonary involvement reflected progression of metastatic disease and therefore a poor prognosis.

This case highlights the rarity and atypical presentation of cutaneous metastases from papillary thyroid carcinoma involving unusual sites such as the abdomen, back, and lower limbs. It emphasizes the importance of performing skin biopsy in any unexplained cutaneous nodule occurring in patients with a history of thyroid cancer, even in the absence of suggestive clinical signs.

EADV CONGRESS
VIENNA
30 SEP - 3 OCT 2026

Abstract N°: 3047

Leukemia cutis revealing acute lymphoblastic leukemia

Tarek Mansoul*[1], Amel Bouznad[1], Ahmed Samaouel Chehad[1]

[1] Department of Dermatology, Benbadis University Hospital Center, University of Constantine 3, Constantine, Algeria

Introduction

In malignant hematologic diseases, cutaneous manifestations are frequent and varied, and can be broadly classified into four groups: cutaneous localizations, satellite dermatoses, infections, drug eruptions, and other iatrogenic reactions.

Leukemia cutis are rare dermatological manifestations of acute leukemias, presenting as violaceous nodules, with a histopathological infiltrate of blast cells. We report the case of a patient with acute lymphoblastic leukemia revealed by leukemia cutis.

Case Presentation

A 21-year-old patient consulted for papulonodular lesions on the face, trunk, and limb roots that had been evolving for eight months. Dermatological examination revealed violaceous lesions, hardened, painless, with occasional central necrosis, associated with petechial purpura and multiple bilateral cervical, axillary, and inguinal lymphadenopathy.

Histopathological examination of a papule showed a dermal lymphomatous tumor proliferation composed of blast cells.

Complete blood count revealed anemia (10 g/dL), thrombocytopenia (71,000/mm^3), and hyperleukocytosis (38,000/mm^3) with lymphocytic predominance. Bone marrow aspiration showed infiltration by lymphoid cells, some of which were immature. Immunophenotyping by flow cytometry was consistent with T-cell acute lymphoblastic leukemia.

Thoraco-abdomino-pelvic computed tomography revealed a tumor syndrome characterized by homogeneous stage II splenomegaly and right hilar and iliac lymph node enlargement.

The diagnosis of acute lymphoblastic leukemia with cutaneous involvement was established, and the patient was treated with the LINKER chemotherapy protocol (14-day cycles per month for nine months), resulting in clinical and biological remission.

Conclusion

In leukemias, in addition to manifestations related to bone marrow failure, tumor syndrome, and visceral involvement, rare dermatologic manifestations may occur. These lesions are referred to as *leukemids* when nonspecific, and as *leukemia cutis* when they represent specific cutaneous infiltration by neoplastic leukemic cells. Histologically, leukemia cutis corresponds to dermal infiltration by blast cells. It is more commonly associated with myeloid leukemias and it is regarded as a sign of a poorer prognosis.

In the present case, cutaneous lesions were the inaugural manifestation leading the patient to seek dermatologic consultation. The association of cutaneous findings with clinical and radiological evidence of tumor syndrome, together with histopathological examination, enabled rapid diagnostic orientation.

EADV CONGRESS
VIENNA
30 SEP - 3 OCT 2026

Abstract N°: 3054

Active Surveillance in Low-Risk Basal Cell Carcinoma in Older Adults: Protocol for the Co-Design of a Patient-Centred Integrated Care Pathway

Floor Verstraete*[1, 2], Isabelle Hoorens[1, 3], Kim Beernaert[1], Satish Lubeek[4]

[1] University of Ghent, Ghent University Hospital, Gent, Belgium

[2] Ghent University Hospital, Gent, Belgium

[3] Ghent University Hospital, Dermatology, Gent, Belgium

[4] Radboud University Nijmegen Medical Center, Nijmegen, Netherlands

Introduction

Skin cancer is the most prevalent malignancy worldwide, with incidence rates continuing to rise, particularly among older adults. Basal cell carcinoma (BCC) are the most common subtype, and recent literature projects a 140% increase in incidence by 2050 due to population ageing, environmental changes, and ozone depletion. The true disease burden is likely underestimated, as keratinocyte skin cancers (KCs) are often excluded from cancer registries.

Despite their indolent nature and limited impact on health-related quality of life, standard management of BCC continues to favour surgical excision. However, this approach may not always be appropriate in older adults, a population characterised by substantial heterogeneity in comorbidities, functional status, and life expectancy. Nevertheless, international guidelines rarely integrate time-to-benefit considerations in patients with limited life expectancy, potentially exposing older adults with asymptomatic low-risk BCC to overtreatment.

Recent literature therefore supports active surveillance (AS) as a valuable alternative for low-risk BCC. This strategy of carefully monitoring the skin lesion without immediate treatment has been successfully applied in other cancer types, such as low-risk prostate cancer. Two recent studies on untreated BCC reported that approximately half of lesions remain stable over time, suggesting that AS may be a more appropriate strategy in older patients. Consensus-based guidelines for managing KCs in older adults acknowledge the potential role of AS, while highlighting the need for further evidence on its cost-effectiveness and its impact on patient satisfaction compared to surgical excision. Furthermore, the authors emphasise that decisions to refrain from treatment should be based on shared decision-making with patients and their proxies, taking into account key factors, including life expectancy, comorbidities, lifestyle, and individual preferences. A Europe-wide survey showed that 70% of dermatologists would consider AS for low-risk BCCs, while highlighting the lack of evidence-based guidelines for safe non-treatment in older adults.

Materials and Methods

This study aims to address this knowlegde gap by developing an integrated care pathway (ICP) for the non-treatment and surveillance of older adults with low-risk BCC, using an experience-based co-design (EBCD) methodology. This approach involves close collaboration between patients, their proxies, and a multidisciplinary team of healthcare professionals, and has been successfully applied across various cancer settings.

The EBCD process comprises six phases: (1) project set-up, (2) collection of staff experiences, (3) collection of patient and proxy experiences, (4) development of a trigger film, (5) a joint priority-setting group discussion, and (6) a final review event. Ultimately, these phases will guide the development of a care pathway for the safe

surveillance of low-risk BCC in older adults, ensuring alignment with patients' preferences, expectations, and individual care goals.

Results

The EBCD process is expected to result in a patient-centred ICP for the safe implementation of AS in older adults with low-risk BCC. The ICP will define care organisation, roles and responsibilities of healthcare professionals, and coordination between primary and secondary care. In addition, the study will generate insights into clinical decision-making, patient information needs, and factors influencing adherence to an AS approach, based on interviews with healthcare professionals, patients, and their proxies.

Conclusions

This research project will provide an evidence-informed framework to support safe and personalized use of AS in low-risk BCC. By integrating patient and professional perspectives, it aims to improve shared decision-making and reduce overtreatment. The resulting ICP will serve as a foundation for future evaluation in a multicentre trial comparing AS with standard care.

EA DV CONGRESS
VIENNA
30 SEP - 3 OCT 2026

Abstract N°: 3055

Purpose and future implementation of biomarkers for cutaneous T-cell lymphoma (CTCL): the voice of the patient

Anaïs van Haaren*[1], Elise Beljaards[2], Linda Godding[1], Elke de Jong[1], Rosanne Ottevanger[2], Stephan Westerdijk[3], Maarten Vermeer[2], Marieke Seyger[1], Juul van den Reek[1]

[1] Radboud University Medical Centre, Nijmegen, Netherlands
[2] Leiden University Medical Centre, Leiden, Netherlands
[3] Stichting Huidlymfoom, Weesp, Netherlands

Introduction

Cutaneous T-cell lymphoma (CTCL) is a rare and clinically heterogeneous malignancy in which biomarkers are increasingly investigated with the main purpose to support diagnosis, monitor disease activity, prognostic stratification and prediction of treatment response. Despite the growing interest in biomarker development, no studies to date have examined the preferences of patients with CTCL or dermatological care providers (DCPs) regarding the implementation of potential biomarkers in daily practice. Such insights are, however, essential to inform future research priorities and facilitate effective translation into routine care.

Therefore, this study aims to assess the priorities of patients with CTCL and their DCPs regarding the intended purpose of a biomarker. In addition, the perceived barriers and facilitators of patients were assessed for implementation of biomarkers in daily clinical practice.

Materials and Methods

Two web-based surveys were developed using Qualtrics survey software (Qualtrics, Provo, UT): one for patients who reported a diagnosis of CTCL and one for DCPs. The surveys covered demographic characteristics, disease related information, biomarker needs and preferred purposes, perceived barriers and facilitators, and acceptable time investment.

Results

A total of 74 CTCL patients were included (64.9% female; mean age 61.3 ± 11.8 years; median disease duration 5.0 years [IQR 2.0–12.0]). Of the 99 included DCPs, the majority were dermatologists (80.8%).

Patients most frequently prioritised biomarkers with the purpose to indicate disease severity (24.3%), disease course (23.0%) and therapeutic response (21.6%). DCPs ranked disease course as the most important purpose (44.4%), followed by therapeutic response (26.3%). Only 14.9% of patients and 10.1% of DCPs mentioned diagnostic accuracy as their primary priority, and it was rarely chosen as a second or third priority, as illustrated in the Sankey diagram (Figure 1).

Patients mentioned the following as the most important potential barriers: biomarker collection at an external centre, particularly if travel time would exceed 1 hour (25.0 %), incomplete reimbursement (18.8%), and collection outside regular hours (15.6%).

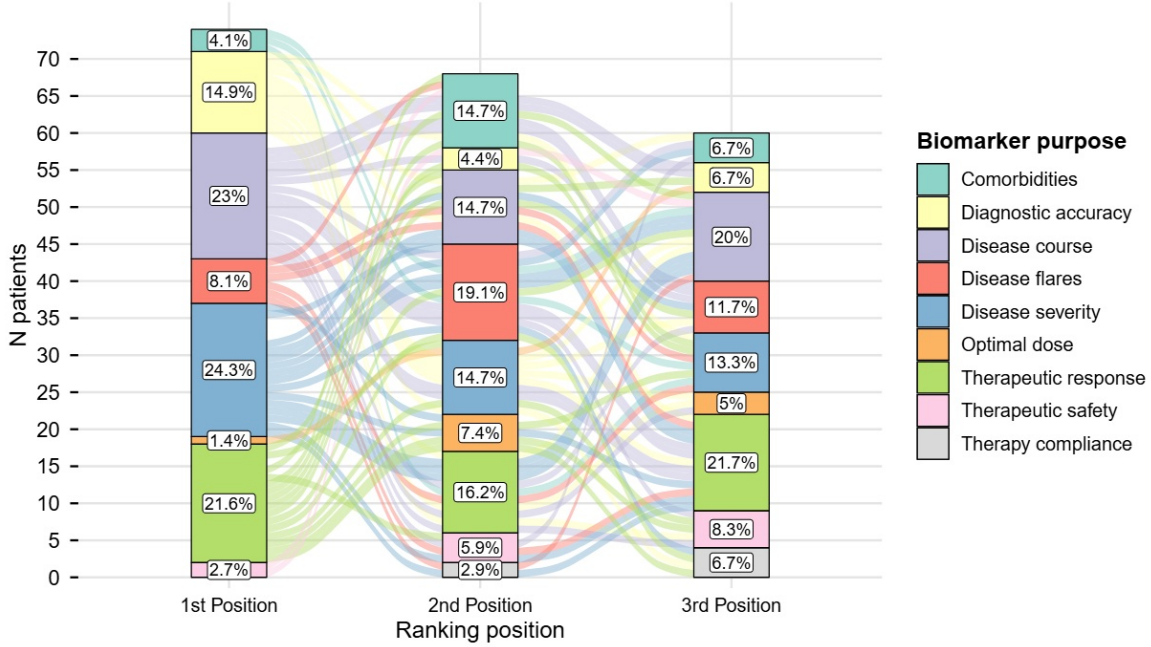

Figure 1. Top three ranked biomarker purposes for patients with CTCL (only first-ranked biomarker choices were mandatory; second- and third-ranked selections were optional, leading to decreasing numbers across the bar charts in the Sankey diagram)

Conclusions

Both patients and DCPs predominantly prioritised biomarkers addressing disease course over diagnostic accuracy, despite the latter being a well-documented challenge in CTCL. For successful implementation of such biomarkers in clinical practice, patients considered collection at their own clinic and full reimbursement essential.

EA DV CONGRESS
VIENNA
30 SEP - 3 OCT 2026

Abstract N°: 3056

Spontaneous regression of a primary cutaneous CD30-positive T-cell lymphoproliferative disorder with discordant histopathology

JOÃO GARCIA DA ROCHA NETO*[1], Carolina Siqueira Varotto Martins[1], Carolina Lourenço dos Santos Landini Freitas[1], Camila Gouvea Facure[1], EDUARDA LUISA ROCHA CORTI[1], MARIA BEATRIZ LIRA DO O ESPOSITO[1], Célia Antonia Xavier de Moraes Alves[1], Juliana Arêas de Souza Lima Beltrame Ferreira[1], Clovis Antonio Lopes Pinto[1], Glaucos Ricardo Paraluppi[1], Mariana Careta[1]

[1] Faculdade de Medicina de Jundiaí, Jundiaí, Brazil

Introduction

Primary cutaneous CD30-positive T-cell lymphoproliferative disorders comprise a spectrum that includes lymphomatoid papulosis and primary cutaneous anaplastic large cell lymphoma and are typically associated with an indolent course and favorable prognosis. However, diagnosis may be challenging when histopathologic and immunophenotypic findings from different biopsies are heterogeneous or discordant, especially in the setting of suspected mycosis fungoides or other cutaneous T-cell lymphomas.

Case Presentation

A 64-year-old woman presented with a solitary, progressively enlarging erythematous-violaceous infiltrated nodule on the forehead that developed after local trauma, in the context of long-standing psoriasis treated with methotrexate. Clinical differential diagnoses included a cutaneous lymphoid neoplasm. Two skin biopsies from distinct sites were obtained and independently evaluated by different pathology services. The first biopsy showed an atypical epidermotropic T-cell infiltrate extending through the superficial and deep dermis, with CD3 positivity, a T-cell receptor delta phenotype, and no detectable CD30 expression, raising concern for a primary cutaneous T-cell lymphoma versus mycosis fungoides. Subsequent immunohistochemical studies and expert review of additional specimens revealed strikingly discordant results: a trunk biopsy was reinterpreted as a reactive inflammatory T-cell infiltrate, whereas the forehead lesion demonstrated a T-cell lymphoma composed of medium and large atypical cells, CD4-/CD8-, strongly CD30-positive with a high proliferative index (Ki-67 up to 70%) and non-cytotoxic profile, compatible with the spectrum of primary cutaneous CD30-positive T-cell lymphoproliferative disorders or advanced-stage mycosis fungoides. Staging investigations showed no extracutaneous involvement.No systemic oncologic treatment was initiated, and only careful clinical follow-up was undertaken. Over subsequent months, the forehead nodule gradually regressed and ultimately resolved completely, leaving clinically normal-appearing skin without recurrence, supporting an indolent cutaneous lymphoproliferative process despite the initial neoplastic impression

Conclusion

This case illustrates the diagnostic complexity of primary cutaneous T-cell lymphoproliferative disorders, emphasizing how sequential biopsies from different sites and interpretative variability between pathology laboratories can generate discordant findings ranging from reactive inflammatory infiltrate to CD30-negative epidermotropic T-cell infiltrate and CD30-positive large-cell lymphoproliferative disorder. Careful clinicopathologic correlation, repeat biopsy, and specialized dermatopathology assessment are crucial for accurate classification in such borderline cases. The spontaneous regression observed, despite worrisome histopathologic

features, underscores the characteristic potential for self-limited behavior within the spectrum of primary cutaneous CD30-positive T-cell lymphoproliferative disorders.

EADV CONGRESS
VIENNA
30 SEP - 3 OCT 2026

Abstract N°: 3066

Epidermotropic Melanoma Metastasis Mimicking Multiple Primaries: A Diagnostic Challenge

Joyce Gouvêa Freire*[1], André Molina[1], Raquel Castro[1], Rafaela de Paula[1], Ana Flávia Kohatsu[1]

[1] Hospital A.C. Camargo, São Paulo, Brazil

Introduction

Epidermotropic melanoma metastasis (EMM) is a rare form of cutaneous spread where metastatic cells invade the epidermis, mimicking primary melanoma both clinically and histopathologically. Distinguishing between multiple primary melanomas and EMM is crucial, as treatment and prognosis differ significantly.

Case Presentation

We report a 47-year-old female patient under follow-up with total body mapping and digital dermoscopy after excision of two superficial spreading melanomas (Breslow 1.0mm and 0.4mm, right paravertebral and left breast, respectively). Systemic staging showed no evidence of metastatic disease.
During the first follow-up exam, a single globular pattern lesion was observed near the left breast scar, prompting short-term follow-up. Within 3 months, the lesion showed growth and increased pigmentation on dermoscopy, confirmed as superficial spreading melanoma (Breslow 0.5mm). Figure 1

One month later, a new lesion on the back (near a previous scar) grew and was excised.
Histopathology revealed a superficial spreading melanoma (Breslow 0.7mm) with features suggestive of cutaneous metastasis (EMM). Figure 2

The patient was referred for adjuvant treatment with nivolumab.
The patient had no personal history of melanoma but reported a significant family history of neoplasms on both sides, including melanoma, genitourinary, pancreatic, lung, and gastric cancers. A genetic panel of 121 genes was negative.

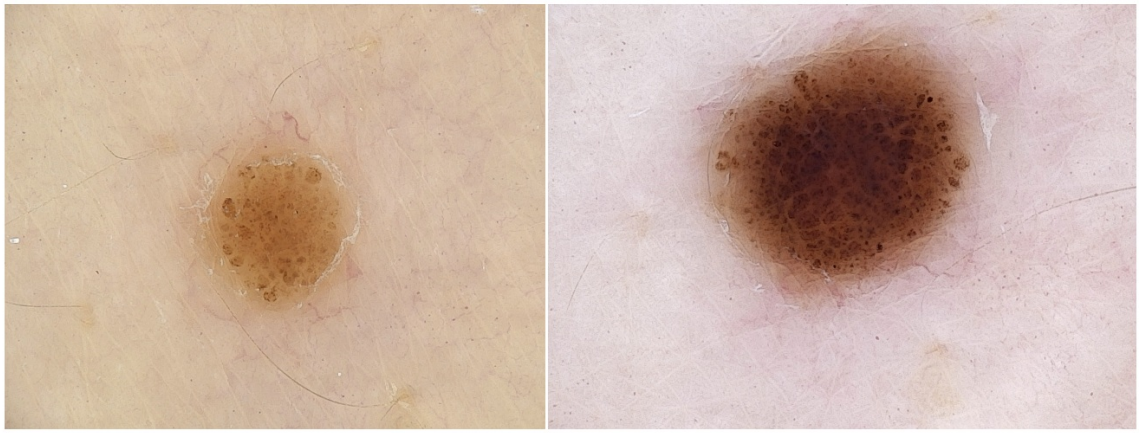

Left breast lesion with a 3-month follow-up interval

Conclusion

EMM is an unusual form of cutaneous spread that morphologically mimics a new primary melanoma. This case highlights the diagnostic difficulty and the implications for staging, treatment, and prognosis, emphasizing the role of digital dermoscopy in early detection.

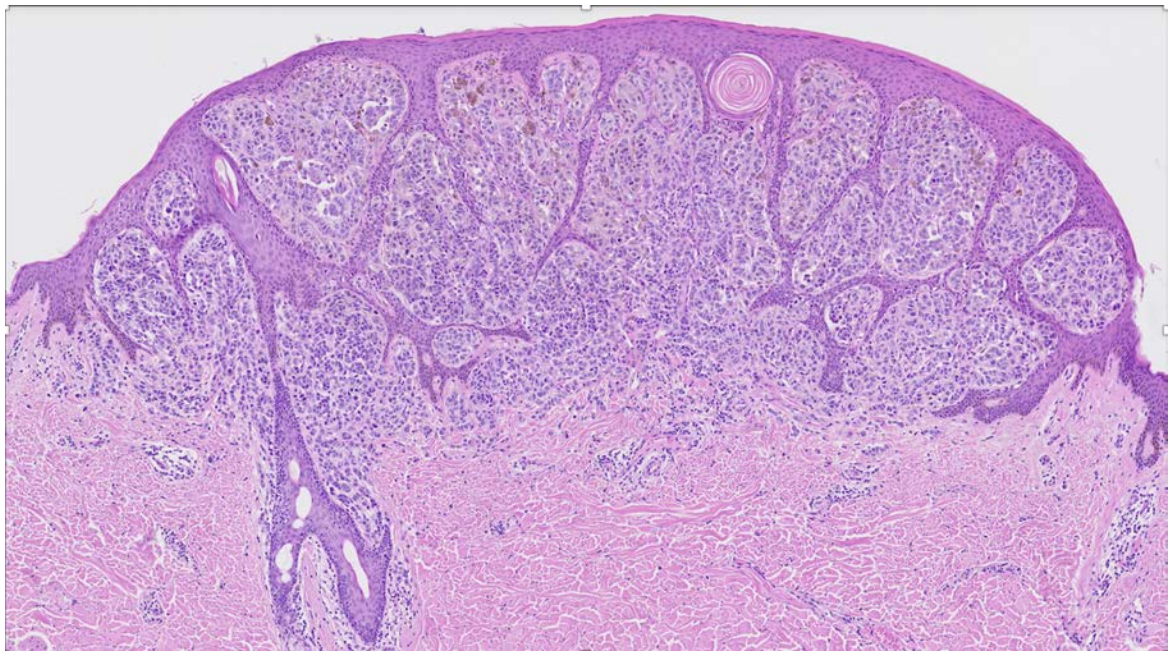

50× magnification (H&E): Well-circumscribed intradermal melanocytic lesion, demarcated by an epidermal collarette, without evidence of maturation. No significant associated lymphocytic or inflammatory infiltrate is identified.”

EA DV CONGRESS
VIENNA
30 SEP - 3 OCT 2026

Abstract N°: 3072

Kaposi Sarcoma In Patients With Hematological Malignancies

Batya Davidovici*[1], Assi Levi[1], Yonit Wohl[2], Daniel Mimouni[1, 1], Tal Benkovich[3]

[1] Division of Dermatology, Rabin Medical Center – Beilinson Hospital, Petach Tikva, Israel, Gray Faculty of Medical and Health Science, Tel Aviv University, Tel Aviv, Israel, Petach Tikva, Israel

[2] Faculty of Medicine, Ariel University, Israel, Kahn Sagol Maccabi Research and Innovation Center, Maccabi Healthcare, Ariel, Israel

[3] Kaplan Medical Center, Rehovot, Israel, Rehovot, Israel

Introduction

Kaposi sarcoma (KS) is a rare vascular neoplasm associated with human herpesvirus-8 infection, classically observed in individuals of Mediterranean, Central, and Eastern European origin. It occurs more frequently in immunocompromised populations, including patients with HIV/AIDS and solid organ transplant recipients. Hematologic malignancies (HM) are characterized by intrinsic immune dysregulation, often exacerbated by cytotoxic, biologic, and immunosuppressive therapies. This biological milieu suggests a potential increased risk of KS in HM patients; however, the incidence, clinical behavior, and outcomes of KS in this population remain insufficiently defined.

Objective:

To evaluate the incidence, risk factors, clinical features, and outcomes of KS in patients with HM, and to assess associated morbidity and mortality in this population.

Materials and Methods

We conducted a retrospective cohort study including all patients diagnosed with HM between 2000 and 2025 at a a tertiary medical center. Cases of KS were identified through institutional databases. Incidence rates were calculated, and comparative analyses were performed using survival analysis and multivariable regression models.

Results

Among 8,677 patients with HM, 24 cases of KS were identified (0.276%), of whom 66.7% were male. In 58.3% of cases, HM preceded or coincided with KS, while in 41.7% KS preceded HM diagnosis. Patients with both HM and KS were significantly older at HM diagnosis compared to those without KS (75.1 vs. 61.6 years, P=0.008). Mortality was significantly higher in the HM+KS group (58.3% vs. 29.3%, P=0.0006). Clinically, KS mostly presented as cutaneous lesions on the lower extremities, occasionally with multifocal involvement. Most cases were confined to the skin, with no visceral disease.

Conclusions

KS is an uncommon but clinically relevant comorbidity in patients with HM. Its presentation resembles classic KS with an indolent course. The increased mortality observed in this group appears primarily driven by the underlying hematologic malignancy rather than KS itself, underscoring the need for heightened clinical awareness and

individualized management strategies.

EA DV CONGRESS
VIENNA
30 SEP - 3 OCT 2026

Abstract N°: 3075

Cutaneous angiosarcoma of the scalp: exuberant presentation and challenging diagnosis

Laís Arroyo Lopes Anjo*[1], Eduardo Monteiro Diniz Junqueira[1], Lorraine Souza Santos[1], Barbara de Galvao e Brito Medeiros[1], Thais Buffo[1], Hamilton Ometto Stolf[1], Renata Ferreira Magalhães[1], Rafael Fantelli Stelini[1]

[1] UNICAMP, campinas, Brazil

Introduction

Cutaneous angiosarcoma is a rare and highly aggressive malignant vascular neoplasm, accounting for less than 1% of soft tissue sarcomas. It shows a predilection for elderly men, with preferential involvement of the scalp and cephalic region, primarily associated with chronic actinic damage. Clinically, it may initially present as violaceous macules or plaques resembling ecchymoses, rapidly progressing to nodular, ulcerated, or exophytic lesions, which frequently hampers early diagnosis. The histopathological spectrum is broad, ranging from well-differentiated forms to epithelioid and poorly differentiated variants that can mimic carcinomas, melanomas, and other sarcomas. Definitive diagnosis depends on clinicopathological correlation and immunohistochemistry with endothelial markers such as CD31, ERG, and D2-40. Despite therapeutic advances, the prognosis remains poor, with high rates of local recurrence and metastatic dissemination.

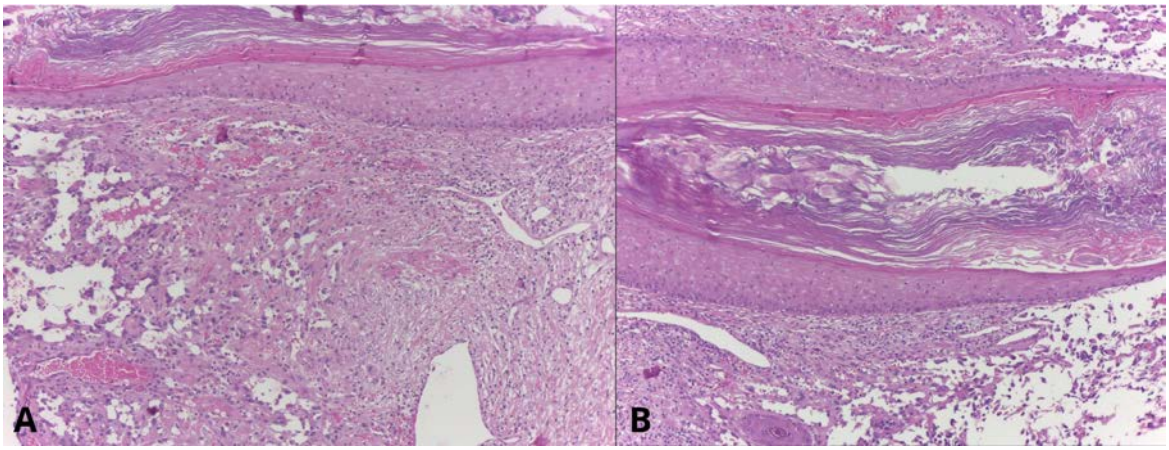

Figure A: Neoplastic vascular proliferation in the reticular dermis, with a diffuse and infiltrative pattern, poorly defined borders, and irregular lacunar spaces interspersed with atypical tumor cells. HE, ×100
Figure B: Hair follicle in longitudinal section surrounded by neoplastic vascular proliferation, with lacunar spaces dissecting the perifollicular mesenchyme and infiltrating the follicular sheaths. HE, ×100.

Case Presentation

A 70-year-old male patient, was referred for a scalp lesion with a six-month history. He reported the initial appearance of a violaceous macule in the left parietal region with progressive growth into a painful tumor mass. He denied fever, weight loss, or systemic complaints. Past medical history included smoking (50 pack-years) and prior alcohol use. Dermatological examination revealed a violaceous, cystic-appearing tumor measuring 7×7 cm in the parietal region of the scalp, with no palpable lymphadenopathy. Initial diagnostic hypotheses included squamous cell carcinoma, pleomorphic sarcoma, Merkel cell carcinoma, and angiosarcoma, and an incisional biopsy was performed. Histopathological examination revealed an infiltrative neoplastic proliferation in the reticular dermis, composed of pleomorphic epithelioid and spindle cells, irregular vascular spaces containing red

blood cells, poorly differentiated solid areas, tumor necrosis, and atypical mitoses. Immunohistochemistry demonstrated diffuse positivity for CD31 and D2-40, with negativity for AE1/AE3, p63, S100, desmin, SMA, and CD34, ruling out squamous cell carcinoma, amelanotic melanoma, leiomyosarcoma, and undifferentiated pleomorphic sarcoma. Skull computed tomography confirmed an extensive lesion restricted to the scalp, with no bone involvement. En bloc surgical resection was indicated, along with evaluation for adjuvant radiotherapy and chemotherapy with paclitaxel.

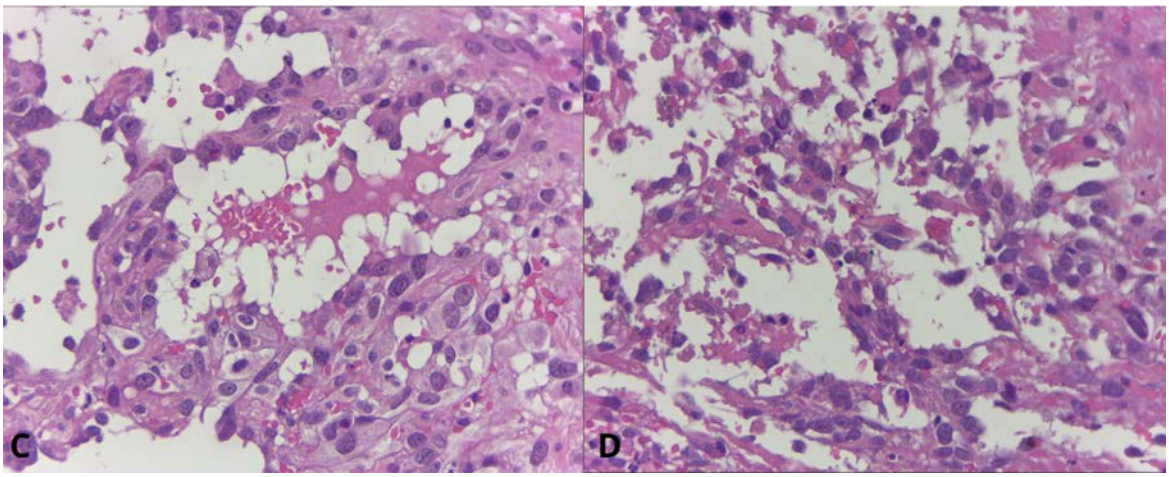

Figura C: Neoplastic cells with an epithelioid pattern, ample eosinophilic cytoplasm, vesicular nuclei and evident nucleoli, intracytoplasmic lumens containing red blood cells and atypical mitoses. HE, ×400. Figura D: Spindle cell component with cells arranged in sheets, marked nuclear atypia, frequent mitoses, and areas of tumor necrosis. HE, ×400.

Conclusion

This case illustrates the classic epidemiological profile of primary cutaneous angiosarcoma: an elderly man with an aggressive cephalic lesion and late diagnosis. Poorly differentiated variants represent a significant diagnostic challenge due to their resemblance to undifferentiated carcinomas, amelanotic melanoma, and pleomorphic sarcomas. Immunohistochemistry with CD31 as the most sensitive marker for endothelial differentiation and D2-40 for the lymphatic component was decisive for diagnostic confirmation and exclusion of differential diagnoses. Tumors larger than 5 cm, as in this case, are associated with a worse prognosis and lower overall survival. Treatment of cutaneous angiosarcoma remains challenging due to its high potential for local recurrence and metastatic dissemination. A multimodal approach involving surgery with wide margins, radiotherapy, and taxane-based chemotherapy offers better oncological outcomes. Immunotherapy with pembrolizumab and nivolumab has emerged as a promising option in advanced cases, although definitive evidence is still lacking. Overall prognosis remains poor, with five-year survival rates ranging between 9% and 40%. Early recognition and clinicopathological correlation with immunohistochemistry remain essential for improving outcomes in this rare and aggressive neoplasm.

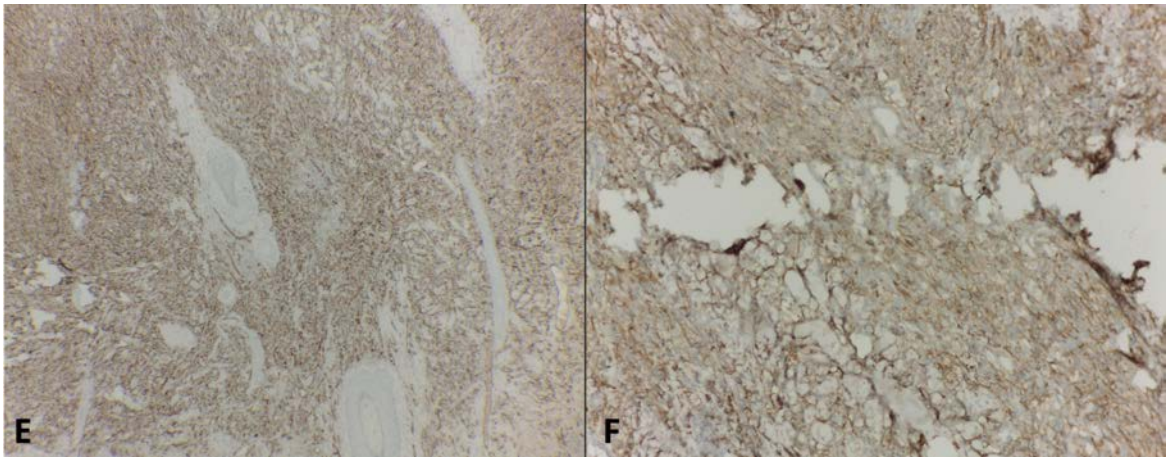

Figure E: CD31 positive. Diffuse endothelial staining confirming neoplastic vascular differentiation, consistent with angiosarcoma. IHC, ×100. Figure F: D2-40 positive. Membranous staining in neoplastic

cells lining irregular vascular channels, evidencing lymphatic differentiation in scalp angiosarcoma. IHC, ×200

EA DV CONGRESS
VIENNA
30 SEP - 3 OCT 2026

Abstract N°: 3078

Cutaneous Manifestations of Neurofibromatosis and Challenges of Diagnosis and Management in Uzbekistan: Current Perspectives in Dermatologic Care

Malika Solmetova*[1], Irodaxon Tulanova[2]

[1] Tashkent state medical university, Central asian university, Tashkent, Uzbekistan

[2] Central Asian University, Tashkent, Uzbekistan

Introduction

Neurofibromatosis (NF) is a group of hereditary neurocutaneous disorders characterized by multisystem tumor development and considerable clinical variability. In Uzbekistan and other Central Asian countries, delayed diagnosis, limited access to genetic testing, insufficient multidisciplinary care, and restricted availability of targeted therapies remain important healthcare challenges. Cutaneous manifestations, particularly in neurofibromatosis type 1 (NF1), are often the earliest detectable signs and may significantly impair psychosocial well-being and quality of life.

Materials and Methods

To review the dermatologic manifestations of neurofibromatosis and discuss current challenges in diagnosis, treatment accessibility, long-term monitoring, and preventive strategies in the context of Uzbekistan's healthcare system. A narrative literature review was conducted using PubMed/MEDLINE, Scopus, and Google Scholar databases. Publications from 2020–2026 related to NF1, NF2-related schwannomatosis, cutaneous manifestations, molecular pathways, targeted therapies, and healthcare challenges in low- and middle-income settings were analyzed. Clinical studies, review articles, and translational research papers were included.

Results

Cutaneous manifestations including café-au-lait macules, axillary freckling, and cutaneous neurofibromas remain major diagnostic indicators of NF1. However, in Uzbekistan, early recognition of these lesions is frequently delayed because of limited awareness among primary care physicians and restricted access to specialized dermatologic and genetic services. Plexiform neurofibromas may lead to severe functional impairment and carry a risk of malignant transformation into malignant peripheral nerve sheath tumors (MPNSTs).

Molecular dysregulation of the RAS/MAPK and PI3K/mTOR pathways plays a central role in tumorigenesis. Recent studies demonstrated that MEK inhibitors, particularly selumetinib, may reduce plexiform neurofibroma volume and improve clinical outcomes in selected patients. Nevertheless, the high cost and limited regional availability of targeted therapies create significant barriers to treatment in Uzbekistan.

Psychological stigma associated with visible cutaneous lesions, insufficient rehabilitation services, and lack of structured long-term surveillance programs further contribute to disease burden. Strengthening physician education, improving early screening, expanding genetic counseling services, and establishing multidisciplinary referral pathways may improve patient outcomes and quality of care.

Conclusions

Neurofibromatosis remains a lifelong multisystem disorder requiring coordinated multidisciplinary management. In Uzbekistan, improving early diagnosis, physician awareness, access to genetic evaluation, psychosocial support, and availability of modern targeted therapies represents an important priority. Further regional research and healthcare system development may contribute to earlier intervention and improved dermatologic and systemic outcomes in patients with neurofibromatosis.

EA DV CONGRESS
VIENNA
30 SEP - 3 OCT 2026

Abstract N°: 3080

ALK-positive anaplastic large cell lymphoma with cutaneous involvement: a case report.

Nidia Aguilar[1], Columba Navarro*[1], Earvin Loera[1], Renata Espejo[1], Anareli Ruvalcaba[1], Jose Lopez[2], Martha Melendez[1], Nancy Arreola[1], Natalia Figueroa[1]

[1] Mexican Social Security Institute-Regional General Hospital No. 180, Tlajomulco de Zuñiga, Mexico
[2] Mexican Social Security Institute-Western Medical Center, Guadalajara, Mexico

Introduction

Anaplastic large cell lymphoma (ALCL) is an uncommon CD30-positive mature T-cell lymphoma. In the United States, its estimated incidence is 0.25 cases per 100,000 individuals, representing approximately 3–5% of all non-Hodgkin lymphomas.[1] The World Health Organization (WHO) classifies ALCL into four entities: ALK-positive ALCL, ALK-negative ALCL, primary cutaneous ALCL, and breast implant-associated ALCL.[2] Diagnosis requires an integrated assessment of clinical manifestations, histopathologic findings, immunophenotypic profile, and disease extension, since different ALCL subtypes and their mimickers may exhibit CD30 positivity and similar morphologic features. However, each entity has distinct biological behavior and overall survival. [3,4]

Case Presentation

A 25-year-old female hospitalized patient with a history of untreated hypothyroidism. Evaluated by the dermatology department in March 2026 for six months history of skin lesions in the suprapubic, genital, and inguinal regions. Her clinical presentation included fatigue, unintentional weight loss, fever, abdominal pain, and lower extremity edema. Physical examination revealed a bilateral, localized, symmetrical dermatosis affecting the suprapubic, inguinal, and labia majora regions consistent of multiple exophytic nodular, pink and indurated tumors with a largest measured of 3 x 2.5 cm. Tumors with irregular borders and surface; accompanied by purulent discharge with apparently chronic course. The contrast-enhanced Computed Tomography (CT) scan showed cervical, axillary, mediastinal, para-aortic, retroperitoneal, and inguinal lymph node conglomerates, hepatosplenomegaly, pleural effusion, a solid right subpleural lesion, and a pelvic mass. Based on these findings, a neoplasm of unknown primary origin with cutaneous metastases was suspected. A skin biopsy was performed, which revealed a high-grade undifferentiated malignant neoplasm. The immunohistochemical profile showed diffuse strong positive CD30, positive CD45, positive CD3, patchy positive CD5, positive ALK, with negativity for Melan-A, CD138, CD20, CD10, AE1/AE3 and PAX5 (Figure 1). These findings supported the diagnosis of stage IV ALK-positive anaplastic large cell lymphoma. The patient died before chemotherapy could be administered.

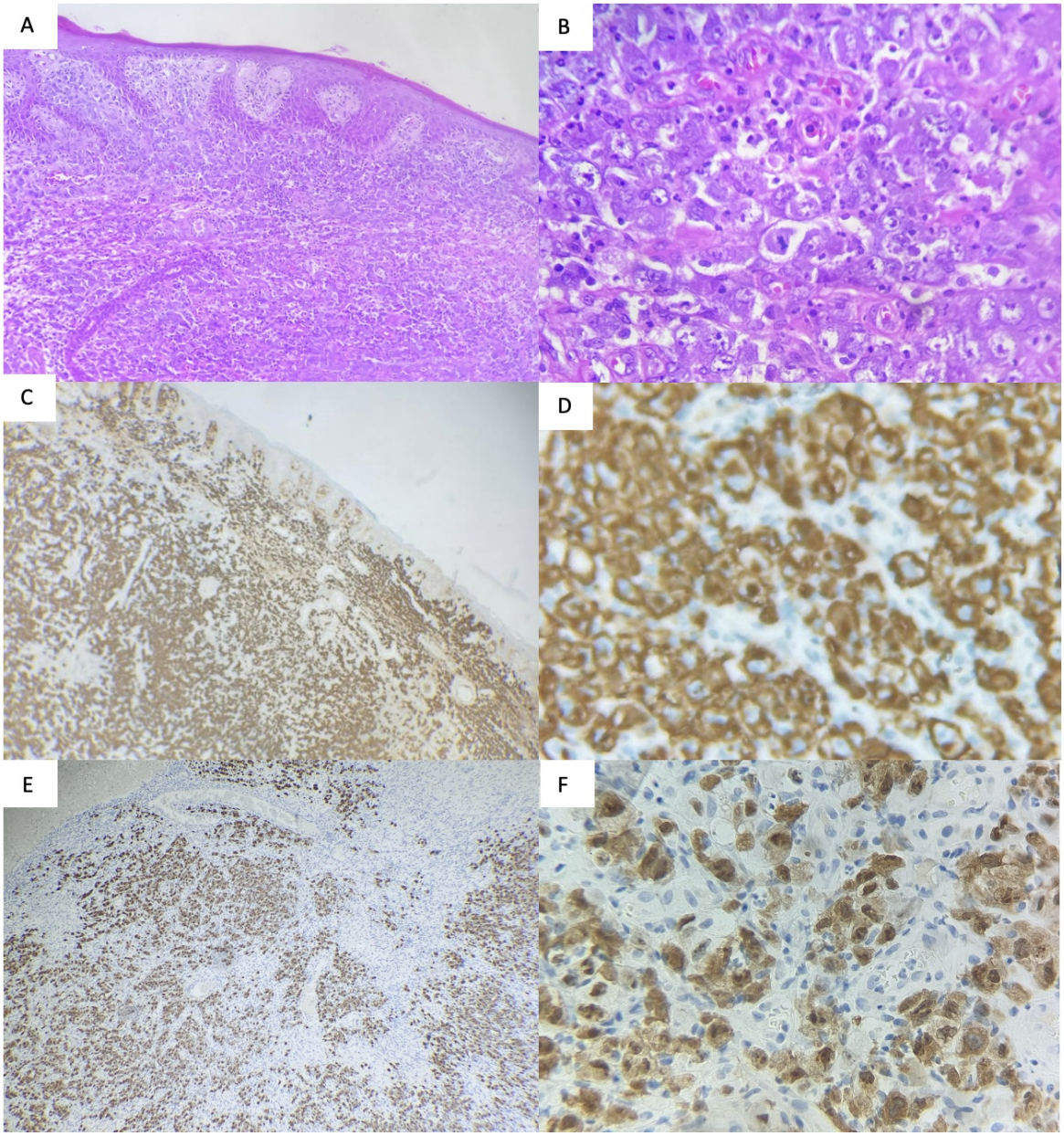

Figure 1.- A: Skin biopsy, hematoxylin and eosin (H&E) stain, 10×. B: H&E stain, 100×, showing a diffuse dermal infiltrate of large cells with atypical mitoses. C: Immunohistochemical (IHC) stain, 10×, showing neoplastic cells with diffuse and strong CD30 positivity. D: IHC stain, 100×, showing CD30 positivity. E: IHC stain, 10×, showing ALK-positive neoplastic cells. F: IHC stain, 100×, showing ALK positivity with diffuse granular cytoplasmic staining and intense nuclear staining.

Conclusion

Skin lesions can be the first manifestation of a systemic malignant disease. This case highlights the dermatological importance of suspecting a primary neoplasm with cutaneous involvement if persistent, ulcerated, painful, friable, or treatment-resistant skin lesions, especially when systemic symptoms and lymphadenopathy are present [2]. A multidisciplinary evaluation, together with early biopsy, immunohistochemistry, and clinicopathological correlation, is required to differentiate ALK-positive ALCL from primary cutaneous ALCL, as well as from other mimicking conditions, such as infections, metastases, epithelial melanocytomas, and other hematolymphoid tumors [3]. This is essential for early diagnosis and for defining a treatment plan.[4]

References

EA DV CONGRESS
VIENNA
30 SEP - 3 OCT 2026

Abstract N°: 3083

Integrative proteomic profiling to characterize the tumor microenvironment in infiltrative versus nodular basal cell carcinoma.

Kamila Anna Zub Carlsson*[1], Lars Hagen[2, 3], Animesh Sharma[2, 3], Katrine Høeg Liland[4], Geir Slupphaug[2, 3, 5], Øystein Sandanger[1, 6], Kristin Halvorsen Hortemo[1, 6]

[1] Department of Dermatology and Venereology, Oslo University Hospital, Oslo, Norway
[2] Department of Clinical and Molecular Medicine, Norwegian University of Science and Technology, Trondheim, Norway
[3] The Proteomics and Modomics Core Facility, PROMEC, at NTNU and the Central Norway Regional Health Authority, Trondheim, Norway
[4] Department of Pathology, Oslo University Hospital, Oslo, Norway
[5] Clinic of Laboratory Medicine, St. Olavs Hospital, Trondheim, Norway
[6] Institute of Clinical Medicine, Faculty of Medicine, University of Oslo, Oslo, Norway

Introduction

Basal cell carcinoma (BCC) is the most common human cancer. Although rarely metastatic, infiltrative BCC is locally destructive and prone to recurrence. The contribution of the tumor microenvironment (TME) to immune regulation and tumor behavior, particularly stromal components such as cancer-associated fibroblasts (CAFs) and extracellular matrix (ECM) remodeling, remains incompletely understood. This study aims to characterize stromal–immune interactions in BCC, with a particular focus on how infiltrative and nodular subtypes differ in immune polarization patterns.

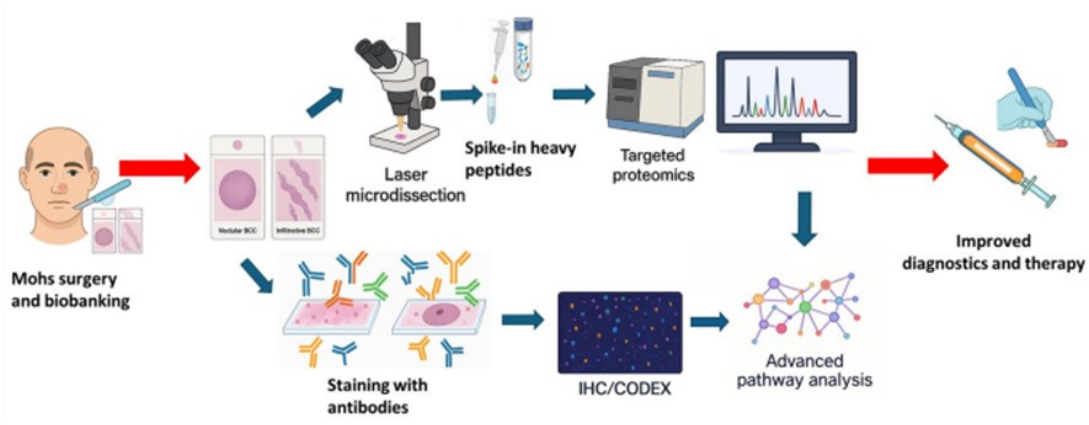

Figure 1. Workflow illustrating integrative proteomic and spatial analysis of stromal–immune interactions in nodular and infiltrative basal cell carcinoma, from Mohs surgery and biobanking through laser microdissection, targeted proteomics, and spatial validation using antibody-based imaging methods, including IHC and CODEX.

Materials and Methods

Label-free proteomics was performed on formalin-fixed paraffin-embedded tissue from 9 nodular and 9 infiltrative BCC samples obtained from patients undergoing Mohs surgery. Tumor and stromal regions were verified by dermatopathology and isolated by laser microdissection to enable compartment-specific analysis. Bioinformatic analysis included differential expression, pathway enrichment, and network analyses to identify subtype-associated biological programs. Based on peptide coverage, fold change, and biological relevance, a targeted proteomics panel was designed for parallel reaction monitoring. Spatial validation using immunohistochemistry (IHC), including multiplex IHC where feasible, is planned.

Results

Label-free profiling identified approximately 8,000 proteins in total, with 5,000–6,000 proteins per sample. Statistical analysis revealed 43 stromal and 112 tumor proteins that differed significantly between nodular and infiltrative BCC, although not all individual proteins remained significant after Benjamini–Hochberg correction. In contrast, multivariate pathway and network-enrichment analyses indicated coherent stromal programs. Infiltrative BCC demonstrated enrichment of ECM-remodeling and CAF-associated proteins, including periostin, COL11A1, tenascin-C, MMP14, and versican, consistent with an activated stromal phenotype. These stromal alterations were accompanied by immune-associated profiles suggesting an interplay between type 1 and type 2 inflammatory polarization, while type 3/inflammasome-related markers were retained for comparison. Tumor-compartment differences were present but comparatively subtle, suggesting that stromal remodeling and the invasive niche may contribute importantly to infiltrative behavior in BCC.

Conclusions

This study suggests that infiltrative BCC is characterized by a stromal microenvironment marked by CAF/ECM activation and associated immune polarization, consistent with a regulatory, matrix-remodeling phenotype. These findings highlight the potential role of stromal–immune interactions in driving aggressive tumor behavior. Ongoing targeted proteomics and spatial validation aim to further define these mechanisms and support the development of biomarkers in BCC.

EA DV CONGRESS
VIENNA
30 SEP - 3 OCT 2026

Abstract N°: 3087

Dead, discharged, or diagnosed: skin cancer outcomes of a Category 1 public dermatology waitlist audit

Emily Sisson[1, 2], Bruna Morassi Sasso*[3], Ishana Dixit[3, 4], Sera Sarsam[1, 2], Tricia Chiu[1], Pablo Fernandez-Peñas[3, 4]

[1] NSW Health, Sydney, Australia

[2] University of New South Wales, Sydney, Australia

[3] Westmead Hospital, Sydney, Australia

[4] University of Sydney, Sydney, Australia

Introduction

Public dermatology services globally face growing demand against a backdrop of rising skin cancer incidence. Constrained capacity results in prolonged waiting times for specialist review. Delayed access to dermatology carries significant clinical risk, particularly where malignant conditions are suspected. This study describes the clinical consequences of extended waiting times for patients triaged as high-priority (Category 1) on a public hospital dermatology outpatient waitlist.

Materials and Methods

Observational cohort study of all eligible Category 1 dermatology waitlist patients (n=496) identified at commencement of a waitlist reduction programme. Data were extracted from medical records and waitlist documentation. Waiting times, appointment outcomes, diagnoses, and treatment pathways following dermatology review were analysed.

Results

Of 496 eligible patients (median age 63 years, IQR 44–75; 50% female), median waiting time was 273 days (IQR 149–578) — nearly nine times the recommended 30-day benchmark — with 96% exceeding it. The longest wait was 1,354 days. Seventy-three patients (15%) were referred with biopsy-confirmed skin cancer and 257 (52%) for suspected skin cancer.

Of 258 patients booked for appointment, 223 attended (86%). Skin cancer was diagnosed in 62 attending patients (28%), including basal cell carcinoma (n=41), squamous cell carcinoma (n=15), melanoma (n=3), lentigo maligna (n=1), and Kaposi sarcoma (n=1). Twenty-two patients (10%) required surgical management within the service and a further 20 (9%) required referral for surgical management through other services following dermatology review. An additional 24 patients (11%) had already undergone skin cancer treatment privately before their public appointment.

Of 238 patients never booked, 232 were removed from the waitlist and 6 remained; reasons for removal included already seeking care elsewhere (n=91, 39%), being uncontactable (n=88, 38%), declining review (n=25, 11%), and death while waiting (n=13, 6%). Of the 13 deaths, one was attributed to skin cancer.

Conclusions

Patients triaged as requiring urgent dermatology review experienced prolonged delays far exceeding recommended benchmarks. Skin cancer was confirmed in over a quarter of attended patients, and nearly one in

five required surgical management — adding further delay to definitive treatment after already waiting a median of nine months for assessment. One patient died from skin cancer while awaiting review. Delayed diagnosis of skin cancer in regions of rising incidence carries clear clinical risk, and these findings highlight the cancer burden borne by patients on public dermatology waitlists internationally.

EADV CONGRESS
VIENNA
30 SEP - 3 OCT 2026

Abstract N°: 3088

Reflectance Confocal Microscopy–Optical Coherence Tomography- Guided Laser Ablation of Low-Risk Basal Cell Carcinoma: A Long-Term Prospective Follow-Up Study.

Noa Kremer*[1], Miguel Cordova[1], Cristián Navarrete Dechent[2], Ashfaq Marghoob[1], Melissa Gill[1], Milind Rajadhyaksha[1], Jason Chen Chih-Shan[1]

[1] Dermatology Service, Memorial Sloan Kettering Cancer Center, New York, United States
[2] Department of Dermatology, Facultad de Medicina, Pontificia Universidad Católica de Chile, Santiago, Chile

Introduction

Reflectance confocal microscopy–optical coherence tomography (RCM–OCT)–guided laser ablation enables real-time imaging assessment of tumor margins and immediate treatment within a single visit. However, long-term recurrence data remain limited. Therefore, our objective was to evaluate the long-term recurrence rate following RCM–OCT–guided Er:YAG laser ablation of low-risk BCC and to assess patient-reported outcomes.

Case Presentation

Methods:
This prospective cohort study included 104 patients with 148 BCCs evaluated using combined RCM–OCT imaging between 2017 and 2021. Lesions demonstrating low-risk superficial or nodular BCC characteristics and tumor depth ≤300 µm on RCM–OCT underwent same-day Er:YAG laser ablation with immediate post-treatment imaging to confirm clearance. Patients underwent clinical and RCM–OCT or RCM surveillance at 6 and 12 months and annually thereafter. A patient-reported questionnaire assessing satisfaction, scar appearance, and adverse effects was administered in 2023.

Results:
Fifty-eight lesions (39.2%) in 39 patients met eligibility criteria for laser ablation. Most lesions were located on the trunk (50.0%), with median tumor depth and lesion size of 200 µm and 9.8 mm, respectively. Immediate post-ablation RCM–OCT demonstrated imaging-defined complete tumor clearance after a single session in 53/58 lesions (91.4%). Residual tumor identified in 5/58 lesions (8.6%) was successfully treated during the same visit with additional laser passes. Fifty-four of 58 lesions (93.1%) had at least 6 months of follow-up, with a median follow-up duration of 32 months (range, 8–70 months). One recurrence occurred at 53 months and was successfully retreated, corresponding to 1.04 recurrences per 100 person-years of follow-up. Patient-reported questionnaire response rate was 79.5% (31/39). Overall, 96.8% reported acceptable scar appearance, 83.9% reported they would likely choose laser ablation again, and 9.7% reported mild transient adverse effects.

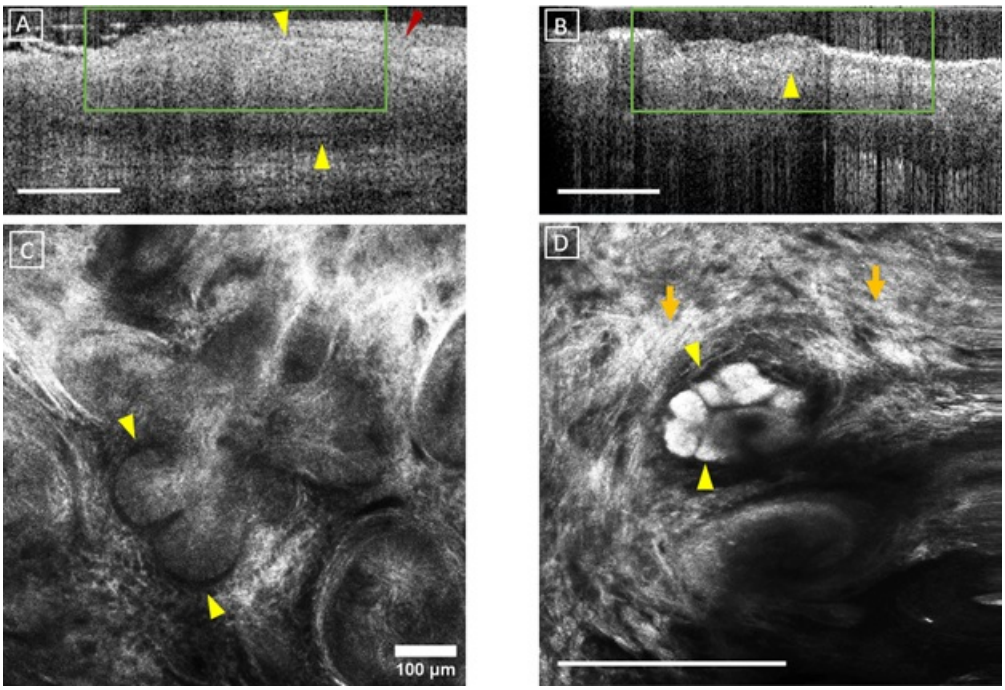

Pre–laser ablation (A and C) and post–laser ablation (B and D) RCM–OCT images of BCC. The upper panels show OCT images (A and B), and the lower panels show the corresponding RCM images (C and D). The green boxes in panels A and B denote the corresponding RCM imaging range within the OCT images.

Conclusion

RCM–OCT–guided Er:YAG laser ablation demonstrated low long-term recurrence rates and high patient satisfaction for selected low-risk BCCs. This imaging-guided “one-stop” treatment approach enables real-time assessment of tumor clearance and may represent a practical minimally invasive alternative for appropriately selected lesions.

EADV CONGRESS
VIENNA
30 SEP - 3 OCT 2026

Abstract N°: 3089

Clinicopathological and Dermoscopic Features of Cutaneous Squamous Cell Carcinomas With Perineural Invasion: A Retrospective Comparative Study

Andreas Dousis*[1], Panagiota Theofilogiannakou[1], Eftychia Kitsiou[1], Anna Syrmali[1], Sofia Theotokoglou[1], Dimitra Koumaki[1], Georgia Pappa[2], Vasileia Damaskou[3], Emmanouil Karampinis[4], Alexander Katoulis[1], Dimitrios Sgouros[1]

[1] 2nd Department of Dermatology and Venereology, "Attikon" General University Hospital, Medical School, National and Kapodistrian University of Athens, 12462, Athens, Greece
[2] 1st Department of Dermatology and Venereology, "Andreas Sygros" Hospital, Medical School, National and Kapodistrian University of Athens, 16121, Athens, Greece
[3] 2nd Department of Pathology, National and Kapodistrian University of Athens, Medical School, Attikon General University Hospital, 12 462, Athens, Greece
[4] Department of Dermatology, Faculty of Medicine, School of Health Sciences, University General Hospital of Larissa, University of Thessaly, 41110, Larissa, Greece

Introduction
Perineural invasion (PNI) is a recognized high-risk histopathological feature in cutaneous squamous cell carcinoma (cSCC), associated with aggressive biological behavior and increased risk of adverse outcomes. However, its correlation with dermoscopic morphology remains insufficiently characterized. The aim of this study was to compare the clinical, histopathological and dermoscopic features of cSCCs with and without PNI, in order to identify potential phenotypic patterns associated with this high-risk subgroup.

Materials and Methods
We retrospectively analyzed a cohort of histologically confirmed cSCCs, stratified according to the presence or absence of perineural invasion. Demographic, anatomical, histopathological and dermoscopic parameters were recorded and compared between PNI-positive and PNI-negative tumors. Histopathological variables included tumor differentiation, anatomical depth of invasion, vascular invasion and high-risk anatomical location. Dermoscopic features included vascular morphology, keratinizing structures, erosions, ulceration, crusting and white/yellow structures. Descriptive statistics were performed, and comparative analyses were interpreted with caution due to the limited number of PNI-positive cases.

Results
A total of 75 cSCCs were included, of which 6 cases were PNI-positive and 69 were PNI-negative. PNI was identified in 8% of tumors. Patients with PNI-positive cSCCs were older than those with PNI-negative tumors, with a mean age of 86.0 years versus 78.1 years, respectively. PNI-positive tumors showed a marked predilection for the head and neck region, particularly the face. Facial involvement was observed in 83.3% of PNI-positive tumors compared with 53.6% of PNI-negative tumors, while high-risk facial zone involvement was present in 66.7% and 26.1%, respectively.

Histopathologically, PNI-positive cSCCs demonstrated a substantially more aggressive profile. Poor differentiation was observed in 83.3% of PNI-positive tumors compared with 14.5% of PNI-negative tumors. In addition, PNI-positive tumors showed deeper anatomical invasion. Subcutaneous or muscular invasion was present in the majority of PNI-positive cases, and muscle invasion was observed exclusively in the PNI-positive group, affecting 50% of these tumors. By contrast, no PNI-negative tumor demonstrated muscle invasion. Vascular invasion was numerically more frequent among PNI-positive tumors, although the small sample size precluded definitive

conclusions.

Dermoscopically, PNI-positive cSCCs frequently displayed features suggestive of a more advanced and destructive tumor phenotype. Hairpin vessels, linear irregular vessels, polymorphous vascular pattern, erosions and ulceration were observed in all evaluable PNI-positive tumors. Crusting and white/yellow keratinizing structures were also frequent. Compared with PNI-negative tumors, PNI-positive cases appeared to show a more ulcerative, erosive and polymorphous vascular dermoscopic pattern. Interestingly, glomerular vessels were observed more frequently in PNI-negative tumors and were absent in the PNI-positive subgroup.

Conclusions

In this retrospective cohort, PNI-positive cSCCs represented a small but clinically distinct subgroup characterized by older patient age, preferential localization on the face and high-risk facial zones, poor histological differentiation and significantly deeper anatomical invasion, including muscle involvement. Dermoscopically, these tumors frequently exhibited polymorphous vascularity, linear irregular and hairpin vessels, erosions, ulceration, crusting and white/yellow keratinizing structures. Although limited by the small number of PNI-positive cases, these findings suggest that PNI-positive cSCCs may cluster within a broader aggressive clinicopathological and dermoscopic phenotype. Larger studies are needed to determine whether dermoscopy can contribute to preoperative suspicion of PNI in selected high-risk cSCCs.

EA DV CONGRESS
VIENNA
30 SEP - 3 OCT 2026

Abstract N°: 3098

Clinical, Histopathological, and Ultrasonographic Features of Eccrine Spiradenoma: A retrospective study of 14 cases

Jun Li*[1], Jingyi Lu[2]

[1] Shanghai Tenth People's Hospital, Shanghai, China

[2] Affiliated Nantong Clinical College of Nantong University, Nantong First People's Hospital, Nantong, China

Introduction

Eccrine spiradenoma (ES) is a rare benign adnexal tumor originating from the epithelial cells of eccrine sweat glands. It was first described by Kersting and Helwig in 1956. Since then, sporadic cases have been reported, mostly as individual case studies. ES lacks distinctive clinical features and usually presents as a solitary, firm, painful nodule that grows slowly and is difficult to differentiate clinically from epidermal cysts or dermatofibromas. Definite diagnosis relies on histopathology, and ES must be distinguished from other adnexal tumors such as dermal cylindroma and trichoepithelioma. Notably, ES can recur and may undergo malignant transformation into spiradenocarcinoma, an aggressive malignant counterpart. Therefore, a thorough understanding of the clinical and histopathological features of ES is essential for improving diagnostic accuracy and enabling timely treatment.

Materials and Methods

A retrospective case series spanning ten years was conducted. Fourteen patients with histopathologically confirmed ES, diagnosed between June 2015 and June 2025 in the Department of Dermatology were included. Diagnosis was confirmed independently by two dermatopathologists. Clinical data—including age, sex, symptoms, lesion site, lesion characteristics, clinical diagnosis, and histopathological findings—were collected from medical records. Ultrasonographic findings were reviewed when available.

Results

Of the 14 patients, the male-to-female ratio was 1:1.3, the mean age was 34.9 years, and the median disease duration was 4 years. Lesions most commonly presented as solitary, painful nodules on the trunk and were often red. Preoperative diagnosis was challenging, and no case was correctly identified before histopathological examination. Histology revealed well-circumscribed intradermal tumor lobules with a fibrous capsule, completely separate from the overlying epidermis. Two cell populations were present: small, hyperchromatic peripheral cells and larger central cells with pale eosinophilic cytoplasm. Ductal differentiation, abundant thin-walled vessels, and scattered lymphocytes were also observed. Two patients underwent ultrasonography, which demonstrated subcutaneous hypoechoic lesions, including a cystic lesion and a band-like hypoechoic structure. All patients were treated with complete surgical excision, and no recurrence was observed during follow-up.

Conclusions

Eccrine spiradenoma is a rare benign adnexal tumor that most commonly presents as a painful nodule on the trunk. The rate of accurate clinical diagnosis is very low, and definitive diagnosis depends on characteristic histological features: well-circumscribed intradermal lobules, two cell populations, and ductal differentiation.

Ultrasonography may assist in diagnosis. Complete surgical excision serves both diagnostic and therapeutic purposes, and recurrence is generally not observed after surgery. Given the rare risk of malignant transformation, clinically suspicious lesions should be promptly excised and examined pathologically, with proper postoperative follow-up.

EA DV CONGRESS
VIENNA
30 SEP - 3 OCT 2026

Abstract N°: 3101

Cutaneous Scalp Metastases Revealing Disease Progression in Breast Carcinoma

Flávia Thomé França*[1]

[1] Unicamp, Campinas, Brazil

Introduction

Cutaneous metastases from internal malignancies are relatively infrequent manifestations, affecting approximately 10% of patients with metastatic disease. Among women, breast cancer is the malignancy most commonly associated with cutaneous metastases. Although cutaneous metastases may occasionally precede the diagnosis of the primary tumor, they more frequently occur in the setting of a previously known neoplastic disease. The scalp, however, represents an uncommon site of metastatic involvement.

We report the case of a patient with a previous diagnosis of breast carcinoma who developed nodules on the scalp. Histopathological and immunohistochemical evaluation confirmed cutaneous metastases of breast origin. Until that time, the patient had been under clinical follow-up with apparent disease stability; however, the onset of the cutaneous lesions raised concern for neoplastic progression.

Case Presentation

A 77-year-old female patient presented with a hardened nodule in the occipital region for approximately four months, with no associated symptoms. On physical examination, a 4 cm lesion of stony-hard consistency was observed, adherent to deep tissue planes and associated with an overlying area of alopecia. In addition, the patient presented multiple smaller nodules, measuring between 0.5 and 1 cm, distributed across the occipital and bilateral parietal regions.

On dermoscopy, diffuse erythema, opaque vessels, and perifollicular scaling were observed.

Ultrasonography revealed a superficial solid nodule located in the occipital region, isoechoic, slightly heterogeneous, with no detectable Doppler flow, measuring approximately 2.4 × 1.0 × 1.8 cm.

The patient had a previous diagnosis of bilateral breast carcinoma, luminal A subtype, with bone metastasis at diagnosis in 2021, when palliative treatment was initiated. She received capecitabine, which was later discontinued in 2024 due to grade 3 hand-foot syndrome. After discontinuation, treatment was maintained with anastrozole and zoledronic acid. An incisional biopsy of the occipital lesion was performed.

Histological sections showed skin fragments in which the epidermis was lined by stratified squamous epithelium with areas of acanthosis. In the dermis, infiltration by an immature glandular epithelial neoplasm was observed, composed of cells with abundant cytoplasm and irregular, hyperchromatic central nuclei.

Immunohistochemistry revealed positivity for pancytokeratins, cytokeratin 7, and GATA3, as well as negativity for cytokeratin 20 and Melan-A.

The patient remains under palliative treatment; however, she shows progression of scalp metastases and progression of bone lesions on imaging studies.

Conclusion

The relevance of this report lies in the importance of considering cutaneous metastasis in the differential diagnosis of scalp nodules, especially in patients with a history of malignancy, even in the context of apparent clinical stability. In the present case, the onset of firm, alopecic scalp nodules represented a manifestation of disease progression in a patient with bilateral luminal A breast carcinoma. Although scalp involvement is uncommon, early recognition and appropriate histopathological and immunohistochemical investigation are essential, as cutaneous lesions may be the first clinical sign of systemic progression and may directly impact patient management.

EADV CONGRESS
VIENNA
30 SEP - 3 OCT 2026

Abstract N°: 3102

Lymphomatoid Papulosis in an Elderly Male: Atypical Chronic Presentation

Guilherme Gonçalves Nascimento*[1], Luisa Homem de Mello Maciel Campilongo[1], Claudio Lelis Souza[2]

[1] Faculdade de Medicina do ABC, Santo André, Brazil

[2] Universidade Professor Edson Antônio Velano, Alfenas, Brazil

Introduction

Lymphomatoid papulosis (LyP) is a rare CD30-positive cutaneous lymphoproliferative disorder characterized by chronic, recurrent and spontaneously regressing papulonodular skin lesions. It typically presents as crops of lesions that self-resolve within weeks to months, leaving varioliform scars. LyP belongs to the spectrum of primary cutaneous CD30-positive T-cell lymphoproliferative disorders and is associated with an increased risk of developing secondary lymphoid malignancies, including mycosis fungoides, primary cutaneous anaplastic large cell lymphoma, systemic anaplastic large cell lymphoma, or Hodgkin lymphoma in 15-20% of patients. The diagnosis requires careful clinicopathologic correlation, as histologic features alone may be indistinguishable from malignant lymphomas.
We report a case of Lymphomatoid Papulosis in an elderly man, which presented as a chronic non-resolving papular lesion.

Case Presentation

A 62-year-old male patient presented to the dermatology outpatient clinic with a chief complaint of a "wart" on the trunk. The patient reported a longstanding lesion present for several years, which demonstrated progressive growth and developed local pain over the preceding three months. Dermatological examination revealed erythematous, shiny, confluent papules forming a well-delimited 2 cm plaque with pseudovesicular appearance and infiltration. Given the atypical presentation, a biopsy was performed for histopathological examination. Histopathological analysis with immunohistochemical staining confirmed the diagnosis of lymphomatoid papulosis type A by revealing CD30-positive large atypical lymphocytes. The lesion was surgically excised with wide margins to ensure complete removal. The patient was subsequently referred to clinical oncology for long-term follow-up for secondary lymphoid malignancies.

Conclusion

Chronic non-resolving papular or plaque-like lesions in elderly patients represent unusual presentations of lymphomatoid papulosis that may mimic more common dermatoses or cutaneous malignancies. This case emphasizes that LyP should be included in the differential diagnosis of persistent cutaneous lesions, even when the classic pattern of recurrent, self-healing papulonodules is absent. Early biopsy with comprehensive immunohistochemical analysis is crucial for accurate diagnosis and appropriate management, as clinical presentation alone may be insufficient to distinguish LyP from other CD30-positive lymphoproliferative disorders.

POWERED BY M-ANAGE.COM

EADV CONGRESS
VIENNA
30 SEP - 3 OCT 2026

Abstract N°: 3110

Efficacy of Immunocryosurgery in Patients with Gorlin-Goltz Syndrome

Piotr Janicki*[1], Joanna Zalewska-Gryszko[1], Iwona Czarnecka[1], Monika Słowińska[1], Anna Kozera[1], Nina Wiśniewska[1], Agnieszka Terlikowska-Brzósko[1], Karol Pniewski[1], Witold Owczarek[1]

[1] Department of Dermatology, Military Institute of Medicine - National Research Institute, Warsaw, Poland

Introduction

Gorlin-Goltz syndrome (GGs) is a rare genetic syndrome causing multiple basal cell carcinomas (BCCs). Patients with GGs require repeated disfiguring surgical and adjuvant procedures. Immunocryosurgery (ICS) is a therapeutic method that combines topical application of imiquimod (IMQ) and cryotherapy. While it has been investigated in treatment of BCC with effectiveness reaching 97%, to date, no studies have evaluated the use of ICS specifically in patients with GGs.

Materials and Methods

This retrospective study was based on videodermoscopic documentation of 9 patients with GGs, ineligible for surgical resection, with multiple BCCs regardless of their subtype, less than 2cm in diameter, treated with ICS (Table 1.) Whenever dermoscopic structures of BCC were found during the control visit, the treatment cycle was repeated as needed. The sites were monitored for 3 months after dermoscopic clearance. The effectiveness of ICS on selected tumors was assessed based on the videodermatoscopic images that were taken before and after the course of treatment.

Cycle part	Duration / timing
Topical IMQ once daily	Day 0-13 (14 days)
Cryotherapy with two 10-second freeze-thaw cycles	Day 14

Table 1. Timeline of an ICS cycle.

Results

A total of 170 lesions were included in the study. Based on dermoscopic and videodermoscopic follow-up 68,8% (n = 117) of tumors resolved after one ICS cycle, while 31,2% required more than one cycle (up to four) (Table 1.). No lesions were resistant to treatment. 11 relapses (6,5%) were observed during the three-month follow-up period. One complete remission of a non-treated concurrent nodular BCC scheduled for surgical resection was observed due to abscopal effect. Adverse events (AEs) included ulcers, erosions, localized superinfections. No severe AEs were observed and no patients refused to continue treatment despite AEs.

Anatomic site	Total lesions	1 cycle	2 cycles	3 cycles	4 cycles	Relapse rate
Face	44	30 (68.2%)	7 (15.9%)	7 (15.9%)	0	4 (9.1%)

Table 2. ICS cycles required for BCC clearance and relapse rate by anatomic site.

Conclusions

Our study demonstrates that ICS may decrease the number of BCCs in GGS patients reducing the number of surgical resections and delivering satisfactory cosmetic results. However, the treatment efficacy in our group with GGs was lower than in the general population without a genetic predisposing factor. However, further studies with longer follow-ups are needed to determine appropriate long-term management and relapse rate.

EADV CONGRESS
VIENNA
30 SEP - 3 OCT 2026

Abstract N°: 3117

Multinucleate Cell Angiohistiocytoma at the Columella–Nasal Vestibule Junction in a Male: Dermoscopic and Ultraviolet-Induced Fluorescence Findings

Andrea Fernández Carrillo[1], Mariana Santos Lopes Da Conceição*[1], Daniela Martinez[1], Mariana Treu[1], Curt Mafra Treu[1]

[1] Policlinica Geral do Rio de Janeiro, Rio de Janeiro, Brazil

Introduction

Multinucleate cell angiohistiocytoma (MCAH) is a rare benign cutaneous proliferation of vascular and fibrohistiocytic origin, predominantly reported in middle-aged women and usually affecting the extremities or face. Approximately 150 cases have been described in the literature. We report an unusual case combining two atypical features: male sex and involvement of the columella–nasal vestibule junction, a site not previously reported. Additionally, we describe multimodal dermoscopic findings, including ultraviolet-induced fluorescence.

Case Presentation

A 50-year-old man presented with asymptomatic confluent erythematous papules involving the left columella–nasal vestibule junction. Due to the patient's history of NMSCs, age, and the high-risk anatomical location, the primary clinical suspicion was basal cell carcinoma. Polarised dermoscopy revealed linear irregular vessels and fine whitish polygonal structures over a pink background. Ultraviolet-induced fluorescence dermoscopy demonstrated a brownish-erythematous background with central whitish fluorescent structures and scattered bright pinpoint dots, a pattern not previously described in MCAH. An excisional biopsy was performed. Histopathological examination showed ectatic dermal vessels associated with sparse stellate multinucleated histiocytoid cells within the superficial dermis. Serial sectioning excluded basal cell carcinoma and confirmed the diagnosis of multinucleate cell angiohistiocytoma.

Conclusion

This case broadens the recognised clinical and dermoscopic spectrum of MCAH by describing a previously unreported presentation at the columella–nasal vestibule junction in a male patient. The unusual mucocutaneous location supports the hypothesis that MCAH may represent a reactive process triggered by chronic local mechanical or inflammatory stimuli. Dermoscopic findings were consistent with previously described vascular and whitish stromal features, while the ultraviolet-induced fluorescence findings represent, to our knowledge, the first description of this imaging modality in MCAH. Recognition of this entity and correlation between multimodal imaging and histopathology are important to avoid misdiagnosis as malignancy in high-risk facial sites.

EA DV CONGRESS
VIENNA
30 SEP - 3 OCT 2026

Abstract N°: 3123

Pleomorphic sarcoma with atypical exuberant acral presentation associated with intracavitary cardiac tumor: a case report

Rodrigo Scabora*[1], Maria Eugênia Dumont Adams Prudente Corrêa[1], Guilherme Reche[1], Paulo Ricardo Criado[1], Francisco Macedo Paschoal[1], Carlos D Apparecida Santos Machado Filho[1]

[1] Centro Universitário FMABC, Santo André, Brazil

Introduction

Sarcomas are malignant neoplasms of mesenchymal origin. Less commonly, they may involve the skin. Although a variety of histological subtypes exist, they are generally associated with severity and rapid progression. We present an exuberant and atypical case in terms of tumor size and acral topography, as well as its association with intracardiac masses potentially related to the cutaneous presentation.

Case Presentation

We report a case of a 81-year-old woman who presented with a 3-month history of skin lesions. Dermatological examination revealed an exuberant tumor involving the left first digit, somewhat pedunculated, vegetating, ulcerated and necrotic, with an erythematous and infiltrated base extending to the entire digit (Figure 1a). Additional lesions were present on the knee, consisting of smooth, firm, erythematous-violaceous nodules on palpation (Figure 1b). Few discrete erythematous papules were also observed on some fingertips (Figure 1c). The lesions began on the right knee and resembled erythematous papules that rapidly evolved into firm nodules. Subsequently, digital lesions appeared, with the most exuberant involving the left first digit. Frequent bleeding was reported, particularly from the tumorous lesion involving the affected digit. The clinical history was notable for significant sun exposure for approximately 30 years. A transthoracic echocardiogram was performed, which revealed multiple intracavitary formations adhered to the left atrium, multiple sessile masses affecting the interatrial septum, pulmonary veins, and atrial appendage (Figure 2). Skin biopsies and histopathological results from both the left first digit and the knee were consistent with the diagnosis of pleomorphic sarcoma, with the knee lesion raising suspicion for metastatic disease (Figure 3a-f). Immunohistochemical findings were also consistent with the diagnosis (Figure 4a-i).

Conclusion

The present case describes a dermal pleomorphic sarcoma, an aggressive tumor of low prevalence that typically affects older individuals. It may present rapid progression, local recurrence, and metastasis, most frequently involving the skin, lymph nodes, and lungs. Although rare, some studies describe cases of cardiac metastasis. Its clinical presentation may mimic several malignant cutaneous conditions, making diagnosis challenging. We present a case of an uncommon skin disease, highlighting an atypical exuberant acral presentation associated with indeterminate cardiac masses potentially related to the cutaneous manifestation, further contributing to the rarity of this case. We also highlight the importance of prompt action to establish an accurate diagnosis and treatment, reducing morbidity and unfavorable outcomes related to the condition.

EADV Congress 2026, VIENNA
30 SEPTEMBER - 03 OCTOBER 2026
POWERED BY M-ANAGE.COM

EA DV CONGRESS
VIENNA
30 SEP - 3 OCT 2026

Abstract N°: 3129

Cutaneous metastasis from breast carcinoma presenting as an atypical atrophic frontotemporal plaque with cervical infiltration: a case report and literature review

Julia Lessa Bretas*[1], Antonio Augusto Claudio Pereira[1], Nurimar Conceição Fernandes[1]

[1] UNIVERSIDADE FEDERAL DO RIO DE JANEIRO, Rio de Janeiro, Brazil

Introduction

Cutaneous metastases are secondary neoplastic lesions disseminated from a primary tumor through lymphatic or hematogenous routes. Although uncommon, they occur in 0.7%–10.4% of cancer patients and account for about 2% of cutaneous tumors. In women, breast carcinoma is the malignancy most frequently associated with skin metastases, corresponding to nearly 24% of cases. The anterior chest wall is the most affected site, followed by the abdomen, scalp, and head and neck regions. In approximately one-third of patients, cutaneous metastasis may precede the diagnosis of the primary tumor, whereas in others it represents tumor recurrence.

Clinical presentation is highly variable and includes papules, nodules, infiltrated plaques, erysipeloid lesions, sclerodermiform (“en cuirasse”) patterns, and neoplastic alopecia. Such variability may delay diagnosis, especially when lesions mimic benign inflammatory or infectious dermatoses. National dermatologic literature has contributed substantially to the recognition of atypical and late manifestations of breast carcinoma cutaneous metastases.

Case Presentation

A 68-year-old woman with previous breast carcinoma presented with a frontal cutaneous lesion evolving over three months. Physical examination revealed a large erythematous atrophic plaque, hardened and adherent to deep planes, with telangiectasia and a small alopecic area on the left frontotemporal region.

Additionally, extensive cervical infiltration forming a hardened infiltrative plaque with reduced local skin mobility was observed.

The condition progressed without significant systemic symptoms. Considering the oncologic history and infiltrative pattern, skin biopsy was performed. Histopathological examination demonstrated dermal infiltration by atypical epithelial cells compatible with cutaneous metastasis of breast carcinoma. The clinical presentation was unusual because of the association of an atrophic frontal plaque with diffuse cervical infiltration, suggesting marked regional lymphatic dissemination.

Conclusion

Cutaneous metastases from breast carcinoma show a broad morphological spectrum and are classically described as normochromic or erythematous hardened nodules predominantly affecting the anterior chest wall. However, atypical infiltrative, inflammatory, alopecic, and sclerodermiform forms are increasingly recognized.

The present case is notable for the atrophic frontal plaque associated with extensive cervical infiltration, an uncommon presentation that may mimic cicatricial dermatoses, morphea, cellulitis, carcinoma erysipeloides, cutaneous lymphoma, or sclerodermiform basal cell carcinoma. The small alopecic area may result from follicular

destruction induced by neoplastic cells, as described in neoplastic alopecia secondary to breast carcinoma.

Diffuse cervical infiltration suggests predominantly lymphatic dissemination, frequently implicated in breast carcinoma skin metastases. In general, cutaneous metastases indicate advanced systemic disease and poorer prognosis, especially when visceral metastases coexist. Nevertheless, delayed presentations years after treatment of the primary tumor have also been reported.

Previous studies emphasize the importance of detailed dermatologic evaluation in oncologic patients, since dermatologists may be the first physicians to suspect an internal malignancy from metastatic skin lesions. Definitive diagnosis depends on clinicopathological correlation, often complemented by immunohistochemistry.[2] Early recognition of suspicious lesions is prognostically relevant and allows appropriate systemic investigation and multidisciplinary management.

EADV CONGRESS
VIENNA
30 SEP - 3 OCT 2026

Abstract N°: 3148

CD20-Negative High-Grade Transformation of Follicular Lymphoma With Secondary Cutaneous Involvement

Miguel Angel Nieto Bayona*[1], Hector Perez[1], Daniela Martinez Barreto[1], Juan Sebastian Sanchez Solarte[1]

[1] Universidad Nacional de Colombia, Bogotá, Colombia

Introduction

Follicular lymphoma (FL) is the most common B-cell non-Hodgkin lymphoma. Although usually indolent, it may transform into diffuse large B-cell lymphoma or high-grade B-cell lymphoma (HGBL) in approximately 2–3% of patients per year. Transformation is associated with increased proliferation and c-MYC/BCL2 double expression, a phenotype linked to poor prognosis. Secondary skin involvement is uncommon and diagnostically challenging and may delay recognition.

Case Presentation

A 69-year-old man presented with 9 days of firm pink scalp nodules, later spreading to the axillae and groin, with violaceous papules on the costal margin, left supraclavicular region, and lumbar area. Lesions were asymptomatic and spared adnexa. His history included low-grade FL transformed to high-grade disease (CD20-negative double expressor), deep vein thrombosis, smoking, and chronic alcohol use. He was receiving DHAP chemotherapy (dexamethasone, cytarabine, and cisplatin), anti-infective prophylaxis, and multiple transfusions.

Relapse, neutrophilic eccrine hidradenitis, and eccrine syringometaplasia were considered. Skin biopsy showed an atypical lymphoid infiltrate with epidermotropism, positive for PAX5 and CD19, confirming B-cell lineage. MUM1 and CD10 were positive, the latter supporting germinal-center origin. BCL2 and c-MYC were expressed, while CD34, TdT, BCL6, and CD5 were negative. Ki-67 was 100%, establishing CD20-negative HGBL with c-MYC/BCL2 double expression. Despite treatment, he developed hemophagocytic syndrome and fatal cerebral hemorrhage.

FL is a mature B-cell lymphoma derived from germinal-center cells with usually favorable prognosis, but it may transform into aggressive lymphoma. Transformation occurs in about 2% of patients per year, with a 5-year risk of 10.7%, reflecting additional mutations and a marked clinical shift.

Bone marrow biopsy showed 100% HGBL infiltration, grade 1 myelofibrosis, and CD20−, CD19+, PAX5+, MUM1+, CD10+, BCL2+, and c-MYC+ in >60% of cells. PAX5 and CD19 confirmed B-cell lineage despite CD20 loss, while CD10 indicated germinal-center differentiation. c-MYC/BCL2 double expression is associated with chemoresistance and aggressiveness, supported by Ki-67 of 100%.

CD20 is expressed by most mature B lymphocytes and is the target of rituximab. The initial FL was CD20-positive, but expression was lost after anti-CD20-containing treatment, consistent with clonal selection under therapeutic pressure. This loss occurs in 12–60% of recurrent lymphomas, reducing expected CD20-therapy efficacy.

Cutaneous involvement by systemic B-cell lymphomas must be distinguished from primary cutaneous lymphomas because prognosis and treatment differ. Here, skin biopsy showed concordance between cutaneous and systemic infiltrates. Reported cutaneous involvement ranges from 1.5% to <10%. It may appear as erythematous or violaceous papules, plaques, nodules, or tumors on the trunk, extremities, head, or neck, mimicking infections or

adnexal tumors.

Conclusion

The case shows an uncommon cutaneous manifestation of HGBL with CD20 negativity, suggesting clonal selection and reduced usefulness of CD20-targeted therapy. Secondary skin involvement may mimic adnexal tumors or infections; biopsy confirms infiltration and its systemic correlation. c-MYC/BCL2 coexpression plus Ki-67 of 100% correlated with a rapidly fatal course despite intensive chemotherapy, underscoring adverse prognosis.

EADV CONGRESS
VIENNA
30 SEP - 3 OCT 2026

Abstract N°: 3149

Leukemia Cutis Along Langer's Lines: An Unusual Initial Presentation of Acute Myeloid Leukemia

Maha Al housni*[1], Ayida Al Khalili[2]

[1] Oman medical specialty board, Muscat, Oman
[2] Sultan Qaboos University Hospital, Muscat, Oman

Introduction

Leukemia cutis is an uncommon extramedullary manifestation of acute myeloid leukemia (AML) resulting from infiltration of leukemic cells into the skin. It may occasionally precede the diagnosis of systemic leukemia and is associated with aggressive disease behavior and poor prognosis. Certain molecular subtypes of AML, particularly those harboring FLT3 mutations, have been associated with an increased tendency for extramedullary involvement. Recognition of characteristic cutaneous findings is essential, as early dermatologic evaluation may facilitate prompt diagnosis of an underlying hematologic malignancy.

Clinically, leukemia cutis demonstrates considerable morphologic heterogeneity and may mimic a wide spectrum of dermatologic conditions. Reported atypical presentations include localization at sites of trauma, surgical scars, vascular access sites, and areas of prior skin injury, suggesting that local inflammatory or microenvironmental factors may contribute to leukemic skin homing.

In the present case, the distribution of lesions along Langer's lines represents an exceedingly uncommon presentation. This pattern may reflect hematogenous dissemination with preferential infiltration along cutaneous structural planes, clinically resembling dermatoses known to follow similar distributions, such as pityriasis rosea and guttate psoriasis. Recognition of such unusual morphologic and distributional patterns is important to avoid diagnostic delay and to broaden the recognized clinical spectrum of leukemia cutis presentations.

Case Presentation

A 40-year-old female presented with progressive asymptomatic erythematous-to-violaceous papules and nodules initially involving the lower extremities, with subsequent spread to the trunk. The lesions followed a striking distribution along Langer's lines. In the setting of constitutional B symptoms, lymphadenopathy, abnormal hematologic parameters, and characteristic skin findings, leukemia cutis was strongly suspected. Histopathological examination of a skin biopsy demonstrated diffuse dermal infiltration by atypical leukemic blast cells, confirming the diagnosis of leukemia cutis. Subsequent hematologic evaluation established the diagnosis of FLT3- and NPM1-mutated acute myeloid leukemia. The cutaneous manifestations constituted the initial presentation of the underlying malignancy.

Conclusion

This case underscores leukemia cutis as a significant dermatologic manifestation of underlying acute myeloid leukemia and highlights the crucial role of early dermatologic recognition in facilitating prompt diagnosis of systemic malignancy. The distinctive distribution of lesions along Langer's lines represents a rare and clinically instructive morphological pattern that is infrequently reported in the literature.

EA DV CONGRESS
VIENNA
30 SEP - 3 OCT 2026

Abstract N°: 3163

Breast Skin Involvement Revealing Relapse of Diffuse Large B-Cell Lymphoma

Bounneche Houda*[1], Tarek Mansoul[1], RIADH BOUSSAID[1], Amel Gherfi[1], esma bouhila[1], khadidja bouarroudj[1], kaghouche lilia[1], safa djebbas[1], Ahmed Samaouel Chehad[1]

[1] Department of Dermatology, University Hospital, Constantine, Algeria

Introduction

Secondary cutaneous involvement in non-Hodgkin lymphomas is rare and often reflects advanced systemic disease or relapse. Breast localization of diffuse large B-cell lymphoma (DLBCL) is exceptional and may mimic inflammatory breast cancer. These cutaneous manifestations represent a significant diagnostic challenge, particularly in patients receiving chemotherapy and thoracic radiotherapy. We report the case of a patient presenting with secondary cutaneous breast involvement revealing relapse of DLBCL.

Case Presentation

We report the case of a 48-year-old woman followed for bulky systemic diffuse large B-cell lymphoma (DLBCL) with right axillary involvement, treated with chemotherapy and thoracic radiotherapy. She presented with painful infiltrated erythematous plaques with a peau d'orange appearance and ulceronecrotic areas involving the right breast, evolving over the preceding 15 days. Breast ultrasound revealed cutaneous and subcutaneous edematous infiltration associated with a conglomerate of right axillary lymphadenopathies. Skin biopsy showed a diffuse infiltrative tumoral proliferation composed of large atypical lymphoid cells with prominent nuclei and numerous mitoses. Immunohistochemistry demonstrated positivity for CD79a, CD10, BCL2, and BCL6, with a Ki-67 proliferation index estimated at 90%. Overall clinicopathological findings were consistent with secondary cutaneous metastasis of DLBCL. Adaptation of chemotherapy failed to induce clinical improvement, leading to the initiation of palliative management

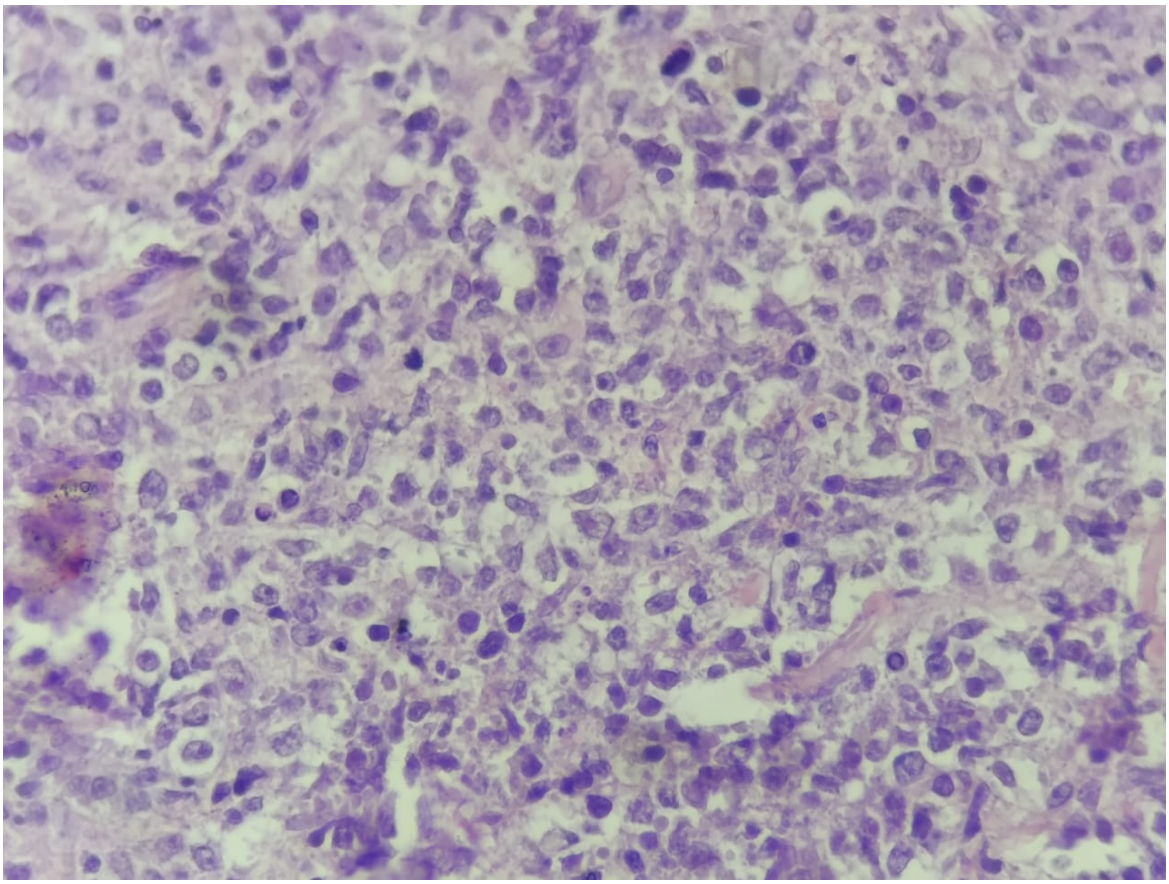

Diffuse Dee dermal infiltration by large atypical lymphoid cells

Conclusion

In our patient, secondary breast cutaneous involvement developed in the setting of systemic DLBCL treated with chemotherapy and thoracic radiotherapy. Breast localization, characterized by infiltrated plaques with a peau d'orange appearance, pain, and partially ulceronecrotic lesions, represented a major diagnostic pitfall, potentially mimicking breast carcinoma, post-radiation dermatitis, infection in the setting of immunosuppression, or chemotherapy-induced cutaneous toxicity. Cutaneous biopsy with histopathological and immunohistochemical analysis confirmed the diagnosis. Positivity for B-cell markers (CD79a), germinal center markers (CD10, BCL6), and the high proliferation index (Ki-67 ≈ 90%) confirmed the secondary nature of the involvement. The absence of response to chemotherapy adjustment highlights the severity and poor prognosis associated with cutaneous metastatic forms and underlines the importance of rapid and accurate recognition of these manifestations.

Secondary breast cutaneous involvement in DLBCL is rare. It represents a true diagnostic challenge in this particular context of immunosuppression, radiotherapy, and polypharmacy.

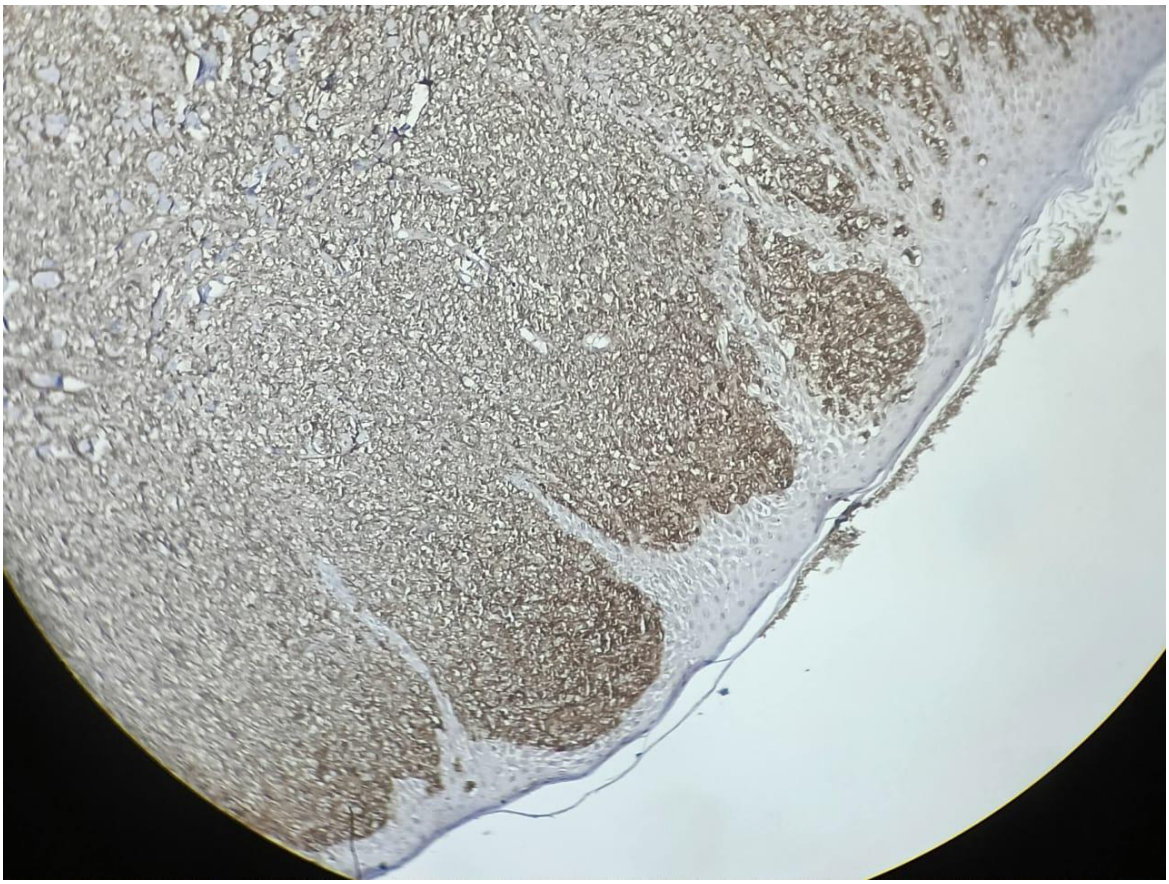

CD79a

EADV CONGRESS
VIENNA
30 SEP - 3 OCT 2026

Abstract N°: 3168

Kaposi sarcoma masking acral melanoma: diagnostic pitfalls and lessons learned

Mouna Frikha*[1], Soumaya Gara[1], Noureddine Litaiem[1], Meriem Fatnassi[1], Soumaya Rammeh[2], Meriem Jones[1], Faten Zeglaoui[1]

[1] Dermatology department, Charles nicolle Hospital, Tunis, Tunisia
[2] Pathology department, Tunis, Tunisia

Introduction

Violaceous lower-limb plaques and nodules strongly suggest Kaposi sarcoma, especially when bilateral and partially responsive to bleomycin. However, acral melanoma may present similarly, causing diagnostic delay. We report acral melanoma mimicking Kaposi sarcoma, with synchronous contralateral HHV-8-positive Kaposi sarcoma.

Case Presentation

An 88-year-old woman with hypertension presented with a 4-year history of a right heel nodule, previously excised without available histology. She later developed bilateral erythematous-violaceous plaques and firm nodules involving the lower limbs and feet. Kaposi sarcoma was initially suspected, and intramuscular bleomycin was started.

The first right ankle biopsy showed atypical dermal tumor cells with frequent mitoses and diffuse nuclear SOX10 expression, favoring melanoma. A second biopsy revealed atypical nested melanocytic proliferation with focal melanin pigment, frequent mitoses, epidermal ulceration and a lentiginous intraepidermal component, supporting acral lentiginous melanoma in nodular phase. Further biopsies from the right foot and plantar nodules confirmed nodular melanoma without evidence of Kaposi sarcoma.

Clinically, the right lower limb showed a bulky ulcerated violaceous tumoral plaque, compatible with advanced acral melanoma with possible satellite or in-transit metastases. Computed tomography showed right inguinal lymphadenopathies without visceral metastases.

Because left-sided nodular lesions had partially regressed after bleomycin, contralateral biopsy was performed. Histology showed irregular vascular structures, lymphoplasmacytic infiltrate and siderophages, without melanocytic proliferation. Nuclear HHV-8 expression confirmed Kaposi sarcoma. Bleomycin was discontinued, and further management included immunotherapy and palliative radiotherapy.

The particularity of this case lies in the coexistence of two clinically overlapping tumors: right-sided acral melanoma presenting as Kaposi-like violaceous nodules, and true contralateral HHV-8-positive Kaposi sarcoma. The confirmed Kaposi component, bilateral distribution and partial response to bleomycin contributed to delayed melanoma recognition and could have led to inappropriate continuation of Kaposi-directed therapy alone.

Similar pitfalls have been reported: melanoma may masquerade as Kaposi sarcoma, while Kaposi sarcoma has also been described in melanoma patients, particularly with immune dysregulation or targeted therapy. Our case combines both issues, making lesion-by-lesion assessment essential.

Conclusion

This case emphasizes that a single diagnosis should not be assumed in extensive or atypical violaceous lower-limb lesions. Lesions differing in morphology, progression or treatment response should be biopsied separately, with clinicopathological correlation and broad immunohistochemistry to avoid delayed melanoma diagnosis and inappropriate treatment.

EA DV CONGRESS
VIENNA
30 SEP - 3 OCT 2026

Abstract N°: 3190

Adenoid Basal Cell Carcinoma: A Series of 5 Patients

Hamzaoui Soumia*[1], samia khalifa[2], chikhbled nadjet[1], Serradj Amina[1]

[1] Oran University Hospital Establishment, Department of Dermatology, Oran Faculty of Medicine, Oran, Algeria
[2] Oran University Hospital Establishment, Department of Anatomical Pathology, faculté de médecine d'Oran., Oran, Algeria

Introduction

Basal cell carcinoma (BCC) is the most common skin tumor (1). Among its histological subtypes is adenoid BCC, a rare variant of the nodular subtype (2). We report a series of five cases of adenoid BCC.

Case Presentation

Materials and Methods:

This was a prospective study conducted over a period of five years, from September 2019 to August 2024, at the University Hospital Establishment of Oran , involving patients with BCC. Data were collected using a pre-established data sheet.

Résults :

Among the 178 BCC lesions recorded, five corresponded to the adenoid form, representing 2.8% of patients. The characteristics of these five patients were as follows: the mean age was 68.2 years, ranging from 61 to 77 years; the male-to-female ratio was 1.5 (3 men and 2 women); and the predominant phototype was type III. Intermittent sun exposure was reported in three patients (60%). None of the patients had a history of radiotherapy, phototherapy, or tanning bed use. The mean duration of lesion evolution was 90.4 months, ranging from 20 to 240 months. Clinically, the lesions presented as erythematous-pigmented nodules and plaques, with ulceration in two patients. The mean lesion size was 37 mm, ranging from 15 to 60 mm. Eighty percent of lesions were located on the head and neck, with one lesion on the abdomen; the remainder of the physical examination was unremarkable. Adenoid BCC was confirmed histologically, showing pseudoglandular structures composed of basaloid cells with peripheral palisading nuclei. All patients underwent surgical excision. The outcome was favorable, with no recurrence, after a two-year follow-up.

Conclusion

Adenoid BCC is a rare and indolent variant of BCC. The reported incidence is 1.3% [3]. It is considered a histological variant of the nodular type according to the WHO 2018 classification [4]. Adenoid BCC occurs most often in sun-exposed areas but can also affect extra-facial locations. Clinically, it generally presents as a firm nodular lesion with slow growth, sometimes ulcerated or pigmented, which may resemble a sebaceous cyst or other BCC variants [5]. Histological examination shows pseudoglandular structures composed of basaloid cells, sometimes requiring immunohistochemistry to exclude differential diagnoses, mainly cutaneous adenoid cystic carcinoma and primary cutaneous apocrine cribriform carcinoma [4]. Adenoid BCC is treated like other BCC subtypes, primarily by surgical excision. Its slow and minimally aggressive course confers a favorable prognosis [5]. Our findings regarding adenoid BCC are largely consistent with those from our overall BCC study (178 cases) regarding epidemiological aspects (age, sex, phototype), except for the duration of evolution, which was longer in

adenoid BCC cases. Furthermore, they are in agreement with previously reported data on adenoid BCC in terms of rarity, clinicopathological features, and favorable outcome

EADV CONGRESS
VIENNA
30 SEP - 3 OCT 2026

Abstract N°: 3195

Characteristics of Scalp Melanoma

Reis Mukhamadiev*[1]

[1] Hautpraxis Dresden, Dresden, Germany

Introduction

Anatomic site is a well-recognized prognostic determinant in primary cutaneous melanoma. Scalp melanoma (SM) has been termed the “invisible killer” due to its significantly worse prognosis compared with melanomas arising at other body locations. SMs tend to exhibit aggressive biological behavior, commonly presenting with a high mitotic rate and a greater likelihood of ulceration than melanomas at other sites. Although scalp melanomas account for approximately 35% of head and neck melanomas, they represent about 5% of all cutaneous melanomas overall.

Case Presentation

Multiple studies have demonstrated that scalp melanoma (SM) is associated with worse survival outcomes compared with melanomas at other anatomical sites, particularly other cutaneous head and neck melanomas. Xie et al. reported that patients with SM have a poorer prognosis, largely attributable to unfavorable clinicopathological features, including greater Breslow thickness and a predominance of male patients. Similarly, Matthew et al. found that melanomas arising on the posterior scalp were associated with significantly higher melanoma-specific mortality than those originating on the upper back. Epidemiological data indicate that SM occurs approximately six times more often in men than in women, likely due to a higher prevalence of androgenetic alopecia and increased cumulative and intermittent ultraviolet exposure of the scalp. In a study by Benati et al., scalp melanomas developing on bald or thinning scalp were significantly thicker than those occurring on hair-covered scalp.

Conclusion

Early diagnosis of melanoma followed by timely surgical excision is crucial for achieving favorable patient outcomes. Nevertheless, scalp melanoma has consistently been associated with a worse prognosis compared with melanomas arising at other anatomical sites. One potential explanation for this unfavorable outcome is delayed detection, as the scalp is frequently covered by hair and may be overlooked during routine clinical examinations. Consequently, thorough inspection of the scalp should be an integral part of a complete skin examination when evaluating patients for pigmented lesions.

EADV CONGRESS
VIENNA
30 SEP - 3 OCT 2026

Abstract N°: 3216

Pyogenic granuloma-like cutaneous involvement revealing refractory Hodgkin lymphoma in a 14-year-old child: an exceptional dermatologic presentation

MOHAMED HOUBAYELI*[1], layla bendaoud[1], Mariem Aboudourib[1], Amal Said[1], Ouafa Hocar[1]

[1] Mohammed VI University Hospital of Marrakech, Bioscience and Health Laboratory, Department of Dermatology Venerology, marrakech, Morocco

Introduction

Specific cutaneous involvement in Hodgkin lymphoma is rare, particularly in pediatric patients, occurring in less than 1% of cases. Clinical presentations are heterogeneous and may mimic infectious, inflammatory, or vascular tumors, leading to diagnostic delay. We report an unusual pyogenic granuloma-like presentation of secondary cutaneous Hodgkin lymphoma in a child.

Case Presentation

A 14-year-old girl followed in pediatric hematology for Hodgkin lymphoma since 2019 was referred for evaluation of two progressive cutaneous lesions evolving for 5 months. Clinical examination revealed a large ulcerated, exophytic, highly vascularized thoracic mass with spontaneous bleeding and a broad implantation base. An additional infiltrated axillary plaque composed of nodular and verrucous budding lesions covered with thick scales and crusts was observed, associated with retractile cicatricial changes of the surrounding skin. The patient remained hemodynamically and respiratory stable. Laboratory findings showed inflammatory syndrome without major organ dysfunction.

The clinical differential diagnoses included pyogenic granuloma, cutaneous metastasis, tuberculosis, and deep fungal infection. Skin biopsy with histopathological and immunohistochemical examination was performed and demonstrated secondary cutaneous localization of classical Hodgkin lymphoma.

Cutaneous Hodgkin lymphoma is exceptionally uncommon in children and usually indicates advanced or refractory disease. Lesions may present as papules, nodules, plaques, ulcerations, or vegetative tumors. The pyogenic granuloma-like appearance observed in our patient represents a misleading and extremely rare presentation. Mechanisms of skin involvement include retrograde lymphatic spread, direct extension from underlying lymph nodes, or hematogenous dissemination. Histopathology remains essential for diagnosis, particularly in atypical vascularized tumors occurring in immunocompromised or oncologic patients.

Conclusion

Dermatologists should consider cutaneous Hodgkin lymphoma in the differential diagnosis of rapidly growing vascular or ulcerative tumors in children with known hematologic malignancy. Early biopsy is crucial to avoid diagnostic delay and to guide oncologic management.

EADV CONGRESS
VIENNA
30 SEP - 3 OCT 2026

Abstract N°: 3227

Use of 5% Imiquimod Cream to Successfully Treat Extra-mammary Paget Disease in a 75-Year-Old Man, A Case Report.

Zahra Almosawy*[1], Peter Fergin[1]

[1] Department of Dermatology, Monash Health, Clayton, Vic, Australia, Melbourne, Australia

Introduction

Extra-mammary Paget Disease (EMPD) is a rare and slow growing skin-cancer of apocrine-rich tissue. Traditionally, wide-local excision has been used to treat the disease; but this is not without complications. Imiquimod cream is a topical immune response modulator. There is emerging literature supporting its efficacy in treating EMPD. This report details the use of imiquimod cream for the clearance of EMPD in two different body sites.

Case Presentation

The 75-year-old male patient originally had an eruption in his right axilla for 5 years. EMPD was eventually diagnosed on skin-biopsy. The region was treated successfully with wide local excision and sentinel node removal. One year and a half later, he presented with a persistent eruption in the left inguinal region. Histopathology confirmed EMPD in this additional site. Two surgical excisions failed to achieve clearance of the rash. The latter attempt was complicated by wound dehiscence. A further biopsy, performed eighteen-months later, confirmed persistent EMPD. An additional, ill-defined, atrophic site on the right scrotum also demonstrated EMPD on histopathology. Reluctant to pursue further surgery, the patient sought alternative therapy. A trial of imiquimod 5% cream was implemented. The cream was applied daily for three months. On review twelve-months later, the left inguinal and right scrotal areas remained clinically clear of EMPD.

Conclusion

This case illustrates the role of imiquimod cream as a promising adjuvant or alternative therapy for EMPD. Considering the sensitive anatomical sites and older age group typically affected, topical therapy may be a particular option in selected patients.

EA DV CONGRESS
VIENNA
30 SEP - 3 OCT 2026

Abstract N°: 3228

Cutaneous metastasis revealing advanced lung cancer: A rare initial presentation

MOHAMED HOUBAYELI*[1], layla bendaoud[1], Mariem Aboudourib[1], Ouafa Hocar[1], Amal Said[1]

[1] Mohammed VI University Hospital of Marrakech, Bioscience and Health Laboratory, Department of Dermatology Venerology, marrakech, Morocco

Introduction
Cutaneousmetastasis are an uncommon manifestation of internal malignancies occurring in approximately 1 12 of cancer patients Lung cancer is among the most frequent primary tumors associated with skin metastasis in both men and women. These lesions may occasionally represent the first clinical sign of an underlying malignancy posing a diagnostic challenge Clinically cutaneous metastasis often present as rapidly growing firm nodules, sometimes inflammatory most frequently located on the chest wall abdomen, scalp, or upper extremities Their presence usually indicates advanced systemic dissemination and poor prognosis.

Case Presentation
A 65 year old woman was admitted to the pulmonology department for the evaluation of chronic progressive dyspnea. Physical examination revealed a painful inflammatory nodular mass over the left shoulder measuring several centimeters in diameter with erythematous overlying skin. Ultrasound examination demonstrated a solid tissue lesion raising suspicion of a tumoral process.
A cutaneous biopsy of the lesion was performed Histopathological examination revealed cutaneous metastasis consistent with a pulmonary primary tumor. Subsequent chest radiography demonstrated multiple bilateral rounded pulmonary nodules with a characteristic cannonball appearance suggestive of hematogenous metastatic dissemination
The overall clinical radiological and histopathological findings supported the diagnosis of advanced lung cancer revealed by cutaneous metastasis.

Cutaneous metastasis from lung cancer remain relatively rare but are well documented in the literature. They may occur through hematogenous or lymphatic dissemination and are typically associated with advanced stage disease.
The most common clinical presentation is that of firm painless or mildly tender dermal or subcutaneous nodules, which may occasionally appear inflammatory and mimic infectious or benign dermatologic conditions.
Radiologically the presence of multiple well circumscribed pulmonary nodules cannonball metastases on chest imaging strongly suggests hematogenous tumor spread and is commonly associated with metastatic malignancies including lung cancer.
Histopathological examination of skin lesions plays a crucial role in establishing the diagnosis particularly when the primary tumor has not yet been identified.
The prognosis in patients with cutaneous metastases from lung cancer is generally poor with reported median survival ranging from 3 to 6 months after diagnosis reflecting the advanced stage of the disease.

Conclusion
Cutaneous metastasis may represent an unusual initial manifestation of lung cancer. Recognition of suspicious skin lesions particularly in patients presenting with respiratory
symptoms is essential. Skin biopsy remains a simple, minimally invasive, and highly valuable diagnostic tool that can facilitate early identification of metastatic disease and guide further oncological evaluation.

EA DV CONGRESS
VIENNA
30 SEP - 3 OCT 2026

Abstract N°: 3235

ALK-Positive Histiocytosis: clinical, histopathological, and dermatologic aspects of a rare histiocytic neoplasm

Amanda Quintaes*[1], Yasmin Mohamed[1], Igor Barcelos[1], Gustavo Costa Verardino[1], Sergio Romano[2], Luna Azulay-Abulafia[1]

[1] Department of Dermatology, Universidade do Estado do Rio de Janeiro (UERJ), Rio de Janeiro, Brazil, Rio de Janeiro, Brazil
[2] Microimagem Laboratory, Rio de Janeiro, Brazil, Rio de Janeiro, Brazil

Introduction

ALK-positive histiocytosis is a rare histiocytic neoplasm belonging to the group of non-Langerhans histiocytoses, characterized by ALK gene rearrangements, most commonly the KIF5B-ALK fusion. Initially described as a systemic disease of early infancy, a broader clinical spectrum is now recognized, including localized forms and presentations in older children and adults. In addition to multisystem involvement, cutaneous manifestations have been increasingly reported, highlighting the importance of early recognition by dermatologists. Clinically, the disease may present with nonspecific lesions such as macules, papules, or cutaneous nodules, frequently mimicking juvenile xanthogranuloma, Langerhans cell histiocytosis, and Rosai-Dorfman disease. Histopathologically, it is characterized by histiocytes with abundant eosinophilic cytoplasm and lobulated nuclei, associated with positivity for ALK, CD68, and CD163, findings that contribute to diagnostic confirmation.

Case Presentation

A 4-year-old male patient was admitted for investigation of obstructive cholestatic syndrome associated with multiple hepatic, pancreatic, renal, pulmonary, and cerebral nodules. He evolved with seizures, hepatosplenomegaly, ascites, persistent jaundice, and right median nerve mononeuropathy documented by electroneuromyography. During hospitalization, he developed well-demarcated erythematous-yellowish and brownish plaques with mild scaling, associated with pruritus, on the scalp for approximately 10 days. Dermoscopic examination revealed an erythematous background with yellow dots and fine scales. Given the systemic context, histiocytosis and cutaneous lymphoma were considered, and a skin biopsy was performed. Histopathological and immunohistochemical investigation revealed a diffuse histiocytic infiltrate composed of histiocytes diffusely positive for ALK, supporting the diagnosis of ALK-positive histiocytosis. Immunohistochemistry was negative for S100, CD1a, CD3, CD20, and CD30, helping to exclude other histiocytic and lymphoproliferative disorders. The diagnosis was further confirmed in submandibular lymph node and salivary gland biopsies. Imaging studies demonstrated multiple contrast-enhancing nodules throughout the supratentorial brain parenchyma, disseminated hypodense hepatic lesions, bilateral cortical renal nodules, a paravertebral extrapleural lesion, and scattered lytic bone lesions. Cranial computed tomography demonstrated perilesional edema and an associated mastoid lytic lesion. The patient initiated chemotherapy based on the LCH-IV protocol associated with systemic prednisolone according to treatment availability within the public healthcare system. Partial clinical improvement was observed, although significant multisystem involvement persisted.

Conclusion

Multisystem involvement in ALK-positive histiocytosis frequently affects the liver, lungs, central nervous system, lymph nodes, and skin, with neurological manifestations representing characteristic findings described in the

literature. Cutaneous lesions are heterogeneous and may present as erythematous plaques, papules, nodules, or infiltrated lesions, often mimicking inflammatory, infectious, or neoplastic dermatoses. Consequently, skin findings and dermoscopic features may be nonspecific, delaying diagnosis. In the present case, dermatological evaluation and skin biopsy were essential for diagnostic definition during investigation of multisystem disease. Histopathological analysis associated with ALK immunohistochemistry plays a central role in confirming the diagnosis, especially in atypical or disseminated presentations. Recent studies have demonstrated significant responses to ALK inhibitors in severe or refractory cases, when available, reinforcing the importance of early recognition and molecular characterization. This case highlights the importance of considering ALK-positive histiocytosis in the differential diagnosis of atypical scalp lesions in pediatric patients.

EA DV CONGRESS
VIENNA
30 SEP - 3 OCT 2026

Abstract N°: 3237

Clinicopathological Spectrum of Rare Benign Cutaneous Neoplasms on the scalp

Kirti Jangid *[1], Swagata Tambe[1], PRIYA MOTE[1]

[1] Seth VC Gandhi and MA Vora Municipal Hospital Rajawadi, Mumbai, India

Introduction
Scalp tumours comprise a diverse group of congenital, hamartomatous, adnexal, neural, vascular, and melanocytic lesions with overlapping clinical features, often making diagnosis challenging. Although many scalp lesions are benign, accurate identification is important because of cosmetic concerns, potential complications, and the possibility of malignant transformation in selected entities. Histopathological examination remains the gold standard for definitive diagnosis. We present a case series of rare benign scalp tumours encountered in a tertiary dermatology centre.

Case Presentation
A retrospective descriptive analysis was performed on patients presenting with uncommon scalp tumours over a defined study period. Clinical details, including age, sex, duration, morphology, symptoms, and site of involvement, were recorded. Dermoscopic findings were reviewed where available. Histopathological examination was performed in all cases for confirmation of diagnosis. Treatment modalities and follow-up outcomes were also assessed.

Results

The first case involved syringocystadenoma papilliferum arising within a nevus sebaceous in a young adult presenting with a verrucous alopecic plaque over the scalp associated with nodular and papillomatous surface changes. Histopathology demonstrated cystic invaginations extending from the epidermis into the dermis, lined by a dual layer of epithelial cells with papillary projections and dense plasma cell infiltrate, confirming syringocystadenoma papilliferum developing in a background nevus sebaceous.

The second case was steatocystoma multiplex, presenting as multiple soft cystic scalp nodules in a 32-year-old male. Histopathological examination showed dermal cysts lined by stratified squamous epithelium lacking a granular layer with attached sebaceous glands, consistent with steatocystoma multiplex.

The third case described a scalp schwannoma presenting as a solitary, slow-growing, tender subcutaneous nodule. Histology revealed a well-circumscribed encapsulated spindle cell neoplasm with Antoni A and Antoni B areas along with Verocay bodies, confirming schwannoma.

The fourth case involved a pyogenic granuloma presenting as a rapidly enlarging erythematous friable scalp papule with recurrent bleeding following trivial trauma. Histopathology showed lobular proliferation of capillaries separated by fibromyxoid stroma and inflammatory infiltrate, consistent with pyogenic granuloma.

The fifth case was a congenital melanocytic nevus presenting as a pigmented nodule over the scalp since birth. Dermoscopy and ultrasonography confirm a congenital melanocytic nevus.

All lesions were managed successfully with surgical excision, with good cosmetic outcomes and no major recurrence during follow-up.

Conclusion

This case series highlights the wide clinicopathological spectrum of rare benign scalp tumours and emphasises the importance of considering diverse differential diagnoses for scalp nodules and plaques. Clinical overlap among adnexal, neural, vascular, and melanocytic lesions may lead to diagnostic difficulty, making histopathological confirmation essential. Early recognition and appropriate management are important to prevent complications, alleviate patient anxiety, and exclude malignant mimickers. Reporting such uncommon scalp lesions contributes to the existing dermatological literature and enhances diagnostic awareness among dermatologists and dermatopathologists.

EA DV CONGRESS
VIENNA
30 SEP - 3 OCT 2026

Abstract N°: 3242

Patient Characteristics, Management Pathways, and Recurrence Following Diagnostic Biopsy of Head and Neck Basal Cell Carcinomas: A retrospective observational study from a Tertiary Dermatology Centre

Farishta Khan*[1], Zhenghao Wang[1], Hina Baloch[1], Shruti Sreekumar[1], Darya Petrik[1], Zoe C[1, 2], Ava SW[1]

[1] Norfolk and Norwich University Hospitals NHS Foundation Trust, Norwich, United Kingdom
[2] University of East Anglia, Norwich Research Park, NR4 7TJ, Norwich, United Kingdom

Introduction

Basal cell carcinoma (BCC) is the most common malignancy in England. Although prognosis is excellent, head and neck (H&N) tumours can cause significant morbidity. Biopsies are used for diagnostic uncertainty or when planning complex treatments.

Materials and Methods

Aim

To assess patient and tumour characteristics, management pathways, and recurrence in patients undergoing a diagnostic biopsy for a H&N BCC in a tertiary dermatology service.

Methods

H&N BCC patients undergoing diagnostic biopsy (Dec 2022–Dec 2023) were identified from pathology records. Clinical data were reviewed. Proportions were compared with chi-squared tests (MedCalc).

Results

A total of 751 cases were identified, most biopsies were punch biopsies (623, 83.0%), followed by shave biopsies (87, 11.6%), curettage and cautery (16, 2.1%), incisional biopsy (16, 2.1%), and other methods (9, 1.2%). The median age was 77 years (interquartile range [IQR] 69–84), with a male-to-female ratio of 1.3:1.

Clinical data were reviewed including Rockwood's Clinical Frailty Scale (CFS) to quantify frailty on a nine-point system. Of 623 patients aged >65 years, frailty data were available for 495 (79.5%). The median CFS was 3 (IQR 2–3), with 60/495 (12.1%) having CFS ≥5. Patients had a median of 2 comorbidities (IQR 1–3), increasing to 3 (IQR 2–3) among those with CFS ≥5. The most common comorbidities were hypertension (37%), atrial fibrillation (27%), and type 2 diabetes (16%). Overall, 93/751 (12.4%) patients were immunosuppressed.

Tumours were predominantly nodular (54.1%) with a median size of 10 mm (IQR 6–15). Management included Mohs micrographic surgery (32%), conventional surgery (28%), radiotherapy (10%), topical therapy (4%), other treatments (8%), and no treatment (18%). Among untreated patients (n=138), 90% were aged ≥65 years; frailty data were available for 93, of whom 24 (27%) had CFS ≥5.

Documented recurrence occurred in 20/751 (2.7%) cases. Recurrence rates were higher in non-nodular or mixed histology compared with nodular tumours (3.5% vs 2.0%) and in tumours ≥5 mm compared with <5 mm (2.9% vs 0%), although these differences were not statistically significant. Compared with conventional surgery, recurrence was higher in patients receiving no treatment (5.9%, n=8; p=0.0084), other treatments (7.0%, n=4; p=0.0070), and

topical therapy (14.3%, n=4; p<0.0001), while no significant difference was observed following Mohs surgery (0.4%, n=1) or radiotherapy (1.4%, n=1).

Patients who received no treatment (n= 138) after initial diagnostic biopsy, 8 (5.8%) re-presented to dermatology with progression, with a median time to progression of 15.4 months and median age 86.5 years.

These findings are consistent with those of Clay et al., who reported no increased recurrence risk in basal cell carcinoma with <1 mm margins (HR 1.23, 95% CI 0.41–3.72), supporting conservative management in selected cases.

Conclusions

With an ageing and increasingly frail population, understanding diagnostic pathways and associated outcomes is essential for streamlining individualised management. These findings align with emerging evidence that close (<1 mm) excision margins in BCC may not adversely impact recurrence risk when managed within a multidisciplinary framework, supporting more conservative, patient-centred decision making in selected cases.

EADV CONGRESS
VIENNA
30 SEP - 3 OCT 2026

Abstract N°: 3248

Late-onset multifocal vitiligo-like depigmentation during brigatinib therapy for ALK-rearranged metastatic lung adenocarcinoma

Mohammed shanshal[1], Sumbel Khan*[1]

[1] Imperial College Healthcare NHS Trust, London, United Kingdom

Introduction

Vitiligo-like depigmentation is an uncommon pigmentary event reported during selected anticancer therapies, including some tyrosine kinase inhibitors. Within the anaplastic lymphoma kinase (ALK) inhibitor class, published reports of vitiligo-like depigmentation remain rare and have mainly involved alectinib.

Brigatinib is a second-generation ALK tyrosine kinase inhibitor used in ALK-rearranged non-small cell lung cancer. To our knowledge, brigatinib-associated vitiligo-like depigmentation has not previously been reported. We describe a case of late-onset multifocal vitiligo-like depigmentation developing during long-term brigatinib therapy for ALK-rearranged metastatic lung adenocarcinoma.

Case Presentation

A woman in her early sixties with ALK-rearranged metastatic lung adenocarcinoma had been receiving brigatinib since May 2022, with stable systemic disease. Approximately 32 months after treatment initiation, she developed progressive, sharply demarcated hypopigmented patches, initially affecting the face and later involving the back, flanks and breasts. She had no previous personal history of vitiligo and no family history of vitiligo. Clinical examination showed multiple well-circumscribed, nonscaly, chalk-white macules and patches involving the frontal hairline/forehead and trunk, consistent with multifocal non-segmental vitiligo-like depigmentation. There was no recorded preceding dermatitis, trauma or chemical exposure. Brigatinib was continued because the pigmentary change was not treatment-limiting and systemic disease remained controlled. Treatment was started with site-appropriate topical corticosteroids, and narrowband ultraviolet B phototherapy was planned.

Conclusion

This case highlights late-onset multifocal vitiligo-like depigmentation developing during established brigatinib therapy, with onset approximately 32 months after treatment initiation. The latency is clinically relevant because pigmentary changes may emerge long after targeted therapy has been well tolerated and may not be immediately linked to treatment. In patients receiving ALK tyrosine kinase inhibitors, new sharply demarcated hypopigmented or depigmented patches should prompt dermatologic recognition, treatment of visible and quality-of-life burden, and multidisciplinary discussion without automatic interruption of effective cancer therapy. Further reporting is needed to determine whether brigatinib represents a rare ALK-inhibitor-associated depigmentation phenotype and to define latency, clinical spectrum and outcomes.

EADV CONGRESS
VIENNA
30 SEP - 3 OCT 2026

Abstract N°: 3250

Cutaneous nodular relapse revealing mantle cell lymphoma in a patient previously treated for diffuse large B-cell lymphoma

MOHAMED HOUBAYELI*[1], layla bendaoud[1], Nouhaila Bourht[1], Mariem Aboudourib[1], Ouafa Hocar[1], Amal Said[1]

[1] Mohammed VI University Hospital of Marrakech, Bioscience and Health Laboratory, Department of Dermatology Venerology, marrakech, Morocco

Introduction

Secondary cutaneous involvement by mantle cell lymphoma (MCL) is rare and may present with misleading dermatologic manifestations. Distinguishing relapse, transformation, or a second lymphoid neoplasm remains challenging, particularly in patients with previous hematologic malignancy. We report an unusual case of cutaneous nodular lesions occurring during remission of diffuse large B-cell lymphoma (DLBCL), ultimately diagnosed as mantle cell lymphoma.

Case Presentation

A 65-year-old woman, followed in hematology for diffuse large B-cell lymphoma and in complete remission after chemotherapy for 3 months, was referred for rapidly progressive nodular skin lesions evolving for one month in a context of asthenia and anorexia.

Dermatological examination revealed multiple deep subcutaneous nodules of variable size involving both forearms and lower limbs. The nodules were mobile, firm, painful on palpation, and associated with bilateral inflammatory swelling of the elbows. Mucosal examination showed a venous lake of the lower lip. The remainder of the physical examination was unremarkable.

Initial differential diagnoses included infectious panniculitis, superficial thrombophlebitis, erythema nodosum, and cutaneous relapse of lymphoma. Laboratory work-up demonstrated inflammatory syndrome. Doppler ultrasonography and soft tissue imaging identified multiple infiltrative nodular formations. Histopathological examination of a skin biopsy revealed dermal and hypodermal infiltration by atypical lymphoid cells. Immunohistochemistry was compatible with mantle cell lymphoma.

The patient was subsequently referred to hematology for staging and therapeutic management.

Cutaneous involvement in mantle cell lymphoma is uncommon and usually associated with advanced systemic disease. Clinical presentations are polymorphic, including nodules, plaques, tumors, or panniculitis-like lesions. In our patient, the occurrence of multiple painful nodules after remission of DLBCL raised the question of relapse versus emergence of another B-cell lymphoma subtype. Histopathology with immunohistochemistry was essential to establish the diagnosis. This observation highlights the importance of considering secondary lymphoid neoplasms in atypical cutaneous lesions occurring in patients with previous hematologic malignancies.

Conclusion

New-onset nodular skin lesions in patients with a history of lymphoma should prompt early dermatologic evaluation and biopsy. Cutaneous mantle cell lymphoma, although rare, must be considered because of its prognostic and therapeutic implications.

EA DV CONGRESS
VIENNA
30 SEP - 3 OCT 2026

Abstract N°: 3255

Spatial Transcriptomics Reveals Immune Microniches and Sex-Stratified Differences in Melanoma Progression

Namrata Singh*[1], Christine Wagner[1], Regina Shaikhutdinova[1], Kirsten Merz[2], Martin Simon[1], Stephan Wagner[1], Johannes Griss[1]

[1] Dermatology, Medical University of Vienna, Wien, Austria

[2] Institute of Medical Genetics and Pathology, University Hospital Basel, Basel, Switzerland

Introduction

Immune checkpoint inhibitors have revolutionized treatment of melanoma, however, over 50% of patients fail to achieve durable responses. Tumour invasive margin, the interface for tumour-stroma and tumour-immune interactions, is the site of immune exclusion and infiltration. Its spatial architecture determines anti-tumour immune response, disease progression, and therapy outcomes. We and others previously showed that B cells play a major role in anti-tumour immunity and are predictive of response to immunotherapy in melanoma.

Materials and Methods

To characterise the role of B cells in the melanoma tumour microenvironment at the tumour invasive margin, we applied single-cell spatial transcriptomics to 275 tissue microarray cores from 142 patients with primary or metastatic disease and high or low B cell infiltration.

Results

Compared to primary disease, metastatic tumours showed loss of conventional and migratory dendritic cells required for cross-presentation and sustaining tumour-reactive T cell responses, a fibroblast state switch from inflammatory iCAF, which secrete CXCL12 and support immune recruitment, to myofibroblastic CAFs which showed upregulation of genes associated with collagen matrix deposition thus driving immune exclusion, and expansion of SPP1+ tumour-associated macrophages (TAMs) which suppress T cell-recruiting chemokines CXCL9 and CXCL10. Therefore, the TME in metastasis is associated with dendritic cell loss, stromal activation, and immunosuppressive macrophage expansion, and is predominantly immunosuppressive compared to primary melanomas.

Sex-stratified analyses revealed further differences in immune phenotypes across disease stages. Female primary tumours were enriched for terminally exhausted CD8 T cells and interferon-gamma+ macrophages, indicating a ‘hot’ microenvironment that is chronically engaged but progressively suppressed. Male primary tumours were mainly immune cold, characterised by homeostatic stromal populations and low T cell infiltration. In metastatic disease, this difference in the TME was rewired, with male patients showing infiltration of SPP1+ and TREM2+ immunosuppressive TAMs associated with T cell exclusion and poor immune checkpoint inhibitor outcomes.

Spatial analysis showed that the tumour-invasive margin in melanoma is enriched for myofibroblastic cancer-associated fibroblasts and interferon-gamma macrophages regardless of disease stage. Additionally, tumours with high intratumoural B cell infiltration, and by extension, high tertiary lymphoid structure (TLS) formation, showed a fundamentally different architecture at the tumour invasive margin compared to tumours with low B cell infiltration. B cell high tumours showed coordinated enrichment of plasma cells as expected, but also CD4+ T central memory cells, regulatory T cells, and transitional effector CD8 T cells co-expressing cytotoxic genes and exhaustion checkpoints including PD-1, TIM-3, and LAG-3 at the tumour-stroma boundary. This CD8 population is consistent with a progenitor-derived transitional exhausted state (TPEX), the primary responder to PD-1 blockade.

Tertiary lymphoid structures have been shown to maintain TPEX pools in human cancers, and our analyses showed that their effector progeny are enriched at the tumour-stroma boundary in B cell-rich tumours, thereby spatially connecting TLS function to immune engagement at the invasive front.

Conclusions

Our results show that the tumour-stroma boundary in melanoma acts as a microniche where immunosuppressive players, such as SPP1+ macrophages, and anti-tumour effectors such as TPEX, coexist and collectively shape the local immunity.

EA DV CONGRESS
VIENNA
30 SEP - 3 OCT 2026

Abstract N°: 3267

High-frequency ultrasound in Merkel cell carcinoma: imaging clues for the evaluation of suspicious superficial nodular lesions

Vincenza Amoruso*[1], Letizia Castelli[2], Anastasia Mercurio[3], Patrizia Matano[4], Giacomo Montaldi[4, 5]

[1] Recovery and Functional Reeducation Unit, Rehabilitation Department, Santa Corona Hospital, Pietra Ligure, Italy
[2] Department of Neurosciences, Università Cattolica del Sacro Cuore, Roma, Italy
[3] Unit of Anatomical Pathology, Department of Experimental Medicine, University La Sapienza, Roma, Italy
[4] Private Practice in Aesthetic Medicine, Center for Aesthetic Surgery and Aesthetic Medicine, Albenga, Italy
[5] Musculoskeletal Ultrasound School, Italian Society for Ultrasound in Medicine and Biology, Bologna, Italy

Introduction

Merkel cell carcinoma (MCC) is a rare and aggressive neuroendocrine skin malignancy characterized by rapid growth and early metastatic potential. Early diagnosis remains challenging, particularly in atypical superficial lesions. Although PET/CT and MRI are routinely used for staging, the role of high-frequency ultrasound (HFUS) in the diagnostic evaluation of MCC remains underexplored. We report a clinical case highlighting the potential contribution of HFUS in the early suspicion and characterization of MCC.



Case Presentation

An 81-year-old male presented with a painless subcutaneous nodule on the dorsal aspect of the third finger, initially suspected to represent a benign lesion. HFUS examination performed with a 22 MHz probe revealed a well-circumscribed hypoechoic subdermal mass with both peripheral and central vascularity on Power Doppler imaging. The lesion appeared superficially located above the extensor tendon without tendon infiltration. The marked vascular pattern and solid echostructure raised suspicion for malignancy and prompted surgical excision. Histopathological examination and immunohistochemistry confirmed Merkel cell carcinoma, demonstrating positivity for CK20, chromogranin A and synaptophysin. Short-term postoperative HFUS follow-up demonstrated a well-defined avascular scar area without evidence of residual lesion. Review of the current literature revealed limited standardized sonographic descriptions of MCC and a paucity of high-frequency ultrasound documentation in dermatologic oncology.

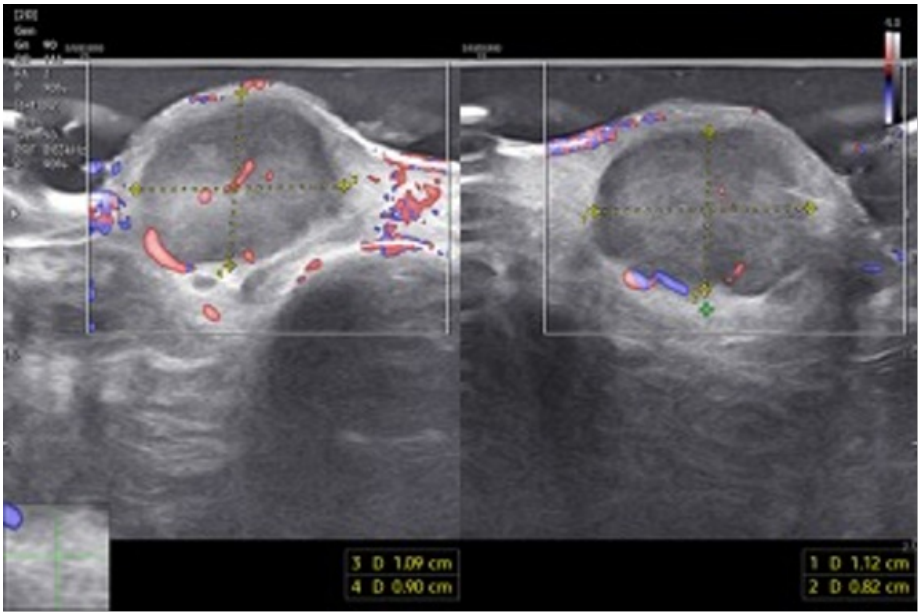

Conclusion

HFUS may represent a valuable adjunctive imaging modality in the evaluation of suspicious superficial nodular lesions, particularly in anatomically delicate areas such as the digits. The combination of marked hypoechogenicity and prominent internal vascularity may support earlier clinical suspicion of MCC and assist in surgical planning and postoperative follow-up. Further studies are needed to better define the sonographic features of MCC and its differential diagnosis with benign cutaneous lesions.

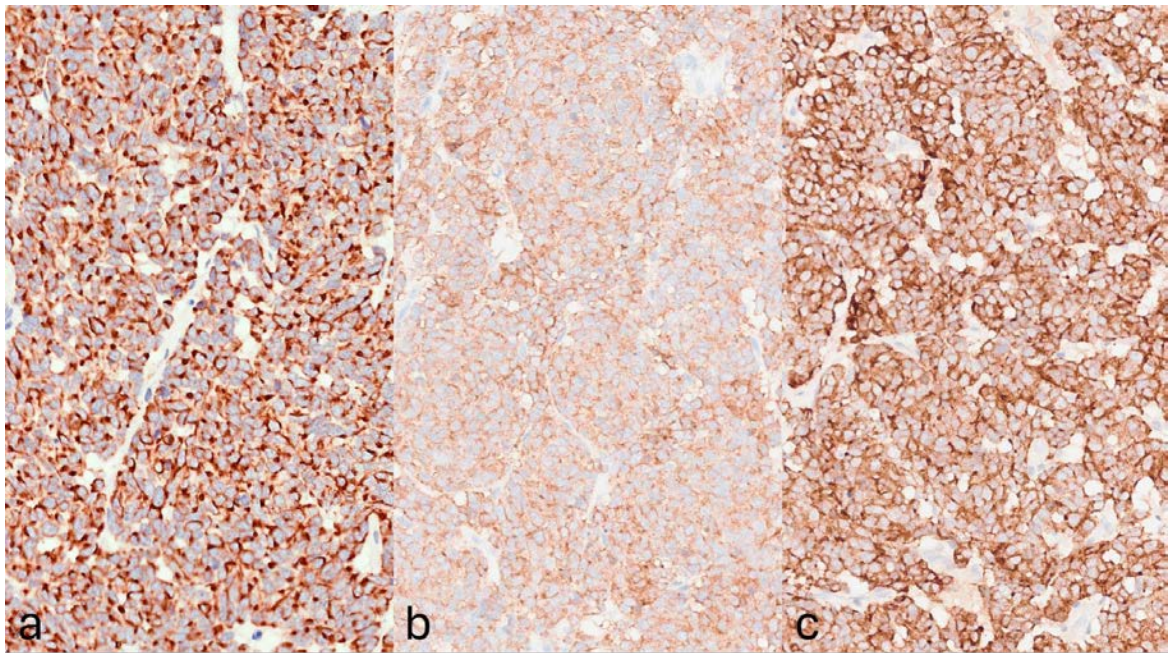
a
b
c

EA DV CONGRESS
VIENNA
30 SEP - 3 OCT 2026

Abstract N°: 3276

Diagnostic Challenges in Recurrent Adenoid Basal Cell Carcinoma Arising in Scalp Lymphangioma Circumscriptum

Urszula Fałkowska*[1], Joanna Czuwara[1], Joanna Misiewicz-Wroniak[1], Małgorzata Olszewska[1], Lidia Rudnicka[1]

[1] Department of Dermatology, Medical University of Warsaw, Warsaw, Poland., Warszawa, Poland

Introduction

Lymphangioma circumscriptum, known as superficial or microcystic lymphatic malformation, is an uncommon benign congenital lymphatic malformation involving the skin and mucosa [1–3]. Clinically, it typically presents as grouped translucent vesicles that vary in size with hemorrhagic discoloration [4,5]. Treatment remains challenging, as it recurs after surgery, especially when the lymphatic component is not completely removed [6].

Case Presentation

A 77-year-old woman presented with a 15-year history of recurrent translucent vesicles lesions of the hair-bearing scalp. The disease initially manifested as a solitary lesion located in the midline scalp. Following surgical excision with a skin graft, a non-healing erythematous, eroded, and crusted plaque developed within the postoperative scar, diagnosed histopathologically as basal cell carcinoma (BCC).

Over the following years, multiple recurrences of BCC developed within and around the scarred area, which covered the entire crown of the scalp, in association with tense vesicles at the lesion or scar margins. Line-field confocal optical coherence tomography (LC-OCT) showed large hyporeflective cavities corresponding to the histological cystic spaces. Histopathology showed cystically dilated lymphatic spaces within scarred dermis, accompanied in selected specimens by hyperreflective cellular clods corresponding to basaloid epithelial proliferations with an adenoid pattern in histology.

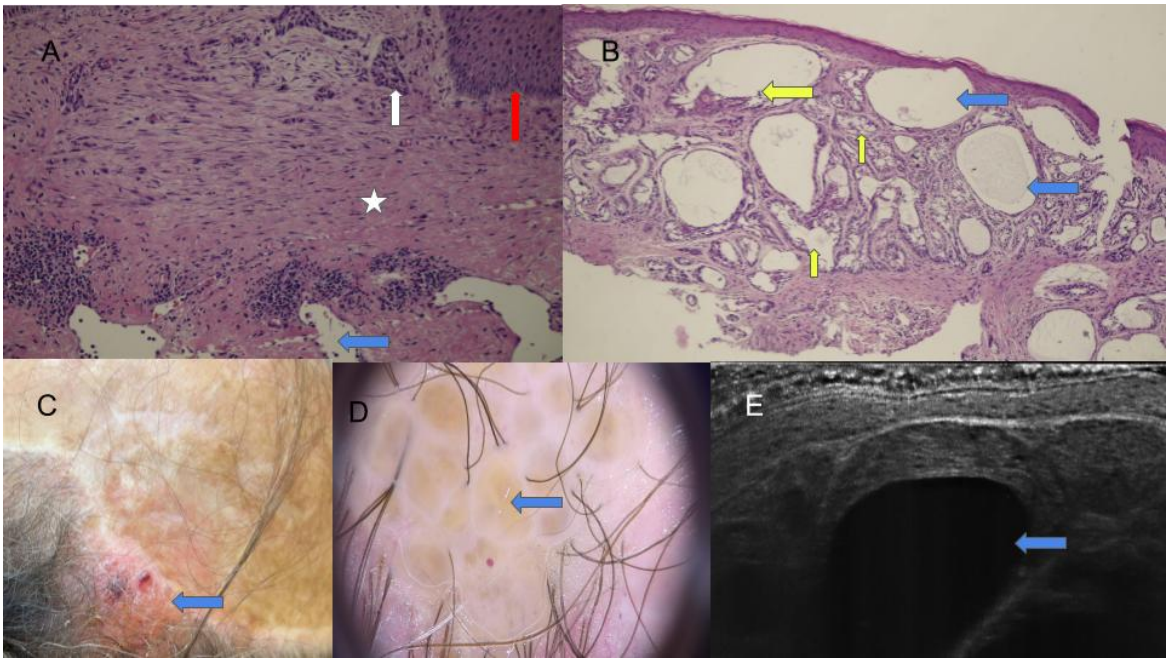

Figure 1. A–B. Histopathological images, H&E staining. The white arrow indicates a nodule of basal cell carcinoma with the infiltrative growth pattern, yellow arrows mark prominent cystic spaces of BCC with pseudoglandular architecture, blue arrows indicate cystically dilated lymphatic vessels filled with pale proteinaceous fluid, red arrow highlights the overlying epidermis. The white star marks scar and dermal fibrosis pushing down the cystic spaces of lymphangioma. C. Clinical image of the hair-bearing scalp showing coalescing recurrent vesicular lesions at the margin of the scarred grafted skin. D. Dermoscopy demonstrating grouped, tense, translucent to yellowish vesicles/lacunae on a pale pink fibrotic background, with a frog-spawn-like pattern appearance. E. LC-OCT, vertical view showing large hyporeflective cystic cavities corresponding to lymphangioma presence.

Conclusion

This case illustrates how persistent lymphangioma circumscriptum may create a complex histological background for assessing adenoid basaloid proliferations in the scalp skin. Dilated lymphatic spaces, adnexal structures, remnants of the hairs follicles, and post-surgical remodeling create difficulties not only to detect adenoid BCC, but also to determine its extent and relationship to the clinically recurrent vesicular component. Recognizing suspicious areas is important for the biopsy selection, margin assessment, and surgical planning, particularly when repeated excisions fail to prevent recurrence.

EADV CONGRESS
VIENNA
30 SEP - 3 OCT 2026

Abstract N°: 3277

Exploring Tenascin-C in MAPK inhibitor resistant melanoma

Nina Zila*[1, 2], Andrea Bileck[3, 4], Yasmin Fareed[3, 5], Christopher Gerner[3, 4], Ossia Eichhoff[6], Verena Paulitschke[2]

[1] University of Applied Sciences Campus Vienna, Biomedical Science, Vienna, Austria
[2] Medical University of Vienna, Department of Dermatology, Vienna, Austria
[3] University of Vienna, Faculty of Chemistry, Department of Analytical Chemistry, Vienna, Austria
[4] University of Vienna and Medical University of Vienna, Joint Metabolome Facility, Vienna, Austria
[5] University of Vienna, Faculty of Chemistry, Doctoral School in Chemistry, Vienna, Austria
[6] University Hospital Zurich, University Zurich, Department of Dermatology, Zurich, Switzerland

Introduction

Targeted inhibition of the MAPK signaling pathway has substantially improved clinical outcomes for patients with BRAFV600-mutant melanoma. However, the rapid emergence of resistance to MAPK inhibitors (MAPKi) remains a major challenge, frequently resulting in disease progression. While tumor-intrinsic mechanisms are well characterized, increasing evidence highlights a critical contribution of the tumor microenvironment in shaping adaptive resistance.

Materials and Methods

Using proteomic profiling, we identified the extracellular matrix glycoprotein Tenascin-C (TNC) as significantly upregulated in MAPKi-resistant melanoma cells. To assess its functional role, TNC was genetically ablated in primary BRAFV600-mutant melanoma cells via CRISPR/Cas9. Real-time live-cell imaging was used to analyze proliferation kinetics and migratory behavior of TNC knockout and control cells. To further dissect underlying mechanisms, integrated proteomic and phosphoproteomic analyses were performed, followed by functional enrichment analyses. In addition, kinase activity inference analyses were conducted to evaluate alterations in signaling network states. Ongoing integrative analyses combining RNA sequencing and proteomic datasets aim to identify convergent regulatory programs and define shared resistance signatures across transcriptional and protein levels.

Results

TNC knockout led to pronounced alterations in proliferation kinetics and migratory behavior compared to control cells, indicating a functional involvement of TNC in regulating tumor cell dynamics associated with aggressiveness and therapy adaptation. Functional enrichment analyses consistently highlighted biological processes related to extracellular matrix (ECM)-receptor interaction, cell adhesion molecules and their ligands, adherens junctions, focal adhesion, and cytoskeletal organization. These findings suggest that TNC contributes to a coordinated regulation of cell–matrix and cell–cell interaction networks that are critical for melanoma cell plasticity and survival under therapeutic pressure. In parallel, we are currently working to systematically identify and characterize specific proteins contributing to these biological processes to refine the mechanistic understanding of TNC-associated signaling networks. Furthermore, kinase activity inference pointed to altered signaling network states, supporting a role for TNC in modulating intracellular pathways downstream of extracellular cues.

Conclusions

Collectively, our findings suggest that TNC may act as a mediator linking extracellular matrix remodeling to intracellular signaling changes in MAPKi-resistant melanoma. By influencing adhesion-dependent signaling and cytoskeletal dynamics, TNC could contribute to the development of an adaptive, therapy-resistant phenotype. Elucidating these mechanisms may help uncover novel therapeutic vulnerabilities and support the development of more durable treatment strategies for patients with advanced BRAFV600-mutant melanoma.Formularbeginn.

EADV CONGRESS
VIENNA
30 SEP - 3 OCT 2026

Abstract N°: 3286

Bullous Kaposi Sarcoma: A Rare Clinical Presentation

Zineb Aqasbi Ouahi*[1], Sara Elloudi[1], ikrame bejja[1], Saadia Boughaleb[1], Zakia Douhi[1, 1], Meryem Soughi[1], Hanane Baybay[1], Fatima Zohra Mernissi[1]

[1] Department of Dermatology, Hassan II University Hospital, Fez, Morocco

Introduction

Kaposi's sarcoma (KS) is a proliferative vasculo-fibroblastic tumor associated with human herpesvirus 8 (HHV-8) infection, encompassing four epidemioclinical subtypes: classic, endemic, iatrogenic, and epidemic. Bullous variants are rare and mainly described in classic KS, particularly in elderly patients with lower-limb involvement. Their atypical presentation may represent a significant diagnostic challenge, especially in distinguishing KS from autoimmune blistering dermatoses. We report a case of classic KS in prolonged remission that subsequently developed atypical bullous lesions.

Case Presentation

An 84-year-old patient, followed for 7 years for classic KS, initially presented with violaceous angiomatous plaques limited to the lower limbs. He was HIV-negative and HHV-8 positive and was treated with radiotherapy, achieving complete clinical remission maintained for six years. Six years later, he developed multiple tense vesicles and bullae with sero-hemorrhagic content on the right leg, associated with a few erythematous-violaceous plaques, without associated lymphedema. Nikolsky’s sign was negative. Dermoscopy revealed an angiomatous pattern with scales and chrysalis-like structures. Given the atypical presentation, prolonged remission, unilateral distribution, and absence of lymphedema, a skin biopsy with direct immunofluorescence was performed to rule out bullous pemphigoid. Histopathological examination showed a vascular proliferation consistent with Kaposi sarcoma, while direct immunofluorescence was negative. A diagnosis of bullous Kaposi sarcoma was retained. The patient underwent an additional session of radiotherapy with good clinical outcome.

Conclusion

This case highlights the rarity and diagnostic challenge of bullous Kaposi sarcoma occurring after prolonged remission of classic KS. The unusual unilateral bullous presentation in the absence of lymphedema closely mimicked an autoimmune blistering disorder, emphasizing the importance of histopathological examination and direct immunofluorescence in establishing the diagnosis. Awareness of this rare variant is essential to ensure early diagnosis and appropriate management in elderly patients presenting with atypical blistering lesions.

EA DV CONGRESS
VIENNA
30 SEP - 3 OCT 2026

Abstract N°: 3329

Bridging ultrasonography as a diagnostic tool for skin cancers: A case of an atypical basal cell carcinoma mimicking angiosarcoma

Öyküm Üdül*[1], Hale Nur Ertugay Aral[1], Berkay Temel[1]

[1] Gazi University Faculty of Medicine, Department of Dermatology, Ankara, Türkiye

Introduction

Basal cell carcinoma (BCC) is the most common skin cancer worldwide. The lifetime risk for the white population is nearly 30 percent; fortunately, it scarcely metastasizes (1). Nevertheless, early diagnosis and treatment of BCCs are critical to prevent local invasion and facilitate better surgical outcomes. In recent years, a couple of highly sensitive and specific dermatoscopic findings have been defined for BCC, leading to an increased diagnostic accuracy even for determining subtypes. Moreover, the use of ultrasonography for cutaneous tumors is another "hot topic" in the dermatology field, since it is also a non-invasive, easily applicable, and affordable diagnostic tool which can provide key tips (2). In this observational letter, we are presenting a violaceous-pinkish tumour on the left flank of an 85-year-old lady, resembling angiosarcoma but histopathologically diagnosed as BCC. Through this case, we want to emphasize how the integration of ultrasound imaging with dermatoscopic examination can guide us towards the accurate diagnosis of skin cancers.

Case Presentation

An 85-year-old woman applied to our outpatient clinic with a complaint of a growing nodule on her left trunk. She described the lesion as beginning 15 years ago, with the central part appearing last year. It was ulcerated and bleeding with traumatization. No subjective symptom was accompanying. Dermatoscopic examination revealed a violaceous heterogeneous lesion. It presented as a nodular portion in the center containing blue ovoid nests, white circles, cherry blossom-like and arborizing vessels, and surrounding structureless pale pink areas with brown lines encircling the entire lesion. Although findings such as arborizing vessels and nest-like blue areas seemed to be in favor of BCC, we couldn't exclude angiosarcoma due to the large size of the tumor, its violaceous color, atypical localization, and the fact that the former findings consistent with BCC can also be seen in angiosarcoma cases. Since angiosarcoma was still a strong preliminary diagnosis, we performed ultrasonography to assess the degree of tumor vascularization. In Doppler ultrasonography, the tumor was found to have a low blood supply. That finding was more indicative of BCC than highly vascularized angiosarcoma. Furthermore, ultrasound imaging revealed hyperechoic spots scattered over the nodular part of the lesion. Based on these findings, we determined our preliminary diagnosis for histopathological examination as BCC and its micronodular subtype. Three punch biopsies confirmed the diagnosis of BCC; the central nodular part was identified as nodular and micronodular subtypes, while the surrounding flat portion was identified as the superficial subtype. The total excisional biopsy report was the same.

Conclusion

There are a few case reports in the literature related to basal cell carcinoma and angiosarcoma mimicking each other (3, 4). In these reports, highlighted common features also include a similar clinical appearance and dermatoscopic findings. Considering the different prognosis and survival status, the distinction is critical. In this case report, we wanted to emphasize the pivotal role of

ultrasonography in the differential diagnosis of skin cancers as a non-invasive and easily accessible method.

EADV CONGRESS
VIENNA
30 SEP - 3 OCT 2026

Abstract N°: 3341

From Plaques to Tumors: A Challenging CD30+ Cutaneous Lymphoproliferation

Teodora Toc*[1], Denisa Hertanu[1], Alexandru Grozavescu[2], Constantin-Ioan Busuioc[3], Alina Gogulescu[1]

[1] Municipal Emergency Hospital-Clinic for Dermatology, "Victor Babeș" University of Medicine and Pharmacy, Timisoara, Romania

[2] OncoHelp Oncology Center, Timisoara, Romania

[3] Department of Pathology, Saint Mary Clinical Hospital, epartment of Pathology, Onco Team Diagnostic, Bucharest, Romania

Introduction

Primary cutaneous CD30+ lymphoproliferative disorders include primary cutaneous anaplastic large-cell lymphoma (pcALCL) and other entities with overlapping clinicopathologic features, particularly mycosis fungoides (MF) with large-cell transformation. Their diagnosis may be challenging because of heterogeneous clinical presentations and resemblance to inflammatory, infectious, or parasitic dermatoses.

Case Presentation

A 30-year-old male patient with a history of extensive travel in Asia was referred to our clinic in March 2026 for ulceronecrotic nodules localized predominantly on the legs. The first nodular lesion had appeared in November 2025 on the right leg and remained relatively stable initially, while additional lesions progressively developed. Some tumoral lesions demonstrated partial spontaneous regression. Dermoscopy of the nodular lesions revealed pink-white structureless areas, hemorrhagic crusts, erosions, and dotted vessels, initially favoring an inflammatory or infectious process.

At clinical examination, the patient also presented asymptomatic hyperpigmented squamous plaques, mainly on the trunk and legs. He stated they had been present on the shoulders for several years, but interpreted them as post-inflammatory hyperpigmentation or inflammatory dermatosis. Previous treatment with topical corticosteroids and fusidic acid resulted in minimal improvement.

Because of the patient's travel history and the clinical presentation, extensive investigations were performed to exclude infectious and parasitic diseases. Tuberculosis, fungal infections, parasitoses, HIV, HBV, HCV infection, PAS staining and microbiological investigations were negative.

Histopathologic examination of a plaque lesion demonstrated psoriasiform epidermal hyperplasia with superficial perivascular lymphocytic infiltrates. However, biopsy from a tumoral lesion revealed a dense dermal infiltrate formed of atypical medium-to-large lymphoid cells with marked cytonuclear atypia and numerous atypical mitoses. Immunohistochemistry showed CD45 positivity, diffuse CD3 expression, CD30 positivity in approximately 90% of atypical cells, ALK negativity, and a high proliferative index (Ki67 approximately 90%). These results raised the possibility of tumor-stage MF with CD30+ large-cell transformation.

Following the pathological diagnosis, PET/CT was performed, and it demonstrated hypermetabolic cutaneous and subcutaneous lesions. These were predominantly involving the lower extremities without extracutaneous dissemination.

The patient showed rapid clinical improvement following initiation of CHOEP chemotherapy and 20 sessions of

UVB therapy.

Discussion

This case highlights the diagnostic complexity of CD30+ cutaneous lymphoproliferative disorders with overlapping clinicopathologic features. The longstanding plaques preceding the appearance of nodules support the possibility of an underlying MF-spectrum disorder with CD30+ large-cell transformation, whereas the strong CD30 expression and tumoral presentation raise consideration of pcALCL.

Predominant lower-extremity involvement may additionally indicate a more aggressive clinical course.

Conclusion

CD30+ cutaneous lymphoproliferative disorders may present with significant overlap between transformed MF and pcALCL while simultaneously mimicking infectious dermatoses. Careful clinicopathologic correlation, repeated biopsies, and multidisciplinary evaluation are essential for establishing an accurate diagnosis and guiding appropriate management.

EA DV CONGRESS
VIENNA
30 SEP - 3 OCT 2026

Abstract N°: 3348

Marjolin ulcer masquerading as chronic osteomyelitis: delayed diagnosis of invasive cutaneous squamous cell carcinoma in longstanding burn scars

Weijia Yi*[1]

[1] Department of Dermatology, John Hunter Hospital, New South Wales, Australia

Introduction

Marjolin ulcer masquerading as chronic osteomyelitis: delayed diagnosis of invasive cutaneous squamous cell carcinoma in longstanding burn scars

Marjolin ulcers are uncommon but aggressive cutaneous squamous cell carcinomas (cSCCs) arising in chronic wounds, scars or sites of longstanding inflammation, most classically burn scars. Diagnosis is frequently delayed because ulceration is attributed to more common inflammatory or infective processes, contributing to advanced disease at presentation, increased morbidity and higher rates of recurrence and metastasis compared with conventional cSCC.

Case Presentation

We report the case of a 78-year-old Aboriginal woman from a remote rural community who presented with progressive, painful lower-limb ulceration initially attributed to chronic osteomyelitis. She had multiple longstanding ulcers involving the right lateral malleolus, right calcaneus and left lower leg, associated with draining sinus formation, surrounding erythema and progressive functional decline despite prolonged oral antibiotic suppression, community nursing care and multidisciplinary high-risk foot review. Computed tomography demonstrated cortical irregularity and sclerosis of the distal fibula, reinforcing the presumed infective diagnosis. Further history later revealed extensive burns involving approximately 90% total body surface area decades earlier, with residual bilateral lower-limb scarring.

Given progressive ulceration despite conservative management and the background of chronic burn scars, punch biopsies were performed. Histopathology demonstrated invasive well-differentiated cSCC with irregular nests of squamous cells infiltrating a desmoplastic inflamed dermis, consistent with Marjolin ulcer. There was no evidence of nodal or distant metastatic disease at diagnosis. Below-knee amputation was initially recommended for oncological and infective source control but declined because of concerns regarding rehabilitation access, mobility and remaining on Country. Twelve months later, worsening pain, malodorous discharge and progressive ankle destruction necessitated above-knee amputation.

Conclusion

This case highlights the importance of maintaining suspicion for malignant transformation in chronic ulcers, particularly in patients with burn scars or longstanding inflammation. It also demonstrates how coexisting osteomyelitis may contribute to diagnostic anchoring and delay biopsy. Early tissue diagnosis, multidisciplinary care and culturally safe access to specialist services are critical to improving outcomes for rural and Aboriginal patients with complex chronic wounds.

EADV CONGRESS
VIENNA
30 SEP - 3 OCT 2026

Abstract N°: 3364

Cutaneous involvement by T-Lymphoblastic lymphoma with loss of immaturity markers in a patient treated for acute myeloid leukemia

Iratxe Ruiz Álvarez de Arcaya*[1], Aina Estany Bécares[1], Ariadna Casamitjana Casabó[1], Jordi Mollet Sánchez[1], Berta Ferrer[2], Ingrid López-Lerma[1], Vicente García-Patos Briones[1]

[1] Department of Dermatology, Vall d'Hebron University Hospital, Barcelona, Spain
[2] Department of Pathology, Vall d'Hebron University Hospital, Barcelona, Spain

Introduction

Cutaneous involvement by T-lymphoblastic lymphoma (T-LBL) is uncommon and may mimic drug eruptions, neutrophilic dermatoses, or mature T-cell lymphomas. Loss of immaturity markers at cutaneous sites can further complicate diagnosis. We present a case of T-LBL with cutaneous dissemination showing site-dependent loss of immaturity markers and a phenotypically distinct mature T-cell population in peripheral blood, arising during treatment for acute myeloid leukemia (AML).

Case Presentation

A 79-year-old male was diagnosed with AML in february of 2025. First-line azacitidine plus venetoclax achieved complete marrow response after six cycles. During treatment, in march of 2025, the follow-up PET-CT revealed a hypermetabolic mediastinic mass (39x64x79 mm) with focal hepatic uptake.

Concurrently, a progressive maculopapular exanthem developed on the trunk and upper extremities. On examination, macular erythema predominated on the anterior thorax, while papular lesions were more prominent posteriorly. Facial erythema involved the nasal dorsum, cheeks, and forehead with characteristic periocular sparing. Lower extremities were minimally affected. Palms, soles, and oral mucosa were spared. No bullae were observed. The clinical differential included cutaneous infiltration by hematologic malignancy, neutrophilic dermatosis, and drug eruption.

A 4-mm punch biopsy of a papular lesion on the back showed diffuse dermal infiltration by monomorphous atypical lymphocytes of intermediate size with irregular nuclei, fine chromatin, and small nucleoli. Immunohistochemistry demonstrated CD4/CD8 co-expression, CD99 positivity, and weak CD10, supporting a precursor T-cell origin. CD1a and TdT were negative, indicating loss of immaturity markers. Ki-67 was 80%. In contrast, core needle biopsy of the mediastinal mass showed identical morphology but retained immaturity markers: CD1a positive and TdT focally positive. The diagnosis was cortical thymic T-LBL.

Following the first cycle of vincristina and prednisone, disease progression was confirmed, with the T-lymphoblastic lymphoma now demonstrating peripheral expression and hepatic infiltration. Peripheral blood flow cytometry identified a third, phenotypically distinct population: 65% aberrant mature T lymphocytes expressing surface CD3, TCR alpha-beta, CD4 (without CD8 co-expression), intense CD52, and lacking TdT, CD10, and CD25. This was interpreted as a leukemized mature T-cell lymphoma with nonspecific profile.

Given the coexistence of acute myeloid leukemia with a refractory T-lymphoblastic lymphoma and the absence of further therapeutic options capable of prolonging life with acceptable quality, a shared decision was reached with the patient and family to discontinue active oncohematologic treatment and all other futile interventions, prioritizing symptom control. The patient died 1 month after the discovery of the hipermetabolic mediastinic

mass.

Conclusion

Cutaneous T-LBL may present as a nonspecific maculopapular exanthem with facial erythema and periocular sparing, closely mimicking drug eruption or neutrophilic dermatosis. Skin biopsy is essential in hematologic patients with unexplained rashes. The cutaneous infiltrate showed loss of CD1a and TdT compared to the mediastinal primary, a recognized phenomenon that may lead to misdiagnosis as mature T-cell lymphoma. The co-expression of CD4 and CD8 with CD99 was the critical diagnostic clue to precursor T-cell origin. Third, the coexistence of a phenotypically distinct mature T-cell population in peripheral blood lacking CD8 co-expression and expressing TCR alpha-beta and intense CD52 raises questions about immunophenotypic maturation during dissemination versus independent T-cell neoplasms. Cutaneous T-LBL may lose immaturity markers, mimicking mature T-cell lymphoma. In hematologic patients with new skin eruptions, biopsy with attention to CD4/CD8 co-expression and CD99 is essential to identify precursor T-cell neoplasms when CD1a and TdT are absent.

EA DV CONGRESS
VIENNA
30 SEP - 3 OCT 2026

Abstract N°: 3408

Patient with More Than 60 Basal Cell Carcinomas: Etiopathogenic Hypotheses and Proposal for a Structured Management Algorithm

Nina Ivanovic*[1], Patricia Bratu[2], Ana-Olivia Toma[1]

[1] Timișoara Municipal Emergency Clinical Hospital, University of Medicine and Pharmacy "Victor Babes", Morphoderm (Centre for Morphological Research of the Skin), Timisoara, Romania

[2] Timișoara Municipal Emergency Clinical Hospital, Timisoara, Romania

Introduction

Basal cell carcinoma (BCC) is the most common malignant skin tumour, typically presenting as a solitary or a limited number of lesions on sun-exposed areas, with slow evolution and very low metastatic potential but significant local invasion risk. The occurrence of more than 20–30 BCCs in the same patient is considered exceptional; to our knowledge, fewer than 30 cases of non-syndromic multiple unilateral BCCs have been reported in the world literature, with none exceeding 60 lesions. Such presentations require systematic exclusion of genodermatoses, evaluation of individual susceptibility factors, and a structured long-term management approach.

Case Presentation

We report the case of a 61-year-old patient with phototype II with more than 60 cutaneous lesions clinically and dermoscopically consistent with BCC, predominantly located on the left side of the body. A remarkable feature is the complete absence of actinic keratoses, the patient's denial of significant solar exposure, and the lack of any clinical signs suggestive of Gorlin-Goltz syndrome or other genodermatoses associated with multiple BCCs (palmoplantar pits, odontogenic keratocysts, skeletal or craniofacial anomalies, Bazex-Dupré-Christol syndrome, Rombo syndrome, xeroderma pigmentosum). These elements led us to formulate three non-mutually exclusive etiopathogenic hypotheses: (1) a subclinical field cancerization mechanism, with accumulation of somatic mutations in the left cutaneous territory without visible precancerous expression; (2) an individual genetic susceptibility, possibly involving a non-PTCH1 germline variant (SUFU, MC1R, TERT or others), with or without an incompletely expressed syndromic phenotype – noting that genetic testing was not available for this patient at the time of presentation; (3) the action of non-UV environmental carcinogens or incompletely identified immunological factors. The diagnostic workup included clinical examination, dermoscopy, histopathological confirmation with 16 biopsies confirming BCC since 2022, documenting an active progression pattern and total body digital mapping (FotoFinder), which enabled cartographic documentation of all lesions, identification of previously undetected tumours, and establishment of a reference baseline for follow-up.

Conclusion

Based on this exceptional case, we propose a five-step management algorithm for patients with multiple BCCs: (1) systematic clinical syndromic exclusion; (2) initial total body digital mapping; (3) dermoscopic risk stratification and treatment prioritisation; (4) structured 6–12 month follow-up using digital dermoscopy and total body photography to detect new lesions early; (5) parallel aetiological workup including immunological assessment and genetic counselling. This case illustrates that high-burden BCC patients represent a distinct clinical category requiring integrated clinical, dermoscopic, histopathological and - when available - genetic evaluation; in settings

where genetic testing is not immediately accessible, the proposed algorithm remains fully applicable and clinically actionable, with genetic counselling deferred as a parallel and ongoing step rather than a prerequisite for management. This approach also underscores the need for a structured long-term surveillance strategy, regardless of whether an underlying genetic syndrome is ultimately identified.

EA DV CONGRESS
VIENNA
30 SEP - 3 OCT 2026

Abstract N°: 3413

Sunscreen Availability and Diagnostic Capability for Skin Cancer Worldwide - Findings from the Global Skin Observatory Study

Simon Westby*[1, 2], Joseph Michael Yardman-Frank[1, 3], Jennifer Kilmer[4], Karry Su[2], Christine Li[5], Ann Pacheco[2, 6], Sarah Anwar[7], Tebyan Khalfalla[1, 8], Parisa Shamaei Zadeh[1, 9], Devon McMahon[10], Ramesh Bhat[11], Mahira El Sayed[12], Wendemagegn Yeshaneh[13, 14], Cristina Galvan-Casas[15], Xing-Hua Gao[16], Srie Gondokaryono[17], Abdul-Ghani Kibbi[18], Adriene Lee[19], Fatimata Ly[20, 21], Jorge Ocampo-Candiani[22], Marie-Aleth Richard[23], Ricardo Romiti[24], Alexis Strahan[1], Junko Takeshita[25, 26], Henry W. Lim[27], Bertrand Chuberre[28], Delphine Kerob[29], Lucinda Claire Fuller[30], Christopher E. M. Griffiths[31], Guénolée De Lambert[28], Ncoza Dlova[32], Esther Freeman[1, 2]

[1] Department of Dermatology, Massachusetts General Hospital, Boston, United States
[2] Medical Practice Evaluation Center, Mongan Institute, Massachusetts General Hospital, Boston, United States
[3] Department of Dermatology, Beth Israel Deaconess Medical Centre, Boston, United States
[4] The International League of Dermatological Societies, London, United Kingdom
[5] University of Massachusetts Chan Medical School, Worchester, United States
[6] University of Toledo College of Life Sciences, Toledo, United States
[7] Tufts University School of Medicine,, Boston, United States
[8] University of Rochester School of Medicine and Dentistry, Rochester, United States
[9] University of Kentucky College of Medicine, Lexington, United States
[10] Department of Dermatology, Hospital of the University of Pennsylvania, Philadelphia, United States
[11] Department of Dermatology, Venereology and Leprosy, Father Muller Medical College, Mangalore, India
[12] Ain Shams University, Cairo, Egypt
[13] Bahir Dar University, College of Medicine and Health Sciences, Bahir Dar, Ethiopia
[14] Collaborative Research and Training Center for Neglected Tropical Diseases, Arba Minch University, Arba Minch, Ethiopia
[15] Hospital Universitario de Móstoles, Madrid, Spain
[16] The First Hospital of China Medical University, Shenyang, China
[17] Department of Dermatology and Venereology, Dr. Hasan Sadikin General Hospital, Universitas Padjadjaran, Badung, Indonesia
[18] Department of Dermatology, American University of Beirut Medical Center, Beirut, Lebanon
[19] Department of Dermatology, St Vincent's Hospital, Melbourne, Australia
[20] Department of Dermatology, STI EPS Institut D'Hygiène Sociale de Dakar, Dakar, Senegal
[21] Faculty of Medicine, Pharmacy, and Odontostomatology, University Cheikh Anta Diop of Dakar, Dakar, Senegal
[22] Department of Dermatology, Hospital Universitario "Dr. José E. González", Universidad Autónoma de Nuevo León, Monterrey, Mexico
[23] Research Centre in Health Services and Quality of Life, Aix Marseille University Dermatology Department, University Hospital Timone, Assistance Publique Hôpitaux de Marseille, Marseille, France
[24] Department of Dermatology, University of São Paulo, São Paulo, Brazil
[25] Department of Dermatology, Perelman School of Medicine at the University of Pennsylvania, Philadelphia, United States
[26] Department of Biostatistics, Epidemiology and Informatics, Perelman School of Medicine at the University of

Pennsylvania, Philadelphia, United States
[27] Department of Dermatology, Henry Ford Health, Detroit, United States
[28] L'Oréal Dermatological Beauty, Global Medical Team, Levallois-Perret, France
[29] La Roche-Posay Laboratoire Dermatologique,, Levallois-Perret, France
[30] London Bridge Hospital, London, United Kingdom
[31] Centre for Dermatology Research, NIHR Manchester Biomedical Research Centre, Manchester Academic Health Science Centre, University of Manchester, Manchester, United Kingdom
[32] Department of Dermatology, University of KwaZulu-Natal, Durban, South Africa

Introduction
There are over 6.5 million cases of skin cancer annually. Early evidence suggests disparities exist in access to key skin cancer diagnostics, and preventative treatments and procedures, especially for certain at-risk groups such as persons with albinism. Despite this early data, a country's ability to care for skin cancer has not been systematically investigated on a global scale.

We use data from the Global Access to Skin Health Observatory (SkinObservatory) Study to investigate whether countries have the medication access and diagnostic availability required to prevent and diagnose skin cancer.

Materials and Methods
The SkinObservatory study is a cross-sectional, Delphi-derived, survey study of national dermatologic leaders from 194 WHO member states. Participants were asked questions related to dermatologic care access. Data related to sunscreen, cryotherapy, punch and shave biopsies and dermatopathologic review availability were analyzed. We also investigated the impact on persons with albinism by assessing the availability of sunscreen across four African nations with high reported albinism prevalence (Tanzania, Namibia, Zimbabwe and Cameroon).

Variation was tested across World Health Organization (WHO) regions and World Bank income (WBI) levels using chi-squared and Fisher's exact tests.

Results
One hundred and fifty-eight countries responded to the survey, with 136 reporting on sunscreen availability. While 98 (72.1%) countries reported that sunscreen was generally available in greater than 50% of settings, there was substantial variation by WHO region and WBI level ($p<0.001$). In Africa, the WHO region with the highest reported prevalence of albinism, only 11 (31%) countries had sunscreen generally available. Similarly, only 3 (17%) low-income countries had sunscreen generally available, compared to 44 (96%) high-income and 32 (100%) European countries. Of the four African countries with high reported prevalence of albinism, only half had sunscreen generally available. Angola and Democratic Republic of Congo reported persons with albinism were an underserved community; however, neither reported general access to sunscreen.

As it pertains to interventions for skin cancer, 74 (54%) countries reported cryotherapy was generally available, with variation by WHO region and WBI level ($p<0.001$). Cryotherapy was generally available in 41 (89%) high-income and 32 (97%) European countries compared to 4 (24%) low-income, 11 (32%) African and 1 (10%) Southeast Asian countries.

Availability of dermatopathologic review and shave or punch biopsies varied by WHO region and WBI level ($p<0.001$), with 24 (77%) European countries reporting sufficient or greater access to dermatopathologic review compared to 7 (19.6%) African countries. Less than half of African, Southeast Asian and low-income countries had adequate, satisfactory or excellent access to shave or punch biopsies compared to nine out of ten European and high-income nations. While 132 (96.4%) countries reported skin biopsy availability in urban areas, only 32 (23.4%) reported rural availability.

Conclusions

There are substantial global disparities in skin cancer preventative and diagnostic service access, with lower income, African and Southeast Asian countries most affected. Particularly concerning is the poor availability of sunscreen in countries reporting high prevalence of albinism, emphasizing the importance of sunscreen's addition to the 2025 WHO Essential Medicines List. Efforts to manufacture treatments and train providers locally will be particularly important in addressing these gaps.

EA DV CONGRESS
VIENNA
30 SEP - 3 OCT 2026

Abstract N°: 3435

Paraneoplastic Vasculitis Associated With Metastatic Sigmoid Adenocarcinoma: a case report

Afafe JEI*[1, 1], Hanane Rachadi[1], Soumiya Chiheb[1]

[1] Ibn Rochd University Center, casablanca, Morocco

Introduction
Neoplastic or malignant disorders are associated with a large number of vasculopathic syndromes that affect both the venous and the arterial vascular trees. However, coexistence of vasculitis and malignancy is rare, and paraneoplastic vasculitides represent less than 5% of all the vasculitides, being more frequently associated with hematological malignancies than with solid tumors. We report a challenging case of paraneoplasic vasculitis occurring in a patient with metastatic colorectal cancer and multiple drug use.

Case Presentation
A 50-year-old woman was admitted for progressive purpuric skin lesions of the lower extremities. Her medical history included sigmoid adenocarcinoma with liver metastases treated surgically in 2024 followed by chemotherapy. She subsequently underwent repeat surgery for hepatic metastases, complicated postoperatively by acute Takotsubo stress cardiomyopathy, with favorable outcome under angiotensin-converting enzyme inhibitors, beta-blockers, and anticoagulation therapy. She also reported a previous miscarriage, multiple drug exposures, and a poorly documented allergic reaction after the fourth chemotherapy cycle that resolved with antihistamines and topical treatment.

The history of the current disease dated back 15 days before admission, with the onset of purpuric lesions associated with pruritus, burning pain, and electric shock-like sensations. Lesions progressively extended to both lower limbs and evolved into bullous and ulcero-necrotic lesions, associated with edema and arthralgia of the right ankle. The patient denied headache or digestive symptoms apart from discomfort related to her stoma. The clinical course occurred in an afebrile context with altered general condition.

Clinical examination revealed infiltrated petechial purpura involving the feet, legs, and hands, confluent and necrotic in some areas, associated with vesiculo-bullous lesions with tense serohemorrhagic content and negative Nikolsky sign. Hemorrhagic bullous and necrotic ulcerative lesions were predominantly observed on the right leg, the right hand at the base of the fifth digit, and the right elbow, with post-bullous erosions on the left elbow. Black crusted lesions were also noted on the posterior, lateral, and medial aspects of the thighs. The right ankle was swollen and painful on both active and passive mobilization.
Laboratory investigations revealed normochromic normocytic aregenerative anemia. Bone marrow examination showed inflammatory marrow changes. Immunological investigations were unremarkable, and electroneuromyography findings were normal. Given the patient’s polymedication, a pharmacological investigation was conducted but did not support a drug-induced etiology. Skin biopsy demonstrated leukocytoclastic vasculitis. In view of the active malignancy, the bullous and ulcero-necrotic evolution of the purpuric lesions, the negative pharmacological assessment, and the histopathological findings, a diagnosis of paraneoplastic cutaneous vasculitis was retained.

Systemic corticosteroid therapy at a dose of 0.5 mg/kg/day was initiated in association with vitamin C supplementation and local wound care. The patient was subsequently referred back to the oncology department

for resumption of chemotherapy. Clinical condition improved under treatment.

Conclusion

This case illustrates a cutaneous vasculitis occurring in a complex oncological and therapeutic context. Multiple studies support the notion of vasculitis being a true paraneoplasic syndrome. It might be present initially as an acute vasculitis or as a chronic and persistent vasculitis with poor response to treatment. Its resolution follow the treatment of the linked malignangy, and its reccurence is associted with tumor reccurence or progression. Early recognition of atypical vasculitic presentations is essential to ensure prompt diagnostic workup and multidisciplinary management.

EA DV CONGRESS
VIENNA
30 SEP - 3 OCT 2026

Abstract N°: 3457

A Slowly Progressive Localized Presentation of Primary Cutaneous CD8-Positive Peripheral T-Cell Lymphoma, Not Otherwise Specified

Şule Güneş*[1], Emel Öztürk Durmaz[2], Funda Güneri[3], Sedef Şahin[1], Cüyan Demirkesen[4]

[1] Acıbadem University, Department of Dermatology, Istanbul, Türkiye
[2] Acibadem Maslak Hospital, Department of Dermatology, Istanbul, Türkiye
[3] Acıbadem Kadıköy Hospital, Department of Dermatology, Istanbul, Türkiye
[4] Acıbadem University, Department of Pathology, Istanbul, Türkiye

Introduction

Primary cutaneous peripheral T-cell lymphoma, not otherwise specified (PCPTCL-NOS), is a rare and heterogeneous subtype of cutaneous T-cell lymphoma diagnosed after exclusion of better-defined entities, including mycosis fungoides, primary cutaneous CD30-positive lymphoproliferative disorders, subcutaneous panniculitis-like T-cell lymphoma, primary cutaneous aggressive epidermotropic CD8-positive cytotoxic T-cell lymphoma, cutaneous gamma/delta T-cell lymphoma, extranodal NK/T-cell lymphoma and primary cutaneous acral CD8-positive T-cell lymphoproliferative disorder. Although usually considered aggressive, its clinical behavior may vary according to lesion distribution, cytomorphology and systemic involvement. Diagnosis requires integration of clinical findings, histopathology, immunohistochemistry and molecular studies.

Case Presentation

A 45-year-old man presented with a two-year history of a slowly enlarging lesion on the left upper thigh, followed by a second smaller lesion nearby, without pruritus, pain or B symptoms. Medical history included hyperthyroidism (thiamazole) and insulin resistance (metformin). Examination revealed a 3 × 1.5 cm dusky, atrophic, scaly plaque with an adjacent 0.7 cm discoid patch. Dermoscopy showed a pink-erythematous background, fine scaling, irregular linear, dotted and comma-like vessels, structureless pigmented areas and focal white stellate fibrotic structures.

Histopathology demonstrated a diffuse dermal lymphoid infiltrate from superficial to deep dermis, composed of small-to-medium atypical lymphoid cells with scattered larger cells and admixed histiocytes, without prominent epidermotropism. Tumour cells expressed CD2, CD3, CD5, CD8, CD56 and granzyme B; CD4, CD20, CD30, BCL-6 and EBER were negative. CD7 loss was noted. Ki-67 was 55–60%. PCR-based T-cell receptor gene rearrangement analysis demonstrated clonality.

Laboratory findings were unremarkable except for mild hyperuricemia. Ultrasonography of a small ipsilateral inguinal lymph node showed a node under 2 cm with preserved fatty hilum, regular cortical morphology and no fixation, consistent with a reactive node. Whole-body PET-CT revealed no hypermetabolic lesion beyond the cutaneous site, confirming stage T1 primary cutaneous disease. PTCL-NOS was favored after clinicopathological correlation. Following multidisciplinary evaluation, the patient underwent complete surgical excision by plastic surgery with clear margins.

Conclusion

This case illustrates an unusual, slowly progressive and localized presentation of primary cutaneous CD8-positive PTCL-NOS. Although generally associated with poor prognosis, solitary or localized presentations may follow a

more indolent course amenable to surgical excision or radiotherapy. The largest multicentre EORTC study confirmed durable complete remissions with surgery or radiotherapy in solitary limb lesions. Small-to-medium cell morphology is an independent favorable prognostic factor. CD56 co-expression alongside CD8 raised the differential of NK/T-cell lymphoma; however, EBER negativity excluded this entity, and CD56 positivity in PTCL-NOS is an uncommon but recognised phenomenon. The Ki-67 of 55–60% appeared discordant with the indolent two-year course, underscoring the need to integrate clinical context into prognostic assessment. Comprehensive immunophenotyping, EBER testing and PCR-based TCR clonality analysis are essential for accurate classification of CD8 positive cytotoxic infiltrates, and multidisciplinary follow-up remains mandatory given the potential for disease progression.

EA DV CONGRESS
VIENNA
30 SEP - 3 OCT 2026

Abstract N°: 3470

Use of non-invasive therapy modalities in treatment of basal cell carcinoma

Rania Abdusamad*[1], Yen Thao Luu[2], Johanny Lopez[2], Nour Kibbi[2]

[1] Stanford School of Medicine, Palo Alto, United States
[2] Stanford Department of Dermatology, Redwood City, United States

Introduction

Basal cell carcinoma (BCC) is the most common cutaneous malignancy worldwide, with 4.4 million new cases diagnosed annually. While surgery remains the gold-standard of care for the treatment of BCC,challenges to surgical intervention exist, including anatomical constraints, risk for functional and cosmetic morbidity, and surgical fatigue. Topical modalities, such as 5-fluorouracil, imiquimod, tazarotene, and PDT exist as an alternative for the treatment of BCC with variable efficacy. Limited studies exist directly comparing topical modalities and outcomes by tumor subtype. While a range of topical dosing regimens has been reported, evidence-based clinical guidelines for clinical practice remain lacking.

Materials and Methods

A systematic review was conducted in accordance with PRISMA guidelines in December 2025. Databases queried included PubMed, Embase and Web of Science, with search terms relevant to BCC. Included articles pertained to the topical treatment of BCC and reported data on at least three lesions. Analysis and image production was conducted using R Studio (version 4.5.2). Categorical data (treatment type, dosing regimen, BCC subtype, anatomical location) was described. Pearson's chi square test was used to compare outcomes (clearance, recurrence, persistence rates) among treatment groups. Logistic regression was employed to evaluate dosing regimens and outcomes. One sample t-test was used to analyze mean time-to-recurrence. All statistical tests were two-sided, with significance set at alpha=0.05.

Results

Our study included a total of 10,788 BCCs (75% superficial BCC, 21% nodular BCC, 1% infiltrative BCC). Topical modalities included 5-fluorouracil, imiquimod, tazarotene, and PDT. The combined disease-free rate across all topical modalities was 74%. Persistent disease occurred in 19%, while initial "clearance" followed by recurrence occurred in 7%. Among reported BCC subtypes, superficial BCC achieved significantly higher disease-free rates than nodular BCC (76.6% vs 67.3%; p=5.96×10−7).

Daily imiquimod use was associated with significantly higher disease-free rates than 5x/week (85.2% vs 79.1%, p=0.0002). Similarly, daily imiquimod use achieved higher tumor clearance rates than either 3x/week or twice daily 3x/week regimens (85.2% vs 78.2% and 66.1%; p=0.0004 and p=0.0003). In contrast, use of 5x/week imiquimod showed significant benefit over twice daily 3x/week imiquimod use, but not 3x/week imiquimod use (79.1% vs 78.2% and 66.1%; p=0.77 and p=0.047).

Disease persistence was seen in 24.8% BCC reviewed histologically and 10.2% of lesions reviewed clinically. Clinically evaluated lesions were more likely to be diagnosed with recurrence (14.9% vs 1.6%, p<.0001).

Patients with BCC were followed on average for 26 monthsfollowing initial diagnosis and topical treatment In

contrast, the mean time to recurrence was 15.6 months. .

Conclusions

Our findings highlight the benefit of topical therapies in the treatment of certain subtypes of BCC, particularly sBCC. Differences in recurrence via clinical versus histologic exams suggest that subclinical levels of disease may not be detectable on clinical exam alone. Detection of clinically apparent recurrence 1-year post-treatment reaffirms current standard practices for consistent post-treatment skin exams.

EADV CONGRESS
VIENNA
30 SEP - 3 OCT 2026

Abstract N°: 3482

Melanoma In Situ and Subsequent IAMPUS in a 42-Year-Old Woman: Surveillance and Management Challenges

Vera Plužarić*[1], Martina Mihalj[2], Maja Tolušić Levak[3], Jasmina Rajc[4], Maja Kozul[2], Stana Tokić[5], Ivana Krajina[6], Marija Sola[7]

[1] Department of Dermatology and Venerology, University Hospital Osijek, Department of Laboratory Medicine and Pharmacy, Faculty of Medicine, Josip Juraj Strossmayer University of Osijek, Osijek, Croatia
[2] Department of Dermatology and Venerology, University Hospital Osijek, Department of Dermatovenereology, Faculty of Medicine, University of Osijek, Osijek, Croatia
[3] Department of Dermatology and Venerology, University Hospital Osijek, Department of Histology and Embryology, Faculty of Medicine, Josip Juraj Strossmayer University of Osijek, Osijek, Croatia
[4] Department of Pathology and Forensic Medicine, Osijek University Hospital, Department of Pathological Anatomy and Forensic Medicine, Faculty of Medicine Osijek, Josip Juraj Strossmayer University of Osijek, Osijek, Croatia
[5] Department of Laboratory Medicine and Pharmacy, Faculty of Medicine, Josip Juraj Strossmayer University of Osijek, Osijek, Croatia
[6] Department of Dermatology and Venereology, University Hospital Osijek, Department of Physiology and Immunology, Faculty of Medicine, University of Osijek, Osijek, Croatia
[7] Department of Dermatology and Venerology, University Hospital Osijek, Osijek, Croatia

Introduction

Melanoma in situ (MIS) carries excellent prognosis after complete excision, but patients remain at increased risk for subsequent primary melanomas. Intraepidermal atypical melanocytic proliferation of uncertain significance (IAMPUS) represents a histopathological grey zone within ambiguous melanocytic neoplasms. IAMPUS belongs to superficial atypical melanocytic proliferations of uncertain significance (SAMPUS), which carry excellent prognosis, with zero metastatic events in the largest cohort (1,957 cases). However, 4.2–8.2% of atypical intraepidermal melanocytic proliferations are reclassified as MIS or melanoma upon re-excision. This case illustrates the clinical challenges in surveillance and management of patients with concurrent MIS and ambiguous melanocytic neoplasms.

Case Presentation

A 42-year-old woman, phototype III, average nevus count, negative family history, presented in 2023 with a newly developed pigmented lesion on the right forearm. Excisional biopsy confirmed MIS. Re-excision achieved clear margins. During 2023, two additional lesions were excised (left upper arm, right thigh), both confirmed as dysplastic nevi. In 2026, a 1-mm lesion on the right upper arm (ipsilateral to original MIS) was excised, with histopathology showing IAMPUS. Re-excision achieved clear margins. Staging workup including LDH, S100B, and regional lymph node ultrasound

was performed as part of a personalized surveillance approach exceeding standard guidelines, with all results within normal limits.

Conclusion

Current NCCN and AAD guidelines recommend annual skin examination for stage 0 MIS without routine blood tests or imaging, as LDH and S100B lack sensitivity for early-stage disease. However, this patient's young age (42 years), multiple atypical melanocytic proliferations, and ipsilateral location of MIS and IAMPUS warrant heightened vigilance. IAMPUS falls within MPATH-Dx V2.0 class II (high-grade benign), requiring re-excision when margins are positive. Patients with MIS have increased long-term risk of subsequent melanoma; multiple dysplastic nevi further increase this risk (relative risk 10.49 for 5 atypical nevi). An individualized, multimodal surveillance approach integrating dermoscopy, digital monitoring (total-body photography and sequential digital dermoscopy imaging), and selective reflectance confocal microscopy is recommended. NCCN recommends these modalities for high-risk patients, with Australian guidelines suggesting 6-monthly examinations for very high-risk individuals. Recent studies show 3D total-body photography achieves number-needed-to-excise of 3.26:1. While routine serological markers and imaging are not supported by guidelines for stage 0 disease, personalized surveillance may be justified in select high-risk patients through shared decision-making. Genetic counseling may be considered given young age and multiple atypical proliferations, particularly under European "rule of 2" criteria (≥2 melanomas including in situ). Further studies are needed to define optimal surveillance protocols for patients with concurrent MIS and ambiguous melanocytic neoplasms.

EADV CONGRESS
VIENNA
30 SEP - 3 OCT 2026

Abstract N°: 3502

Clinical Predictors of Hyperprogressive Disease in Patients With AdvancedMelanoma Treated With Immune Checkpoint Inhibitors

Tim Zell*[1], Noah Zimmermann[1], Glenn Geidel[1], Stefan Schneider[1], Julian Kött[1], Christoffer Gebhardt[1]

[1] University Medical Center Hamburg-Eppendorf, Hamburg, Germany

Introduction
Hyperprogression under immune checkpoint inhibition (ICI) represents a clinically critical pattern of accelerated disease progression. However, the underlying risk factors in remain poorly understood. This study aimed to identify clinical and molecular characteristics associated with hyperprogression and to compare these patients with those exhibiting primary resistance to ICI.

Materials and Methods
To identify patients with hyperprogression, we analyzed a cohort of 244 patients from the multicenter skin cancer registry ADOREG who were treated with ICIs for metastatic melanoma, had normal baseline lactate dehydrogenase (LDH) levels, an Eastern Cooperative Oncology Group (ECOG) performance status of 0 or 1, and demonstrated primary resistance to ICIs, defined as disease progression within 6 months after treatment initiation according to Society for Immunotherapy of Cancer (SITC) criteria. Hyperprogression was defined according to Fournier et al. (MelBase) as progression within 3 months accompanied by deterioration to an ECOG performance status of 3 or 4 and/or an increase in serum LDH levels above the upper limit of normal. Associations between hyperprogression and potential risk factors, including age, sex, metastatic sites (brain, lung, liver, bone), molecular markers (BRAF, NRAS), and treatment regimen (PD-1 monotherapy vs combined PD-1/CTLA-4 therapy), were evaluated.

Results
Hyperprogression was observed in 102 patients (41.8% of patients with primary resistance to ICI) who experienced significantly impaired overall survival (p=0.001). Significant clinical risk factors were younger age (P = .018), elevated serum S100 levels (P < .001), and the presence of bone metastases (P = .004) or brain metastases (P = .007) in multivariable logistic regression analysis. No significant associations were observed for combination therapy, other metastatic sites, or BRAF/NRAS mutational status.

Conclusions
Hyperprogression represents a clinically distinct progression pattern which severely impacts overall survival. Younger patient age, as well as the presence of brain and bone metastases were identified as potential risk factors for hyperprogression in melanoma.

POWERED BY M-ANAGE.COM

EADV CONGRESS
VIENNA
30 SEP - 3 OCT 2026

Abstract N°: 3522

Frozen Section Mohs Micrographic Surgery for Dermatofibrosarcoma Protuberans – A Case Series of 38 patients in NSW, Australia

Marjia Johns*[1], Maya Deva[2], Gilberto Moreno[3, 4, 5], Simon Lee[3], Duncan Stanford[6, 7, 8], Saleem Loghdey[1]

[1] Integrated Specialist Healthcare, Miranda, Australia
[2] Royal Prince Alfred Hospital, Camperdown, Australia
[3] The Skin & Cancer Foundation Australia, Westmead, Australia
[4] The University of Sydney, Camperdown, Australia
[5] Royal North Shore Hospital, Saint Leonards, Australia
[6] University of Wollongong, Loftus, Australia
[7] South Coast Dermatology, Kiama, Australia
[8] Wollongong Day Surgery, Wollongong, Australia

Introduction
Dermatofibrosarcoma protuberans (DFSP) is a rare cutaneous tumour with a locally infiltrative growth pattern that has high rates of recurrence. Mohs micrographic surgery is recommended as the gold-standard treatment over wide local excision (WLE) due to tissue-sparing and reduced recurrence rates. No previous data on surgical outcomes following Mohs Micrographic Surgery (MMS) for DFSP have been reported in Australia to date. This study aims to review the outcomes of DFSP treated with frozen-section MMS across three centres in New South Wales (NSW), Australia, and compare these outcomes with those in the current literature.

Materials and Methods
A retrospective review of patients who underwent MMS for DFSP between 2010-2023 were performed. Patient demographics, surgical treatment and follow-up data were collected. Recurrence was assessed through electronic medical records, clinical assessments by a dermatologist or general practitioner, and patient self-report.

Results
38 cases of DFSP were included (27 female, 11 male; median age 39 years, range 16–64). The trunk was the most common site. Clinical margins and Mohs stages were recorded in 37 of 38 cases, with 73% of cases cleared with clinical margins of ≤20 mm. Clinical or self-reported follow-up was available for 28 of 38 patients (73.6%) over a mean of 51 months (range, 5–132 months). No local recurrences were identified during this period.

Conclusions
This is the first Australian case series on MMS for DFSP. Our findings demonstrate no recurrences with follow-up and demonstrate that MMS may achieve clearance with smaller clinical margins than WLE. These results support international guidelines recommending MMS as the gold-standard treatment and highlight the need to improve access to MMS in Australia.

EADV CONGRESS
VIENNA
30 SEP - 3 OCT 2026

Abstract N°: 3524

Spontaneous Partial Regression of Merkel Cell Carcinoma in a Fitzpatrick Phototype IV Patient: A Rare Presentation

Thais Campello*[1], Gabriel Leite[1], Bernardo Peryassu[1]

[1] Instituto de Pós-Graduação em Ciências da Saúde - Izamar Milidiu da Silva, INCA - Instituto Nacional do Câncer, Rio de Janeiro, Brazil

Introduction

Merkel cell carcinoma (MCC) is a rare neuroendocrine neoplasm with aggressive behavior and a high rate of lymphatic metastasis. It most commonly arises in the head and neck region and typically occurs in elderly Caucasian males with a history of sun exposure, making its presentation in patients with darker phototypes uncommon. Spontaneous regression of MCC is rare, with fewer than 40 cases documented since 1986. We describe partial spontaneous regression of MCC in a patient with Fitzpatrick phototype IV.

Case Presentation

A 59-year-old female, Fitzpatrick phototype IV, presented in October 2025 with a 6-month history of a rapidly growing facial mass. CT revealed a 4.8 x 4.3 cm lobulated soft-tissue mass in the left maxillary region extending to the periorbital area, with a preserved cleavage plane from underlying bone. On subsequent examination, an 8 x 7 x 6 cm erythematous-violaceous, friable, ulcerated tumor was noted in the left malar and periorbital region. A punch biopsy was performed. Histopathology and immunohistochemistry showed CK20 perinuclear dot-like and synaptophysin positivity, with CK7 and GATA3 negativity, confirming MCC, T3N0Mx. After referral to Head and Neck Surgery, the lesion decreased in size. Follow-up MRI in December 2025 confirmed volumetric reduction. By February 2026, only a 2 cm hyperpigmented plaque remained in the left malar region. On May 5, 2026, the patient underwent wide local excision of the left malar lesion with advancement flap reconstruction, left superficial parotidectomy, and left selective neck dissection of levels IIA, IIB, and III. Final pathology of the residual lesion is pending.

Discussion: This case is atypical due to partial spontaneous regression in a Fitzpatrick IV patient, diverging from classic MCC epidemiology. Regression likely results from T-cell mediated immunity, though mechanisms remain undefined. Despite clinical regression, MCC retains high metastatic potential.

Conclusion

Partial spontaneous regression does not exclude residual disease or nodal metastasis. Complete staging, wide excision, and nodal evaluation remain mandatory.

EA DV CONGRESS
VIENNA
30 SEP - 3 OCT 2026

Abstract N°: 3528

Acceptance of Artificial Intelligence in Skin Cancer Screening in Germany: A Cross-Sectional Study

Alina Wacker[1], Jana Stucke[1], Jana Koch[1], Sabine Steinke*[1]

[1] University Bielefeld, Medical School OWL, Bielefeld, Germany

Introduction
The global burden of skin cancer is rising [1], and artificial intelligence (AI) is increasing in relevance in dermatological diagnostics, achieving a sensitivity of 87–91% and a specificity of 86–94% in skin cancer detection [2,3]. However, research into the acceptance of AI in skin cancer screening remains limited. This study aims to explore AI acceptance in Germany among screening participants (skin cancer screening within the last two years), non-participants, and patients with a prior skin cancer diagnosis, assessing overall acceptance as well as perceived benefits and concerns.

Materials and Methods
A nationwide cross-sectional study was conducted (April 2025 - March 2026), recruiting participants from dermatology and general practices as well as online channels. Items assessed trust in AI, willingness to use AI, perceived benefits, and concerns using five-point Likert scales. Descriptive statistics were calculated for all items. Subgroup comparisons were performed using Mann-Whitney U tests, comparing screening participants with non-participants and patients with a prior skin cancer diagnosis with those without. A complete case analysis was conducted.

Results
Of 405 participants, 258 (63.7%) had undergone skin cancer screening within the last two years and 82 (20.4%) had previously been diagnosed with skin cancer. Overall, 59.2% of respondents trusted AI for skin cancer detection, and 46.7% reported that the availability of AI would increase their willingness to have a skin cancer screening at a practice. A completely AI-based screening without physician involvement was rejected by 65.2% of respondents, while 96.8% rated physician review of AI findings as very important or important. The most commonly perceived benefits were monitoring of skin changes over time (95.3%), early detection of skin cancer (93.3%), and increased diagnostic accuracy (91.1%). Major or very serious concerns were expressed regarding AI replacing physician judgment (52.6%), lack of transparency in AI decision-making (30.8%) and AI errors (30.2%).
Screening participants reported fewer privacy concerns about AI ($p = 0.001$) and more frequently said that the availability of AI at a practice would increase their willingness to attend a skin cancer screening there ($p < 0.001$). Non-participants were more open to AI-only screening without a physician ($p < 0.001$). Participants with a prior skin cancer diagnosis more frequently indicated that AI availability at a practice would encourage them to attend screening there ($p = 0.002$) and considered the most up-to-date AI more important ($p < 0.001$). However, participants with a prior diagnosis were also more likely to reject AI-only screening without physician involvement ($p < 0.001$).

Conclusions
Participants accepted AI as a diagnostic tool in skin cancer screening but largely rejected AI-only screening without a physician. While they acknowledged the benefits of AI, concerns about errors and lack of transparency remain.

Given the acceptance rates observed in this study and AI's potential to improve diagnostic accuracy, implementing AI as a physician-assisted tool could improve skin cancer screening, provided that patient concerns are transparently addressed.

References:

1. Zhou L, Zhong Y, Le Han et al. Global, regional, and national trends in the burden of melanoma and non-melanoma skin cancer: insights from the global burden of disease study 1990-2021. *Scientific reports* 2025;15(1):5996.
2. Patel RH, Foltz EA, Witkowski A et al. Analysis of Artificial Intelligence-Based Approaches Applied to Non-Invasive Imaging for Early Detection of Melanoma: A Systematic Review. *Cancers* 2023;15(19).
3. Nadour N, Duguet T, Zahedi S et al. Diagnostic accuracy of artificial intelligence compared to family physicians and dermatologists for skin conditions: a systematic review and meta-analysis. *BMC primary care* 2025;26(1):384.

EA DV CONGRESS
VIENNA
30 SEP - 3 OCT 2026

Abstract N°: 3535

The Melanoma Environmental Stress Test Protocol: A Systematic Review Validating A New Dynamic Diagnostic Framework Combining Total Body Photography, Ai-Assisted Dermoscopy, And Microthermography

Krish Lightwala*[1], Randa Abdelhamid[1], Zeel Lightwala[1], Chanul Thennekoon[1]

[1] Belarusian state medical university, Minsk, Belarus

Introduction

Most melanoma screening tools look at a lesion's shape and color at a single point in time. That means they miss something important, how a mole or melanoma actually responds to real-world triggers like sunlight or heat. To current knowledge, no open-source framework exists that combines sequential total body photography, AI-driven dermoscopy, and microthermography under controlled stress. Therefore, the Melanoma Environmental Stress Test (MEST) Protocol was developed. It is the first dynamic, freely accessible diagnostic approach that measures how a lesion behaves under mild thermal and UV stress – helping decide which lesions truly need biopsy.

Materials and Methods

PRISMA guidelines were followed and the protocol was registered (PROSPERO CRD42024516789). A systematic search of PubMed, Scopus, and IEEE Xplore (2015–2025) found 1,204 records. Studies were kept that used at least two of the three MEST components (total body photography, AI dermoscopy, microthermography) with at least 12 months of follow-up. After screening, 47 studies remained, covering 8,932 patients and 21,456 nevi. Three dynamic features were extracted: thermal recovery half time (TRH), UV induced erythema decay, and an AI derived asymmetry change index (ACI). Using Python, scikit learn, and XGBoost with nested cross validation, a risk predictor was trained on 60% of lesions (n=12,874) and validated on the remaining 40% (n=8,582). The ground truth was either histopathology or 18 months stability on imaging. SHAP analysis identified which features mattered most.

Results

The MEST risk score performed very well, with a ROC AUC of 0.92 (95% CI, 0.89–0.95), overall accuracy of 88.3%, precision of 0.85, and recall of 0.91 for detecting lesions that turned out to be melanoma or high grade atypia within 18 months. The most powerful predictors were: a TRH longer than 90 seconds (odds ratio 6.2), an ACI above 0.21 (odds ratio 4.8), and patchy pigmentation after UV stress (odds ratio 3.9). Adding microthermography alone increased sensitivity by 14% compared to using AI dermoscopy by itself. In a real world test (450 lesions followed for 12 months), MEST reclassified 22% of previously "equivocal" lesions as low risk, saving them from unnecessary surgery, and flagged 9% of "benign looking" lesions as high risk, which were later confirmed as early melanoma in situ after excision.

Conclusions

The Melanoma Environmental Stress Test Protocol is the first open source, validated dynamic framework that combines total body photography, AI assisted dermoscopy, and microthermography. By watching how a lesion

responds to environmental stress rather than just how it looks at rest, MEST outperforms static screening. The full code, thermal stimulation settings, and AI model weights are publicly available for anyone to validate further or integrate into clinical workflows.

EADV CONGRESS
VIENNA
30 SEP - 3 OCT 2026

Abstract N°: 3545

Intralesional Methotrexate for the Treatment of Thick Plaque Mycosis Fungoides: Revisiting an Underutilized Classic

Jehad Alassaf*[1]

[1] King Hussein Medical Center, Royal Medical Services, Amman, Jordan

Introduction

Mycosis Fungoides is the most common form of cutaneous T cell lymphoma. It presents with patches and plaques that can rarely progress to tumors. It usually has an indolent course but in cases which progress can be recalcitrant. Rarely, tumors can transform and have a significant proportion of large cells.

Treatment follows the stages and the response. In early stages, emollients, can be used along with topical steroids. Phototherapy is an effective modality and can be sufficient for early stages. Methotrexate is a well-established option for the treatment of mycosis fungoides that is more advanced. Other treatments include brentuximab, mogamulizumab, chemotherapy, and stem cell transplantation.

Case Presentation

A 47-year-old man, presented with a 15-year history of generalized erythematous to hyperpigmented patches and thin plaques. He was diagnosed with mycosis fungoides years ago after biopsies, and was being treated with topical steroids and phototherapy. In the last couple of years, some of the lesions started becoming more of thick plaques and tumor-like nodules. Thorough evaluation and biopsies showed transformation, with large cells forming a significant proportion. No lymph nodes were enlarged. During his treatment course, the patient was referred to hemato-ocology and low dose gemcitabine in six cycles was given. He responded but then plaques developed, the largest being an on the right shoulder and showed an thick plaque with central ulceration. At this stage, intralesional methotrexate was suggested. Methotrexate was diluted and injected via infiltration into the thick portion of the plaque. It responded greatly and on the next follow up it had flattened with an excellent response and no reported systemic side effects.

Conclusion

Methotrexate is an effective and tolerable treatment option for thick plaque and tumor stage mycosis fungoides. In the case presented, it was shown effective in thick plaques with large cell transformation. Methotrexate is an easy and available option that can be utilized in recalcitrant isolated plaques and tumors and in transformation.

EADV CONGRESS
VIENNA
30 SEP - 3 OCT 2026

Abstract N°: 3552

From Sclerosis to Vascular Proliferation: Iatrogenic Kaposi's Sarcoma Arising on a Morphea Plaque

Douae Jayat*[1], Sara Elloudi[1], IKRAME BEJJA[1], Saadia Boughaleb[1], Zakia Douhi[1], Meryem Soughi[1], Hanane Baybay[1], Fatima Zohra Mernissi[1]

[1] Department of Dermatology, Hassan II University Hospital, Fes, Morocco

Introduction

Kaposi's sarcoma (KS) is a vascular neoplasm associated with infection by Human herpesvirus-8 (HHV-8), occurring preferentially in the setting of immunosuppression. Four epidemiological forms are classically described: classical, endemic, HIV-associated epidemic, and iatrogenic. The latter is mainly reported in transplant recipients but may also occur during immunosuppressive therapies administered for autoimmune diseases. We report a rare case of iatrogenic KS developing within a morphea plaque in a patient treated with systemic corticosteroids and methotrexate.

Case Presentation

A 60-year-old patient, HIV-seronegative, was being treated for localized morphea with monthly intravenous methylprednisolone pulses (1 g/day for three days) combined with methotrexate (25 mg/week). After six months of treatment, angiomatous nodules and violaceous plaques appeared within the initial sclerotic plaque.

Skin histology revealed a well-circumscribed dermal proliferation of spindle cells forming irregular vascular slit-like spaces with erythrocyte extravasation, associated with a lymphoplasmacytic inflammatory infiltrate rich in sidérophages.

Immunohistochemical analysis showed strong nuclear positivity for ERG and diffuse staining for HHV-8 (LANA-1), confirming the diagnosis of Kaposi's sarcoma. HIV serology was negative and staging investigations revealed no extracutaneous involvement.

After the corticosteroid bolus was completed, methotrexate was continued. Topical timolol maleate was initiated, leading to progressive regression and complete disappearance of the lesions within a few months.

Conclusion

This case highlights the exclusive localization of lesions within the morphea plaque, suggesting a role for the local microenvironment in the tumorigenesis of Kaposi's sarcoma. It also underscores the importance of individualized management. Reducing or discontinuing immunosuppressive therapy may lead to regression of the lesions; however, this decision must be carefully considered in light of the extent of the Kaposi's sarcoma and the underlying disease requiring immunosuppression.

EA DV CONGRESS
VIENNA
30 SEP - 3 OCT 2026

Abstract N°: 3555

High-Sensitivity Proteomics Identifies Viral Oncoproteins and Distinct, Targetable Tumor Signatures in Merkel Cell Carcinoma

Sonja Kabatnik[1], Ying Zhang[1], Christina Martins[2], Ann Mari Rosager[3], Michael Bzorek[4], Sofie Agerbæk[1], Marcel Teunissen[5], Jessica Teague[2], Ahmed Gehad[2], Rachel Clark[2], Steve Barthel[2], Tobias Schatton[2], Marianne Løvendorf[1, 6, 7], Beatrice Dyring-Andersen*[1, 2, 6, 8]

[1] Department of Dermatology, Zealand University Hospital, Roskilde, Denmark
[2] Department of Dermatology, Mass General Brigham, Harvard Medical School, Boston, United States
[3] Department of Pathology, Hospital of Southern Jutland, Aabenraa, Denmark
[4] Department of Pathology, Zealand University Hospital, Køge, Denmark
[5] Amsterdam Institute for Immunology and Infectious Diseases, Amsterdam, Netherlands
[6] LEO Foundation Skin Immunology Research Center, Department of Immunology and Microbiology, Faculty of Health and Medical Sciences, University of Copenhagen, Copenhagen, Denmark
[7] Department of Dermatology and Allergy, Copenhagen University Hospital, Herlev and Gentofte Hospital, Copenhagen, Denmark
[8] Department of Clinical Medicine, Faculty of Health and Medical Sciences, University of Copenhagen, Copenhagen, Denmark

Introduction

Merkel cell carcinoma (MCC) is a rare, highly aggressive cutaneous neuroendocrine carcinoma associated with sun exposure or Merkel cell polyomavirus infection. Its frequently non-specific clinical presentation renders diagnosis dependent on immunohistochemical staining, and the limited molecular characterization of MCC and low incidence has left new treatment strategies largely extrapolated from other cancer types.

Materials and Methods

To address this gap, we applied laser microdissection to spatially isolate tumor and adjacent non-tumor regions from 20 paired MCC patient samples, followed by ultra-high sensitivity mass spectrometry.

Results

We quantified over 9,900 proteins, including low-abundance MCC markers and the viral large and small T antigens, and revealed clear separation between tumor and non-tumor proteomes with 3,336 differentially expressed proteins. Proteins significantly enriched in tumor samples were predominantly involved in proliferation, specifically RNA processing and splicing, and epigenetic regulation. To identify drug repurposing candidates for MCC treatment, we complemented our clinical proteomic data with proteomic characterization of MCC cell lines, revealing both shared molecular features with patient-derived tumor samples and distinct cell line-specific patterns. We identified RNA polymerase I and aurora kinase/CDK1/2 signaling as therapeutic vulnerabilities, leading to the evaluation of CX-5461 and CAS 443797-96-4 as repurposing candidates. Both drugs demonstrated significant effects on cell viability across multiple MCC cell lines using orthogonal methodology. *In vivo* validation confirmed these findings, with both drugs independently reducing tumor volume significantly in mice engrafted with MCC tumor cells.

Conclusions

Together, these results demonstrate that deep proteomic profiling of rare skin cancers can identify and functionally validate drug repurposing candidates, offering a rational therapeutic strategy for MCC, a malignancy with rising incidence and limited treatment options.

EADV CONGRESS
VIENNA
30 SEP - 3 OCT 2026

Abstract N°: 3562

Predicting a metachronous cutaneous squamous cell carcinoma: a competing-risk model based on nationwide linked registries.

Andrya Reder Hollatz*[1], Celeste J Eggermont[1], Barbara Rentroia-Pacheco[1], Antien L. Mooyaart[1], Tamar Nijsten[1], Marlies Wakkee[1], Loes Hollestein[1]

[1] Erasmus University Medical Center, Rotterdam, Netherlands

Introduction
following a first cutaneous squamous cell carcinoma (CSCC), approximately one-third of patients develop new primaries, escalating their risk of metastasis and poor outcomes. However, current follow-up strategies lack risk stratification, representing a critical gap in patient management.

Materials and Methods
we conducted a nationwide, population-based cohort study of 11,737 patients with a first histologically confirmed CSCC (Netherlands Cancer Registry, 2007-2008) with up to 10 years of follow-up. Subsequent tumors were identified via linkage to the Automated National Pathological Anatomy Archive (Palga). A Fine-Gray competing-risk model was developed using routinely available clinical and pathological predictors. Model performance was assessed 10-fold cross-validation, quantifying discrimination (time-dependent area under the receiving operator characteristic curve [AUCt]) and calibration. Clinical utility was evaluated using Decision Curve Analysis (DCA) and tertile risk stratification.

Results
during follow-up, 3,288 (28%) developed a first metachronous CSCC. Key predictors included markers of cumulative UV-exposure (included AK history, ≥5 prior BCCs), and chronic lymphocytic leukaemia/small lymphocytic leukaemia (CLL/SLL). Male sex and presence of synchronous CSCC at baseline were also associated with higher risk. While discrimination was modest (cross-validated 5-year AUCt: 0.64), the model demonstrated excellent calibration across all predictor subgroups. DCA showed modest net benefit for predicted probabilities between 18% and 45%. Risk stratification into tertiles revealed a nearly five-fold acceleration: the high-risk tertile reached a 15% cumulative incidence in 1.4 years, compared to 6.9 years for the low-risk tertile.

Conclusions
this competing-risk model provides individualized, well-calibrated absolute risk estimates for a first metachronous CSCC. Based on routinely available clinical features, it offers insight into how established predictors shape risk in this high-susceptibility population and quantifies relative risk acceleration. External validation and the identification of novel predictors are necessary to further refine the model and support personalized surveillance strategies.

EA DV CONGRESS
VIENNA
30 SEP - 3 OCT 2026

Abstract N°: 3572

Impact of an artificial intelligence as a medical device community pathway on urgent suspected skin cancer referral demand: a retrospective real-world evaluation

Joanna Dempsey*[1], Nicholas Philo[2], Caroline Angus[2], Simon Leigh[1]

[1] Health Innovation East, Cambridge, United Kingdom

[2] NHS Norfolk and Suffolk ICB, Norwich, United Kingdom

Introduction

To address rising pressure on dermatology services, a Health Innovation Network commissioned an evaluation of an innovative community skin lesion pathway using artificial intelligence as a medical device (AIaMD), on the urgent suspected skin cancer (USSC) referral volume and quality.

Materials and Methods

The pathway used AIaMD in screening, triage and assessment of lesions suspicious for skin cancer in community diagnostic settings. High-risk lesions were routed to the USSC pathway; lower-risk lesions were redirected to primary care, routine care or discharged with safety-netting.

Referral impact was assessed using controlled interrupted time-series analysis with a fuzzy intervention phase [1,2], comparing practices with and without pathway access over 27 months pre- and post-implementation, with Newey-West standard errors and small sample-size correction [3].

Referral quality was assessed using conversion rate, defined as USSC referrals resulting in high-risk skin cancer diagnosis, and detection rate, defined as high-risk cancers diagnosed via the USSC pathway. Statistical comparisons are made using two-tailed Two-Proportion Z Tests (significance threshold $p < 0.05$).

Results

40 practices participating in the AIaMD pathway were evaluated against 62 non-participating control practices from the same locality. Participating practices made 9,976 USSC referrals in the final year of available data.

In controlled interrupted time-series analysis, participating practices had a significant post-implementation step-reduction of approximately 89 USSC referrals per month versus the modelled counterfactual without the pathway ($p<0.001$) (Figure 1). This is equivalent to 1,068 fewer referrals annually, or 10% fewer than the 11,044 expected without the pathway.

Among patients accessing the AIaMD pathway there was a statistically significant increase in both the USSC conversion rate increased from 7.5% [95% CI 7.0–7.9] to 9.4% [8.3–10.6] ($p = 0.0017$), and detection rate from 71.4% [69.0–73.6] to 94.4% [89.0–97.3] ($p = <0.001$), compared with the pre-deployment local baseline.

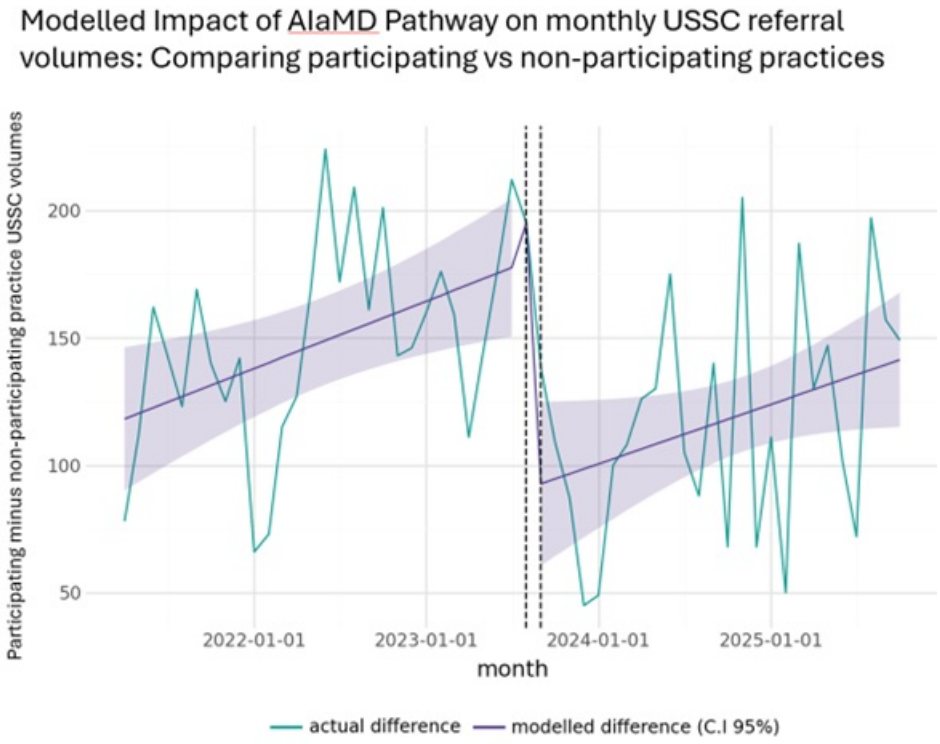

Figure 1: Modelled impact of the community AIaMD pathway on monthly USSC referral volumes. Monthly difference in urgent suspected skin cancer (USSC) referral volumes between participating and non-participating practices, before and after pathway implementation. A statistically significant upward pre-intervention trend was observed ($p<0.05$). Following implementation, participating practices showed a statistically significant step reduction of approximately 89 referrals per month relative to non-participating practices ($p<0.001$), with no evidence of a post-intervention change in trend.

Conclusions

An AIaMD community skin lesion pathway was associated with reduced USSC referrals, and higher conversion and detection rates.

[1] Lopez Bernal J, Cummins S, Gasparrini A. The use of controls in interrupted time series studies of public health interventions. Int J Epidemiol. 2018;47(6):2082-2093. doi:10.1093/ije/dyy135.

[2] de Chaisemartin C, D'Haultfoeuille X. Fuzzy differences-in-differences. Rev Econ Stud. 2018;85(2):999-1028. doi:10.1093/restud/rdx049

[3] Lee DK. Improving causal inference in observational studies: interrupted time series design. Cardiovasc Prev Pharmacother. 2020;2(1):18-23. doi:10.36011/cpp.2020.2.e2

EADV CONGRESS
VIENNA
30 SEP - 3 OCT 2026

Abstract N°: 3592

The 31-gene expression profile test for cutaneous melanoma accurately identifies patients with transected tumors at high and low 5-year risk of recurrence

Joseph Gadzia[1], Lindsay Ackerman[2], Jeffrey Sussman[3], Abel Jarrell[4], Brian Martin*[5], Craig Kraffert[6]

[1] Kansas Medical Clinic, Topeka, KS, United States
[2] Medical Dermatology Specialists, Phoenix, AZ, United States
[3] University of Cincinnati Medical Center, Cincinnati, OH, United States
[4] StracSkin, Portsmouth, NH, United States
[5] Castle Biosciences, Inc., Friendswood, TX, United States
[6] CK Derm, Redding, CA, United States

Introduction
Accurate assessment of Breslow thickness in cutaneous melanoma (CM) is critical for accurate staging; however, shave biopsy frequently results in deep transection with positive margins (up to 40% of cases), leading to inaccurate staging and potentially underestimating prognosis. The 31-gene expression profile (31-GEP) test provides personalized, objective molecular tumor risk of recurrence independent of Breslow thickness, which can be used to help guide management decisions.

Materials and Methods
We evaluated how the 31-GEP stratified risk among patients with transected tumors. This retrospective analysis included 687 patients with stage I–III CM and deep-margin-positive initial biopsy who underwent clinical 31-GEP testing (2013-2017). Median follow-up was 4.22 years. Kaplan-Meier analysis was used to estimate 5-year recurrence-free survival (RFS), with log-rank tests comparing outcomes by 31-GEP Class.

Results
Among stage I–III CM patients transected tumors, the 31-GEP significantly stratified 5-year RFS (Class 1A=93.2%, Class 1B/2A=75.1%, vs. Class 2B=64.1%, $p<0.001$). In the stage I–IIA subgroup, where transection may result in mis-staging and altered management recommendations, the 31-GEP also significantly stratified 5-year RFS (Class 1A=94.4%, Class 1B/2A=82.4%, vs. Class 2B=73.7%, $p<0.001$).

Conclusions
The 31-GEP test accurately identifies patients with a transected tumor at low versus high risk of recurrence, allowing clinicians and patients to make risk-appropriate surveillance, sentinel lymph node biopsy, and treatment management decisions in this common clinical scenario.

EA DV CONGRESS
VIENNA
30 SEP - 3 OCT 2026

Abstract N°: 3597

The Itchy Ulcer That Wouldn't Heal: A Diagnostic Challenge Revealing Extramammary Paget Disease

Alia H. Ramadan[1], Yousef Husseiny*[2], Mona R. E. Abdelhalim[1]

[1] Faculty of Medicine, Cairo University, Cairo, Egypt
[2] Faculty of Medicine, NewGiza University, Giza, Egypt

Introduction

Extramammary Paget disease (EMPD) is a rare intraepithelial adenocarcinoma that often presents as nonspecific inflammatory dermatosis, leading to delayed diagnosis. Secondary EMPD may result from epidermotropic spread of an underlying visceral malignancy, most commonly of colorectal or genitourinary origin. Perianal involvement is associated with a potential risk of internal malignancy.

Case Presentation

A 45-year-old female with a history of atopic dermatitis, hypertension, and dyslipidemia presented with a one-year history of a progressively enlarging, intensely pruritic perianal lesion. It started as itchy papules that became confluent into an eroded plaque and finally an ulcer with nocturnal exacerbation. Clinical examination revealed an ulcer adjacent to the anal opening with a fleshy base and irregular, fungating border. The initial differential diagnosis included Crohn disease, deep fungal infection, squamous cell carcinoma, and pyoderma gangrenosum.

Two punch biopsies were received. Histopathological examination showed marked hyperkeratosis with focal parakeratosis and psoriasiform epidermal hyperplasia. The epidermis was permeated by large atypical cells with pale amphophilic cytoplasm and vesicular nuclei, arranged singly and in clusters, with focal ductal differentiation. Multiple mitoses, including atypical forms, and dyskeratotic cells were present within the epidermis, along with a superficial upper dermal inflammatory infiltrate. Immunohistochemistry demonstrated strong CK7 positivity, weak CK20 positivity, and negative Melan-A expression.

Immunohistochemistry demonstrated strong CK7 positivity, weak CK20 positivity, and negative Melan-A expression, supporting a diagnosis of EMPD. Although CK7+/CK20+ co-expression raised concern for secondary disease, no primary tumor was identified.

Pelvi-abdominal ultrasonography showed hepatomegaly with benign-appearing hemangiomas and uterine fibroids. PET-CT revealed no FDG-avid malignancy or hypermetabolic lymphadenopathy, and colonoscopy was unremarkable.

The case was discussed in a multidisciplinary meeting; considering the size of the lesion and the risk of functional morbidity, wide excision was not the first choice. Topical imiquimod was suggested, with consideration of Mohs surgery.

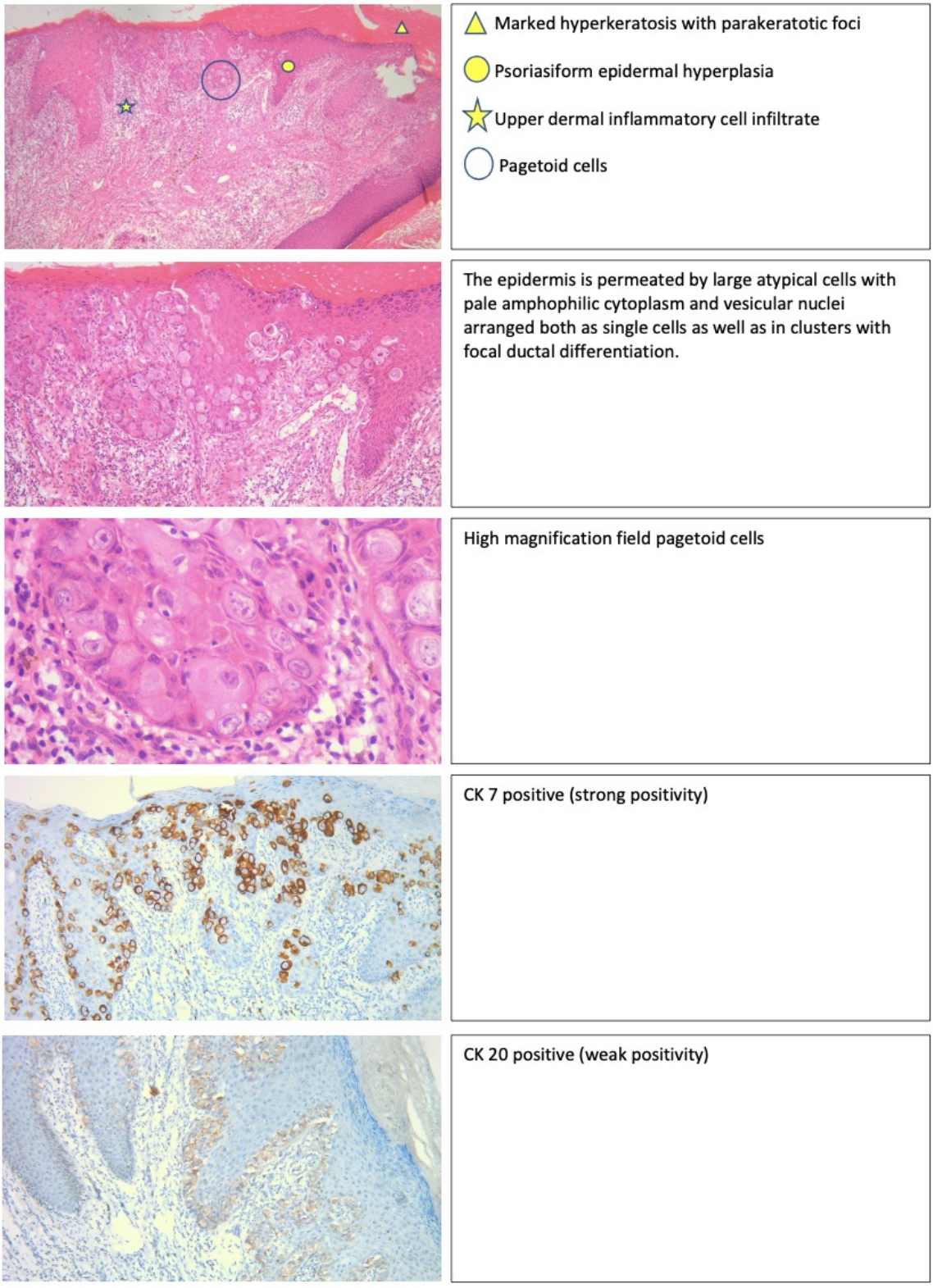

Biopsy

Conclusion

This case highlights EMPD presenting as a chronic perianal ulcer with nonspecific features at an age younger than the usual peak incidence of EMPD (60–70 years) emphasizing diagnostic challenges related to clinicopathologic overlap. Although CK7/CK20 co-expression may suggest secondary disease, it can also be seen in primary perianal EMPD. Careful clinicopathologic correlation and early biopsy are essential in chronic perianal lesions. Long-term surveillance is required even in the absence of an identified primary malignancy, as related internal malignancies have been reported up to 5 years after initial diagnosis.

EADV Congress 2026, VIENNA
30 SEPTEMBER - 03 OCTOBER 2026
POWERED BY M-ANAGE.COM

EADV CONGRESS
VIENNA
30 SEP - 3 OCT 2026

Abstract N°: 3608

When mucin meets lymphoma: A rare collision of Reticular Erythematous Mucinosis and Mycosis Fungoides

Sara Pană*[1, 2], Olga Simionescu[1, 2]

[1] Colentina Clinical Hospital, Bucharest, Romania

[2] Carol Davila University of Medicine and Pharmacy, Bucharest, Romania

Introduction

Reticular Erythematous Mucinosis (REM) is a rare form of primary cutaneous mucinosis with unclear pathogenesis. It has often been associated with inflammatory conditions, malignant disorders, ultraviolet radiation or disorders linked to the immune system. Its association with mycosis fungoides has only exceptionally been reported within the peer-reviewed literature and to our knowledge, this is the first documented case of REM in a patient previously diagnosed with MF within our medical institution. This report highlights the importance of an exhaustive differential diagnosis of persistent erythematous lesions, especially in a patient with a history of malignancy. Also, our findings emphasize the indispensable contribution of histopathology, immunohistochemical profiling, and dermoscopy to the establishment of an accurate and comprehensive clinical picture.

Case Presentation

A 52-year-old non-smoking female patient, previously diagnosed with stage I patch-type Mycosis Fungoides without systemic involvement, with disease onset in April 2022, developed an acute eruption of sudden onset, reportedly triggered by a stressful event, consisting of a disseminated exanthem with individual and confluent papules, finely scaly erythematous violaceous plaques, some showing slight infiltration, non-pruritic in nature, involving both the upper and lower limbs. The patient was still following the treatment for MF consisting in oral retinoids when the eruption occurred.

The uniqueness of this case resides in the patient's excellent adherence to treatment for Mycosis Fungoides, consisting of ten PUVA therapy sessions performed in our department, followed by oral retinoids combined with vitamin D supplementation and hepatoprotective therapy. Given the favorable therapeutic response with a 90% remission of lesions, a repeat biopsy was performed, with histopathological findings supporting a diagnosis of Reticular Erythematous Mucinosis rather than progression of MF.

Conclusion

REM-like eruptions in patients with MF may represent either a distinct mucinosis or an atypical manifestation of CTCL, requiring careful clinicopathological correlation.

EA DV CONGRESS
VIENNA
30 SEP - 3 OCT 2026

Abstract N°: 3612

Non-Melanoma Skin Cancers in Pigmented Skin: Clinical Challenges and the Evolving Role of Hedgehog Inhibitors and Immunotherapy

Kajomi Shingala*[1], Dipesh Nariya[1]

[1] M P Shah Medical College, Jamnagar, India

Introduction

Non-melanoma skin cancers, particularly basal cell carcinoma and cutaneous squamous cell carcinoma, are traditionally considered uncommon in darker phototypes. However, this perception likely reflects under-recognition, delayed diagnosis, and limited epidemiologic reporting rather than true rarity. In pigmented skin, NMSC frequently presents with atypical morphology, reduced clinical suspicion, and involvement of non–sun-exposed sites, often resulting in more advanced disease at presentation. Cutaneous SCC in darker phototypes commonly arises in chronic scars, burns, ulcers, and sites of longstanding inflammation, while pigmented variants of BCC may mimic benign melanocytic or inflammatory lesions. Over the past decade, systemic management of advanced NMSC has undergone major therapeutic transformation with the introduction of Hedgehog pathway inhibitors for advanced BCC and immune checkpoint inhibitors targeting programmed death-1 for advanced cSCC and HHI-refractory BCC.

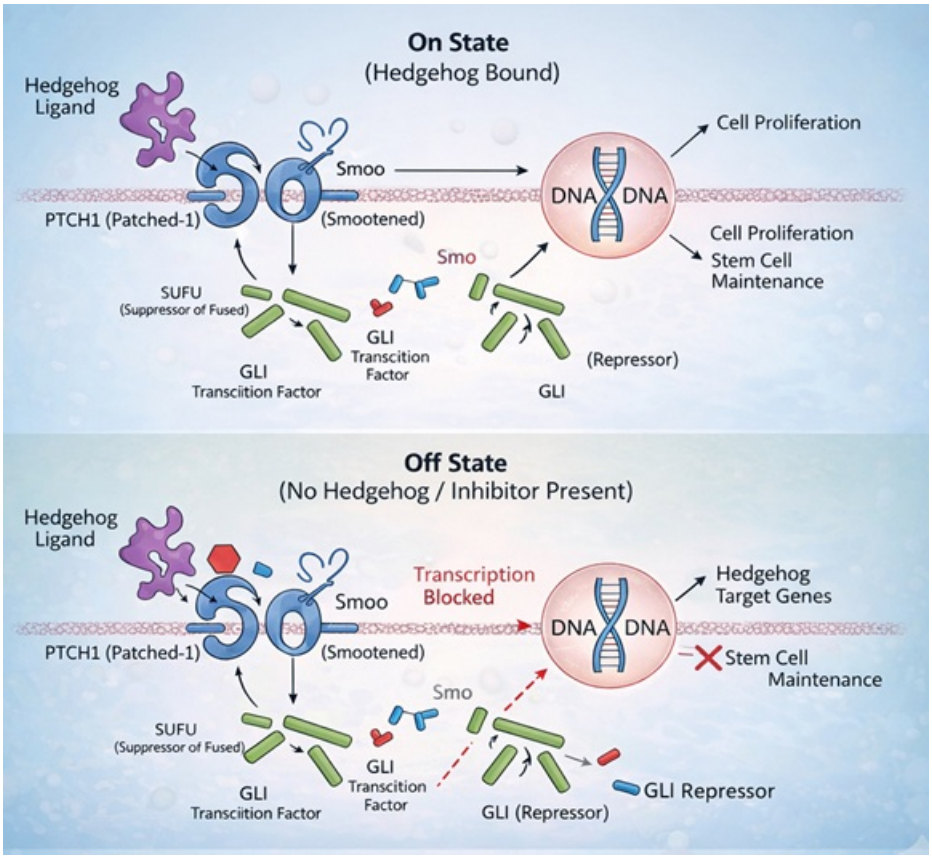

Figure 1: Molecular mechanism of Hedgehog inhibitors (original image). Hh: Hedgehog (signalling ligand), PTCH1: Patched-1 receptor SMO: Smoothened receptor, SUFU: Suppressor of Fused, Gli: Glioma-associated oncogene transcription factors, HHI: Hedgehog Pathway Inhibitor, DNA: Deoxyribonucleic Acid

Materials and Methods

A comprehensive narrative review of the literature was conducted using PubMed, Scopus, and Google Scholar databases. Published English-language studies evaluating epidemiology, clinical presentation, dermoscopy, pathology, risk factors, systemic therapies, immunotherapy, and Hedgehog pathway inhibition in NMSC were reviewed. Evidence from clinical trials, long-term extension studies, observational cohorts, guideline recommendations, and translational research was synthesized to provide a clinically oriented overview of NMSC in pigmented-skin populations. The objective was to review the epidemiology, diagnostic challenges, clinicopathologic features, and evolving systemic management of NMSC in pigmented skin, with emphasis on the role of Hedgehog inhibitors and immunotherapy.

Results

NMSC in pigmented skin demonstrates important epidemiologic and clinical differences compared with white-skinned populations. Ultraviolet radiation remains a major carcinogenic factor, UV-independent mechanisms such as chronic inflammation, burn scars, persistent ulcers, radiation damage, and immunosuppression play a greater role in darker phototypes. cSCC occurs relatively more frequently in pigmented skin and often behaves aggressively when arising in chronic scars or Marjolin ulcers.

Diagnosis is frequently delayed because classical features of BCC, including pearly translucency and telangiectasia, may be subtle or absent in pigmented skin. Pigmented BCC commonly presents as dark papules, plaques, or ulcerated lesions. These lesions are frequently misdiagnosed, histopathology remains the diagnostic gold standard. Advanced tumors unsuitable for surgery or radiotherapy increasingly require systemic therapy. Hedgehog pathway inhibitors such as vismodegib and sonidegib have transformed the management of advanced BCC by targeting aberrant SMO signaling, with clinical trials demonstrating durable responses in locally advanced disease.

PD-1 inhibitors including cemiplimab and pembrolizumab have similarly improved outcomes in advanced cSCC and now represent first-line systemic therapy for unresectable or metastatic disease, while also serving as second-line therapy in HHI-refractory BCC. Treatment selection depends on histology, resectability, toxicity profile, and multidisciplinary assessment. Early biopsy of suspicious or non-healing lesions remains essential for improving outcomes in pigmented-skin populations.

Conclusions

NMSC in pigmented skin presents unique epidemiologic, diagnostic, and therapeutic challenges that contribute to delayed diagnosis and more advanced disease at presentation. Hedgehog pathway inhibitors and PD-1 inhibitor immunotherapy have fundamentally changed the treatment landscape for advanced BCC and cSCC, offering durable and organ-sparing therapeutic options in previously difficult-to-manage disease. Continued research focused on pigmented-skin populations is needed to optimize diagnostic strategies, improve therapeutic access, and refine long-term management approaches.

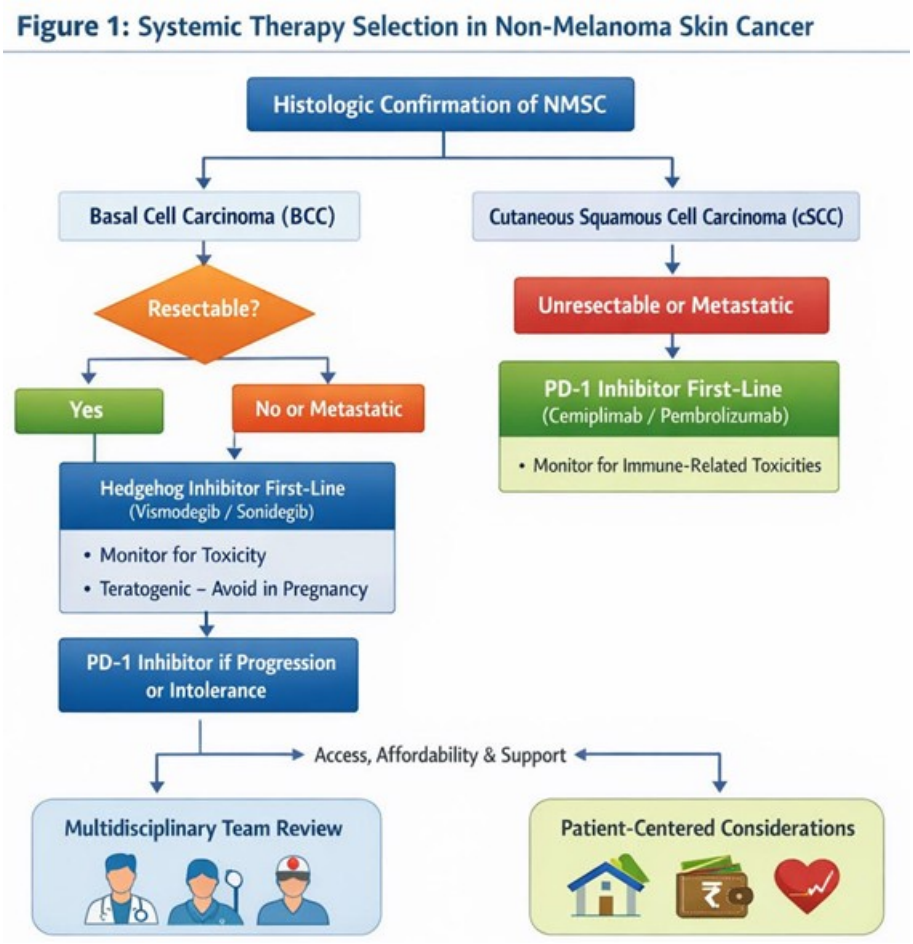

Figure 2: Selection of systemic therapy in NMSC (Original Image) Systemic therapy selection in non-melanoma skin cancer begins with histological confirmation and assessment of resectability. For basal cell carcinoma, Hedgehog pathway inhibitors are first-line systemic therapy when the disease is locally advanced, metastatic, or not amenable to curative surgery or radiotherapy; PD-1 inhibitors are considered following HHI failure or intolerance. For cutaneous squamous cell carcinoma, PD-1 inhibitors are first-line systemic therapy when the disease is unresectable, recurrent, or metastatic. Treatment choice is influenced by toxicity profile, comorbidity, patient preference, and access to therapy. Multidisciplinary review and close toxicity monitoring are essential throughout.

EADV CONGRESS
VIENNA
30 SEP - 3 OCT 2026

Abstract N°: 3614

Dermoscopic features of invasive cutaneous squamous cell carcinoma in organ transplant recipients: a tertiary-center retrospective study

Jesus Cornudella-Lema*[1], Adrián Lario-González[1], Ignasi Martí-Martí[1], Francesc Alamon Reig[1]

[1] Department of Dermatology, Institut Clínic de Medicina i Dermatologia (ICMiD), Hospital Clínic de Barcelona, Baracelona, Spain

Introduction

Solid organ transplant recipients (SOTRs) are at increased risk of developing cutaneous squamous cell carcinoma (cSCC), often with a high keratinocyte tumor burden and accelerated field cancerization. While dermoscopic criteria for invasive cSCC have mainly been described in immunocompetent patients, dermoscopic patterns in immunosuppressed SOTRs remain poorly characterized in real-world cohorts.

Materials and Methods

Objective: To describe dermoscopic features of histopathologically confirmed invasive cSCC in SOTRs and provide real-world frequencies of predefined dermoscopic criteria.

We performed a retrospective, single-center study at a tertiary referral hospital, analyzing dermoscopic images from fifty-five histopathologically confirmed cSCCs in twenty-eight SOTRs. Clinical and dermoscopic features were systematically evaluated, including vascular patterns, keratinization, ulceration, and background structures.

Results

Fifty-five invasive cSCC lesions in SOTRs with recorded dermoscopy were included. Lesions were mainly located on the head/neck (54.5%), followed by upper limbs (23.6%), trunk (10.9%) and lower limbs (10.9%). Tumor size was available for 53 lesions: <2 cm (79.2%), 2–4 cm (18.9%) and >4 cm (1.9%). Histological differentiation was available for 50 lesions: well differentiated (48.0%), moderately differentiated (44.0%) and poorly differentiated (8.0%). High risk criteria assessment was available for 52 lesions: deep invasion (7.7%), perineural invasion (1.9%), no vascular or bone invasion was recorded. Dermoscopically, the most frequent criteria were erythema (85.5%) and white/yellow scale (78.2%), followed by structureless white areas (58.2%). Vascular findings were common, with irregular linear vessels in 50.9% and hairpin vessels in 27.3%; dotted and glomerular vessels were less frequent (21.8% and 9.1%, respectively). Keratinization-related signs were frequent, including a central keratin mass in 45.5% and yellow globules in 41.8%. Signs of surface disruption and bleeding were also observed (erosion 40.0%, superficial hemorrhages/blood spots 49.1%), while ulceration was present in 29.1%. Rosettes and red starburst-like structures were uncommon (7.3% each).

Table 1A. General characteristics		
Characteristic	**Category**	**n/N (%)**
Location		
	Head/neck	30/55 (54.5%)
	Upper limbs	13/55 (23.6%)
	Trunk	6/55 (10.9%)
	Lower limbs	6/55 (10.9%)
Tumor size		
	< 2 cm	42/53 (79.2%)
	2-4 cm	10/53 (18.9%)
	>4 cm	1/53 (1.9%)
Differentiation		
	Well differentiated	24/50 (48.0%)
	Moderately differentiated	22/50 (44.0%)
	Poorly differentiated	4/50 (8.0%)
High-risk histopathologic features		
	Deep invasion (>6 mm and/or beyond subcutaneous tissue)	4/52 (7.7%)
	Perineural invasion	1/52 (1.9%)
	Vascular/lymphatic invasion	0/52 (0.0%)
	Bone invasion	0/52 (100.0%)

Table 1B. Dermoscopic criteria	
Dermoscopic criterion	**n/N (%)**
Erythema	47/55 (85.5)
White/yellow scale	43/55 (78.2)
Structureless white areas	32/55 (58.2)
Irregular linear vessels	28/55 (50.9)
Superficial hemorrhages/blood spots	27/55 (49.1)
Central keratin mass	25/55 (45.5)
Yellow globules	23/55 (41.8)
Erosion	22/55 (40.0)
Ulceration	16/55 (29.1)
Hairpin vessels	15/55 (27.3)
Dotted vessels	12/55 (21.8)
Red pseudonetwork	8/55 (14.5)
Glomerular vessels	5/55 (9.1)
Red starburst	4/55 (7.3)
Rosettes	4/55 (7.3)

Table 1. Characteristics and dermoscopic findings of invasive cSCC.

Conclusions

In our cohort of SOTRs with invasive cSCC and recorded dermoscopy, lesions frequently showed prominent erythema together with structureless white areas and irregular vascular patterns. These observations raise the possibility that dermoscopic appearances of cSCC in immunosuppressed patients may differ from patterns predominantly described in immunocompetent cohorts, potentially reflecting a more inflamed and less differentiated-appearing phenotype. Further comparative studies are warranted to clarify the specificity and diagnostic relevance of these features.

EADV CONGRESS
VIENNA
30 SEP - 3 OCT 2026

Abstract N°: 3618

Carcinoma en Cuirasse: A Rare Cutaneous Manifestation of Metastatic Breast Cancer

Sabrina Saidi*[1], Mariame Meziane[1], Syrine Hamada[1], Najwa Ammar[1], Narjess Errachdy[1], Nadia Ismaili[1], Leila Benzekri[1]

[1] CHU Ibn Sina, Université Mohammed V Souissi, Rabat, Rabat, Morocco

Introduction

Carcinoma en cuirasse is a rare clinical presentation of cutaneous metastases (1), characterized by tumoral infiltration of the skin and subcutaneous tissue, resulting in an indurated and sclerotic appearance of the affected area (2). It is suggestive of locoregional or metastatic dissemination and may sometimes reveal neoplastic recurrence or progression (1). We report a case of carcinoma en cuirasse secondary to metastatic breast cancer.

Materials and Methods

A 46-year-old woman with a history of right breast cancer metastatic to the lungs presented with a two-month history of progressive sclerodermiform induration involving the right hemithorax. Her oncologic history included mastectomy in 2022, several cycles of chemotherapy, 15 sessions of radiotherapy, and hormonal therapy.

Clinical examination revealed an infiltrated erythematous plaque with multiple satellite erythematous papules over the anterior right hemithorax, overlying the mastectomy scar (Figure 1), and an indurated erythematous plaque on the posterior right hemithorax. Thoraco-abdominopelvic CT scan showed multiple subcutaneous nodules in the right posterolateral thoracoabdominal wall, the largest measuring 14 mm. Skin biopsy demonstrated a poorly differentiated dermal carcinomatous proliferation composed of atypical cells with high mitotic activity within a fibrous stroma. Immunohistochemistry was positive for AE1/AE3 and GATA3, supporting metastatic cutaneous involvement of mammary origin.
The patient was referred to oncology, and palliative chemotherapy was initiated.



Figure 1 : Erythematous sclerotic plaque with satellite papules.

Results

It was first described by Alfred Velpeau in 1938, who gave it this name due to its resemblance to the metallic breastplate of cuirassiers (3).

It is mainly observed in breast cancers, although it has also been described in other adenocarcinomas (2).

Extremely rare, it accounts for 3–4% of cutaneous metastases of breast origin. In a retrospective cohort study including 31 female patients with cutaneous metastases from breast cancer, only 3.2% presented with clinical manifestations of carcinoma en cuirasse (3).

It most often occurs during the evolution of an already known breast cancer, frequently after treatment, thus representing a sign of locoregional recurrence or metastatic progression, as observed in our patient. More rarely, it may reveal the disease and represent the initial presentation of an occult breast cancer (2).

Its pathophysiology is based on cutaneous tumor dissemination via lymphatic spread, direct extension, or hematogenous route, leading to dermal infiltration associated with a fibrotic stromal reaction (2). This explains its initial presentation as isolated nodules that coalesce to form diffuse sclerodermiform induration. The tumor surface may be pruritic, painful, ulcerated, or bleeding (3).

Histologically, it is characterized by an interstitial infiltration of tumor cells arranged in single-file patterns, with a typical “Indian file” appearance within a fibrous stroma (3).

Differential diagnoses include inflammatory breast cancer, radiation-induced morphea, chronic radiodermatitis, and even benign dermatoses (2).

It is generally associated with advanced disease, with a 10-year survival rate of 3.1% and a median survival of 13.8 months (2).

Management aims to maintain quality of life and is based on systemic treatment of metastatic breast cancer, tailored to the tumor subtype (2).

Conclusions

Carcinoma en cuirasse should be considered in any unusual thoracic cutaneous infiltration, particularly in patients with a history of breast cancer. Early recognition is essential to avoid diagnostic delay and to ensure prompt oncologic management (1).

EADV CONGRESS
VIENNA
30 SEP - 3 OCT 2026

Abstract N°: 3622

Clinicopathologic Predictors of Invasive Disease and Recurrence in Extramammary Paget Disease: A Retrospective Cohort Study in an Asian Population

Catherine Shin Huey Chen*[1], Cheng Yuan Li[2]

[1] Taipei Veterans General Hospital, Taipei, Taiwan

[2] Taipei Veterans General Hospital, Dermatology Department, Taipei, Taiwan

Introduction

Extramammary Paget disease (EMPD) is a rare cutaneous adenocarcinoma characterized by high local recurrence and variable risk of invasive transformation. Prognostic factors remain inconsistently defined, particularly in Asian populations. We aimed to identify clinicopathologic variables associated with invasive disease, recurrence, and overall survival (OS) in an Asian EMPD cohort.

Materials and Methods

This retrospective cohort study included patients with histologically confirmed EMPD treated at a tertiary center in Taipei, Taiwan between January 2010 and January 2022. Demographic, clinical, pathological, and treatment variables were reviewed. Invasive disease was defined as dermal invasion beyond the epidermal basement membrane. Recurrence-free survival (RFS) and OS were estimated using Kaplan–Meier analysis. Cox proportional hazards regression was performed to identify prognostic factors. Statistical significance was defined as $p<0.05$.

Results

Among the 25 patients recruited, 20 patients (80%) were male, with a mean age of 72 years. Invasive disease was identified in 8 patients (32%), all demonstrating deep dermal invasion >1 mm. During a median follow-up of 3.62 years (IQR 1.30–6.29), recurrence occurred in 4 patients (16%) and 10 (40%) died. The estimated 3-year and 5-year RFS rates were approximately 85% and 78.7% respectively. The 3-year and 5-year OS rates were approximately 70% and 57.9% respectively. On univariate Cox analysis, deep dermal invasion was significantly associated with reduced RFS (HR 10.65; 95% CI, 1.10–103.0; p=0.041). For OS, any dermal invasion (HR 5.51; 95% CI, 1.13–26.80; p=0.035), deep dermal invasion (HR 4.39; 95% CI, 1.09–17.68; p=0.037), and lymphovascular invasion (HR 4.10; 95% CI, 1.09–15.40; p=0.036) were significantly associated with increased mortality. In multivariable analysis adjusting for age ≥75 years, lesion size ≥5 cm, deep dermal invasion, lymphovascular invasion, and metastatic status, deep dermal invasion showed a trend toward worse OS (HR 6.61; 95% CI, 0.80–54.40; p=0.079).

Conclusions

Overall, deep dermal invasion emerged as the dominant determinant of recurrence and mortality. Patients with invasive disease demonstrated markedly worse survival outcomes, highlighting the central role of tumor biology over margin status or immunophenotypic profile in prognostic stratification. These findings emphasize the importance of early diagnosis, meticulous pathological assessment of invasion depth, and risk-adapted surveillance strategies. Improved identification of high-risk patients may inform individualized management approaches and optimize long-term outcomes in EMPD.

EA DV CONGRESS
VIENNA
30 SEP - 3 OCT 2026

Abstract N°: 3632

A rare case of aggressive cutaneous squamous cell carcinoma metastatic to the parotid gland in a renal transplant recipient

Michaela Novakova*[1]

[1] Dermatovenerology Department, Second Faculty of Medicine, Charles University, University Hospital Bulovka, Dermatovenerology Centre, Institute for Clinical and Experimental Medicine (IKEM), Prague, Czech Republic

Introduction
Cutaneous squamous cell carcinoma (cSCC) is the most common skin malignancy in renal transplant recipients (RTRs) and demonstrates a more aggressive clinical behavior, with a significantly higher risk of local recurrence, metastasis, and disease-specific mortality compared with the general population. The incidence of cSCC in RTRs increases progressively with time after transplantation as a consequence of long-term immunosuppression. Major risk factors include cumulative ultraviolet (UV) radiation exposure, chronic use of immunosuppressive agents—particularly azathioprine due to its photosensitizing properties—and infection with oncogenic human papillomaviruses (HPV). In addition, cSCC in transplant recipients often presents at a younger age, may occur multifocally, and tends to exhibit more rapid progression and poorer outcomes than in immunocompetent individuals.

Case Presentation
We present the case of a 76-year-old woman with a rapidly enlarging tumor in the right preauricular region. The patient had undergone kidney transplantation in 2014 and was receiving long-term immunosuppressive therapy. Histopathological examination of a biopsy specimen confirmed cutaneous squamous cell carcinoma (cSCC) with deep tissue infiltration. Imaging studies revealed no evidence of distant metastases; however, the tumor invaded the superficial lobe of the right parotid gland. Wide local excision of the lesion together with superficial parotidectomy was performed while preserving the facial nerve. The patient subsequently received adjuvant radiotherapy. At 14-month follow-up, no local recurrence or metastatic disease was detected. The patient subsequently died from causes unrelated to cSCC.

Conclusion
Metastatic cSCC involving the parotid gland is a rare but highly aggressive disease requiring a multidisciplinary treatment approach. Combined therapy consisting of surgical resection followed by adjuvant radiotherapy is associated with lower recurrence rates and improved overall survival compared with surgery alone. Poor prognostic factors include tumor size greater than 6 cm, deep tissue invasion, facial nerve involvement, extracapsular spread, and immunosuppression. Modification of the immunosuppressive regimen should also be considered in the management of high-risk renal transplant recipients.

As most cSCCs arise in the head and neck region, optimal management often requires close collaboration among dermatologists, dermatologic surgeons, otolaryngologists, transplant physicians, radiation oncologists, and medical oncologists. Regular dermatologic surveillance in renal transplant recipients is essential for early diagnosis and treatment, potentially reducing morbidity, metastatic spread, and disease-specific mortality. This case highlights the aggressive behavior of cSCC in immunosuppressed patients and underscores the importance of early recognition and multidisciplinary care.

EADV CONGRESS
VIENNA
30 SEP - 3 OCT 2026

Abstract N°: 3635

Blueberry muffin skin reveals congenital leukemia: report of two cases.

Maria-Emmanouela Anagnostaki*[1], Myrto-Maria Trakatelli[1], Aikaterini Patsatsi[1], Elisabeth Lazaridou[1], Stavroula Pervana[1], Sofia-Ariadni Theodorelou -Charitou[1], Zoe Apalla[1]

[1] Aristotle University of Thessaloniki, 2nd Dermatology Clinic, Thessaloniki, Greece

Introduction

"Blueberry muffin" appearance in neonates is characterized by the presence of violaceous cutaneous nodules and has been associated to a wide and diverse spectrum of underlying conditions, including serious hematologic disorders, such as congenital leukemia (CL), histicytosis, mastocytosis, neuroblastoma, Torch, angiomatosis etc.

Case Presentation

We present two neonates who were referred to our outpatient clinic for dermatologic evaluation of violaceous dermal nodules. The clinical appearance conformed with the so-called blueberry muffin baby. We performed exhaustive clinical, laboratory, and histopathological investigation in order to clarify the aetiology, since the list of differentials is wide.The first case involved a full-term neonate with a solitary bluish macule on the lower lip that appeared ten days after birth. Based on clinical examination, the suspicion of CL was raised. Hematologic evaluation revealed leukocytosis with circulating blasts, whilst histopathological examination and immunohistochemistry confirmed leukemic infiltration consistent with CL.

The second case presented at birth with widespread violaceous papules and nodules. Laboratory evaluation demonstrated marked leukocytosis with circulating blasts, and Ki-67 expression on immunohistochemistry exceeding 70%. Skin biopsy confirmed diffuse leukemic infiltration, establishing the diagnosis of CL.

Conclusion

Among others, blueberry muffin lesions may represent cutaneous manifestations of CL. Suspicion of leukemia should be raised even in cases with initially localized or subtle presentation. Both localized and generalized lesions warrant thorough investigation to ensure early diagnosis and prompt management of this life-threatening condition.

EADV CONGRESS
VIENNA
30 SEP - 3 OCT 2026

Abstract N°: 3638

Histone deacetylase inhibitors for cutaneous T-cell lymphoma: A systematic review and meta-analysis

Laura Ghanem*[1], Daniela Lucía Mendoza-Millán[2, 2], Najwaa Kirmani[3], Alfonso Gotor-Rivera[4], Bárbara Baptista Lopes[5], Sümeyye Aktaş[6], Martin Cevallos-Cueva[7], Ibrahim Awar[8], Virginia Velasco-Tamariz[4], Pablo Luis Ortiz-Romero[4]

[1] Faculty of Medical Sciences, Lebanese University, Beirut, Lebanon

[2] Department of Dermatology, Beth Israel Deaconess Medical Center, Boston, Massachusetts, United States

[3] Dow Medical College, Karachi, Pakistan

[4] Dermatology Department, Hospital Universitario 12 de Octubre, I+12 Research Institute, Universidad Complutense, Madrid, Spain

[5] Faculty of Medicine, Faculdade de Filosofia, Ciências e Letras de Penápolis, São Paulo, Brazil

[6] Department of Dermatology, Necmettin Erbakan University Faculty of Medicine, Konya, Türkiye

[7] School of Medicine, Universidad Central del Ecuador, Quito, Ecuador

[8] Medical University of Łódź, Łódź, Poland

Introduction

Mycosis Fungoides (MF) and Sézary Syndrome (SS) are the most frequent primary cutaneous T-cell lymphomas (CTCL), a rare group of non-Hodgkin lymphomas characterized by chronic skin involvement, impaired quality of life, and potential systemic progression. Histone deacetylase inhibitors (HDACi) have emerged as promising therapeutic agents for CTCL through modulation of gene expression, induction of apoptosis, and immunomodulatory effects. Several clinical studies have evaluated their efficacy and safety in patients with CTCL; however, outcomes remain variable across different agents and study designs. This systematic review and meta-analysis aimed to evaluate the efficacy and safety of HDACi in patients with CTCL.

Materials and Methods

PubMed, Embase, and Cochrane Library were searched for randomized controlled trials and prospective observational studies following PRISMA and Cochrane guidelines. A single-arm meta-analysis was conducted because the included studies lacked consistent comparator groups. Data were pooled using inverse-variance random-effects meta-analysis with restricted maximum likelihood (REML). The Hartung-Knapp-Sidik-Jonkman (HKSJ) correction was applied when $\tau^2 > 0$ and more than two studies were available. Sensitivity analyses were conducted to evaluate potential sources of heterogeneity. Subgroup analyses by disease stage and disease subtype (MF/SS), as well as by the HDACi molecule, were conducted when data were available. Statistical analyses were performed using RStudio.

Results

Thirteen studies involving 1,042 patients were included; most evaluated HDACi as treatment for CTCL, whereas one investigated resminostat as post-response maintenance therapy. Age ranged from 21 to 89 years, and 551 patients (52.87%) were male. In patients with CTCL receiving HDACi, the pooled overall response rate (ORR) was 22.29% (95% CI: 15.22–31.43), including a partial

response (PR) rate of 17.56% (95% CI: 11.15–26.56) and a complete response (CR) rate of 4.36% (95% CI: 2.20–8.47). Subgroup analyses by CTCL subtype and disease stage demonstrated no significant differences in ORR, PR, or CR between subgroups. For the HDACi molecule type, no significant subgroup differences were observed for CR; however, differences were significant for PR (p=0.003) and ORR (p=0.0006). Romidepsin showed the highest PR and ORR rates across molecules.

The pooled rates of progressive disease (PD) and stable disease (SD) were 25.35% (95% CI: 15.41–38.77) and 43.04% (95% CI: 29.19–58.07), respectively. Pruritus relief was observed in 60.79% of patients (95% CI: 27.63–86.30).

Regarding safety, the most common adverse events were nausea (50.28%), fatigue (46.71%), diarrhea (34.67%), thrombocytopenia (27.16%), anorexia (25.40%), vomiting (21.9%), alopecia (16.60%), constipation (15.64%), headache (15.37%), neutropenia (15.09%), weight loss (14.90%), anemia (14.37%), hypertension (12.79%), hypotension (10.69%), lymphopenia (10.41%), pyrexia (8.76%), leukopenia (7.24%), rash (6.52%), and QT prolongation (3.14%). Serious adverse events occurred in 21.18% of patients.

Treatment discontinuation due to adverse events occurred in 16.51% (95% CI: 11.20–23.66), while discontinuation due to PD occurred in 51.84% (95% CI: 35.98–67.33).

Laboratory disturbances included increased creatinine (20.04%), hyperbilirubinemia (14.19%), hypokalemia (10.95%), hyperglycemia (10.49%), aspartate aminotransferase (AST) elevation (9.71%), hyperuricemia (8.66%), alanine aminotransferase (ALT) elevation (7.12%), and hypoalbuminemia (5.13%).

Trial	Published study	Country / Setting	Design	HDAC inhibitor	Dose & schedule	N (analyzed)	CTCL subtype	Stage distribution	Median age, y (range)	Male	Prior systemic Tx, median (range)
NCT00091559	**Olsen 2007**	USA (multicenter, 7 sites)	Phase IIB, single-arm, open-label	Vorinostat	400 mg PO once daily	74	MF 44 (59.5%); SS 30 (40.5%)	IB 11 (15%); IIA 2 (3%); IIB 19 (26%); III 20 (27%); IVA 18 (24%); IVB 4 (5%)	60 (39–83)	38 (51.4%)	3 (1–12)
	Kuo 2008	USA (Yale, single center)	Phase IIB, single-arm, open-label	Vorinostat	400 mg PO once daily	3	MF 1 (33%); SS 1 (33%); NR 1 (33%)	IB 1 (33%); III 2 (66%)	62 (58–68)	3 (100%)	7 (7-10)
NR	**Duvic 2007**	USA (single center)	Phase II, single-arm	Vorinostat	Group 1: 400 mg PO QD; Group 2: 300 mg PO BID×3 d/wk; Group 3: 300 mg PO BID×14d induction → 200 mg BID maintenance	33	MF 22 (67%); SS 11 (33%)	IA 1 (3%); IB 3 (9%); IIA 1 (3%); IIB 5 (15%); III 5 (15%); IVA 10 (30%); IVB 8 (24%)	67 (26–82)	18 (55%)	5 (1-15)
NCT00106431 (GPI-04-0001)	**Whittaker 2010** **Kim 2012** **Foss 2016**	Multinational (33 sites, 8 countries)	Phase II, pivotal, single-arm, open-label	Romidepsin	14 mg/m² IV days 1, 8, 15 of 28-d cycle; up to 6 cycles	96	MF; SS	IB 15 (16%); IIA 13 (14%); IIB 21 (22%); III 23 (24%); IVA 24 (25%)	57 (21-89)	59 (61%)	2 (1–8)
NCT00007345 (NCI 1312)	**Piekarz 2009**	Multinational (12 sites, USA + Australia)	Phase II, single-arm, open-label	Romidepsin	Initial 18 mg/m² IV days 1 & 5 of 21-d cycle (n=3); amended to 14 mg/m² IV days 1, 8, 15 of 28-d cycle	71	MF; SS	IA 1 (1.4%); IB 6 (8.5%); IIA 2 (2.8%); IIB 15 (21.1%); IIIA 3 (4.2%); IIIB 3 (4.2%); IVA 28 (39.4%); IVB 13 (18.3%)	57 (28–84)	48 (67.6%)	4 (0–14)
	Bates 2015	Multinational (12 sites, USA + Australia)	Phase II, single-arm, open-label (long-term follow-up)	Romidepsin	14 mg/m² IV days 1, 8, 15 of 28-d cycle	131 (84 CTCL)	MF; SS	IA 1 (1.2%); IB 6 (7%); IIA 3 (3.6%); IIB 18 (21%); III 6 (7%); IVA 32 (38%); IVB 17 (20%)	59 (28–84)	57 (68%)	3 (0–14)
NCT00425555	**Duvic 2013**	Multinational (USA + Europe)	Phase II, multicenter, single-arm, open-label	Panobinostat	20 mg PO three times weekly	139	MF 105 (75.5%); SS 33 (23.7%); GSS 1 (0.7%)	IA–IIA 36 (25.9%); IIB–III 70 (50.4%); IV 33 (23.7%)	61	88 (63%)	4 (1–15)
NR	**Ellis 2008**	Multinational (Australia + USA + Germany; 2 CTCL centers)	Phase I, dose-escalation, multicenter, open-label	Panobinostat	20 mg PO Mon/Wed/Fri weekly on 28-d cycle	10	MF 7 (70%); SS 3 (30%)	IB 2 (20%); IIB 3 (30%); III 2 (20%); IVA 3 (30%)	59. 5 (35-79)	2 (20%)	1 (0-7)
NCT00274651	**Foss 2014**	Multinational (USA, France, Germany, Israel, Thailand)	Phase II, multicenter, single-arm, open-label	Belinostat	1000 mg/m² IV days 1–5 of 21-d cycle	53 total (29 CTCL)	MF 17 (58.6%); SS 7 (24.1%); ALCL 2 (6.9%); other 3 (10.3%)	IB 4 (13.8%); IIA 2 (6.9%); IIB 5 (17.2%); IIIA1 (3.4%); IVA 12 (41.4%); IVB 5 (17.2%)	68.1 (25.9–84.6)	14 (48.3%)	4 (1–9)
NCT00771472	**Wada 2012**	Japan (multicenter, 5 center)	Phase I, single-arm, open-label, non-randomized	Vorinostat	400 mg PO once daily, 28-d cycles	6	MF 6 (100%)	IIB 4 (66.7%); IVA1 2 (33.3%)	53.5 (34–75)	6 (100%)	2.5 (1–5)
NCT01486277	**Child 2016**	Multinational (12 European sites + 1 US)	Phase II, multicenter, single-arm, open-label (2 dose cohorts)	Quisinostat	8mg or 12 mg PO days 1, 3, 5 weekly, 21-d cycles	26 (25)	MF 25 (96%); SS 1 (4%)	IB/IIA 9 (35%); IIB/III/IVA 17 (65%)	61 (32–80)	21 (81%)	NR
NCT01728805 **(MAVORIC)**	**Kim 2018 (MAVORIC)** **Porcu 2021** **Johnson 2021**	Multinational (61 centers, 11 countries)	Phase III, open-label, randomized (1:1, vorinostat: mogamulizumab) trial	Vorinostat (control arm)	400 mg PO once daily, 28-d cycles	372 (186 vorinostat arm)	MF 99 (53%); SS 87 (47%)	IB-IIA 49 (26%); IIB 23 (12%); IIIA-IIIB 16 (9%); IVA1 82 (44%); IVA2 12 (6%); IVB 4 (2%)	65 (56–72)	107 (58%)	3 (2–5)
NCT02953301	**Stadler 2026 (RESMAIN)**	Multinational (55 sites, 12 countries)	Phase II, multicenter, double-blind, randomized, placebo-controlled trial	Resminostat	600 mg PO once daily ×5d then 9d off (14-d cycle)	201 randomized (100 resminostat arm)	MF 164 (82%); SS 37 (18%)	IIB 117 (58%); IIIA 12 (6%); IIIB 11 (5%); IVA1 26 (13%); IVA2 26 (13%); IVB 9 (4%)	64 (30-87)	123 (61%)	3 (1-21)
NCT00958074		USA (single center)	Phase II, open-label, non-randomized, single arm trial	Vorinostat	200 or 400 mg PO once daily, 28-d cycles for 6 cycles	11	NR	NR	NR	6 (54.5%)	NR
NCT01433731	**Kim 2014**	USA (multicenter, 6 sites)	Phase Ib, randomized, double-blind, placebo-controlled	Remetinostat	0.1% / 0.5% / 1% BID for 28-d cycle	18 (15)	NR	IA 5 (28%); IB 12 (67%); IIA 1 (5%)	NR	12 (67%)	NR

Table 1. Characteristics of included studies. Abbreviations: BID, twice daily; CTCL, cutaneous T-cell lymphoma; IV, intravenous; MF, mycosis fungoides; NCT, ClinicalTrials.gov identifier; NR, not reported; PO, by mouth; PTCL, peripheral T-cell lymphoma; QD, once daily; RCT, randomized controlled trial; SAHA, suberoylanilide hydroxamic acid; SS, Sézary syndrome.

Conclusions

HDACi show modest efficacy in CTCL with meaningful symptom relief, but are frequently associated with adverse events and laboratory abnormalities that may affect tolerability and lead to discontinuation. These findings emphasize the importance of close clinical and laboratory monitoring during therapy, alongside prompt symptomatic management and supportive care strategies, to optimize safety and maintain treatment continuity.

EADV CONGRESS
VIENNA
30 SEP - 3 OCT 2026

Abstract N°: 3646

Environmental, Sociodemographic, Healthcare, and Digital Behavioral Determinants of County-Level Melanoma Incidence in the United States

Samir Salah[1], Delphine Kerob[1, 2], Khaled Ezzedine*[3, 4]

[1] La Roche-Posay Dermatological Laboratories, Levallois-Perret, France

[2] Department of Dermatology, AP-HP Saint-Louis Hospital, PARIS, France

[3] Department of Dermatology, Henri Mondor University Hospital, Créteil, France

[4] 5EA 7379 EpidermE, Faculty of Medicine, Université Paris-Est Créteil, UPEC, Créteil, France

Introduction

Sun-safety advice is delivered as if UV carried the same melanoma risk everywhere, yet age-adjusted incidence varies markedly between U.S. counties. Beyond UV exposure and skin phototype, climate, dermatologic access, socioeconomic position, air quality, and population mental-health burden may all influence where melanoma develops and where it is diagnosed. We asked whether environmental, behavioural, and healthcare data could explain geographic differences in melanoma incidence, and whether the UV–melanoma association depends on local context?

Materials and Methods

Cross-sectional ecological analysis of 1,691 contiguous U.S. counties. Outcome: age-adjusted melanoma incidence 2017–2021 from the United States Cancer Statistics database. Exposures, measured weekly from Jan 2020 to Sep 2024 and averaged into county-level chronic-exposure means, included: (1) NASA environmental measurements via Google Earth Engine — UV index, NO2, PM2.5, humidity, and wind speed from MERRA-2, GEOS-CF, and OMI/Aura; (2) Google county-level search volumes for anxiety/depression terms from COVID-19 Open Data; (3) sociodemographics from US Census and USDA-ERS; and (4) dermatologic access from HRSA AHRF, including a composite weighted 0.7 toward dermatologist density, plus state health-system tiers from America's Health Rankings. Variables were screened with machine-learning-based selection to identify the most relevant predictors for the final model. A standardized multivariable regression then estimated independent effects, with exploratory one-at-a-time UV-interaction terms. Robustness was checked with a spatial error model.

Results

The machine-learning model explained 55% of variation in county-level melanoma incidence on a held-out, population-weighted test set (R^2 = 0.55; RMSE 5.75/100,000). The multivariable regression identified independent predictors of higher detected incidence of melanoma: proportion of White residents, UV index, high-tier state health-system performance, median household income, and population-level anxiety-related search activity. Counties in the low health-performance tier showed lower detected incidence, consistent with under-detection rather than lower true disease burden. The most clinically striking finding was effect modification: The UV–melanoma association was eightfold weaker in high-performance counties than in low-performance counties (0.48 vs. 3.84 additional cases per 100,000 per 1-SD increase in UV). One hypothesis is that stronger health systems may reduce the population-level impact of UV exposure through better prevention and photoprotection behaviours. Higher PM2.5 and more easterly longitude amplified UV-associated incidence. Substantive findings were robust to spatial autocorrelation; interactions are hypothesis-generating.

Conclusions

Across 1,691 U.S. counties, satellite environmental data, internet-search signals, and sociodemographic and

healthcare variables jointly explain over half of the geographic variation in melanoma incidence. The UV–melanoma relationship is not uniform; it depends on local healthcare capacity. In counties with weaker health systems, UV was more strongly associated with melanoma incidence. At the same time, these counties had lower detected incidence overall, which may reflect differences in detection, population characteristics, healthcare access, or other unmeasured factors. These are priority populations for targeted screening, mobile and teledermatology programmes, and tailored sun-protection messaging. The independent contribution of digital behavioural signals supports integrating internet-derived data into dermatologic surveillance to flag underserved communities earlier. Melanoma prevention should consider where patients live, not only their individual skin phenotype.

EADV CONGRESS
VIENNA
30 SEP - 3 OCT 2026

Abstract N°: 3674

Title: Interdigital Squamous Cell Carcinoma: The "Great Mimicker" of Chronic Intertrigo

ghita bouzoubaa*[1], Baghad Bouchra[1], Benhayoun Fatima Zohra[1], Rachadi Hanane[1], Chiheb Soumya[1]

[1] university hospital center ibn rochd, casablanca, Morocco

Introduction
Interdigital intertrigo is a common dermatological condition, usually attributed to infectious or inflammatory etiologies. However, atypical evolution or resistance to conventional therapy must raise suspicion of a neoplastic process. We report a rare and challenging case of squamous cell carcinoma (SCC) of the toe web space, initially misdiagnosed as chronic intertrigo.

Case Presentation
A 71-year-old male with no significant medical history presented with a painful, non-healing lesion in the fourth interdigital web space of the right foot, evolving over five months. The patient had undergone multiple unsuccessful treatments, including mid-potency topical corticosteroids and broad-spectrum antifungals, prescribed under the assumption of eczema or tinea pedis.

Physical examination revealed a 4x3 cm ulcerated, budding, and infiltrated mass. The lesion featured irregular, indurated borders and a necrotic, hemorrhagic base that bled easily upon manipulation. A 4 cm ipsilateral inguinal lymphadenopathy was palpated. Dermoscopic analysis was pivotal, revealing a chaotic landscape: thick yellowish keratotic masses, hemorrhagic crusts, and a polymorphous vascular pattern (glomerular and hairpin vessels) lacking any organized architectural network. Histopathological examination of a punch biopsy confirmed a well-differentiated, invasive squamous cell carcinoma. The patient subsequently underwent wide surgical excision with sentinel lymph node management.

Conclusion
This case highlights that the interdigital space can harbor aggressive malignancies concealed by chronic maceration and high microbial density. These anatomical factors act as a 'diagnostic veil,' potentially promoting carcinogenesis while obscuring the classic morphological features of Squamous Cell Carcinoma (SCC).

Our experience confirms that any interdigital lesion displaying 'red flags'—such as induration, contact bleeding, or failure to respond to therapy within 4 weeks—must be considered neoplastic until proven otherwise. In this setting, dermoscopy is an essential bridge, revealing chaotic vascular signatures hidden beneath macerated debris. Ultimately, a high index of clinical suspicion and early biopsy are mandatory to avoid detrimental delays, preserve foot function, and improve overall patient survival

EA DV CONGRESS
VIENNA
30 SEP - 3 OCT 2026

Abstract N°: 3677

Squamous Cell Carcinoma in Chronic Cutaneous Leishmaniasis: Diagnostic Pitfall or Malignant Evolution?

Samah Boualem*[1], Ouiame El Jouari[1], Sabrina Oujdi[1], Salim Gallouj[1]

[1] Dermatology Department, University Hospital Center Mohammed VI, Tangier, Morocco, Tangier, Morocco

Introduction

Cutaneous squamous cell carcinoma (SCC) is a common non-melanoma skin cancer that may exhibit aggressive behavior when diagnosis is delayed. Beyond ultraviolet exposure, chronic inflammatory processes and long-standing skin damage are recognized contributing factors to its development. Cutaneous leishmaniasis (CL), a parasitic disease endemic in many regions, generally follows a benign course. However, rare cases of SCC arising in CL lesions have been reported, particularly in persistent lesions associated with chronic inflammation, repeated trauma, or prolonged tissue damage. This uncommon association remains poorly understood and may represent a significant diagnostic challenge in endemic areas, where persistent lesions are often attributed solely to infection. We report a case of invasive SCC developing in a cutaneous leishmaniasis lesion, highlighting the importance of careful evaluation and close follow-up of non-healing lesions to ensure early detection of possible malignant transformation.

Case Presentation

A 39-year-old man with a history of asthma presented with a chronic lesion on the left leg evolving over approximately seven years. The lesion initially appeared as a painless subcutaneous nodule on the medial aspect of the leg and progressively enlarged over time, subsequently becoming painful and associated with purulent discharge. There was no history of trauma, insect bite, or systemic symptoms. The patient had attempted self-medication using traditional remedies without improvement.

Clinical examination revealed a painful 2.5-cm ulcerated nodular lesion covered by a hemorrhagic crust, without surrounding inflammation or regional lymphadenopathy. Dermoscopic examination showed hairpin vessels, central ulceration, yellowish and hemorrhagic crusts, and peripheral erythema.

A skin biopsy demonstrated active cutaneous leishmaniasis with numerous amastigotes. Intralesional meglumine antimoniate therapy was initiated for two months without clinical improvement. Due to persistence of the lesion and suspicion of squamous cell carcinoma, complete surgical excision was performed. Histopathological examination confirmed a poorly differentiated invasive squamous cell carcinoma, with no residual Leishmania bodies identified in the excised specimen. Surgical margins were free of tumor, with no evidence of perineural or lymphovascular invasion.

Computed tomography showed no locoregional or distant abnormalities. No recurrence was observed at 3-month and 6-month follow-up visits.

Conclusion

Although rare, the coexistence of cutaneous leishmaniasis and invasive squamous cell carcinoma highlights the potential risk of malignant transformation in chronic infectious dermatoses. This case emphasizes the importance of prolonged clinical vigilance and consideration of underlying malignancy in persistent or atypical lesions of cutaneous leishmaniasis, particularly in endemic regions. Early histopathological evaluation remains essential for timely diagnosis and appropriate management, thereby improving patient outcomes.

EA DV CONGRESS
VIENNA
30 SEP - 3 OCT 2026

Abstract N°: 3682

Non-melanoma skin cancer in a coastal Ecuadorian population: a retrospective observational study

Edison Defaz*[1], Luz Maria Dressendorfer[1], Paola Belén Guambo[1]

[1] Pontificia Universidad Católica del Ecuador, Quito, Ecuador

Introduction

Non-melanoma skin cancer (NMSC) is the most common skin cancer worldwide and includes two main subtypes: basal cell carcinoma (BCC) and squamous cell carcinoma (SCC), with BCC being the most prevalent subtype. Its incidence has progressively increased over recent decades, particularly in populations with chronic ultraviolet radiation exposure. The main risk factor associated with NMSC development is cumulative ultraviolet radiation exposure. Due to its geographic location within the equatorial torrid zone, Ecuador may display variations in the classic epidemiological patterns of NMSC; however, available information regarding this disease in coastal Ecuadorian populations remains limited. This study aimed to characterize the clinical and epidemiological profile of non-melanoma skin cancer in a coastal Ecuadorian population.

Materials and Methods

A retrospective observational study was conducted reviewing databases and medical records of patients with histopathological diagnoses of skin cancer treated at an oncology unit in the Ecuadorian coastal region between 2016 and 2021. Among 150 patients diagnosed with skin cancer, the melanoma cases were excluded, resulting in a final cohort of 80 NMSC patients, corresponding to basal cell carcinoma and squamous cell carcinoma. Clinical, histological, and sociodemographic variables were collected, including age, sex, tumor subtype, and anatomical location.

Results

From an epidemiological perspective, among the 80 patients with NMSC included in the study, 51 (64%) had basal cell carcinoma (BCC), and 29 (36%) had squamous cell carcinoma (SCC). A total of 68% of the cohort consisted of patients aged ≥65 years, making this the predominant age group. A slight male predominance was observed, representing 54% of cases. Regarding histopathological findings, all BCC were classified as nodular subtype in this group. In the SCC group, moderately differentiated and well-differentiated subtypes accounted for 55% and 45% of cases, respectively. Regarding topographic distribution, the head and neck region was the most frequent anatomical location, representing 76% of cases.

Conclusions

Non-melanoma skin cancer in the studied population showed an epidemiological profile characterized by the predominance of basal cell carcinoma, higher frequency in patients older than 65 years, and slight male predominance. From a histopathological perspective, all BCC cases were of the nodular subtype. The predominant anatomical location in the head and neck region suggests an association between NMSC development and cumulative damage from chronic ultraviolet radiation exposure in photoexposed areas. These findings provide clinical and epidemiological information on the behavior of NMSC in a coastal Ecuadorian population located

within the equatorial torrid zone.

EA DV CONGRESS
VIENNA
30 SEP - 3 OCT 2026

Abstract N°: 3683

Cutaneous Squamous Cell Carcinoma in Xeroderma Pigmentosum: Efficacy of a Combined Approach Using Systemic and Intralesional Bleomycin with Cryotherapy

Mohammad Azouagh*[1], Mariem Tabka[1], Feryel Amri[1], Hicham Mokhtari[1], Asmahane Souissi[1], Mohamed Zghal[1], Mourad Mokni[1]

[1] Dermatology department, La Rabta Hospital, Tunis, Tunisia

Introduction

Xeroderma pigmentosum (XP) is a rare genodermatosis characterised by defective DNA repair mechanisms, leading to early-onset and aggressive cutaneous carcinogenesis. The management of cutaneous squamous cell carcinoma (cSCC) in this context is particularly challenging, especially when surgical options are limited. Optimising non-surgical and combination therapeutic strategies, therefore, represents a major clinical priority. We report a case of large cSCC in a patient with XP type V that achieved complete response after treatment with intramuscular and intralesional bleomycin combined with cryotherapy, highlighting the potential value of this approach in complex high-risk settings.

Case Presentation

A 63-year-old woman with a 17-year history of XP type V, born to second-degree consanguineous parents, had previously developed two cSCCs treated with IL BLM and cryosurgery. She was inconsistently adherent to strict photoprotective measures and presented with a giant tumour of the right temporal region evolving over nine months with progressive enlargement. Clinical examination revealed a bulky, ulcerated, exophytic lesion measuring approximately 15 cm at its greatest diameter, friable and bleeding on minimal contact. Skin biopsy confirmed a well-differentiated invasive keratinising cSCC. Staging investigations showed no evidence of distant metastasis. Given the tumour size, orbital compression, and the underlying XP, a conservative combined treatment was initiated. Intramuscular (15 mg) and intralesional (15 mg) bleomycin were administered fortnightly, together with cryotherapy sessions over two months, for a total cumulative dose of 120 mg. After one month, tumour volume had decreased by approximately 50%. Complete clinical regression was achieved after two months, leaving a residual 6 cm ulcer. Post-treatment margin biopsies revealed no residual tumour, confirming histologically tumour-free margins.

Conclusion

Surgical excision remains the gold standard treatment for cSCC; however, it was not feasible in this patient due to tumour location and size, with potential compromise of visual and cosmetic outcomes. Radiotherapy was contraindicated owing to the underlying XP. In advanced or unresectable cases, PD-1 inhibitors are currently considered the standard systemic therapy. In the absence of access to immunotherapy, conventional cytotoxic chemotherapy was considered despite the absence of a specific approved indication in this context.BLM was selected because of its favourable tolerability profile compared with cisplatin and its more rapid onset of action compared with 5-fluorouracil. IL administration allows higher local drug concentrations while limiting systemic exposure. This approach is particularly relevant in cutaneous malignancies, as the skin is relatively deficient in bleomycin hydrolase, the enzyme responsible for BLM inactivation, thereby allowing prolonged local drug activity. Cryotherapy may further potentiate BLM activity by facilitating intracellular drug penetration, which is otherwise

limited by the drug’s hydrophilic properties. Freeze–thaw cycles induce ice crystal formation and osmotic stress, resulting in transient disruption of cellular membranes and increased drug diffusion. Although distinct from electroporation, the underlying principle is similar: enhancement of membrane permeability to increase cytotoxic efficacy. In addition, local vasoconstriction and ischaemia may prolong tumour cell exposure to BLM.

The combination of intralesional and systemic bleomycin with cryotherapy represents an innovative organ-preserving therapeutic strategy, offering a potential alternative for large cutaneous tumours or lesions located in anatomically critical areas while preserving function and cosmesis. This protocol may represent a promising therapeutic option for high-risk cSCC, particularly in situations where standard curative treatments are not feasible.

EADV CONGRESS
VIENNA
30 SEP - 3 OCT 2026

Abstract N°: 3693

Leukemia Cutis in a Patient With Chronic Lymphocytic Leukemia

Ege Uğur*[1], Muazzez Çiğdem Oba[1], Guldana Zulfaliyeva[2], Ahmet Emre Eşkazan[2]

[1] Cerrahpaşa Faculty of Medicine, Department of Dermatology and Venereology, Istanbul, Türkiye
[2] Cerrahpaşa Faculty of Medicine, Department of Internal Medicine, Division of Hematology, Istanbul, Türkiye

Introduction

Chronic lymphocytic leukemia is a mature B-cell neoplasm characterized by the progressive accumulation of monoclonal B lymphocytes. It is the most common leukemia in adults in Western countries. Chronic lymphocytic leukemia typically involves the lymph nodes, spleen, and bone marrow. Leukemia cutis associated with chronic lymphocytic leukemia is a rare complication. The reported incidence of leukemia cutis in patients with chronic lymphocytic leukemia ranges from 4% to 27%. Cutaneous lesions most commonly involve the trunk, extremities, and face, and may present as macules, papules, nodules, ulcers, or vesicles. In this study, we aimed to describe the clinical and dermoscopic features of leukemia cutis developing in a patient with chronic lymphocytic leukemia and to demonstrate the treatment response.

Case Presentation

A 78-year-old male patient was referred for dermatologic evaluation because of a widespread eruption involving the upper and lower extremities, abdomen, back, and nuchal region, with more prominent involvement of the lower extremities (Figure 1). The patient had a 30-year history of chronic lymphocytic leukemia and had not received any prior treatment. Dermatological examination revealed pruritic, erythematous, monomorphic papular and nodular lesions that had persisted for several months and were resistant to topical corticosteroids, topical calcineurin inhibitors, and topical/oral antihistamines.

Dermoscopic examination demonstrated fine linear vessels on an orange-yellow background (Figure 2). Histopathological examination revealed dense atypical lymphocytic infiltration in nodular and band-like patterns involving the perivascular and periadnexal areas, extending from the reticular dermis into the subcutaneous adipose tissue. Immunohistochemical analysis showed positivity for CD20, CD5, CD23, PAX5, and Bcl-2, while cyclin D1 was negative. These findings were reported as compatible with chronic lymphocytic leukemia/small lymphocytic lymphoma involvement.

Laboratory investigations revealed marked leukocytosis (93,000/mm^3), lymphocytosis (84,880/mm^3), and anemia (hemoglobin: 12.2 g/dL).

Based on the clinical, dermoscopic, histopathological, and laboratory findings, the patient was diagnosed with leukemia cutis associated with chronic lymphocytic leukemia. Treatment with obinutuzumab 1000 mg (day 1) combined with chlorambucil 0.5 mg/kg (days 1 and 14, every 28 days) was initiated. During the first cycle, obinutuzumab was administered on days 1, 8, and 15. Following the day 8 infusion, marked improvement of both the cutaneous lesions and pruritus was observed (Figure 3).

Conclusion

Leukemia cutis is a rare manifestation in patients with chronic lymphocytic leukemia and requires early recognition and histopathological confirmation with biopsy. It should be noted that cutaneous involvement is not necessarily

associated with poor prognosis unless accompanied by Richter transformation. The rapid clinical response observed in our patient following obinutuzumab and chlorambucil therapy further highlights the effectiveness of available treatment options.

EADV CONGRESS
VIENNA
30 SEP - 3 OCT 2026

Abstract N°: 3698

Multidisciplinary management of a complex case of basosquamous carcinoma

Nicolò Mori*[1], Irina Balan[1], Valentina Dini[1], Marco Romanelli[1], Agata Janowska[1]

[1] Unit of Dermatology, Department of Clinical and Experimental Medicine, University of Pisa, Pisa, Italy

Introduction

Basosquamous carcinoma (BSC), also called metatypical basal cell carcinoma, is a rare form of non-melanoma skin cancer. It combines histopathological features of both basal cell carcinoma (BCC) and squamous cell carcinoma (SCC), yet its precise classification and pathogenesis remain debated. Although uncommon, with an incidence estimated at approximately 1–3% of cutaneous carcinomas, BSC is clinically relevant because of its aggressive biological behaviour, showing higher recurrence and metastatic rates compared not only with BCC but also with SCC.

Case Presentation

We present the case of a 64-year-old woman with a prior diagnosis of BCC in the inguinal region, confirmed by an incisional biopsy. Due to inoperability, she subsequently received radiotherapy. A follow-up biopsy revealed no evidence of recurrence. The patient attended our clinic for treatment of a radiodermatitis-related ulcer in the same region as the previously located BCC. Topical therapy with advanced local dressings was initiated; however, during the three-month follow-up period, the wound increased in depth and size.

Given the patient's history, targeted biopsies of the ulcer were performed, and histopathological examination showed BSC. The personal history revealed a flame-related thermal burn at the tumor site approximately 25 years ago.

Due to the paucity of large-scale series and prospective studies on standardized management protocols, it was decided to initiate a cytoreductive therapy with Sonidegib, an inhibitor of the Hedgehog signalling pathway. During subsequent examinations, the lesion has notably decreased in size, and radiological tests, such as Computer Tomography, revealed no evidence of lymph nodes or systemic metastasis. Line-Field Confocal Optical Coherence Tomography (LC-OCT) was used for monitoring, demonstrating persistence of BSC in the central part of the lesion and remission at the edges.

Once the lesion had stabilised, surgical excision and reconstruction were undertaken, still showing a deep positive margin. The post-operative course proceeded without complications and we decided to continue the systemic treatment. The patient is currently under follow-up with no adverse reactions observed, and no local or systemic recurrence after 2 years of therapy with Sonidegib.

Conclusion

This article aims to contribute to existing knowledge on the medical-surgical treatment of these rare carcinomas. Given its rarity and clinical unpredictability, each case of BSC provides valuable insights to improve understanding and therapeutic strategies for this challenging neoplasm.

EADV CONGRESS
VIENNA
30 SEP - 3 OCT 2026

Abstract N°: 3703

Invasive Scalp Melanoma in Neurofibromatosis Type 1: A Case Report

Abir Abdelkarim*[1, 1], bouchra baghad[1], soumia chiheb[1]

[1] chu ibn rochd, casablanca, Morocco

Introduction

Neurofibromatosis type 1 is an autosomal dominant genodermatosis caused by mutations in the *NF1* tumor suppressor gene. It predisposes patients to the development of multiple benign and malignant tumors. Although cutaneous melanoma remains uncommon in this population, its incidence appears significantly increased, with a reported relative risk greater than 5 in some studies. Diagnosis may be delayed because of the presence of numerous pigmented lesions and neurofibromas, which can mask suspicious lesions. We report a case of invasive scalp melanoma occurring in a patient with NF1, highlighting the diagnostic and therapeutic challenges associated with this condition.

Case Presentation

A 30-year-old woman with familial Neurofibromatosis type 1 presented with a recently appearing black nodular lesion on the scalp that had shown progressive growth.

An initial excision was performed outside our institution, and histopathological examination revealed malignant Melanoma. The patient was subsequently referred to our department for management of residual disease.

Staging investigations including PET-CT, brain MRI, and cervical ultrasound showed no evidence of metastatic disease. A wide local re-excision was then performed.

Histopathological examination confirmed residual melanoma with a Breslow thickness of 3 mm and no ulceration. The tumor was classified as pT3a N0 M0, corresponding to stage IIA according to the AJCC 8th edition classification.

The patient was lost to follow-up and returned six months later with a nodular lesion arising on the surgical scar. PET-CT findings were consistent with local recurrence associated with lymph node, pulmonary, hepatic, and right renal fossa metastases. The patient was subsequently referred to the oncology department for immunotherapy management.

Conclusion

This case underscores the importance of careful dermatologic surveillance in patients withNeurofibromatosis type 1. Any new or changing cutaneous lesion should prompt specialist evaluation and biopsy when clinically suspicious. Once melanoma is diagnosed, comprehensive staging and multidisciplinary management integrating modern adjuvant therapies are crucial to optimize patient outcomes.

EA DV CONGRESS
VIENNA
30 SEP - 3 OCT 2026

Abstract N°: 3713

EZH2 Upregulation Reflects Proliferation and Disease Stage in Mycosis Fungoides: A Potential Therapeutic Target

Aslı Aksu[1], Deniz Tuncel[2], Semih Arslan[1], Ayberk Aktaran*[1], pınar özdemir çetinkaya[1], Birgül Özkesici[1], Hazel Kaya[1], Ilknur Altunay[1]

[1] University of Health Sciences, Department of Dermatology and Venereology, Cemil Tascioglu City Hospital, Istanbul, Türkiye
[2] University of Health Sciences, Department of Dermatology and Venereology, Seyrantepe Hamidiye Etfal Training and Research Hospital, Istanbul, Türkiye

Introduction

Mycosis fungoides (MF) is the most common subtype of primary cutaneous T-cell lymphoma (CTCL) and is characterized by a malignant proliferation of skin-homing $CD4^+$ T lymphocytes. The clinical course is often protracted and unpredictable, with a subset of patients progressing to advanced stages associated with significantly increased morbidity and mortality. The molecular pathogenesis of MF involves a complex interplay of genetic, epigenetic, and immune regulatory mechanisms that contribute to malignant T-cell transformation, tumor persistence, and disease progression.

Enhancer of Zeste Homolog 2 (EZH2), the catalytic subunit of the Polycomb Repressive Complex 2 (PRC2), mediates histone H3 lysine 27 trimethylation (H3K27me3) and promotes oncogenesis through epigenetic transcriptional repression[1]. Although EZH2 mutations are well characterized in B-cell lymphomas, their role in cutaneous T-cell lymphomas (CTCL), particularly mycosis fungoides (MF), remains incompletely defined. Defining the relationship between EZH2 expression, disease stage, and cellular proliferation may help to clarify its potential role as both a prognostic biomarker and a therapeutic target. The aim of the present study was to evaluate EZH2 expression in MF by immunohistochemistry and to analyze its correlation with clinicopathological parameters, disease
stage, and proliferative activity.

Materials and Methods

A total of 46 patients diagnosed with MF and followed in the Department of Dermatologic Oncology cases between January 2019 and August 2025 were included in this retrospective study. Immunohistochemical staining for EZH2 and Ki-67 was performed on an automated staining platform. Nuclear EZH2 expression was semi-quantitatively scored, and Ki-67 proliferation indices were calculated. Associations with disease stage, lesion morphology, and laboratory variables were analyzed using non-parametric tests.

Figure 1. Clinicopathologic and laboratory characteristics of patients according to lesion morphology

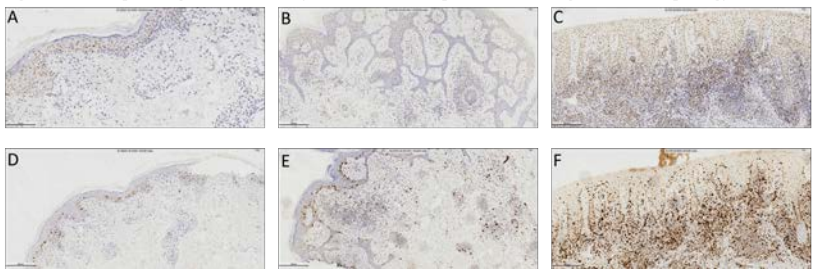

Immunohistochemical evaluation of EZH2 (A-C) and Ki-67 (D-F) in Mycosis Fungoides demonstrates increasing staining intensity from patch (A,D) to plaque (B,E) and tumor (C,F) stages. A significant

positive correlation exists between EZH2 overexpression and proliferative activity (10x)

Results

EZH2 expression showed a positive correlation with disease stage (r = 0.342; p = .02), and Ki-67 proliferation index (r = 0.575; p < .001). EZH2 expression differed significantly across lesion morphology groups (patch, plaque, tumor) (p < .001). No significant correlations were identified between EZH2 expression and serum LDH levels, β_2 microglobulin levels, age, or disease duration. No significant associations were observed between EZH2 expression and sex.

Table 1. Clinicopathologic and laboratory characteristics of patients according to lesion morphology

	Patch (n=41, 89.1%)	Plaque (n=3, 6.5%)	Tumor (n=2, 4.3%)	*p value*
Age, years, median (min–max)	49 (19–80)	57 (22–65)	68 (61–75)	.178
β2-microglobulin, mg/L, median (min–max)	1.81 (0.87–3.27)	1.54 (1.40–2.27)	2.57 (2.40–2.74)	.130
LDH, U/L, median (min–max)	192 (114–313)	208 (166–226)	184 (144–224)	.898
Disease duration, months, median (min–max)	24 (1–312)	12 (12–18)	85 (2–168)	.524
Ki-67, %, median (min–max)	1 (1–10)	10 (5–21)	32.5 (30–35)	.001
*EZH2 expression score, median (min-max)	1 (1-1)	2 (2-2)	3 (3-3)	<.001

EZH2 scoring: mild (1), moderate (2), strong (3). Data: median (min-max). Comparisons: Kruskal–Wallis test. LDH: Lactate dehydrogenase; EZH2: Enhancer of zeste homolog 2

Conclusions

In conclusion, our findings demonstrate that EZH2 expression increases in parallel with disease progression and correlates strongly with proliferative activity in MF. These results support the potential clinical utility of EZH2 as both a prognostic biomarker of disease aggressiveness and a rational therapeutic target in advanced MF. Further translational and clinical studies are warranted to determine whether EZH2-directed therapies may ultimately improve outcomes in selected patients with advanced MF.

EA DV CONGRESS
VIENNA
30 SEP - 3 OCT 2026

Abstract N°: 3722

IL4R-α expression and its clinicopathological correlation in human specimens of nevus and melanoma: a new target for immunotherapy?

Sarah Coradini[1], Demetrio Sposato*[1], Francesco Bellomi[2], Claudia Caturano[2], Christian Brunetti[3], Giuseppe Perrone[3], Rosa Coppola[4], Vincenzo Roberti[4], Giorgio Vivacqua[2], Vincenzo Panasiti[1, 4]

[1] Department of Medicine and Surgery, Università Campus Bio-Medico di Roma, Via Alvaro del Portillo, 21 - 00128 Roma, Italia;, Rome, Italy
[2] Laboratory of Microscopic and Ultrastructural Anatomy, Integrated Research Center PRABB, Campus Bio-Medico University of Rome, 00128 Rome, Italy, Rome, Italy
[3] Department of Pathology, Campus Bio-Medico University of Rome, Via Alvaro del Portillo, 200, Rome, Italy, Rome, Italy
[4] Unit of Dermatology, Fondazione Policlinico Universitario Campus Bio-Medico, Via Alvaro del Portillo, 200 - 00128 Roma, Italia;, Rome, Italy

Introduction
Melanoma is a malignancy characterized by a highly immunogenic tumor microenvironment, where cytokine signaling plays a crucial role in neoplastic progression and immune modulation. Interleukin-4 receptor α (IL4R-α) has been recently reported to be overexpressed in several tumor and implicated in tumor-associated immune regulation. However, its role in melanoma remains poorly defined.
This study aimed to evaluate IL4R-α expression in primary melanoma and compound melanocytic nevi, and to investigate its association with clinicopathological features in patients affected by melanoma.

Materials and Methods
IL4R-α expression was assessed by immunofluorescence in human formalin-fixed paraffin-embedded (FFPE) specimens of melanoma (22 cases) and compound melanocytic nevi (7 cases). Expression levels were analyzed in both tumoral and stromal compartments, with the use of specific markers (Melan-A and CD45 respectively) and correlated with clinicopathological parameters.

Results
IL4R-α expression was significantly increased in melanoma compared to nevus, both within tumoral MelanA+ cells (p=0.0277) and in the adjacent stromal CD45+ immune cells (p=0.0110). Tumoral IL4R-α expression in MelanA+ melanoma cells was positively and significantly associated with T staging (p=0.0145), Breslow's thickness (p=0.036) and ulceration (p=0.0058).

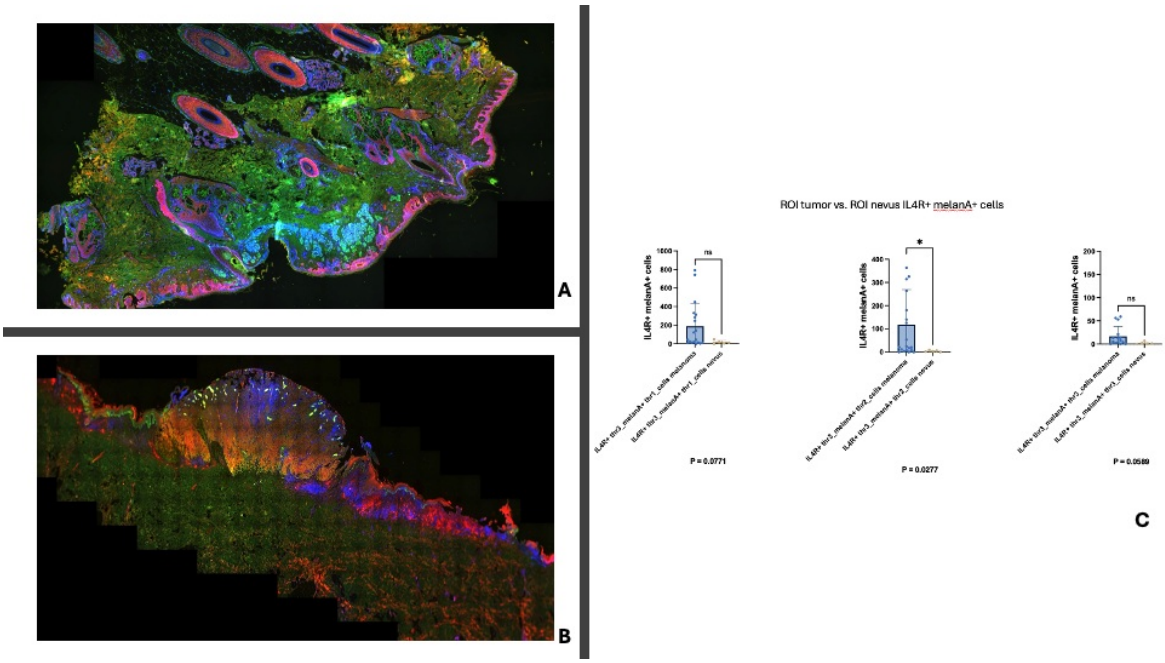

A) Immunofluorescence staining of a nevus; blue for DAPI, green for IL4R-α and red for Melan-A. B) Immunofluorescence staining of an ulcerated melanoma (T3); blue for DAPI, green for IL4R-α and red for Melan-A. Co-localization between IL4R-α and Melan-A visualized in orange. C) Graphs showing the differential expression of IL4R-α in Melan-A positive cells of Melanoma vs nevus

Conclusions

Taken together, these results suggest that IL4R-α might be involved in the progression of melanoma and identify IL4R-α as a candidate prognostic biomarker and therapeutic target. Given the availability of IL4R-α-blocking antibodies already in clinical use for inflammatory disorders, repurposing such agents represents a rational strategy to enhance melanoma immunotherapy efficacy.

EADV CONGRESS
VIENNA
30 SEP - 3 OCT 2026

Abstract N°: 3723

The Lymphoma Beneath the Itch: Tumoral Folliculotropic Mycosis Fungoides Hidden Behind Chronic Prurigo

ikram lahmouch*[1]

[1] Department of Dermatology, Ibn Sina University Hospital, Rabat, Morocco, rabat, Morocco

Introduction

Folliculotropic mycosis fungoides (FMF) is an aggressive variant of cutaneous T-cell lymphoma with heterogeneous and often misleading clinical presentations, frequently resulting in delayed diagnosis. Its ability to mimic chronic pruritic dermatoses represents a major diagnostic pitfall, particularly in patients presenting with long-standing, treatment-refractory pruritic eruptions lacking classic early mycosis fungoides lesions.

We report a case of tumoral FMF with follicular mucinosis initially misdiagnosed for years as refractory scabies and chronic prurigo, highlighting the importance of early clinicopathological reassessment in persistent treatment-resistant pruritic dermatoses.

Case Presentation

A 60-year-old man with severe heart failure secondary to aortic valvular disease (left ventricular ejection fraction: 22%), hypertension, prediabetes, and former chronic smoking was referred for a four-year history of progressively worsening generalized pruritic eruption.

The disease began in 2020 with intense nocturnal pruritus of the lower limbs, rapidly becoming generalized and followed by prurigo-like papular lesions. The patient was repeatedly treated for scabies and subsequently managed as chronic prurigo, without clinical improvement.

Examination revealed extensive infiltrated erythematous-violaceous plaques and tumoral nodules involving the face and scalp, including a 4-cm ulcerated temporal tumor, with widespread excoriated papules and erosions affecting the trunk and limbs (BSA ~45%), associated with xerosis, hypopigmented scars, and nail dystrophy. Body surface area involvement was estimated at 45%. Massive ascites was also noted, without lymphadenopathy.

Dermoscopy of infiltrated facial lesions demonstrated milky-red structureless areas, white streaks, ulcerations, and fine scaling. Histopathological examination revealed tumoral-stage folliculotropic mycosis fungoides with follicular mucinosis. Immunohistochemistry showed positivity for CD2, CD3, and CD5, loss of CD7 expression, and negativity for CD4, CD8, and CD20.

Extension work-up disclosed normochromic normocytic anemia without circulating Sézary cells, elevated tumor burden markers, hepatic dysfunction, renal insufficiency, and markedly increased CA-125 levels. Thoraco-abdomino-pelvic computed tomography demonstrated cardiomegaly with right pleural effusion, dysmorphic liver, and massive ascites with mesenteric infiltration. Ascitic fluid analysis yielded an exudative fluid suggestive of infectious or neoplastic origin.

Before further diagnostic investigations and therapeutic management could be initiated, the patient died from combined septic and cardiogenic shock.

Conclusion

This case underscores the deceptive nature and potentially devastating consequences of folliculotropic mycosis fungoides, which may remain concealed for years behind the misleading façade of chronic prurigo and intractable itch. What appeared to be a benign pruritic dermatosis ultimately revealed an advanced tumoral cutaneous lymphoma with a rapidly fatal outcome before treatment could even be initiated.

Beyond its rarity, this observation delivers a critical clinical message: persistent unexplained pruritus should never be trivialized, particularly when associated with atypical, infiltrated, or treatment-refractory lesions. In such settings, early biopsy and repeated clinicopathological correlation are essential to avoid missing an underlying cutaneous lymphoma.

In folliculotropic mycosis fungoides, the itch may be the first warning sign of an underlying lethal disease.

EA DV CONGRESS
VIENNA
30 SEP - 3 OCT 2026

Abstract N°: 3730

Morphological Severity and Disease Burden as Primary Drivers of Impaired Health-Related Quality of Life in Mycosis Fungoides and Sézary Syndrome: Updates from PROCLIPI

Gregg Murray*[1], Kevin Molloy[1], Julia Scarisbrick[2]

[1] Tallaght Hospital, Dublin, Ireland

[2] University Hospital Birmingham NHS Trust, Birmingham, United Kingdom

Introduction

Background: Cutaneous T-cell lymphoma (CTCL) subtypes such as mycosis fungoides (MF), including classical and folliculotropic variants, and Sézary syndrome impose a substantial burden on health-related quality of life, yet the specific clinical and morphological drivers of patient-reported impairment remain incompletely characterised in large prospective cohorts.

Objective: To identify the independent clinical, morphological, and demographic determinants of HRQoL impairment in a large international prospective cohort of patients with MF and SS.

Materials and Methods

Methods: Baseline HRQoL data from 769 patients with MF/SS enrolled in the PROCLIPI registry between 2015 and 2024 were analysed. HRQoL was assessed using the validated Skindex-29 instrument across global, symptom, emotional, and functioning domains. Associations with clinical and morphological variables were examined using univariate non-parametric testing and multivariable linear regression.

Results

Results: Female sex and age younger than 40 years were independently associated with worse HRQoL, particularly in the emotional domain. A stepwise morphological gradient was observed, with tumour-stage disease and erythroderma associated with the greatest impairment across all domains compared with patch disease ($p < 0.001$). Increasing mSWAT and BSA correlated with progressively worse HRQoL across all domains ($p < 0.001$). In multivariable analysis, morphological severity emerged as the dominant independent predictor of impaired HRQoL, with tumour-stage disease ($\beta = +1.09$), erythroderma ($\beta = +1.10$), alopecia ($\beta = +0.43$), and confluent erythema ($\beta = +0.53$) each independently associated with greater burden (all $p < 0.001$). After adjustment for disease severity and morphology, diagnostic subtype did not independently predict HRQoL, indicating that objective disease burden rather than CTCL subtype drives patient impairment.

Conclusions

Conclusion: In this analysis of HRQoL determinants in MF/SS, morphological severity and cutaneous disease burden emerged as the primary drivers of patient-reported impairment, superseding diagnostic classification after multivariable adjustment. These findings argue for morphology-focused disease management, systematic HRQoL assessment, and targeted supportive

care strategies in patients with tumour-stage disease, erythroderma, and visible clinical features including alopecia.

EA DV CONGRESS
VIENNA
30 SEP - 3 OCT 2026

Abstract N°: 3744

When Cutaneous Lymphoma Involves the Lip: A Rare and Misleading Presentation of Mycosis Fungoides

BTISSAM JALLOUL*[1], HANANE RACHADI[1], FATIMA ZAHRA BENHAYOUN[1], BOUCHRA BAGHAD[1], SOUMIYA CHIHEB[1]

[1] Department of Dermatology, CHU Ibn Rochd, casablanca, Morocco

Introduction

Mycosis fungoides is the most common cutaneous T-cell lymphoma, characterized by a slow and polymorphic course, predominantly involving skin lesions such as patches, plaques, and tumors. Unusual localizations, particularly mucosal involvement, are rare and may pose a significant diagnostic challenge. Lip involvement, especially presenting as macrocheilitis, is an exceptional and misleading presentation that can delay appropriate management.

Case Presentation

This case involves a 76-year-old female patient, followed since April 2025 for an epidermotropic large-cell cutaneous T-cell lymphoma suggestive of transformed mycosis fungoides (MF) (Stage IIIA: T4 NX M0 B0). Her therapeutic protocol included polychemotherapy (Cyclophosphamide, Vincristine, and Prednisone), notable for episodes of macrocheilitis following each cycle, which were initially responsive to corticosteroid therapy. The current history began three months prior to admission with a sudden worsening of the macrocheilitis, which became hyperalgic, ulcerated, and refractory to conventional treatments, associated with a decline in her general health status.

Dermatological examination revealed severe inflammatory macrocheilitis primarily involving the lower lip, characterized by tumor-like budding with a lateralized "venous lake" appearance, overlaid by meliceric (honey-colored) crusts and focal erosions. Additional findings included severe limitation of mouth opening, bilateral cervical lymphadenopathy, and scattered infiltrated scar-like skin lesions. The diagnostic workup, including a labial biopsy with immunohistochemical study, confirmed direct lymphomatous infiltration (CD3+, CD4+, Ki67 25%), supporting a diagnosis of tumor-stage MF. CT staging demonstrated fulminant systemic progression with pulmonary parenchymal involvement, multifocal lymphadenopathy, and pleural and pericardial effusions. The clinical course was unfortunately marked by the death of the patient.



Conclusion

Mucosal involvement in mycosis fungoides (MF) is exceptional (<1%) and typically signals advanced stages. This case highlights how lip involvement can mimic inflammatory cheilitis, leading to dangerous diagnostic delays. The presence of tumoral budding and therapeutic resistance were crucial warning signs of large-cell transformation.

As observed in our patient, lip involvement is a marker of poor prognosis and rapid systemic dissemination (pulmonary and nodal). Clinicians should maintain high vigilance: any atypical or treatment-resistant macrocheilitis in a patient with cutaneous lymphoma requires urgent biopsy to avoid therapeutic delay and address systemic progression.

EADV CONGRESS
VIENNA
30 SEP - 3 OCT 2026

Abstract N°: 3756

Pyoderma Gangrenosum–Like Ulcer Revealing Cutaneous Metastasis of Urothelial Carcinoma

Lemya Mezdour*[1], Farid Ait Belkacem[1], Mohamed Rachid Bahriz[2], Samira Zobiri[1]

[1] Mustapha University Hospital Center, University of health sciences, Moudjahid Dr.Youcef El Khatib , Faculty of medecine, Algiers, Algeria
[2] Laboratory of Pathological Anatomy and Nephropathology, Dr. Bahriz, Algiers, Algeria

Introduction

Cutaneous metastases from urothelial carcinoma are rare and usually indicate advanced systemic dissemination associated with poor prognosis. Their clinical presentation is highly variable. To date, no cases mimicking pyoderma gangrenosum have been reported. We report a case of cutaneous metastasis presenting as a pyoderma gangrenosum–like ulcer revealing a loco-regional recurrence of high-grade urothelial carcinoma.



Ulceration on the anteromedial aspect of the right thigh, presenting with raised violaceous borders and a fibrinous base, clinically mimicking pyoderma gangrenosum.

Case Presentation

A 63-year-old woman with a history of high-grade infiltrating urothelial carcinoma treated one year earlier by

anterior pelvectomy presented with a painful ulcerative lesion evolving for one month on the right thigh. Clinical examination showed a painful ulcer with raised violaceous borders and a fibrinous base with progressive centrifugal extension, strongly suggesting pyoderma gangrenosum. Skin biopsy revealed dermal infiltration by an undifferentiated malignant epithelial proliferation consistent with metastatic carcinoma. Immunohistochemistry showed positivity for CK20 and p63, supporting a urothelial origin. Staging investigations including pelvic MRI demonstrated tumor recurrence in the posterior wall of the vesical bed with infiltration of the obturator internus muscle, without other metastatic sites. The patient was referred to oncology for appropriate management.

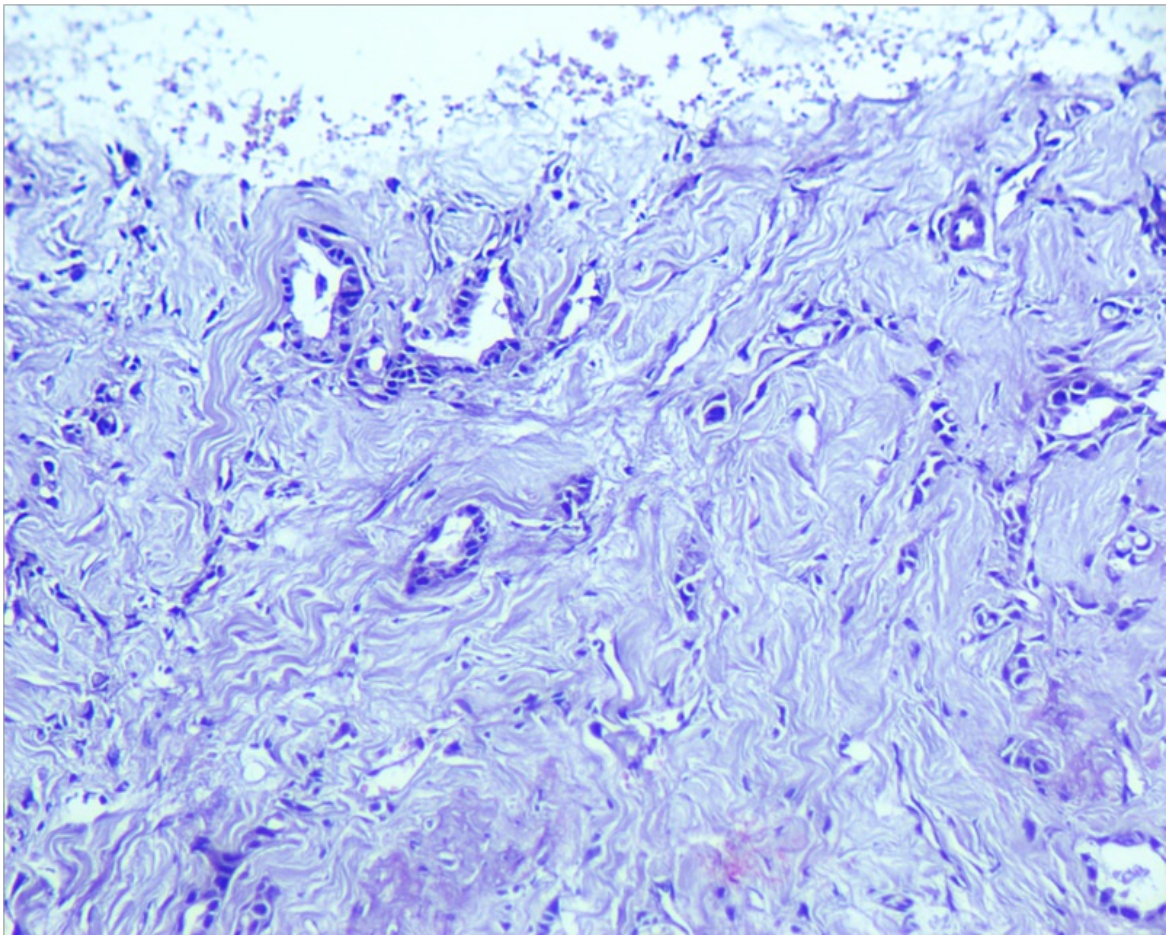

Dermal infiltration by an undifferentiated malignant epithelial neoplasm.

Conclusion

Cutaneous metastases of urothelial carcinoma are uncommon, with a reported incidence ranging from 0.84% to 3.6%. They typically occur within the first year after treatment of the primary tumor. The abdominal wall, chest, and surgical scars represent the most frequently involved sites. Their clinical presentation is heterogeneous and includes nodules, infiltrated plaques, or ulcerative lesions that may mimic inflammatory or infectious dermatoses. To our knowledge, a presentation mimicking pyoderma gangrenosum has not been previously reported. This atypical aspect may lead to diagnostic delay if histological confirmation is not promptly performed. Histopathological examination combined with immunohistochemistry (CK7, CK20, p63, GATA3) is essential to establish the urothelial origin.

Any atypical, painful, and progressive skin lesion in a patient with a history of malignancy should raise suspicion of cutaneous metastasis. Skin biopsy enables early diagnosis and appropriate management, highlighting the role of dermatological examination in oncologic follow-up.

EADV CONGRESS
VIENNA
30 SEP - 3 OCT 2026

Abstract N°: 3757

Cutaneous Plasmocytoma arising at chemotherapy port site in a patient with multiple myeloma: a rare case report

Beghdad Ikram*[1], Lemya Mezdour[1], Farid Ait Belkacem[1], Samira Zobiri[1]

[1] Mustapha University Hospital, Dermatology Departement, Algiers, Algeria

Introduction

Cutaneous plasmocytomas associated with multiple myeloma are rare manifestation that usually indicate advanced or relapsed disease. Their occurrence at sites of medical devices or repeated microtrauma raises specific pathophysiological hypotheses

Case Presentation

We report the case of a 44-year-old man with a history of Multiple myeloma associated with diffuse osteolytic invovement and pathological fractures, receiving chemotherapy and considered for allogenic stem cells transplantation. The patient developed angiomatous cutaneous tumor lesions evolving over two months, located over the left subclavian chemotherapy port site as well as at two sites of intramuscular injection sites. Dermatological examination revealed a 4-cm erythematous-purpuric, firm nodular lesions traversed with telangiectasias. In context of MM relapse with spinal osteolytic progression, therapeutic intensification led to partial improvement of the cutaneous lesions.

Conclusion

This case illustrates a rare presentation of cutaneous plasmocytomas arising at the site of an implanted chemotherapy port, supporting the hypothesis that microtrauma may contribute to the extramedullary dissemination of multiple myeloma. Early recognition of these lesions is essential as they often reflect aggressive disease progression

EADV CONGRESS
VIENNA
30 SEP - 3 OCT 2026

Abstract N°: 3772

Diagnostic pitfalls and deceptive presentations of primary cutaneous diffuse large B-cell lymphoma : a two-case series

Hajar Baali*[1], Mariem Aboudourib[1], Bendaoud Layla[1], Ouafa Hocar[1], Said Amal[1]

[1] Dermatology department, Arrazi Hospital, CHU MOHAMMED VI Marrakech, Marrakech, Morocco

Introduction

Primary cutaneous diffuse large B-cell lymphoma (PCDLBCL) is a rare aggressive cutaneouslymphoma with heterogeneous clinical presentations. Ulcerative, infiltrative, or pseudo-infectious forms may closely mimic chronic inflammatory, infectious, or epithelial tumors, leading to delayed diagnosis and inappropriate management. Early recognition is particularlychallenging in patients presenting with necrotic or rapidly enlarging cutaneous masses. Wereport two cases of PCDLBCL with secondary nodal involvement presenting as deceptiveulcerative and infiltrative tumors, highlighting the importance of clinicopathologicalcorrelation in establishing an early diagnosis.

Case Presentation

Two male patients aged 61 and 77 years presented with chronic progressively enlargingcutaneous tumors evolving for nearly two years before diagnosis, both initially managed as non-lymphomatous conditions.

The first patient developed intensely pruritic infiltrated erythematous-violaceous nodules on the back, including a large 8-cm ulcerated tumor with a central necrotic crater and seropurulent discharge associated with ipsilateral axillary lymphadenopathy. The clinicalpresentation initially suggested chronic infection or cutaneous T-cell lymphoma.

The second patient presented with an extensive ulcerative and infiltrative axillary tumormeasuring 8 cm with irregular indurated borders, necrotic-fibrinous ulceration, bleeding, and bacterial superinfection, clinically mimicking an epithelial malignancy or chronic infectiousprocess. Ipsilateral axillary and bilateral inguinal lymphadenopathy were present at diagnosis.

Histopathological examination in both cases demonstrated dense dermal infiltration by large atypical lymphoid cells consistent with diffuse large B-cell lymphoma of germinal center phenotype. Immunohistochemistry revealed strong CD20 expression associated with BCL6 positivity and high proliferative activity (Ki67: 60% and 80%, respectively). Extension workup confirmed secondary nodal involvement without bone marrow infiltration or systemicdissemination.

Both patients received systemic CHOP/R-CHOP polychemotherapy with rapid and markedregression of the cutaneous tumors after the initial treatment cycles.

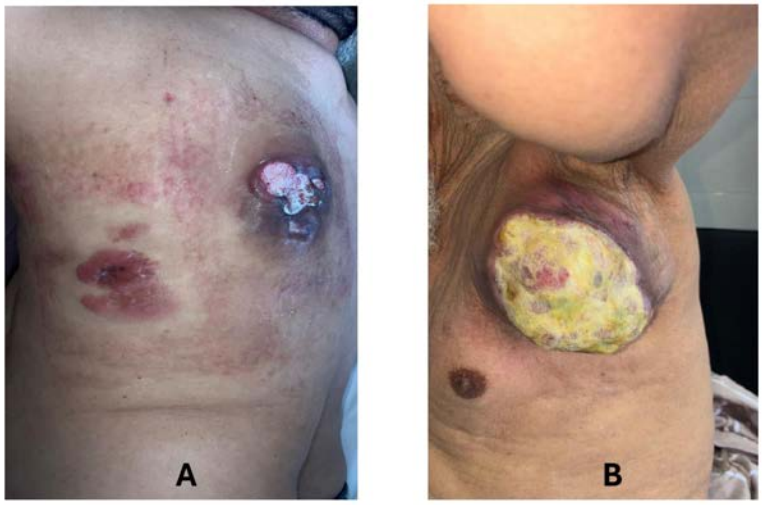

A. Infiltrated erythematous-violaceous dorsal nodules with central ulceration in primary cutaneous diffuse large B-cell lymphoma.
B. Massive ulcerative and infiltrative axillary tumor with necrotic-fibrinous surface and violaceous indurated borders mimicking an infectious or epithelial neoplastic process.

Deceptive clinical presentations of primary cutaneous diffuse large B-cell

Conclusion

PCDLBCL may present as chronic ulcerative or infiltrative tumors mimicking infectious, inflammatory, or epithelial neoplastic diseases, leading to major diagnostic delay and secondary nodal extension. These observations highlight the importance of early biopsy of persistent atypical cutaneous lesions and emphasize the crucial role of clinicopathologicalcorrelation in establishing prompt diagnosis and initiating appropriate systemic therapy.

EADV CONGRESS
VIENNA
30 SEP - 3 OCT 2026

Abstract N°: 3777

Spatial transcriptomics reveals the tumor microenvironment of cutaneous acute myeloid leukemia at single-cell resolution

Julia Staller*[1], Inigo Oyarzun[1], Martin Simon[1], Sabina Gansberger[1], Namrata Singh[1], Johannes Griss[1]

[1] Department of Dermatology, Medical University of Vienna, Vienna, Austria

Introduction

Cutaneous infiltration in acute myeloid leukemia (AML) represents a rare but clinically significant form of extramedullary disease, associated with adverse outcomes and limited therapeutic options. Despite its diagnostic relevance, the spatial architecture of leukemic infiltrates within the skin and their interactions with resident immune and stromal populations remain poorly characterized. 10x Xenium offers a powerful approach to dissect the tumor microenvironment (TME) in situ, enabling simultaneous profiling of gene expression and tissue morphology at single-cell resolution.

Materials and Methods

Skin biopsies from patients with biopsy-confirmed cutaneous AML and perilesional biopsies from patients with atopic dermatitis as non-malignant reference tissue were analyzed using the 10x Xenium platform with a targeted gene panel of over 5,000 genes. Cell-type deconvolution was carried out using a reference-based decomposition approach, drawing on a dual reference combining leukemia cutis-derived and healthy skin single-cell RNA sequencing datasets.[1,2] Multi-sample integration was performed with a spatially aware batch correction algorithm.[3] The integrated dataset encompassed over 250,000 cells across all AML samples. Analyses included sub-clustering of leukemic infiltrates, proximity-dependent differential gene expression, spatial niche characterization, and neighborhood differential abundance testing. Comparison with non-malignant control tissue was performed at both cellular composition and marker expression levels.

Results

Spatial transcriptomic profiling demonstrated substantial heterogeneity of AML infiltrates within the skin, comprising transcriptionally distinct leukemic subpopulations and diverse immune and stromal cell types. Despite this interpatient variability, the leukemic cutaneous tumor microenvironment (TME) displayed a highly conserved organization. We identified a reproducible, patient-independent, proximity-dependent transcriptional switch operating across major cellular compartments of the LC TME. Spatial analyses revealed non-random positioning of leukemic infiltrates relative to epidermal and dermal structures and highlighted conserved programs of immune evasion and stromal remodeling. We uncovered functionally organized immunological niches and identified previously uncharacterized immune evasion mechanisms, including HOX gene-mediated impairment of dendritic cell function and selectin-dependent endothelial remodeling potentially facilitating leukemic homing to the skin. Spatially resolved gene expression analyses identified a consistent proximity-associated reprogramming of the TME in regions adjacent to AML infiltrates. Immune populations, including MO/MACs, IFN-pDCs, pDCs, DCs, T cells, and NK cells, as well as stromal and tissue-resident cells such as fibroblasts, endothelial cells, smooth muscle cells, and keratinocytes, exhibited reduced interferon-associated immune surveillance signatures together with induction of leukemia-supportive transcriptional programs in close spatial association with AML cells. Compared to healthy skin we could also detect a gain of cancer-associated fibroblast (CAF) markers (COL1A1, FAP, TWIST1, HAS2, GREM1, VCAM1) in AML-LC tissue.

Conclusions

This work presents the first spatially resolved, single-cell resolution transcriptomic atlas of cutaneous AML, demonstrating that affected skin represents not merely a site of leukemic infiltration, but a comprehensively remodeled immunosuppressive niche. A defining feature of this microenvironment is the AML-proximity-dependent transcriptional reprogramming of all major TME cell types, spanning immune, stromal, and endothelial compartments. These findings extend existing transcriptomic characterizations of AML to a spatial in situ dimension and converge on multiple candidate axes for targeted therapeutic intervention in extramedullary leukemic disease.

EADV CONGRESS
VIENNA
30 SEP - 3 OCT 2026

Abstract N°: 3807

Correlation of circulating tumor DNA levels and cell-free DNA fragmentation pattern in mutant BRAF melanoma patients

Pablo Balado-Simó*[1], Anton Fornies-Mariné[2], Daniel Rizo[1], Judit Mateu[2], Susana Puig[3], Josep Malvehy[4], Jose Luis Villanueva-Cañas[2], Cristina Carrera[3], Joan Anton Puig Butille[5]

[1] Dermatology Department, Hospital Clínic Barcelona, Barcelona, Spain, Melanoma Group, August Pi Sunyer Biomedical Research Institute (IDIBAPS), Barcelona, Spain, University of Barcelona, Barcelona, Spain., Barcelona, Spain

[2] Melanoma Group, August Pi Sunyer Biomedical Research Institute (IDIBAPS), Barcelona, Spain, Barcelona, Spain

[3] Dermatology Department, Hospital Clínic Barcelona, Barcelona, Spain, Barcelona, Spain

[4] Dermatology Department, Hospital Clínic Barcelona, Barcelona, Spain, Dermatology Department, Hospital de Figueres, Fundació Salut Empordà, Figueres, Spain, Barcelona, Spain

[5] Molecular Biology CORE facility, Hospital Clínic Barcelona, Barcelona, Spain, Barcelona, Spain

Introduction

Cutaneous melanoma requires accurate non-invasive biomarkers for disease monitoring and relapse detection. Circulating cell-free DNA (cfDNA) contains DNA fragments released by both tumor and non-tumor cells, mainly hematopoietic cells. In patients with *BRAF*-mutated melanoma, *BRAF*-mutant cfDNA copies represent circulating tumor DNA (ctDNA) and can be sensitively quantified by droplet digital PCR (ddPCR).

Beyond mutational detection, ctDNA may display specific fragmentomic features compared with non-tumor cfDNA, including shorter fragment size and greater fragment-size heterogeneity. We investigated whether cfDNA fragmentation patterns are associated with ctDNA levels in patients with *BRAF*-mutated high-risk melanoma.

Materials and Methods

We analyzed 318 plasma samples from 127 patients with *BRAF*-mutated high-risk melanoma. Median age was 60 years (IQR 52-74), and 56.0% of samples were from female patients. Baseline stages were II in 59 samples (18.6%), III in 219 (68.9%), and IV in 40 (12.6%). Samples were collected preoperatively (n=22, 6.9%), postoperatively (n=29, 9.1%), during follow-up (n=189, 59.4%), at relapse (n=24, 7.5%), or in unresectable disease (n=54, 17.0%).

ctDNA was quantified using a *BRAF V600* ddPCR assay and expressed as variant allele frequency (VAF). cfDNA fragmentation was assessed by automated capillary electrophoresis, including fragment proportions, mean fragment size and coefficient of variation across predefined size ranges: 20-150, 100-150, 160-180, 163-169, 180-220, 250-320, 320-700 and 700-1300 bp.

Two complementary analyses were performed. First, fragmentomic differences between *BRAF*-detectable and non-detectable plasma samples were evaluated using a matched case-control approach. Second, associations between cfDNA fragmentomic features and ctDNA levels were assessed only among *BRAF*-detectable samples using Spearman correlation and regression models adjusted for age, sex and cfDNA concentration. Spearman correlation p-values were adjusted for multiple testing using false discovery rate (FDR) correction.

Results

BRAF-mutant ctDNA was detectable in 53/318 plasma samples (16.7%). In the matched case-control analysis of ctDNA detectability, 102 samples from 58 patients were retained, including 37 *BRAF*-detectable and 65 *BRAF*-non-detectable samples. cfDNA fragmentomic features did not robustly discriminate ctDNA detectability. However, among the 53 *BRAF*-detectable samples, ctDNA levels were significantly associated with cfDNA fragmentomic features.

ctDNA levels correlated negatively with canonical nucleosomal fragment ranges, including 160-180 bp (Spearman's rho=-0.494, p=0.00017) and 163-169 bp (rho=-0.430, p=0.0013). Conversely, *ctDNA levels* correlated positively with 20-150 bp fragments (rho=0.332, p=0.0150), 100-150 bp fragments (rho=0.347, p=0.0109) and 250-320 bp fragments (rho=0.389, p=0.0048). Higher *ctDNA levels* was also associated with increased fragment-size variability in the 250-320 bp range (rho=0.367, p=0.0080) and with reduced mean fragment size within this range (rho=-0.333, p=0.0170). In adjusted regression models, the main associations with 160-180, 163-169, 250-320, 100-150, and 20-150 bp fragment proportions were retained.

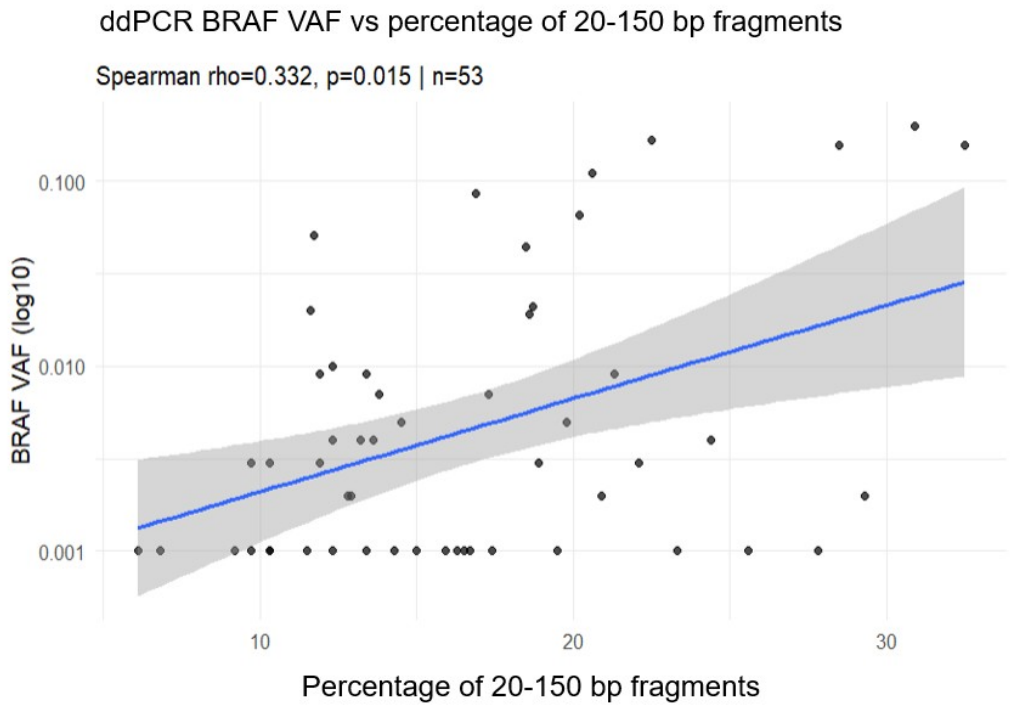

Positive correlation between ddPCR BRAF VAF and the proportion of short cfDNA fragments (20-150 bp) in samples with detectable ctDNA.

Conclusions

cfDNA fragmentomics did not act as a binary marker of ctDNA detectability, but reflected ctDNA burden in *BRAF*-mutated high-risk melanoma. This may be explained by the increasing contribution of tumor-derived cfDNA, which carries distinct fragmentation patterns and adds heterogeneity to the predominantly hematopoietic cfDNA background. Fragmentomic profiling may therefore complement mutation-based ctDNA quantification as a measure of tumor DNA burden.

EADV CONGRESS
VIENNA
30 SEP - 3 OCT 2026

Abstract N°: 3809

Diffuse plane normolipaemic xanthomatosis as a manifestation of monoclonal gammopathy

feyrouz laradi*[1]

[1] chu bab el oued, Algers, Algeria

Introduction

Diffuse plane xanthoma is a rare form of non-Langerhans histiocytosis that typically presents as asymptomatic symmetric diffuse yellow macules and plaques. Extracutaneous lesions may be noted. It is strongly associated with haematological disorders.

Case Presentation

A 74-year-old man presented with an 18-month history of progressive, asymptomatic yellow–orange plaques symmetrically distributed over the periorbital area, trunk, back and upper and lower extremities(Figure). Mucosal involvement was noted, with yellowish discoloration of the genital mucosa. His medical history was significant for hypertension and an IgG lambda monoclonal gammopathy under haematological investigation. Lipid profile was normal. Skin biopsy with immunohistochemistry was performed and results are pending. Systemic evaluation, including abdominal ultrasound, bone scintigraphy and thoraco-abdomino-pelvic CT, was undertaken to assess extracutaneous involvement.

The clinical presentation is consistent with diffuse plane xanthoma in the context of a monoclonal gammopathy.

Conclusion

Diffuse plane xanthomatosis is a rare dermatosis, often indicative of an underlying monoclonal gammopathy, particularly in normolipidemic patients. Our case illustrates a typical clinical presentation associated with an IgG monoclonal gammopathy, with the unusual feature of mucosal involvement. This case highlights the importance of a systematic hematologic workup in any patient with diffuse plane xanthomatosis and the need for a multidisciplinary management approach.

EA DV CONGRESS
VIENNA
30 SEP - 3 OCT 2026

Abstract N°: 3816

Multifocal scalp angiosarcoma in a young patient with xeroderma pigmentosum (XPC): successful response to neoadjuvant pembrolizumab and radiotherapy a decade after first-line immunotherapy

Joanna Cheng*[1], Ke Zhang[2], Judy Zhou[2], Yuhan Zeng[1], Zinan Zhang[3], Aaron Paul[4], Emily Hartsough[5], Ruth Foreman[5], Kevin Liu[6], Kevin Emerick[7], Edwin Choy[8], Shadmehr Demehri[1]

[1] Center for Cancer Immunology, Krantz Family Center for Cancer Research, Massachusetts General Hospital and Harvard Medical School, Boston, MA, USA, Cutaneous Biology Research Center, Department of Dermatology, Massachusetts General Hospital and Harvard Medical School, Boston, MA, USA, Boston, United States

[2] Cutaneous Biology Research Center, Department of Dermatology, Massachusetts General Hospital and Harvard Medical School, Boston, MA, USA, Broad Institute of MIT and Harvard, Cambridge, MA, USA, Boston, United States

[3] Department of Dermatology, Massachusetts General Hospital and Harvard Medical School, Boston, MA, USA, Boston, United States

[4] Department of Radiology, Massachusetts General Hospital, Harvard Medical School, Boston, MA, USA, Boston, United States

[5] Dermatopathology Unit, Department of Pathology, Massachusetts General Hospital, Harvard Medical School, Boston, MA, USA, Boston, United States

[6] Department of Radiation Oncology, Massachusetts General Hospital, Harvard Medical School, Boston, MA, USA, Boston, United States

[7] Department of Otolaryngology, Head and Neck Surgery, Massachusetts Eye and Ear, Harvard Medical School, Boston, MA, USA, Boston, United States

[8] Division of Hematology and Oncology, Massachusetts General Hospital, Harvard Medical School, Boston, MA, USA, Boston, United States

Introduction

Cutaneous angiosarcoma (cAS) typically arises on the scalp of elderly, chronically photodamaged patients (median age >70 years). Its occurrence in young patients with xeroderma pigmentosum (XP) is exceptional, with fewer than ten cases reported worldwide. Because XP results in extreme UV-induced mutational load, XP-associated cAS is predicted to be highly immunogenic, yet evidence for checkpoint blockade in this rare entity is limited. We present a young XPC-deficient patient with multifocal scalp angiosarcoma who responded to neoadjuvant pembrolizumab combined with radiotherapy. Notably, a decade after she had received a complete one-year course of pembrolizumab for an unresectable squamous cell carcinoma of the eyelid.

Case Presentation

A 27-year-old woman with biallelic XPC mutation (NIH-confirmed) and a history of multiple cutaneous malignancies, including an unresectable periocular squamous cell carcinoma treated with 17 cycles of pembrolizumab in 2016–2017, presented with rapidly progressive multifocal scalp lesions. Punch biopsy demonstrated high-grade angiosarcoma (CD31+, ERG+, HHV8−, cytokeratin−, p40−, SOX-10−, Melan-A−); initial excision showed residual disease at margins. Following multidisciplinary review, she received neoadjuvant pembrolizumab (200 mg IV q21d) combined with definitive radiotherapy (7000 cGy in 35 fractions; VMAT). After ten pembrolizumab cycles and completed radiotherapy, PET/CT demonstrated no residual FDG uptake at the scalp and

resolution of the previously avid cervical lymph node. Treatment was tolerated with grade-3 radiation dermatitis but no cutaneous radiation-induced complications attributable to XP.

Conclusion

This case expands the limited literature on XP-associated cutaneous angiosarcoma and provides clinical evidence that neoadjuvant pembrolizumab combined with definitive radiotherapy can achieve excellent locoregional response in NER-deficient patients, including those previously exposed to checkpoint blockade for a separate cutaneous malignancy. Radiotherapy was tolerable despite XP. These observations support consideration of checkpoint blockade and radiotherapy as a rational therapeutic strategy in this ultra-rare patient population.

EADV CONGRESS
VIENNA
30 SEP - 3 OCT 2026

Abstract N°: 3818

Predictive Role of Autoantibodies in Immune Checkpoint Inhibitor Therapy using Liquid Biopsies

Julian Steininger*[1], Björk Klein[2], Dana Westphal[2], Friedegund Meier[2], Claudia Günther[1, 2]

[1] Department of Dermatology, University Hospital Tübingen, Tübingen, Germany

[2] Department of Dermatology, Faculty of Medicine and University Hospital Carl Gustav Carus, Technische Universität (TU) Dresden, Dresden, Germany

Introduction

Immune checkpoint inhibitors (ICIs) have revolutionized the treatment of advanced skin cancers, particularly malignant melanoma (MM), leading to significant clinical successes. However, predicting how an individual patient will respond to therapy or whether they will develop immune-related adverse events (irAEs) remains a major clinical challenge. Despite the overall effectiveness of ICIs, there is a clear need for further research into reliable, non-invasive biomarkers to improve individual risk assessment and patient stratification. This study investigates the potential of systemic autoantibody (AAb) profiles to serve as predictive markers for therapeutic outcomes.

Materials and Methods

From March 2020 to March 2023 a total of 100 patients (30 women, 70 men, median age 72) receiving ICI therapy for advanced skin cancer (94% MM, 6% NMSC) were included at the University Hospital Dresden. Blood samples were collected before, during, and after ICI therapy. 35 autoantibodies (AABs), each associated with specific autoimmune diseases, were selected to establish a customized detection panel. Healthy donor sera were used for defining cut-offs. Tumor responses (complete response [CR], partial response [PR], or progressive disease [PD]) were analyzed separately based on ongoing staging assessments.

Results

Analysis of the AAb burden showed a balanced distribution: approximately 1/3 of patients presented with 0 AAbs, 1/3 with 1 AAb, and 1/3 with 2 or more AAbs. A high AAb burden (≥2 AAbs) emerged as the sole significant predictor for CR. Patients in the AAb-high cohort demonstrated a 4.7-fold higher probability of achieving CR compared to those with a low burden (OR 4.71; 95%-CI 1.12–23.69; p=0.043). Clinical covariates, including age (p=0.606), sex (p=0.565), and immune-related adverse events (irAEs; p=0.638), showed no significant influence. On a single-antigen level, CDR2 was identified as the strongest individual predictor (p=0.029). Interestingly, CDR2 showed an inverse trend: while high total burden correlated with benefit, CDR2 presence specifically associated with PD. A dose-response analysis using a "Benefit-Score" (total AAbs excluding CDR2) confirmed a significant positive trend for CR (p=0.0321). The diagnostic accuracy of the AAb burden was validated via ROC analysis, yielding an AUC of 0.711. Using the Youden Index, an optimal threshold of ≥2 AAbs was identified, providing a specificity of 87.5% and a sensitivity of 61.9% for predicting CR. The model's robustness was confirmed through 5-fold cross-validation (CV-AUC = 0.722), ensuring the stability of the predictive signal.

Conclusions

In our model, we were unable to establish a clear association between specific AABs and the development of irAEs. However, we observed that the presence of at least 2 AABs was significantly associated with improved therapeutic response. This finding is biologically plausible, as it may reflect a more active immune system, which in turn could enhance antitumor efficacy.

EADV CONGRESS
VIENNA
30 SEP - 3 OCT 2026

Abstract N°: 3820

Melanoma in CDKN2A Mutation Carriers: Longitudinal Real-World Data From a Melanoma Unit in Spain

Amalia Luna*[1, 1], Miriam Potrony[1], Celia Badenas[1], Sebastian Podlipnik[1], Cristina Carrera[1], Josep Malvehy[1], Susana Puig[1], Paula Aguilera[1]

[1] Hospital Clinic of Barcelona, Universitat de Barcelona, IDIBAPS, Barcelona, Spain

Introduction

Germline *CDKN2A* mutations are the leading known cause of hereditary cutaneous melanoma, conferring susceptibility to early-onset and multiple primary tumors.

In Spain, affected patients display a clinically heterogeneous phenotype, and a deeper characterization of this population may improve risk stratification, surveillance strategies, and genetic counseling in melanoma-prone families.

Materials and Methods

We conducted a retrospective cohort study including patients with melanoma carrying pathogenic*CDKN2A* mutations followed at a melanoma referral unit in Spain between 2010 and 2026. Melanoma-prone families harbouring *CDKN2A* mutations were identified and characterised. Demographic, clinical, and genetic data were collected, including sex, age at first melanoma diagnosis, total number of primary melanomas, and *CDKN2A* mutation subtype. Breslow thickness across successive melanoma diagnoses was compared using a paired Wilcoxon signed-rank test. All statistical analyses were performed using R statistical software.

Results

A total of 135 affected individuals from 83 families were included (56.7% female). Median age at first melanoma diagnosis was 40 years (range 18–77), with a cumulative burden of 297 melanomas across the cohort (mean 2.48 per patient). The majority of families (57%) had a single identified affected member, while the largest family comprised 6 affected individuals.

The c.301G>T p.(Gly101Trp) pathogenic variant was the most frequent, identified in 35 of 83 families (42.2%), accounting for 43% of all affected patients.

A key clinical finding emerged regarding the impact of surveillance on tumor thickness. Among patients with ≥2 melanomas, Breslow thickness decreased significantly with successive diagnoses: median Breslow at first melanoma was 0.9 mm [IQR 0.5–1.5] (27% in situ), compared to 0.5 mm [IQR 0.4–0.7] at second melanoma (39% in situ) and 0.5 mm [IQR 0.4–0.7] at third melanoma (55% in situ). In the 27 patients with recorded Breslow thickness at both first and second melanoma, a paired Wilcoxon signed-rank test confirmed a statistically significant reduction in tumor thickness ($p = 0.0148$), with each patient serving as their own control to account for inter-individual variability in genetic background, age, and phototype.

Conclusions

This large Spanish cohort demonstrates that *CDKN2A* mutation carriers develop multiple primary melanomas at a young age, with the c.301G>T p.(Gly101Trp) being the dominant pathogenic variant. Dermatological surveillance shifts the diagnostic landscape toward earlier, thinner tumors, as evidenced by a statistically significant reduction in Breslow thickness and a near-doubling of in situ melanoma rates at successive diagnoses. These findings underscore the importance of lifelong structured surveillance and genetic testing in melanoma-prone families, with direct implications for risk stratification and clinical management.

EADV CONGRESS
VIENNA
30 SEP - 3 OCT 2026

Abstract N°: 3831

Primary cutaneous marginal zone lymphoma associated with discoid lupus erythematosus. ¿Causality or coincidence?

Harold Farit Arenas Torrado*[1], Miguel Angel Nieto Bayona[1], Hector Perez[1]

[1] Universidad Nacional de Colombia, Bogotá, Colombia

Introduction

Primary cutaneous marginal zone lymphoma (PCMZL) is a cutaneous lymphoma of mature B cells, predominantly of post-germinal center origin. Its incidence and prevalence are not well known; however, it is estimated to account for 30–40% of all primary cutaneous B-cell lymphomas, mainly affecting adults in the fourth and fifth decade of life, with a male predominance.

Case Presentation

We present the case of a 30-year-old woman who consults the dermatology department for lesions on the nose and cheeks since adolescence that were exacerbated by sun exposure and had been managed as rosacea. For the past year, she reported recurrent lesions on both ears and, additionally, she had lesions on her nose and cheeks of 8 months' evolution, which prompted her to seek consultation. On physical examination, erythematous papules and nodules with apple jelly sign were observed on an infiltrated erythematous plaque on the cheeks and nose. A skin biopsy was performed, revealing a dermal lymphoid proliferation with a grenz zone; the tumor cells were CD20 positive, with positivity for BCL2 and CD43, and negative for immunostaining for CD10, BCL6, and CD5, establishing the diagnosis of PCMZL. Hematologic involvement was ruled out by flow cytometry and involvement of other organs by positron emission tomography, so it was decided to manage with anti-CD20 (rituximab) with dose adjusted to body surface area, administered monthly, for a total of 4 doses. One month after the completion of rituximab therapy, the lesions on the cheeks and nose had improved notably; however, the patient continued to report lesions on the ears. On this occasion, erythematoviolaceous plaques were observed on the right auricle. Dermoscopy revealed the presence of keratotic plugs, so a biopsy was taken, confirming the diagnosis of discoid lupus erythematosus. Systemic lupus erythematosus was ruled out. In the pathophysiology of PCMZL, persistent antigenic stimulation by antigens applied intradermally—such as tick bites (Borrelia spp.), tattoo pigments, and vaccines—has been described. Additionally, a higher frequency of several gastrointestinal disorders (such as reflux, gastric ulcers, positive serology for Helicobacter pylori, irritable bowel disease) and of various different autoimmune diseases such as systemic lupus erythematosus has been observed. The risk of non-Hodgkin lymphomas in patients with systemic lupus erythematosus is well described, with a risk 3–5.4 times greater. Pathophysiologically, chronic inflammation, B- and T-cell hyperactivity, together with somatic hypermutation of immunoglobulin genes that lead to clonal evolution of B cells have been proposed. However, no association between cutaneous lupus erythematosus and the risk of PCMZL or non-Hodgkin lymphomas has been described.

Conclusion

The fact that the lesions on the ears preceded the PCMZL lesions suggests a probable relationship between both entities. Although the risk of developing PCMZL in patients with systemic lupus erythematosus has been described, this is the first time a case associated with cutaneous lupus erythematosus without systemic involvement has been reported, representing an opportunity for future research.

POWERED BY M-ANAGE.COM

EA DV CONGRESS
VIENNA
30 SEP - 3 OCT 2026

Abstract N°: 3848

Basal Cell Nevus Syndrome with a Pathogenic PTCH1 Mutation in a 61-Year-Old Filipino Male: Multimodal Management and Case Report

Karen Amora*[1], Nicole Marella Tan[1], Mia Katrina Gervasio[1], Felix Paolo Lizarondo[1], Arunee Siripunvarapon[1]

[1] University of the Philippines - Philippine General Hospital, Manila, Philippines

Introduction

Basal cell nevus syndrome (BCNS), also known as Gorlin-Goltz syndrome, is a rare autosomal dominant genodermatosis characterized by the development of multiple basal cell carcinomas (BCCs), palmoplantar pits, craniofacial abnormalities, ectopic calcification, odontogenic keratocysts, and an overall increased risk of developing neoplasms. Mutations in the *PTCH1*, *PTCH2*, or *SUFU* genes cause aberrations in the hedgehog signaling pathway (Hh), thus producing the clinical manifestations of BCNS. It has an estimated prevalence of 1 per 57,000; however, true prevalence could be higher as phenotypic variability and different ages of onset complicate diagnosis.

Treatment of cutaneous lesions depends on the subtype of each BCC lesion, but is primarily surgical While cure is often achieved with minimal risk of recurrence, invasive strategies may cause disfigurement and distress, especially in the setting of multiple lesions; hence, less invasive, novel approaches are being explored to optimize disease control while preserving function and quality of life.

We present a case of BCNS with *PTCH1* mutation managed with both curative and preventive intent through surgical and non-invasive modalities.

Case Presentation

A 61-year old Filipino male presented with a 3-year history of enlarging papules and plaques on the face. Full body examination revealed 30 BCCs, palmar pits, coarse facies, hypertelorism, keloidal scars, and multiple cystic and lipomatous masses. A clinical diagnosis of BCNS was made, supported by a pathogenic *PTCH1* mutation documented on genetic testing, and bilamellar calcification of the falx cerebri on plain cranial computed tomography scan. The patient underwent Mohs micrographic surgery for select lesions on the face; reconstruction with cheek advancement flap provided excellent cosmetic outcomes. A BCC on the flank treated with one session of long-pulsed 1064-nm neodymium-doped yttrium aluminum garnet laser showed complete histopathologic clearance. Imiquimod cream and oral itraconazole resulted in improvement of BCCs not treated with other modalities. The patient presently has good disease control, and reports no concern with his current management.

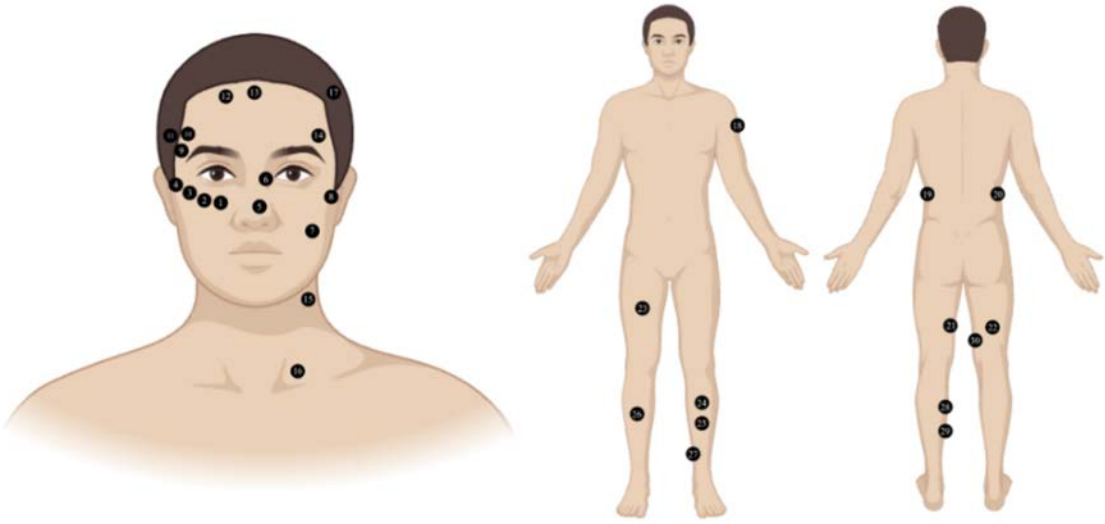

A body map of basal cell carcinomas seen on full body examination.

Conclusion

In BCNS, heightened clinical vigilance and early recognition are imperative to timely intervention. Management increasingly incorporates novel therapies to achieve tumor control while preserving patient quality of life. Given the lifelong risk of tumorigenesis and multisystem involvement, a multidisciplinary and multimodality, patient-centered approach is essential to optimize long-term outcomes.

Curative		**Preventive**
Surgical	**Non-Surgical**	
Mohs micrographic surgery for BCCs 1, 2, 3, 4	*Topical* Imiquimod 5% cream for BCCs 9, 10, 11 *Systemic* Itraconazole 100 mg cap, 1 cap twice a day *Procedural* Long-pulsed 1064-nm Nd:YAG laser for BCCs 18, 19, 20	Photoprotective measures Avoidance of environmental mutagens Routine full body skin examination every 6 months
Wide excision for BCC 19		

Summary of interventions done in this patient.

POWERED BY M-ANAGE.COM

EA DV CONGRESS
VIENNA
30 SEP - 3 OCT 2026

Abstract N°: 3852

Diffuse Large B-Cell Lymphoma Presenting as a Solitary Nodule on the Lip in a Newly Diagnosed Case of HIV

Karen Amora*[1], Marian Rosel Villaverde[1], Leah Antoinette Caro-Chang[1]

[1] University of the Philippines - Philippine General Hospital, Manila, Philippines

Introduction

Non-Hodgkin lymphomas (NHL) are among the most common hematologic malignancies, with diffuse large B-cell lymphoma (DLBCL) being its most common subtype, accounting for approximately 30% of cases worldwide. The pathogenesis of DLBCL has not been fully elucidated; it may arise de novo, or stem from high-grade transformation of a less aggressive lymphoma, primarily affecting the elderly. Immunodeficiency is a risk factor for developing DLBCL. In fact, it is the most common type of lymphoma in the background of human immunodeficiency virus (HIV) infection, accounting for about 70-90% of NHLs in the HIV population.

Survival rates in NHL, including DLBCL, have improved with advances in early detection and treatment. Treatment depends on disease extent, but is primarily immunochemotherapy-driven. In the setting of HIV infection, highly active antiretroviral therapy (HAART) is considered an essential component of the chemotherapeutic regimen, contributing to improved overall survival.

We present a case of a biopsy-proven DLBCL presenting as a solitary nodule on the lip in a newly-diagnosed case of HIV, which showed clinical regression on HAART alone.

Case Presentation

A 28-year-old Filipino male with a recent diagnosis of HIV presented with a 3-week history of a gradually enlarging, asymptomatic nodule on the right lower lip. He denied any preceding trauma or other medical illnesses. A complete systemic examination was unremarkable. A wedge biopsy of the lesion was performed, followed by histopathologic examination and immunohistochemical staining.

Physical examination revealed a solitary, firm, erythematous nodule measuring 1.2 × 1.0 × 0.2 cm on the right lower lip with central hemorrhagic crusting and no associated lymphadenopathy. Histopathologic examination showed a dense nodular dermal proliferation of atypical large hyperchromatic lymphoid cells with conspicuous nucleoli and frequent mitotic figures, admixed with inflammatory cells. Immunohistochemistry demonstrated CD20 positivity and CD3, CD30 negativity, with Bcl2 positivity, Bcl6 negativity, scattered kappa and lambda light chain staining, MUM1 positivity in approximately 20% of cells, and a high Ki-67 proliferative index of 60%, consistent with DLBCL. Neck ultrasound revealed a solitary enlarged right submandibular lymph node.

The patient was lost to follow-up for four months but returned with complete clinical regression of the lip nodule while on highly active antiretroviral therapy (HAART) alone. He is currently undergoing further oncologic evaluation for possible initiation of R-CHOP chemotherapy.

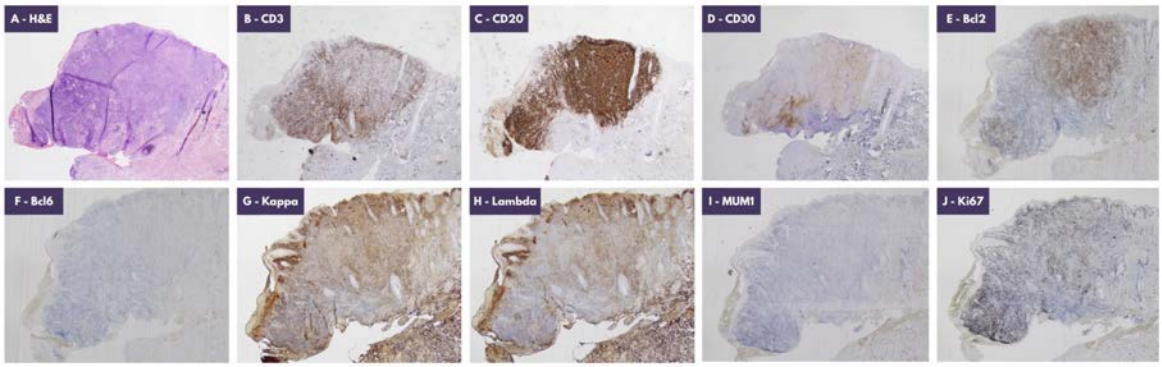

A dense nodular dermal proliferation of atypical large hyperchromatic lymphoid cells with conspicuous nucleoli and frequent mitoses was seen on H&E (40×). Immunohistochemistry showed CD20+, CD3−, CD30−, Bcl2+, Bcl6−, scattered kappa, lambda, and MUM1 (20%), with high Ki-67 index (60%).

Conclusion

There is an increased incidence of hematologic malignancies among patients with HIV. This case highlights the rare presentation of diffuse large B-cell lymphoma as a nodule on the lip, underscoring the importance of vigilant malignancy screening, particularly when atypical mucocutaneous lesions arise in this population. Prompt recognition of HIV-associated lymphomas, together with multidisciplinary collaboration among HIV specialists, hematologist-oncologists, head and neck surgeons, and dermatologists, is crucial for the timely initiation of therapy. In addition to standard chemotherapeutic regimens, concomitant administration of HAART has been shown to improve clinical outcomes

EA DV CONGRESS
VIENNA
30 SEP - 3 OCT 2026

Abstract N°: 3856

Oculodermal Melanocytosis (Nevus of Ota) and Its Association with Choroidal Melanoma and Primary Central Nervous System Melanocytic Tumors: A Systematic Review

Wiktor Kruczek*[1, 2, 3], Iga Litwińska[3], Wiktoria Bajek[3], Aleksandra Frątczak[2], Anna Tekielak[1, 2], Bartosz Miziołek[2], Beata Bergler-Czop[2]

[1] Doctoral School, Medical University of Silesia, Department of Dermatology, School of Medicine in Katowice, Medical University of Silesia, Students' Scientific Association at the Department of Dermatology, School of Medicine in Katowice, Medical University of Silesia, Katowice, Poland

[2] Department of Dermatology, School of Medicine in Katowice, Medical University of Silesia, Katowice, Poland

[3] Students' Scientific Association at the Department of Dermatology, School of Medicine in Katowice, Medical University of Silesia, Katowice, Poland

Introduction

Oculodermal melanocytosis (ODM), also known as nevus of Ota, is a congenital pigmentary disorder involving the periocular skin and ocular structures, with less frequent mucosal or meningeal extension. Although usually classified as a benign melanocytic condition, its clinical significance is shaped by the risk of glaucoma and uveal melanoma, particularly choroidal melanoma. Primary melanocytic tumours of the central nervous system (CNS) have also been described in this context, but available data are limited and dispersed across isolated reports.

Materials and Methods

A systematic review was performed in accordance with PRISMA 2020 guidelines. PubMed/MEDLINE, Embase, Scopus, Web of Science, the Cochrane Library and Google Scholar were searched without date restriction up to May 2026. Search terms combined synonyms for "nevus of Ota", "oculodermal melanocytosis" and "ocular melanocytosis" with terms related to "choroidal melanoma", "uveal melanoma", "primary CNS melanoma", "meningeal melanocytoma", "leptomeningeal melanosis" and "leptomeningeal melanomatosis". Human case reports, case series and observational studies were eligible when ODM or related ocular/dermal melanocytosis was described together with choroidal/uveal melanoma or a primary CNS melanocytic tumour. Titles, abstracts and full texts were screened independently by two reviewers. Disagreements were resolved by consensus. Data were extracted on demographics, laterality, tumour site, diagnostic confirmation, treatment and outcomes. Methodological quality was assessed using design-specific critical appraisal tools. Owing to clinical and methodological heterogeneity, the findings were synthesised narratively.

Results

668 records were identified. After duplicate removal, screening and full-text assessment, 14 publications were included. Most available data concerned ocular disease and were derived from retrospective ophthalmic cohorts, whereas CNS involvement was represented mainly by isolated case reports. In the largest cohort, ODM was documented in 230 of 7,872 eyes with uveal melanoma, corresponding to 3%. Compared with uveal melanoma without melanocytosis, a higher metastatic risk was observed, with published estimates indicating a 1.6-fold relative increase overall and greater risk when iris or choroidal melanocytosis was present. In White patients with ODM, the lifetime risk of uveal melanoma has been estimated at approximately 1 in 400. Choroidal melanoma was the predominant malignancy linked to ODM, including tumours arising within diffuse or sectoral areas of

pigmentation. Primary CNS melanocytic tumours were rare and included cerebral, meningeal and leptomeningeal lesions within the melanoma–melanocytoma spectrum. Reporting was uneven, particularly regarding molecular profiling, follow-up duration and indications for neurological assessment. Glaucoma and mucosal involvement were also repeatedly described as clinically relevant manifestations.

Conclusions

ODM extends beyond a cosmetic or purely dermatologic diagnosis. Its ocular implications, especially the association with choroidal/uveal melanoma, support long-term ophthalmic surveillance with careful fundus examination and multimodal imaging. Primary CNS melanocytic tumours remain exceptional; therefore, neurological evaluation appears most justified in patients with neurological symptoms or atypical clinical features. On the basis of current evidence, individualized multidisciplinary follow-up seems preferable to routine neuroimaging of asymptomatic patients.

EADV CONGRESS
VIENNA
30 SEP - 3 OCT 2026

Abstract N°: 3895

In silico analysis of KIT gene variants and their possible association with melanoma pathogenesis

Monaly da Silva Ribeiro*[1], Larissa Rabi[2], Natassia Bufalo[1]

[1] Faculdade São Leopoldo Mandic, Campinas, Brazil

[2] Centro Universitário Nossa Senhora do Patrocínio, Itu, Brazil

Introduction

Cutaneous melanoma is the most aggressive malignant skin neoplasm, presenting a high metastatic potential and unfavorable clinical prognosis. Exposure to ultraviolet radiation is the main etiological determinant, promoting the accumulation of genomic alterations that modulate essential signaling pathways. The KIT gene, located on chromosome 4q12, encodes a transmembrane tyrosine kinase receptor fundamental to cell proliferation and differentiation processes. Mutations in this gene are frequently described in the acral lentiginous melanoma and mucosal melanoma subtypes, often resulting in ligand-independent constitutive activation of the receptor. However, the functional impact of many missense single nucleotide polymorphisms (SNPs) in the KIT gene is still poorly characterized, limiting the identification of variants with biological and clinical relevance. This study aims to predict, through in silico analysis, the functional, structural, and stability effects of missense variants of the KIT gene to prioritize candidates for functional validation.

Introduction

Cutaneous melanoma is the most aggressive malignant skin neoplasm, presenting a high metastatic potential and unfavorable clinical prognosis. Exposure to ultraviolet radiation is the main etiological determinant, promoting the accumulation of genomic alterations that modulate essential signaling pathways. The KIT gene, located on chromosome 4q12, encodes a transmembrane tyrosine kinase receptor fundamental to cell proliferation and differentiation processes. Mutations in this gene are frequently described in the acral lentiginous melanoma and mucosal melanoma subtypes, often resulting in ligand-independent constitutive activation of the receptor. However, the functional impact of many missense single nucleotide polymorphisms (SNPs) in the KIT gene is still poorly characterized, limiting the identification of variants with biological and clinical relevance. This study aims to predict, through in silico analysis, the functional, structural, and stability effects of missense variants of the KIT gene to prioritize candidates for functional validation.

Materials and Methods

The study design was based on a descriptive and analytical in silico approach. Variants were obtained from the Genome Browser, dbSNP, and UniProt databases, totaling 101 initial SNPs. A systematic filtering process was applied considering the frequency of the minority allele between 0.1 and 1.0 and the location in coding regions (missense). The prediction of functional impact was performed using an integrated set of tools: PredictSNP, SIFT, PolyPhen-1, PolyPhen-2, MAPP, PhD-SNP, and PANTHER. Variants classified as deleterious by at least six independent algorithms were considered highly relevant. Protein stability was investigated using iStable, allowing

inferences about trends in changes in conformational stability. Detailed structural analysis used the DynaMut2 tool to evaluate changes in protein flexibility, hydrogen bonds, and hydrophobic interactions resulting from mutations. The three-dimensional reference model was obtained from databases such as the Protein Data Bank and AlphaFold predictions.

Material and Method
The study design was based on a descriptive and analytical in silico approach. Variants were obtained from the Genome Browser, dbSNP, and UniProt databases, totaling 101 initial SNPs. A systematic filtering process was applied considering the frequency of the minority allele between 0.1 and 1.0 and the location in coding regions (missense). The prediction of functional impact was performed using an integrated set of tools: PredictSNP, SIFT, PolyPhen-1, PolyPhen-2, MAPP, PhD-SNP, and PANTHER. Variants classified as deleterious by at least six independent algorithms were considered highly relevant. Protein stability was investigated using iStable, allowing inferences about trends in changes in conformational stability. Detailed structural analysis used the DynaMut2 tool to evaluate changes in protein flexibility, hydrogen bonds, and hydrophobic interactions resulting from mutations. The three-dimensional reference model was obtained from databases such as the Protein Data Bank and AlphaFold predictions.

Results

Systematic filtering resulted in the identification of 21 variants with high deleterious potential. Among these, 10 SNPs were prioritized for in-depth structural analysis due to their location in critical functional regions of the protein. Nine variants showed total prediction agreement as deleterious: V560D, V620A, V654A, G664R, R686C, R796G, E839K, T847P, and F584C. The D816H variant showed partial concordance but was retained due to its established association with resistance to tyrosine kinase inhibitors. Structural modeling revealed that mutations are concentrated in the tyrosine kinase domain, specifically in areas linked to the catalytic cleft and the ATP binding site. Substitutions such as G664R and T847P significantly alter the organization of hydrophobic interactions and local flexibility. Variants such as D816H and R686C were associated with the rearrangement of hydrogen bonds, modifying the network of contacts that sustains the native conformation. Overall, the mutations promote a reduction in the density of stabilizing contacts, suggesting an increase in conformational flexibility capable of favoring active receptor states even without ligand stimulation.

Results

Systematic filtering resulted in the identification of 21 variants with high deleterious potential. Among these, 10 SNPs were prioritized for in-depth structural analysis due to their location in critical functional regions of the protein. Nine variants showed total prediction agreement as deleterious: V560D, V620A, V654A, G664R, R686C, R796G, E839K, T847P, and F584C. The D816H variant showed partial concordance but was retained due to its established association with resistance to tyrosine kinase inhibitors. Structural modeling revealed that mutations are concentrated in the tyrosine kinase domain, specifically in areas linked to the catalytic cleft and the ATP binding site. Substitutions such as G664R and T847P significantly alter the organization of hydrophobic interactions and local flexibility. Variants such as D816H and R686C were associated with the rearrangement of hydrogen bonds, modifying the network of contacts that sustains the native conformation. Overall, the mutations promote a reduction in the density of stabilizing contacts, suggesting an increase in conformational flexibility capable of favoring active receptor states even without ligand stimulation.

Conclusions

The integrated analysis allowed us to delineate a set of KIT gene variants with a high probability of functional impact on melanoma pathogenesis. The strategic location of these mutations in the tyrosine kinase domain and the predicted alterations in the network of structural interactions suggest that these polymorphisms may lead to constitutive activation of the PI3K/AKT and MAPK/ERK pathways. The agreement between multiple algorithms reinforces the robustness of prioritizing these top 10 variants. These findings provide fundamental theoretical support for target selection in experimental functional validation studies and may aid in the future identification of prognostic and therapeutic response markers in melanoma patients

Conclusion

The integrated analysis allowed us to delineate a set of KIT gene variants with a high probability of functional impact on melanoma pathogenesis. The strategic location of these mutations in the tyrosine kinase domain and the predicted alterations in the network of structural interactions suggest that these polymorphisms may lead to constitutive activation of the PI3K/AKT and MAPK/ERK pathways. The agreement between multiple algorithms reinforces the robustness of prioritizing these top 10 variants. These findings provide fundamental theoretical support for target selection in experimental functional validation studies and may aid in the future identification of prognostic and therapeutic response markers in melanoma patients.

EADV CONGRESS
VIENNA
30 SEP - 3 OCT 2026

Abstract N°: 3935

Bridging the Evidence Gap in Advanced MF/SS: Stage-Stratified Treatment Patterns and Outcomes from PROCLIPI

Abraham E. Bashir*[1], Pietro Quaglino[2], Sean Whittaker[3], Martine Bagot[4], Evangelia Papadavid[5], Emmanuella Guenova[6], Henry Miles Prince[7], Jose A Sanches[8], Octavio Servitje[9], Christiane Querfeld[10], Oleg Akilov[11], Arvind Arumainathan[12], Luke Bennett[13], Maxime Battistella[4], Kim Benstead[14], Emilio Berti[15], Marie Beylot-Barry[16], Anne-mari Busschots[17], Richard Cowan[18], Reinhard Dummer[19], Giles Dunnill[20], Teresa Estrach[21], Felicity Evison[22], Larisa Geskin[23], Joan Guitart[24], Emillia Hodak[25], Steve Horwitz[26], Constanze Jonak[27], Claus-Detlev Klemke[28], Robert Knobler[27], Pam Mckay[29], Marta Marschalkó[30], Cesare Massone[31], Rubeta Matin[32], Christina Mitteldorf[33], Pablo Ortiz-Romero[34], Nicola Pimpinelli[35], Ramon M Pujol[36], Annmari Ranki[37], Rudolf Stadler[38], Franz Trautinger[39], Maartin Vermeer[40], Rachel Wachsmuth[41], Sophie Weatherhead[42], Ulrike Wehkamp[43], Marion Wobser[44], Youn H Kim[45], Julia J Scarisbrick[1]

[1] University Hospitals Birmingham NHS Foundation Trust, University of Birmingham, Birmingham, United Kingdom
[2] University of Turin Medical School, Turin, Italy
[3] St Johns Institute of Dermatology, King's College London, London, United Kingdom
[4] Hôpital Saint Louis, Université Paris Cité, Paris, France
[5] National and Kapodistrian University of Athens, Athens, Greece
[6] Johannes Kepler University, Linz, Austria
[7] Peter McCallum Cancer Center, Melbourne, Australia
[8] University of Sao Paulo Medical School, Sao Paulo, Brazil
[9] Hospital Universitari de Bellvitge, Barcelona, Spain
[10] City of Hope Comprehensive Cancer Center, Duarte, United States
[11] UPMC Hillman Cancer Center, Pittsburgh, United States
[12] The Clatterbridge Cancer Centre, Liverpool, United Kingdom
[13] University Hospital Southampton, Southampton, United Kingdom
[14] Gloucestershire Hospitals NHS Foundation Trust, Gloucester, United Kingdom
[15] University of Milan, Milano, Italy
[16] Hospital Center University de Bordeaux, Bordeaux, France
[17] University Hospitals Leuven, Leuven, Belgium
[18] The Christie, Manchester, United Kingdom
[19] Universität Zürich, Zürich, Switzerland
[20] Bristol Royal Infirmary, Bristol, United Kingdom
[21] University of Barcelona, Barcelona, Spain
[22] University Hospitals Birmingham NHS Trust, Birmingham, United Kingdom
[23] Columbia University Medical Center, New York, United States
[24] Northwestern University, Chicago, United States
[25] Davidoff Cancer Center, Tel Aviv, Israel
[26] Memorial Sloan Kettering Cancer Center, New York, United States
[27] University of Vienna Medical School, Vienna, Austria
[28] Akademisches Lehrkrankenhaus der Universitat Freiburg, Karlsruhe, Germany

[29] Beatson West of Scotland Cancer Center, Glasgow, United Kingdom
[30] Semmelweis Medical University, Budapest, Hungary
[31] Galliera Hospital, Genoa, Italy
[32] Oxford University Hospitals NHS Trust, Oxford, United Kingdom
[33] HELIOS Klinikum Hildesheim Gmbh, Hildesheim, Germany
[34] University Complutense, Madrid, Spain
[35] University of Florence, Florence, Italy
[36] Hospital del Mar, Barcelona, Spain
[37] University of Helsinki, Helsinki, Finland
[38] University Hospitals of the Ruhr University of Bochum, Minden, Germany
[39] University Hospital of St. Pölten, St. Pölten, Austria
[40] Leiden University Medical Center, Leiden, Netherlands
[41] Taunton and Somerset NHS Foundation Trust, Exeter, United Kingdom
[42] Newcastle Upon Tyne NHS Trust, Newcastle, United Kingdom
[43] Medical School Hamburg, Hamburg, Germany
[44] University Hospital Wuerzburg, Wuerzburg, Germany
[45] Stanford University School of Medicine, Palo Alto, United States

Introduction
Advanced-stage mycosis fungoides/Sézary syndrome (MF/SS) encompasses skin tumours (stage IIB), erythroderma (stage III), and blood, nodal, or visceral involvement (stages IVA1–IVB). Management remains challenging due to disease heterogeneity and prior exposure to multiple therapies. We explored real-world, prospectively collected treatment data from the PROCLIPI study (NCT02848274) to characterise current practice and treatment effectiveness.

Materials and Methods
All advanced-stage patients with treatment data in PROCLIPI (n=509) were analysed: 33.4% (n=170) IIB, 12.6% (n=64) IIIA, 9.6% (n=49) IIIB, 29.3% (n=149) IVA1, 11.8% (n=60) IVA2, and 3.3% (n=17) IVB at diagnosis. In total, 2,472 treatment lines from 44 centres were cleaned and reconciled against site input data. Time to next systemic treatment (TTNsT) was calculated from initiation of first-line treatment to commencement of the next systemic therapy. Overall response rates (ORR; Complete Response+Partial Response) and treatment patterns were assessed across first- and second-line settings.

Results
At a median follow-up of 67 months, patients received a median of 3 treatment lines (range 1–19). At first line, 70% (n=358) received systemic therapy, 28% (n=142) skin-directed therapies (SDTs) only, and 2% (n=9) expectant management.

The most common first-line systemic therapies were extracorporeal photopheresis (ECP) (22.0%), methotrexate (16.8%), interferon-alpha (16.8%) and bexarotene (16.1%), together accounting for 71.7% of 410 first-line systemic treatments. Stratified by stage, the most frequent first-line therapies were local radiotherapy in IIB (n=68, ahead of all systemic options), methotrexate in IIIA–IIIB, ECP in IVA1, interferon-alpha in IVA2, and multi-agent chemotherapy (CHOP) in IVB. ECP achieved the longest median TTNsT of any first-line agent (19.0 months, IQR:7.1–28.7), followed by brentuximab vedotin (10.3, IQR:7.5–26.7), interferon-alpha (9.3, IQR:4.7–14.9) and bexarotene (8.8, IQR:5.6–15.3). The highest first-line ORRs were seen with gemcitabine (78%), romidepsin (60%) and brentuximab vedotin (60%).

Of first-line systemic treatments, 64% (262/410) were given in combination (178 with another systemic agent, 84 with an SDT), achieving a modestly higher ORR than monotherapy (46% vs 44%). 81% of patients reached a second line; the most common second-line therapies were bexarotene (17.6%), ECP (16.8%) and interferon-alpha (13.3%). Mogamulizumab achieved the highest second-line ORR (79%, n=29; median TTNsT 11.6 months),

whereas the gemcitabine response rate fell from 78% at first line to 38% at second line.

Conclusions

In advanced-stage MF/SS, treatment selection varies substantially by disease stage, reflecting the absence of a uniform standard of care. ECP demonstrated the most durable disease control at both first and second line, while mogamulizumab achieved the highest second-line response rate. Sequential treatment exposure and the prevalence of combination regimens preclude attribution of overall survival to individual agents; longer follow-up and confounder-adjusted analyses will be required. Our analysis underscores the complexity of disease management and supports the need for stage-adapted treatment strategies informed by real-world prospective evidence to optimise sequencing and outcomes in this challenging patient population.

EADV CONGRESS
VIENNA
30 SEP - 3 OCT 2026

Abstract N°: 3945

Subclinical PRO III Actinic Keratoses Detected by LC-OCT Before and After Tirbanibulin 1% Ointment: A Pilot Imaging Assessment

Luca Ambrosio*[1], Federico Garbarino[2], Giovanni Di Lella[2], Giovanni Pellacani[1], Claudio Conforti[3]

[1] Sapienza Università di Roma, Roma, Italy

[2] Idi Roma, Roma, Italy

[3] Link Campus University, Roma, Italy

Introduction

Actinic keratosis represents a continuum of clinically visible and subclinical keratinocyte dysplasia within chronically photodamaged skin. Subclinical atypical keratinocyte proliferations contribute to field cancerization and may persist despite apparent clinical clearance. Within the LC-OCT keratinocyte intraepithelial neoplasia scoring system, PRO III lesions are characterized by full-thickness epidermal disarrangement and cytological atypia detectable at quasi-histological resolution, without clinically evident morphology. Tirbanibulin may exert activity against these subclinical atypical proliferations through anti-proliferative and pro-apoptotic mechanisms. LC-OCT may therefore represent a useful non-invasive tool for evaluating subclinical disease burden and treatment response in field-directed therapies.

Materials and Methods

Three adult patients (mean age 71 years; 2 male, 1 female) with Olsen grade I–II actinic keratoses on chronically photodamaged face or scalp skin were prospectively evaluated. A standardized 25 cm^2 treatment field was examined by LC-OCT at baseline (D0) and day 57 (D57). PRO III lesions were identified according to established LC-OCT criteria, including full-thickness epidermal disarrangement and diffuse atypical keratinocyte patterns without clinically visible correlates. Lesions were enumerated per field by an investigator experienced in LC-OCT interpretation. All patients received tirbanibulin 1% once daily for 5 consecutive evenings according to the approved regimen. Changes in number and LC-OCT grading of PRO III lesions at D57 represented the primary imaging endpoint. Clinical actinic keratosis clearance and local skin reactions were assessed as secondary outcomes.

Results

Subclinical PRO III lesions were identified by LC-OCT in all three patients at baseline, with lesion counts ranging from 3 to 6 per treatment field. Despite the clinically low-grade appearance of visible lesions (Olsen grade I–II), LC-OCT revealed concomitant subclinical PRO III atypia in all evaluated fields, suggesting biologically advanced keratinocyte dysplasia not appreciable on clinical examination alone. At D57, all patients demonstrated reduction in PRO III lesion number compared with baseline, with decreases ranging from 50% to 83%. Reduction in epidermal architectural disorganization and partial restoration of regular keratinocyte layering were observed on follow-up LC-OCT imaging. Downgrading from PRO III to lower-grade atypia patterns was documented in two patients, while complete disappearance of detectable PRO III lesions within the evaluated field was observed in one patient. No progression toward higher-grade atypia or invasive features was identified during follow-up. Patients showing greater clinical clearance also demonstrated greater reduction of subclinical PRO III lesions on LC-OCT, suggesting possible correlation between visible and subclinical treatment response. Clinically visible

actinic keratosis clearance was achieved in two patients. Local skin reactions were mild and transient in all cases, with no treatment discontinuations.

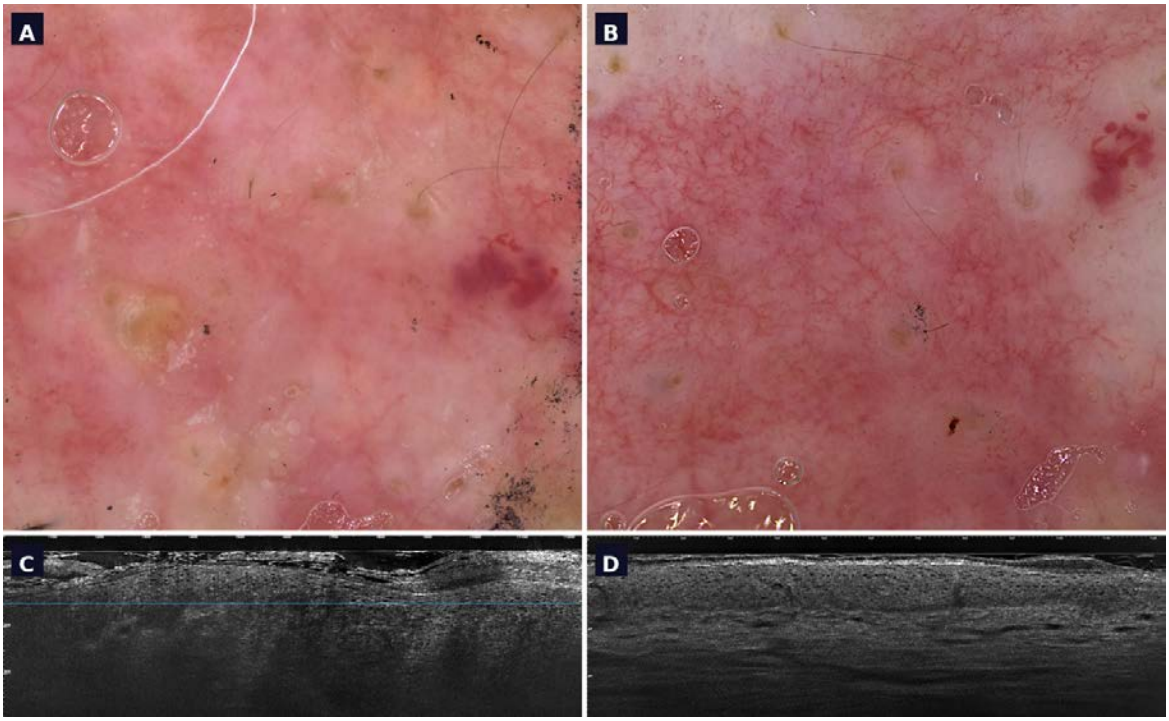

Figure 1. Dermoscopy and LC-OCT monitoring of a subclinical actinic keratosis before and after tirbanibulin 1% ointment (single 5-evening cycle). (A, B) Dermoscopy (polarised contact mode): diffuse background erythema with surface scale and focal yellowish hyperkeratotic areas at baseline (T0); marked regression of erythema, scale, and hyperkeratotic foci at 8-week follow-up (T2). (C, D) LC-OCT B-scan: at T0, epidermal dyskeratosis with loss of the normal layered architecture, blurring of the dermal–epidermal junction silhouette and papillary sprouting (pro-III); at T2, restoration of epidermal architecture with full recovery of the dermal–epidermal junction profile. AK, actinic keratosis; LC-OCT, line-field confocal optical coherence tomography; T0, baseline; T2, 8-week follow-up.

Conclusions

LC-OCT identified subclinical PRO III keratinocyte atypia in all evaluated patients and enabled non-invasive monitoring of imaging changes following tirbanibulin treatment. Despite the exploratory nature and small sample size, these findings support the potential utility of LC-OCT for detecting and quantifying biologically relevant subclinical field cancerization and for documenting early response of non-visible atypical keratinocyte proliferations to topical field therapy. The observed parallel reduction of clinical lesions and subclinical PRO III lesions further supports the potential role of tirbanibulin in targeting both visible and occult components of actinic field damage. Prospective studies incorporating LC-OCT as a quantitative endpoint in field cancerization trials are needed to establish standardized imaging criteria for subclinical treatment response assessment.

EADV CONGRESS
VIENNA
30 SEP - 3 OCT 2026

Abstract N°: 3948

QUALITY OF LIFE IN PATIENTS WITH MYCOSIS FUNGOIDES AND SEZARY SYNDROME IN SKIN OF COLOR: A CROSS SECTIONAL STUDY

Maitha Aljuwaied*[1]

[1] Rashid hospital, Sharjah, United Arab Emirates

Introduction
Mycosis fungoides (MF) and Sézary syndrome (SS) are the most common subtypes of cutaneous T-cell lymphomas, associated with chronic disease progression and significant impairment in quality of life (QoL). Patients frequently experience pruritus, pain, fatigue, and visible skin lesions, all of which contribute to psychological distress, social withdrawal, and reduced functional capacity. Despite advances in therapeutic options, the overall burden of these conditions—particularly in patients with skin of color—remains underexplored. This study aimed to assess QoL in patients with MF and SS and to identify key clinical and psychosocial factors influencing patient-reported outcomes.

Materials and Methods
A cross-sectional observational study was conducted among adult patients (≥18 years) with confirmed diagnoses of MF or SS attending Dubai Health facilities. Diagnosis was established through histopathology and immunophenotyping. Patients with concurrent malignancies or severe psychiatric conditions were excluded. Data were collected from electronic medical records and patient-reported outcome measures, including Skindex-29, EORTC QLQ-C30, and the Hospital Anxiety and Depression Scale (HADS). Collected variables included demographic data, disease stage, treatment history, symptom burden, and psychological status. Statistical analysis was performed using SPSS, incorporating descriptive statistics, comparative analyses, correlation testing, and multivariate regression to identify predictors of impaired QoL.

Results
A total of 137 patients were included in the study, comprising 128 patients with mycosis fungoides (MF) and 9 patients with Sézary syndrome (SS). Patients with SS demonstrated significantly lower QoL scores across multiple domains compared to those with MF. Increased symptom burden, particularly pruritus and fatigue, was strongly associated with poorer QoL outcomes. Advanced disease stage correlated with greater impairment in both functional and emotional domains. Additionally, higher levels of anxiety and depression were observed in patients with more severe disease and symptom burden. Multivariate analysis identified disease stage, symptom severity, and psychological distress as independent predictors of reduced QoL.

Conclusions
MF and SS have a substantial negative impact on patients' quality of life, extending beyond physical symptoms to include significant psychological and social consequences. Patients with SS and advanced-stage disease experience disproportionately greater impairment. These findings highlight the importance of integrating symptom control, psychological support, and

patient centered care into management strategies. Addressing these factors may improve overall patient outcomes and guide the development of more comprehensive care models for individuals with cutaneous T-cell lymphomas.

EA DV CONGRESS
VIENNA
30 SEP - 3 OCT 2026

Abstract N°: 3956

Real-world effectiveness of mogamulizumab and prognostic value of sustained response (ORR4) in mycosis fungoides and Sézary syndrome: the FIL-MOGA study

Gabriele Roccuzzo*[1], Paolo Fava[1], Serena Rupoli[2], Erika Morsia[2], Miriam Teoli[3], Pier Luigi Zinzani[4], Alessandro Pileri[5], Alessandra Tucci[6], Silvia Alberti Violetti[7], Cesare Massone[8], Adalberto Ibatici[9], Andrea Bernardelli[10], Luca Nassi[11], Sonya De Lorenzo[12], Patrizia Bernuzzi[13], Nicola Pimpinelli[14], Marco Paulli[15], Francesco Onida[16], Maria Cantonetti[17], Giacomo Loseto[18], Raffaele Filotico[19], Maria Pina Simula[20], Amalia Figuera[21], Mauro Salvatore Alaibac[22], Chiara Cavalloni[23], Alberti Fabbri[24], Agostino La Porta[25], Giorgio Priolo[25], Luigi Marcheselli[25], Pietro Quaglino[1]

[1] Department of Medical Sciences, Section of Dermatology, University of Turin, Turin, Italy
[2] Hematology Unit, AOU delle Marche, Ancona, Italy
[3] Porphyria and Rare Diseases Unit, San Gallicano Dermatological Institute-IRCCS, 00144 Rome, Italy, Rome, Italy
[4] IRCCS Azienda Ospedaliero-Universitaria di Bologna, Istituto di Ematologia "Seràgnoli" and Università di Bologna, Bologna, Italy
[5] Dermatology Unit, IRCCS Azienda Ospedaliero-Universitaria di Bologna, 40138, Bologna, Italy
[6] Department of Hematology, ASST Spedali Civili di Brescia, Brescia, Italy
[7] Dermatology Unit, IRCCS Ca'Granda - Ospedale Maggiore Policlinico, Milan, Italy
[8] Dermatology Unit, Galliera Hospital, Genoa, Italy
[9] Haematology and Transplant Unit, IRCCS Ospedale Policlinico San Martino, Genoa, Italy
[10] Hematology Unit, Department of Medicine, Azienda Ospedaliera Universitaria Integrata di Verona, Verona, Italy
[11] Hematology Unit, Careggi University Hospital, 50134, Firenze, Italy
[12] Hematology and T.M.O.-A.O.R.N. "S. G. Moscati", Avellino, Italy
[13] Hematology Unit, Department of Onco-Hematology, Guglielmo da Saliceto Hospital, Piacenza, Italy
[14] Health Science Department, University of Florence, Firenze, Italy
[15] Unit of Anatomic Pathology, IRCCS San Matteo Hospital Foundation, Pavia, Italy
[16] Haematology and BMT Unit, ASST Fatebenefratelli Sacco, University of Milan, Milano, Italy
[17] IRCC-IDI Istituto Dermopatico dell'Immacolata, Roma, Italy
[18] Hematology and Cell Therapy Unit, IRCCS Istituto Tumori "Giovanni Paolo II", Bari, Italy
[19] Section of Dermatology and Venereology, Department of Precision and Regenerative Medicine and Ionian Area (DiMePRe-J), University of Bari Aldo Moro, Bari, Italy
[20] Ematology and CTMO, Businco Hospital, Azienda Ospedaliera Brotzu, Cagliari, Cagliari, Italy
[21] Hematology With BMT Unit, A.O.U. "G. Rodolico-San Marco", Catania, Italy
[22] Dermatology Unit, Department of Medicine (DIMED), University of Padua, Padua, Padova, Italy
[23] Division of Hematology, Fondazione IRCCS Policlinico San Matteo, Pavia, Pavia, Italy
[24] Unit of Hematology, Azienda Ospedaliera Universitaria Senese and University of Siena, Siena, Italy
[25] Italian Lymphoma Foundation (FIL), Alessandria, Italy

Introduction

Conventional response endpoints do not adequately capture durable clinical benefit in mycosis fungoides (MF) and Sézary syndrome (SS), where responses are often heterogeneous and short-lived. Sustained response (ORR4) has been proposed as a clinically meaningful endpoint, but its prognostic role has not been established in real-

world settings and has never been specifically evaluated in patients treated with mogamulizumab. Moreover, large real-world data on the effectiveness of mogamulizumab remain limited. We therefore aimed to assess the clinical relevance of ORR4 as an on-treatment prognostic marker in a nationwide real-world cohort of MF/SS patients treated with mogamulizumab.

Materials and Methods

We conducted a retrospective multicentre study within the Italian Lymphoma Foundation (FIL) network, including 98 MF/SS patients treated with mogamulizumab between January 1st, 2021 and December 31st, 2023. ORR4 was analysed as a time-varying covariate (TVC) in Cox models. Survival outcomes were assessed using Kaplan–Meier estimates, 4-month landmark analyses, and multivariable models adjusted for age, sex, and stage. Additional exploratory analyses included treatment-free interval (TFI) and feasibility of allogeneic haematopoietic stem cell transplantation (allo-HSCT).

Results

Among 93 evaluable patients, ORR4 was achieved in 44 (47.3%). Median follow-up was 35 months. Overall, 43 death events were recorded, with a median OS of 37 months (95% CI 30–NA) and a 24-month OS of 72% (95% CI 62–80). In 4-month landmark analyses, ORR4 was associated with improved OS (24-month OS 76% vs 60%; p=0.006), PFS (24-month PFS 58% vs 35%; p=0.001), and TTNT (24-month TTNT 76% vs 47%; p=0.002) (Figures a-b-c). These findings were consistent in time-dependent models (OS HR 2.53, p=0.008; PFS HR 2.70, p=0.001; TTNT HR 3.04, p=0.003). In multivariable analyses, lack of ORR4 remained independently associated with worse OS (HR 3.18, p=0.002), PFS (HR 2.67, p=0.002), and TTNT (HR 4.27, p=0.001). Older age was associated with longer TTNT (HR 0.33, p=0.003). Baseline disease stage was not significantly associated with survival outcomes. Most adverse events were low to moderate severity, with skin disorders and infections being the most frequent. Skin adverse events were associated with higher ORR4 rates (70% vs 40%, p=0.017), but not with survival outcomes when modelled as time-dependent variables. Among patients discontinuing treatment (n=34), median TFI was 15 months, with a 2-year estimate of 42% (95% CI 21–62). Thirteen patients (13%) underwent allo-HSCT after a median of 20 months from treatment initiation.

Conclusions

This real-life experience represents one of the largest cohorts reported in Europe. Overall, outcomes were clinically meaningful, with indirect comparison suggesting more favourable effectiveness than that reported in clinical trials, despite less favourable baseline characteristics. ORR4 emerged as a robust, clinically applicable on-treatment prognostic marker, supporting its use for prognostication in routine practice.

(a) OS

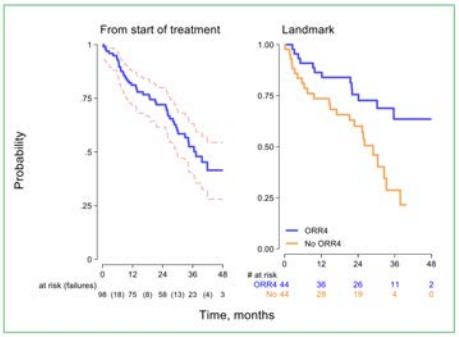

Landmark 4 months	N (events)	2y OS % (95%CI)	HR (95%CI)	p
	88 (37)	68 (56-77)	-	-
ORR4+	44 (13)	76 (59-86)	1.00	
No ORR4	44 (24)	60 (43-73)	2.59 (1.31-5.12)	0.006
No ORR4 vs ORR4+	TVC		2.53 (1.27-5.03)	0.008

(b) PFS

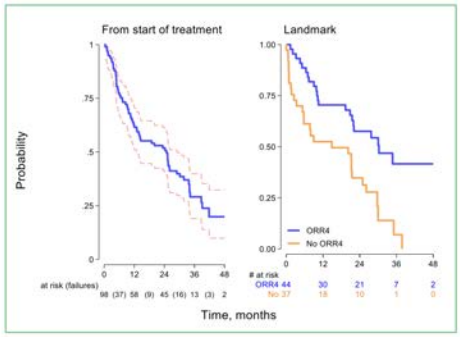

Landmark 4 months	N (events)	2y PFS % (95%CI)	HR (95%CI)	p
	81 (51)	47 (36-58)	-	-
ORR4+	44 (22)	58 (41-71)	1.00	
No ORR4	37 (29)	35 (20-50)	2.60 (1.48-4.58)	0.001
No ORR4 vs ORR4+	TVC		2.70 (1.52-4.78)	0.001

(c) TTNT

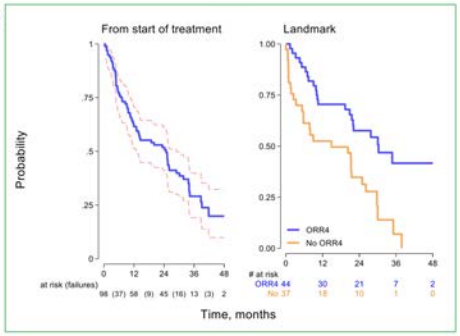

Landmark 4 months	N (events)	2y TTNT % (95%CI)	HR (95%CI)	p
	86 (33)	62 (50-72)	-	-
ORR4+	44 (11)	76 (59-87)	1.00	
No ORR4	42 (22)	47 (30-62)	3.18 (1.53-6.60)	0.002
No ORR4 vs ORR4+	TVC		3.04 (1.45-6.40)	0.003

EADV CONGRESS
VIENNA
30 SEP - 3 OCT 2026

Abstract N°: 3974

Photoprotection knowledge and practices among tattooed and untattooed beachgoers: a cross-sectional survey study

Daniel Nette*[1], Patrycja Rogowska[1], Krzysztof Pastuszak[2], Nicole Bulińska[3], Roman Nowicki[1], Martyna Sławińska[1]

[1] Department and Clinic of Dermatology, Venereology and Allergology, Faculty of Medicine, Medical University of Gdańsk, Department of Dermatology, Venereology and Allergology, University Clinical Center of Gdańsk, Gdańsk, Poland

[2] Faculty of Electronics, Telecommunication and Informatics, Gdańsk University of Technology, Laboratory of Translational Oncology, Intercollegiate Faculty of Biotechnology, Medical University of Gdańsk, Centre of Biostatistics and Bioinformatics, Medical University of Gdańsk, Gdańsk, Poland

[3] Department of Dermatology, Venereology and Allergology, University Clinical Center of Gdańsk, Gdańsk, Poland

Introduction

Tattooing has become an increasingly widespread form of body art and self-expression. Individuals with tattoos are generally advised to limit ultraviolet exposure and apply adequate sun protection to tattooed skin. Nevertheless, data on real-life photoprotective behaviours among tattooed individuals remain limited.

Materials and Methods

A cross-sectional questionnaire-based study was conducted among beachgoers at multiple seaside locations in northern Poland. Participants with and without tattoos were surveyed regarding sun exposure practices, use of photoprotective measures, and awareness of the risks associated with ultraviolet radiation. Additionally, the prevalence of self-reported tattoo reactions following sunlight exposure was assessed.

Results

Among 415 respondents, 208 (50.1%) reported having at least one tattoo. Individuals with tattoos more frequently declared complete lack of sunscreen use compared with non-tattooed participants (21.2% vs 15.5%). At the same time, they also more commonly reported using high-protection sunscreen with SPF50+ (46.2% vs 36.7%). The use of physical photoprotection measures remained similarly low in both groups. Overall knowledge regarding sun protection was relatively high, with a mean correct response rate of 82.9%; however, this contrasted with actual preventive practices, as only 30% of respondents reported year-round sunscreen use. Men above 45 years of age demonstrated the poorest results in both knowledge and photoprotective behaviours. Previous sun-induced skin reactions within tattoos were reported by 9.6% of tattooed participants.

Conclusions

The study revealed a substantial gap between awareness of photoprotection and implementation of effective sun-protective behaviours. Moreover, the tattooed population appeared polarized, with some individuals demonstrating inadequate protection while others reported particularly high use of SPF50+ products, potentially reflecting growing awareness among tattooed individuals. Future educational and preventive campaigns should focus on tattooed subpopulations at risk of insufficient photoprotection, especially older men.

EADV CONGRESS
VIENNA
30 SEP - 3 OCT 2026

Abstract N°: 3992

Two cases of melanoma arising in tattoos

José Manuel Sánchez Sánchez*[1], Lucía García Almazán[1], Marina Torrent García[1], Alejandro Castillo Botero[1], Francisco Blasco Torres[1], Celia Campoy Carreño[1], Fernando Javier Allegue Gallego[1]

[1] Hospital General Universitario Santa María del Rosell, Cartagena, Spain

Introduction

It is important to note that the proportion of the population with tattoos has been increasing in recent years, with an estimated prevalence of 10–36% of the population currently having tattoos. Although the evidence is limited, several causes of malignancy associated with tattoos have been proposed: local trauma from the needle, the inflammatory response to the ink, the composition of the ink, or the by-products formed following UV exposure of the ink. This potential carcinogenicity is currently a matter of debate; however, there is no dispute that tattoos act as a confounding factor when assessing melanocytic lesions suspected of malignancy, altering their clinical presentation and dermatoscopic findings. In this poster, we present two cases of melanoma arising in tattoos, aiming to demonstrate the possible relationship between these two.

Materials and Methods

Description of two cases of melanoma arising in a tattoo, detailing their clinical presentation and pathological findings following a retrospective review of our hospital's database from 2020 to 2026.

Results

The first case concerns a 50-year-old man with phototype I who presented with a pigmented lesion that had been present for four months at the edge of a tattoo he had had done in his youth. On examination, a 1 cm blackish papule was observed on the right shoulder, situated on one of the lines of the black ink tattoo. Dermoscopy revealed a disorganised black patch with a brown periphery, alongside chrysalids and areas of bluish-whitish veiling. Pathological examination revealed a 7 mm **ulcerated nodular melanoma** with a Breslow depth of 1.6 mm, a negative sentinel lymph node and no evidence of metastasis to other organs (pT2bN0M0, stage IIA). The patient is currently undergoing annual check-ups and shows no evidence of recurrence or metastasis after four years of follow-up.

The second case concerns a 45-year-old woman with phototype II who presented with a pigmented lesion that had been present for six months over a tattoo done 10 years ago. On examination, a 6 mm greyish-brown papule was observed on the left chest, located at the periphery of a black ink tattoo. Dermoscopy revealed a slightly atypical brown reticulum alongside fine telangiectasias and punctate vessels. Histopathological examination revealed a **superficial spreading melanoma** with no evidence of infiltration and normal regional lymph node status (pTisN0M0, stage 0). The patient has been under our follow-up for 6 months, with no signs of recurrence or metastasis observed.

Conclusions

Over the past five and a half years, our hospital has seen two cases of melanoma arising from tattoos, one nodular and the other superficial. We emphasise the need for further studies to establish the link between tattoos and the development of melanoma, as this is a rare finding based on our case series.

EADV CONGRESS
VIENNA
30 SEP - 3 OCT 2026

Abstract N°: 4036

When Negative is Not Enough: Diagnostic Lag and Stage Migration from False-Negative FNA in Metastatic Melanoma

Paul Cooper*[1], Ao Lik Lee[1], Molly Dempsey[1], Patrick Ormond[1]

[1] St. James's Hospital, Department of Dermatology, Dublin, Ireland

Introduction
Ultrasound-guided fine-needle aspiration (US-guided FNA) is widely used to investigate suspected metastatic melanoma. However, a negative result may not reliably exclude metastasis, risking diagnostic delay, stage migration and altered systemic treatment eligibility.

Objectives

To evaluate the diagnostic accuracy and downstream clinical impact of US-guided FNA for suspected metastatic melanoma in a tertiary referral centre, with particular focus on false-negative results.

Materials and Methods
We performed a retrospective cohort study of consecutive patients undergoing US-guided FNA for suspected metastatic melanoma between 2020 and 2026 in a tertiary Irish centre (n=67). The index test was US-guided FNA cytology. A composite reference standard was used: histopathology from core biopsy/excision and/or sentinel lymph node biopsy, or repeat sampling with subsequent confirmation, supported by clinicoradiologic follow-up where applicable. Primary outcomes were sensitivity, specificity, positive predictive value (PPV), negative predictive value (NPV), and time to definitive diagnosis. Secondary outcomes were melanoma stage migration and change in management attributable to false-negative FNA.

Results
Of 67 US-guided FNAs, 38 were true positives, 18 true negatives, 8 false negatives, and 0 false positives, with a further 3 results inconclusive (1 suspicious, 2 non-diagnostic) and excluded from accuracy calculations, giving sensitivity 82.6%, specificity 100%, PPV 100%, and NPV 69.2%. Median time from initial FNA to definitive malignant diagnosis in false-negative cases was 37 days (range 0–108). Three of eight false-negative cases (37.5%) were upstaged following confirmatory sampling and had a clinically meaningful change in management, including escalation to systemic immunotherapy. Interpretation of downstream impact is limited by the small number of false-negative events.

Conclusions
In this cohort, US-guided FNA was an excellent rule-in test for metastatic melanoma but had limited rule-out value (NPV 69.2%). A negative US-guided FNA in a clinically or sonographically suspicious lesion should prompt early confirmatory tissue sampling (e.g., core biopsy or excision) to minimise diagnostic delay and potential stage migration.

EADV Congress 2026, VIENNA
30 SEPTEMBER - 03 OCTOBER 2026
POWERED BY M-ANAGE.COM

EADV CONGRESS
VIENNA
30 SEP - 3 OCT 2026

Abstract N°: 4043

Overall Survival and Characteristics of Early Stage Mycosis Fungoides Patients Refractory After Three Lines of Systemic Therapy

Yunus Toso*[1, 2], Madeleine Lachance[1, 3], Ram-Wolff Caroline[1], Maelle Dumont[1], Alizee Bozonnat[1, 4], GILLES BATTESTI[1, 4], Baptiste Louveau[4, 5, 6], Fanélie Jouenne[4, 5, 6], Maxence Mancini[4, 5, 6], Samia Mourah[4, 5, 6], Helene MOINS-TEISSERENC[4, 5, 7], Martine Bagot Robin[1, 4, 5], Maxime Mouthon[8], Jean David Bouaziz[1], Battistella Maxime[4, 5, 8], Adele de Masson[1, 4, 5], Jeremie Delaleu[1, 4, 5]

[1] Department of Dermatology, Saint-Louis Hospital, Assistance Publique-Hôpitaux de Paris, Centre coordinateur national du réseau de cancers rares INCa Lymphomes Cutanés, Department of Dermatology and Venereology, Bursa Uludag University, Bursa, Türkiye, Paris, France

[2] Bursa Uludag University, Department of Dermatology and Venereology, Bursa, Türkiye

[3] Department of Dermatology, Saint-Sacrement Hospital, CHU de Québec, Québec, Canada

[4] INSERM U1342, Paris, France

[5] Université Paris Cité, Paris, France

[6] Department of Tumor Genomics and Pharmacology Tumors, Saint-Louis Hospital, Assistance Publique-Hôpitaux de Paris, Paris, France

[7] Hematology and Biology Laboratory; Saint-Louis Hospital, Assistance Publique-Hôpitaux de Paris, France, Paris, France

[8] Department of Pathology, Saint-Louis Hospital, Assistance Publique-Hôpitaux de Paris, Paris, France

Introduction

Mycosis fungoides (MF) is the most common primary cutaneous lymphoma.[1] Although allogeneic stem cell treatment (allo-SCT) has demonstrated benefit in advanced-stage MF[2,3], its role in early-stage refractory disease remains undefined. Recently the European Society for Blood and Marrow Transplantation Practice Harmonisation and Guidelines Committee recommended that allo-SCT may be discussed in early MF refractory to several systemic therapies.[4] However to our knowledge, no published data support this strategy. We therefore aimed to evaluate overall survival (OS) and characteristics of this specific subset of early stage MF patients who were refractory after three lines of systemic therapy.

Materials and Methods

Clinical and demographic data were extracted from the institutional registry database (Table). Inclusion criteria were i) early stage (IA-IIA) MF at the initiation of third systemic treatment line, ii) documented refractory disease after at least three lines of systemic therapy and iii) progressed to advanced stage (IIB-IVB) or have at least five years of follow-up without progression. Refractory disease defined as the absence of complete or partial clinical response after the third systemic treatment line. The study period extended from July 2006 to July 2025. Patients were excluded if the diagnosis of MF was unconfirmed, relevant clinical data were incomplete, or if advanced-stage disease was present before the third systemic line.

Results

In our institutional registry database we had 448 patients who were early stage at diagnosis and had at least 5 year follow up or progressed to advanced stage before. In the entire population of patients 17 patients met our

criterias. For the cohort of study median follow up period was 102.27 months **(Table)**. Male/female ratio was 10/7. Median age at diagnosis was 48.98 (with a range of 18-75). Classic/folliculotropic variant ratio was 8/9. Except one stage 1a patient, all others were in stage 1b at the diagnosis. The total number of systemic treatments ranged in 3-13. Three patient underwent allo-SCT. Median OS from diagnosis was 129.4 months (83.5-165.4 months CI 95%), with a 5-year OS of 88.2 % **(Figure)**. Progression to advanced-stage occurred in 71% of patients in a median delay of 16 months after third line initiation, and 59% of them also developed large cell transformation during follow-up. Median OS after progression to advanced-stage was 21.1 months (CI: 0.4-57.8) and median OS after LCT was 73.2 months (CI:3.2-78.1). Median time to first systemic treatment line was 9.5 months (range 0-108 months).

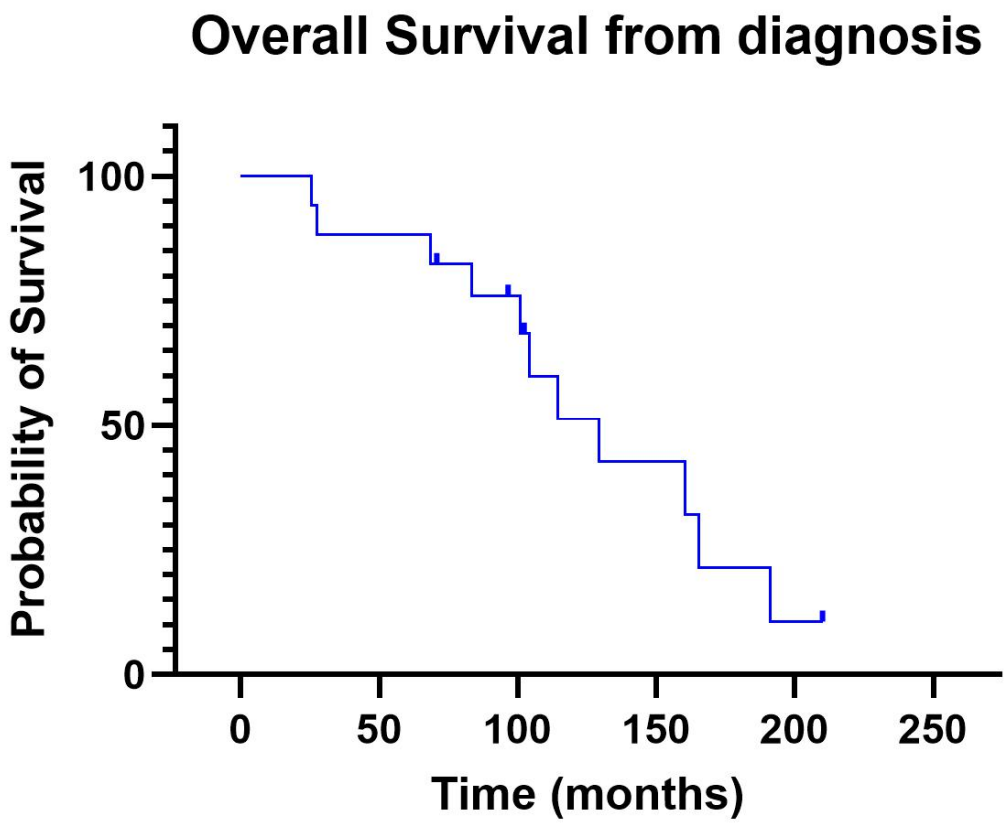

Conclusions

This study describes a distinct subgroup of patients with early MF who were refractory after at least three lines of systemic therapy. Notably, the vast majority of patients eventually progressed to advanced-stage during follow-up, whereas typically 20-30 % early stage MF patients progress to advanced stage disease.[5] Morever median OS observed in this refractory group (129.4 months) was substantially shorter than the survival generally reported in early-stage MF populations which often exceeds 20 years.[5,6] Limitations of this study include its retrospective monocentric design and the limited number of patients. Validation in larger multicenter cohorts will be required to better define prognostic factors associated with adverse outcomes in this population.

Overall, these findings support the recognition of refractory early-stage MF as a distinct high-risk clinical entity with poorer long-term outcomes despite initially limited-stage disease. They also support considering earlier discussion of intensified therapeutic strategies, including allo-SCT, in selected patients.

Male/Female	10/7
Median Age at Diagnosis	48.98 (18-75)
Classic/Folliculotropic MF	8/9
Initial Stage (IA/IB/IIA)	1/16/0
Status at last follow-up (Alive/Dead)	6/11
Median follow-up (months)	102.27
Total Number of Systemic Treatments from diagnosis to last follow up (including bexarotene, methotrexate, interferon, acitretin, brentuximab, mogamulizumab, lacatumab, alemtuzumab, gemcitabin, doxorubicine, CHOP, ifosfamide-etoposide, romidepsin, pembrolizumab, atezolizumab, alemtuzumab, ECP, other polychemotherapies and allo-SCT)	3-13
Median Overall Survival from Diagnosis	129.4 months (CI:83.5-165.4)
5 Year Overall Survival from Diagnosis	88.2 %
Median Overall Survival from 3rd systemic line of treatment	69.5 months (CI:31.2-72.47)
5 Year Overall Survival from 3rd systemic line of treatment	70.5 % (at maximum)
Progression to advanced stage	12 (71%)
Median Survival after Progression to advanced stage	21.1 months (CI: 0.4-57.8)
Large cell transformation during follow-up (LCT) (n;%)	10 (59%)
Early LCT (< 2 years after diagnosis) (n;%)	3 (17.6%)
Median Survival after LCT	73.2 months (CI:3.2-78.1)
Median Time to First Systemic Treatment	9.5 months (0-108)

Table: Clinical Characteristics of Cohort

EADV CONGRESS
VIENNA
30 SEP - 3 OCT 2026

Abstract N°: 4064

Noninvasive technologies for understanding BCC pathogenesis

Kevin Jacobsen*[1], Peter Alshede Philipsen[1], Vinzent Kevin Ortner[1], Niels Morling[2], Jeppe Dyrberg Andersen[2], Merete Haedersdal[1, 3]

[1] University of Copenhagen, Department of Dermatology, Bispebjerg Hospital, Copenhagen, Denmark

[2] University of Copenhagen, Faculty of Health and Medical Sciences, Section of Forensic Genetics, Department of Forensic Medicine, Copenhagen, Denmark

[3] Department of Clinical Medicine,University of Copenhagen, Copenhagen, Denmark

Introduction
Basal cell carcinoma (BCC) is the most common skin cancer. The molecular pathways that drive BCC pathogenesis and their association with subclinical tumor thickness remain poorly understood. The combination of noninvasive technologies, such as optical coherence tomography (OCT) and mRNA from tape strips could provide a better understanding. This study aimed to explore the association between subclinical BCC thickness and biologically relevant differentially expressed genes (DEGs) and pathways.

Materials and Methods
OCT-derived vertical BCC thickness was measured in 53 tumors using proprietary software (VivoSight), and mRNA sequencing was performed on tape strips collected from the same lesions. Tumors were divided into two groups based on BCC thickness using the median value as a cutoff. Associations with mRNA expression levels were analyzed using edgeR and reported as DEGs with a false discovery rate < 0.1. Pathways were further investigated using online enrichment tools and databases (Enrichr, Kyoto Encyclopedia of Genes and Genomes [KEGG]).

Results
BCCs thicker than 0.5 mm (n = 32/53) were associated with 52 upregulated and 3 downregulated genes. Among these genes, C7orf25, GGTLC2, and ACTL10 had the highest positive expression levels, whereas MMP3, HBB, and DEFB4A showed the largest negative expression levels (log fold change range: −4.62 to 4.93). Pathways included lipid metabolism (regulation of lipolysis in adipocytes and biosynthesis of unsaturated fatty acids) and signaling pathways, such as cyclic adenosine monophosphate (cAMP) signaling.

Conclusions
This exploratory study identified DEGs and pathways in BCCs using noninvasive technologies. Thicker BCCs may have distinct transcriptomic profiles involving lipid metabolism and signaling pathways important in pathogenesis.

EADV CONGRESS
VIENNA
30 SEP - 3 OCT 2026

Abstract N°: 4074

Incomplete reporting and interobserver variability of histopathological risk factors in cutaneous squamous cell carcinoma: implications for identifying high risk patients

Olivia Steijlen*[1], Barbara Rentroia Pacheco[1], Jeffrey Damman[2], Marlies Wakkee[1], Antien Mooyaart[2]

[1] Erasmus MC Cancer Institute, University Medical Center Rotterdam, Department of Dermatology, Rotterdam, Netherlands

[2] Erasmus MC University Medical Center Rotterdam, Department of Pathology, Rotterdam, Netherlands

Introduction

Metastasis in cutaneous squamous cell carcinoma (CSCC) is rare, and identifying patients at risk remains challenging. Current staging systems, including those of the American Joint Committee on Cancer (AJCC, 8th edition) and Brigham and Women's Hospital (BWH), show limited accuracy in predicting metastasis. The recently developed Erasmus MC (EMC) model has demonstrated improved prognostic performance by combining clinical variables with three histopathological variables: differentiation grade, perineural or lymphovascular invasion (PNI or LVI), and tissue involvement (anatomical depth of invasion). However, all these risk systems depend on histopathological variables, which may be subject to interobserver variability and influence risk classification. This study aims to compare histopathological risk factors recorded in routine pathology reports with those obtained by expert revision of the same specimens, and to determine how such variability affects staging according to established staging systems and the EMC model.

Materials and Methods

This nested case-control study used Dutch nationwide registry data to identify patients with a first CSCC diagnosed between 2017 and 2018 and follow-up until 2023. The study included 185 patients who developed metastasis and 185 non-metastatic controls. Details of this cohort were previously described in the Dutch Squamous Cell Carcinoma and Metastasis (D-SQUAME) study. Histopathological risk factors, including depth of invasion, tissue involvement, differentiation grade, PNI, and LVI, were extracted from pathology reports. Formalin-fixed paraffin-embedded tumor blocks from excision of the primary tumor of both cases and controls were retrieved from the nationwide pathology archives. Two dedicated dermatopathologists independently reviewed newly prepared hematoxylin-eosin slides using clear definitions. Observer agreement was assessed using weighted Cohen's κ for ordinal variables and intraclass correlation coefficients (ICC) for absolute agreement. Harrell's C-index was used to calculate the performance of the EMC model score based on pathology reports before and after central revision.

Results

Reporting of histopathological risk factors in routine pathology reports was incomplete, in 72% for tissue involvement followed by ; 27% for LVI, 25% for PNI and 27% for differentiation grade. Compared with expert revision, differentiation grade showed poor agreement (weighted k 0.42, 95% CI 0.33-0.51), while tissue involvement showed limited agreement (weighted κ 0.53, 95% CI 0.38-0.65). Agreement for PNI and LVI was good, with weighted κ values of 0.84 (95% CI 0.73-0.96) and 0.84 (95% CI 0.68-0.99); however, both features were rare. Figure 1 illustrates the agreement between the reported and revised categorical risk factors. Table 1 shows moderate to good agreement between staging and EMC model risk classification before and after expert revision. After revision, AJCC risk classification changed in both directions: 8% (12/149) of low-risk patients were upstaged to T3–T4, while 30% of high-risk patients (19/64) were downstaged to T1-T2. Similar changes were observed for BWH, 3% (6/211) upstaged to T2b–T3, and 27% (9/33) downstaged to T1-T2a. The EMC model showed

consistent c-indices of 0.71 (0.66-0.76) based on pathology reports and 0.72 (0.68-0.76) based on expert revision.

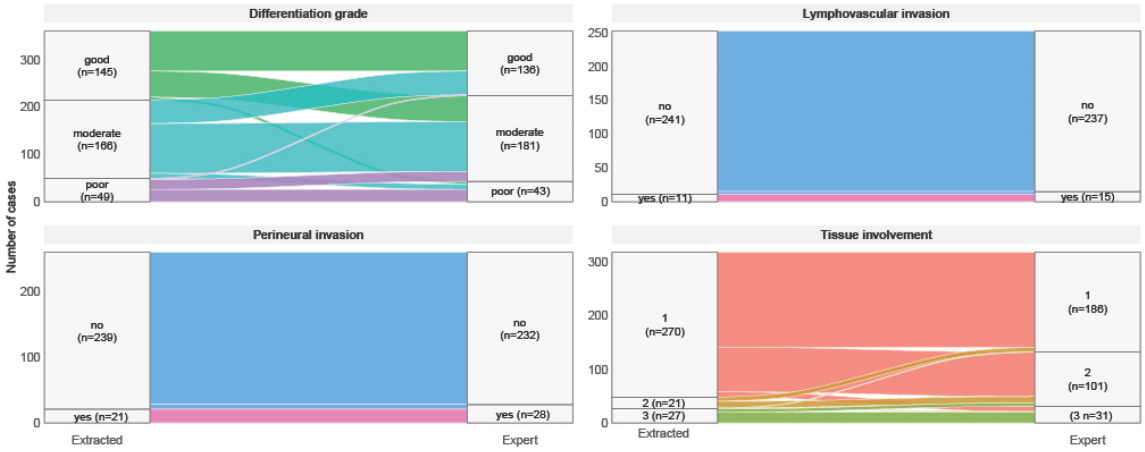

Figure 1. Agreement between routine pathology reports (extracted) and expert revision for histopathological risk factors in cutaneous squamous cell carcinoma. For tissue involvement, 1 indicates dermis, 2 subcutaneous fat, and 3 beyond subcutaneous fat.

Conclusions

This nationwide study shows that routine pathology reporting is often incomplete, particularly for tissue involvement, limiting the use of risk classification tools. Expert revision changed AJCC and BWH staging in a subset of patients, mainly through downstaging, but had little impact on EMC model discrimination. These findings highlight the importance of synoptic reporting in CSCC and support the need for more reproducible risk factors, potentially through computational pathology or novel biomarkers, especially when not all histopathological variables can be reliably assessed.

2017-2018 cohort (n=370)					
Staging variables		*Pathology report (n=370)*	*Revised (n=370)*	Number of complete sets	Weighted κ / intraclass correlation coefficient
AJCC-8 staging	T1	136 (37%)	182 (49%)	N=213	0.74 (0.65-0.83)
	T2	24 (6.5%)	45 (12%)		
	T3	69 (19%)	66 (18%)		
	T4	0 (0%)	0 (0%)		
	Unknown	141 (38%)	77 (21%)		
BWH staging	T1	154 (42%)	168 (45%)	N= 244	0.80 (0.74-0.86)
	T2a	70 (19%)	92 (25%)		
	T2b	35 (9.5%)	37 (10%)		
	T3	2 (0.5%)	1 (0.3%)		
	Unknown	109 (29%)	72 (19%)		
EMC model score		1.3 (0.7, 3.1)	1.3 (0.7, 3.6)	N=240	0.78 (0.73-0.83)
Unknown		112 (30%)	76 (21%)		

Table 1. Agreement between routine pathology reports (extracted) and expert revision for staging and the EMC model based on histopathological risk factors in cutaneous squamous cell carcinoma.

EA DV CONGRESS
VIENNA
30 SEP - 3 OCT 2026

Abstract N°: 4085

The costs for skin cancer care in Germany are still rising: Analysis of volumes and predictors

Andrea Gottschalk*[1], Ricarda Graf[1], Katharina Müller[1], Kristina Hagenström[1], Matthias Augustin[1]

[1] Institute for Health Services Research in Dermatology and Nursing (IVDP), German Center for Health Services Research in Dermatology (CVderm), University Medical Center Hamburg-Eppendorf, Hamburg, Germany

Introduction
Skin cancer represents a growing healthcare and economic burden in Germany. Longitudinal real-world data on healthcare utilisation, treatment costs, and the impact of statutory skin cancer screening remain limited.

Materials and Methods
We analysed anonymised German statutory health insurance claims data extrapolated to the national population between 2016 and 2022. Outcomes included prevalence, incidence, healthcare utilisation, inpatient costs, pharmaceutical expenditures, and participation in statutory skin cancer screening for malignant melanoma (MM), non-melanoma skin cancer (NMSC), melanoma in situ, and actinic/in situ lesions. Incident cohorts from 2018 and 2020 were compared following an eight-quarter washout period.

Results
Between 2016 and 2022, prevalence of MM increased from 147,484 to 158,123 cases, while prevalence of NMSC increased from 838,160 to 962,886 cases. Disease burden increased markedly with age, particularly in individuals aged ≥60 years. Substantial pharmaceutical expenditures were observed across all analysed skin cancer entities.

Total inpatient expenditures increased across all analysed diagnoses. For MM, cumulative inpatient costs increased from €2.32 million in the 2018 incident cohort to €2.59 million in the 2020 cohort. For NMSC, inpatient costs increased from €3.98 million to €4.01 million. Mean inpatient costs per patient increased from €3,708 to €4,512 for MM and from €2,877 to €3,370 for NMSC. Mean length of hospital stay remained high, ranging from 5.2 to 7.7 days across analysed skin cancer entities.

Participation in statutory skin cancer screening declined from approximately 16% before the COVID-19 pandemic to 13–14% in 2022. Patients in the 2018 incident cohort with preceding statutory skin cancer screening were associated with lower inpatient costs and shorter length of hospital stay compared with unscreened patients (MM: €3,286 vs. €3,990; 5.3 vs. 9.3 days; NMSC: €2,723 vs. €2,972; 5.0 vs. 5.9 days).

Conclusions
Skin cancer care in Germany is characterised by increasing prevalence and rising inpatient and pharmaceutical expenditures. Major cost drivers included the growing number of affected patients, increasing disease burden in older populations, and high healthcare resource utilisation. Patients with preceding statutory skin cancer screening showed lower inpatient costs and shorter hospital stays, indicating potential health-economic benefits of early detection.

EADV Congress 2026, VIENNA
30 SEPTEMBER - 03 OCTOBER 2026
POWERED BY M-ANAGE.COM

EADV CONGRESS
VIENNA
30 SEP - 3 OCT 2026

Abstract N°: 4115

FACIAL NEVUS COUNT AS A PROXY FOR TOTAL BODY NEVUS BURDEN: RESULTS FROM THE MULTICENTER PRI-TBNC STUDY

Roberta Giuffrida*[1], Iris Zalaudek[2], Giuseppe Micali[3], Francesco Lacarrubba[3], Anna Elisa Verzì[3], Franco Rongioletti[4], Stefania Guida[4], Maria Michela Lauriola[4], Maria Concetta Fargnoli[5], Andrea D'Arino[5], Rosella Gallo[6], Giovanni Ghigliotti[6], Giuseppe Argenziano[7], Eugenia Veronica Di Brizzi[7], Pietro Quaglino[8], Gabriele Roccuzzo[8], Emi Dika[9], Leonardo Veneziano[9], Alessandro Borghi[10], Cristina Bertoli[10], Caterina Foti[11], Lucia Lospalluti[11], Emanuele Cozzani[12], Ilaria Trave[12], Giovanni Pellacani[13], Flavia Persechino[13], Claudio Conforti[14], Piergiacomo Calzavara Pinton[15], Simone Soglia[15], Antonio Costanzo[16], Mario Valenti[16], Pietro Rubegni[17], Linda Tognetti[17], Ketty Peris[18], Gerardo Palmisano[18], Eleonora Bearzi[2], Rosanna Rita Satta[19], Angelo Valerio Marzano[20], Gianluca Nazzaro[20], Silvia Mariel Ferrucci[20], Silvia Alberti Violetti[20], Giuseppe Stinco[21], Enrico Zelin[21], Fabrizio Guarneri[1]

[1] Department of Clinical and Experimental Medicine, University of Messina, Messina, Italy

[2] Dermatology Clinic, Hospital Maggiore of Trieste, University of Trieste, Trieste, Italy

[3] Dermatology Clinic, University of Catania, Catania, Italy

[4] Vita-Salute San Raffaele University, Milan, Italy

[5] UOSD CTC, Biostatistics and Bioinformatics, Scientific Direction, San Gallicano Dermatological Institute, IRCCS, Rome, Italy

[6] Section of Dermatology, Department of Health Sciences, University of Genoa, IRCCS-Hospital Policlinico San Martino, Genoa, Italy

[7] Dermatology Unit, University of Campania Luigi Vanvitelli, Naples, Italy

[8] Dermatologic Clinic, Department of Medical Sciences, University of Turin, Turin, Italy

[9] Department of Medical and Surgical Sciences (DIMEC), University of Bologna; Oncologic Dermatology Unit, IRCCS Azienda Ospedaliero-Universitaria di Bologna, Bologna, Italy

[10] Section of Dermatology and Infectious Diseases, Department of Medical Sciences, University of Ferrara, Ferrara, Italy

[11] Section of Dermatology and Venereology, Department of Precision and Regenerative Medicine and Ionian Area (DiMePRe-J), University of Bari, Bari, Italy

[12] Section of Dermatology, Department of Health Sciences (DiSSal), University of Genoa, Genoa, Italy; IRCCS, Ospedale Policlinico San Martino, Genoa, Italy

[13] Unit of Dermatology, Department of Clinical Internal, Anesthesiological and Cardiovascular Sciences, Sapienza University of Rome, Rome, Italy

[14] Department of Life Science, Health, and Health Professions, Link University of Rome, ROME, Italy

[15] Department of Dermatology, University of Brescia, Brescia, Italy

[16] Dermatology Unit, Humanitas Research Hospital - IRCCS, Rozzano; Department of Biomedical Sciences, Humanitas University, Pieve Emanuele, Milan, Italy

[17] Dermatology Unit, Department of Medical, Surgical and Neurological Sciences, University of Siena, Siena, Italy

[18] Dermatologia, Dipartimento Universitario di Medicina e Chirurgia Traslazionale, Università Cattolica del Sacro Cuore, Rome, Italy; Dermatologia, Dipartimento Scienze Mediche e Chirurgiche, Fondazione Policlinico Universitario A. Gemelli IRCCS, Rome, Italy

[19] Department of Medicine, Surgery and Pharmacy, University of Sassari, Sassari, Italy

[20] Dermatology Unit, Fondazione IRCCS Ca' Granda Ospedale Maggiore Policlinico, Milan, Italy

[21] Institute of Dermatology, Department of Medicine, University of Udine, Udine, Italy

Introduction

High total body nevus count (TBNC) is among the strongest phenotypic risk factors for cutaneous melanoma. However, accurate TBNC assessment requires total body skin examination (TBSE), which is not consistently performed in routine clinical practice. Previous studies demonstrated that nevus counts on selected anatomical sites, particularly the upper limbs, may serve as surrogate markers of overall nevus burden and melanoma risk. In the era of increasing facial imaging use in dermatology, facial nevus count may represent a practical proxy for TBNC.

The study aims to evaluate the association between TBNC and facial nevus count together with additional variables including sex, age, eye color, phototype, body mass index, body surface area, history of sunburns before the age of 20 years, and personal or family history of melanoma or other skin cancers. Furthermore, we aimed to develop a predictive model estimating the probability of having ≥50 nevi based on these variables.

Materials and Methods

This observational, prospective, investigator-initiated, non-profit multicenter study involved 16 Italian dermatology centers. Subjects aged ≥18 years attending outpatient clinics for dermatologic evaluation were consecutively enrolled. Patients refusing participation were excluded.

Results

A total of 2,131 subjects were included, with balanced sex distribution (50.2% men and 49.8% women). Mean age was 51.8 ± 16.7 years and mean BMI was 24.4 ± 4.2. Brown eyes was the most represented eye color (59.9%), while Fitzpatrick phototypes II and III accounted for most participants (48.0% and 45.7%, respectively). A history of sunburns before the age of 20 years was reported in 74.4% of subjects. Personal history of melanoma was present in 28.2% of participants, whereas 16.8% reported a family history of melanoma.

Mean facial nevus count was 2.73 ± 3.66 (median 2; IQR 0–4), with 26.1% of subjects presenting ≥5 facial nevi. Arm nevus count ≥20 was observed in 29.2% of participants, while 36.5% had a TBNC ≥50.

A significant correlation between facial nevus count and TBNC was observed ($p<0.001$). ROC curve analysis demonstrated good predictive performance of facial nevus count for identifying subjects with TBNC ≥50 (AUC=0.766). A cutoff value of ≥3 facial nevi provided the best balance between sensitivity, specificity, and diagnostic accuracy for predicting TBNC ≥50.

Multivariate analysis confirmed facial nevus count as an independent predictor of TBNC ≥50 (OR 43.93, 95% CI 32.76–58.92; $p<0.001$), together with younger age, history of sunburns before the age of 20 years, and family or personal history of skin cancer. Based on these variables, a multivariable logistic regression model was developed to estimate the probability of TBNC ≥50.

Conclusions

Although TBSE remains the gold standard for assessing total body nevus burden and melanoma risk, it requires expertise and may be time-consuming in routine clinical practice. Our findings suggest that facial nevus count may represent a practical surrogate marker for identifying individuals with high TBNC. Facial evaluation can be easily performed without requiring patients to undress and may be facilitated by the increasing availability of facial imaging technologies.

The proposed predictive model combines facial nevus count with a limited number of readily available clinical variables and may support identification of individuals at increased likelihood of high TBNC and potentially higher melanoma risk.

Facial nevus count appears to be a reliable proxy marker of total body nevus burden. The proposed predictive model may represent a simple, rapid, and accessible triage tool to identify individuals who could benefit from TBSE and melanoma-oriented surveillance. This approach could potentially

be adopted not only by dermatologists, but also by general practitioners and other healthcare professionals involved in skin cancer prevention and early melanoma detection.

EA DV CONGRESS
VIENNA
30 SEP - 3 OCT 2026

Abstract N°: 4175

Germline Mutational Landscape of Familial and Multiple Melanoma: Insights from Variant Co-occurrence and Clustering Analysis

Sara Triolo*[1], Mirco Mastrangelo[1], Manfredo Bruni[1], Luisa Mattoscio[1], Lina Maria Magnanimi[1], Eleonora Carosa[1], Maria Esposito[1], Maria Concetta Fargnoli[1], Cristina Pellegrini[1]

[1] Department of Biotechnological and Applied Clinical Sciences, University of L'Aquila, L'Aquila, Italy

Introduction

Familial melanoma (FM) and multiple primary melanoma (MPM) are traditionally considered distinct high-risk clinical entities, linked to germline alterations in melanoma susceptibility genes. However, it remains unclear whether they represent different genetic backgrounds or different clinical presentations of a shared inherited susceptibility.

The aim of the study was to investigate the germline mutational landscape of FM, MPM and combined FM/MPM patients, focusing on variant co-occurrence patterns and genetic clustering, and to assess their relationship with clinical and tumor characteristics.

Materials and Methods

We conducted a retrospective observational study on melanoma patients and their unaffected relatives. Clinical variables and tumor characteristics were considered. Germline Germline DNA was analysed using a next-generation sequencing (NGS) panel including 30 melanoma-related genes with high, moderate, or low penetrance. Germline variants were classified according to ClinVar as pathogenic/likely pathogenic (classes 4-5), variants of uncertain significance (VUS) (class 3), and benign/likely benign (classes 1-2). For the analysis, patients were stratified into FM, MPM and FM/MPM groups. In MPM patients, first and subsequent lesions were compared. For statistical comparison, only pathogenic and VUS were considered. Co-occurrence analysis, Multiple Correspondence Analysis (MCA) and network analysis were performed using Rstudio (v4.4.2).

Results

A total of 45 patients were included and stratified into FM (n=22), MPM (n=13), and FM/MPM (n=10) groups; additionally, 28 unaffected relatives were analysed. From a clinical perspective, a high nevus count (>100) was significantly more frequent in MPM (70%) and FM/MPM (62%) than FM patients (32%) (p=0.038). The presence of atypical nevi showed a non-significant trend (p = 0.066). Subsequent melanomas were significantly more often diagnosed in situ compared to first melanomas (52.6% vs 23.3%, p=0.011). Among invasive lesions, subsequent melanomas showed a lower mean Breslow thickness (0.48 mm vs 0.88 mm), although this difference did not reach statistical significance (p=0.133).

The MCA revealed that clinical subtypes (FM, MPM, and FM/MPM) do not constitute genetically distinct clusters, as they distribute across overlapping areas of the factor map (Dimension 1, 7.30%; Dimension 2, 6.74%). However, a statistically significant separation was identified between melanoma patients and unaffected relatives specifically along Dimension 1 (p=0.015), driven by VUS and pathogenic variants in ATM, MC1R, BRCA2, and SLC45A2. To further explore whether specific combinations of variants contributed to the clustering pattern, co-occurrence was assessed for selected gene pairs. ATM-BRCA2 (OR=3.82, p=0.17) and MC1R-SLC45A2 (OR=3.70, p=0.19) showed a trend toward positive co-occurrence, but neither association reached statistical significance in this cohort.

Among high-risk genes, pathogenic or conflicting variants in CDKN2A were identified in 7 patients (12.96%), followed by MC1R (n=4), BRCA2 (n=2), and BAP1 (n=1).

Conclusions

FM, MPM, and FM/MPM appear to reflect a shared germline susceptibility spectrum rather than distinct genetic entities. Affected patients showed a specific profile of pathogenic variants and VUS in DNA repair and pigmentary pathways compared with unaffected relatives. These findings, together with the 13% prevalence of CDKN2A variants in our cohort, support the use of expanded multi-gene panels for melanoma risk assessment, while larger cohorts are needed to validate specific gene-gene interactions.

EADV CONGRESS
VIENNA
30 SEP - 3 OCT 2026

Abstract N°: 4177

Modular deconstruction of DNA methylation clocks identifies drivers of human skin aging

Zoe Saßmannshausen*[1], Ariane Schmidt[1], Cassandra Falckenhayn[2], Günter Raddatz[1], Manuel Rodríguez-Paredes[1], Marc Winnefeld[2], Frank Lyko[1]

[1] DKFZ - German Cancer Research Center, Heidelberg, Germany

[2] Beiersdorf AG, Hamburg, Germany

Introduction
Aging and skin aging are major risk factors for the development of skin cancer. DNA methylation clocks are widely used tools to estimate biological age. However, their underlying cellular mechanisms are not well understood, although they could offer promising approaches for rejuvenation. Here, we demonstrate that modularization of epigenetic clocks for different human skin layers allows the identification of age-tracking substructures.

Materials and Methods
We used a multi-step clustering approach to assign CpGs of epigenetic clocks to co-varying and comparable modules.

Results
Characterization of these modules revealed distinct features on the level of genomic localization and chromatin modification. Notably, only three modules out of twelve tracked the majority of age-related changes. Additional analysis of these modules confirmed their association with various known and novel pathways relevant for skin aging. Finally, we validated our computational predictions by knocking down certain module genes, which resulted in a pronounced deceleration of epigenetic age in human dermal fibroblasts.

Conclusions
Our findings thus contribute to our knowledge of skin aging and facilitate the identification of novel targets for its rejuvenation.

EADV CONGRESS
VIENNA
30 SEP - 3 OCT 2026

Abstract N°: 4218

Treating challenging basal cell carcinoma with Vismodegib: A Real-World prospective experience

Dimitrios Sgouros*[1], Georgia Pappa[2], Panagiota Theofilogiannakou[1], Spyridon Manolakis[1], Eftychia Kitsiou[1], Andreas Dousis[1], Sofia Theotokoglou[1], Anna Syrmali[1], Emmanouil Karampinis[3], Vasileia Damaskou[4], Periklis Foukas[4], Alexander Katoulis[1]

[1] 2nd Department of Dermatology-Venereology, "Attikon" General University Hospital, National and Kapodistrian University of Athens, Medical School, Athens, Greece
[2] 1st Department of Dermatology-Venereology, "Andreas Syggros" Hospital of Cutaneous and Venereal Diseases, National and Kapodistrian University of Athens, Medical School, Athens, Greece
[3] Department of Dermatology, University General Hospital of Larissa, University of Thessaly, Faculty of Medicine, Larissa, Greece
[4] 2nd Department of Pathology, "Attikon" General University Hospital, National and Kapodistrian University of Athens, Medical School, Athens, Greece

Introduction

Basal cell carcinoma (BCC) is the most common cutaneous neoplasm in Caucasians. As alterations in the hedgehog signalling pathway play a crucial pathophysiological role, vismodegib has emerged as an effective alternative therapeutic modality for advanced, metastatic and recurrent BCC that is not amenable to surgery or radiotherapy.

Materials and Methods

We present our experience regarding the efficacy and safety of vismodegib in a real-world clinical setting. This ongoing, prospective, non-blinded study included patients with locally advanced (la) BCC, recurrent BCC, multiple BCCs and Gorlin-Goltz syndrome (G-G), treated with oral vismodegib 150 mg daily, during an 11-year period (2015–2026).

Results

The cohort included 33 patients (23 males, 10 females; median age 79 years, range 46–93) with 328 baseline BCCs. Sixteen patients had locally advanced BCC (16 tumors), 10 multiple BCCs (81 tumors), 4 Gorlin syndrome (227 tumors), 2 recurrent BCC (2 tumors), and 1 both locally advanced and relapsing BCC (2 tumors). Two approved patients never initiated treatment because of death before initiation and severe anemia, respectively.

Among the 31 patients who ultimately received vismodegib, median treatment duration was 6 months (range 2–19). Most patients experienced a meaningful clinical benefit, with complete response observed in 9/31 patients (29.0%) and partial response in 19/31 (61.3%), resulting in an overall response rate of 90.3% (28/31). Clinical improvement was often observed early during treatment; among the 28 patients with available time-to-response data, median time to >30% tumor reduction was 3 months (range 2–5), while 22/28 evaluable patients (78.6%) achieved this threshold within 3 months.

Safety data were available for 30 treated patients. Dysgeusia was the most frequently reported adverse event, occurring in 28/30 patients (93.3%), followed by muscle cramps in 21/30 (70.0%) and alopecia in 18/30 (60.0%).

At data cutoff, treatment remained ongoing in 7/31 patients (22.6%). Among the remaining evaluable patients, treatment discontinuation was associated with adverse events in 10/31 (32.3%), treatment clearance in 5/31 (16.1%), adjuvant procedures in 5/31 (16.1%), progressive disease in 2/31 (6.5%), and comorbidities or other causes in 4/31 patients (12.9%).Two-year follow-up data were available for 15 patients, among whom recurrence occurred in 9/15 (60.0%).

Conclusions

In this prospective real-world cohort, vismodegib showed substantial clinical benefit across locally advanced, recurrent, and multiple BCCs, including patients with extensive tumor burden and syndromic disease. Most patients achieved an early and clinically meaningful response, often within the first months of therapy.

EA DV CONGRESS
VIENNA
30 SEP - 3 OCT 2026

Abstract N°: 4222

Adjuvant Immunotherapy in Stage II–III Melanoma with Microscopic Nodal or In-Transit Disease: A Retrospective Real-World Cohort

Nadia Vega Almendra*[1], Claudia Guilarte-Cadavide[2], Ana Luiza Schuldt[2], Cristina Carrera[3], Josep Malvehy[3], Francesca Crespí-Payeras[3], Mar Luque Luna[2], Ariadna Ortiz-Brugués[2], Suzana Puig[3], Sebastian Podlipnik[4]

[1] Universitat de Barcelona, Hospital Clínic, Dermatology, Universidad de Chile, Dermatology, Santiago, Chile, Institut d'Investigacions Biomèdiques August Pi I Sunyer (IDIBAPS), Barcelona, Spain

[2] Universitat de Barcelona, Hospital Clínic, Dermatology, Barcelona, Spain

[3] Universitat de Barcelona, Hospital Clínic, Dermatology, Institut d'Investigacions Biomèdiques August Pi I Sunyer (IDIBAPS), Centro de Investigación en Red de Enfermedades Raras (CIBER-ER), Instituto de Salud Carlos III, Barcelona, Spain

[4] Universitat de Barcelona, Hospital Clínic, Dermatology, Institut d'Investigacions Biomèdiques August Pi I Sunyer (IDIBAPS), Barcelona, Spain, Barcelona, Spain

Introduction

Adjuvant immune checkpoint inhibitors have improved relapse-free survival in resected high-risk melanoma and are the current standard of care. However, immune-related adverse events (irAEs) frequently lead to treatment interruption or discontinuation. This balance is particularly relevant in patients with stage II–III melanoma with microscopic nodal or in-transit disease, where the absolute benefit may be lower. We aimed to characterize clinical features, toxicity, and outcomes in this population in a real-world setting

Materials and Methods

We conducted a retrospective single-center study including patients with resected stage IIB/IIC or stage III melanoma with microscopic nodal involvement (N1a, N2a, N3a) or isolated in-transit/microsatellite disease without nodal involvement (N1c), who initiated adjuvant immunotherapy from January 2015 onwards. Demographic and clinical data were collected from electronic medical records from our center. The primary outcomes included recurrence-free survival (RFS), distant metastasis-free survival (DMFS), overall survival (OS), and melanoma-specific survival (MSS). The irAEs were recorded and graded according to the Common Terminology Criteria for Adverse Events (CTCAE) version 5.0

Results

A total of 80 patients were included. Median age was 60.3 years, and 65% were male. Twenty patients (25%) had stage IIB/IIC, while 60 (75%) had stage III disease within the selected subgroups. After a median follow-up of 3.1 years, 28.8% experienced recurrence, 16.2% developed distant metastasis, and 12.5% died, with 8.8% of deaths attributed to melanoma. Overall, 42.5% of patients developed at least one irAE, most commonly dermatologic (15%), followed by gastrointestinal (7.5%) and endocrine (6.2%) toxicities. Grade ≥3 irAEs occurred in 12.5% of patients, including one treatment-related death (1.2%). Toxicity led to treatment discontinuation in 16.2% of cases, and nearly half of the patients discontinued therapy, mainly due to toxicity or

recurrence. Survival outcomes were broadly consistent with pivotal trials despite real-world heterogeneity. Patients treated after recurrence had worse RFS compared with those treated after primary resection. An association between severe irAEs and improved outcomes was observed

Conclusions

Adjuvant anti-PD1 therapy in this real-world cohort of high-risk stage II–III melanoma with microscopic nodal or in-transit disease demonstrates effectiveness and safety consistent with clinical trials. However, high discontinuation rates and poorer outcomes in patients treated after recurrence highlight the need to optimize patient selection. The observed association between severe irAEs and improved outcomes should be interpreted with caution due to the potential for immortal time bias. Integration of clinical and molecular biomarkers will be critical to improve risk-benefit stratification and personalize treatment strategies

EA DV CONGRESS
VIENNA
30 SEP - 3 OCT 2026

Abstract N°: 4275

The aggressive nature of cutaneous squamous cell cancer in solid organ transplant patients; optomising skin surveillance and management

Nina Muirhead*[1], Omar Nassar[1]

[1] Amersham Dermatology Department Buckinghamshire NHS Trust, Buckinghamshire, United Kingdom

Introduction

Approximately 80 solid organ transplant patients (SOTRs) receive regular skin surveillance in a dedicated monthly transplant skin surveillance clinic in our secondary care district general hospital. Subjectively, our team of dermatologists have noted a significant increase in clinical burden, increased numbers of poorly differentiated cSCCs (cutaneous squamous cell cancers), and an opportunity for better use of systemic chemoprevention.

Materials and Methods

We identified SOTR patients who had a diagnosis of their first cSCC between 01/01/2021 and 31/12/2025. Datasets were triangulated via the trust cancer information team, patient notes, and clinic letters. Individual patient details were entered into a standardised spreadsheet to capture data that could be directly compared with the published results of the National UK Contemporary Outcomes After cutaneous SCC in Transplant recipients (COAST) study.

Results

Sixteen SOTRs developing their first cSCC between 2021 and 2025 were identified. One lung transplant and three liver transplant patients were excluded to match existing COAST data, which are limited to patients with renal +/- pancreas transplants only. Of the 12 patients, 7 were male and 5 female, all were Caucasian with a fair skin type, and the average follow-up was 32 months, three patients died from graft failure, heart failure, or sepsis.

Cutaneous SCCs were generally large, with an average diameter of 19 mm, and were poorly (4/12) or moderately (5/12) differentiated. Furthermore, 4/12 had perineural invasion. PT stage was PT3 in 5/12, PT2 in 1/12, and PT1 in 6/12. Two patients received post-operative radiotherapy. There was also a higher incidence of other skin cancers and pre-cancerous lesions. 1/12 had a melanoma, 5/12 had basal cell cancers, and 12/12 had actinic or Bowenoid keratoses, with many patients receiving multiple excision biopsies. Topical prevention of pre-cancerous lesions was commonly used 11/12 patients were given a course of topical 5-Flurouracil (Efudix) and 8/12 had cryotherapy.

Systemic chemoprevention was rare, with 2/12 patients started on nicotinamide and none on acitretin. There was no modification of immunosuppression with all patients remaining on their normal medications (mycophenolate mofetil (MMF) + tacrolimus 7/12; tacrolimus and prednisolone 2/12; azathioprine 1/12; and MMF 2/12). Two patients have had a subsequent cSCC; one had a recurrence, and the other developed a second PT3 poorly differentiated cSCC at a distant site.

Generally, all cSCCs showed more aggressive behaviour compared to cSCCs diagnosed in non-immunosuppressed patients.

Conclusions

Numbers of new cSCCs in SOTRs in our secondary care hospital have more than doubled since 2016–2020. Most patients had large, moderate, or poorly differentiated cSCCs. Our data was consistent with national UK COAST data published earlier in 2026 showing a higher frequency of high risk tumours which are poorly differentiated (18.6%) and/or pT3 (23.9%). This study highlights the aggressive nature of cSCCs in this group of patients, with a subsequent effect on patients' morbidity and mortality.

These results reinforce the importance of seeing transplant patients in a specialist skin surveillance clinic, which enables more time for full skin and lymph node checks, as well as adhering to established protocols for frequency of very high-risk skin cancer follow-up. Furthermore, our study has identified opportunities for earlier chemoprevention. Low dose acitretin is recognised as a safe option for chemoprevention of keratinocyte carcinomas in transplant patients. Azathioprine is well-known for its association with UV-A photosensitivity, which has been shown to reverse after switching to MMF. Optimal management should include starting systemic agents such as acitretin and multidisciplinary co-ordination with transplant physicians to consider modification of immunosuppressive therapy.

EADV CONGRESS
VIENNA
30 SEP - 3 OCT 2026

Abstract N°: 4288

Integrated Molecular Profiling Defines Clinical and Biological Heterogeneity in Basal Cell Carcinoma

Andrey Yurchenko*[1], Fatemeh Rajabi[1], Laurent Parmentier[2], Shensi Shen[3], Lukas Flatz[4], Sergey Nikolaev[1]

[1] Gustave Roussy, Villejuif, France

[2] Valais Hospital, Sierre, Switzerland

[3] Sichuan University, Chengdu, China

[4] Eberhard Karls Universität Tübingen, Tübingen, Germany

Introduction

Basal cell carcinoma (BCC) is the most common human malignancy, yet the molecular mechanisms underlying its initiation, histological diversity, immune phenotype and rare metastatic progression remain incompletely understood. A more refined molecular classification is needed to explain the broad clinical spectrum of BCC and to identify biologically relevant vulnerabilities.

Materials and Methods

We performed integrated genomic, methylomic and transcriptomic profiling of a large BCC cohort (n=443), complemented by single-cell RNA sequencing. We assessed associations between molecular features and clinical, geographical and histological variables, analyzed UV-related mutational signatures in relation to replication timing and *TP53* status, reconstructed evolutionary trajectories, characterized the tumor microenvironment (TME), and compared localized and metastatic tumors. Integrative clustering was used to define molecular subtypes of BCC.

Results

Tumor mutational burden (TMB) varied significantly according to clinical and geographical factors, indicating that environmental and host-related features contribute to mutational heterogeneity. Replication timing and *TP53* status jointly shaped UV-induced mutagenesis: *TP53*-mutant BCCs accumulated substantially more SBS7b mutations, particularly in early-replicating genomic regions, consistent with impaired DNA-damage response and altered repair of UV-induced lesions. Evolutionary analyses suggested that *TP53* inactivation frequently precedes *PTCH1* loss during BCC development, supporting a model in which defective cell-cycle control and differentiation facilitate accumulation of UV-induced mutations before full Hedgehog pathway activation. We also identified *PAK2* as a putative novel oncogenic driver, with recurrent missense mutations affecting its autoinhibitory and kinase domains, suggesting a potential therapeutic vulnerability in a subset of tumors (18%). Histological subtypes differed markedly in their TME despite similar driver mutational landscapes: nodular BCC displayed an immune-desert phenotype, whereas aggressive histologies showed abundant stromal infiltration dominated by cancer-associated fibroblasts. Rare metastatic BCCs lacked unique recurrent driver mutations but showed pronounced aneuploidy and frequent whole-genome duplication, indicating that genomic instability rather than specific driver events may underlie metastatic potential. Single-cell RNA sequencing identified LGR5^{+} hair follicle stem cells as the most likely cell of origin, characterized by low MHC-I and high TGF-β expression,

consistent with an intrinsically immunosuppressive state. Integrative multi-omic clustering defined four molecular BCC subtypes distinguished by histological presentation, immune and stromal infiltration, Hedgehog pathway activity and mutational burden.

Conclusions

These findings provide a comprehensive molecular framework for BCC pathogenesis and heterogeneity. They identify *TP53* as a central determinant of UV-driven mutagenesis, support LGR5^{+} hair follicle stem cells as the probable cell of origin, nominate *PAK2* as a new candidate oncogenic driver, and show that TME composition and genomic instability are major correlates of clinical behavior. This integrative classification may support biomarker development and guide future therapeutic stratification, including approaches targeting Hedgehog signaling, tumor-stromal interactions and immunosuppressive pathways in selected BCC subtypes.

EA DV CONGRESS
VIENNA
30 SEP - 3 OCT 2026

Abstract N°: 4289

Microstructural dermoscopic criteria for recurrent and cutaneous metastatic melanoma after surgical treatment: Toward a diagnostic algorithm

Chaimae Bouhamdi*[1], elloudi sara[1], imane denni[1], Kawtar El fid[1], IKRAME BEJJA[1], Saadia Boughaleb[1], Zakia Douhi[1], Meryem Soughi[1], Hanane Baybay[1], Fatima Zohra Mernissi[1]

[1] Dermatology Department, Hassan II University Hospital, Fez, Morocco

Introduction

New lesions arising during post-surgical melanoma surveillance, whether on or near melanoma excision or lymph-node dissection scars, or at distant cutaneous sites, represent a high-stakes diagnostic challenge, ranging from non-recurrent/non-metastatic lesions to local recurrence or cutaneous metastasis. Available dermoscopic criteria remain mainly global, with limited microstructural characterization and performance quantification. We aimed to identify dermoscopic structures and microstructural features associated with histologically confirmed recurrence/metastasis, quantify their diagnostic performance, and develop a biopsy-oriented dermoscopic algorithm.

Materials and Methods

We conducted an analytical case-control study nested within a prospective cohort of patients surgically treated for histologically confirmed cutaneous melanoma. New surveillance lesions on, near, or distant from melanoma excision or lymph-node dissection scars were included with exploitable dermoscopic images and histopathological confirmation classifying the lesion, the unit of analysis, as recurrence/metastasis or non-recurrent/non-metastatic control. A standardized grid captured 478 lesion-level variables. Associations and diagnostic performance were analyzed using odds ratios, sensitivity, specificity, predictive values, and likelihood ratios; significant signs with sensitivity and/or specificity ≥80% were integrated into a decision algorithm.

Results

The study included 88 patients and 210 histologically confirmed lesions: 113 recurrence/metastasis lesions and 97 controls.

Strong rule-in criteria (sensitivity and/or specificity ≥80%; LR+ ≥10) included parallel-ridge dominant pattern, gray focal homogeneous pigmentation, blue clods, exploded irregular clods, white dermoscopic circles, globally anarchic ink blot, peripheral/eccentric blue-white veil, and hairpin, glomerular, central, or eccentrically distributed vessels.

Strong rule-out criteria (sensitivity ≥80%; LR− <0.1) included irregular or globally anarchic dots, irregular or globally anarchic globules, globally anarchic clods, irregular or discontinuous sharply demarcated pigmented lines/streaks, peripheral circles unrelated to follicles, globally anarchic chrysalis-like structures, and globally anarchic non-shiny whitish lines/streaks. Additional criteria showed moderate or weak rule-out value, including onset delay ≥12 months, polychromia, and asymmetry.

Moderate rule-in criteria (sensitivity and/or specificity ≥80% with LR+ 5 to <10) included dominant non-continuous centrifugal non-chaotic pattern, dominant chaotic growth pattern, blue-gray focal homogeneous pigmentation, exploded irregular dots, blue globules, exploded irregular globules, irregular clods, blue-white veil, white area with peppering, dermoscopic circles polygonal or forming a discontinuous peripheral border, ramified

pigmented lines/streaks, comma vessels, and concentrically distributed vessels. Other criteria showed weak rule-in value only.
Benign-oriented de-escalation criteria included globally structured ink blot, circles not forming a discontinuous peripheral border, absent ink blot, absent blue-white veil, absent regression, non-ramified pigmented lines/streaks, and unichrome structureless areas.
This hierarchy supported a four-node algorithm combining immediate rule-in, rule-out by absence, confirmatory stratification, and de-escalation for targeted biopsy decision-making during post-surgical melanoma surveillance.

Conclusions

Diagnostic value in melanoma post-surgical surveillance lesions depended on microstructural morphology rather than structure presence alone. Only statistically significant signs with sensitivity and/or specificity ≥80% were integrated ; significant low-performance signs and multimodal variables unsuitable for binary performance estimates were excluded from decision-driving levels. The proposed likelihood-ratio-based algorithm may guide immediate biopsy/excision versus surveillance in suspected local recurrence or cutaneous metastasis.

EA DV CONGRESS
VIENNA
30 SEP - 3 OCT 2026

Abstract N°: 4338

Rhenium-188 Resin for Non-Melanoma Skin Cancer: Safety, Efficacy, and Cosmetic Results from a Prospective Study

Carmen Garcia-Donoso*[1], Diana Vega-Pérez[1], Beatriz García-Bracamonte[1], Alfonso Gotor-Rivera[1], Eva Chamorro[1], Jorge Arroyo-Andres[1], Virginia Blasco-Tamariz[1], Elisa Martínez-Albero[1], Pablo Ortiz-Romero[1]

[1] Hospital Universitario 12 de Octubre, Madrid, Spain

Introduction

Non melanoma skincancer (NMSC) is the most frequent malignancy. Treatment of non-melanoma skin cancer (NMSC) with 188-Rhenium resin (188-Re) is a therapeutic alternative to conventional techniques, such as surgery (gold standard), especially in patients who are ent not candidates for surgical treatment, either due to comorbidities or lesion characteristics (location and extent). In these scenarios, 188-Re is a useful tool, with good tolerance, low toxicity, and excellent response rates. This prospective study primarily aimed to evaluate symptoms burden, acute toxicity, and cosmetic outcomes in patients with non-melanoma skin cancer (NMSC) treated with rhenium-188 resin at our institution, as well as to assess the clinical response to treatment.

Materials and Methods

A total of 32 patients (p) (13 women, 19 men) with 39 NMSC lesions (L) were treated at our institution between June 2024 and March 2026. Lesions with a mean follow-up of 6 months were included in the analysis: 24L from 20p Lesion-related symptoms (pruritus, burning, pain, or other symptoms) were assessed during follow-up at 15 days, 30 days, 3 months, and 6 months. Acute adverse events were evaluated at 30 days using the Common Terminology Criteria for Adverse Events (CTCAEv5.0), while cosmetic outcomes were assessed at 6 months according to the Radiation Therapy Oncology Group (RTOG) toxicity criteria. Treatment response was evaluated throughout follow-up by dermoscopy and/or confocal microscopy. Mean patient age was 70 years (range: 57-91 years). Histological subtypes included cutaneous squamous cell carcinoma in 4.1% (1L), extramammary Paget disease in 4.1% (1L), and basal cell carcinoma in 91.8% (22L). Mean lesion surface area was 5.66 cm^2 (range; 1.43-24 cm^2), with a mean depth of 1.25 mm (range: 0.3-3.1 mm). Regarding treatment characteristics, a mean administered activity of 361.27 MBq (range: 41.7-1 128.4 MBg) was applied, with a mean treatment duration of 118 minutes (range: 50-240 minutes).

Results

At 15 days, the most frequently reported symptoms were pruritus in 20L (83,33%), burning in 8L (33,33%) and pain in 3L (12,5%). At 30 days, pruritus was reported in 16L (66,67%), burning in 5L (20,83%) and pain in 3L (12,5%). At 3 and 6 months, pruritus remained the predominant symptom (16,67% and 4,1%, respectively), while most (91.8%) of the patients were asymptomatic 6 months after treatment. Acute toxicity at 30 days was G1 in 62.5% of lesions(15L), G2 in 25.0%(6L), and G3 in 12.5%(3L), with complete resolution during follow-up, Cosmetic outcomes according to the RTOG scale were rated as excellent in 16L(66.7%) and good in 8L(33.3%). Complete clinical response was achieved in all lesions, with no evidence of recurrence at 6 months.

Conclusions

Treatment with Rhenium-188 resin appears to be an effective and safe therapeutic option for NMSC, showing low acute toxicity, a favorable symptom profile, and excellent cosmetic outcomes in most cases.

EA DV CONGRESS
VIENNA
30 SEP - 3 OCT 2026

Abstract N°: 4356

Positive Surgical Margins Impact Nodal Metastasis and All-Cause Mortality in Merkel Cell Carcinoma: A National Cancer Database Study 2004-2022

Carli Tucci*[1], Akshay Pulavarty[2], Mary Stevenson[2], Nayoung Lee[2], Maressa Criscito[2], John Carucci[2]

[1] New York University Grossman School of Medicine, New York, United States

[2] The Ronald O. Perelman Department of Dermatology, New York University Grossman School of Medicine, New York, United States

Introduction

Merkel cell carcinoma (MCC) is a rare but highly aggressive cutaneous malignancy with a strong propensity for regional and distant metastasis. Current NCCN guidelines recommend surgical resection with wide local excision or Mohs micrographic surgery and sentinel lymph node biopsy for clinically node-negative Merkel cell carcinoma. The goal of surgery is to achieve histologically negative margins as positive surgical margins are associated with increased risk of recurrence and disease-specific mortality.[1] IFor positive margins, adjuvant radiotherapy (aRT) is recommended and prioritized over re-excision.[1] However, existing evidence for aRT in this setting is limited by small or unreported numbers of margin-positive cases.[2-5] Whether aRT offsets the adverse prognostic impact of residual microscopic disease remains unknown. This study evaluates whether positive surgical margins following excision and aRT are associated with increased regional nodal metastasis and all-cause mortality in patients with clinically node-negative MCC.

Materials and Methods

Using the National Cancer Database (2004–2022), we identified patients with cN0 MCC who underwent excision followed by aRT with histologically evaluated surgical margins. Multivariable logistic regression assessed predictors of regional lymph node metastasis, and Cox modeling evaluated all-cause mortality. AJCC T-stage groupings were included in multivariable models to ensure that associations between margin status and outcomes were not confounded by extent of disease.

Results

Among 7,510 eligible patients, 11.7% had positive margins. Among 4,180 patients with histologically evaluated regional nodes, positive margins independently predicted nodal metastasis (adjusted odds ratio 1.57, 95% CI 1.24–1.99; $p<0.001$). Additional predictors of metastasis included tumor size >20 mm, Charlson–Deyo comorbidity score ≥1, and non-private insurance. Positive margins also independently predicted increased all-cause mortality (hazard ratio 1.60, 95% CI 1.43–1.78; $p<0.001$). Greater all-cause mortality was also significantly associated with positive nodal status, larger tumor size, non-private insurance, and non-academic facility type.

Conclusions

In this large, national cohort of patients with clinically node-negative MCC treated with excision and aRT, positive surgical margins were independently associated with increased regional nodal metastasis and higher all-cause mortality. Achieving histologically negative margins remains critical in MCC management, even when aRT is administered. Our findings suggest that achieving negative margins, through either staged excision or complete

margin assessment techniques, is advantageous. We also extend prior research on disparities in MCC by demonstrating that access-related barriers are associated with poor outcomes. Future research should explore whether integrating molecular or immunologic predictors with margin assessment can refine prognostication and guide individualized therapy.

References

1. Schmults, C.D.*, et al.* NCCN Guidelines® Insights: Merkel Cell Carcinoma, Version 2.2026. *J Natl Compr Canc Netw* **22**, e240002 (2026).
2. Hruby G, Scolyer RA, Thompson JF. The important role of radiation treatment in the management of Merkel cell carcinoma. Br J Dermatol. 2013;169(5):975-982. doi:10.1111/bjd.12481
3. Kang SH, Haydu LE, Goh RYH, Fogarty GB. Radiotherapy is associated with significant improvement in local and regional control in Merkel cell carcinoma. Radiat Oncol. 2012;7(1). doi:10.1186/1748-717x-7-171
4. Tarabadkar, E.S.*, et al.* Narrow excision margins are appropriate for Merkel cell carcinoma when combined with adjuvant radiation: Analysis of 188 cases of localized disease and proposed management algorithm. *J Am Acad Dermatol* **84**, 340-347 (2021).
5. Lodde GC, Leiter U, Gesierich A, et al. Clinical course of Merkel cell carcinoma: A DeCOG multicenter study of 1049 patients. European Journal of Cancer. 2025;221:115406. doi:10.1016/j.ejca.2025.115406

EADV CONGRESS
VIENNA
30 SEP - 3 OCT 2026

Abstract N°: 4364

A Systematic Review of Geographic Access to Specialist Care and Its Correlation with Preventable Skin Cancer Mortality and a Proposed Minimum Access Standard

Krish Lightwala*[1]

[1] Belarusian state medical university, Minsk, Belarus

Introduction
Geographic maldistribution of dermatologists is a recognized global problem, yet its direct contribution to preventable skin cancer mortality has never been systematically quantified. Millions of patients live in dermatology deserts where travel distance, wait times, and specialist scarcity delay diagnosis. This systematic review maps the relationship between geographic access to dermatology care and skin cancer outcomes, and proposes an evidence based Minimum Access Standard for health workforce planning.

Materials and Methods
We systematically reviewed PubMed, Embase, Web of Science, and gray literature from 2000 to 2026 for studies reporting dermatologist density per capita, travel distance to nearest specialist, and skin cancer outcomes defined as melanoma stage at diagnosis, melanoma specific mortality, and keratinocyte carcinoma mortality. Geographic information system data were synthesized where available. Correlation between access metrics and mortality outcomes was calculated using meta regression. We derived a proposed Minimum Access Standard based on mortality inflection points, defined as the dermatologist density and maximum travel time below which skin cancer mortality increased disproportionately.

Results
Thirty four studies covering 18 countries met inclusion criteria. Regions with fewer than 2.5 dermatologists per 100,000 population showed a 27 percent higher odds of late stage melanoma diagnosis, rising to 41 percent below 1.0 per 100,000. Travel time exceeding 60 minutes to the nearest dermatologist independently predicted a 19 percent increase in melanoma specific mortality after adjusting for UV exposure, socioeconomic status, and health insurance coverage. Rural and low income urban zones were disproportionately affected across all health systems studied. The mortality gradient persisted across both public and private healthcare models.

Conclusions
Geographic access to dermatologists is an independent predictor of preventable skin cancer death, not merely an inconvenience. We propose a Minimum Access Standard of 2.5 dermatologists per 100,000 population and a maximum travel time of 60 minutes to specialist care. This benchmark provides an actionable threshold for policy makers evaluating teledermatology deployment, training incentive programs, and mobile dermatology units. Without a measurable standard, dermatology deserts will persist and patients will continue to die from detectable, curable skin cancers.

EADV CONGRESS
VIENNA
30 SEP - 3 OCT 2026

Abstract N°: 4388

Passenger-Side Melanoma? A Single-Centre Study of Divergent Laterality in Cutaneous Malignancies

Kevin Machů*[1], Lucie Jaresova[1]

[1] Dermamedest, Prague, Czech Republic

Introduction
Laterality of cutaneous malignancies may reflect asymmetric ultraviolet exposure and behaviour-related risk patterns. In European populations, left-sided predominance has often been linked to driver-side exposure, whereas right-sided clustering may suggest alternative patterns such as passenger-side exposure or intermittent recreational ultraviolet exposure.We analysed tumour laterality in a single-centre cohort, with a predefined focus on upper-body lesions.

Materials and Methods
We performed a retrospective analysis of a dermatology oncology logbook including histologically confirmed basal cell carcinoma (BCC), squamous cell carcinoma (SCC), and melanoma diagnosed between 2024 and April 2026. Extracted variables included tumour type, sex, age, anatomical localisation, tumour laterality, histological subtype, and melanoma stage where available. Midline, bilateral, non-lateralised, and genital lesions were excluded from laterality analyses. A predefined upper-body subanalysis, including the head, neck, trunk, and upper limbs, was performed to better assess asymmetric ultraviolet exposure.

Results
A total of 102 cutaneous malignancies were included: 62 BCC, 21 melanoma, and 19 SCC. After exclusions, 80 unilateral tumours were analysed. Median age was 58 years overall, 58 years for BCC, 49 years for melanoma, and 62 years for SCC. Overall laterality did not significantly deviate from symmetry: 35 right-sided versus 45 left-sided tumours; $p = 0.314$. Laterality differed significantly by tumour type using the chi-square test: $p = 0.0046$. BCC showed left-sided predominance: 30 left versus 16 right. Melanoma showed right-sided predominance: 15 right versus 5 left. SCC also tended toward the left: 10 left versus 4 right. In the upper-body subanalysis, this divergence became more pronounced: BCC remained left-predominant, with 28 left versus 14 right; $p = 0.044$, whereas melanoma was markedly right-predominant, with 14 right versus 3 left; $p = 0.013$. Most melanomas were early stage: 14/21 were pTis, 5/21 pT1a, and 2/21 pT1b.

Conclusions
In this single-centre cohort, cutaneous malignancies showed tumour type-specific laterality patterns. BCC showed left-sided predominance and SCC a left-sided tendency, whereas melanoma showed significant right-sided predominance, particularly on the upper body. Differences from previously reported left-sided melanoma patterns may reflect cohort composition, the relatively younger melanoma subgroup, anatomical site distribution, or behaviour-related ultraviolet exposure. The marked right-sided upper-body predominance of melanoma raises the possibility of a passenger-side or behaviour-related exposure effect. Although hypothesis-generating, these findings suggest that tumour laterality may offer a simple but overlooked epidemiological clue and warrant validation in larger multicentre cohorts.

EADV CONGRESS
VIENNA
30 SEP - 3 OCT 2026

Abstract N°: 4394

MAMMARY PAGET DISEASE – A Case Report

Tanja Mladenovic*[1], Slađana Cekić[1], Danijela Popovic[1, 2], Andrija Jović[1, 2], Zorana Zlatanovic[1], Danica Tiodorovic[1, 2]

[1] Clinic for Dermatovenerology, University Clinical Center Niš, Niš, Serbia

[2] Faculty of Medicine, University of Niš, Niš, Serbia

Introduction

Mammary Paget's disease is a rare intraepidermal adenocarcinoma of the breast affecting the skin of the nipple and areola. It is most commonly associated with ductal carcinoma in situ or invasive carcinoma.It occurs most often in postmenopausal women. We present a 44-year-old women with an eighteen-month history of an erythematous plaque in the area of the right nipple-areolar region, examined dermoscopically and histopathologically verified as Paget's disease.

Materials and Methods

A 44-year-old woumen was referred to a dermatologist due to a skin lesion in the right breast region, present for approximately 18 months. Her personal medical history without significant diseases, while her family history was positive for breast cancer (maternal grandmother).

Results

Clinical examination revealed an erythematous plaque with desquamation, accompanied by subjective pruritus, present for approximately 18 month. The patient was treated with systemic antihistamines, topical corticosteroids, and calcineurin inhibitors, without an adequate therapeutic response. Dermoscopy demonstrated a pink structureless area, whitish scales, and shiny white lines, findings that supported the clinical suspicion. Considering the patinet’s history and the dermoscopic findings, skin biopsy was performed for histopathological analysis. Histopathological findings confirmed Morbus Paget of the nipple, along with ductal carcinoma in situ (DCIS high nuclear grade III), immunohistochemical analysis showed HER2 3+ positivity. Due to the possible connection with breast cancer, the patient was referred for further examination (ultrasound, mammography and MRI).

Conclusions

Paget's disease is a rare carcinoma of the breast ductal system and is frequently associated with in situ or invasive ductal carcinoma. Due to its clinical presentation, it is often misdiagnosed as another benign or malignant dermatological condition. Chronic unilateral lesions resistant to therapy, should raise concern and prompt further histopatological and immunohistochemical evaluation. A clinicodermoscopic-pathological correlational approach is crucial for an early and accurate diagnosis.

EADV CONGRESS
VIENNA
30 SEP - 3 OCT 2026

Abstract N°: 4407

Artificial Intelligence in Melanoma Detection Across Diverse Skin Tones: A Systematic Review of Diagnostic Accuracy and Equity

Aamaal Malik*[1], Zahraa Zaini[1], Bernard Ho[2]

[1] St George's Hospital Medical School, London, United Kingdom

[2] St George's Hospital Medical School, St George's, Epsom and St Helier Hospital Group (gesh), London, United Kingdom

Introduction
Early detection remains the strongest factor influencing melanoma survival. Artificial intelligence (AI) is increasingly being explored as a tool to support melanoma diagnosis, with some studies reporting performance comparable to that of dermatologists. However, many algorithms have been trained mainly on lighter skin tones, raising concerns about diagnostic equity. This systematic review evaluates the diagnostic performance of AI models for melanoma detection and bias related to skin tone representation.

Materials and Methods
A systematic literature search was conducted in PubMed, MEDLINE and EMBASE following PRISMA guidelines, using combinations of the terms “melanoma”, “skin cancer”, “artificial intelligence”, “machine learning”, “deep learning”, “skin tone”, “Fitzpatrick” and “bias”. A total of 1188 records were identified, and 61 studies underwent full-text screening.

Results
AI systems demonstrate high diagnostic performance, with most algorithms reporting AUROC values above 0.85 and accuracy comparable to dermatologists. However, a significant dataset imbalance was identified. Analysis of 21 major dermatology image datasets (106,950 images) found that only 2.1% contained Fitzpatrick skin type metadata, with types V-VI represented by only 11 images. Algorithmic audits report reduced sensitivity in darker skin, where true positive rates decline from 0.45 in lighter skin to 0.26 in darker skin. Melanomas more common in darker skin, including acral lentiginous melanoma, were also underrepresented in training datasets.

Conclusions
AI shows considerable promise for melanoma detection, however limited skin tone representation risks perpetuating diagnostic disparities. Future research must prioritise more inclusive datasets to ensure equitable care for all patients.

EADV CONGRESS
VIENNA
30 SEP - 3 OCT 2026

Abstract N°: 4432

Carcinoma en cuirasse as manifestation of metastatic breat cancer progression: a case report

Beghdad Ikram*[1], Lemya Mezdour[1], Asma Haciane[1], Samira Zobiri[1]

[1] Mustapha University Hospital, Dermatology Departement, Algiers, Algeria

Introduction

Cutaneous metastases from breast cancer represent relatively rare but not exceptional manifestation, most often associated with advanced disease and poor prognosis. Their clinical presentation is polymorphic and may mimic various dermatoses, potentially delaying diagnosis

Materials and Methods

We report the case the case of 49-year-old woman followed for metastatic breast cancer carcinoma, surgically treated in 2019, who developed since since January 2025 erythematous, painful, non pruritic nodular skin lesions, evolving in a context of moderate deterioration of general condition. Dermatological examination revealed firm nodules measuring 0,5 to 01 cm, isolated or coalescing into infiltrated plaques involving the upper trunk with dorsal extension, bleeding on contact, and associated with lymphedema on the left upper limb. Histopathological examination showed a dermal epithelial neoplastic proliferation. Immunohistochemistry demonstrated positivity for CKMNF116, GATA3, and mammaglobin consistent with breast cancer. Chemotherapy was continued

Results

Cutaneous breast cancer metastases occur in rare cases and represent the most frequent cause of cutaneous metastases in women. They usually present as firm nodules that may coalesce into infiltrated plaques, sometimes in distinctive forms such as carcinoma en cuirasse. Their occurrence generally reflects systemic dissemination and is associated with unfavorable prognosis. Diagnosis relies on histopathological and immunohistochemical examination which helps exclude differential diagnosis

Conclusions

This case illustrates a typical presentation of cutaneous metastases of breast origin. Any unsual skin lesion in a patient with a history of breast cancer should raise suspicion for cutaneous metastatic disease in order to ensure appropriate management

EA DV CONGRESS
VIENNA
30 SEP - 3 OCT 2026

Abstract N°: 4445

Risk Factors Associated with Severity of Acute Radiation-Induced Skin Injury (aRISI) in Head and Neck Cancer – Single Center Retrospective Analysis with Review of the Literature

Paweł Głuszak*[1], Aleksandra Dańczak-Pazdrowska[1], Agnieszka Seraszek-Jaros[2], Joanna Kaźmierska[3, 4], Jakub Pazdrowski[5, 6]

[1] Department of Dermatology, Poznan University of Medical Sciences, Poznan, Poland
[2] Department of Bioinformatics and Computational Biology, Poznan University of Medical Sciences, Poznan, Poland, Poznan, Poland
[3] Department of Electroradiology, Poznan University of Medical Sciences, Poznan, Poland, Poznan, Poland
[4] Department of Radiotherapy II, Greater Poland Cancer Center, Poznan, Poland, Poznan, Poland
[5] Department of Head and Neck Surgery, Poznan University of Medical Sciences, Poznan, Poland
[6] Department of Head and Neck Surgery, Greater Poland Cancer Center, Poznan, Poland, Poznan, Poland

Introduction

Acute radiation-induced skin injury (aRISI) is a frequent and clinically significant toxicity in patients with head and neck cancer (HNC) undergoing radiotherapy (RT). However, risk factors in this population remain unclear. We aimed to identify clinical and treatment-related predictors of severe aRISI and its onset.

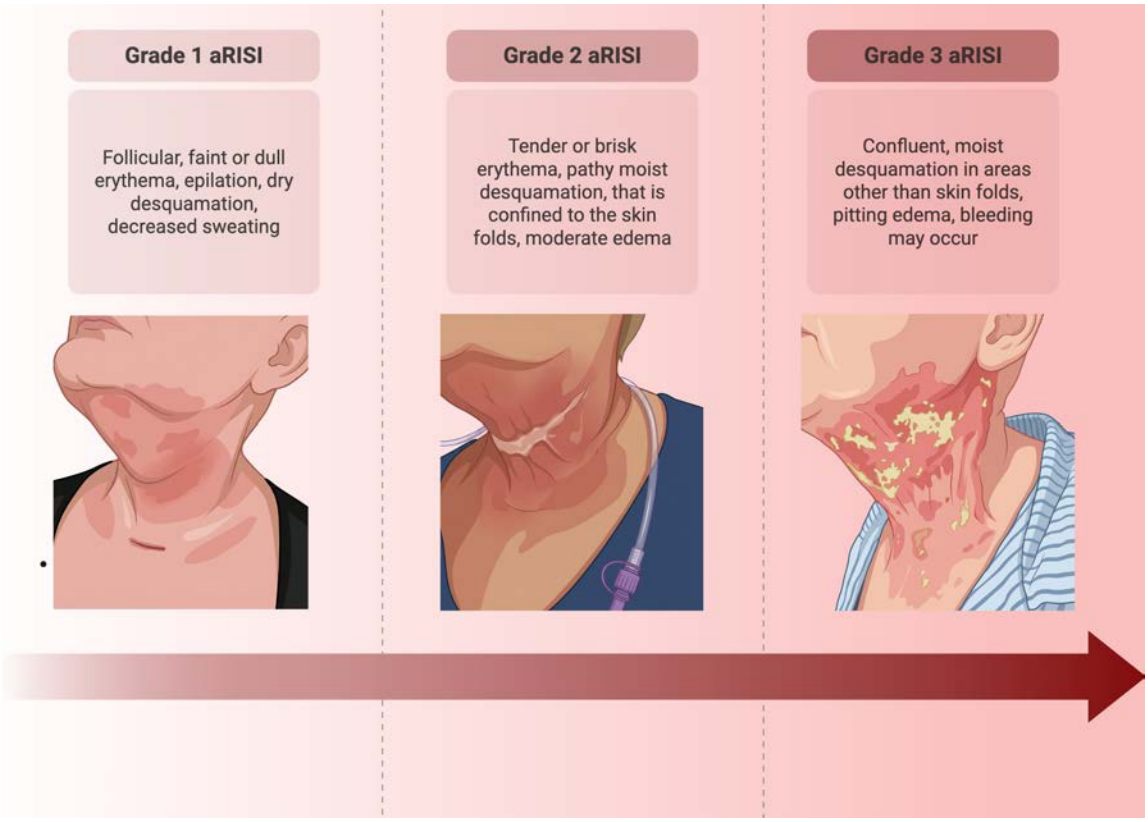

Features of clinically relevant acute radiation-induced skin injury stratified by severity grade according to the Radiation Therapy Oncology Group (RTOG) grading system

Materials and Methods
We conducted a retrospective single-center cohort study of 251 consecutive HNC patients treated with definitive RT (2016–2024), with or without concurrent systemic therapy. The primary endpoint was severe aRISI (grade 3, Radiation Therapy Oncology Group scale). The secondary endpoint was time to first grade 1 aRISI. Logistic regression identified risk factors, while Kaplan–Meier and Cox models evaluated time-to-event outcomes.

Results
Grade 3 aRISI occurred in 84 patients (33%). Median time to grade 1 and grade 3 aRISI was 17 and 38 days, respectively. Multivariable analysis showed that female sex, poorer performance status, obesity, advanced nodal disease, and concurrent cetuximab were independently associated with severe aRISI. The strongest associations were observed for female sex (OR 4.48, $p<0.001$) and cetuximab (OR 5.64, $p=0.014$). Cetuximab was also linked to earlier onset of grade 1 aRISI compared with cisplatin or no systemic therapy. Age had a weak association with earlier onset, while smoking, diabetes, inflammatory markers, and cisplatin were not significant predictors.

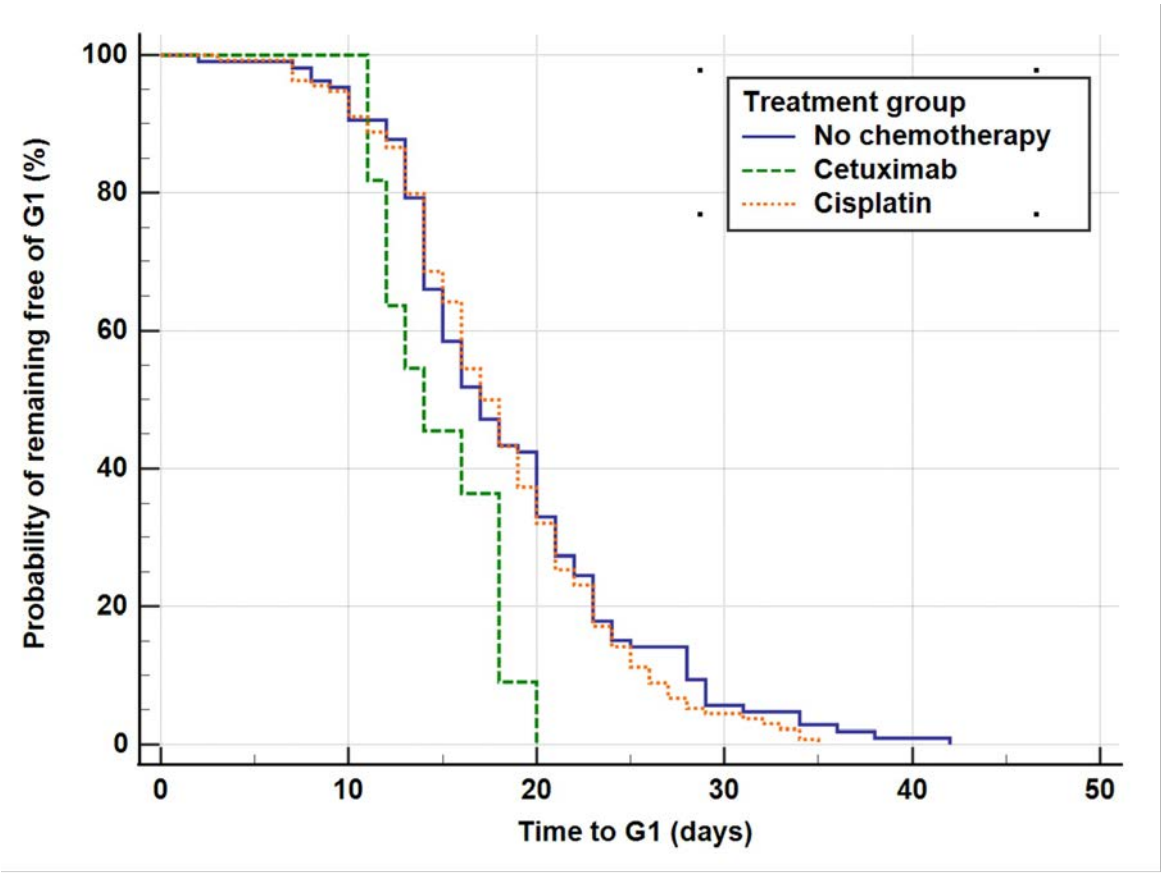

Kaplan–Meier curves illustrating time to first (G1) aRISI stratified by treatment type. Differences between groups were assessed using the log-rank test. Hazard ratios (HRs) were estimated using exploratory Cox proportional hazards regression analysis. Cetuximab was associated with a significantly earlier onset of grade 1 aRISI compared with no systemic therapy (HR = 2.23) and compared with cisplatin (HR = 2.02). No significant difference was observed between cisplatin and no systemic therapy.

Conclusions
Severe aRISI is common in HNC patients receiving RT. Clinical factors and cetuximab exposure may help identify high-risk patients for closer monitoring and preventive strategies. Prospective multicenter studies are needed to refine individualized risk prediction.

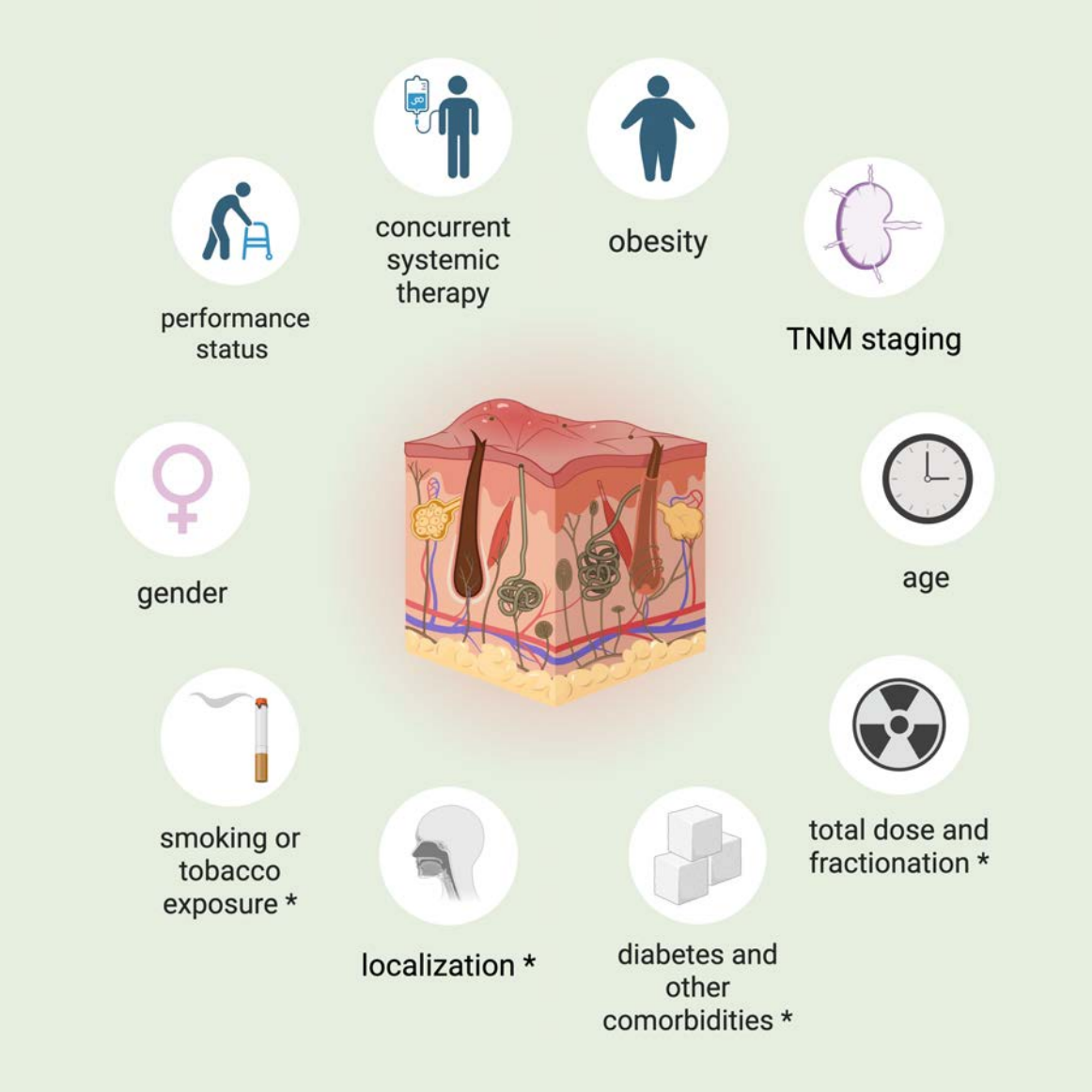

Risk factors for acute radiotherapy-induced skin injury (aRISI) that have been described in the literature. The present study confirmed that female sex, obesity, poorer performance status, nodal status (N stage within the TNM classification), advanced age, and the use of concurrent systemic therapy (particularly cetuximab) are significant risk factors for aRISI. Factors not confirmed in this study have been marked with an asterisk (*). These include, among others, smoking status, tumor localization, diabetes mellitus and other comorbidities, as well as total radiation dose and fractionation schedule.

EA DV CONGRESS
VIENNA
30 SEP - 3 OCT 2026

Abstract N°: 4468

When melanoma breaks the rules: limitations of dermoscopy in atypical presentations

Maria Luiza Corrêa Sebba*[1], Ana Beatriz Gomes Cordovil[1], Julia Dionisio Lima[2], Allen Becker[1], Caroline Teruszkin Wiedermann[1], Maria Eduarda da Silva Cunha Pinheiro[1], Renata da Gama Cruz Luz[1], Giovana Bueno Fernandes[1], Manuela Attianesi de Freitas Rocha[3], Alice Klajman Agostino[1], Clara Brito Hegedüs[1], Maria Esperança Figueira de Mello Altberg[1], Sofia Rase Chaves[1], Laura Kale Machado Pereira do Amaral Daher[1]

[1] Universidade Estácio de Sá, Rio de Janeiro, Brazil

[2] Universidade do Oeste Paulista, São Paulo, Brazil

[3] Faculdade São Leopoldo Mandic, São Paulo, Brazil

Introduction

Dermoscopy is a diagnostic tool that has significantly improved the early detection of melanoma, being considered essential in dermatology. However, despite its high sensitivity and specificity, certain melanoma subtypes and atypical clinical presentations may not exhibit classic dermoscopic patterns, increasing the risk of delayed diagnosis or misinterpretation. Lesions such as amelanotic, nodular, acral, and spitzoid melanomas may present with subtle, nonspecific, or misleading dermoscopic features, highlighting important limitations of pattern-based diagnostic approaches. This review aims to evaluate the limitations of dermoscopy in atypical melanoma presentations and to discuss the importance of clinical suspicion, multimodal evaluation, and histopathological correlation in challenging diagnostic scenarios.

Materials and Methods

A narrative review was conducted using scientific literature indexed inPubMed, Scopus, Google Scholar, and Embase. The search included the terms “melanoma,” “dermoscopy,” “atypical melanoma,” “amelanotic melanoma,” “nodular melanoma,” “acral melanoma,” “diagnostic challenges,” and “dermoscopic limitations.” Articles addressing atypical dermoscopic presentations, diagnostic pitfalls, false-negative findings, and complementary diagnostic strategies were selected for analysis.

Results

Although dermoscopy substantially increases diagnostic accuracy for pigmented lesions, atypical melanoma presentations remain clinically challenging (Cabrera and Recule, 2018). Amelanotic and hypomelanotic melanomas frequently lack classic pigment networks and melanoma-specific structures, often mimicking inflammatory, vascular, or benign proliferative lesions (Pizzichetta et al., 2014). Nodular melanomas may demonstrate symmetrical growth patterns and minimal lateral extension, limiting the applicability of traditional dermoscopic algorithms and increasing the risk of delayed diagnosis (Cabrera and Recule, 2018; Lallas et al., 2019). Similarly, acral and spitzoid melanomas may exhibit variable or ambiguous dermoscopic findings, particularly in early stages, making clinicopathological correlation essential (Lallas et al., 2019; Pampena et al., 2023).

Additional factors such as chronic sun-damaged skin, regression structures, inflammatory changes, and lesion location may further complicate dermoscopic interpretation (Cabrera and Recule, 2018). Overreliance on standardized dermoscopic criteria alone may therefore contribute to false-negative evaluations in selected cases. Current evidence suggests that dermoscopy should be integrated with comprehensive clinical examination, longitudinal monitoring, patient history, total-body skin assessment, and histopathological evaluation when diagnostic uncertainty persists (Pampena et al., 2023).

Emerging technologies, including reflectance confocal microscopy and artificial intelligence-assisted image analysis, may improve diagnostic support in difficult presentations; however, these tools should complement rather than replace clinical judgment.

Conclusions

Dermoscopy remains one of the most valuable noninvasive tools for melanoma detection; however, atypical melanoma presentations continue to represent important diagnostic challenges. Awareness of dermoscopic limitations is essential to avoid delayed diagnosis and improve clinical outcomes. A broader diagnostic approach integrating dermoscopy, clinical evaluation, complementary imaging techniques, and histopathological correlation may enhance diagnostic accuracy when melanoma does not follow conventional patterns.

EA DV CONGRESS
VIENNA
30 SEP - 3 OCT 2026

Abstract N°: 4496

Advanced Cutaneous Melanoma in the Immunotherapy Era: a 10-Year Real-World Prognostic Cohort from a Tertiary Dermatology Center

Francisco Mano*[1], Inês Antunes[2], Joana Calvão[1], Inês Coutinho[1], Ricardo Vieira[1]

[1] Hospital University of Coimbra, ULS Coimbra, Faculty of Medicine of the University of Coimbra, Coimbra, Portugal

[2] Faculty of Medicine of the University of Coimbra, Coimbra, Portugal

Introduction

Systemic therapy has substantially changed the prognosis of advanced cutaneous melanoma, yet outcomes remain heterogeneous in real-world practice. Unlike clinical trials, routine-care cohorts may also capture the influence of geographic and healthcare-access factors on outcomes. We aimed to characterize survival outcomes and prognostic factors in a 10-year real-world cohort of patients with advanced cutaneous melanoma treated with systemic therapy during the immunotherapy era.

Materials and Methods

We conducted a retrospective single-center study including adults with cutaneous melanoma who received at least one line of systemic therapy between January 2014 and September 2025. Demographic, clinicopathological, molecular and baseline clinical variables were collected. Overall survival (OS) and progression-free survival (PFS) were estimated using Kaplan–Meier analysis. Survival curves were compared with the log-rank test. Prognostic factors were assessed using univariable and multivariable Cox regression.

Results

A total of 194 patients were included. Median age at systemic therapy initiation was 65.1 years [55.7–73.1], and 53.6% were male. At first-line treatment, 56.7% were treated in the palliative setting. Median OS was 51.4 months (95%CI 32.9–not reached), with estimated OS rates of 78.6%, 57.4% and 45.0% at 1, 3 and 5 years, respectively. Median PFS was 14.5 months (95%CI 9.7–19.3), with estimated PFS rates of 53.0%, 33.0% and 19.6% at 1, 3 and 5 years. Survival was significantly better in the adjuvant setting than in the palliative setting for both OS ($p<0.001$) and PFS ($p=0.005$). In multivariable analysis, baseline LDH was the most consistent adverse prognostic factor for both OS (HR 3.16, $p<0.001$) and PFS (HR 2.13, $p<0.001$). Male sex was independently associated with worse OS (HR 2.41, $p=0.008$) and PFS (HR 2.13, $p=0.002$). Palliative first-line intent remained independently associated with worse OS (HR 2.54, $p=0.010$), but not PFS. Inland residence was independently associated with worse PFS (HR 1.73, $p=0.027$), while BRAF mutation was independently associated with better OS (HR 0.44, $p=0.016$) and PFS (HR 0.47, $p=0.003$).

Conclusions

This 10-year real-world study identified baseline LDH as the most robust prognostic factor in advanced cutaneous melanoma treated with systemic therapy. The independent association between inland residence and worse PFS highlights the added value of real-world data in revealing potential geographic inequalities not easily captured in clinical trials. These findings may help refine prognostic stratification and support strategies to optimize access and continuity of care.

EADV CONGRESS
VIENNA
30 SEP - 3 OCT 2026

Abstract N°: 4508

Statutory Skin Cancer Screening in Germany: Quality, Patient Experience, and Perceived Benefit – A Long-Term Analysis from 2011 to 2025

Matthias Augustin*[1], Andrea Gottschalk[1], Chiara Blomen[2], Christoffer Gebhardt[2], Fanus Shah[1]

[1] Institute of Health Services in Research in Dermatology and Nursing (IVDP), University Medical Center Hamburg-Eppendorf (UKE), Hamburg, Germany

[2] University Medical Center Hamburg-Eppendorf (UKE), Hamburg, Germany

Introduction

Statutory skin cancer screening (sSCS) represents a key instrument of secondary prevention in Germany. Beyond participation rates, perceived quality, perceived benefits and harms are critical determinants of screening acceptance. This study aimed to examine the experiences of sSCS participants, including perceived benefit and harm, quality of physician counselling, provider preferences, waiting times, and psychological burden associated with follow-up, and to analyse trends across five survey waves.

Materials and Methods

Cross-sectional telephone survey data (CATI) were obtained from a population-representative sample of statutory health-insured adults aged 18 years and older in Germany, collected by the FORSA Institute across five independent survey waves (2011, 2013, 2015, 2019, and 2025; each approx. n=1,000). Participants were selected via random sampling; data were weighted by age, sex, educational attainment, and region. Descriptive analyses were performed for each survey wave.

Results

Among those who had ever undergone sSCS, the large majority reported that the benefits outweighed the harms, with the lowest rate recorded in 2015 (83%) and 90% in 2025. Only 3% of participants in 2025 reported a predominance of disadvantages; poor perceived examination quality and lack of trust in the physician were cited most frequently. Perceived quality of physician counselling showed a moderate decline over time: the proportion informed about what to expect during screening decreased from 71% (2019) to 64% (2025), preventive advice from 72% (2019) to 67% (2025), and the opportunity to ask questions from 73% (2015) to 67% (2025). sSCS was most commonly performed by dermatologists (79% in 2025), who were also the preferred provider when all respondents were asked about their preference (69%), compared to 8% preferring general practitioners. Waiting times for appointments were considerable, with 50% of participants waiting five weeks or longer in 2025, reflecting a shift toward longer waiting times compared to 2019 (28%). Among the 10% of participants in whom an abnormal finding was identified, 36% waited three weeks or longer for follow-up results. The psychological burden of waiting was limited overall, with 15% rating the wait as very or fairly distressing.

Conclusions

Participants consistently perceive sSCS as predominantly beneficial. However, a moderate decline in perceived counselling quality and increasing waiting times, particularly regarding standardised counselling practices and timely access to appointments, represent areas requiring attention. Given the limited evidence on patient-reported outcomes in skin cancer screening, these findings highlight the value of incorporating participants' perspectives

into quality assessment and underscore the need for continuous patient-centred evaluation to guide programme development and sustain screening quality.

EADV CONGRESS
VIENNA
30 SEP - 3 OCT 2026

Abstract N°: 4510

Integrated Biomarker Response to Photodynamic Therapy in Actinic Keratosis: Effects on Proliferation, Inflammation, Mast Cell Infiltration and Angiogenesis.

Justyna Ceryn*[1], Aleksandra Lesiak[1], Magdalena Ciazynska[2], Karol Ciazynski[3], Olga Stasikowska-Kanicka[4], Joanna Narbutt[1]

[1] Department of Dermatology, Paediatric Dermatology and Dermatological Oncology, Medical University of Lodz, Poland, Lodz, Poland

[2] Chemotherapy Sub-Department and One-Day Chemotherapy Department, Specialist Oncological Hospital NU-MED sp. z o. o., Tomaszów Mazowiecki, Poland, Tomaszów Mazowiecki, Poland

[3] Institute of Applied Computer Science, Lodz University of Technology, Lodz, Poland, Lodz, Poland

[4] Department of Diagnostic Techniques in Pathomorphology, Medical University of Lodz, Lodz, Poland, Lodz, Poland

Introduction

Actinic keratosis (AK) is a UV-induced intraepidermal neoplasia and a marker of field cancerization, with a recognized potential for progression to cutaneous squamous cell carcinoma. Photodynamic therapy (PDT) is an established field-directed treatment; however, its broader effect on the inflammatory, angiogenic and proliferative microenvironment of AK remains incompletely defined. This study aimed to integrate clinical, dermatoscopic and immunohistochemical data on the effects of 5-aminolevulinic acid PDT on mast cells, microvessel density, Ki67, p53 and COX-2 expression in AK.

Materials and Methods

This prospective single-centre study included 31 adults with histopathologically confirmed, previously untreated AK. Patients underwent three sessions of 5-aminolevulinic acid PDT at four-week intervals, using red light at 630 ± 5 nm, 37 J/cm² and 40 mW/cm² after a three-hour occlusion period. Clinical and dermatoscopic assessments were performed at baseline and eight weeks after the final PDT session. Biopsies from AK lesions, apparently healthy skin and post-treatment AK sites were analysed immunohistochemically. Mast cell infiltration was assessed using mast cell tryptase, angiogenesis using CD31-defined microvessel density, proliferation using Ki67 and p53, and inflammation using COX-2.

Results

All patients demonstrated clinical and dermatoscopic improvement after PDT. Complete clinical clearance was achieved in 17/31 patients (54.8%), while the remaining 14 patients (45.2%) regressed to Olsen grade 1; no residual grade 2 or 3 lesions were observed after treatment. Dermatoscopically, complete clearance was documented in 8/31 patients (25.81%), whereas the remaining cases showed a reduction in dermatoscopic severity, with no post-treatment grade III lesions. At baseline, AK lesions showed a marked increase in mast cell infiltration and microvessel density compared with clinically uninvolved skin, confirming activation of the inflammatory–angiogenic axis within the cancerized field. Following PDT, mast cell count decreased from 24.13 ± 7.38 to 13.29 ± 5.25 cells/HPF, and microvessel density decreased from 25.03 ± 7.87 to 14.55 ± 5.18 vessels/HPF. Despite this reduction, the positive relationship between mast cell infiltration and angiogenesis persisted after therapy, suggesting residual biological activity within treated fields. PDT also significantly attenuated key markers of keratinocyte proliferation, dysplasia-related molecular alteration and inflammation: Ki67 expression decreased

from 2.70 ± 1.16 to 1.51 ± 1.02, p53 from 2.38 ± 1.68 to 0.87 ± 1.20, and COX-2 from 2.51 ± 0.57 to 1.74 ± 0.77. Reductions in Ki67, p53 and COX-2 correlated with improvement in both clinical Olsen grading and dermatoscopic severity. Treatment was generally well tolerated. Adverse events occurred in 18 patients (58.1%), predominantly mild local burning or pinching sensations; severe burns were observed in two patients.

Conclusions

Three-session 5-aminolevulinic acid PDT induced meaningful clinical and dermatoscopic regression of AK and produced concordant reductions in proliferative, inflammatory, mast-cell and angiogenic biomarkers. These findings suggest that PDT acts not only through direct cytotoxicity against dysplastic keratinocytes, but also through partial remodelling of the tumour-supportive microenvironment within the cancerized field. Persistent post-treatment biomarker activity, particularly within the mast cell–angiogenesis axis, may indicate residual biological field activity and supports further studies evaluating repeated or combined treatment strategies and long-term recurrence risk.

EADV CONGRESS
VIENNA
30 SEP - 3 OCT 2026

Abstract N°: 4513

Adenoid Basal Cell Carcinoma: A Series of 5 Patients

Hamzaoui Soumia*[1], chikhbled nadjet[1], Serradj Amina[1], samia khalifa[2]

[1] Oran University Hospital Establishment, Department of Dermatology, Oran Faculty of Medicine, Oran, Algeria
[2] Oran University Hospital Establishment, Department of Anatomical Pathology, Oran Faculty of Medicine, Oran, Algeria

Introduction

Basal cell carcinoma (BCC) is the most common skin tumor (1). Among its histological subtypes is adenoid BCC, a rare variant of the nodular subtype (2). We report a series of five cases of adenoid BCC.

Materials and Methods

This was a prospective study conducted over a period of five years, from September 2019 to August 2024, at the University Hospital Establishment of Oran , involving patients with BCC. Data were collected using a pre-established data sheet

Results

Among the 178 BCC lesions recorded, five corresponded to the adenoid form, representing 2.8% of patients. The characteristics of these five patients were as follows: the mean age was 68.2 years, ranging from 61 to 77 years; the male-to-female ratio was 1.5 (3 men and 2 women); and the predominant phototype was type III. Intermittent sun exposure was reported in three patients (60%). None of the patients had a history of radiotherapy, phototherapy, or tanning bed use. The mean duration of lesion evolution was 90.4 months, ranging from 20 to 240 months. Clinically, the lesions presented as erythematous-pigmented nodules and plaques, with ulceration in two patients. The mean lesion size was 37 mm, ranging from 15 to 60 mm. Eighty percent of lesions were located on the head and neck, with one lesion on the abdomen; the remainder of the physical examination was unremarkable. Adenoid BCC was confirmed histologically, showing pseudoglandular structures composed of basaloid cells with peripheral palisading nuclei. All patients underwent surgical excision. The outcome was favorable, with no recurrence, after a two-year follow-up.

Conclusions

Adenoid BCC is a rare and indolent variant of BCC. The reported incidence is 1.3% [3]. It is considered a histological variant of the nodular type according to the WHO 2018 classification [4]. Adenoid BCC occurs most often in sun-exposed areas but can also affect extra-facial locations. Clinically, it generally presents as a firm nodular lesion with slow growth, sometimes ulcerated or pigmented, which may resemble a sebaceous cyst or other BCC variants [5]. Histological examination shows pseudoglandular structures composed of basaloid cells, sometimes requiring immunohistochemistry to exclude differential diagnoses, mainly cutaneous adenoid cystic carcinoma and primary cutaneous apocrine cribriform carcinoma [4]. Adenoid BCC is treated like other BCC subtypes, primarily by surgical excision. Its slow and minimally aggressive course confers a favorable prognosis [5]. Our findings regarding adenoid BCC are largely consistent with those from our overall BCC study (178 cases) regarding epidemiological aspects (age, sex, phototype), except for the duration of evolution, which was longer in adenoid BCC cases. Furthermore, they are in agreement with previously reported data on adenoid BCC in terms of rarity, clinicopathological features, and favorable outcome.

EADV Congress 2026, VIENNA
30 SEPTEMBER - 03 OCTOBER 2026
POWERED BY M-ANAGE.COM

EA DV CONGRESS
VIENNA
30 SEP - 3 OCT 2026

Abstract N°: 4514

Mycosis Fungoides: Epidemiological, Clinicopathological, Therapeutic, and Prognostic Features in a 16-Year Retrospective Study

Maissa Abid*[1], Rim Chaabouni[1], Marwa Bouhamed[2], Hamida Turki[1]

[1] Dermatology Department, Hedi Chaker Hospital, Sfax, Tunisia, Sfax, Tunisia

[2] Anatomy pathology department, Hbib Bourguiba Hospital, Sfax, Tunisia, Sfax, Tunisia

Introduction

Mycosis fungoides (MF) is the most common primary cutaneous T-cell lymphoma. Its heterogeneous clinical and histopathological presentation, together with its unpredictable course, makes diagnosis and management particularly challenging. This study aimed to analyze the epidemiological, clinical, therapeutic, and prognostic features of MF in our center.

Materials and Methods

We conducted a retrospective monocentric study including 103 patients diagnosed with MF over a 16-year period (2009–2024). Epidemiological, clinical, histopathological, therapeutic, and outcome data were analyzed.

Results

The mean annual incidence was 6.4 cases/year, increasing from 3.3 cases/year during 2009–2015 to 8.7 cases/year during 2016–2024. MF predominantly affected men (male-to-female ratio: 2:1) with a mean age of 54.4 years. Most patients originated from urban areas (76.7%). Smoking was reported in 31.1% of patients, while 14.6% had occupational exposure to potential carcinogens. Pruritus was present in 92.2% of cases. Classical MF accounted for 74.8% of cases. Plaque lesions were observed in 88.3% of patients, mainly involving photo-protected areas (94.2%), particularly the flanks. Tumoral lesions and erythroderma were noted in 10.4% and 14.3% of cases, respectively. Other clinicopathological variants included hyperpigmented MF (9.7%), folliculotropic MF (6.8%), hypopigmented MF (6.8%), and poikilodermatous MF (1.9%). Clinically detectable lymphadenopathy was present in 31.1% of patients. At diagnosis, 52.4% of patients were stage IA, 36.9% stage IB, and 7.8% stage IIIA.

In early-stage disease, complete remission rates were 59% with topical corticosteroids, 66.7% with UVA phototherapy, 72.2% with narrowband UVB, 66.7% with acitretin, 60% with methotrexate, and 100% with combined acitretin-phototherapy therapy. In tumoral MF, partial remission rates reached 66.7% with methotrexate in non-transformed MF and 75% with CHOP chemotherapy in transformed MF. Among erythrodermic MF cases, complete remission was achieved in 27.3% with methotrexate and 66.7% with narrowband UVB. Disease progression to advanced stages occurred in 15.5% of patients, and eight deaths were recorded after a mean delay of 3.4 years, all in patients with tumor transformation.

Multivariate analysis identified several significant predictors of progression to advanced-stage disease, including male sex (OR: 3.6; p=0.01), smoking history exceeding 20 pack-years (OR: 3.9; p=0.01), infiltrated plaques (OR: 2.8; p=0.02), clinically detectable lymphadenopathy (OR: 2.5; p=0.03), the folliculotropic variant (OR: 2.3; p=0.02), and a dense lymphocytic infiltrate (OR: 4.7; p=0.001). In contrast, age, occupational exposure, and history of atopy were not significantly associated with disease progression.

Conclusions

MF demonstrates marked clinicopathological heterogeneity and remains a therapeutic challenge. This study highlights the epidemiological and clinicopathological characteristics of MF in our region and identifies several prognostic factors associated with disease progression, which may help optimize risk stratification and therapeutic management.

EADV CONGRESS
VIENNA
30 SEP - 3 OCT 2026

Abstract N°: 4523

Statutory Skin Cancer Screening in Germany: Attitudes and Uptake in the General Population – A 15 years analysis

Fanus Shah*[1, 2], Chiara Blomen[2], Andrea Gottschalk[1], Christoffer Gebhardt[2], Matthias Augustin[1, 2]

[1] Institute of Health Services in Research in Dermatology and Nursing (IVDP), University Medical Center Hamburg-Eppendorf (UKE), Hamburg, Germany

[2] University Medical Center Hamburg-Eppendorf (UKE), Hamburg, Germany

Introduction

Statutory skin cancer screening (sSCS) was introduced in Germany in 2008 to enable early detection of skin cancer and thereby reduce morbidity and mortality. Despite its established availability, evidence suggests persistently moderate uptake alongside substantial knowledge and attitudinal barriers. This study aimed to assess general attitudes toward preventive examinations, ever-participation in sSCS, timing of last participation, sources of information on statutory entitlement, and reasons for non-participation, and to analyse temporal trends across five survey waves.

Materials and Methods

Data were derived from population-representative computer-assisted telephone interviews (CATI) of statutory health-insured adults aged 18 years and older in Germany, conducted by the FORSA Institute. A repeated cross-sectional design was applied, encompassing survey waves from 2011, 2013, 2015, 2019, and 2025 (2011: n=1,014; 2013: n=1,004; 2015: n=1,004; 2019: n=1,015; 2025: n=1,004). Samples were drawn using random sampling procedures and weighted for age, sex, educational attainment, and region. Analyses were descriptive and exploratory-comparative.

Results

General endorsement of preventive examinations exceeded 90% in both 2019 and 2025. Concern about skin cancer fluctuated over the observation period, ranging from 40% (2019) to 51% (2013), with 48% reporting concern in 2025. Ever-participation in sSCS increased moderately over the observation period: 28% (2011), 35% (2013), 39% (2015), 42% (2019), and 46% (2025). Among those who had ever participated, the majority reported their most recent screening within the past two years (57% in 2024/2025), while 21% had last participated in 2022/2023 and smaller proportions reported earlier attendance. Between 56% (2011) and 51% (2025) of respondents were unaware of their statutory entitlement to screening. Among those aware of their statutory entitlement (n=490 in 2025), information sources shifted over time (multiple responses permitted), with awareness through health insurers increasing from 32% (2015) to 36% (2025) and through personal networks from 20% (2015) to 27% (2025). Among those who had never participated (n=542 in 2025), the most frequently reported reasons for non-participation (multiple responses permitted) were perceived good health (59%) and lack of awareness of the programme (47%).

Conclusions

Although uptake of sSCS has increased since its introduction, overall participation rates leave considerable room for improvement. A pronounced intention–behaviour gap persists, driven primarily by knowledge deficits and low risk perception. Insufficient awareness of the statutory entitlement and shifting information pathways underscore the need for targeted public health communication strategies and stronger integration of physician recommendation with policy-level interventions.

EA DV CONGRESS
VIENNA
30 SEP - 3 OCT 2026

Abstract N°: 4529

UV-Related Risk Behaviour and Preventive Awareness in the German Population: A Long-Term Analysis from 2011 to 2025

Fanus Shah*[1, 2], Andrea Gottschalk[1], Chiara Blomen[2], Christoffer Gebhardt[2], Matthias Augustin[1]

[1] Institute of Health Services in Research in Dermatology and Nursing (IVDP), University Medical Center Hamburg-Eppendorf (UKE), Hamburg, Germany

[2] University Medical Center Hamburg-Eppendorf (UKE), Hamburg, Germany

Introduction

Skin cancer ranks among the most prevalent malignancies globally, with cumulative UV exposure representing the most important modifiable risk factor. Primary prevention efforts therefore focus on reducing UV-related risks, including the restriction of artificial UV sources such as solarium use. This study investigated temporal changes in UV-related risk behaviour, risk perception, and awareness of preventive programmes in the German general population, with particular emphasis on solarium use and its association with skin cancer screening behaviour.

Materials and Methods

Selected items from a standardised questionnaire were analysed, covering solarium use, concern about skin cancer, barriers to sSCS participation, and knowledge of statutory entitlement. The questionnaire was administered via computer-assisted telephone interviews (CATI) to a nationally representative sample of adults with statutory health insurance in Germany, spanning five survey waves (2011, 2013, 2015, 2019, and 2025; each approx. n=1,000). Sampling followed a random procedure with post-stratification weighting for age, sex, educational level, and region. Analyses were descriptive and comparative across survey waves.

Results

Solarium use declined over the observation period. The proportion reporting any use in the preceding twelve months fell from 9% (2013) to 4% (2025), with regular use decreasing from 2% to 1% and occasional use from 7% to 3%. Concern about skin cancer showed no consistent trend, fluctuating between 40% (2019) and 51% (2013), with 48% reporting concern in 2025. Notable increases were observed among men (30% in 2019 vs. 40% in 2025) and adults aged 18–29 years (23% in 2019 vs. 50% in 2025). Among those who had never attended sSCS, perceived good health was the most consistently cited reason across survey waves (60% in 2019; 59% in 2025), while insufficient programme knowledge grew as a barrier from 39% (2019) to 47% (2025). Respondents expressing concern about skin cancer showed higher sSCS attendance rates, whereas a relevant proportion of solarium users had never undergone screening.

Conclusions

The substantial decline in solarium use points to a positive impact of regulatory measures and health education initiatives. Nevertheless, risk perception remained moderate and variable, and programme awareness as a barrier to screening participation increased over time. These findings highlight the need for integrated prevention approaches that link UV risk reduction with improved communication about statutory screening entitlements to

foster comprehensive preventive behaviour.

EADV CONGRESS
VIENNA
30 SEP - 3 OCT 2026

Abstract N°: 4536

A retrospective audit assessing adherence to NICE guidance on the documentation and referral of suspected melanoma in primary care

Ria Bhatt*[1]

[1] University of Lancashire, Preston, United Kingdom

Introduction
Melanoma is an aggressive form of skin cancer with significant metastatic potential and high mortality if diagnosed late. Early recognition and timely referral from primary care are essential to improve outcomes. NICE guidance recommends the use of the weighted 7-point checklist to assess suspicious pigmented skin lesions and urgent referral through the suspected cancer pathway for lesions scoring 3 or more. This audit assessed adherence to NICE guidance regarding documentation and referral practices for suspected melanoma in a primary care setting.

Materials and Methods
A retrospective audit was conducted using electronic patient records over a 52-week period. Adult patients coded as having suspected skin cancer, suspected melanoma, or a 2-week-wait skin cancer referral were identified. Patients with benign lesions, confirmed melanoma diagnosed elsewhere, deceased patients, and patients under 18 years were excluded. Data collected included documentation of the weighted 7-point checklist, referral pathway used, and time interval between referral and dermatology review. Audit standards were derived from NICE NG12 guidance.

Results
A total of 48 patient records were identified, of which 20 met the inclusion criteria following manual review. Compliance with documentation of the weighted 7-point checklist was 75% (15/20), exceeding the predefined audit standard of 70%. Compliance with review within 2 weeks following referral was 60% (12/20), below the target standard of 90%.

Conclusions
This audit demonstrated good compliance with NICE guidance regarding documentation of the weighted 7-point checklist in patients presenting with suspicious pigmented skin lesions. However, adherence to timely referral within the suspected cancer pathway did not meet the expected standard, highlighting an area for improvement in patient pathway efficiency.

To address these findings, a few interventions are recommended. Firstly, the introduction of a structured electronic clinical template within the documentation system incorporating the weighted 7-point checklist would promote consistent and complete documentation. Secondly, implementation of mandatory prompts within the electronic record when coding suspected skin lesions would support completion of the checklist and reduce omission errors. Finally, refresher training for primary care clinicians on the recognition of suspicious pigmented lesions and appropriate use of the 2-week-wait referral pathway would help standardise assessment and improve confidence in referral decision-making.

Re-audit following implementation of these measures would also be recommended to assess improvement in compliance and patient pathway outcomes.

EADV Congress 2026, VIENNA
30 SEPTEMBER - 03 OCTOBER 2026
POWERED BY M-ANAGE.COM

EA DV CONGRESS
VIENNA
30 SEP - 3 OCT 2026

Abstract N°: 4553

Malignant Transformation of Erythema Ab Igne: A Systematic Review

Sanaz Lordfard*[1], Nandi Edwards[1], Durr Al-Mohammed[2], Katya Peri[3], Rafael Lansang[4], Anastasiya Muntyanu[4]

[1] Temerty Faculty of Medicine, University of Toronto, Toronto, Canada
[2] Faculty of Science, University of Western Ontario, London, Canada
[3] Faculty of Medicine and Health Sciences, McGill University, Montreal, Canada
[4] Division of Dermatology, Department of Medicine, University of Toronto, Toronto, Canada

Introduction
Erythema ab igne (EAI) is a cutaneous reaction pattern caused by chronic heat exposure, presenting as reticulated erythema and/or hyperpigmentation. Although often considered benign, longstanding EAI has demonstrated potential to transform to cutaneous malignancy due to chronic inflammation and subsequent DNA damage. There have been reports of pre-neoplastic change in EAI biopsies. This review aimed to characterize malignant transformation in EAI.

Materials and Methods
This review was conducted in accordance with PRISMA 2020 reporting guidelines and registered on PROSPERO (CRD420261298750). MEDLINE, Embase, and Web of Science were searched from inception to January 2026 using keywords related to EAI. Eligible studies included full-text primary research involving patients with cutaneous malignant transformation arising in EAI lesions.

Results
The search identified 4186 unique studies, of which 22 met inclusion criteria, comprising 483 patients. Risk of bias was assessed using the Joanna Briggs Institute Critical Appraisal Checklist, with studies categorized as low (27.3 %), moderate (59.0%), or high quality (13.7 %). Included cases were predominantly female (65.9%), with a mean age of 51.2 years (range 41.5-92) at time of malignant transformation. When reported, most patients were of Kashmiri ethnicity (n = 226), followed by Indian (n = 10), Black (n = 5), White (n = 2), and Japanese (n = 2).

Among 289 cases with reported heat exposure duration, most involved prolonged exposure: 118 cases reported durations of >10 years, and 166 were described qualitatively as long-term. The latency from EAI onset to malignant transformation had a mean of 27.8 years (range 3-60). Of the 483 patients included, 416 specifically outlined malignancy type. Squamous cell carcinoma (SCC) was the most common malignancy (n = 411, 85.1%), with invasive SCC reported 6-fold more frequently than in situ SCC, when specified. There were also rare cases of simultaneous merkel cell carcinoma and SCC (n = 2), cutaneous marginal zone lymphoma (n = 1), poorly differentiated carcinoma (n = 1), and basal cell carcinoma (n = 1). One study reported several malignancies at a rate of <20%, but no exact breakdown was provided. The most common management strategy was surgery with adjuvant radiation therapy (n = 106), followed by wide local excision alone (n = 65) (Table 1). Follow-up was limited and inconsistently reported. Among 124 patients (mean follow-up 2.8 years; range 4 months–10 years), 39 recurrences were reported.

Table 1. Characteristics of malignant transformation occurring in erythema ab igne lesions.

		N (%)
Latency (years) (reported in 119 patients)		
	Weighted Mean	27.8
	Range	3-60
Cancer type (reported in 483 patients)		
	Squamous cell carcinoma (SCC)	411 (85.1)
	In-situ SCC	26
	Invasive SCC	161
	In-situ + invasive SCC	1
	Not reported	223
	Merkel cell carcinoma + squamous cell carcinoma	2 (0.4)
	Cutaneous marginal zone lymphoma	1 (0.2)
	Poorly differentiated	1 (0.2)
	Basal cell carcinoma	1 (0.2)
	Other[1*]	67 (13.9)
Biopsy-confirmed cases		
	Yes	356
	Not reported	127
Malignancy treatment (reported in 191 patients)		
	Surgery + radiation therapy	106
	Wide local excision only	65
	Amputation	8
	Excision + graft	4
	Declined treatment	2
	Excision + graft + lymph node dissection + radiation therapy	1
	Curettage + electrocautery + radiation therapy	1
	Cryotherapy + 5-fluorouracil	1
	Imiquimod cream	1
	Mohs	1
	Radiation therapy	1

[1]* Other includes atypical fibroxanthoma, basal cell carcinoma, cutaneous marginal zone lymphoma, dermatofibrosarcoma protuberans, extramammary paget's disease, melanoma, merkel cell carcinoma, microcystic adnexal carcinoma, sebaceous carcinoma, squamous cell carcinoma, undifferentiated pleomorphic sarcoma. Specific number of patients for each cancer type was not consistently reported in the study.

Conclusions

This systematic review highlights that malignant transformation of EAI is a possible long-term complication of chronic heat exposure. The marked predominance of SCC in this cohort supports a shared pathogenic mechanism with other forms of chronic cutaneous injury, such as burn scars and chronic ulcers. These findings stress the importance of counselling on heat avoidance when EAI is diagnosed. Lesions demonstrating atypical changes

should prompt biopsy to rule out malignant transformation. This study is limited by its reliance on case reports and series, limiting generalizability of findings. Additionally, Kashmiri patients are overrepresented in this review, likely reflecting chronic exposure to traditional kangri baskets that may not apply to other populations.

EA DV CONGRESS
VIENNA
30 SEP - 3 OCT 2026

Abstract N°: 4569

Temporal Trends and Demographic Disparities in Chemotherapy and Radiation Utilization for Vulvar Squamous Cell Carcinoma Across 2000-2021: a SEER retrospective analysis

Carli Tucci*[1], Archie Spindler[1], Lynn Liu[2], Miriam Pomeranz[2], John Carucci[2], Maressa Criscito[2]

[1] New York University Grossman School of Medicine, New York, United States

[2] The Ronald O. Perelman Department of Dermatology, New York University Grossman School of Medicine, New York, United States

Introduction

Vulvar squamous cell carcinoma (vSCC) accounts for ~90% of vulvar malignancies.[1] Historically, vSCC was managed with radical vulvectomy with bilateral inguinofemoral lymphadenectomy. Treatment has since shifted toward multimodal treatment with radiation and chemotherapy.[2] Population-level data on temporal trends and factors influencing utilization of these modalities remain limited. We aimed to characterize temporal trends in radiation and chemotherapy receipt among patients with vulvar squamous cell carcinoma from 2000–2021. Additionally, we identify demographic, clinicopathologic, geographic, and temporal factors associated with radiation and chemotherapy receipt in vulvar squamous cell carcinoma.

Materials and Methods

A retrospective SEER analysis (2000-2021) of 18 population-based cancer registries (~28% of the U.S. population) was performed. vSCC cases were using ICD-O-3 histology codes 8050–8086 (excluding verrucous carcinoma) and vulvar site codes C51.0–C51.9. Patient demographics, tumor characteristics, and were analyzed in RStudio using univariable and multivariable logistic regressions.

Results

Among 18,299 vSCC cases, radiation and chemotherapy receipt increased over time. On univariate analysis, radiation therapy was associated with age ≥60 years, increasing tumor size, regional and distant disease, diagnosis in 2015–2021, Hispanic, Non-Hispanic Black, and non-Hispanic Asian or Pacific Islander race. Greater odds of chemotherapy were associated with larger tumor size, regional and distant disease, diagnosis after 2004, and Hispanic and non-Hispanic Black race. On multivariate analysis, larger tumor size, regional and distant disease, and later year of diagnosis remained significant independent predictors of both increased radiation and chemotherapy (all $p<0.05$). Nonmetropolitan residence remained a significant predictor of lower odds of radiation ($p=0.04$). Differences in radiation and chemotherapy receipt by race were no longer significant.

Conclusions

This population-based analysis demonstrates evolving vSCC management, with increased radiation and chemotherapy use over time. Treatment utilization was primarily driven by increased disease burden, including larger tumor size, overlapping vulvar lesions, and advanced disease stage, which aligns with NCCN guidelines recommending radiation therapy with concurrent chemotherapy for locally advanced, unresectable vSCC.[2] After adjustment for disease-specific factors, race was not an independent predictor of radiation and chemotherapy use, whereas larger tumor size and advanced stage remained significant predictors. These findings suggest that

previously observed racial differences in treatment utilization may reflect differences in disease severity at presentation rather than race itself, helping clarify mixed prior reports on race and stage in vSCC.[3,4] Additionally, lower odds of radiation and chemotherapy among nonmetropolitan areas may reflect reduced access to oncologic care and treatment facilities.

1. Sheern C, Levell NJ, Craig PJ, et al. Vulval squamous cell carcinoma: a review.*Clinical and Experimental Dermatology*. 2025;51(1):1-13. doi:10.1093/ced/llaf389
2. Vulvar Cancer. Published online February 2026.
3. Rauh-Hain JA, Clemmer J, Clark RM, et al. Racial disparities and changes in clinical characteristics and survival for vulvar cancer over time. *American Journal of Obstetrics and Gynecology*. 2013;209(5):468.e1-468.e10. doi:10.1016/j.ajog.2013.07.021
4. Chase DM, Lin CC, Craig CD, et al. Disparities in Vulvar Cancer Reported by the National Cancer Database: Influence of Sociodemographic Factors. *Obstetrics & Gynecology*. 2015;126(4):792-802. doi:10.1097/AOG.0000000000001033